

## CONTINUING MEDICAL EDUCATION

# Carpal and Cubital Tunnel and Other, Rarer Nerve Compression Syndromes

Hans Assmus, Gregor Antoniadis, Christian Bischoff

## SUMMARY

**Background:** Carpal tunnel syndrome is by far the most common peripheral nerve compression syndrome, affecting approximately one in every six adults to a greater or lesser extent. Splitting the flexor retinaculum to treat carpal tunnel syndrome is the second most common specialized surgical procedure in Germany. Cubital tunnel syndrome is rarer by a factor of 13, and the other compression syndromes are rarer still.

**Methods:** This review is based on publications retrieved by a selective literature search of PubMed and the Cochrane Library, along with current guidelines and the authors' clinical and scientific experience.

**Results:** Randomized controlled trials have shown, with a high level of evidence, that the surgical treatment of carpal tunnel syndrome yields very good results regardless of the particular technique used, as long as the diagnosis and the indication for surgery are well established by the electrophysiologic and radiological findings and the operation is properly performed. The success rates of open surgery, and the single-portal and dual-portal endoscopic methods are 91.6%, 93.4% and 92.5%, respectively. When performed by experienced hands, all these procedures have complication rates below 1%. The surgical treatment of cubital tunnel syndrome has a comparably low complication rate, but worse results overall. Neuro-ultrasonography and magnetic resonance imaging (neuro-MRI) are increasingly being used to complement the diagnostic findings of electrophysiologic studies.

**Conclusion:** Evidence-based diagnostic methods and treatment recommendations are now available for the two most common peripheral nerve compression syndromes. Further controlled trials are needed for most of the rarer syndromes, especially the controversial ones.

### ► Cite this as:

Assmus H, Antoniadis G, Bischoff C: Carpal and cubital tunnel and other, rarer nerve compression syndromes. *Dtsch Arztebl Int* 2015; 112: 14–26.  
DOI: 10.3238/arztebl.2015.0014

**P**eripheral nerve compression syndromes involve chronic irritation and pressure lesions where nerves pass through anatomical bottlenecks and fibro-osseous canals. The characteristic tunnel syndromes are distinct from acute pressure injuries to a nerve caused by an external compression or blow at a site where a nerve courses superficially over a bony prominence, and from nerve stretching injuries across joints, although mixed injuries also arise. The main clinical manifestations of nerve compression syndromes are paresthesiae, sensory impairment, and paresis (1). The diagnosis is established by the history and physical examination, along with the findings of electrophysiologic studies and imaging (1). Nerve compression syndromes are not life-threatening and generally not disabling, yet they are nonetheless very disturbing for the affected patients.

Carpal tunnel syndrome is by far the most common and most important peripheral nerve compression syndrome. It can generally be diagnosed from the history and physical examination alone on the basis of its typical symptoms and signs. Nonetheless, in our experience, it is often misdiagnosed as a C7 syndrome or as a “circulatory disturbance” such as Raynaud’s disease. Cubital tunnel syndrome, also called ulnar neuropathy at the elbow, is the second most common peripheral nerve syndrome; it is 13 times rarer than carpal tunnel syndrome (2). It was once commonly called “sulcus ulnaris syndrome,” especially in the German-speaking countries, but this designation has been dropped because it described the site of the lesion too imprecisely and seemed to imply a justification for invasive transposition procedures that are now only rarely performed. The available S3 guidelines for these two conditions

(Former Practice of Peripheral Nerve Surgery in Dossenheim/Heidelberg): Dr. med. Assmus, neurosurgeon and neurologist, Schriesheim (near Heidelberg)

District Hospital of Günzburg (Neurosurgical Department of the University of Ulm): Prof Dr. med. Antoniadis  
Neurology Group Practice Marienplatz, Munich: Prof. Dr. med. Bischoff

## Definition

**Peripheral nerve compression syndromes involve chronic irritation and pressure lesions where nerves pass through anatomical bottlenecks and fibro-osseous canals.**

**TABLE 1**

**Compression syndromes and focal nerve lesions (from [3])**

Classic / typical compression syndromes	Combined forms (with pressure or stretch lesions)	Controversial and/or very rare compression syndromes	Atypical syndromes / occupational palsies
Carpal tunnel syndrome Supinator syndrome Morton's metatarsalgia Meralgia paresthetica Cheiralgia (Wartenberg syndrome) Symptomatic tarsal tunnel syndrome	Cubital tunnel syndrome Loge de Guyon syndrome Peroneal nerve compression syndrome	Pronator / anterior interosseous nerve syndrome Idiopathic tarsal tunnel syndrome Thoracic outlet syndrome (TOS) Piriformis syndrome Radial tunnel syndrome Pudendal neuralgia Suprascapular nerve compression syndrome	Intraneural ganglion Compartment syndrome Nerve torsion Nerve lesions in athletes, musicians, etc.

serve as the basis for this review (2, 3). The other compression syndromes are much rarer, and some of them are controversial (Table 1). They are discussed in the second part of this review.

The topic of peripheral nerve compression syndromes is dealt with in greater depth in a current monograph (3). A book including a thorough discussion of all aspects of carpal tunnel syndrome was published in 2002 (4).

**Learning objectives**

This review article should enable readers to:

- diagnose carpal tunnel syndrome, determine whether surgery is indicated, and know the differences between open and endoscopic surgery for carpal tunnel syndrome;
- diagnose cubital tunnel syndrome and know what conservative and surgical treatments are available;
- be aware of the neurogenic causes of sensory disturbances and pain in the limbs, particularly in the feet, and their differential diagnosis.

**Methods**

Our search for pertinent literature on the carpal and cubital tunnel syndromes was based on the respective S3 guidelines for the diagnosis and treatment of these two conditions (2, 3), which are up to date as of 2014 and have been extended to include discussion of the rarer compression syndromes. We searched for randomized controlled trials (RCTs), systematic reviews, and guidelines in the Medline (PubMed) database, the Cochrane Library, guideline databases (the home-

pages of the German specialty societies and organizations [AWMF and ÄZQ]), and the homepages of the following international specialty societies and organizations:

- Guideline International Network (GIN),
- Scottish Intercollegiate Guideline Network (SIGN),
- National Institute for Health and Care Excellence (NICE),
- National Guideline Clearinghouse (NGC).

**Carpal tunnel syndrome**

Carpal tunnel syndrome is by far the most common peripheral nerve compression syndrome (3, 4). Some 300 000 operations to treat carpal tunnel syndrome are performed in Germany every year, 90% of them on an outpatient basis (5). Carpal tunnel release is the second most common specialized outpatient surgical procedure in the country, after cataract surgery. Precise case numbers are unavailable, as the German Association of Statutory Health Insurance Physicians (*Kassenärztliche Bundesvereinigung*, KBV) has not published any newer statistics on the frequency of operations since the introduction of the new Uniform Fee Scale (*Einheitlicher Bewertungsmaßstab*, EBM). Carpal tunnel syndrome is due to (chronic) median nerve compression in the carpal tunnel (Figure 1).

**Prevalence and incidence**

In a study on the adult population of southern Sweden, the prevalence of typical symptoms of carpal tunnel syndrome was 14.8%, while that of electrophysiologically verified carpal tunnel syndrome was 4.9% (3).

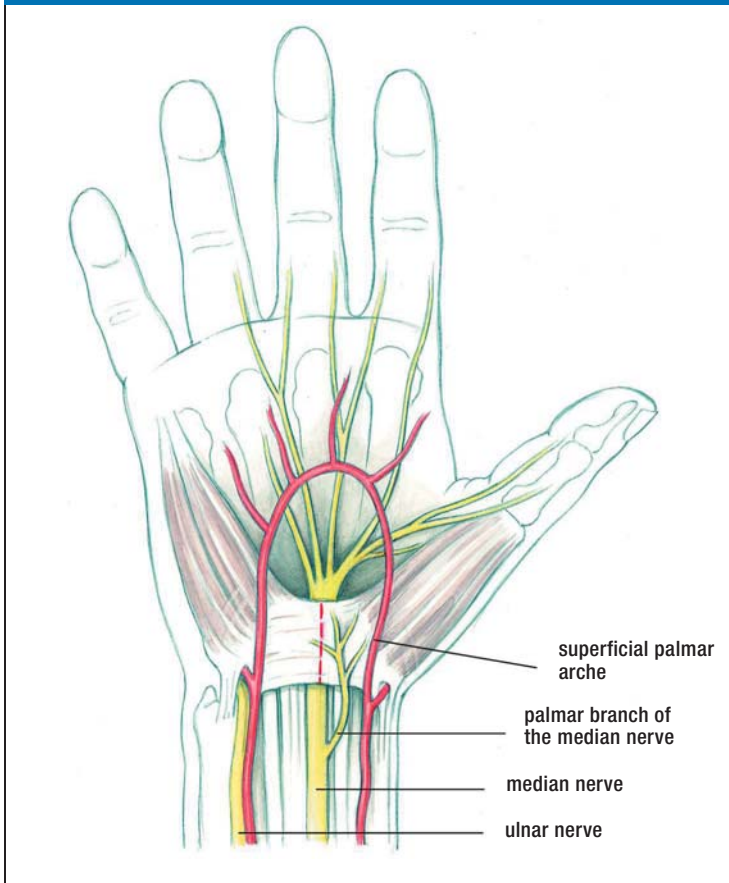
**Carpal tunnel syndrome**

**Carpal tunnel syndrome is by far the most common peripheral nerve compression syndrome.**

**Incidence**

**The incidence of carpal tunnel syndrome is >3 new cases per 1000 persons per year. Women are affected 3 to 4 times as commonly as men.**

FIGURE 1



**The carpal tunnel** Topographical anatomy of the carpal tunnel and of the course of the median nerve under the flexor retinaculum (the dotted line marks the incision) (3).

The incidence of the condition was more than 3 new cases per 1000 persons per year (3). Among affected persons, the female-to-male ratio is between three and four to one. Prevalence is associated with age; it is highest in the fifth and sixth decades (4). Carpal tunnel syndrome usually arises bilaterally, but the dominant hand is somewhat more commonly affected, and usually more intensely. In our experience, carpal tunnel syndrome often runs in families (e1). It does not seem to be related to any particular hand position used while typing on a computer keyboard (e2).

The symptoms of carpal tunnel syndrome often arise in the setting of an episode of tenosynovitis or (perhaps

occupational) overuse of the hand, or during pregnancy (3). Carpal tunnel syndrome is recognized as an occupational disorder in persons who perform certain activities involving repetitive flexion and extension of the wrist (e.g., working on a conveyor belt, meat packing, gardening, playing a musical instrument) (5).

The initial and main symptom of carpal tunnel syndrome is a painful pins-and-needles sensation in the hand(s), primarily at night (brachialgia paresthetica nocturna) (1, 3, 4). In more advanced cases, the patient may suffer from numbness of the thumb and middle three fingers and difficulty performing fine manual work. Thenar muscle atrophy is seen only in very advanced cases. The diagnosis can be established by electrophysiology and imaging (*Box 1*).

Physical examination involves a search for sensory and motor deficits, as well as two clinical screening tests—the Hoffman–Tinel sign and the Phalen test. Even if the history and physical findings are entirely typical of carpal tunnel syndrome, an electrophysiologic study should be performed to confirm the diagnosis definitively and to provide a baseline for follow-up studies.

Imaging studies—high-resolution neuro-ultrasonography and magnetic resonance imaging—are now coming into more common use but are not yet the diagnostic methods of first choice. A meta-analysis of 19 clinical trials of these imaging methods yielded overall figures of 77.6% sensitivity and 86.8% specificity (6); in comparison, sensory neurography is 89% sensitive and 98% specific (7). A current evidence-based guideline includes a recommendation for imaging studies as a useful complement to electrodiagnostic studies, particularly for the demonstration of structural changes at the wrist (8).

The main differential diagnoses of carpal tunnel syndrome are C7 syndrome (occasionally, C6 syndrome) and polyneuropathy. The following criteria suggest that a radicular syndrome is present:

- the paresthesiae cannot be “shaken out”;
- they extend beyond the median nerve distribution;
- they are present more or less continuously and are made worse by head movement, coughing, and Valsalva maneuvers.

Carpal tunnel syndrome is sometimes seen in combination with radiculopathy or diabetic neuropathy. Carpal tunnel syndrome is more common in persons with diabetic neuropathy (30%) than in persons without it (14%) (9).

### Initial symptom

The initial and main symptom of carpal tunnel syndrome is a painful pins-and-needles sensation in the hand(s), primarily at night (brachialgia paresthetica nocturna).

### Conservative treatment

In the early stage of the condition, nocturnal splinting of the wrist and local corticoid infiltration can be recommended.

**Treatment**

Carpal tunnel syndrome needs to be treated when its typical manifestations are present frequently or persistently and are severe enough to impair the patient's quality of life. On the other hand, a positive electrophysiologic finding without any corresponding symptoms requires no treatment.

**Conservative treatment**—In the early stage of the condition, nocturnal splinting of the wrist and local corticoid infiltration can be recommended as treatments whose efficacy has been documented in prospective randomized trials (10, e3). Splinting has been found effective over the long term; corticoid infiltration provides relief for four weeks at most (3). There is no evidence that treatment with nonsteroidal anti-inflammatory drugs brings any significant lasting benefit (3).

Therapeutic ultrasound application, exercises, and mobilization techniques (including yoga) are only marginally superior to placebo (e3–e5) and cannot be recommended as treatment options.

The decision when to terminate conservative treatment and proceed to surgery largely depends on the patient's degree of suffering, rather than on any objective finding. In general, surgery should be performed before a persistent neurologic deficit arises.

**Surgical treatment**—The following are indications for surgery:

- persistent sensory impairment;
- intractable nocturnal pain and paresthesiae that keep the patient awake at night.

Multiple randomized controlled trials have documented the superiority of surgery (both open and endoscopic) to conservative treatment, especially with respect to long-term results (11–15). Surgery must involve the complete splitting of the flexor retinaculum. The operation is now performed on an outpatient basis in nearly all cases; it can also be performed during pregnancy or on a patient who is very old, diabetic, or undergoing dialysis for end-stage renal failure (3).

The available surgical techniques are summarized in *Table 2*. The simplest and most common treatment, which is also the treatment of choice, is open splitting of the flexor retinaculum.

Minimally invasive techniques are currently just as safe as open surgery when performed in experienced hands (e6) and yield comparable results, as

**BOX 1**

**The diagnostic evaluation of carpal tunnel syndrome (1)**

- **History**
  - hands “falling asleep”: typical and nearly pathognomonic early symptom
  - paresthesiae improve or disappear when the hands are “shaken out”
  - often, both hands are affected; therefore, commonly misdiagnosed as a cervical spine syndrome, cervical myelopathy, or polyneuropathy
  - persistent numbness and a loss of fine motor control are late symptoms
- **Physical examination**
  - the neurological examination is usually normal in the early stage
  - clinical tests such as the Phalen (hand flexion) test are unreliable as screening methods for early median nerve compression
- **Neurography**
  - distal motor latency of median nerve >4.2 ms (distance, 7 cm); recommended as a standard measurement because of its high specificity
  - prolongation of distal motor latency of median nerve compared to ulnar nerve when measured from the 2<sup>nd</sup> interdigital space, >0.4 ms
  - sensory nerve conduction velocity (NCV) of the median nerve lower than that of ulnar nerve by more than 8 m/s (most sensitive method) (sensory neurography)
- **Imaging**
  - demonstration of a pseudoneuroma proximal to the site of stenosis as increased cross-sectional area in a high-resolution neuro-ultrasonogram
  - obtain an MRI if a tumor is suspected

has been confirmed in comparative randomized trials (12).

The most commonly used endoscopic instrumentation systems are the single-portal Agee system and the dual-portal Chow system. Endoscopically assisted splitting of the flexor retinaculum is performed with an instrument resembling a pistol (the Agee system) or with various knives introduced through guide tubes (the Chow system). Endoscopic carpal tunnel release has a longer learning curve than the open procedure; the surgeon must be adequately trained in endoscopic technique (16). According to a

**Ineffective treatments**

**Therapeutic ultrasound application, exercises, and mobilization techniques (including yoga) are only marginally superior to placebo and cannot be recommended as treatment options.**

**The surgical treatment of choice**

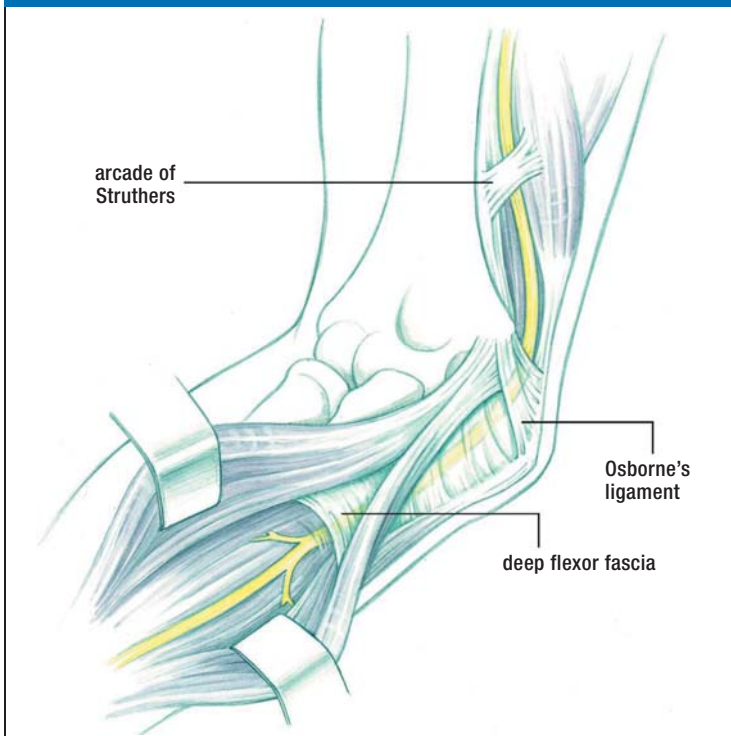
**The simplest and most common surgical treatment, which is also the treatment of choice, is open splitting of the flexor retinaculum.**

**TABLE 2**

**Surgical methods of retinaculum splitting (from [3])**

Method	Advantages	Disadvantages	Remarks
Open retinaculum splitting (normal incision, 3–4 cm)	Simple, inexpensive, safe	Larger scar than other methods	Standard method
Open retinaculum splitting (mini-incision, ca. 2 cm)	Smaller scar; possible earlier return to full wrist movement	Risk of incomplete retinaculum splitting and of nerve injury	An alternative to the standard method
Single-portal endoscopy (Agee method)	The pistol-like apparatus is easy to manipulate (one-hand technique)	Costly; special training needed (learning curve) because of the (low) risk of neural and vascular injury	No clear advantage over the standard open methods
Dual-portal endoscopy (Chow method)	Good control of the knife assures that the cut is in the intended direction; cheaper than single-portal technique	Special training needed (learning curve) because of the risk of injury to the common digital nerve	No clear advantage over the standard open methods
Semi-open, endoscopically assisted techniques (Preissler, Krishnan, Hoffmann, and others)	Relatively easy to learn, incision somewhat smaller than with the standard open methods	No particular disadvantages	No clear advantage, not widely used, application depends on the surgeon's personal experience

**FIGURE 2**



The most common site of ulnar nerve compression, where the nerve passes through the cubital tunnel under Osborne's ligament (3)

current meta-analysis of pertinent publications, most of which contain relatively low-level evidence (17), endoscopic carpal tunnel release has the same complication rate as open surgery but is associated with an earlier recovery of hand strength and a more rapid return to work.

Patients should perform functional exercises beginning in the first few days after surgery. On the other hand, patients who have undergone surgery without any complications do not need postoperative rehabilitation measures such as wrist orthoses, cold therapy, laser therapy, multimodal hand rehabilitation, electrotherapy, or scar desensitization. There is insufficient evidence for the efficacy of any of these treatments (18).

Timely surgery yields very good results, with documented success rates as follows:

- open surgery, 91.6%;
- single-portal endoscopic surgery, 93.4%;
- dual-portal endoscopic surgery, 92.5%.

The complication rate in experienced hands is less than 1% (4), over both the short and the long term (4, e6). Surgery is beneficial even in advanced cases with sensory impairment and muscle atrophy, and even in elderly patients (1); the pain and sensory impairment tend to improve, but the muscle atrophy is generally irreversible (1, 4). True recurrence of carpal tunnel syndrome after initially effective

**The success rates of surgery are:**

- open surgery, 91.6%
- single-portal endoscopic surgery, 93.4%
- dual-portal endoscopic surgery, 92.5%

**Elderly patients**

**Surgery is beneficial even in advanced cases with sensory impairment and muscle atrophy, and even in elderly patients.**

treatment is rare. In our experience, true recurrence accounted for only 27% of reoperations and was usually seen in dialysis patients (e7).

Improper surgical technique and poor intraoperative exposure may lead to incomplete splitting of the retinaculum and, in turn, to persistent or progressive symptoms that will necessitate a second, corrective surgical procedure (e7, e8).

### Cubital tunnel syndrome (ulnar neuropathy at the elbow)

Cubital tunnel syndrome involves compression and irritation of the ulnar nerve at the elbow. It is the second most common nerve compression syndrome and was previously called the sulcus ulnaris syndrome. Neurologists know it as ulnar neuropathy at the elbow (Figure 2).

Cubital tunnel syndrome involves compression in the cubital tunnel under Osborne's ligament, often with a contributory component from nerve stretching. It is classified as either primary (idiopathic), including anatomical variants such as ulnar nerve subluxation or an epitrochleo-anconeus muscle, or secondary (symptomatic), including delayed ulnar palsy due to trauma or elbow arthrosis. Secondary cubital tunnel syndrome can also be caused by extra-neural or, less commonly, intraneural masses, such as a lipoma or ganglion.

The incidence of cubital tunnel syndrome is 24.7 cases per 100 000 persons per year, which is one-thirteenth that of carpal tunnel syndrome. It is roughly twice as common in men as in women (2). In our experience, the left side is affected almost three times as often as the right, making a further contrast to carpal tunnel syndrome (3, 19) (Box 2). The most common differential diagnoses are an acute pressure-related ulnar nerve palsy after prolonged lying on, or propping oneself up with, the elbow, and acute C8 or T1 radiculopathy due to an irritative or compressive lesion.

#### Treatment

Mild cases with a recent history can be treated conservatively at first. Nocturnal elbow splinting can markedly improve symptoms. According to a recent clinical study, there is no consensus regarding the optimal type or duration of splinting (e9). Surgery should be performed before the development of muscle atrophy, which is largely irreversible (2).

### Cubital tunnel syndrome

Cubital tunnel syndrome involves compression or irritation of the ulnar nerve at the elbow.

#### BOX 2

### The diagnostic evaluation of cubital tunnel syndrome (3)

- **History**
  - onset often acute, with numbness or paresthesiae of the 4<sup>th</sup> and 5<sup>th</sup> fingers
  - aching pain in the forearm
  - atrophy of the intrinsic muscles of the hand, often not noticed by the patient
  - delayed paresis after old elbow joint injury
- **Physical examination**
  - hypesthesia of the ulnar 1 1/2 digits, the ulnar side of the dorsum of the hand, and the hypothenar eminence
  - positive Froment sign
  - incomplete or absent adduction of the little finger
  - tenderness and (often) thickening of the ulnar nerve at the elbow / in the sulcus ulnaris
  - less commonly, subluxation of the ulnar nerve
  - atrophy of the intrinsic muscles of the hand innervated by the ulnar nerve, with abnormal claw posture of the 4<sup>th</sup> and 5<sup>th</sup> fingers
- **Neurography**
  - lowering of the motor nerve conduction velocity in the elbow segment of the ulnar nerve by more than 16 m/s compared to its forearm segment
  - significantly lowered amplitude (by at least 40%) of the motor response potential after stimulation proximal to the cubital tunnel, compared to stimulation distal to it
  - prolonged proximal latency (can be followed longitudinally over the patient's further course)
- **Imaging**
  - with high-resolution neuro-ultrasonography, demonstration of changes in the size and position of the ulnar nerve at the elbow (also of changes in the echo texture of the nerve)
  - magnetic resonance neurography (MRN) enables the visualization of structural changes of the ulnar nerve and its environment

### Differential diagnosis

The most common differential diagnoses are an acute pressure-related ulnar nerve palsy after prolonged lying on, or propping oneself up with, the elbow, and acute C8 or T1 radiculopathy due to an irritative or compressive lesion.

**TABLE 3**

**Advantages and disadvantages of surgical methods of treating cubital tunnel syndrome (from [3])**

Method	Advantages	Disadvantages	Remarks
Open decompression	Simple technique, low risk	Note exceptions	Now the standard method for most cases, including with luxation and subluxation
Endoscopically assisted (in situ) decompression	Small incision, low risk, possible over a long distance	Occasionally, subcutaneous hematoma in a wide area; rarely, nerve injury	Competes with the open method
Subcutaneous (or submuscular) transposition	Indicated in cases of cubitus valgus and severe post-traumatic conditions	Endangerment of blood supply, operative risks (kinking of the nerve)	Requires extensive operative experience
Epicondylectomy (with decompression and/or transposition), partial/minimal epicondylectomy	Less traumatic than deep submuscular transposition	Risk of joint instability; this risk is lower if the epicondylectomy is only partial or minimal	Less commonly used in the German-speaking countries than in the USA and elsewhere

Surgery is indicated in case of (2, 19):

- progressive symptoms,
- sensorimotor deficits,
- lack of clinical and electroneurographic improvement, or
- worsening of the objective findings on follow-up several weeks after the initial visit.

**Surgical treatment**—A variety of surgical methods can be used to treat cubital tunnel syndrome. There has been a paradigm shift over the past decade: according to representative statistics from the USA, the percentage of treatments by nerve transposition has declined from 49% to 38%, while the overall number of surgical procedures has increased by 47% (20). The method of choice is a simple decompression in which the cubital tunnel retinaculum is completely opened in an open surgical procedure through an incision measuring 4 to 6 cm in length (19). Endoscopically assisted decompression is now being increasingly performed. The initial findings in a prospective, blinded trial have not revealed any clear superiority of endoscopy over open surgery (personal communication from Prof. Schroeder, Neurosurgery, Greifswald). The long-term results of anterior transposition (63.1 months of follow-up) are identical to those of decompression (52 months of follow-up) (21). Primary subcutaneous transposition of the ulnar nerve, perhaps accompanied by a partial epicondylectomy, should be considered or preferred in cases with marked anatomical changes in the elbow joint (2) (Table 3).

**Results**

Multiple meta-analyses and systematic reviews have not revealed any statistically significant difference between the outcomes of simple decompression and anterior transposition (whether subcutaneous or submuscular) (2). The transposition procedures had more frequent complications.

For milder cases, the findings of a randomized controlled trial suggest that conservative treatment is best, with avoidance of unfavorable arm positions and movements (22, 23).

Minimal medial epicondylectomy is an alternative to subcutaneous anterior transposition of the ulnar nerve (e10). No predictive factors for the success of the latter procedure could be identified in either of the two studies in which this was tried (24, 25). The second study (25) concerned painful cubital tunnel syndrome.

Overall, the results of surgery for cubital tunnel syndrome are not as good as those of surgery for carpal tunnel syndrome (23). Muscle atrophy of more than one year’s duration is generally only partly reversible, if at all. The rate of recurrence of cubital tunnel syndrome after endoscopic or open decompression is 12.2% (e11).

**Rarer and controversial compression syndromes**

An overview of these compression syndromes, which affect the upper and the lower limbs, is found in Tables 4 and 5.

**Surgery for cubital tunnel syndrome**

The method of choice is a simple decompression in which the cubital tunnel retinaculum is completely opened in an open or endoscopic surgical procedure.

**Treatment outcomes**

Multiple meta-analyses and systematic reviews have not revealed any statistically significant difference between the outcomes of simple decompression and anterior transposition (whether subcutaneous or submuscular).

**TABLE 4**

**Synopsis of the rarer compression syndromes and neuropathies of the shoulder girdle and the upper limb**

	Neurogenic thoracic outlet syndrome (TOS)	Suprascapular nerve syndrome	Supinator tunnel syndrome	Pronator teres / anterior interosseous nerve syndrome	Wartenberg syndrome (cheiralgia)	Loge de Guyon syndrome (distal ulnar nerve compression)
Cause	Anomalies (including fibromuscular) of the upper thoracic aperture, cervical rib	Ganglia, normal anatomic variants, traction injuries in athletes	Compression of the deep radial nerve under the arcade of Frohse, lipomas, and other mass lesions	Possibly inflammatory in lesions of the anterior interosseous nerve or nerve fascicle torsion	Idiopathic compression of the superficial radial nerve	Subacute compression (handlebar palsy, crutch palsy), ganglia
Symptoms	Pain and paresthesiae, particularly when carrying heavy loads and working above the head	Shoulder pain, weakness of external rotation of the arm	Weakness of finger extensors (DD ruptured extensor tendon); if painful, DD tennis elbow	Uncharacteristic in pronator syndrome; in AIN lesion, weakness of thumb and of flexion of the distal phalanx of the index finger	Pain and paresthesiae in the thumb and dorsum of the hand	activity-induced pain (more common if a ganglion is the underlying lesion), weak key grip
Physical findings	Hoffmann–Tinel sign in the supraclavicular fossa, sometimes weakens and atrophy of the small muscles of the hand	Atrophy of the supra- and infraspinatus muscles	Weakness of finger extensors and of ulnar (but not radial) wrist extensor; no sensory deficit	Pathological pinch grip	Positive Finkelstein test, hypesthesia may be absent	Froment sign, atrophy of adductor pollicis; no hypesthesia in exclusive involvement of the deep branch of the ulnar nerve
Electro-physiology	For the exclusion of CTS, CUTS, etc.	EMG	EMG, neurography of the deep radial nerve	EMG	Sensory neurography	Sensory and motor neurography, EMG
Imaging	Magnetic resonance neurography of the brachial plexus; x-ray for cervical rib	MRI to demonstrate ganglia	Demonstration of compression and mass with US and MRI	Potential demonstration of fascicle torsion by MRN or neuro-ultrasonography	Ultrasound	Ultrasound
Treatment	Patient exercises; surgery not recommended, as the evidence base is inadequate	Infiltration to treat pain, surgery to remove ganglia; no RCTs available	Usually surgical; no RCTs available	Controversial; no RCTs	Usually conservative, no RCTs	From expectant to surgical; no RCTs

AIN, anterior interosseous nerve; CTS, carpal tunnel syndrome; CUTS, cubital tunnel syndrome; DD, differential diagnosis; EMG, electromyography; MRI, magnetic resonance imaging; MRN, magnetic resonance neurography; RCT, randomized and controlled trial

**What is known about the rarer compression syndromes, and what remains uncertain?**

Here we will briefly characterize and assess, as well as we can, this mixed group of focal compressive nerve lesions, some of which are still inadequately explained and controversial (*see also Table 1*).

In the supinator tunnel syndrome (syndrome of the posterior interosseous nerve, PIN), the deep radial nerve is compressed under the arcade of Frohse. A systematic review of the treatment of this condition revealed that controlled clinical trials are scarce, but two observational studies provide evidence that sur-

gical decompression of the PIN may be effective in cases of idiopathic compression (26). A space-occupying lesion such as a lipoma or ganglion that causes symptomatic compression of the PIN is a clear indication for surgery. This syndrome is associated with weakness and is not to be confused with the so-called painful supinator tunnel syndrome (also called “tennis elbow”). Studies to date have not revealed a neurogenic origin for the pain in the latter condition, which is its only symptom.

Meralgia paresthetica is pain due to compression of the lateral femoral cutaneous nerve under the

**Supinator tunnel syndrome**

In the supinator tunnel syndrome (syndrome of the posterior interosseous nerve, PIN), the deep radial nerve is compressed under the arcade of Frohse.

**Meralgia paraesthetica**

Meralgia paresthetica is pain due to compression of the lateral femoral cutaneous nerve under the inguinal ligament. Only weak evidence exists to support any treatment recommendation because of a lack of randomized controlled trials.



**TABLE 5**

**Synopsis of rarer peripheral nerve compression syndromes of the lower limb**

	Meralgia paresthetica	(Posterior) tarsal tunnel syndrome	Morton's metatarsalgia	Peroneal nerve compression	Anterior tarsal tunnel syndrome
Cause	Compression of the lateral femoral cutaneous nerve under the inguinal ligament	Compression of the tibial nerve or plantar nerves in the tarsal tunnel or distally; unequivocal only with a tumor	Compression of digital nerves between metatarsal heads, accompanying bursitis	Unknown in most cases; work in squatting position, extra- and intraneural ganglia	Compression of the deep peroneal nerve in the dorsum of the foot; cause often unknown; shoes
Symptoms	Hypesthesia and dysesthesia on the ventrolateral aspect of the thigh	Paresthesia, dysesthesia, and numbness of the sole and toes	"I can't wear tightly fitting shoes any more"	Pain radiating into the leg, weakness of dorsiflexion	Pain in the dorsum of the foot
Physical findings	Tenderness medial to the anterior superior iliac spine	Local tenderness and Hoffmann–Tinel sign	Tenderness in the interdigital space, usually D3/4 (Mulder test); in some cases, hypesthesia of the adjacent sides of toes	Weakness of tibialis anterior and extensor digitorum muscles, tenderness over fibular head, hypesthetic dorsum of foot	Tenderness in the dorsum of the foot, atrophy of the extensor digitorum brevis, hypesthesia on the dorsum of the hallux
Electro-physiology	Sensory neurography optional	Not definitive (Patel 2005); sensory NCV in a comparison of the two sides	Not applicable	Neurography, EMG	Neurography, EMG
Imaging	Ultrasonography difficult	Demonstration of extra- and intraneural mass lesions in the symptomatic form	Ultrasonography as method of 1 <sup>st</sup> choice, otherwise MRI	Ultrasonography, demonstration of a ganglion	Unknown
Treatment	Initially conservative (corticoid injection), surgical in case of intractability; no RCTs available	Unclear for idiopathic origin; generally operative when caused by a mass; no RCTs available	Generally operative by a plantar or dorsal approach; no RCTs	Expectant or operative (ganglion); no RCTs	Expectant or operative; no RCTs

RCT, randomized and controlled trial; NCV, nerve conduction velocity; EMG, electromyography

inguinal ligament. Only weak evidence exists to support any treatment recommendation because of a lack of randomized controlled trials. In the best observational studies performed to date, similar results were observed after treatment with injections, after surgical treatment (by decompression or nerve transection), and without any treatment (27).

Suprascapular nerve syndrome arises both in an idiopathic form, mainly in high-performance athletes (e.g., volleyball and basketball players), and in a symptomatic form, caused by a ganglion. The indication for surgery is intractable pain along with atrophy of the supra- and infraspinatus muscles, if the presence of a ganglion is confirmed by an imaging study. The surgical treatment can be either open or endoscopic (28, e12). No controlled trials of treatment have been performed to date.

Thoracic outlet syndrome (TOS) is one of the more controversial nerve compression syndromes. The diagnosis is hard to make in patients who have pain but no clear-cut neurologic deficit (so-called atypical TOS). It may be that magnetic resonance neurography will bring greater diagnostic certainty in the future (29). A randomized double-blind trial revealed no improvement of pain or paresthesiae after conservative treatments such as botulinum toxin injections in the anterior and medial scalene muscles (30). In the absence of evidence-based criteria for surgical indications, the decision to operate can only be made on a case-by-case basis (31).

Wartenberg syndrome, also called cheiralgia parasthetica, is a rare condition in which compression of the superficial branch of the radial nerve causes pain and paresthesiae on the radial side of the dorsum of

**Thoracic outlet syndrome**

Thoracic outlet syndrome (TOS) is one of the more controversial nerve compression syndromes. The diagnosis is hard to make in patients who have pain but no clear-cut neurologic deficit (so-called atypical TOS).

**Wartenberg syndrome**

Wartenberg syndrome is a rare condition in which compression of the superficial branch of the radial nerve causes pain and paresthesiae on the radial side of the dorsum of the hand, and in the thumb.

the hand, and in the thumb (3). Sensory deficits are rare, and neurography is reliable only if there is a pathological finding. There have been only sporadic case reports of ultrasonographic findings and treatment outcomes, and there have not been any controlled clinical trials on which to base decisions about surgery. External pressure lesions of the cutaneous nerve are more common and are often caused by bracelets with sharp edges.

The symptoms of loge de Guyon syndrome and of distal ulnar nerve compression at the wrist vary depending on the site of the lesion. Isolated compression of the deep branch is more common. It is characterized by a positive Froment sign and by atrophy of the first dorsal interosseous muscle, without any accompanying sensory deficit. It is commonly caused by a ganglion or by external pressure (thus the term “cyclist’s palsy” or “handlebar palsy”). Because of the rarity of this condition, no controlled therapeutic trials have been performed. A ganglion causing progressive neurologic symptoms should be surgically removed. Pressure lesions usually improve spontaneously.

Pronator syndrome, caused by compression of the median nerve just below the elbow, and anterior interosseous nerve syndrome, caused by compression of this nerve, are rare and controversial conditions (32). There are no large case series or controlled therapeutic trials for either. These entities clinically resemble Kiloh-Nevin syndrome, which is presumed to be a form of neuritis. They have been provisionally attributed to fascicle torsion, of uncertain pathogenetic significance, in the main stem of the median nerve and proximal to the origin of the anterior interosseous nerve (33). According to a recently published study, these entities may be related to immunological mononeuropathies such as multifocal motor neuropathy (MMN) (34).

Morton’s metatarsalgia is due to compression of the interdigital nerves by displacement of the neurovascular bundle, usually in the space between the third and fourth toes, and usually with accompanying bursitis. A “spot diagnosis” can often be made on clinical grounds alone if the patient has typical symptoms (“I can’t wear tightly fitting shoes any more”) and a positive Mulder sign. Local infiltration of alcohol has been found ineffective (e13), while local corticoid infiltration has been found effective, but only for a limited time (35). Success rates of

70% to 90% have been reported for surgical excision of the pseudoneuroma through a dorsal (or plantar) approach (36, e14, e15).

Tarsal tunnel syndrome is a controversial entity, at least in cases that cannot be attributed to a mass lesion (ganglion, schwannoma) or prior trauma. The very rare idiopathic type is overdiagnosed (37); this diagnosis is particularly inappropriate when it is not supported by either electrophysiology or imaging. A mass lesion is the only clear indication for surgery. In other cases, no evidence-based treatment recommendation can be made.

Anterior tarsal tunnel syndrome, i.e., idiopathic compression of the distal portion of the deep peroneal nerve under the extensor retinaculum, has been only rarely described and remains poorly diagnosed (e16). Proximal, focal peroneal neuropathy near the fibular head is more common; it is often due to external pressure (e.g., faulty positioning for surgery) or a stretch injury. Surgery for a peroneal nerve palsy is generally indicated where ultrasound reveals an intra- or extraneural ganglion cyst originating from the tibiofibular joint (38).

Multiple decompressions of the tibial nerve and its branches in the tarsal tunnels, and of the peroneal nerve at the knee, were recommended at one time as a putative means of preventing ulcers in patients with diabetic polyneuropathy. It was concluded in a systematic review (39) that there is no evidence from randomized controlled trials, or from well-documented prospective studies, to support the efficacy of this treatment. Further studies have been published since then, some of them with large numbers of cases (e17–e19); nevertheless, the benefit of decompressive surgery of this type cannot be definitively assessed at present.

Piriformis syndrome, another controversial compression syndrome, is said to be due to compression of the sciatic nerve in the infrapiriform foramen. There is no validated diagnostic or therapeutic procedure for piriformis syndrome (e20). Attempts have been made to treat it with local infiltration of local anesthetic agents, corticoids, and botulinum toxin, usually under imaging guidance (computed tomography or ultrasound) (e21, e22).

Compression syndromes of the ilioinguinal and iliohypogastric nerves are rare. They can arise as the result of a traumatic hematoma, or else iatrogenically after inguinal hernia repair, urologic

### Morton’s metatarsalgia

Morton’s metatarsalgia is due to compression of the interdigital nerves by displacement of the neurovascular bundle, usually in the space between the third and fourth toes, and usually with accompanying bursitis.

### Controversial compression syndromes

Piriformis syndrome is a controversial compression syndrome said to be due to compression of the sciatic nerve in the infrapiriform foramen. There is no validated diagnostic or therapeutic procedure for piriformis syndrome.

procedures, laparoscopy, vascular puncture, or iliac crest biopsy.

Diagnostic and therapeutic nerve blocks are ineffective in the management of pain after inguinal hernia repair (e23).

The clinical experience with pudendal neuralgia as a putative cause of pain in the perineal region is similarly problematic. Electrophysiologic studies have only limited sensitivity and specificity for this condition, which is diagnosed on clinical grounds (e24). Surgical decompression has been reported to be of limited efficacy in two-thirds of cases (e25).

**Conflict of interest statement**

The authors declare that no conflict of interest exists.

Manuscript submitted on 27 June 2014, revised version accepted on 31 July 2014.

Translated from the original German by Ethan Taub, M.D.

**REFERENCES**

1. Assmus H, G: Die Kompressionssyndrome des N. medianus. In: Assmus H, Antoniadis G (eds.): Nervenkompressionssyndrome. 3<sup>rd</sup> edition. Berlin, Heidelberg: Springer 2015; 45–94.
2. Assmus H, Antoniadis G, Bischoff C, et al.: Diagnostik und Therapie des Kubitaltunnelsyndroms. AWMF-Leitlinienregister Nr. 005–009. [www.awmf.org/uploads/tx\\_szleitlinien/005-009l\\_abgelaufen.pdf](http://www.awmf.org/uploads/tx_szleitlinien/005-009l_abgelaufen.pdf) (last accessed on 11 September 2014)
3. Assmus H, Antoniadis G, Bischoff C, et al.: Diagnostik und Therapie des Karpaltunnelsyndroms. AWMF-Leitlinienregister Nr. 005–003 [www.awmf.org/uploads/tx\\_szleitlinien/005-003l\\_S3\\_Karpaltunnelsyndrom\\_Diagnostik\\_Therapie\\_2012-06.pdf](http://www.awmf.org/uploads/tx_szleitlinien/005-003l_S3_Karpaltunnelsyndrom_Diagnostik_Therapie_2012-06.pdf) (last accessed on 11 September 2014)
4. Rosenbaum RB, Ochoa JL. Carpal tunnel syndrome and other disorders of the median nerve. 2<sup>nd</sup> ed. Amsterdam: Butterworth Heinemann 2002.
5. Giersiepen K, Spallek M: Carpal tunnel syndrome as an occupational disease. *Dtsch Arztebl Int* 2011; 108: 238–42.
6. Fowler JR, Gaughan JP, Ilyas AM: The sensitivity and specificity of ultrasound for the diagnosis of carpal tunnel syndrome: a metaanalysis. *Clin Orthop Relat Res* 2011; 469: 1089–94.
7. AAEM American Association of Electrodiagnostic Medicine: Practice parameter for electrodiagnostic studies in carpal tunnel syndrome. *Muscle Nerve* 2002; 25: 918–22.
8. Cartwright MS, Hobson-Webb LD, Boon AJ, et al.: Evidence based guideline: neuromuscular ultrasound for the diagnosis of carpal tunnel syndrome. *Muscle Nerve* 2012; 46: 287–93.
9. Bahrmann A, Zieschang T, Hein G, Oster P: Karpaltunnelsyndrom bei Diabetes mellitus. *Med Klin* 2010; 105: 150–4.

10. Marshall S, Tardif G, Ashworth N: Local steroid injection for carpal tunnel syndrome. *Cochrane Database Syst Rev*. 2007; 2: CD001554.
11. Huisstede BM, Randsdorp MS, Coert JH, et al.: Carpal tunnel syndrome. Part II: Effectiveness of surgical treatment—a systematic review. *Arch Phys Med Rehabil* 2010; 91: 1005–24.
12. Scholten RJ, Mink van der Molen A, Uitdehaag BM, et al.: Surgical treatment options for carpal tunnel syndrome. *Cochrane Database Syst Rev* 2007; 17: CD003905.
13. Verdugo RJ, Salinas RS, Castillo J, Cea JG: Surgical versus non-surgical treatment for carpal tunnel syndrome. *Cochrane Database Syst Rev* 2003; 3: CD001552.
14. Shi Q, MacDermid JC: Is surgical intervention more effective than non-surgical treatment for carpal tunnel syndrome? A systematic review. *J Orthop Res* 2011; 6: 17.
15. Vasilidiadis HS, Georgoulas P, Shrier I, et al.: Endoscopic release for carpal tunnel syndrome. *Cochrane Database Syst Rev* 2014; 1: CD008265
16. AAOS: American Academy of Orthopaedic Surgeons. Clinical practice guideline on the treatment of carpal tunnel syndrome. Rosemont: 2008.
17. Kretschmer T, Antoniadis G, Richter HP, König RW: Avoiding iatrogenic nerve injury in endoscopic carpal tunnel release. *Neurosurg Clin N Am* 2009; 20: 65–71.
18. Peters S, Page MJ, Coppieters MW, et al.: Rehabilitation following carpal tunnel release. *Cochrane Database Syst Rev* 2013; 6: CD004158.
19. Assmus H, Antoniadis G, Bischoff C, et al.: Cubital tunnel syndrome—a review and management guidelines. *Cent Eur Neurosurg* 2011; 72: 90–8.
20. Soltani AM, Best MJ, Francis CS, et al.: Trends in the surgical treatment of cubital tunnel syndrome: an analysis of the national survey of ambulatory surgery database. *J Hand Surg Am* 2013; 38: 1551–6.
21. Keiner D, Gaab MR, Schroeder HW, et al.: Comparison of the long-term results of anterior transposition of the ulnar nerve or simple decompression in the treatment of cubital tunnel syndrome—a prospective study. *Acta Neurochir (Wien)* 2009; 151: 311–5.
22. Macadam SA, Bezuhyly M, Lefavre KA: Outcomes measures used to assess results after surgery for cubital tunnel syndrome: a systematic review of the literature. *J Hand Surg Am* 2009; 34: 1482–91.
23. Caliendo P, La Torre G, Padua R, et al.: Treatment for ulnar neuropathy at the elbow. *Cochrane Database Syst Rev*. 2012; 7: CD006839.
24. Shi Q, MacDermid JC, Santaguida PL, Kyu HH: Predictors of surgical outcomes following anterior transposition of ulnar nerve for cubital tunnel syndrome: a systematic review. *J Hand Surg Am* 2011; 36: 1996–2001. e1–6.
25. Rinkel WD, Schreuders TA, Koes BW, Huisstede BM: Current evidence for effectiveness of interventions for cubital tunnel

- syndrome, instability, or bursitis of the elbow: a systematic review. *Clin J Pain* 2013; 29: 1087–96.
26. Huisstede BM, Miedema HS, van Opstal T, et al.: Interventions for treating the radial tunnel syndrome: a systematic review of observational studies. *J Hand Surg Am* 2008; 33: 72–8.
  27. Khalil N, Nicotra A, Racovicz W: Treatment for meralgia paraesthetica. *Cochrane Database Syst Rev* 2008; 16: CD004159 und 2012; 12: CD004159.
  28. Antoniadis G, Richter HP, Rath S, et al.: Suprascapular nerve entrapment: experience with 28 cases. *J Neurosurg* 1996;85:1020–25.
  29. Baumer P, Kele H, Kretschmer T, et al: Thoracic outlet syndrome in 3T MR neurography-fibrous bands causing discernible lesions off the lower brachial plexus. *Eur Radiol* 2014; 24: 756–61.
  30. Finlayson HC, O'Connor RJ, Brasher PM, Travlos A: Botulinum toxin injection for management of thoracic outlet syndrome: a double-blind, randomized, controlled trial. *Pain* 2011; 152: 2023–8.
  31. Povlsen B, Belzberg A, Hansson T, Dorsi M: Treatment for thoracic outlet syndrome. *Cochrane Database Syst Rev* 2010; 20: CD007218.
  32. Rodner CM, Tinsley BA, O'Malley MP: Pronator syndrome and anterior interosseous nerve syndrome. *J Am Acad Orthop Surg* 2013; 21: 268–75.
  33. Ochi K, Horiuchi Y, Tazaki K, Takayama S, Matsumura T: Fascicular constrictions in patients with spontaneous palsy of the anterior interosseous nerve and the posterior interosseous nerve. *J Plast Surg Hand Surg* 2012; 46: 19–24.
  34. Pham M: MR-Neurographie zur Läsionslokalisation im peripheren Nervensystem. Warum, wann und wie? *Nervenarzt* 2014; 85: 221–37.
  35. Thomson CE, Beggs I, Martin DJ, et al.: Methylprednisolone injections for the treatment of Morton's neuroma: a patient-blinded randomized trial. *J Bone Joint Surg Am* 2013; 95: 790–8.
  36. Assmus H: Die Morton-Metatarsalgie. Ergebnisse der operativen Behandlung bei 54 Fällen. *Nervenarzt* 1994; 65: 238–40.
  37. Antoniadis G, Scheglmann K: Posterior tarsal tunnel syndrome: diagnosis and treatment. *Dtsch Arztl Int* 2008; 105: 776–81.
  38. Spinner RJ, Atkinson JLD, Scheithauer BW, et al.: Peroneal intraneural ganglia: the importance of the articular branch. *Clinical series. J Neurosurg* 2003; 99: 319–29.
  39. Chaudry V, Russell J, Belzberg A: Decompression surgery of lower limbs for symmetrical diabetic peripheral neuropathy. *Cochrane Database Syst Rev*. 2008; 3: CD006152.
  40. Dellon AL; Muse VL, Nickerson DS et al.: Prevention of ulceration, amputation, and reduction of hospitalization: outcomes of a prospective multicenter trial of tibial neurolysis in patients with diabetic neuropathy. *J Reconstr Microsurg* 2012; 28: 241–6.

**Corresponding author**

Dr. med. Hans Assmus  
 Abtsweg 13,  
 69198 Schriesheim, Germany  
 hans-assmus@t-online.de



For eReferences please refer to:  
[www.aerzteblatt-international.de/ref0115](http://www.aerzteblatt-international.de/ref0115)

eFigure 1, 2, 3:  
[www.aerzteblatt-international.de/15m0014](http://www.aerzteblatt-international.de/15m0014)

**Further information on CME**

This article has been certified by the North Rhine Academy for Postgraduate and Continuing Medical Education. Deutsches Ärzteblatt provides certified continuing medical education (CME) in accordance with the requirements of the Medical Associations of the German federal states (Länder). CME points of the Medical Associations can be acquired only through the Internet, not by mail or fax, by the use of the German version of the CME questionnaire. See the following website: [cme.aerzteblatt.de](http://cme.aerzteblatt.de).

Participants in the CME program can manage their CME points with their 15-digit “uniform CME number” (einheitliche Fortbildungsnummer, EFN). The EFN must be entered in the appropriate field in the [cme.aerzteblatt.de](http://cme.aerzteblatt.de) website under “meine Daten” (“my data”), or upon registration. The EFN appears on each participant’s CME certificate.

This CME unit can be accessed until 29 March 2015 and will be inactivated on 30 March 2015.

Earlier CME units can be accessed until the dates indicated:

“The Diagnosis of Chronic Obstructive Pulmonary Disease” (issue 49/2014) until 1 March 2015

“Chronic and Treatment Resistant Depression” (issue 45/14) until 1 February 2015

“Physical Examination in Child Sexual Abuse” (issue 41/14) until 4 January 2015

Please answer the following questions to participate in our Continuing Medical Education program. Only one answer is possible per question. Please select the answer that is most appropriate.

**Question 1**

**What is the most sensitive test for the early diagnosis of carpal tunnel syndrome?**

- a) distal motor latency
- b) sensory neurography
- c) electromyography
- d) neuro-ultrasonography
- e) neuro-MRI

**Question 2**

**What is absolutely essential in the surgical treatment of carpal tunnel syndrome?**

- a) The motor branch must be exposed.
- b) An epineurotomy must be performed.
- c) The retinaculum must be completely split.
- d) The wrist must be immobilized in a cast.
- e) A synovectomy must be performed.

**Question 3**

**What syndrome has a positive Phalen test?**

- a) loge de Guyon syndrome
- b) pronator syndrome
- c) carpal tunnel syndrome
- d) Wartenberg syndrome
- e) Morton syndrome

**Question 4**

**What is the typical site of ulnar nerve compression?**

- a) in the loge de Guyon
- b) under Osborne's ligament
- c) under the arcade of Struthers
- d) in the sulcus ulnaris
- e) in the supinator tunnel

**Question 5**

**What is the most likely diagnosis if a male patient complains of painful "falling asleep" of the hands?**

- a) syringomyelia
- b) impaired circulation
- c) cervical spondylosis
- d) carpal tunnel syndrome
- e) peripheral neuropathy

**Question 6**

**What condition is associated with isolated atrophy of the first dorsal interosseus muscle without any sensory disturbance?**

- a) C8 radiculopathy
- b) distal ulnar nerve compression
- c) neural muscular atrophy
- d) posterior interosseous nerve syndrome
- e) thoracic outlet syndrome (TOS)

**Question 7**

**Which of the following is typical in supinator tunnel syndrome?**

- a) arm pain at night
- b) sensory impairment on the dorsum of the hand and thumb
- c) weak wrist extension
- d) weak finger and thumb extension
- e) loss of the brachioradialis reflex

**Question 8**

**What diagnosis is most likely when a female patient complains that she can no longer wear tightly fitting shoes?**

- a) intermittent claudication
- b) sciatica
- c) Morton's metatarsalgia
- d) flat feet
- e) tarsal tunnel syndrome

**Question 9**

**What syndrome characteristically manifests weakness of key grip?**

- a) anterior interosseous nerve syndrome
- b) neurogenic thoracic outlet syndrome
- c) supinator tunnel syndrome
- d) Wartenberg syndrome
- e) loge de Guyon syndrome

**Question 10**

**What is the usual cause of Morton's metatarsalgia?**

- a) interdigital nerve compression by displacement of the neurovascular bundle
- b) compression of the deep radial nerve under the arcade of Frohse
- c) compression of the lateral femoral cutaneous nerve under the inguinal ligament
- d) subacute compression by a ganglion
- e) a hereditary normal anatomical variant

## CONTINUING MEDICAL EDUCATION

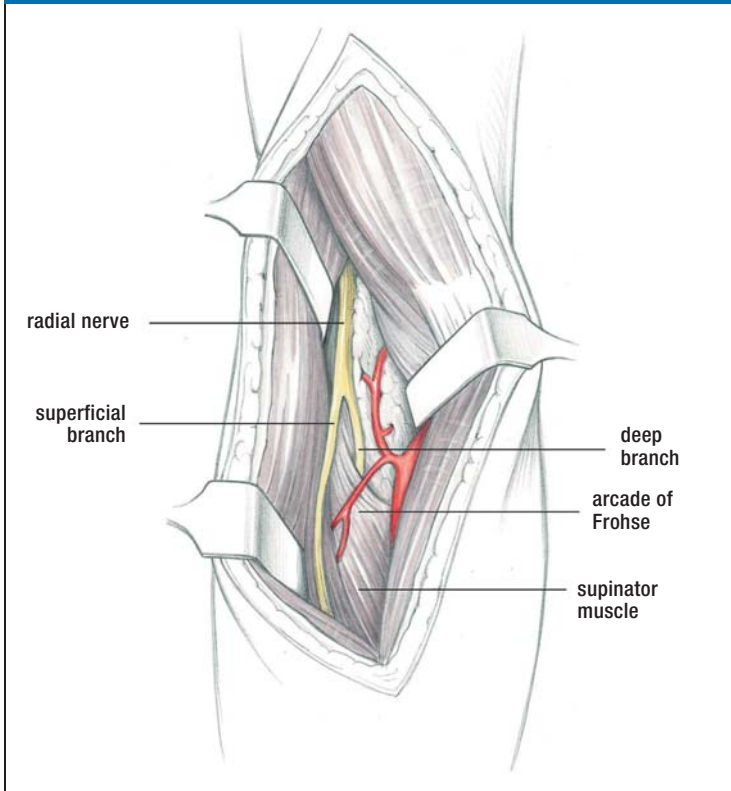
# Carpal and Cubital Tunnel and Other Rare Nerve Compression Syndromes

Hans Assmus, Gregor Antoniadis, Christian Bischoff

## eREFERENCES

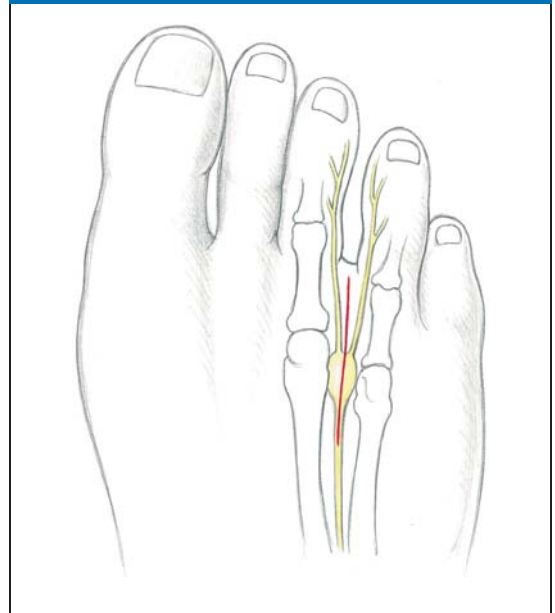
- e1. Assmus H: Ist das Karpaltunnelsyndrom erblich? *Akt Neurol* 1993; 20: 138–141.
- e2. O'Connor D, Page MJ, Marshall SC, Massy-Westropp N: Ergonomic positioning or equipment for treating carpal tunnel syndrome. *Cochrane Database Syst Rev* 2012; 1: CD009600.
- e3. Page MJ, Massy-Westropp N, O'Connor DA, Pitt V: Splinting for carpal tunnel syndrome. *Cochrane Database Syst Rev* 2012; 7: CD010003.
- e4. Page MJ, O'Connor DA, Pitt V, Massy-Westropp N: Exercise and mobilisation interventions for carpal tunnel syndrome. *Cochrane Database Syst Rev* 2012; 6: CD009899.
- e5. Page MJ, O'Connor DA, Pitt V, Massy-Westropp N: Therapeutic ultrasound for carpal tunnel syndrome. *Cochrane Database Syst Rev* 2013; 7: CD009601.
- e6. Haupt WF, Wintzer G, Schop A, Lottgen J, Pawlik G: Long-term results of carpal tunnel decompression. Assessment of 60 cases. *J Hand Surg Br* 1993; 18: 471–4.
- e7. Assmus H, Dombert T, Staub F: Rezidiv- und Korrekturingriffe beim Karpaltunnelsyndrom. *Handchir Mikrochir Plast Chir* 2006; 38: 306–11.
- e8. Soltani AM, Allan BJ, Best MJ, et al.: A systematic review of the literature on the outcomes of treatment for recurrent and persistent carpal tunnel syndrome. *Plast Reconstr Surg* 2013; 132: 114–21.
- e9. Szabo RM, Kwak C: Natural history and conservative management of cubital tunnel syndrome. *Hand Clin* 2007; 23: 311–18.
- e10. Capo JT, Jakob G, Maurer RJ: Subcutaneous anterior transposition versus decompression and medial epicondylectomy for the treatment of cubital tunnel syndrome. *Orthopedics* 2011; 34: 713–7.
- e11. Cobb TK, Sterbank PT, Lemke JH: Endoscopic cubital tunnel recurrence rates. *Hand* 2010; 5: 179–83.
- e12. Freehill MT, Shi LL, Tompson JD, Warner JJ: Suprascapular neuropathy. Diagnosis and treatment. *Phys Sportsmed* 2012; 40: 72–83.
- e13. Gurdezi S, White T, Ramesh P: Alcohol injection for Morton' neuroma: a five-year follow-up. *Foot Ankle Int* 2013; 34: 1064–7.
- e14. Kasperek M, Schneider W: Surgical treatment of Morton's neuroma: clinical results after open excision. *Int Orthop* 2013; 37: 1857–61.
- e15. Akermark C, Crone H, Skoog A, Weidenhielm L: A prospective randomized controlled trial of primary versus dorsal incisions for operative treatment of primary Morton's neuroma. *Foot Ankle Int* 2013; 34: 1198–204.
- e16. Logullo F, Ganino C, Lupidi F, Perozzi C, Di Bella P, Provinciali L: Anterior tarsal tunnel syndrome: a misunderstood and a misleading entrapment neuropathy. *Neurol Sci* 2014; 35: 773–5.
- e17. Zhang W, Li S, Zheng X: Evaluation of the clinical efficacy of multiple lower extremity nerve decompression in diabetic peripheral neuropathy. *J Neurol Surg A Cent Eur Neurosurg* 2013; 74: 96–100.
- e18. Valdivia JM, Weinand M, Malconey CT Jr, et al.: Surgical treatment of superimposed, lower extremity, peripheral nerve entrapments with diabetic and idiopathic neuropathy. *Ann Plast Surg* 2013; 70: 675–9.
- e19. Nickerson DS, Rader AJ: Low long-term risk of foot ulcer recurrence after nerve decompression in a diabetes neuropathy cohort. *J Am Podiatr Med Assoc* 2013; 103: 380–6.
- e20. Miller TA, White KP, Ross DC: The diagnosis and management of piriformis syndrome: myths and facts. *Can J Neurol Sci* 2012; 39: 577–83.
- e21. Masala S, Crusco S, Meschini A, Taglieri A, Calabria E, Simonetti G: Piriformis syndrome: long-term follow-up in patients treated with percutaneous injection of anesthetic and corticosteroid under CT guidance. *Cardiovasc Intervent Radiol* 2012; 35: 375–82.
- e22. Jankovic D, Peng P, van Zundert A: Brief review: piriformis syndrome: etiology, diagnosis, and management. *Can J Anaesth* 2013; 60: 1003–12.
- e23. Bischoff JM, Koscielniak-Nielsen ZJ, Kehlet H, Werner MU: Ultrasound-guided ilioinguinal/iliohypogastric nerve blocks for persistent inguinal postherniorrhaphy pain: a randomized, double-blind, placebo-controlled, crossover trial. *Anesth Analg* 2012; 114: 1323–9.
- e24. Robert R, Labat JJ, Riant T, Khalfallah M, Hamel O: Neurosurgical treatment of perineal neuralgias. *Adv Tech Stand Neurosurg* 2007; 32: 41–59.
- e25. Lefaucheur JP, Labat JJ, Amerenco G, et al.: What is the place of electroneuromyographic studies in the diagnosis and management of pudendal neuralgia related to entrapment syndrome. *Neurophysiol Clin* 2007; 37: 223–8.

eFIGURE 1



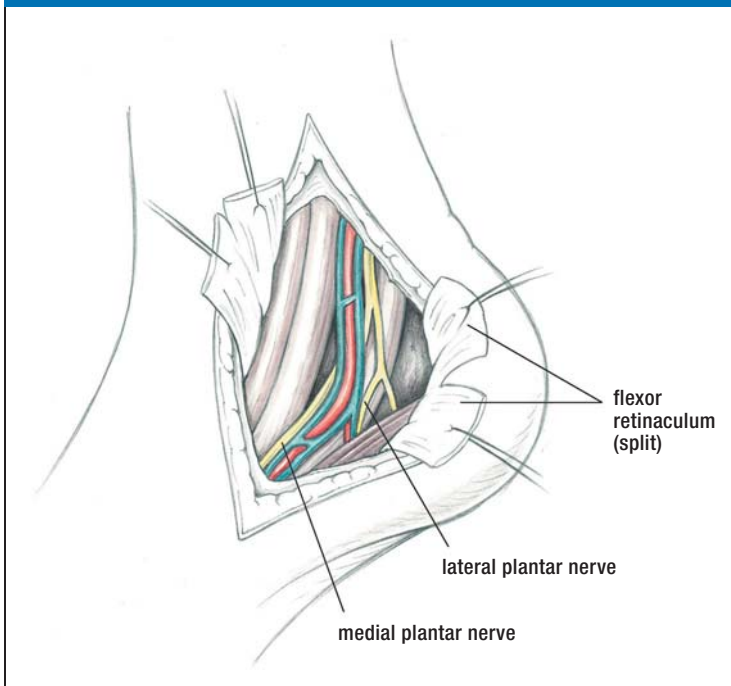
**Supinator tunnel syndrome.** The deep branch of the radial nerve is usually compressed under the arcade of Frohse (3)

eFIGURE 2



**Morton's metatarsalgia.** A pseudoneuroma develops between the 3<sup>rd</sup> and 4<sup>th</sup> (and between the 2<sup>nd</sup> and 3<sup>rd</sup>) metatarsal heads (3)

eFIGURE 3



**Exposure of the neurovascular bundle** after opening the posterior tarsal tunnel (3)