

Case-based implementation of the 2017 ESC Focused Update on Dual Antiplatelet Therapy in Coronary Artery Disease[†]

The Task Force for the Management of Dual Antiplatelet Therapy in Coronary Artery Disease of the European Society of Cardiology (ESC) and of the European Association for Cardio-Thoracic Surgery (EACTS)

Authors/Task Force Members: Jean-Philippe Collet (France), Marco Roffi (Switzerland), Robert A. Byrne (Germany), Francesco Costa (Italy) and Marco Valgimigli* (Chairperson) (Switzerland) on behalf of the Task Force for the Management of Dual Antiplatelet Therapy in Coronary Artery Disease of the European Society of Cardiology (ESC)[†]

Document Reviewers: Lina Badimon (CPG Review Coordinator) (Spain), Pascal Vranckx (CPG Review Coordinator) (Belgium), Stefan Agewall (Norway), Leonardo De Luca (Italy), Walter Desmet (Belgium), Stefan James (Sweden), Maddalena Lettino (Italy), Eugene Patrick McFadden (Ireland), Robert Storey (UK), Jurrien M Ten Berg (The Netherlands), Victor Aboyans (CPG Supervisor) (France)

*Corresponding author: Marco Valgimigli, Swiss Cardiovascular Center, Inselspital, University of Bern, CH-3010, Bern, Switzerland, Phone: +41 31 632 96 53; Fax: +41 31 632 47 71; e-mail: marco.valgimigli@insel.ch

[†]Full text document: Marco Valgimigli (Chairperson) (Switzerland), Héctor Bueno (Spain), Robert A. Byrne (Germany), Jean-Philippe Collet (France), Francesco Costa (Italy), Anders Jeppsson (Sweden), Peter Jüni (Canada), Adnan Kastrati (Germany), Philippe Kolh (Belgium), Laura Mauri (USA), Gilles Montalescot (France), Franz-Josef Neumann (Germany), Mate Petricevic (Croatia), Marco Roffi (Switzerland), Philippe Gabriel Steg (France), Stephan Windecker (Switzerland), Jose Luis Zamorano (Spain) 2017 ESC Focused Update on Dual Antiplatelet Therapy in Coronary Artery Disease developed in collaboration with the European Association for Cardio-Thoracic Surgery (EACTS). Eur Heart J. doi: 10.1093/eurheartj/ehx419

Available at <http://www.escardio.org/guidelines> and <http://eurheartj.oxfordjournals.org>.

The content of these European Society of Cardiology (ESC) Guidelines has been published for personal and educational use only. No commercial use is authorized. No part of the ESC Guidelines may be translated or reproduced in any form without written permission from the ESC. Permission can be obtained upon submission of a written request to Oxford University Press, the publisher of the European Heart Journal and the party authorized to handle such permissions on behalf of the ESC.

Disclaimer. The ESC Guidelines represent the views of the ESC and were produced after careful consideration of the scientific and medical knowledge and the evidence available at the time of their publication. The ESC is not responsible in the event of any contradiction, discrepancy and/or ambiguity between the ESC Guidelines and any other official recommendations or guidelines issued by the relevant public health authorities, in particular in relation to good use of healthcare or therapeutic strategies. Health professionals are encouraged to take the ESC Guidelines fully into account when exercising their clinical judgment, as well as in the determination and the implementation of preventive, diagnostic or therapeutic medical strategies; however, the ESC Guidelines do not override, in any way whatsoever, the individual responsibility of health professionals to make appropriate and accurate decisions in consideration of each patient's health condition and in consultation with that patient and, where appropriate and/or necessary, the patient's caregiver. Nor do the ESC Guidelines exempt health professionals from taking into full and careful consideration the relevant official updated recommendations or guidelines issued by the competent public health authorities, in order to manage each patient's case in light of the scientifically accepted data pursuant to their respective ethical and professional obligations. It is also the health professional's responsibility to verify the applicable rules and regulations relating to drugs and medical devices at the time of prescription.

Case Contributors (listed in alphabetical order): Alberto Berenguer Jofresa (Spain), Adela Bišćević (Bosnia and Herzegovina), Paolo Calabrò (Italy), Savvas Constantinides (Cyprus), Elena Damrina (Russia), Moustapha Diakite (Switzerland), Boris Dzudovic (Serbia), Victoria Garcia Ruiz (Spain), Ivan Keituqwa Yáñez (Spain), Juan Lacalzada-Almeida (Spain), Luís Leite (Portugal), Oteh Maskon (Malaysia), Lin Lin Myat (Australia), Elisabetta Ricottini (Italy), Francesco Saporito (Italy), Peter Sze Chai Wong (Hong Kong), Kyohei Yamaji (Japan), Michel Zeitouni (France),

All supporting documents (figures and movies) for these clinical cases can be found here: <https://academic.oup.com/eurheartj/article-lookup/doi/10.1093/eurheartj/ehx503#supplementary-data>

Online publish-ahead-of-print 26 August 2017

Table of contents

Abbreviations and acronyms.....	e2
Case #1 Navigating between the risks of stent thrombosis and major haemorrhage	e3
Case #2: Platelet function testing in high-risk non-ST-elevation myocardial infarction	e4
Case #3: Recurrent gastrointestinal bleeding in a patient on dual antiplatelet therapy waiting for coronary revascularization	e4
Case #4: Recurrent left ventricle thrombus after discontinuation of oral anticoagulation.....	e6
Case #5: A heart and brain emergency	e6
Case #6: Dual antiplatelet therapy in an elderly man with multivessel disease treated with coronary angioplasty	e8
Case #7 Nasal bleeding and dual antiplatelet therapy.....	e10
Case #8: Dual antiplatelet therapy reveals what the eye cannot (yet) see	e11
Case #9: A case with very late stent thrombosis 20 months after implantation of a biodegradable polymer sirolimus-eluting stent	e12
Case #10: Prolongation of dual antiplatelet therapy after stent implantation for ST-segment elevation myocardial infarction	e13
Case #11: Ischaemia and bleeding in a young patient: between a rock and a hard place.	e16
Case #12: Dual antiplatelet therapy: treatment decision-making with risk scores after stent implantation	e19
Case #13: Oral anticoagulation, triple therapy and complex percutaneous coronary intervention	e21
Case #14: Periprocedural myocardial infarction in elective percutaneous coronary intervention: when stenting goes wrong, dual antiplatelet therapy should be strong.	e23
Case #15: Spontaneous coronary artery dissection in a young woman	e24
Case #16: Platelet reactivity testing after percutaneous coronary intervention: caveat emptor	e25
Case #17: Antiplatelet therapy after bioresorbable scaffold implantation – when is it safe to interrupt?	e28
Case #18: Management of dual antiplatelet therapy in a patient with a femoral pseudoaneurysm following percutaneous coronary intervention.....	e30
References	e31

Abbreviations and acronyms

ACS	Acute coronary syndrome
ACE	Angiotensin-converting enzyme
ADP	Adenosine diphosphate
BMS	Bare-metal stent
BRS	Bioresorbable stent
CABG	Coronary artery bypass grafting
CAD	Coronary artery disease
CRUSADE	Can Rapid Risk Stratification of Unstable Angina Patients Suppress Adverse Outcomes With Early Implementation of the ACC/AHA Guidelines
CT	Computed tomography
CTO	Chronic total occlusion
DAPT	Dual antiplatelet therapy
DES	Drug-eluting stent
ECG	Electrocardiogram
ECMO	Extracorporeal membrane oxygenation
ESC	European Society of Cardiology
ESGE	European Society of Gastrointestinal Endoscopy
GI	Gastrointestinal
GRACE	Global Registry of Acute Coronary Events
HAS-BLED	Hypertension, Abnormal Renal/Liver Function, Stroke, Bleeding History or Predisposition, Labile INR, Elderly, Drugs/Alcohol Concomitantly
INR	International normalized ratio
IV	Intravenous
LAD	Left anterior descending
LCX	Left circumflex
LEADERS	Prospective randomized comparison of the BioFreedom biolimus A9 drug-coated stent versus the gazelle bare-metal stent in patients at high bleeding risk
FREE	
LM	Left main
LV	Left ventricle/ventricular
LVEF	Left ventricular ejection fraction
OAC	Oral anticoagulant
OCT	Optical coherence tomography
MI	Myocardial infarction
MRI	Magnetic resonance imaging

NOAC	Non-vitamin K antagonist oral anticoagulant
NSTEMI	Non-ST-segment elevation myocardial infarction
PCI	Percutaneous coronary intervention
PDA	Posterior descending artery
PEGASUS-	Prevention of Cardiovascular Events in Patients With
TIMI 54	Prior Heart Attack Using Ticagrelor Compared to Placebo on a Background of Aspirin-Thrombolysis in Myocardial Infarction 54
PIONEER-	Rivaroxaban and a dose-adjusted oral vitamin K
AF-PCI	antagonist treatment strategy in subjects with atrial fibrillation who undergo percutaneous coronary intervention
PLATO	Platelet Inhibition and Patient Outcomes
PPI	Proton pump inhibitor
PRECISE-	PREdicting bleeding Complications In patients under-
DAPT	going Stent implantation and subsequent Dual Anti Platelet Therapy
PRODIGY	Prolonging Dual Antiplatelet Treatment After Grading Stent- Induced Intimal Hyperplasia Study
RCA	Right coronary artery
ST	Stent thrombosis
STS	Society of Thoracic Surgery
STEMI	ST-segment elevation myocardial infarction
TIMI	Thrombolysis In Myocardial Infarction
t-PA	Tissue plasminogen activator
TRITON-	TRial to assess Improvement in Therapeutic
TIMI 38	Outcomes by optimizing platelet inhibition with prasugrel–Thrombolysis In Myocardial Infarction 38
TTE	Transthoracic echocardiography
ULN	Upper limit of normal
VASP	Vasodilator-stimulated phosphoprotein
VKA	Vitamin K antagonist

Case #1 Navigating between the risks of stent thrombosis and major haemorrhage

A 77-year-old male presented with inferolateral ST-segment elevation myocardial infarction (STEMI) complicated by transient complete heart block and syncope, and underwent successful thrombolysis within two hours of symptom onset. He was immediately loaded with aspirin and clopidogrel and was brought to the catheterization laboratory for coronary angiography, which showed no flow-limiting plaques in the left system (*Figure 1A*) but the presence of a thrombotic non-occlusive coronary stenosis in the distal right coronary artery (RCA) (*Figure 1B*), which was treated with implantation of a bare-metal stent (BMS) (4 x 18 mm long, Genous® stent). In the morning after percutaneous coronary intervention (PCI) and before the planned intake of dual antiplatelet therapy (DAPT), the patient presented a sudden haematemesis followed by melena. The ongoing major gastrointestinal (GI) bleeding was accompanied by haemodynamic instability and a drop in the haemoglobin level to 8.5 g/dL, requiring intravenous (IV) fluids and red blood cell concentrate transfusion. A decision was taken to stop both clopidogrel and aspirin, start IV proton pump inhibitor (PPI) and refer the patient for an upper GI endoscopy, which identified and treated a

large Mallory-Weiss tear. Three hours after endoscopic intervention (i.e. 39 hours after the bleeding episodes and after having skipped two consecutive clopidogrel maintenance doses after the loading regimen) the patient showed pulseless ventricular tachycardia terminated by defibrillation but followed by third degree atrioventricular block and again ST elevation in the inferior leads. The patient was brought back to the catheterization laboratory. Angiography revealed occlusion of the RCA, then treated using a thrombus aspiration catheter device.

Comments from the Task Force

This case illustrates the multifactorial origin of stent thrombosis (ST) and the interplay between major bleeding and acute thrombotic state. Several aspects warrant further discussion.

- (i) The use of a slow-acting P2Y₁₂ oral receptor inhibitor (clopidogrel) in the context of a high thrombotic burden may account for a non-optimal inhibition of this pathway (see chapter 3.6 in full text document). In addition, fibrinolysis, severe anaemia and cardiogenic shock may have potentiated platelet activation/aggregation. Yet, there is no reassuring evidence on the safety of combining more potent P2Y₁₂ oral receptor inhibitors in patients who have received fibrinolysis, and the decision in this case to administer clopidogrel is justifiable and in line with current recommendations. The decision to interrupt both oral antiplatelet drugs in the context of ongoing major bleeding may have magnified platelet reactivity leading to ST.¹
- (ii) Delayed interventional endoscopy precluding earlier oral re-administration of oral antiplatelet drug may have also triggered the haemostatic balance towards a prothrombotic state. It should be noted that the European Society of Gastrointestinal Endoscopy (ESGE) recently recommended very early (< 12 hours) upper GI endoscopy in patients with high risk clinical features, namely haemodynamic instability (e.g. tachycardia, hypotension) that persists despite adequate volume replacement; in-hospital bloody emesis/nasogastric aspirate; or contraindication to the interruption of antiplatelet therapies or anticoagulation.² Therefore, an alternative treatment strategy would have been to perform upper GI endoscopy more expeditiously to better control bleeding and obtain a diagnosis while avoiding immediate discontinuation of both antiplatelet agents or even allowing for continuation of both agents.
- (iii) The need for red blood cell transfusion, which was clearly justified in this case due to the presence of haemodynamic instability, may have also favoured high platelet reactivity as a consequence of adenosine diphosphate (ADP) release.³ The need for transfusion should always be weighed against the established detrimental effect in terms of a possible increase in ischaemic events, especially in patients with recent myocardial infarction (MI).⁴
- (iv) Systematic administration of PPI is an effective preventive measure in patients at risk of GI bleeds (see chapter 3.7 in full text document).⁵ This was the case here. The pharmacodynamic interaction observed between clopidogrel and PPI has never been associated with any significant adverse outcome effects.⁶
- (v) A final comment should be reserved for the type and timing of intervention. BMS implantation is no longer supported by evidence and guidelines. In case of successful thrombolysis, there is no evidence that the patient should be immediately brought to the catheterization laboratory while a delay of 3 - 12 hours is recommended.

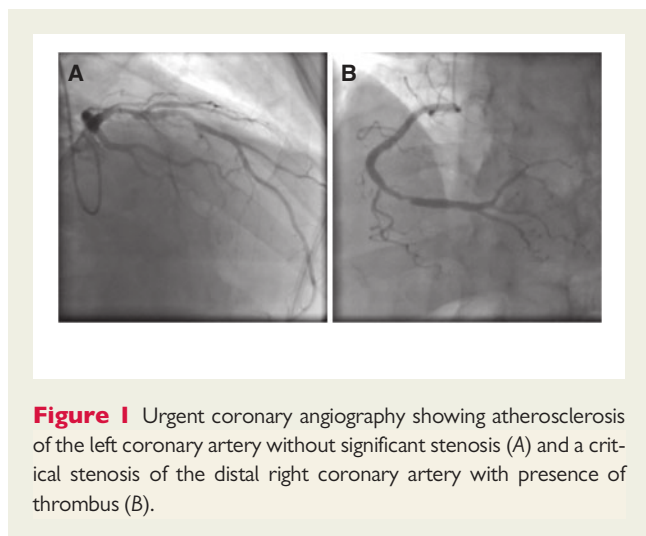


Figure 1 Urgent coronary angiography showing atherosclerosis of the left coronary artery without significant stenosis (A) and a critical stenosis of the distal right coronary artery with presence of thrombus (B).

Case #2: Platelet function testing in high-risk non-ST-elevation myocardial infarction

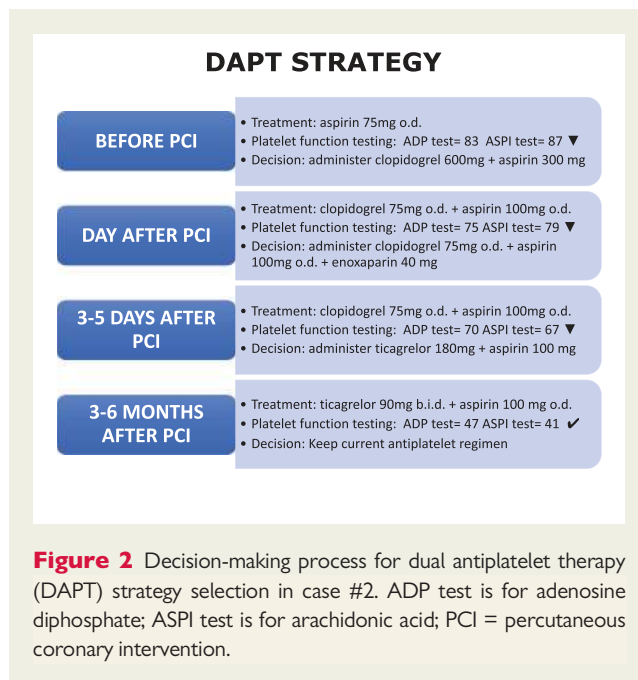
A 70-year-old female with class 2 obesity (i.e. body mass index $>35 \text{ kg/m}^2$) was admitted for a high-risk non-ST-segment elevation myocardial infarction (NSTEMI). She underwent right carotid endarterectomy for asymptomatic disease four years earlier and was known to have a 70% stenosis of the left internal carotid artery. Her medical treatment included statin, angiotensin-converting enzyme (ACE) inhibitor and aspirin. A diagnostic coronary angiogram was performed the same day, and showed a 90% stenosis of the proximal left anterior descending (LAD) coronary artery. The culprit lesion was treated with coronary stenting after a loading dose of 300 mg aspirin and 600 mg clopidogrel. Serial platelet function testing measures using multiplate electrode aggregometry were performed in the following days (Figure 2) to assess on-treatment platelet reactivity. This led to the switch from clopidogrel to ticagrelor on day 5 after PCI by means of 180 mg loading dose followed by 90 mg *b.i.d.* Measurements performed at three and six months follow-up indicated an acceptable level of platelet reactivity according to the threshold of the aggregometry device.

Comments from the Task Force

This clinical case merits further discussion.

- (i) First, this high-risk female presenting with NSTEMI in the context of a known polyvascular disease should have been treated upfront with a more potent P2Y₁₂ receptor inhibitor instead of clopidogrel according to the ESC guidelines (see chapter 3.6 in full text document). Ticagrelor and prasugrel have demonstrated their superiority over clopidogrel in acute coronary syndrome (ACS) patients and either of the two should be first line treatment in this condition.
- (ii) Platelet reactivity assessment during P2Y₁₂ inhibitor treatment identifies PCI-treated patients with a high on-treatment platelet reactivity who are at higher risk for mortality and ST and patients with a low on-treatment platelet reactivity who are at an increased risk for major

bleeding.^{7,8} However, randomized trials testing the hypothesis of the clinical benefit of platelet function monitoring to adjust therapy failed to show any clinical benefit.^{9–12} For these reasons, platelet function testing is not recommended on a routine basis for tailoring DAPT after stenting (see chapter 3.7 in full text document).



Case #3: Recurrent gastrointestinal bleeding in a patient on dual antiplatelet therapy waiting for coronary revascularization

A 52-year-old male with stable angina due to chronic total occlusion (CTO) of the RCA and of the LAD (Figure 3A) underwent successful recanalization of the RCA with three drug-eluting stents (DES) (Xience[®]) (Figure 3B). He was then discharged on aspirin and ticagrelor and re-admitted for scheduled PCI of the LAD five months later. Blood tests at admission showed profound anaemia related to iron deficiency (haemoglobin 7.3g/dL; mean corpuscular volume 63.3 fL). At further assessment, it was found that three months after the first PCI the patient had been admitted for melena and DAPT was withheld for one week.

The planned staged PCI of the LAD was postponed, the patient was transfused with 2 units of blood and DAPT was discontinued. Upper GI tract endoscopy was unremarkable whereas lower GI tract endoscopy identified a solitary rectal ulcer. Therapy with oral esomeprazole was initiated as a measure to prevent GI bleeding. The patient was discharged on aspirin and ticagrelor after confirmation of a negative stool occult blood test and a haemoglobin level of 12.9 g/dL. Recurrent anaemia occurred again three weeks later necessitating

once more DAPT interruption for one week and haemorrhoid clipping. Upper endoscopy remained unremarkable and lower endoscopy identified a healed rectal ulcer. Aspirin was then restarted on a background of PPI and clopidogrel was introduced a month later after repeated testing showing haemoglobin levels above 12 g/dL. PCI of the LAD CTO was then successfully performed with three DES (Figure 3C). The patient was discharged on aspirin and clopidogrel together with PPI. Haemoglobin levels remained stable thereafter and no further recurrent bleeding occurred.

Comments from the Task Force

The present case raises several points:

- (i) The selection of ticagrelor instead of clopidogrel for PCI in a patient with stable coronary artery disease (CAD) merits discussion. The use of ticagrelor or prasugrel is off-label in the setting of elective PCI/stable CAD. ESC guidelines state that ticagrelor or prasugrel may be reasonably used in elective PCI in case of prior history of ST while on clopidogrel (see chapter 3.6 in full text document). Although in the patient described the risk of ST was not negligible considering the complexity of the PCI with multiple and overlapping stent implantation after recanalization of a CTO, no prior ST occurred to justify such an escalation of therapy. It can be argued that the use of ticagrelor may have inappropriately increased the bleeding risk as compared to clopidogrel.
- (ii) The duration of DAPT after elective PCI is also worth focusing on.¹³ The DAPT Focused Update recommends six months irrespective of the stent type (see chapter 4.1 in full text document). In the case of high risk of bleeding, this duration should be reduced to three months or to one month if there is a safety concern.¹⁴ On the other hand, in the case of complex PCI (which encompasses PCI for CTO), DAPT longer than six months may be considered (see chapter 9.4 in full text document). Before the first bleeding episode occurred, the *a priori* ischaemic risk was likely greater than the bleeding hazard. The occurrence of bleeding while on DAPT three months after the first PCI justifies DAPT discontinuation and further diagnostic work-up in order to identify the bleeding aetiology (as correctly performed three months later).
- (iii) Reintroduction of ticagrelor three months after an elective case with on-treatment major bleeding during follow-up is questionable and not supported by the data. De-escalation of the P2Y₁₂ receptor blockade intensity with clopidogrel may have been more appropriate to avoid recurrent bleeding.
- (iv) The fourth point to be discussed is treatment interruption in the context of acute bleeding. GI tract bleeding is the first cause of major bleeding and is associated with a better outcome as compared to bleeding of unknown origin. Interventional endoscopy avoids complete interruption of DAPT (i.e. discontinuation of both antiplatelet agents), an independent predictor of ST and mortality.¹⁵
- (v) The benefit of red blood cell transfusion should always be discussed in the absence of haemodynamic compromise or when the patient tolerates chronic anaemia. Red blood cell transfusion has been shown to be detrimental especially in patients with known CAD.⁴
- (vi) Finally, the patient management before proceeding to PCI of the LAD is noteworthy. Postponing an elective intervention in the absence of angina or angina symptoms until bleeding has resolved or been treated and the patient can safely tolerate a DAPT regimen is commendable.

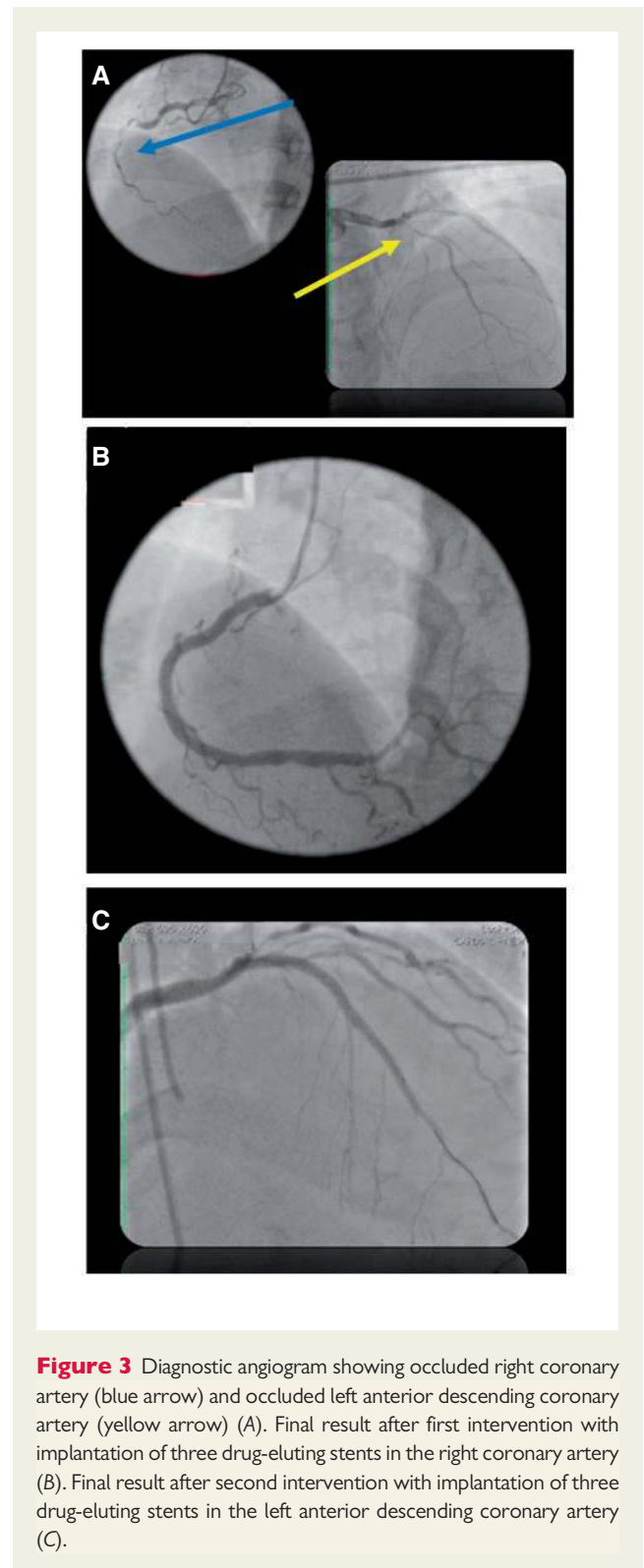


Figure 3 Diagnostic angiogram showing occluded right coronary artery (blue arrow) and occluded left anterior descending coronary artery (yellow arrow) (A). Final result after first intervention with implantation of three drug-eluting stents in the right coronary artery (B). Final result after second intervention with implantation of three drug-eluting stents in the left anterior descending coronary artery (C).

Case #4: Recurrent left ventricle thrombus after discontinuation of oral anticoagulation

A 66-year-old man with a history of hypertension and diabetes presented with chest pain and inferior STEMI. In addition, an electrocardiogram (ECG) showed Q waves in the anterior leads. He reported similar symptoms a month before. Coronary angiography showed chronic occlusion of the mid-LAD (Figure 4A) and acute occlusion of the mid-RCA, which was successfully treated with DES implantation. Transthoracic echocardiography (TTE) showed left ventricular (LV) inferior hypokinesia, and anterior and apical akinesia with a large intraventricular thrombus adherent to the septo-apical and infero-apical endocardium (Figure 4B). The LV ejection fraction (LVEF) was 37%. He was discharged on aspirin and clopidogrel for six months combined with vitamin K antagonist (VKA) and PPI. Four months after discharge, TTE showed an absence of LV thrombus (Figure 4C), recovery of LVEF, but persistent LV apical-anterior and anterior akinesia. VKA was then stopped. However, at six months' follow-up TTE showed a recurrence of apical thrombus in the absence of clinical embolization. Oral anticoagulant (OAC) was resumed with DAPT up to one year and clopidogrel was finally stopped after no recurrent apical thrombus was demonstrated.

Comments from the Task Force

The case raises several points for discussion:

- (i) Type of stent in patients who have or may develop an indication for concomitant OAC: the benefit of using a DES to prevent restenosis has been questioned due to the increased risk of bleeding with long-term triple antithrombotic therapy. The DAPT update guidelines have clearly outlined that the choice of newer-generation DES vs. BMS in patients requiring long-term anticoagulation is no longer controversial. Two randomized trials have demonstrated the superiority of newer-generation DES over BMS in high-bleeding risk patients who cannot tolerate long-term exposure to DAPT such as those needing chronic OAC (see chapter 2.2 in full text document).^{14,16} This has been shown in patients at high bleeding risk in whom long-term DAPT could not be sustained.
- (ii) Duration of VKA therapy in case of mural thrombi: The 2017 ESC STEMI guidelines state that in patients with LV thrombus, anticoagulation should be administered for up to six months guided by repeated imaging. In the present case, cessation of OAC may have been too early given the persistent apical akinesia even if there was an LVEF improvement. In addition, the absence of a bleeding event and the lack of comorbidities or frailty features were supportive arguments for sustained OAC.
- (iii) Duration of DAPT in the context of chronic OAC: the optimal duration of triple antithrombotic therapy is unknown especially in the context of ACS. What is established is that patients exposed to triple therapy should be considered at high bleeding risk. It seems that the rate of bleeding events peaks within the first 30 days of initiation of triple therapy and is twice as high when compared with the rate of acute coronary events including recurrent MI and ST.¹⁷ For these reasons, duration of triple therapy should be minimized depending on bleeding and ischaemic risks. In the present case, high-risk features of stent-

driven recurrent ischaemic events were absent (see Table 5 and chapter 7.2 in full text document) and there were no unfavourable factors that would plead against the combination of OAC and antiplatelet therapy (see Table 6 and chapter 7.2 in full text document). For these reasons, one month to a few month(s) of triple therapy would have been reasonable.

- (iv) Cessation of antiplatelet therapy after one year: This is a pending issue with no prospective evidence. According to the 2017 ESC consensus document, all antiplatelet agents should be stopped after one year and OAC maintained, unless the risk for recurrent ischaemic events is estimated to be high.⁵ Given the low risk of coronary ischaemic recurrences in the case described above, OAC alone seems justified.

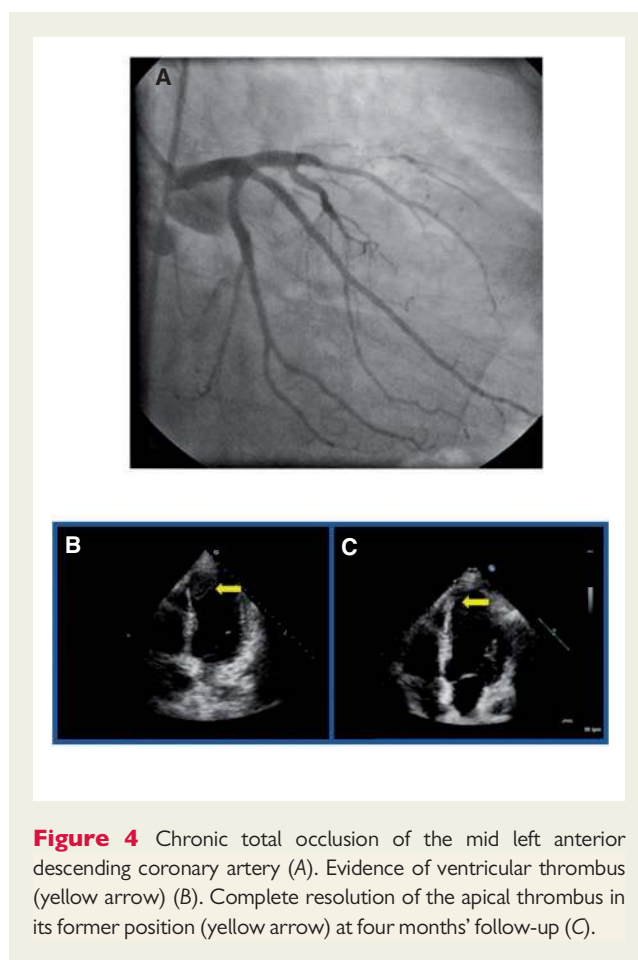


Figure 4 Chronic total occlusion of the mid left anterior descending coronary artery (A). Evidence of ventricular thrombus (yellow arrow) (B). Complete resolution of the apical thrombus in its former position (yellow arrow) at four months' follow-up (C).

Case #5: A heart and brain emergency

A 52-year-old truck driver presented with anterior STEMI as the first manifestation of CAD secondary to mid LAD occlusion, which was treated with primary PCI and the implantation of a DES. Beyond the mentioned LAD lesion, the coronary tree showed only minimal atherosclerosis. The patient received oral aspirin 250 mg, ticagrelor 180 mg and enoxaparin 1 mg/kg as the anticoagulation regimen during PCI. Because of post-procedural persisting pain thought to be due to distal embolization, eptifibatid (10.7 ml × 2 boluses during PCI

followed by 19.2 mL per hour infusion) was administered for a total of 10 hours, while DAPT was pursued. His cardiovascular risk factors included previous smoking and overweight (body mass index 31 kg/m²), while his cholesterol status was unknown. In addition, there was a familial history of haemochromatosis and polycythaemia. His haemoglobin was 16.9 g/dL, white blood cell count $9.4 \times 10^9/L$, platelets $155 \times 10^9/L$, and ferritin level 591 µg/L (upper limit of normal [ULN] 300); troponin I level was raised from 0.144 to 91 ng/mL (ULN 0.04). Renal function was normal. The initial clinical course was uneventful. A TTE performed at day 2 showed a mild reduction in LV systolic function (LVEF 52%) with apico-antero-lateral wall hypokinesia and an echogenic area in the apex suggestive of thrombus (Figure 5A-B). On day 3, the patient complained about transient right eye vision disturbance, mentioning that he was not able to see the television properly. Immediate neurologic examination revealed an isolated right homonymous hemianopia. After excluding an intracranial haemorrhage with a non-injected computed tomography (CT) scan, the stroke team performed IV thrombolysis with tissue plasminogen activator (t-PA). Antiplatelet agents were put on hold. Next day (day 4), visual symptoms recovered completely. Brain magnetic resonance imaging (MRI) showed a small left occipital infarct with no haemorrhagic transformation (Figure 5C). Ticagrelor was replaced by clopidogrel 75 mg/day (no loading dose) and aspirin discontinued. On day 5, both warfarin and enoxaparin (1 mg/kg subcutaneous *b.i.d.* as a bridge until therapeutic anticoagulation with warfarin was achieved) were started. At three months' follow-up, the patient remained asymptomatic and LV function returned to normal at TTE, which did not show imaging compatible with intracavitary thrombus. Warfarin was stopped and aspirin was added to clopidogrel with the goal of continuing DAPT for at least one year. From the cardiac perspective, the patient received initial clearance for commercial driving, though he was scheduled to undergo a formal visual field testing prior to definitive clearance.

Comments from the Task Force

- While neurologic events during or in the few hours following PCI are usually related to the procedure itself (e.g. due to embolization related to catheter manipulation in the aortic arch, thrombus formation on the guiding catheter or wires or at the time of thrombus aspiration), in the case described here the delay is too long to postulate a direct link with the coronary procedure. The likely explanation for the stroke was detected earlier that day: a suspected LV apical thrombus on TTE. However, this finding did not prompt immediate full anticoagulation as it should have.
- The case nicely depicts the challenges of acute stroke treatment in patients on antiplatelet agents. Current evidence suggests that IV thrombolytic therapy in patients on a single antiplatelet drug is possibly associated with a small increase in the risk of intracranial haemorrhage, while, in the presence of DAPT, the risk is probably higher. However, current stroke guidelines estimate as likely that the small increased risk of intracranial haemorrhage in antiplatelet drug users suffering acute stroke is outweighed by a larger benefit from thrombolysis. Therefore, it is estimated that there is an overall net improvement in functional outcomes in pre-stroke antiplatelet drug users treated with IV thrombolytic agents.¹⁸
- In the described patient, the switch from ticagrelor to clopidogrel following stroke was achieved without administering a clopidogrel loading dose. The need to concomitantly initiate full anticoagulation for the suspected LV thrombus may have motivated this choice. However, with

respect to the modality of switching from ticagrelor to clopidogrel, the 2017 ESC DAPT Focused Update recommends to load the patient with 600 mg of clopidogrel 24 hours after the last ticagrelor dose, while in the present case clopidogrel was restarted at 75 mg/day (see chapter 3.8 in full text document). This may have exposed the patient to an increased risk of ST, especially because aspirin was also discontinued at the same time.

- Having stopped aspirin it seemed also reasonable to avoid a potential haemorrhagic transformation of the stroke area. Priority was given to an immediate full anticoagulation with enoxaparin while warfarin was getting fully effective. According to the 2017 ESC DAPT Focused Update, dual therapy with clopidogrel 75 mg/day and OAC should be considered as an alternative to one-month triple antithrombotic therapy (aspirin, clopidogrel, and OAC) in patients in whom the bleeding risk outweighs the ischaemic risk (see chapter 7.2 in full text document).
- With respect to the duration of anticoagulation for LV thrombus in the setting of acute MI, the 2017 ESC STEMI guidelines give a consensus of an expert-type of recommendation, in the absence of dedicated trials, stating that in patients with LV thrombus anticoagulation should be administered for up to six months, guided by thrombus resolution on repeated imaging. In the patient described, after stopping OAC, aspirin was added to clopidogrel. An alternative option would have been to restart the initial DAPT, namely aspirin and ticagrelor. While both options are possible, a more potent platelet P2Y₁₂ inhibitor may have been considered in case of high ischaemic risk (e.g. multiple stents, left main [LM] stent, severe three vessel disease, diabetes).

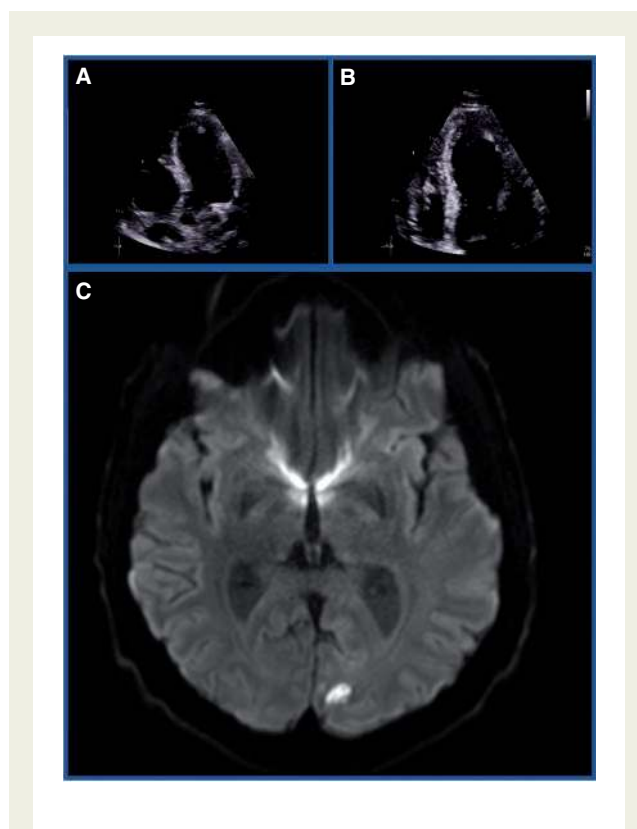


Figure 5 Transthoracic echocardiography with evidence of apical thrombus (A, B). Brain magnetic resonance image showing a small left occipital infarct area with no signs of haemorrhagic transformation (C).

Case #6: Dual antiplatelet therapy in an elderly man with multivessel disease treated with coronary angioplasty

An 81-year-old man was admitted to the emergency room with chest pain at rest and dyspnoea. Cardiovascular risk factors were notable for hypertension, dyslipidaemia, type II diabetes, obesity and prior smoking. This patient, who also had peripheral arterial disease, suffered from NSTEMI treated with multiple stent implantations in the RCA and left circumflex (LCX) arteries. A few years afterwards, due to the occurrence of heart failure symptoms, the patient underwent TTE which demonstrated a slightly reduced LVEF (50%) and a moderate aortic stenosis. At presentation blood pressure was 164/75 mmHg, heart rate 80 bpm and SpO₂ 94% in room air. The patient's ECG is shown in *Figure 6*. After implementation of IV nitrates, the chest pain resolved and a physical examination showed bilateral pulmonary rales and lower extremity oedema. High sensitivity troponin I was elevated (4.91 ng/mL). At further laboratory assessment, haemoglobin was 10.8 g/dL, haematocrit 31.6% and estimated creatinine clearance 66 mL/min/1.73m². GRACE and CRUSADE scores were 170 and 50, respectively, indicating a high risk for both ischaemic and bleeding complications.

According to our local treatment protocol (*Figure 7*), this patient was treated with clopidogrel (the patient was already on aspirin at presentation) and was then brought to the catheterization laboratory within 24 hours where a peak-to-peak transaortic gradient of 40 mmHg was measured indicating moderate aortic stenosis, and stenosis of the ostium of the LAD, proximal and mid RCA. At a further Heart Team discussion, the decision was taken to proceed to PCI with implantation of polymer-free DES in view of the anticipated need to prematurely stop DAPT due to bleeding. At 6 months follow-up, no further ischaemic or bleeding episode had occurred, so DAPT was continued. The case submitter raised a point for discussion: should newer P2Y₁₂ inhibitors have been preferred over clopidogrel in this patient and, more generally, should ticagrelor or prasugrel be preferred to clopidogrel in patients at both high ischaemic and bleeding risks?

Comments from the Task Force

- Patients at both high ischaemic and bleeding risks can encompass up to 50% of patients in routine clinical practice, which speaks for the fact that risk factors for recurrent ischaemic events, such as advanced age and renal dysfunction, overlap with those predicting bleeding. The assessment of both ischaemic and bleeding risks in the management of ACS patients is in agreement with the ESC guidelines, which do endorse, among others, the use of Global Registry of Acute Coronary Events (GRACE) and Can Rapid Risk Stratification of Unstable Angina Patients Suppress Adverse Outcomes With Early Implementation of the

ACC/AHA Guidelines (CRUSADE) scores. However, it should be emphasized that there is no evidence supporting the use of these scores to guide P2Y₁₂ inhibitor choice.

- The ESC non-ST elevation acute coronary syndrome (NSTEMI-ACS) Guidelines as well as the ESC DAPT Focused Update recommend more potent P2Y₁₂ inhibitors (ie, ticagrelor or prasugrel) to be preferred over clopidogrel in patients with ACS, whose duration needs to be tailored according to the bleeding risks.⁵
- However, the use of prasugrel in patients aged 75 or greater is relatively discouraged. Moreover, patients judged at high bleeding risk according to the investigators had to be excluded from participation in the TRial to assess Improvement in Therapeutic Outcomes by optimizing platelet inhibition with prasugrel–Thrombolysis In Myocardial Infarction (TRITON-TIMI 38) where the superiority of prasugrel over clopidogrel was shown.¹⁹ Therefore, it remains unclear if prasugrel should be preferred over clopidogrel in this high-risk setting. Moreover, since therapy with a P2Y₁₂ inhibitor was implemented before knowing the coronary anatomy, ticagrelor should have been preferred over prasugrel, as prasugrel is only indicated in ACS patients in whom coronary anatomy is known and proceed to PCI.
- On the other hand, the benefits of ticagrelor over clopidogrel were shown to be consistent across age groups and high bleeding risk patients were sizable in the Study of Platelet Inhibition and Patient Outcomes (PLATO).²⁰ The use of ticagrelor is thus reasonable in high bleeding risk patients and most likely associated with better outcomes than clopidogrel. Moreover, in PLATO ticagrelor was administered upstream, i.e. before knowing the coronary anatomy, and could therefore have replaced clopidogrel without the need to modify the timing of P2Y₁₂ administration. However, it should be noted that no dedicated study exists comparing ticagrelor over clopidogrel in high bleeding risk patients and patients needing OAC were excluded.
- The Prolonging Dual Antiplatelet Treatment After Grading Stent-Induced Intimal Hyperplasia Study (PRODIGY) retrospectively observed that the CRUSADE score could identify patients at higher risk of haemorrhagic complications when treated with a two-year DAPT as compared to six-month therapy.²¹ However, all patients were treated with aspirin and clopidogrel in both treatment duration arms so no clear conclusion can be drawn from this analysis on which P2Y₁₂ inhibitor should be preferred in high bleeding risk patients. Similarly, only patients without high bleeding risk features, according to the PREDicting bleeding Complications In patients undergoing Stent implantation and subsequent Dual Anti Platelet Therapy (PRECISE-DAPT) score (a bleeding risk stratification tool), were shown to derive benefit from prolonged DAPT as compared to a shorter duration regimen.²² Acknowledging that DAPT consisted mainly of aspirin and clopidogrel, the results of this study remained consistent across the types of P2Y₁₂ inhibitor. This finding corroborates the notion that a shorter DAPT duration regimen is preferable over a longer course of treatment in high bleeding risk patients but it does not help answer the question of whether clopidogrel or one of the newer P2Y₁₂ inhibitors is to be preferred in this subpopulation.

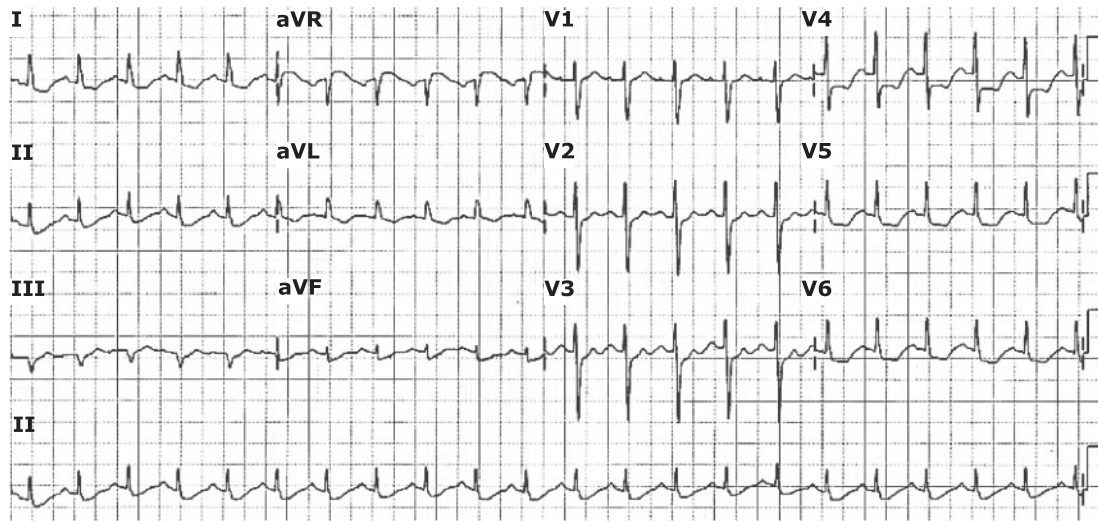


Figure 6 Patient's electrocardiogram at presentation.

DAPT Hospital Algorithm by Berenguer-Jofresa et al.

Non ST-segment elevated myocardial infarction

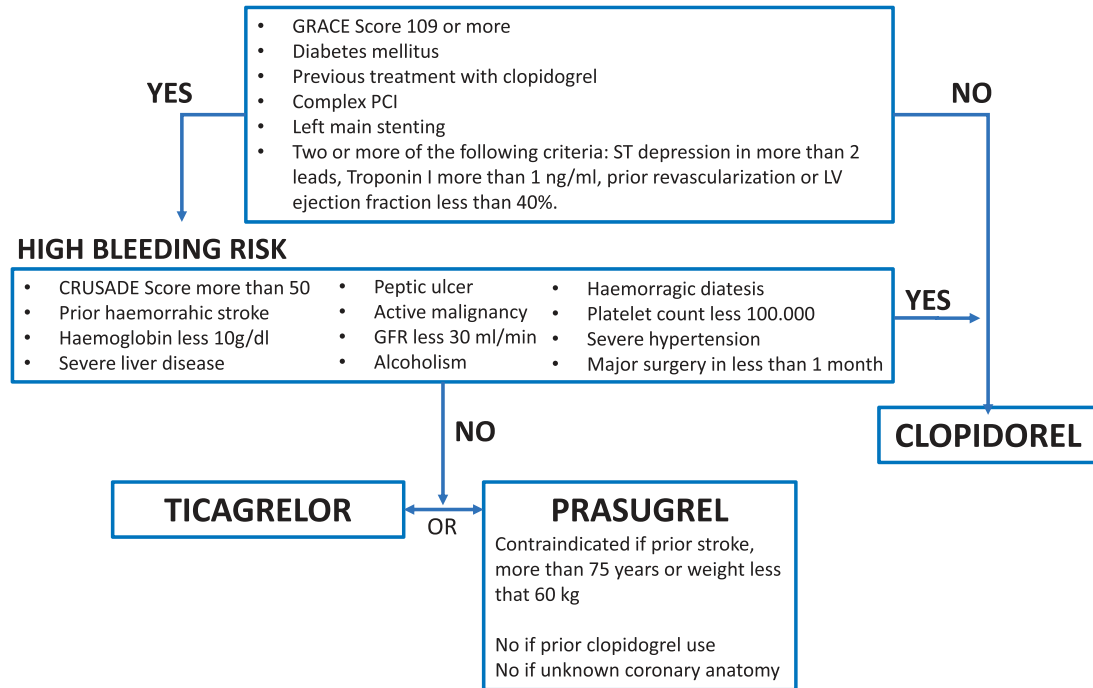


Figure 7 In hospital algorithm for dual antiplatelet therapy selection by Berenguer-Jofresa et al. CRUSADE = Can Rapid Risk Stratification of Unstable Angina Patients Suppress Adverse Outcomes With Early Implementation of the ACC/AHA Guidelines; GFR = glomerular filtration rate; GRACE = Global Registry of Acute Coronary Events; PCI = percutaneous coronary intervention.

Case #7 Nasal bleeding and dual antiplatelet therapy

An 82-year-old woman with multiple comorbidities was admitted to an outpatient clinic because of epistaxis. She also suffered in the days before from uncontrolled hypertension, recurrent chest pain and transient neurological symptoms including possible retrograde amnesia. She had known hypertension, hyperlipidaemia and chronic stable angina. Eight years before presentation, she underwent coronary angiography, which showed normal LV systolic function and three-vessel CAD for which coronary artery bypass grafting (CABG) was indicated. She refused CABG surgery and was managed conservatively with a DAPT regimen consisting of aspirin 100 mg/day and clopidogrel 75 mg/day, a beta-blocker, a nitrate, an ACE inhibitor, a statin and a calcium channel blocker. Since this medical regimen was implemented, the statin and clopidogrel were transiently stopped and then restarted on two different occasions based on first disappearance and then recurrence of anginal symptoms.

Anterior nasal tamponade was performed to control the epistaxis. Therapy with diuretics was also implemented to better control blood pressure levels. A neurology consultation excluded acute neurological disease. Epistaxis, uncontrolled hypertension and recurrent angina symptoms continued for an additional two to three weeks. ACE inhibitors and diuretics were up titrated. Following on from an otorhinolaryngology consultation, treatment with anti-histamines for a few days was also implemented.

Laboratory examinations (e.g. haemoglobin 13.5 g/dL; platelet count 179 000/ μ L; creatinine 88.8 μ mol/L) and cardiac findings, including a TTE and ECG (Figure 8) were unremarkable at the time of presentation.

Since the epistaxis persisted despite clopidogrel discontinuation, aspirin was also discontinued and concomitant therapy with trimetazidine was implemented, which resulted in no further episodes of epistaxis. Aspirin was then restarted a few weeks thereafter and continued throughout, without further recurrences of bleeding.

Comments from the Task Force

- This case provides opportunity for further clarifications on the currently approved DAPT indications in patients with stable CAD. Patients with stable CAD have a class I indication for DAPT if percutaneous revascularization is implemented. With respect to CABG, there is no convincing evidence for DAPT in the postoperative phase to prevent graft failure. Finally, there is no evidence to support DAPT in patients with stable CAD treated conservatively, as in the patient described here. This is at variance with patients presenting with ACS in whom indication for DAPT exists irrespective of the concomitant revascularization procedure and type thereof.
- This patient self-presented to an emergency room with complaints notable, among others, for epistaxis. However, the previously implemented DAPT regimen was not immediately discontinued, which may have contributed to the persistence of symptoms. Given the well-known association between use of anti-thrombotics and bleeding, including epistaxis,²³ and considering the lack of evidence in support of a DAPT regimen for this specific indication,^{24,25} immediate discontinuation of one antiplatelet agent would have been indicated. Hence, the final decision to leave this patient on aspirin monotherapy is entirely justified.
- After managing the acute bleeding with nasal tamponade, a first attempt to prevent recurrences by lowering arterial blood pressure levels was made. Interestingly, it is still doubtful whether a connection exists between epistaxis and hypertension.²⁶ The prevalence rates of hypertension among patients with epistaxis range from 17% to 67%.²⁷ However, it is a subject of longstanding controversy whether there is solely an association or cause and effect relationship between hypertension and epistaxis.²⁶
- Finally, there is no evidence that a DAPT regimen can act by improving anginal symptoms. Hence, if there are recurrent or worsening angina symptoms limiting quality of life despite optimization of anti-anginal medications, a repeat coronary angiogram and revascularization should be considered.

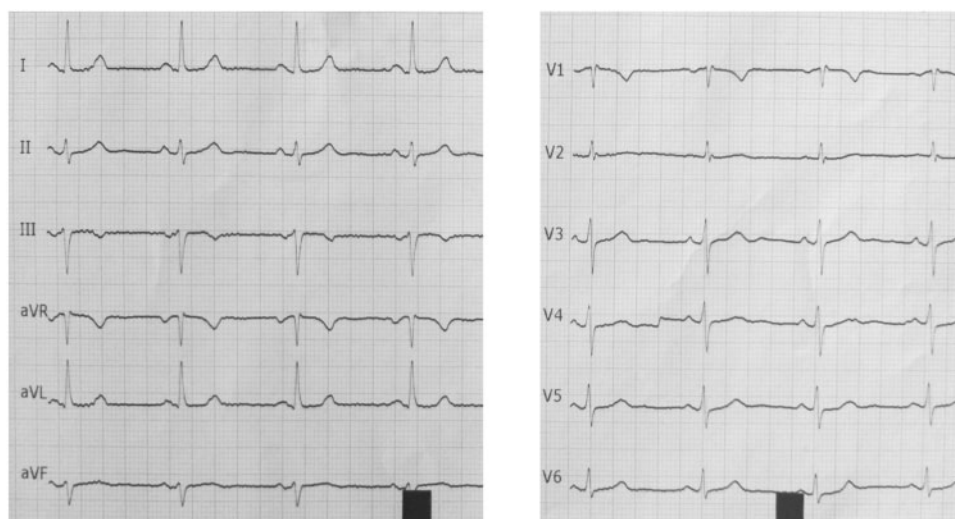


Figure 8 Patient's electrocardiogram at presentation.

Case #8: Dual antiplatelet therapy reveals what the eye cannot (yet) see

A 75-year-old smoker with untreated hypertension and hypercholesterolaemia presented with anterior STEMI. The patient mentioned that three months earlier he had reddish coloured urine for 2 - 3 days without fever or dysuria, but he did not seek medical advice as the condition resolved spontaneously. As soon as the STEMI diagnosis was made, the patient received aspirin 250 mg IV, ticagrelor 180 mg, enoxaparin 4000 units IV, pantoprazole 40 mg, and atorvastatin 80 mg. While waiting for the catheterization laboratory room to be free, the patient underwent TTE showing a moderate reduction in LV systolic function (LVEF 35 - 40%) in the presence of anterior akinesia. Using right radial access, the patient underwent primary PCI of a critical proximal LAD lesion treated with one everolimus-eluting stent (3.5 × 48 mm) and the clinical course was uneventful (Figure 9). The patient was discharged on day 5 on aspirin 100 mg/day and ticagrelor 90 mg *b.i.d.* in association with other secondary prevention medications. On day 8, he was readmitted for macro-haematuria. His systolic blood pressure was 95/55 mmHg, heart rate 90 bpm, haemoglobin level was 8.4 g/dL and haematocrit 30.1%. Bladder ultrasound detected two lesions and raised suspicion for cancer. Aspirin was continued, ticagrelor was discontinued and enoxaparin 4000 units/day was added by the internal medicine doctors. Two units of packed red blood cells were transfused. On day 12, haematuria persisted while the patient was haemodynamically stable and haemoglobin and haematocrit were 10.4 g/dL and 32.1%, respectively. On day 13, a urethro-cystoscopy with endoscopic resection of the lesions was performed. Enoxaparin was stopped 12 hours before the intervention while aspirin was continued. Two hours post intervention, tirofiban infusion was started with a bolus dose of 0.4 µg/kg/min in 30 min, followed by a maintenance infusion of 0.1 µg/kg/min. He had no recurrence of haematuria and on day 14 haemoglobin was 11.4 g/dL and haematocrit 34.1%. The same day ticagrelor was administered with a loading dose of 180 mg and continued with 90 mg *b.i.d.*, and after two hours the tirofiban infusion was stopped. On day 28, while the patient remained asymptomatic, a non-invasive, high-grade bladder cancer, with multiple sessile, micro-papillary lesions was confirmed. It was recommended to perform a radical resection of the bladder as soon as possible and in any case within 90 days to improve survival. On day 38, surgery was performed. Aspirin was continued while ticagrelor was discontinued five days before surgery. Tirofiban infusion was started 24 hours post-ticagrelor discontinuation (i.e. four days before surgery) with a bolus dose of 0.4 µg/kg/min in 30 min, followed by a maintenance infusion of 0.1 µg/kg/min. Tirofiban was stopped four hours before surgery and restarted two hours after surgery, with the same bolus and maintenance doses. In the absence of bleeding, 12 hours post-surgery ticagrelor was administered with a loading dose of 180 mg and continued with a maintenance dose of 90 mg *b.i.d.* intended for a total of 12 months post PCI. Two hours after the ticagrelor bolus the tirofiban infusion was discontinued. The postoperative course was uneventful and at his last follow-up at nine months post PCI the patient was still on DAPT and had no bleeding or ischaemic events.

Comments from the Task Force

- As a general rule, management of patients on DAPT who are referred for surgical procedures involves consideration of: (1) the risk of ST (particularly if DAPT needs to be interrupted); (2) the consequences of delaying the surgical procedure; and (3) the increased intra- and peri-procedural bleeding risk and possible consequences of such bleeding if DAPT is continued. Given the complexity of these considerations, a multidisciplinary approach, involving interventional cardiologists, cardiologists, anaesthetists, haematologists and surgeons is required to determine the patient's risk for bleeding and thrombosis and to choose the best management strategy.
- Presenting with STEMI, the patient qualified for DAPT with aspirin and ticagrelor. The decision to discontinue ticagrelor on day 8 post PCI due to major urinary bleeding was a difficult one, but reasonable due to the ongoing bleeding and the fact that most urologists would not perform urethro-cystoscopy with endocavitary treatment in the presence of DAPT due to the bleeding risk. However, the patient was at the same time at very high risk of ST. Accordingly, he had multiple characteristics that have been associated with ST: recent (< 2 weeks) stent implantation, clinical presentation (ACS), long stent, cancer, and the need for surgery. In addition, in the event of ST the consequences would have been potentially catastrophic based on the stent location (proximal LAD). Ticagrelor was discontinued five days before urethro-cystoscopy; in this respect, a shorter duration of discontinuation could have been an option. Accordingly, the 2017 ESC DAPT Focused Update document states that ticagrelor discontinuation should be considered at least three days before surgery.
- At the time of ticagrelor discontinuation the patient received prophylactic enoxaparin in addition to aspirin. While potentially increasing the risk of bleeding (especially in patients with renal insufficiency, a condition not mentioned in the case), enoxaparin in prophylactic or therapeutic doses is not known to reduce the risk of ST. Therefore, low-molecular-weight heparins should not be administered under the expectations that this would mitigate the risk of ST. For patients with a very high risk of ST, like the one described, the 2017 ESC DAPT Focused Update states that bridging therapy with IV reversible glycoprotein inhibitors, such as tirofiban or eptifibatid, may be considered. The reversible IV P2Y₁₂ inhibitor cangrelor is an appealing alternative, given the role of P2Y₁₂ inhibition in preventing ST and the quicker offset of action as compared with tirofiban or eptifibatid. In this setting concomitant parenteral anticoagulation therapy in conjunction with glycoprotein inhibitors or cangrelor is not recommended. In the case described, tirofiban was not administered before the urologic procedure but thereafter, for 24 hours, before restarting ticagrelor.
- Following the results of a biopsy showing cancer, it was decided to perform a cystectomy on day 38 post PCI. The pros and cons of having an early vs. delayed surgery have to be discussed on a case by case basis. This time the investigators implemented a full bridging (i.e. before and after surgery) with tirofiban. It has to be noted that the risk of ST by DAPT discontinuation decreases after the first month post PCI. Whenever possible, at least one month of DAPT should be administered after stent implantation, independently of the type of device (i.e. BMS or newer generation DES). If surgery has to be performed within the first month after PCI, the operation should take place in hospitals where cardiac catheterization laboratories are available 24/7 in order to treat patients immediately in case of perioperative ST. In patients at

high ischaemic risk due to ACS presentation or complex coronary revascularization procedure, delaying surgery up to six months after ACS or PCI may be reasonable as a safeguard to minimize the risk of perioperative MI

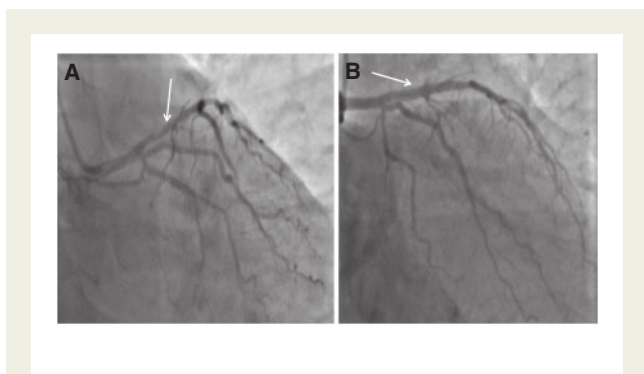


Figure 9 Angiogram showing critical lesion of a proximal left anterior descending coronary artery (A) treated with primary percutaneous coronary intervention and implantation of one everolimus-eluting stent (B).

Case #9: A case with very late stent thrombosis 20 months after implantation of a biodegradable polymer sirolimus-eluting stent

A 56-year-old man presented with NSTEMI (peak troponin T 9.24 µg/L). Coronary angiography showed total occlusions of the proximal LCX and proximal LAD with a collateral flow from the RCA and septal branch to the distal LAD (Figure 10A). Two biodegradable polymer sirolimus-eluting stents (BP-SES, Orsiro 3.5 × 15 mm and 3.0 × 15 mm) were deployed in the LCX (Figure 10B), and two additional BP-SES (3.0 × 26 mm and 2.5 × 40 mm) were used to treat the LAD one month after the index procedure (Figure 10C,D). Maintenance DAPT (aspirin 100 mg *q.d.* and ticagrelor 90 mg *b.i.d.* mg) was prescribed for 12 months, followed by life-long aspirin monotherapy. The patient presented with antero-lateral (Figure 10E) STEMI 20 months after the first stent implantation (peak troponin T 3.9 µg/L). Angiography revealed very late ST in the LAD (Figure 10F). Optical coherence tomography (OCT) after a low-pressure dilatation using a 2.5 mm balloon was performed to assess underlying mechanisms of very late ST. While the stent struts were well apposed proximally and distally to the thrombosed region (Figure 10G,J), a positive remodelling with enlargement of the adventitia (4.9 × 4.3 mm, Figure 10H, arrows) was observed. Apposition status of the struts could not be assessed due to the massive superimposed thrombus. Focal signs of evagination at the proximal edge of the positively remodelled segment were also observed (Figure 10 I, asterisk). Very late ST occurred 20 months after the implantation of a newer-generation DES with biodegradable polymer, with evidence of positive remodelling, even on the maintenance aspirin monotherapy following 12 months of DAPT. How should DAPT be managed in this patient?

Comments from the Task Force

An extraordinary amount of scientific scrutiny has been devoted to the safety profile of first and newer generation DES. First generation DES have been consistently shown to be associated with a four- to five-fold higher risk of very late (i.e. after the first year) ST as compared to BMS.^{28–31} This observation corroborated the perception of increased thrombogenicity of DES as compared to BMS and fuelled ‘the longer the better’ notion for DAPT duration in DES treated patients.

- First generation DES have been entirely replaced by newer generation devices. Evidence of superior safety with respect to ST and target vessel MI has been generated for many of the newly introduced devices when compared to first generation DES.²⁸ There is a growing literature suggesting that at least some second generation devices are safer not only when compared to first generation but also to the corresponding BMS counterparts.^{32,33} As a result, it is relatively rare (unlike for first generation DES) to observe a very late ST after newer generation DES. Unlike the vast amount of rigorous statistics generated around the incidence and distribution of ST events over time after first generation devices, there are no randomized data to inform on the best management strategy for patients presenting ST, especially very late events. Available findings suggest a high risk for ST recurrences after the occurrence of first ST, with one patient in every four experiencing a recurrent event at the five-year time frame.³⁴
- A second key piece of information is that the risk for recurrence is highest in the first few months after the first event, but it does not abate entirely over time. A recent study extending over five years suggests that roughly 50% of events are clustered within the first year after the first ST whereas the remaining 50% of events occur from the second up to the fifth year of follow-up.^{35–38} This observation carries important implications with respect to the duration of secondary preventive measures in this small yet very high-risk patient population.
- All attempts should be made to retrieve all possible drivers for ST, including inspection of the index procedure and careful assessment of the patient’s history focusing on adherence to antiplatelet therapy. Since stent underexpansion or undersizing is known to frequently contribute to ST, optimal, ideally imaging-guided, further expansion of the originally implanted stent is frequently indicated beyond vessel recanalization.³⁷ Considering the long-term risk of recurrent ST after first ST event, any effort to maintain DAPT at very long-term or even lifelong, if tolerated. Since very late ST occurred in this patient months after DAPT discontinuation, and considering the uneventful outcome while the patient was still on DAPT, it may be reasonable to re-implement the previously administered P2Y₁₂ inhibitor. As was frequently the case for first generation DES, especially the Cypher sirolimus-eluting stent, evidence for (most likely acquired) positive remodelling of the vessel is provided here for the thrombosed segment. Should this mechanical issue also be tackled during re-intervention? There is unfortunately no proper guidance from the available literature. However, it is widely accepted that any effort should be made to expand the stent as much as is deemed safe.³⁷ Whether re-implantation of a second stent may help in trying to exclude the enlarged and widely remodelled vessel area and, by doing so, minimize the stagnation of flow and subsequent thrombosis is unknown, yet frequently performed in practice.^{37,38} The presence of positive remodelling, which will likely not be entirely removed or corrected at re-intervention, reinforces the importance of prolonging DAPT as much as tolerated.

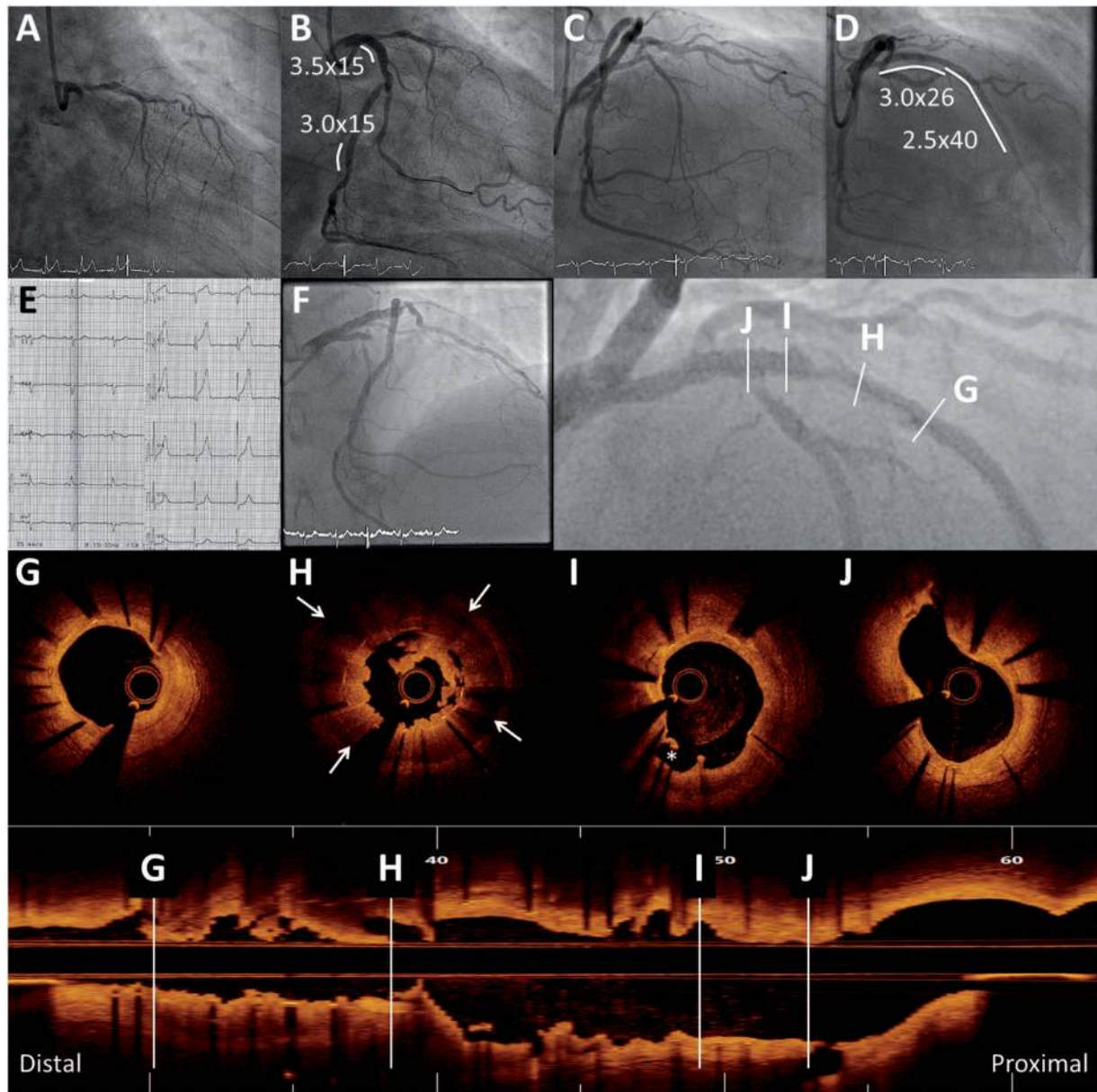


Figure 10 Coronary angiography showing total occlusions of the proximal left circumflex coronary artery and proximal left anterior descending coronary artery (A) treated with coronary stent implantation (B, C, D). Electrocardiogram showing ST segment elevation 20 months after first intervention (E) due to very late stent thrombosis confirmed at angiography (F). Optical coherence tomography showed good apposition of stent struts proximally and distally to the thrombosed region (G, J), positive remodelling (H, arrows) and focal signs of evagination at the proximal edge of the positively remodelled segment (I, asterisk).

Case #10: Prolongation of dual antiplatelet therapy after stent implantation for ST-elevation myocardial infarction

A 51-year-old woman with prior STEMI was evaluated at 12 months after the index event. Risk factors at the time of

primary PCI included prior smoking (40 cigarettes/day), hypertension and poorly controlled diabetes mellitus. Creatinine clearance was 68 mL/min. The STEMI was due to an acute occlusion of the distal LM/ostium of the LAD (Figure 11). A self-expanding nitinol sirolimus eluting stent (3.0 - 3.5 × 22 mm) was implanted from the LM into the proximal LAD (Figure 12). The stent struts lying in front of the LCX artery ostium were fenestrated by inflating a semi-compliant balloon (Figure 12). Finally, a second sirolimus

eluting stent (3.0 × 24 mm) was implanted in the proximal LAD in overlap with the first implanted stent, with a good angiographic result (Figure 12). Echocardiography during the hospital stay showed a mildly impaired LVEF (45%). The patient was discharged after eight days on DAPT with aspirin (100 mg daily) and ticagrelor (90 mg *b.i.d.*) for 12 months, atorvastatin, ACE inhibitor, beta-blockers and metformin. Thereafter, the patient remained asymptomatic. The patient's relatives referred good adherence to the medical treatment and cessation of cigarette smoking. Laboratory testing showed stable renal function and no anaemia. The calculated DAPT score at 12 months was 3 (Figure 13), suggesting a higher ischaemic vs. bleeding risk profile. Given the multiple ischaemic risk factors (clinical features resembling Prevention of Cardiovascular Events in Patients With Prior Heart Attack Using Ticagrelor Compared to Placebo on a Background of Aspirin-Thrombolysis in Myocardial Infarction 54 [PEGASUS-TIMI 54] trial inclusion criteria) and the acute clinical presentation for the index event, the decision was taken to continue DAPT with aspirin and ticagrelor 60 mg *b.i.d.* for an additional 12 months.

Comments from the Task Force

- The DAPT score is a new standardized tool aiming at identifying which patients would derive benefit or harm from a prolonged duration of DAPT.³⁹ The DAPT score integrates ischaemic and bleeding risk

factors, in order to guide patient selection for optimal DAPT duration in patients who received DAPT for one year after PCI, and were free from ischaemic as well as bleeding events. The score ranges from -2 to 10 and is calculated by assigning points according to characteristics related to the *patient* (0 for age < 65 years, -1 for age ≥ 65 and < 75 years, -2 for age ≥ 75 years, 1 for diabetes mellitus, 1 for current smokers, 1 for previous PCI or prior myocardial infarction, 2 for history of congestive heart failure or LVEF < 30%) and the *index procedure* (1 for acute MI at presentation, 2 for PCI of saphenous vein graft, 1 for implantation of paclitaxel-eluting stent, 1 for stent diameter < 3 mm). Overall, a low DAPT score (< 2) identifies patients for whom bleeding risks outweigh ischaemic benefits, while a high DAPT score (≥ 2) identifies patients for whom ischaemic benefits outweigh bleeding risks. The score is available on the website at <http://www.daptstudy.org/for-clinicians/calchome.htm>.

- The 2017 ESC Focused Update states that the DAPT score may be used to guide duration of treatment. While it remains unclear whether the routine use of this score improves patient outcomes, this document endorses its use on the basis that, together with PRECISE-DAPT, it is the only available scoring system which has been developed deliberately with this aim. Additionally, it may help clinicians focusing on the patients and procedural characteristics most likely to derive benefit or lack thereof from a prolonged DAPT treatment in an a priori selected group of patients, which the case just described belongs to.

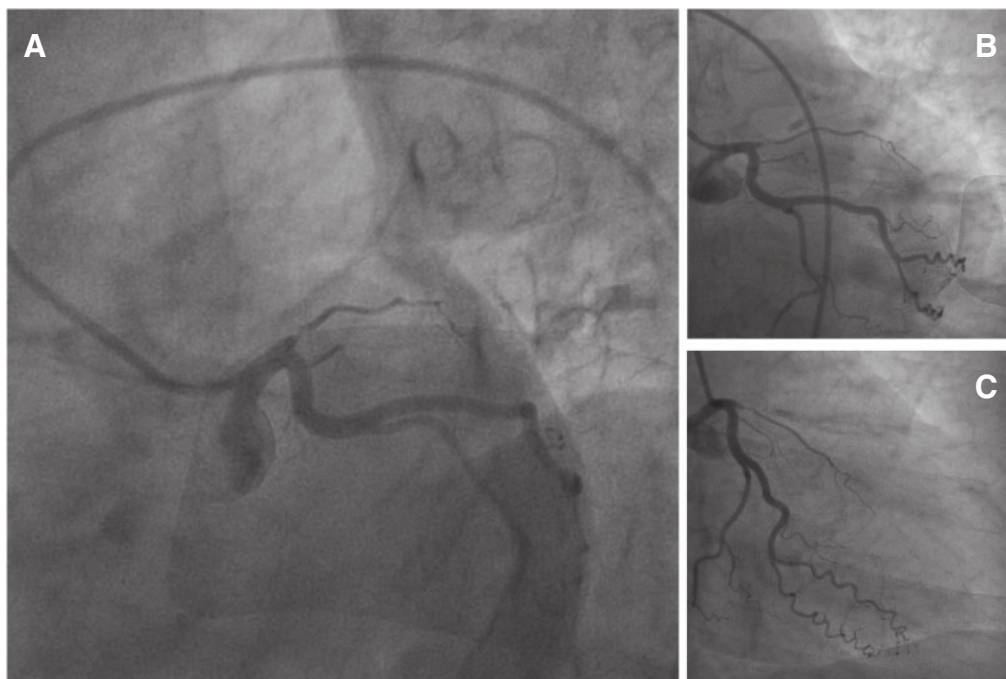


Figure 11 Thrombotic occlusion at the ostium of the left anterior descending coronary artery (A, B, C).

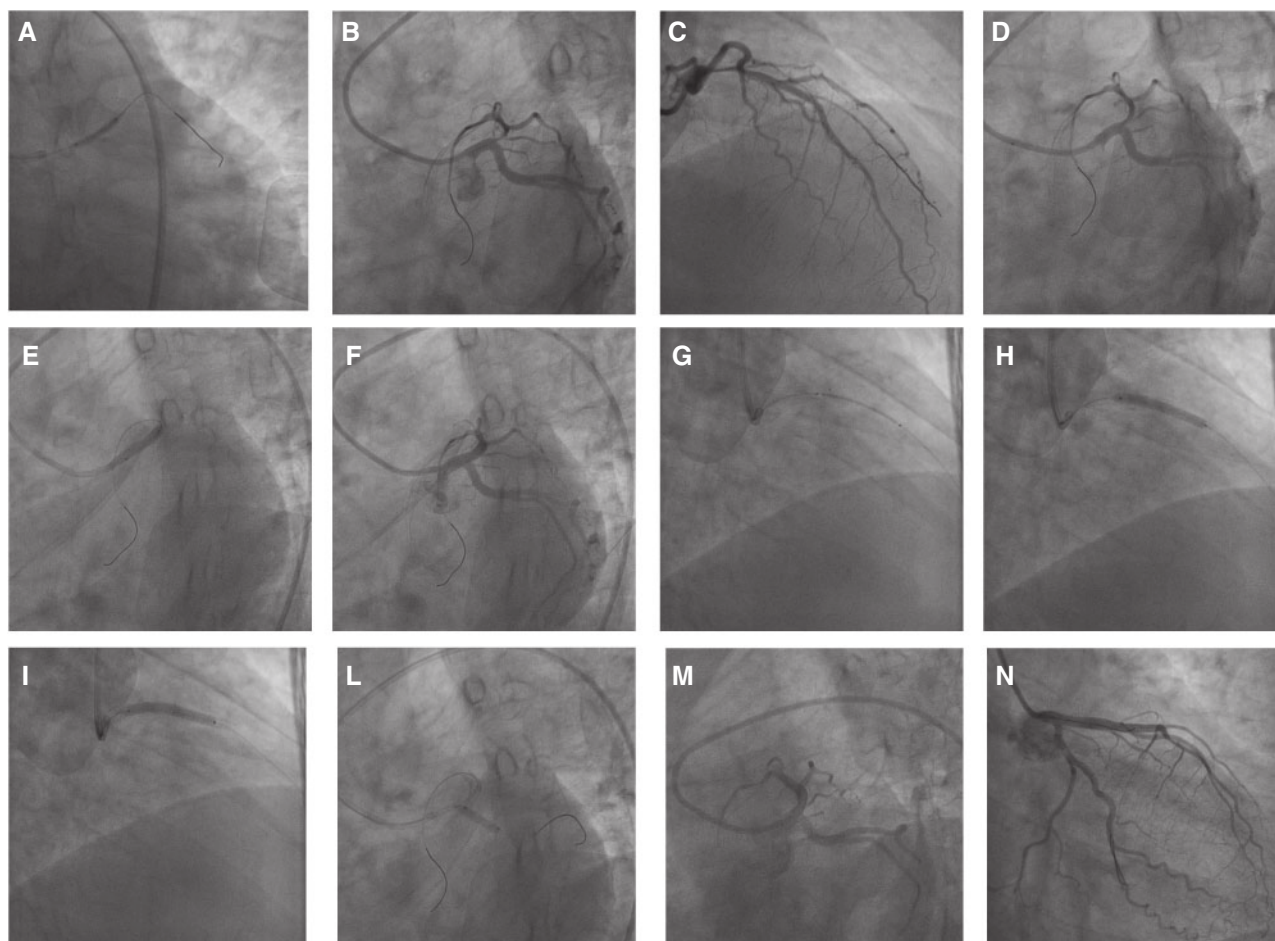


Figure 12 Primary percutaneous coronary intervention. Balloon inflation (A) is used to restore minimal flow in the left anterior descending coronary artery (B, C, D). A self-expanding sirolimus-eluting nitinol stent is placed and implanted at the distal segment of the left main in the direction of the left anterior descending coronary artery (E). A second sirolimus eluting stent is implanted distally with minimal overlap (G, H, I). Fenestration of the stent struts in the left main towards the circumflex artery (L). Final angiographic result (M, N).

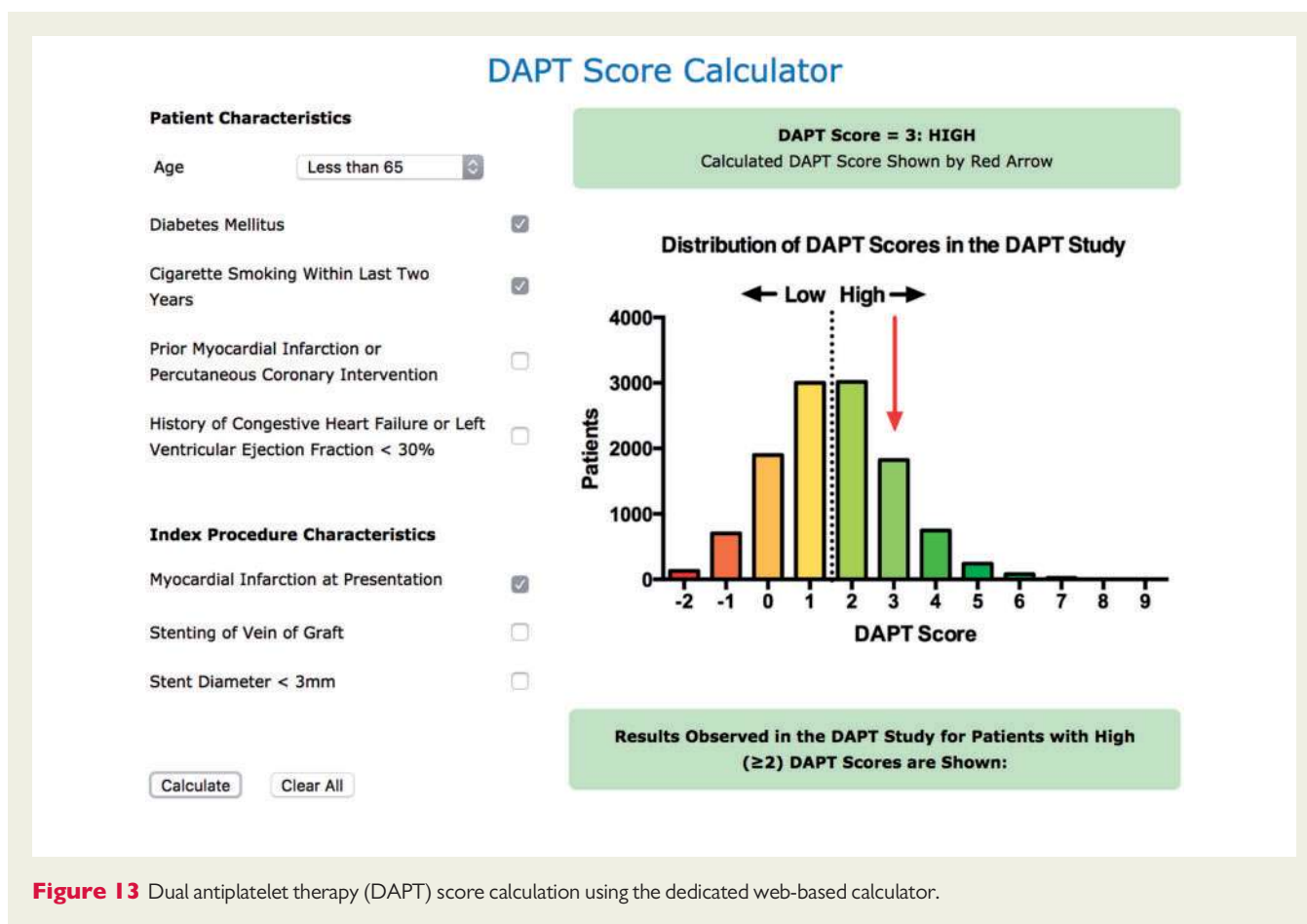


Figure 13 Dual antiplatelet therapy (DAPT) score calculation using the dedicated web-based calculator.

Case #11: Ischaemia and bleeding in a young patient: between a rock and a hard place

A 41-year-old man was transported to the emergency department for continuous and oppressive chest pain associated with nausea and vomiting lasting for six hours. His only cardiovascular risk factor was diabetes mellitus treated with insulin. The ECG showed ST-segment elevation in the anterolateral leads and ST-segment depression in the inferior leads. The patient was haemodynamically stable (blood pressure 147/102 mmHg; heart rate 90 bpm; SaO₂ 100%), with no signs of heart failure. Antiplatelet therapy (aspirin 300 mg and clopidogrel 300 mg) as well as heparin were administered while the patient was transferred to the catheterization laboratory for primary revascularization. A coronary angiogram performed from the right femoral approach revealed a thrombotic occlusion at the ostium of the LAD, which was treated with mechanical thrombectomy and PCI with zotarolimus eluting stent implantation (Figure 14). Vascular closure was obtained with a closure device. At this time, clopidogrel was switched to ticagrelor (180 mg loading dose administered in the catheterization laboratory).

On day 2, TTE was performed showing akinesia of the anterior mid-apical segments and a large apical thrombus (22 × 23 mm); for

this reason, oral anticoagulation with acenocoumarol on top of low molecular weight heparin was started. Ticagrelor was discontinued and clopidogrel 75 mg *q.d.* was initiated the same day.

On day 4, the patient remained asymptomatic but routine blood tests revealed a reduction of approximately 5 mg/dL of the haemoglobin level. CT showed a right retroperitoneal haematoma and persistence of a large thrombus in the LV (Figure 15). Since the LV thrombus was deemed not to be immediately life-threatening, a conservative management with anticoagulation discontinuation (both low molecular weight heparin and acenocoumarol) and IV iron supplementation was selected, while DAPT was maintained. On day 8 the patient experienced a new episode of central crushing chest pain. An ECG revealed recurrent ST-segment elevation in the anterior leads and the patient was emergently transferred for coronary angiography. The angiogram performed via the radial approach showed acute ST at the ostium of the LAD (Figure 16). Mechanical thrombectomy and balloon angioplasty restored Thrombolysis In Myocardial Infarction (TIMI) grade III coronary flow. Unfortunately, at the end of the procedure, after removal of the radial vascular access, a second episode of chest pain and ST segment elevation on lateral leads occurred. The left femoral approach was then used, and a coronary angiogram showed recurrent ST protruding into the distal LM bifurcation with the LCX, with a TIMI grade I flow (Figure 17). An abciximab bolus was administered and mechanical thrombectomy of

both the LAD and circumflex arteries was performed. However, due to the persistence of flow limiting thrombus in the circumflex artery, the distal LM was approached with bifurcation stenting (mini-crush technique) with two zotarolimus eluting stents. The intervention was concluded with a final kissing-balloon, and a good angiographic result (Figure 17). After the intervention, the patient was treated with aspirin, ticagrelor and acenocoumarol with strict international normalized ratio (INR) monitoring. Hospital stay was further complicated by a mesenteric embolization, which was treated conservatively without sequelae. The patient showed a slow but continuous improvement of the clinical condition in the following weeks. At the time of discharge, TTE demonstrated complete resolution of the apical thrombus. The patient was discharged on triple therapy while acenocoumarol discontinuation was planned in the weeks to come.

Comments from the Task Force

This challenging case raises several points for discussion.

- First, the need to de-escalate the type of P2Y₁₂ inhibitors, i.e. from more potent prasugrel or ticagrelor to clopidogrel, in order to accommodate the initiation of oral anticoagulation is not infrequent. The 2017 ESC DAPT Focused Update recommends to switch from ticagrelor to clopidogrel by administering a 600 mg loading dose of clopidogrel, both in the acute and chronic setting (see chapter 3.8 in full text document).

This in order to avoid a lack of proper platelet inhibition while clopidogrel has not yet reached a steady state and the effect of ticagrelor is over. The mentioned state may have contributed to the occurrence of subacute ST in this patient, perhaps in conjunction with the suboptimal stenting technique.

- Given the concerns that treatment with clopidogrel may not suffice to prevent recurrent ST in this very high risk patient, the decision to co-administer aspirin, ticagrelor and oral anticoagulation can be justified, although, as a general rule, triple therapy including ticagrelor or prasugrel is not recommended based on safety concerns.
- To minimize the risk of bleeding in relation to such an anti-thrombotic regimen, the decision was taken to reduce the duration of concomitant oral anticoagulation, from up to six months as per the ESC STEMI 2017 guidelines recommendations to a few weeks. In order to avoid LV thrombus recurrence, a close follow-up with TTE (if the ultrasound window is adequate) or MRI is warranted. Moreover, a longer duration of OAC in a patient with prior systemic embolization could be envisioned. Possible alternative treatment strategies – even if not evidence based – would have been the decision to drop aspirin for the period of time concomitant anticoagulation is administered or to switch the patient back to clopidogrel by means of a 600 mg loading dose and careful monitoring of the degree of P2Y₁₂ inhibition by platelet function testing to exclude the possibility that the patient is a poor- or non-responder to clopidogrel.
- Finally, this case illustrates the advantages of using a radial instead of a femoral access site.

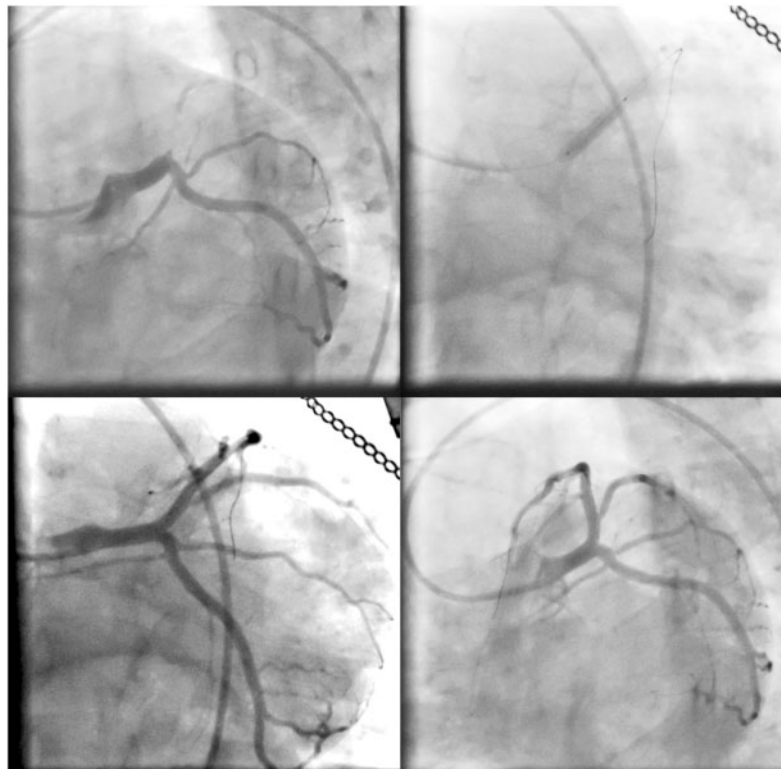


Figure 14 Coronary angiogram showing thrombotic occlusion of the left anterior descending coronary artery, treated with primary percutaneous coronary intervention and stenting.

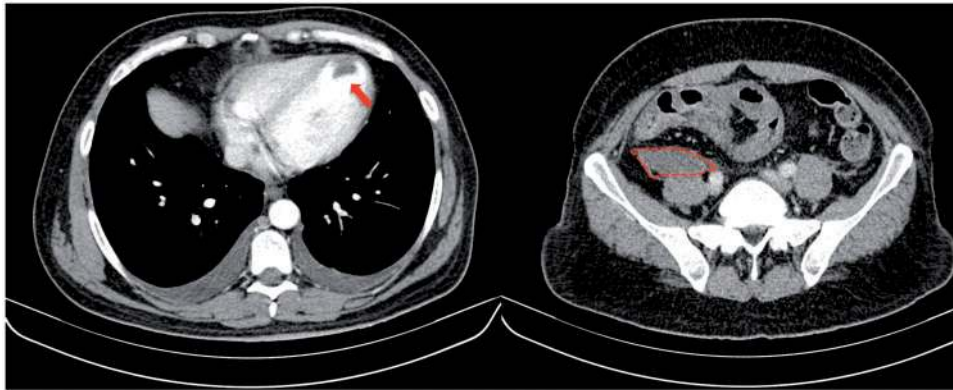

Figure 15 Computed tomography scan revealing persistence of the apical thrombus (left panel) and right retroperitoneal haematoma (right panel). Video available online.

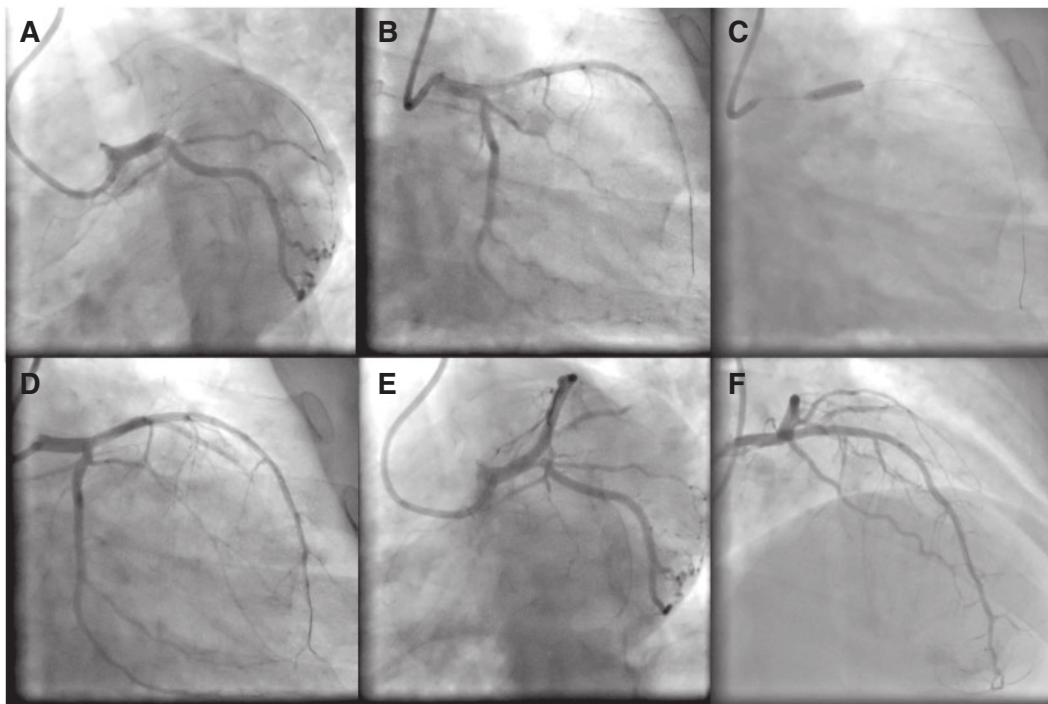


Figure 16 First stent thrombosis of the device implanted at the left anterior descending coronary artery ostium (A, B). Coronary angiogram and intervention with thrombus aspiration and balloon angioplasty (C, D, E, F).

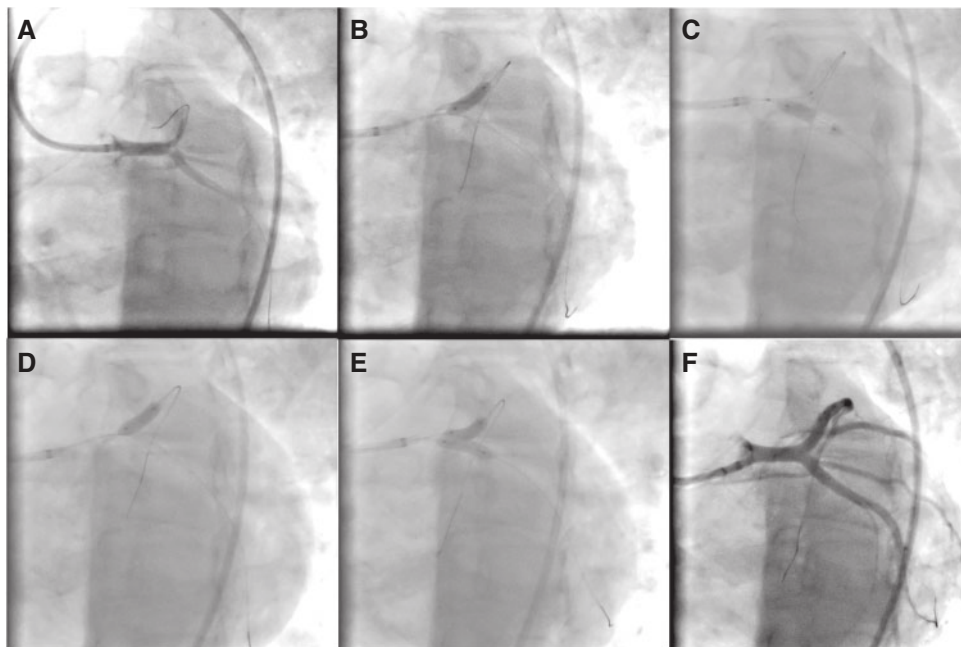


Figure 17 Second stent thrombosis of the device implanted at the left anterior descending coronary artery ostium with thrombotic obstruction of the circumflex artery ostium (A). Bifurcation stenting of the distal left main with mini-crush technique was performed (B, C, D, E) with good result (F).

Case #12: Dual antiplatelet therapy: treatment decision-making with risk scores after stent implantation

A 76-year-old woman with stable angina (Canadian Cardiovascular Society II) and positive stress-echocardiography was referred for coronary angiography. Her medical history included hypertension, dyslipidaemia, well-controlled insulin-requiring diabetes mellitus, and previous smoking (she stopped smoking one year prior to admission). No prior history of bleeding was reported. TTE revealed preserved LVEF (55%) with mild mitral regurgitation. Laboratory data before admission showed haemoglobin 11.2 g/dL and creatinine clearance 48 mL/min. A coronary angiogram revealed significant lesions of the mid-segment of the LAD (Figure 18) and no significant stenosis on RCA and LCX. She was treated with PCI and implantation of two overlapping everolimus-eluting stents (3.0 × 18 mm and 2.75 × 23 mm) in the LAD (Figure 18). No complication occurred during the hospital stay. At discharge her PRECISE-DAPT score was 35, indicating a high risk of bleeding, and three to six months of treatment with clopidogrel on top of life-long aspirin was prescribed

(Figure 19). The patient remained asymptomatic and at three months' follow-up was free of chest pain and no bleeding events had occurred. DAPT was then prolonged for three additional months.

Comments from the Task Force

- DAPT with aspirin plus a P2Y₁₂ inhibitor prevents ischaemic events after coronary stenting, but increases bleeding. Guidelines support weighting bleeding risk prior to the selection of treatment duration, and PRECISE-DAPT may be used for that purpose soon after percutaneous intervention to guide DAPT duration.²² The score integrates age, creatinine clearance, haemoglobin, white blood cell count and prior spontaneous bleeding, and can be found at www.precisedaptscore.com.
- Selecting upfront a shorter than 12-month treatment duration in patients, including ACS, deemed at high bleeding risk (PRECISE-DAPT score ≥ 25) was shown retrospectively to prevent exposing them to an excessive bleeding hazard. In turn, patients at non-high bleeding risk (PRECISE-DAPT score < 25) might receive a standard (i.e. 12 months) or a prolonged (i.e. > 12 months) course of treatment if tolerated. It should be stated, however, that the ESC DAPT Focused Update recommends six months of DAPT as the standard duration in the case of PCI, irrespective of stent type used, in patients with stable CAD.

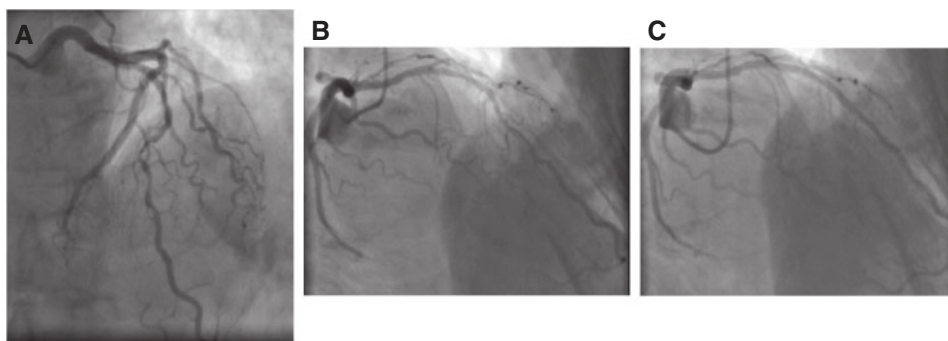


Figure 18 Elective coronary angiogram revealing long lesion of the mid-segment of the left anterior descending coronary artery (A-B). Optimal result after percutaneous coronary intervention (C).

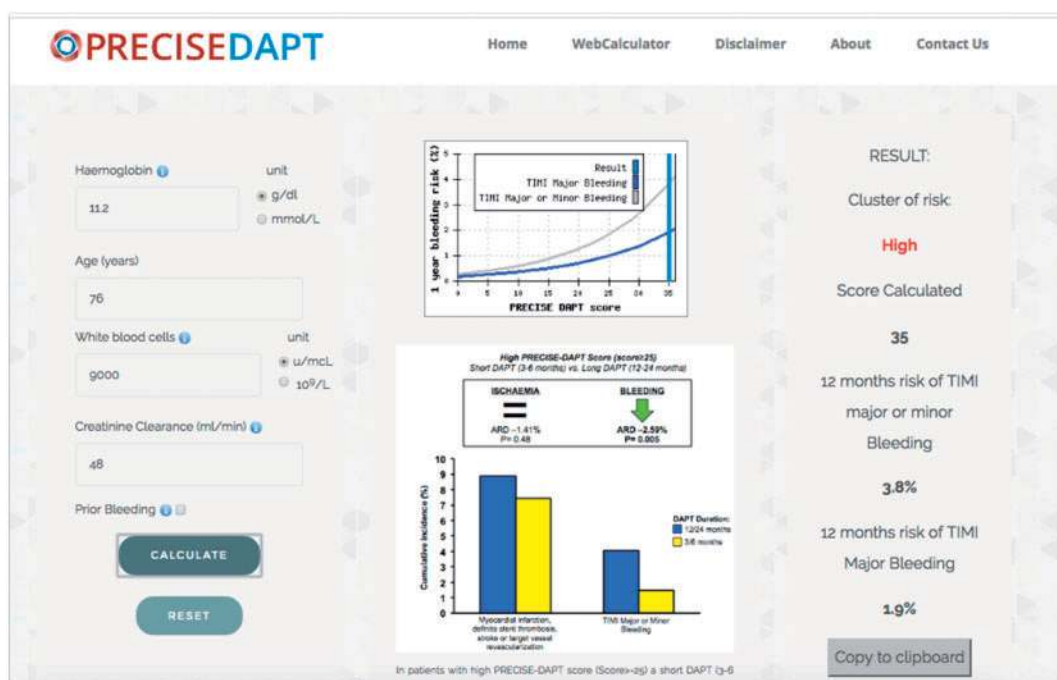


Figure 19 PRECISEDAPT score calculation using the dedicated web-based tool. PRECISEDAPT = PREdicting bleeding Complications In patients undergoing Stent implantation and subsequent Dual Anti Platelet Therapy. TIMI = Thrombolysis in Myocardial Infarction.

Case #13: Oral anticoagulation, triple therapy and complex percutaneous coronary intervention

A 78-year-old man was admitted for NSTEMI. His cardiovascular risk factors included hypertension, hypercholesterolaemia and diabetes treated with oral hypoglycaemic drugs. He was known for paroxysmal atrial fibrillation treated with rivaroxaban 20 mg/day, two previous strokes, and surgery for diverticulitis 13 years earlier. His kidney function was normal. He received oral aspirin 200 mg. Coronary angiography showed a 70 - 90% distal LM bifurcation lesion and a 70 - 90% severely calcified stenosis of the proximal LAD, in conjunction with other multiple lesions in the RCA (Figure 20). The ventricular function was normal. Despite the low CABG mortality estimated by the Society Of Thoracic Surgery (STS) score (2.4%) and Euroscore II (2.2%) and the presence of diabetes, the Heart Team proposed a PCI based on the considerations that the LCX was a small vessel which could not be bypassed, the RCA branches also had distal lesions not accessible to surgical revascularization, and the patient had suffered two previous strokes. These limitations for surgery were weighted, also in the discussion with the patient and his family, against the fact that he would require multiple stents and was at the same time on chronic anticoagulation. This put him at increased ischaemic risk, especially in case of premature platelet inhibition discontinuation, as well as at increased bleeding risk because of triple therapy (aspirin, clopidogrel, and anticoagulation) and a Hypertension, Abnormal Renal/Liver Function, Stroke, Bleeding History or Predisposition, Labile INR, Elderly, Drugs/Alcohol Concomitantly (HAS-BLED) score of 3. Using a bilateral transfemoral approach and intra-aortic balloon counterpulsation (which may have been avoided to further increase the risk of bleeding), a total of four DES (Biofreedom, Biosensor) were placed in the RCA and in the PL branch of the same vessel while the posterior descending artery (PDA) was treated with balloon angioplasty only (small vessel). Subsequently, after rotablation of the LAD, two Biofreedom stents were placed in the LM and proximal LAD while the ostium of the small LCX was treated with balloon angioplasty only (opening of the struts of the LM struts) (Figure 20). The procedure was uneventful and, in addition to aspirin, the patient received 600 mg clopidogrel loading dose followed by 75 mg/day and rivaroxaban 15 mg/day. He was also put on esomeprazole 40 mg/day for gastric protection. A low residual platelet reactivity was documented by vasodilator-stimulated phosphoprotein (VASP) (11%) the next day. The initial plan was to administer triple therapy for six months and then to stop clopidogrel, while aspirin should have been continued for one year and lifelong OAC. One month after the procedure, the patient developed GI bleeding. The minimal haemoglobin level was 6.5 g/dL and he was transfused with two red blood cell concentrates. Rivaroxaban was put on hold while DAPT continued. Gastroscopy showed erythematous gastritis without an active source of bleeding. Colonoscopy showed extensive diverticulosis of the colon thought to be the source of the bleeding, though also at that level no active bleeding source was identified. Rivaroxaban was restarted at the same dosing. Three months after PCI, the patient developed

haematuria. Aspirin was stopped and the patient underwent outpatient cystoscopy. During the filling of the bladder for the cystoscopy, the patient had a (likely vasovagal) syncope, fell, and suffered a traumatic injury of the head. Emergent CT scan showed bilateral post-traumatic subdural and subarachnoid haematomas as well as right temporal intracerebral bleeding (Figure 21). All antithrombotic treatment was stopped, while for the neurosurgeons there was no indication to intervene. The patient never recovered and, in addition, developed pneumonia. He died 12 days after admission.

Comments from the Task Force

This case with a fatal outcome illustrates the challenges of weighting ischaemic and bleeding risks. The first risk assessment in this case was with respect to PCI vs. CABG. In the Heart Team discussion, the increased bleeding risk associated with triple therapy was clearly part of the equation. Nevertheless, for the reasons mentioned earlier, PCI was still considered the most favourable option. Multiple questions related to this come to mind.

Was the intended duration of triple therapy (aspirin, clopidogrel, anticoagulation) of six months appropriate? Yes

First of all, we have to admit that a patient like the one described (NSTEMI, multiple stents including LM stent) would have never been enrolled in any of the (small) randomized controlled trials that have addressed this question. The 2017 ESC DAPT Focused Update states that, although as a general rule in patients undergoing PCI triple therapy should be considered for one month, in patients with high ischaemic risk triple therapy for longer than one month and up to six months should be considered (see chapter 7.2 in full text document).

Was the measurement of P2Y₁₂-mediated residual platelet function after loading of clopidogrel indicated/necessary? No

Although the treating physicians likely feared a suboptimal response to clopidogrel in this diabetic patient with ACS and multiple stents, including in the LM trunk, no study has ever demonstrated that tailoring clopidogrel dose to residual platelet activity improves patient outcomes. Therefore, the 2017 ESC DAPT Focused Update does not recommend assessment of platelet reactivity under DAPT (chapter 3.7 in full text document).

Was the choice of a non-vitamin K antagonist oral anticoagulant (NOAC) as a component of triple therapy appropriate? Yes

Although current recommendations state that both NOAC and VKAs can be used as components of triple therapy, adequately powered randomized controlled trials are ongoing; the limitations of the only trial available (Rivaroxaban and a dose-adjusted oral vitamin K antagonist treatment strategy in subjects with atrial fibrillation who undergo percutaneous coronary intervention [PIONEER-AF-PCI])⁴⁰ are described below.

Was the dose of rivaroxaban (15 mg/day) appropriate?**Not sure**

This dose has compared favourably vs. warfarin in terms of bleeding in patients exposed to triple therapy (unlike rivaroxaban) in the PIONEER-AF-PCI trial.⁴⁰ However, the study was not powered to address ischaemic endpoints, notably ischaemic strokes. Therefore, it is not known whether the 15 mg/day dose of rivaroxaban with or without associated antiplatelet agents confers adequate protection against stroke, as it has never been tested in an adequately powered trial in this context. Accordingly, the 2017 ESC DAPT Focused Update gives only a weak recommendation (IIb) for this dosing, stating that when rivaroxaban is used in combination with aspirin and/or clopidogrel, rivaroxaban 15 mg/day may be used instead of rivaroxaban 20 mg/day. In the case of this patient the 15 mg dose was a "tough call" because he was also at very high risk of embolic stroke (two previous strokes and a CHA₂DS₂-VASc score of 7).

Was the choice of the Biofreedom stent appropriate? Yes

The Biofreedom stent is the only stent currently on the market that has been adequately tested in a population of patients at high bleeding risk. In the Prospective randomized comparison of the BioFreedom biolimus A9 drug-coated stent versus the gazelle bare-metal stent in patients at high bleeding risk (LEADERS-FREE) study, among 2466 patients at high bleeding risk (27% of them with ACS) receiving DAPT with aspirin and clopidogrel for four weeks followed by aspirin alone, randomization to the drug-coated stent Biofreedom, as compared with its BMS version, was associated at one year not only with a reduction in clinically driven target lesion revascularization (as expected) but also a reduction in the primary safety endpoint of

cardiac death, MI, or ST.¹⁴ In particular, no difference in ST was observed. Having said that, the 2017 ESC DAPT Focused Update recommends second generation DES over BMS also in patients at high bleeding risk without differentiating one device from the other.

Was the choice of a transfemoral approach for the PCI according to current recommendations? No

Current recommendations clearly favour routinely the transradial approach over the transfemoral one for PCI as this is associated not only with a reduction in major bleeding but also in mortality.⁴¹ However, in this case the operator chose the transfemoral access because of a larger bore catheter (7 French) for the rotablation of the LAD and the treatment of the LM trunk. In addition, an additional contralateral femoral approach was used for intra-aortic balloon counterpulsation. Finally, the operator obtained also femoral venous access so if needed central venous access was available of vasopressor administration and, in case of major haemodynamic compromise or complication using existing femoral arterial and venous accesses the patient could be rapidly assisted with one extracorporeal membrane oxygenation (ECMO).

Was the fatal event related to the antithrombotic treatment? Yes, though indirectly

On the one hand, the potent antithrombotic regimen favoured the extensive intracranial bleeding following the trauma. On the other hand, the trauma occurred accidentally as the patient was being investigated for a macro-haematuria, the latter also favoured by the triple therapy.

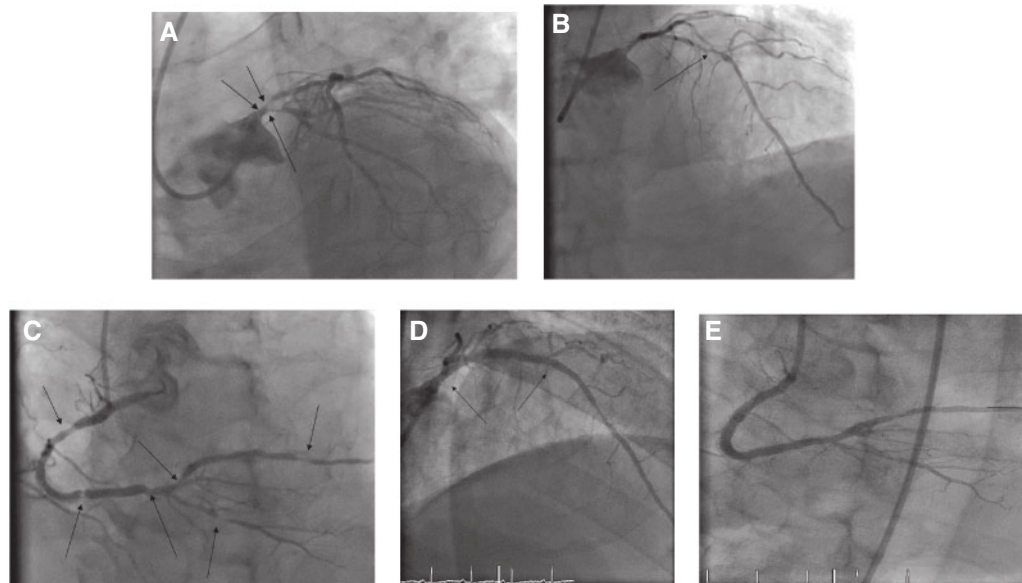


Figure 20 Coronary angiography showing a 70 - 90% distal left main (LM) bifurcation lesion (A), a 70 - 90% severely calcified stenosis of the proximal left anterior descending artery (LAD) (B), and multiple lesions at the level of the right coronary artery (RCA) as well of the large posterior lateral artery (PLA) and of the small posterior descending artery (PDA) (C). Intervention with stent implantation in the LM and proximal LAD (D) and RCA (E).

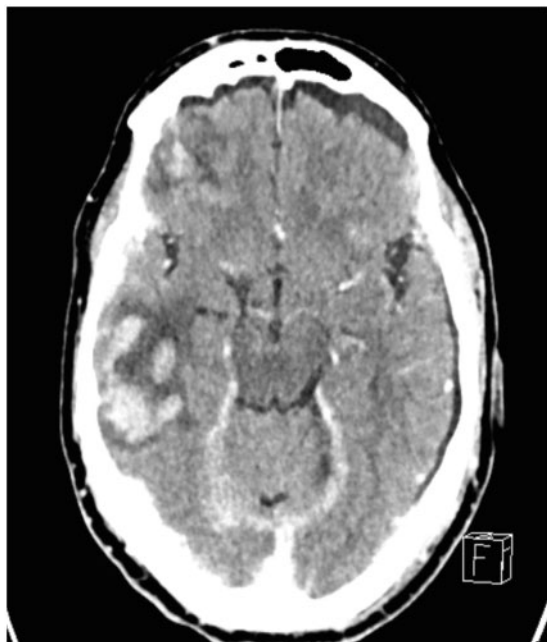


Figure 21 Emergent computed tomography scan showing bilateral post traumatic subdural and subarachnoid haematomas and right temporal intracerebral bleeding.

Case #14: Periprocedural myocardial infarction in elective percutaneous coronary intervention: when stenting goes wrong, dual antiplatelet therapy should be strong

A 55-year-old man with a history of hypertension and active smoking was admitted for an elective coronary angiogram because of stable angina with a positive stress test. He was overweight (body mass index = 32 kg/m^2) and sedentary. Low-density lipoprotein cholesterol was 210 mg/dL and glycated haemoglobin 7.6% , showing undiagnosed diabetes. He received a loading dose of aspirin the day before the angiogram and 600 mg of clopidogrel during the procedure. The

coronary angiogram revealed a significant stenosis of the distal LM coronary artery and proximal circumflex coronary artery (Figure 22A). Ad hoc PCI with a DES implanted from the LM to the circumflex artery was performed with the symptomatic loss of a small obtuse marginal branch (Figure 22B), requiring the use of IV pain relief drugs. Periprocedural MI (type 4a) was confirmed by a rise of high sensitive cardiac troponin up to 1450 ng/L ($N < 14 \text{ ng/L}$). He was discharged the day after on DAPT with clopidogrel and aspirin.

Ten days later, the patient was admitted for cardiogenic shock due to thrombosis of the LM stent (Figure 22C) and treated successfully. Clopidogrel was then switched to ticagrelor and the patient was discharged with DAPT for a year.

Comments from the Task Force

There are several points to be highlighted according to the recent DAPT Focused Update.

- i. In the case of complex anatomy in stable patients (even more so in patients with diabetes mellitus), a Heart Team discussion should always guide the decision-making (i.e. PCI vs. CABG). This may have allowed an oral P2Y₁₂ receptor to reach steady state before PCI was undertaken (see below). Specifically, *ad hoc* intervention for LM stenosis (as well as for complex multi-vessel disease) in stable patients is highly discouraged by guidelines since it prevents a proper Heart Team discussion and transparent patient counselling about the pros and cons of each revascularization technique.
- ii. Pretreatment with P2Y₁₂ receptor inhibitors in this elective PCI should also be discussed. The likelihood of coronary intervention was high in the present case. A strategy of P2Y₁₂ pretreatment prior to the diagnostic coronary angiogram may have been considered, although the evidence is not robust.⁴²
- iii. The third possible point of discussion is the use of crushed clopidogrel tablets. Speeding the onset of P2Y₁₂ inhibition may have avoided the thrombotic obstruction of the obtuse marginal branch. Delayed absorption of clopidogrel had most likely occurred in this patient given that he was laying on his back and the concomitant use of IV pain relief drugs.^{43,44}
- iv. Periprocedural MIs are frequent complications of complex PCI and are associated with increased mortality.⁴⁵ There is some evidence coming from subgroup analyses that more potent P2Y₁₂ inhibitors (i.e. ticagrelor or prasugrel) are better than clopidogrel even in the setting of high-risk elective PCI. This strategy of an off-label use of ticagrelor or prasugrel in elective PCI to avoid periprocedural MI is currently being tested. For the time being, ESC guidelines state that ticagrelor or prasugrel may be used in elective PCI only if there is a prior history of ST while on clopidogrel.

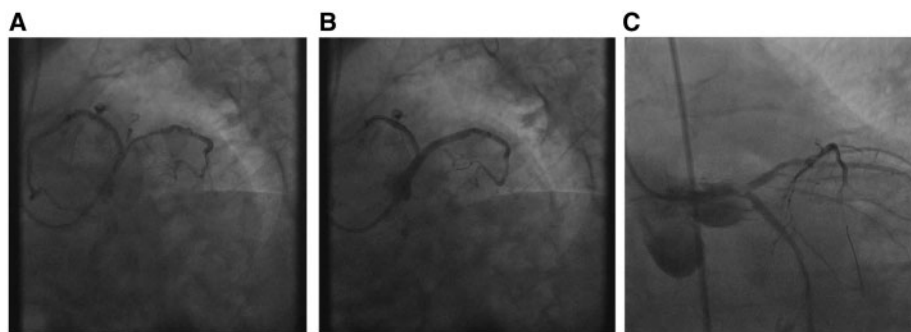


Figure 22 Coronary angiogram revealing a significant stenosis of the distal left main coronary artery and proximal circumflex coronary artery (A). The patient was treated with *ad hoc* percutaneous coronary intervention with a drug-eluting stent (B). Subacute stent thrombosis of the left main stent (C).

Case #15: Spontaneous coronary artery dissection in a young woman

A 44-year-old female presented to the emergency room with acute chest pain accompanied by vomiting and sweating which lasted for two hours and started after an argument within the family. She had a history of hypertriglyceridaemia and smoking (20 cigarettes per day); she had no family history of cardiovascular disease and was not on oral contraceptives. On admission, she was asymptomatic. An ECG performed in the emergency room showed a 1–2 mm ST-segment elevation in leads II, III and aVF as well as a 1–2 mm ST-segment depression in leads V₁, V₂, V₃. A repeat ECG at 10 minutes showed resolution of the ST-segment deviation in all leads, while a negative T-wave in the inferior leads persisted. The troponin I level was 0.12 ng/mL (ULN: 0.1 ng/mL). The patient was treated with aspirin, loading doses of 300 mg clopidogrel, and 1 mg/kg enoxaparin subcutaneously. On TTE there was the suspicion of posterior hypokinesia in the presence of normal global systolic function. Coronary angiography showed a left coronary artery with no evidence of atherosclerosis. Injection of the RCA showed a dissection involving the ostium and the proximal portion of the vessel in the presence of normal flow and no evidence of CAD. There was some evidence of thrombus formation at the distal end of the dissection and a subdivision of the posterolateral branch was occluded by distal embolization (Movie 1). Two DES were implanted at the level of the proximal and mid RCA. Balloon angioplasty was performed at the level of the subdivision of the posterolateral branch with a good angiographic result (Movie 2). The ECG post procedure was unchanged. Troponin I increased to a peak level of 14.96 ng/mL. The patient was treated with aspirin and beta-blockers, the clopidogrel was switched to ticagrelor (no loading dose), and she was discharged on day 8. The intended DAPT duration was one year.

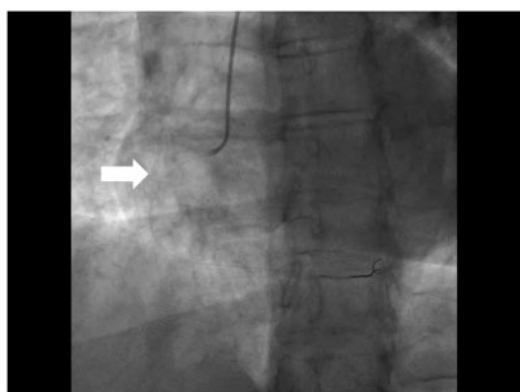
Comments from the Task Force

- This patient had spontaneous coronary artery dissection, a condition that affects women in over 90% of cases. As in the presented case, a

precipitating emotional or physical stress may be identified in the majority of patients. In a recent prospective series of 168 spontaneous coronary artery dissection patients who underwent imaging screening of renal, iliac, and cerebrovascular arteries performed with angiography or CT angiography/MR angiography, fibromuscular dysplasia was identified in 72% of the cases.⁴⁶ The young patient described here presented with transient inferior ST-segment elevation and reciprocal ST-segment depression in the anterior leads and, therefore, qualified for immediate coronary angiography and DAPT with aspirin and either ticagrelor or prasugrel, administered as a loading dose in the emergency department or before PCI.

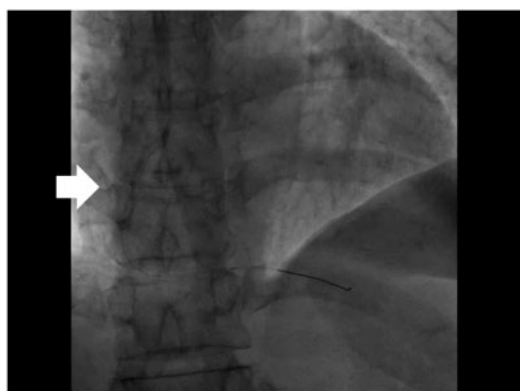
- The decision to proceed to revascularization in spontaneous coronary artery dissection patients is very challenging and based on limited data. Revascularization by PCI or CABG (the latter to be considered mainly in the case of LM trunk involvement) is indicated if the patient has ongoing ischaemia involving a major coronary territory or recurrent ACS episodes on maximal medical treatment. In the absence of ongoing ischaemia, and independently of how ugly the coronary artery looks on angiography, a conservative approach is favoured.
- In the case presented, the operators decided to treat the patient by PCI, with an excellent final result. However, a conservative strategy could have also been proposed, as the patient had no pain/ECG changes at the time of angiography, and had only the (embolic) occlusion of a side-branch of the posterolateral branch of the RCA while the flow in the remaining territory of the RCA was normal. In addition, the dissection started at the ostium and the true lumen could not be easily identified - both risk conditions for an abrupt occlusion during PCI. While intravascular imaging with ultrasound or OCT can elegantly confirm the diagnosis of coronary dissection and document the extension of the disease, invasive imaging should be considered only if the decision to proceed to revascularization has already been made, because any attempt to undertake intravascular imaging could trigger abrupt vessel closure. A recent series on 189 spontaneous coronary artery dissection patients described a failure rate of approximately 50% among patients who underwent PCI. The same degree of failure was also observed in the subgroup with normal coronary flow at baseline, while 13% of the latter required emergency CABG following PCI.⁴⁶

- With respect to DAPT, aspirin and ticagrelor (or prasugrel) for one year followed by aspirin alone seems reasonable following DES implantation for the treatment of ACS, even if not caused by CAD. According to the 2017 ESC DAPT Focused Update, switching from clopidogrel to ticagrelor should imply the administration of a loading dose of 180 mg ticagrelor. With respect to spontaneous coronary artery dissection patients treated conservatively, there is no sufficient evidence to establish a formal recommendation on antiplatelet management. One possible approach is to administer aspirin for at least 12 months and a P2Y₁₂ inhibitor (in most series the administered agent was clopidogrel) for one to 12 months after the index event.⁴⁶



White arrow pointing to the dissection of the proximal-mid RCA

Movie 1 Coronary angiography of the right coronary artery revealing a spontaneous dissection throughout the proximal and mid parts with no evidence of atherosclerosis. The movie file can be found here: <https://academic.oup.com/eurheartj/article-lookup/doi/10.1093/eurheartj/ehx503#supplementary-data>.



White arrow pointing to the dissection RCA stents

Movie 2 Stenting of the proximal and mid right coronary artery with two drug-eluting stents. The movie file can be found here: <https://academic.oup.com/eurheartj/article-lookup/doi/10.1093/eurheartj/ehx503#supplementary-data>.

Case #16: Platelet reactivity testing after percutaneous coronary intervention: caveat emptor

A 65-year-old Chinese male patient with previous stent implantation in the mid LAD artery – treatment for an ACS six weeks earlier – presented with unstable angina pectoris. He was on aspirin and clopidogrel. Coronary angiography revealed a patent LAD stent but evidence of a filling defect inside the stent suspicious for ST (*Movie 3*). Intravascular ultrasound imaging showed stent underexpansion. The patient underwent repeat percutaneous intervention with implantation of a new generation DES in the previously treated segment with a good immediate result (*Movie 4*). Clopidogrel was switched to ticagrelor 90 mg twice daily. Platelet function testing two weeks later showed good platelet inhibition and subsequent follow-up testing on half and then quarter dose ticagrelor dosing showed stable platelet inhibition. Five months later the patient re-presented with unstable angina and a CT coronary angiogram suggested repeat stent occlusion due to restenosis (*Figure 23*). This was confirmed at coronary angiography and OCT imaging and treated with implantation of a further new generation DES (*Figure 24, Movies 5 and 6*).

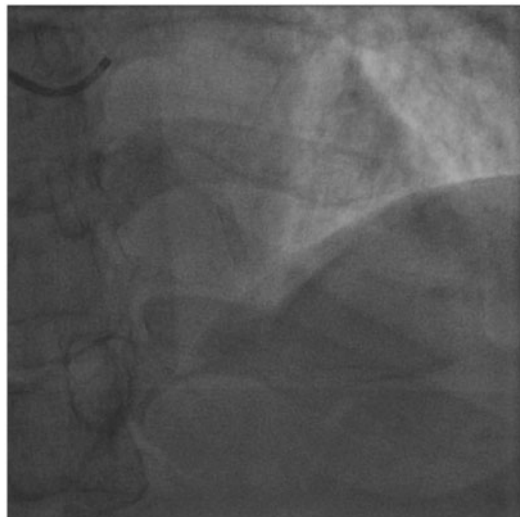Comments from the Task Force

There are a number of excellent discussion points arising from this case.

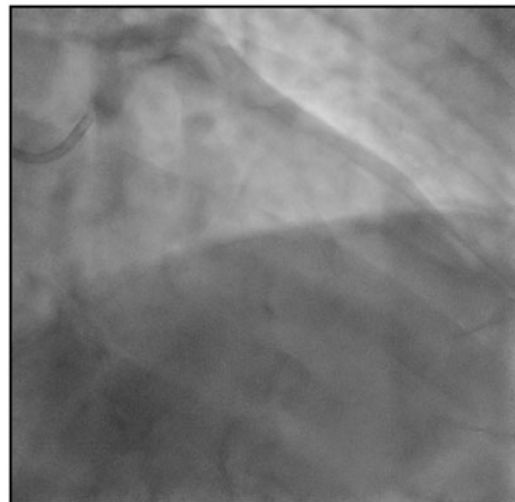
- First, the initial presentation is an ST due to stent underexpansion, a well-recognized risk factor.^{47–49} In this case, the patient had been discharged on aspirin and clopidogrel despite stenting in the setting of ACS. It might be speculated that this event may have been prevented by guideline-recommended combination therapy of aspirin, prasugrel or ticagrelor at the time of the first procedure (see chapter 3.6 in full text document).
- Second, the patient subsequently underwent platelet function testing on a number of occasions during follow-up. Indeed, on the basis of this, the intensity of antiplatelet therapy was de-escalated and the dosage of ticagrelor was successively reduced down to a quarter of the standard dose. Such an approach is not routinely recommended (see chapter 3.7 in full text document). Indeed, although it has long been known that platelet function testing can identify patients who are at a higher risk of ST,⁵⁰ randomized clinical trials have failed to show clinical benefit with management strategies based on therapy tailored according to the results of platelet function testing.^{9–12} Moreover, although a single recent randomized trial reported that a strategy of de-escalation of antiplatelet therapy intensity (from a more potent ADP-receptor antagonist to clopidogrel a number of weeks after stenting) may be reasonable in selected patients,⁵¹ convincing evidence demonstrating the validity of this approach is lacking and this strategy cannot be recommended at present. Third, clinically important differences in terms of the optimal dosage in patients with Asian ethnicity as compared with Caucasian ethnicity must be considered and some randomized trial data exist to support dose reduction of ADP-receptor antagonists in these patients.⁵² However, results from PLATO are indeed consistent across geographic regions, including Asia. Nevertheless, large-scale randomized trial data are lacking and this issue should be the subject of further study.

- A final comment focuses on the implications of three stent layers to successfully treat this mid LAD lesion. While the evidence is clearly not conclusive in this regard, observational data suggest that no attempt should be made to interrupt DAPT treatment in those patients even remotely from the intervention. In addition, the need

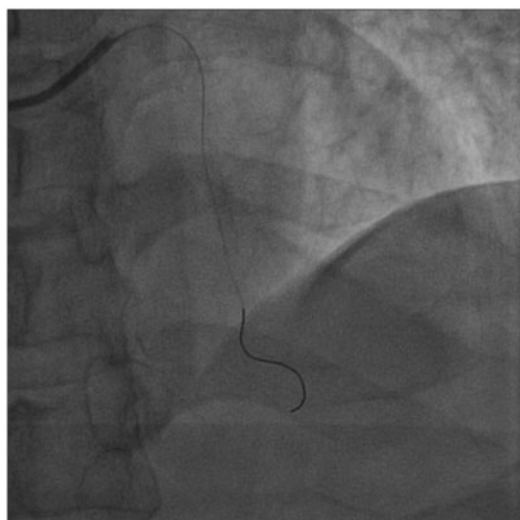
to sequentially stent one coronary lesion three times to achieve proper revascularization should always prompt considerations in favour of switching from percutaneous to surgical revascularization in order to obtain long lasting vessel patency, especially if the LAD is involved.



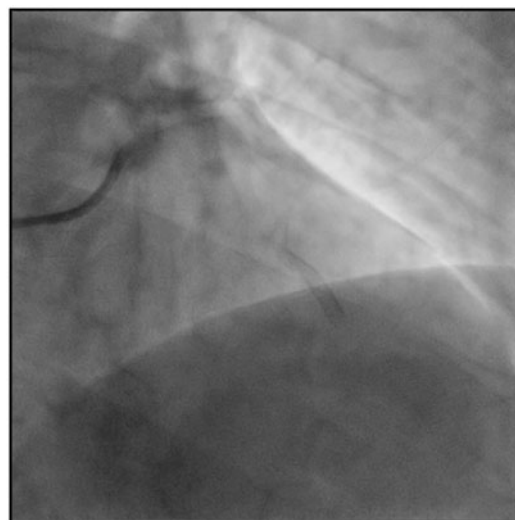Movie 3 Coronary angiography reveals partial filling defect inside the stent suspicious for stent thrombosis. The movie file can be found here: <https://academic.oup.com/eurheartj/article-lookup/doi/10.1093/eurheartj/ehx503#supplementary-data>.



Movie 5 Another coronary angiography showing critical stenosis of the in-stent segment. The movie file can be found here: <https://academic.oup.com/eurheartj/article-lookup/doi/10.1093/eurheartj/ehx503#supplementary-data>.



Movie 4 Percutaneous intervention with implantation of a new generation drug-eluting stent in the previously treated segment. The movie file can be found here: <https://academic.oup.com/eurheartj/article-lookup/doi/10.1093/eurheartj/ehx503#supplementary-data>.



Movie 6 Further intervention with implantation of a drug-eluting stent in the previously treated segment. The movie file can be found here: <https://academic.oup.com/eurheartj/article-lookup/doi/10.1093/eurheartj/ehx503#supplementary-data>.

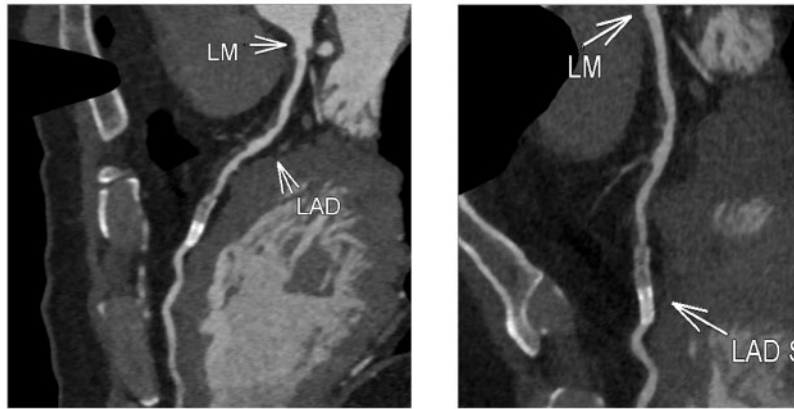


Figure 23 Computed tomography coronary angiogram suggests recurrent in-stent restenosis. LAD = left anterior descending; LM = left main.

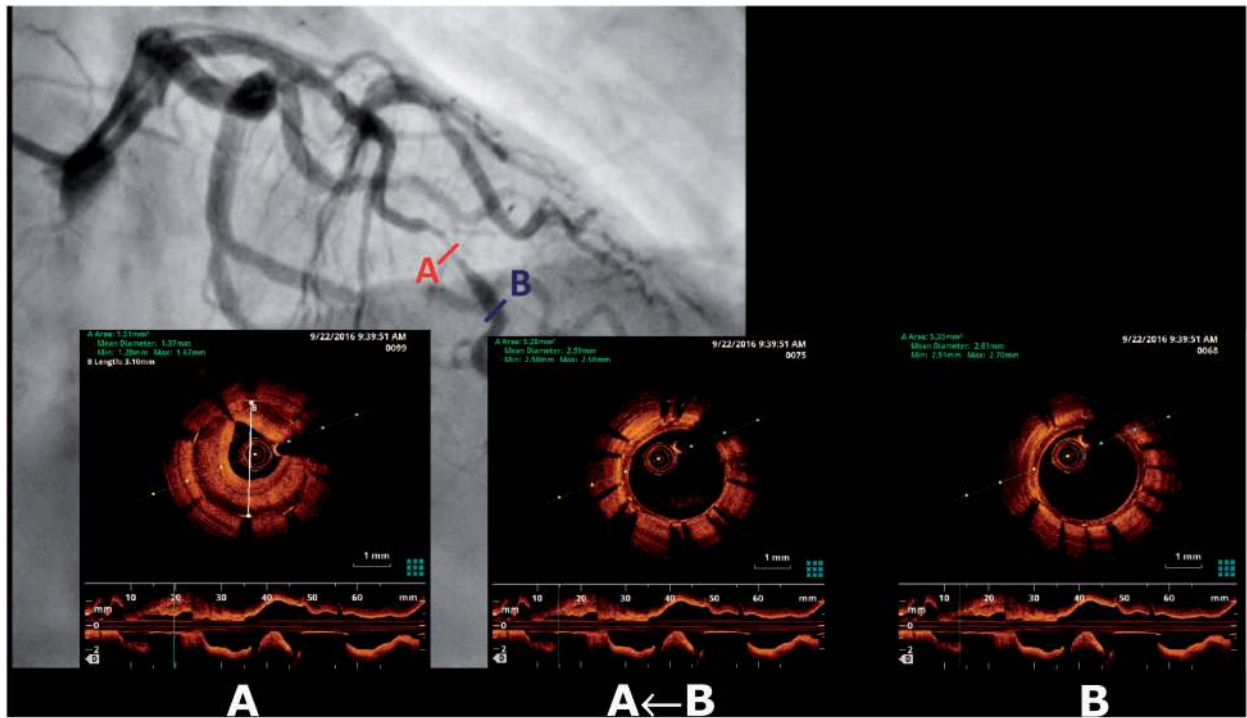


Figure 24 Optical coherence tomography of the in-stent segment.

Case #17: Antiplatelet therapy after bioresorbable scaffold implantation – when is it safe to interrupt?

A 44-year-old female patient presented with an acute STEMI. Emergency coronary angiography showed a complete occlusion of the mid LAD (Figure 25A). Flow was restored with thrombus aspiration, intracoronary nitrate administration and balloon angioplasty. Two everolimus-eluting bioresorbable scaffolds (Absorb, Abbott Vascular) were implanted in overlapping fashion (3.0 × 18 mm and 2.5 × 28 mm) in the mid LAD lesion and a third scaffold (2.5 × 18 mm) was implanted in the distal LAD. The final angiographic result was good (Figure 25B). The patient was discharged on aspirin and ticagrelor. Seven months later the patient was re-admitted with subacute genital tract bleeding requiring transfusion of 3 units of blood in the preceding weeks and persistent symptomatic anaemia (haemoglobin level was 7.9 g/dL). With a view to assessing the risk of discontinuation of DAPT, coronary angiography and OCT imaging of the LAD was done. This revealed a good result in the stented area with good apposition and coverage of the implanted scaffolds (Figure 26). Ticagrelor was discontinued and the patient was discharged on aspirin monotherapy.

Comments from the Task Force

- The optimal duration and intensity of DAPT after implantation of a bioresorbable stent (BRS) has not been well studied. The only BRS that has approval for use and for which there are published randomized clinical trial data is the Absorb BRS, which was used in this case. Randomized clinical trials with this scaffold show that at follow-up of nine to 12 months, the risk of ST is approximately two-fold higher with BRS as compared with conventional newer generation DES.⁵³ Most of this risk occurs early, within the first month after implantation, and may be related to suboptimal deployment of the scaffold during the implantation procedure. Moreover, a number of trial reports with longer-term follow-up

suggest some evidence of a second period of risk between one and three years after implantation,⁵⁴ and a recent clinical trial including patients treated in routine practice showed an overall three- to four-fold increase in ST with BRS at a median follow-up of just over 700 days.⁵⁵ The reasons for this late risk are unclear though it may be related to the dismantling of the scaffold during bioresorption.⁵⁶ One recent report suggested an increased risk of scaffold thrombosis in patients who discontinued DAPT before 18 months.⁵⁷

- Against this background, and faced with a significant bleeding event at seven months after stenting, the treating physician in this case has a difficult choice to make. Ordinarily, 12 months of DAPT would be recommended based on the index presentation with STEMI (class I recommendation, level of evidence A) (see chapter 4.2 in full text document). However, in view of concerns regarding late adverse events with BRS, many physicians would consider prolongation of DAPT for two to three years (with the intention to have high platelet inhibition during the period of scaffold resorption). Indeed, although evidence in this area is lacking, the Task Force recommends prolongation of DAPT beyond 12 months in these patients (class IIa recommendation, level of evidence C) (see chapter 4 in full text document). The decision of the authors to schedule angiography and OCT imaging in order to assist in decision-making regarding DAPT can be understood but cannot be routinely recommended. There are small but defined risks associated with repeat angiography and invasive imaging. In addition, there is no evidence to support the discontinuation of DAPT based on, say, a certain degree of strut coverage or apposition.⁵⁸ Moreover, not all covered struts are covered with mature, thrombo-resistant neointima.⁵⁹ Finally, specifically in the case of BRS, features conferring increased risk of late adverse events are not well characterized. In particular, the rate of patients with favourable imaging characteristics at interval imaging is not known. Nevertheless, in this case, regardless of whether or not surveillance imaging was done, discontinuation of the ADP receptor antagonist and continuation of aspirin treatment seems reasonable. Moreover, it should always be borne in mind that decision-making regarding DAPT is a dynamic process and should be re-visited after clinical evaluation of the patient during further follow-up.

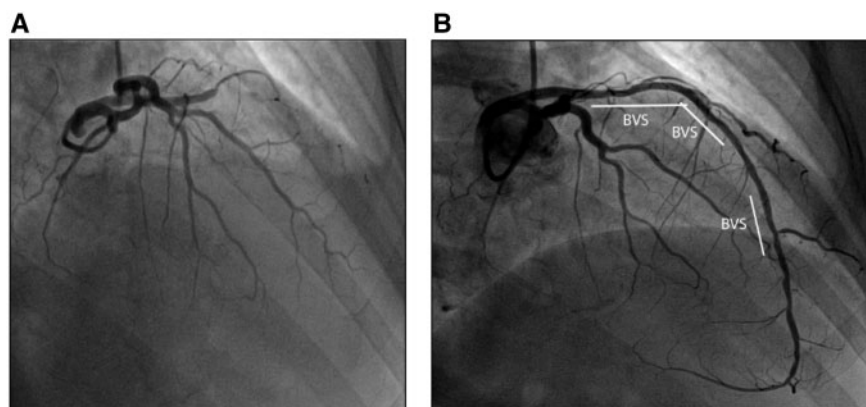


Figure 25 Emergency coronary angiography showing a complete occlusion of the mid left anterior descending coronary artery (A), which was treated with implantation of three bioresorbable vascular scaffolds (BVS) with good angiographic result (B).

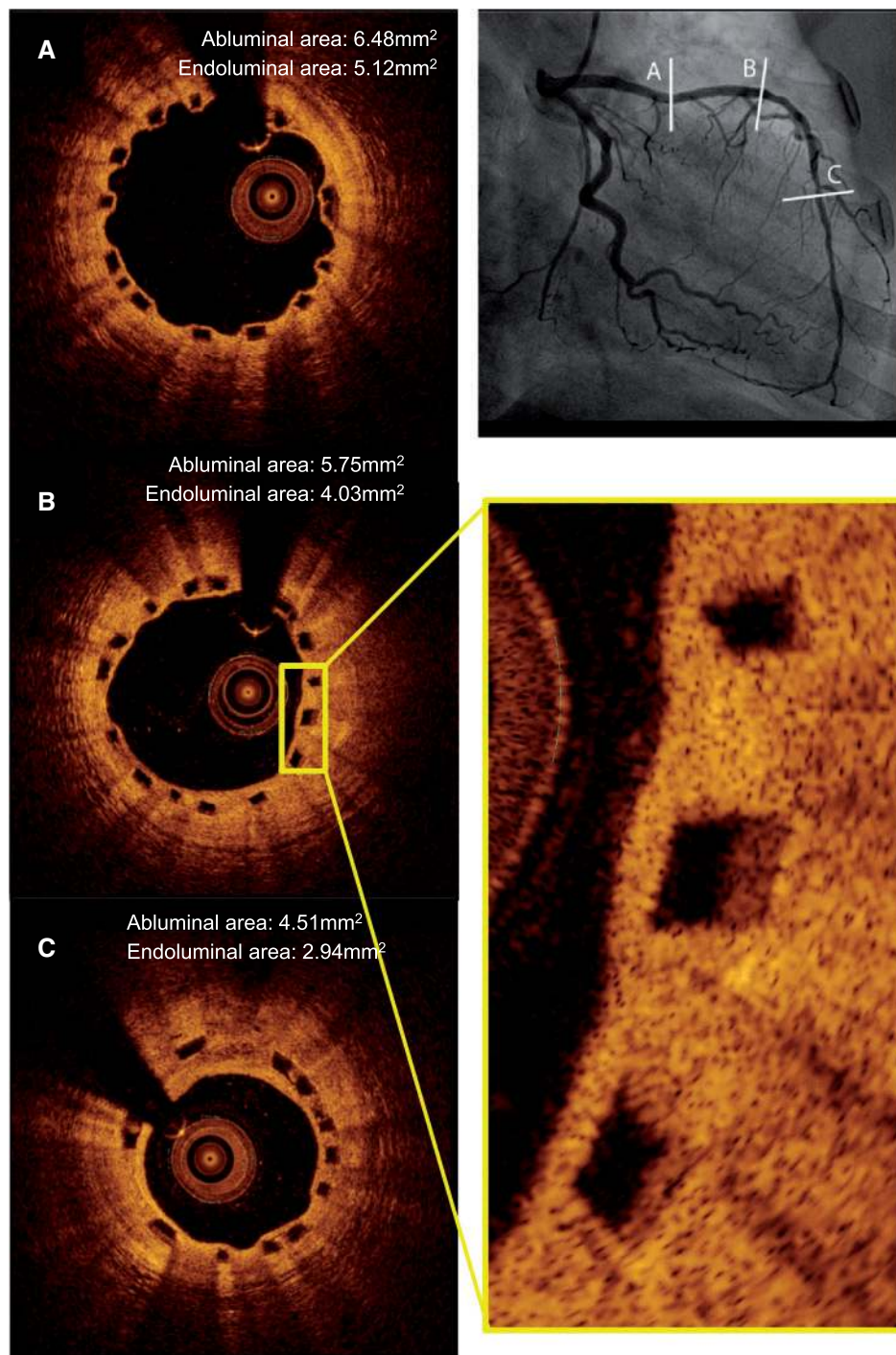


Figure 26 Optical coherence tomography at follow-up showing good coverage of the scaffold struts.

Case #18: Management of dual antiplatelet therapy in a patient with a femoral pseudoaneurysm following percutaneous coronary intervention

A 72-year-old patient presented with unstable angina and an ECG revealed significant ST-segment and T-wave abnormalities in the anterior precordial leads. Coronary angiography revealed a subtotal stenosis of the proximal LAD (Figure 27A). The patient was treated with implantation of a BMS (3.0 × 20 mm, PRO-Kinetic Energy, Biotronik) with a good immediate result (Figure 27B). The post-procedural course was complicated by pseudoaneurysm formation at the site of the right femoral arterial puncture (Figure 28). On day 10, the patient underwent operative repair of the pseudoaneurysm and clopidogrel therapy was interrupted 24 hours in advance of the procedure. A number of hours after the procedure, the patient developed anterior STEMI. Repeat catheterization revealed thrombotic stent occlusion (Figure 29A), which was successfully managed with balloon angioplasty (Figure 29B).

Comments from the Task Force

- Early ST remains a well-recognized complication of coronary stenting. Historically, prior to the advent of DAPT, rates of early ST of up to 10% were reported, despite aggressive anticoagulation with aspirin, heparin, VKAs and thrombolytic agents.^{60, 61} However, the demonstration that DAPT with a P2Y₁₂ ADP-receptor antagonist added to aspirin significantly reduced both ST and bleeding was perhaps the critical development that facilitated widespread adoption of PCI.^{62, 63} Contemporary registries show rates of early ST of 0.5% or less.⁶⁴ Risk factors for early ST include suboptimal procedural result (e.g. underexpansion), inadequate response to antiplatelet therapy, presentation with ACS,

complexity of lesion morphology, reduced LV function, and presence of diabetes mellitus.⁴⁸

The presented case contains a number of instructive discussion points.

- First, increasing adoption of transradial PCI has demonstrated an important role in improving patient outcomes. Indeed, recent randomized clinical trial data support improved outcomes in patients treated with transradial PCI compared with transfemoral PCI and this benefit may be more pronounced in patients presenting with ACS.⁴¹ Successful transradial access in this patient would have prevented this complication. Nevertheless, transfemoral access remains necessary in certain cases and is still widely performed as a routine approach in many countries.
- Second, femoral pseudoaneurysm formation is not infrequently encountered after transfemoral access.⁶⁵ Optimal management depends on early diagnosis and prompt treatment. A variety of strategies may be adopted, ranging from repeat manual compression (better if under ultrasound control) to local thrombin injection, to covered stent implantation, to surgical repair.⁶⁵ Surgical repair may be favoured based on local anatomy or lack of endovascular expertise. If early surgical repair is chosen, DAPT should be continued. Regardless of the stent implanted, the risk of ST with interruption of DAPT in the first 30 days after PCI is considerable.¹⁵ Moreover, surgical intervention promotes a procoagulant response and further increases the risk of ST. Interestingly there are no convincing data to suggest that risk of early ST is lower with BMS in comparison with current generation DES. In fact, the opposite may be the case,⁶⁶ and some experimental work suggests that polymer-coated stents may be less thrombogenic than uncoated stents in the early phase.⁶⁷ For this reason, DES are recommended for use in all clinical situations and the planned duration of DAPT should be tailored according to the patient and lesion characteristics, not the type of stent implanted (see chapter 2.2 in full text document).
- Finally, it is not known whether ST would have occurred had the patient been treated with a more potent P2Y₁₂-receptor antagonist – the preferred therapy in patients with stent implantation in the setting of ACS (see chapter 3.6 in full text document).

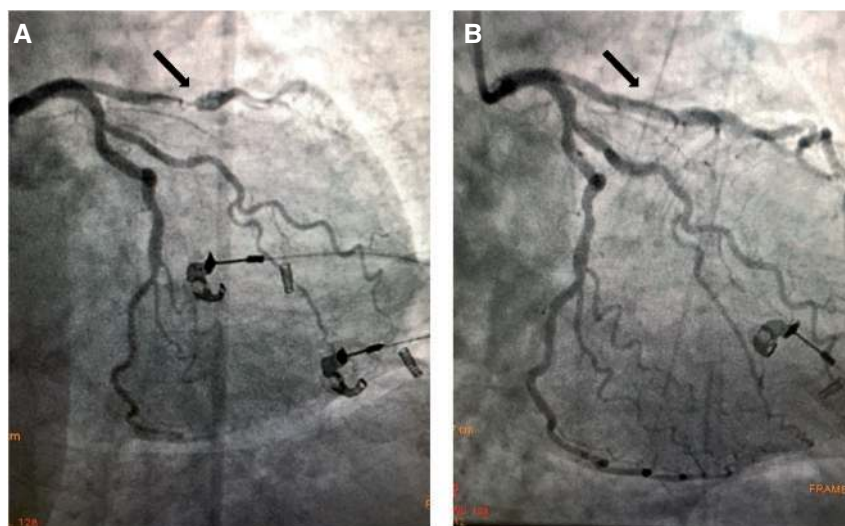


Figure 27 Coronary angiography revealing a subtotal stenosis of the proximal left anterior descending coronary artery (A) treated with implantation of a bare-metal stent with a good acute result (B).

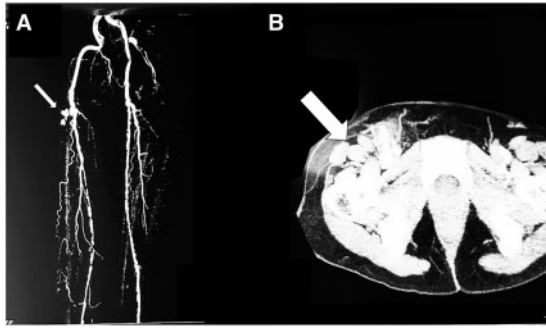


Figure 28 Computed tomography scan showing right femoral artery pseudo-aneurysm.

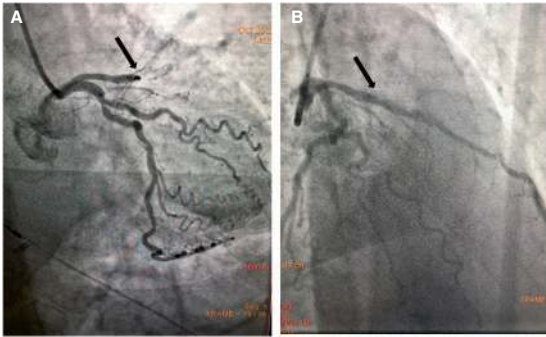


Figure 29 Repeat catheterization after surgery revealing thrombotic stent occlusion (A), which was successfully managed with balloon angioplasty (B).

References

- Halvorsen S, Storey RF, Rocca B, Sibbing D, Ten Berg J, Grove EL, Weiss TW, Collet JP, Andreotti F, Gulba DC, Lip GYH, Husted S, Vilahur G, Morais J, Verheugt FWA, Lanas A, Al-Shahi Salman R, Steg PG, Huber K, ESC Working Group on Thrombosis. Management of antithrombotic therapy after bleeding in patients with coronary artery disease and/or atrial fibrillation: expert consensus paper of the European Society of Cardiology Working Group on Thrombosis. *Eur Heart J* 2017;**38**(19):1455–1462.
- Gralnek IM, Dumonceau JM, Kuipers EJ, Lanas A, Sanders DS, Kurien M, Rotondano G, Hucl T, Dinis-Ribeiro M, Marmo R, Racz I, Arezzo A, Hoffmann RT, Lesur G, de Franchis R, Aabakken L, Veitch A, Radaelli F, Salgueiro P, Cardoso R, Maia L, Zullo A, Cipolletta L, Hassan C. Diagnosis and management of nonvariceal upper gastrointestinal hemorrhage: European Society of Gastrointestinal Endoscopy (ESGE) Guideline. *Endoscopy* 2015;**47**(10):a1–46.
- Silvain J, Abtan J, Kerneis M, Martin R, Finzi J, Vignalou JB, Barthelemy O, O'Connor SA, Luyt CE, Brechot N, Mercadier A, Brugier D, Galier S, Collet JP, Chastre J, Montalescot G. Impact of red blood cell transfusion on platelet aggregation and inflammatory response in anemic coronary and noncoronary patients: the TRANSFUSION-2 study (impact of transfusion of red blood cell on platelet activation and aggregation studied with flow cytometry use and light transmission aggregometry). *J Am Coll Cardiol* 2014;**63**(13):1289–1296.
- Sherwood MW, Wang Y, Curtis JP, Peterson ED, Rao SV. Patterns and outcomes of red blood cell transfusion in patients undergoing percutaneous coronary intervention. *JAMA* 2014;**311**(8):836–843.
- Roffi M, Patrono C, Collet JP, Mueller C, Valgimigli M, Andreotti F, Bax JJ, Borger MA, Brotons C, Chew DP, Gencer B, Hasenfuss G, Kjeldsen K, Lancellotti P, Landmesser U, Mehilli J, Mukherjee D, Storey RF, Windecker S, Baumgartner H, Gaemperli O, Achenbach S, Agewall S, Badimon L, Baigent C, Bueno H, Bugiardini R, Carerj S, Casselman F, Cuisset T, Erol C, Fitzsimons D, Halle M, Hamm C, Hildick-Smith D, Huber K, Iliodromitis E, James S, Lewis BS, Lip GY, Piepoli MF, Richter D, Rosemann T, Sechtem U, Steg PG, Vrints C, Luis Zamorano J. Management of Acute Coronary Syndromes in Patients Presenting without Persistent ST Elevation of the European Society of Cardiology. 2015 ESC Guidelines for the management of acute coronary syndromes in patients presenting without persistent ST-segment elevation: Task Force for the Management of Acute Coronary Syndromes in Patients Presenting without Persistent ST-Segment Elevation of the European Society of Cardiology (ESC). *Eur Heart J* 2016;**37**(3):267–315.
- Hulot JS, Collet JP, Silvain J, Pena A, Bellemain-Appaix A, Barthelemy O, Cayla G, Beygui F, Montalescot G. Cardiovascular risk in clopidogrel-treated patients according to cytochrome P450 2C19*2 loss-of-function allele or proton pump inhibitor coadministration: a systematic meta-analysis. *J Am Coll Cardiol* 2010;**56**(2):134–143.
- Stone GW, Witzenbichler B, Weisz G, Rinaldi MJ, Neumann FJ, Metzger DC, Henry TD, Cox DA, Duffy PL, Mazzaferri E, Gurbel PA, Xu K, Parise H, Kirtane AJ, Brodie BR, Mehran R, Stuckey TD, ADAPT-DES Investigators. Platelet reactivity and clinical outcomes after coronary artery implantation of drug-eluting stents (ADAPT-DES): a prospective multicentre registry study. *Lancet* 2013;**382**(9892):614–623.
- Authors/Task Force members, Windecker S, Kolh P, Alfonso F, Collet JP, Cremer J, Falk V, Filippatos G, Hamm C, Head SJ, Juni P, Kappetein AP, Kastrati A, Knuuti J, Landmesser U, Laufer G, Neumann FJ, Richter DJ, Schauerte P, Sousa Uva M, Stefanini GG, Taggart DP, Torracca L, Valgimigli M, Wijns W, Witkowski A. 2014 ESC/EACTS Guidelines on myocardial revascularization: The Task Force on Myocardial Revascularization of the European Society of Cardiology (ESC) and the European Association for Cardio-Thoracic Surgery (EACTS) Developed with the special contribution of the European Association of Percutaneous Cardiovascular Interventions (EAPCI). *Eur Heart J* 2014;**35**(37):2541–2619.
- Collet JP, Cuisset T, Range G, Cayla G, Elhadad S, Pouillot C, Henry P, Motreff P, Carrie D, Boueri Z, Belle L, Van Belle E, Rousseau H, Aubry P, Monsegu J, Sabouret P, O'Connor SA, Abtan J, Kerneis M, Saint-Etienne C, Barthelemy O, Beygui F, Silvain J, Vicaut E, Montalescot G, ARCTIC Investigators. Bedside monitoring to adjust antiplatelet therapy for coronary stenting. *N Engl J Med* 2012;**367**(22):2100–2109.
- Cayla G, Cuisset T, Silvain J, Leclercq F, Manzo-Silberman S, Saint-Etienne C, Delarche N, Bellemain-Appaix A, Range G, El Mahmoud R, Carrie D, Belle L, Souteyrand G, Aubry P, Sabouret P, du Fretay XH, Beygui F, Bonnet JL, Lattuca B, Pouillot C, Varenne O, Boueri Z, Van Belle E, Henry P, Motreff P, Elhadad S, Salem JE, Abtan J, Rousseau H, Collet JP, Vicaut E, Montalescot G, ANTARCTIC Investigators. Platelet function monitoring to adjust antiplatelet therapy in elderly patients stented for an acute coronary syndrome (ANTARCTIC): an open-label, blinded-endpoint, randomised controlled superiority trial. *Lancet* 2016;**388**(10055):2015–2022.
- Price MJ, Berger PB, Teirstein PS, Tanguay JF, Angiolillo DJ, Spriggs D, Puri S, Robbins M, Garratt KN, Bertrand OF, Stillabower ME, Aragon JR, Kandzari DE, Stinis CT, Lee MS, Manoukian SV, Cannon CP, Schork NJ, Topol EJ, GRAVITAS Investigators. Standard- vs high-dose clopidogrel based on platelet function testing after percutaneous coronary intervention: the GRAVITAS randomized trial. *JAMA* 2011;**305**(11):1097–1105.
- Trenk D, Stone GW, Gawaz M, Kastrati A, Angiolillo DJ, Muller U, Richardt G, Jakubowski JA, Neumann FJ. A randomized trial of prasugrel versus clopidogrel in patients with high platelet reactivity on clopidogrel after elective percutaneous coronary intervention with implantation of drug-eluting stents: results of the TRIGGER-PCI (Testing Platelet Reactivity In Patients Undergoing Elective Stent Placement on Clopidogrel to Guide Alternative Therapy With Prasugrel) study. *J Am Coll Cardiol* 2012;**59**(24):2159–2164.
- Palmerini T, Stone GW. Optimal duration of dual antiplatelet therapy after drug-eluting stent implantation: conceptual evolution based on emerging evidence. *Eur Heart J* 2016;**37**(4):353–364.
- Urban P, Meredith IT, Abizaid A, Pocock SJ, Carrie D, Naber C, Lipiecki J, Richardt G, Iniguez A, Brunel P, Valdes-Chavarrri M, Garot P, Talwar S, Berland J, Abdellaoui M, Eberli F, Oldroyd K, Zambahari R, Gregson J, Greene S, Stoll HP, Morice MC, LEADERS FREE Investigators. Polymer-free drug-coated coronary stents in patients at high bleeding risk. *N Engl J Med* 2015;**373**(21):2038–2047.
- Mehran R, Baber U, Steg PG, Ariti C, Weisz G, Witzenbichler B, Henry TD, Kini AS, Stuckey T, Cohen DJ, Berger PB, Iakovou I, Dangas G, Waksman R,

- Antoniucci D, Sartori S, Krucoff MW, Hermiller JB, Shawl F, Gibson CM, Chieffo A, Alu M, Moliterno DJ, Colombo A, Pocock S. Cessation of dual antiplatelet treatment and cardiac events after percutaneous coronary intervention (PARIS): 2 year results from a prospective observational study. *Lancet* 2013;**382**(9906):1714–1722.
16. Valgimigli M, Patialiakas A, Thury A, McFadden E, Colangelo S, Campo G, Tebaldi M, Ungi I, Tondi S, Roffi M, Menozzi A, de Cesare N, Garbo R, Meliga E, Testa L, Gabriel HM, Airoldi F, Ferlini M, Liistro F, Dellavalle A, Vranckx P, Briguori C, ZEUS Investigators. Zotarolimus-eluting versus bare-metal stents in uncertain drug-eluting stent candidates. *J Am Coll Cardiol* 2015;**65**(8):805–815.
 17. Lamberts M, Gislason GH, Olesen JB, Kristensen SL, Schjerning Olsen AM, Mikkelsen A, Christensen CB, Lip GY, Kober L, Torp-Pedersen C, Hansen ML. Oral anticoagulation and antiplatelets in atrial fibrillation patients after myocardial infarction and coronary intervention. *J Am Coll Cardiol* 2013;**62**(11):981–989.
 18. Demaerschalk BM, Kleindorfer DO, Adeoye OM, Demchuk AM, Fugate JE, Grotta JC, Khalessi AA, Levy EI, Palesch YY, Prabhakaran S, Saposnik G, Saver JL, Smith EE, American Heart Association Stroke Council and Council on Epidemiology and Prevention. Scientific rationale for the inclusion and exclusion criteria for intravenous alteplase in acute ischemic stroke: a statement for health-care professionals from the American Heart Association/American Stroke Association. *Stroke* 2016;**47**(2):581–641.
 19. Wiviott SD, Braunwald E, McCabe CH, Montalescot G, Ruzyllo W, Gottlieb S, Neumann FJ, Ardissino D, De Servi S, Murphy SA, Riesmeyer J, Weerakkody G, Gibson CM, Antman EM, TRITON-TIMI 38 Investigators. Prasugrel versus clopidogrel in patients with acute coronary syndromes. *N Engl J Med* 2007;**357**(20):2001–2015.
 20. Wallentin L, Becker RC, Budaj A, Cannon CP, Emanuelsson H, Held C, Horrow J, Husted S, James S, Katus H, Mahaffey KW, Scirica BM, Skene A, Steg PG, Storey RF, Harrington RA, PLATO Investigators, Freij A, Thorsen M. Ticagrelor versus clopidogrel in patients with acute coronary syndromes. *N Engl J Med* 2009;**361**(11):1045–1057.
 21. Costa F, Tijssen JG, Ariotti S, Giatti S, Moscarella E, Guastaroba P, De Palma R, Ando G, Oretto G, Zijlstra F, Valgimigli M. Incremental value of the CRUSADE, ACUITY, and HAS-BLED risk scores for the prediction of hemorrhagic events after coronary stent implantation in patients undergoing long or short duration of dual antiplatelet therapy. *J Am Heart Assoc* 2015;**4**(12). pii: e002524. doi: 10.1161/JAHA.115.002524
 22. Costa F, van Klaveren D, James S, Heg D, Raber L, Feres F, Pilgrim T, Hong MK, Kim HS, Colombo A, Steg PG, Zanchin T, Palmerini T, Wallentin L, Bhatt DL, Stone GW, Windecker S, Steyerberg EW, Valgimigli M, PRECISE-DAPT Study Investigators. Derivation and validation of the predicting bleeding complications in patients undergoing stent implantation and subsequent dual antiplatelet therapy (PRECISE-DAPT) score: a pooled analysis of individual-patient datasets from clinical trials. *Lancet* 2017;**389**(10073):1025–1034.
 23. Stadler RR, Kindler R, Holzmann D, Soyka MB. The long-term fate of epistaxis patients with exposure to antithrombotic medication. *Eur Arch Otorhinolaryngol* 2016;**273**(9):2561–2567.
 24. van Diepen S, Fuster V, Verma S, Hamza TH, Siami FS, Goodman SG, Farkouh ME. Dual antiplatelet therapy versus aspirin monotherapy in diabetics with multi-vessel disease undergoing CABG: FREEDOM insights. *J Am Coll Cardiol* 2017;**69**(2):119–127.
 25. Verma S, Goodman SG, Mehta SR, Latter DA, Ruel M, Gupta M, Yanagawa B, Al-Omran M, Gupta N, Teoh H, Friedrich JO. Should dual antiplatelet therapy be used in patients following coronary artery bypass surgery? A meta-analysis of randomized controlled trials. *BMC Surg* 2015;**15**:112.
 26. Mancia G, Fagard R, Narkiewicz K, Redon J, Zanchetti A, Bohm M, Christiaens T, Cifkova R, De Backer G, Dominiczak A, Galderisi M, Grobbee DE, Jaarsma T, Kirchhof P, Kjeldsen SE, Laurent S, Manolis AJ, Nilsson PM, Ruilope LM, Schmieder RE, Sirnes PA, Sleight P, Viigimaa M, Waeber B, Zannad F, Redon J, Dominiczak A, Narkiewicz K, Nilsson PM, Burnier M, Viigimaa M, Ambrosioni E, Caulfield M, Coca A, Olesen MH, Schmieder RE, Tsioufis C, van de Borne P, Zamorano JL, Achenbach S, Baumgartner H, Bax JJ, Bueno H, Dean V, Deaton C, Erol C, Fagard R, Ferrari R, Hasdai D, Hoes AW, Kirchhof P, Knuuti J, Kolh P, Lancellotti P, Linhart A, Nihoyannopoulos P, Piepoli MF, Ponikowski P, Sirnes PA, Tamargo JL, Tenders M, Torbicki A, Wijns W, Windecker S, Clement DL, Coca A, Gillebert TC, Tenders M, Rosei EA, Ambrosioni E, Anker SD, Bauersachs J, Hitij JB, Caulfield M, De Buyzere M, De Geest S, Derumeaux GA, Erdine S, Farsang C, Funck-Brentano C, Gerc V, Germano G, Gielen S, Haller H, Hoes AW, Jordan J, Kahan T, Komajda M, Lovic D, Mahrholdt H, Olsen MH, Ostergren J, Parati G, Perk J, Polonia J, Popescu BA, Reiner Z, Ryden L, Sirenko Y, Stanton A, Struijker-Boudier H, Tsioufis C, van de Borne P, Vlachopoulos C, Volpe M, Wood DA. 2013 ESH/ESC guidelines for the management of arterial hypertension: the Task Force for the Management of Arterial Hypertension of the European Society of Hypertension (ESH) and of the European Society of Cardiology (ESC). *Eur Heart J* 2013;**34**(28):2159–2219.
 27. Olatoko F, Ologe FE, Alabi BS, Dunmade AD, Busari SS, Afolabi OA. Epistaxis. A five-year review. *Saudi Med J* 2006;**27**(7):1077–1079.
 28. Bangalore S, Kumar S, Fusaro M, Amoroso N, Attubato MJ, Feit F, Bhatt DL, Slater J. Short- and long-term outcomes with drug-eluting and bare-metal coronary stents: a mixed-treatment comparison analysis of 117 762 patient-years of follow-up from randomized trials. *Circulation* 2012;**125**(23):2873–2891.
 29. Kalesan B, Pilgrim T, Heinemann K, Raber L, Stefanini GG, Valgimigli M, da Costa BR, Mach F, Luscher TF, Meier B, Windecker S, Juni P. Comparison of drug-eluting stents with bare metal stents in patients with ST-segment elevation myocardial infarction. *Eur Heart J* 2012;**33**(8):977–987.
 30. Tebaldi M, Arcocci C, Campo G, Percoco G, Ferrari R, Valgimigli M, STRATEGY Investigators. The 5-year clinical outcomes after a randomized comparison of sirolimus-eluting versus bare-metal stent implantation in patients with ST-segment elevation myocardial infarction. *J Am Coll Cardiol* 2009;**54**(20):1900–1901.
 31. Valgimigli M, Campo G, Percoco G, Bolognese L, Vassanelli C, Colangelo S, de Cesare N, Rodriguez AE, Ferrario M, Moreno R, Piva T, Sheiban I, Pasquetto G, Prati F, Nazzaro MS, Parrinello G, Ferrari R, Multicentre Evaluation of Single High-Dose Bolus Tirofiban vs Abciximab With Sirolimus-Eluting Stent or Bare Metal Stent in Acute Myocardial Infarction Study (MULTISTRATEGY) Investigators. Comparison of angioplasty with infusion of tirofiban or abciximab and with implantation of sirolimus-eluting or uncoated stents for acute myocardial infarction: the MULTISTRATEGY randomized trial. *JAMA* 2008;**299**(15):1788–1799.
 32. Sabate M, Raber L, Heg D, Brugaletta S, Kelbaek H, Cequier A, Ostojic M, Iniguez A, Tuller D, Serra A, Baumbach A, von Birgelen C, Hernandez-Antolin R, Roffi M, Mainar V, Valgimigli M, Serruys PW, Juni P, Windecker S. Comparison of newer-generation drug-eluting with bare-metal stents in patients with acute ST-segment elevation myocardial infarction: a pooled analysis of the EXAMINATION (clinical Evaluation of the Xience-V stent in Acute Myocardial INfArction) and COMFORTABLE-AMI (Comparison of Biolimus Eluted From an Erodible Stent Coating With Bare Metal Stents in Acute ST-Elevation Myocardial Infarction) trials. *JACC Cardiovasc Interv* 2014;**7**(1):55–63.
 33. Valgimigli M, Sabate M, Kaiser C, Brugaletta S, de la Torre Hernandez JM, Galatus S, Cequier A, Eberli F, de Belder A, Serruys PW, Ferrante G. Effects of cobalt-chromium everolimus eluting stents or bare metal stent on fatal and non-fatal cardiovascular events: patient level meta-analysis. *BMJ* 2014;**349**:g6427.
 34. Valgimigli M. Shifting the focus to recurrences: so good we can afford it or too bad we cannot avoid it? *JACC Cardiovasc Interv* 2014;**7**(10):1114–1116.
 35. Armstrong EJ, Maddox TM, Carey EP, Grunwald GK, Shunk KA. Mortality after presentation with stent thrombosis is associated with time from index percutaneous coronary intervention: a report from the VA CART program. *Am Heart J* 2014;**168**(4):560–567.
 36. Armstrong EJ, Sab S, Singh GD, Lim W, Yeo KK, Waldo SW, Patel M, Reeves R, MacGregor JS, Low RI, Shunk KA, Mahmud E, Rogers JH. Predictors and outcomes of recurrent stent thrombosis: results from a multicenter registry. *JACC Cardiovasc Interv* 2014;**7**(10):1105–1113.
 37. Sommer P, Armstrong EJ. Stent thrombosis: current management and outcomes. *Curr Treat Options Cardiovasc Med* 2015;**17**(3):365.
 38. Yeo KK, Armstrong EJ, Soni K, Waldo SW, Patel M, Reeves R, MacGregor JS, Low RI, Shunk KA, Mahmud E, Rogers JH. Long-term outcomes of angiographically confirmed coronary stent thrombosis: results from a multicentre California registry. *EuroIntervention* 2015;**11**(2):188–195.
 39. Yeh RW, Secemsky EA, Kereiakes DJ, Normand SL, Gershlick AH, Cohen DJ, Spertus JA, Steg PG, Cutlip DE, Rinaldi MJ, Camenzind E, Wijns W, Apruzzese PK, Song Y, Massaro JM, Mauri L, DAPT Study Investigators. Development and validation of a prediction rule for benefit and harm of dual antiplatelet therapy beyond 1 year after percutaneous coronary intervention. *JAMA* 2016;**315**(16):1735–1749.
 40. Gibson CM, Mehran R, Bode C, Halperin J, Verheugt FW, Wildgoose P, Birmingham M, Janus J, Burton P, van Eickels M, Korjian S, Daaboul Y, Lip GY, Cohen M, Husted S, Peterson ED, Fox KA. Prevention of bleeding in patients with atrial fibrillation undergoing PCI. *N Engl J Med* 2016;**375**(25):2423–2434.
 41. Valgimigli M, Gagnor A, Calabro P, Frigoli E, Leonardi S, Zaro T, Rubartelli P, Briguori C, Ando G, Repetto A, Limbruno U, Cortese B, Sganzerla P, Lupi A, Galli M, Colangelo S, Ierna S, Ausiello A, Presbitero P, Sardella G, Varbella F, Esposito G, Santarelli A, Tresoldi S, Nazzaro M, Zingarelli A, de Cesare N, Rigattieri S, Tosi P, Palmieri C, Brugaletta S, Rao SV, Heg D, Rothenbuhler M, Vranckx P, Juni P, MATRIX Investigators. Radial versus femoral access in patients with acute coronary syndromes undergoing invasive management: a randomised multicentre trial. *Lancet* 2015;**385**(9986):2465–2476.
 42. Bellemain-Appaix A, O'Connor SA, Silvain J, Cucherat M, Beygui F, Barthelemy O, Collet JP, Jacq L, Bernasconi F, Montalescot G, ACTION Group. Association of clopidogrel pretreatment with mortality, cardiovascular events, and major bleeding among patients undergoing percutaneous coronary intervention: a systematic review and meta-analysis. *JAMA* 2012;**308**(23):2507–2516.

43. Parodi G, Xanthopoulos I, Bellandi B, Gkizas V, Valenti R, Karanikas S, Migliorini A, Angelidis C, Abbate R, Patsilinas S, Baldereschi GJ, Marcucci R, Gensini GF, Antoniucci D, Alexopoulos D. Ticagrelor crushed tablets administration in STEMI patients: the MOJITO study. *J Am Coll Cardiol* 2015;**65**(5):511–512.
44. Rollini F, Franchi F, Hu J, Kureti M, Aggarwal N, Durairaj A, Park Y, Seawell M, Cox-Alomar P, Zenni MM, Guzman LA, Suryadevara S, Antoun P, Bass TA, Angiolillo DJ. Crushed prasugrel tablets in patients with STEMI undergoing primary percutaneous coronary intervention: the CRUSH study. *J Am Coll Cardiol* 2016;**67**(17):1994–2004.
45. Park DW, Kim YH, Yun SC, Ahn JM, Lee JY, Kim WJ, Kang SJ, Lee SW, Lee CW, Park SW, Park SJ. Frequency, causes, predictors, and clinical significance of periprocedural myocardial infarction following percutaneous coronary intervention. *Eur Heart J* 2013;**34**(22):1662–1669.
46. Saw J, Aymong E, Sedlak T, Buller CE, Starovoytov A, Ricci D, Robinson S, Vuormans T, Gao M, Humphries K, Mancini GB. Spontaneous coronary artery dissection: association with predisposing arteriopathies and precipitating stressors and cardiovascular outcomes. *Circ Cardiovasc Interv* 2014;**7**(5):645–655.
47. van Werkum JW, Heestermans AA, Zomer AC, Kelder JC, Suttorp MJ, Rensing BJ, Koolen JJ, Brueren BR, Dambrink JH, Hautvast RW, Verheugt FW, ten Berg JM. Predictors of coronary stent thrombosis: the Dutch Stent Thrombosis Registry. *J Am Coll Cardiol* 2009;**53**(16):1399–1409.
48. Cayla G, Hulot JS, O'Connor SA, Pathak A, Scott SA, Gruel Y, Silvain J, Vignolou JB, Huerre Y, de la Briolle A, Allanic F, Beygui F, Barthelemy O, Montalescot G, Collet JP. Clinical, angiographic, and genetic factors associated with early coronary stent thrombosis. *JAMA* 2011;**306**(16):1765–1774.
49. Byrne RA, Joner M, Kastrati A. Stent thrombosis and restenosis: what have we learned and where are we going? The Andreas Gruntzig Lecture ESC 2014. *Eur Heart J* 2015;**36**(47):3320–3331.
50. Sibbing D, Braun S, Morath T, Mehilji J, Vogt W, Schomig A, Kastrati A, von Beckerath N. Platelet reactivity after clopidogrel treatment assessed with point-of-care analysis and early drug-eluting stent thrombosis. *J Am Coll Cardiol* 2009;**53**(10):849–856.
51. Cuisset T, Deharo P, Quilici J, Johnson TW, Deffarges S, Bassez C, Bonnet G, Fourcade L, Mouret JP, Lambert M, Verdier V, Morange PE, Alessi MC, Bonnet JL. Benefit of switching dual antiplatelet therapy after acute coronary syndrome: the TOPIC (timing of platelet inhibition after acute coronary syndrome) randomized study. *Eur Heart J* 2017 May 16. doi: 10.1093/eurheartj/ehx175. [Epub ahead of print]
52. Kimura T, Isshiki T, Ogawa H, Yokoi H, Yamaguchi T, Ikeda Y. Randomized, double-blind, dose-finding, phase II study of prasugrel in Japanese patients undergoing elective percutaneous coronary intervention. *J Atheroscler Thromb* 2015;**22**(6):557–569.
53. Cassese S, Byrne RA, Ndrepepa G, Kufner S, Wiebe J, Repp J, Schunkert H, Fusaro M, Kimura T, Kastrati A. Everolimus-eluting bioresorbable vascular scaffolds versus everolimus-eluting metallic stents: a meta-analysis of randomised controlled trials. *Lancet* 2016;**387**(10018):537–544.
54. Sorrentino S, Giustino G, Mehran R, Kini AS, Sharma SK, Faggioni M, Farhan S, Vogel B, Indolfi C, Dangas GD. Everolimus-eluting bioresorbable scaffolds versus metallic everolimus-eluting stents. *J Am Coll Cardiol* 2017 Jun 27;**69**(25):3055–3066. doi: 10.1016/j.jacc.2017.04.011. Epub 2017 Apr 12.
55. Wykrzykowska JJ, Kraak RP, Hofma SH, van der Schaaf RJ, Arkenbout EK, IJ AJ, Elias J, van Dongen IM, Tijssen RY, Koch KT, Baan J, Jr., Vis MM, de Winter RJ, Piek JJ, Tijssen JG, Henriques JP, AIDA Investigators. Bioresorbable scaffolds versus metallic stents in routine PCI. *N Engl J Med* 2017 Jun 15;**376**(24):2319–2328. doi: 10.1056/NEJMoa1614954. Epub 2017 Mar 29.
56. Sotomi Y, Suwannasom P, Serruys PW, Onuma Y. Possible mechanical causes of scaffold thrombosis: insights from case reports with intracoronary imaging. *EuroIntervention* 2017 Feb 20;**12**(14):1747–1756. doi: 10.4244/EIJ-D-16-00471.
57. Felix CM, Vlachojannis GJ, AJJ IJ, Fam JM, Smits PC, Lansink WJ, Diletti R, Zijlstra F, Regar ES, Boersma E, Onuma Y, van Geuns RJM. Potentially increased incidence of scaffold thrombosis in patients treated with Absorb BVS who terminated DAPT before 18 months. *EuroIntervention* 2017 Jun 2;**13**(2):e177–e184. doi: 10.4244/EIJ-D-17-00119.
58. Lee KS, Lee JZ, Hsu CH, Husnain M, Riaz H, Riaz IB, Thai H, Cassese S, Finn A, Samady H, Byrne RA. Temporal trends in strut-level optical coherence tomography evaluation of coronary stent coverage: a systematic review and meta-analysis. *Catheter Cardiovasc Interv* 2016;**88**(7):1083–1093.
59. Malle C, Tada T, Steigerwald K, Ughi GJ, Schuster T, Nakano M, Massberg S, Jehle J, Guagliumi G, Kastrati A, Virmani R, Byrne RA, Joner M. Tissue characterization after drug-eluting stent implantation using optical coherence tomography. *Arterioscler Thromb Vasc Biol* 2013;**33**(6):1376–1383.
60. Schomig A, Kastrati A, Mudra H, Blasini R, Schuhlen H, Klaus V, Richardt G, Neumann FJ. Four-year experience with Palmaz-Schatz stenting in coronary angioplasty complicated by dissection with threatened or present vessel closure. *Circulation* 1994;**90**(6):2716–2724.
61. Serruys PW, Strauss BH, Beatt KJ, Bertrand ME, Puel J, Rickards AF, Meier B, Goy JJ, Vogt P, Kappenberger L, et al. Angiographic follow-up after placement of a self-expanding coronary-artery stent. *N Engl J Med* 1991;**324**(1):13–17.
62. Leon MB, Baim DS, Popma JJ, Gordon PC, Cutlip DE, Ho KK, Giambartolomei A, Diver DJ, Lasorda DM, Williams DO, Pocock SJ, Kuntz RE. A clinical trial comparing three antithrombotic-drug regimens after coronary-artery stenting. Stent Anticoagulation Restenosis Study Investigators. *N Engl J Med* 1998;**339**(23):1665–1671.
63. Schomig A, Neumann FJ, Kastrati A, Schuhlen H, Blasini R, Hadamitzky M, Walter H, Zitzmann-Roth EM, Richardt G, Alt E, Schmitt C, Ulm K. A randomized comparison of antiplatelet and anticoagulant therapy after the placement of coronary-artery stents. *N Engl J Med* 1996;**334**(17):1084–1089.
64. Tada T, Byrne RA, Simunovic I, King LA, Cassese S, Joner M, Fusaro M, Schneider S, Schulz S, Ibrahim T, Ott I, Massberg S, Laugwitz KL, Kastrati A. Risk of stent thrombosis among bare-metal stents, first-generation drug-eluting stents, and second-generation drug-eluting stents: results from a registry of 18,334 patients. *JACC Cardiovasc Interv* 2013;**6**(12):1267–1274.
65. Dzijan-Horn M, Langwieser N, Groha P, Bradaric C, Linhardt M, Bottiger C, Byrne RA, Steppich B, Koppa T, Godel J, Hadamitzky M, Ott I, von Beckerath N, Kastrati A, Laugwitz KL, Ibrahim T. Safety and efficacy of a potential treatment algorithm by using manual compression repair and ultrasound-guided thrombin injection for the management of iatrogenic femoral artery pseudoaneurysm in a large patient cohort. *Circ Cardiovasc Interv* 2014;**7**(2):207–215.
66. Palmerini T, Biondi-Zoccai G, Della Riva D, Stettler C, Sangiorgi D, D'Ascenzo F, Kimura T, Briguori C, Sabate M, Kim HS, De Waha A, Kedhi E, Smits PC, Kaiser C, Sardella G, Marullo A, Kirtane AJ, Leon MB, Stone GW. Stent thrombosis with drug-eluting and bare-metal stents: evidence from a comprehensive network meta-analysis. *Lancet* 2012;**379**(9824):1393–1402.
67. Kolandaivelu K, Swaminathan R, Gibson WJ, Kolachalama VB, Nguyen-Ehrenreich KL, Giddings VL, Coleman L, Wong GK, Edelman ER. Stent thrombogenicity early in high-risk interventional settings is driven by stent design and deployment and protected by polymer-drug coatings. *Circulation* 2011;**123**(13):1400–1409.