

Case report of an infant with severe vitamin D deficiency rickets manifested as hypocalcemic seizures

Biljana Vuletić^{1,2}, Slavica Marković^{1,2}, Zoran Igrutinović^{1,2}, Vladimir Radlović³, Zorica Rašković^{1,2}, Jelena Tanasković-Nestorović^{1,2}, Aleksandra Simović^{1,2}

¹Pediatric Clinic, Clinical Center of Kragujevac, Kragujevac, Serbia;

²University of Kragujevac, Faculty of Medical Sciences, Kragujevac, Serbia;

³University Children's Hospital, Belgrade, Serbia

SUMMARY

Introduction Hypocalcemic seizures are uncommon in the post-neonatal period. We report an infant with hypocalcemic seizures caused by severe deficiency of vitamin D.

Case Outline A five-month-old male infant was admitted to hospital in March 2013 with recurrent generalized afebrile seizures resistant to clonazepam therapy. At the clinical examination, the infant showed characteristic rachitic signs, so that after a blood sample was taken for laboratory testing, the infant was given infusion of 2 ml/kg of 10% of calcium gluconate at a rate of 0.5 ml/min. The treatment resulted in immediate termination of seizures and normalization of the consciousness of the infant. Blood sample analysis showed extremely low levels of free and total calcium (0.36/1.24 mmol/l) and 25(OH)D (<3 ng/ml), elevated alkaline phosphatase (878 U/l) and parathyroid hormone (283 pg/ml), and low calcium/creatinine ratio (mg/mg) in a portion of urine (0.03), while the levels of serum phosphorus, pH, total protein, albumin and creatinine were within the reference range. Wrist X-ray showed typical signs of rickets. In order to fully stabilize calcium homeostasis, along with 2,000 IU of vitamin D3 daily and standard cow's milk formula, calcium gluconate (80 mg/kg daily) was given orally over a period of two weeks. The treatment resulted in complete stabilization of the infant's condition and rapid improvement in laboratory, radiological and clinical findings of rickets.

Conclusion Generalized convulsions in the afebrile infant represent a serious and etiopathogenically very heterogeneous problem. Extremely rare, as in the case of our patient, it may be due to severe hypocalcemia caused by a deficiency of vitamin D.

Keywords: vitamin D deficiency; hypocalcemia; convulsions

INTRODUCTION

A seizure or convulsion is a paroxysmal, time-limited change in motor activity or behaviour that results from abnormal electrical activity in the brain. A seizure is the most common pediatric neurological disorder, with 4–10% of children suffering at least one attack of seizure in the first 16 years of life [1]. However, if seizures occur during infancy with clinical symptoms not accompanied by fever, there are many possible causes. It is of utmost importance to distinguish a seizure from other nonepileptic conditions that may mimic seizure activity. If a historical detail does not seem typical for a seizure, an alternative diagnosis should be considered such as infectious, neurologic or developmental, traumatic or vascular, toxicologic or metabolic impairments, including hypocalcaemia. Establishing the diagnosis in patients with hypocalcaemia can be difficult. There is a wide range of disorders such as hypocalcemic hypercalciuria, congenital hypoparathyroidism, infantile osteopetrosis, renal dysplasia, autoimmune polyglandular endocrinopathy, genetic disorders [2, 3]. Calcium deficiency has been implicated and in some, but not all,

disturbances of phosphate metabolism and iron deficiency may be present [4]. Awareness of hypocalcaemia as a cause of seizures is important because children are still treated with anticonvulsants without serum calcium concentrations being checked. Calcium plays a central role in many body functions and is an important cofactor in muscle contraction. Despite variations in dietary intake of calcium, blood calcium concentration is controlled within precise limits. It is regulated principally by three hormones: parathyroid hormone, calcitonin, and 1,25-dihydroxycholecalciferol. Major causes which affect calcium homeostasis are low maternal vitamin D stores, cow's milk feeding, skin pigmentation, physical sunscreen agents, geography, malabsorption (celiac disease, pancreatic insufficiency, cystic fibrosis, biliary obstruction), decreased synthesis or increased degradation of 25(OH)D (chronic liver disease), and drugs [5]. Lower maternal educational status and large family size also play an important role in maintaining calcium homeostasis [6]. Hypocalcemic seizures are uncommon in the post-neonatal period. We report an infant with hypocalcemic seizures caused by severe deficiency of vitamin D.

Correspondence to:

Biljana VULETIĆ
Pediatric Clinic
Clinical Centre of Kragujevac
Zmaj Jovina 30, 34000 Kragujevac
Serbia
sibil@ptt.rs

CASE REPORT

A five-month-old male infant was admitted to the Emergency Department in March 2013 with recurrent generalized afebrile seizures resistant to clonazepam therapy. At the clinical examination, the infant showed characteristic rachitic signs (widely open anterior fontanelle, craniotabes, chicken breast, Harrison's groove, rachitic rosary, thickening of the distal segments of the wrist and tibia, large abdomen) (Figure 1), so that after the blood sample was taken for laboratory testing, the infant was given infusion of 2 ml/kg of 10% calcium gluconate at a rate of 0.5 ml/min. The treatment resulted in immediate termination of seizures and the normalization of consciousness of the infant. Blood sample analysis showed extremely low levels of free and total calcium and 25(OH)D elevated alkaline phosphatase and parathyroid hormone, and low calcium/creatinine ratio in a portion of urine, while the levels of serum phosphorus, pH, total protein, albumin and creatinine were within the reference range (Table 1). Wrist X-ray showed typical signs of rickets (Figure 2). Other physical findings, including neurological ones, were normal. Electroencephalogram was made two weeks later and was also normal. In addition to rickets due to vitamin D deficiency, mild iron-deficiency anemia (hemoglobin 106 g/L, mean corpuscular volume 69 fl, blood iron 6 $\mu\text{mol/l}$) was also detected in the infant.

The child's parents were healthy and young, with lower levels of educational attainment and of modest means.

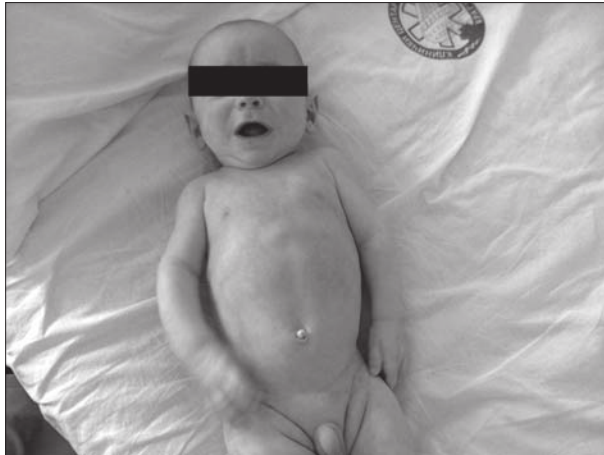

Figure 1. Picture of our patient showing characteristic rachitic signs: chicken breast, Harrison's groove, rachitic rosary, thickening of the distal segments of the wrist, and large abdomen

Table 1. Blood laboratory findings of our patient at admission and after two months of treatment

Parameter	First day	After two weeks	After one month	After two months	Reference range
Ca ⁺⁺ (mmol/l)	0.36	1.06	1.08	1.16	1.15–1.36
Ca (mmol/l)	1.27	2.40	2.70	2.48	2.02–2.65
P (mmol/l)	1.35	1.45	2.19	2.10	0.80–1.90
ALP (U/l)	878	478	465	364	34–104
PTH (pgr/ml)	283	-	22.0	-	8–76
25(OH)D (ng/ml)	< 3	11.06	30.75	17.40	20–40

Ca⁺⁺ – free calcium; Ca – total calcium; P – phosphorus; ALP – alkaline phosphatase; PTH – parathyroid hormone; 25(OH)D – 25-hydroxycholecalciferol (calcidiol)

He was born after the third normal full-term pregnancy with the body weight (BW) of 3,250 g (weight/age z-score 0.46) and the body length (BL) of 51 cm (length/age z-score -0.06). The baby was delivered normally with the Apgar score of 8/9. Since birth, he was formula-fed for two months, and continued with full-fat cow's milk and complementary food at around four months of age. He did not have any additional daily intake of vitamin D. When he was admitted to the hospital, his BW was 6,500 g (weight/age z-score -1.59) and his BL was 60.5 cm (length/age z-score -1.63).

During the treatment, vitamin D₃ was administered in a dose of 2,000 IU daily over a period of two months, followed by 400 IU daily by the end of the first year. Cow's milk was replaced by an adapted milk formula. Sideropenic anemia was simultaneously corrected with oral supplements of iron.

DISCUSSION

Rickets is an example of extreme vitamin D deficiency, with peak incidence between three and 18 months of age. Initial descriptions of rickets were provided by Daniel Whistler and Francis Glisson in England as early as the 17th century [7, 8]. At the turn of the 20th century, with industrialization, this disease became endemic until it was discovered that exposure to sunlight could prevent and treat rickets [9, 10]. However, there has been a reappearance of rickets from vitamin D deficiency in recent decades as a result of multiple factors, and rickets has also been reported even in children in Western countries. Two large case series reported 126 cases over a period of 10 years in Australia and 104 cases over two years in Canada [11, 12]. Increasing incidence of nutritional rickets was reported in the United States, and in other parts of the world it still remains a public health problem [13–18]. The diagnosis of any of the forms of vitamin D deficiency rickets is usually established by clinical, biochemical, and radiographic criteria [19]. To prevent rickets, the European Society for Paediatric Gastroenterology, Hepatology and Nutrition recommended vitamin D as a supplement for

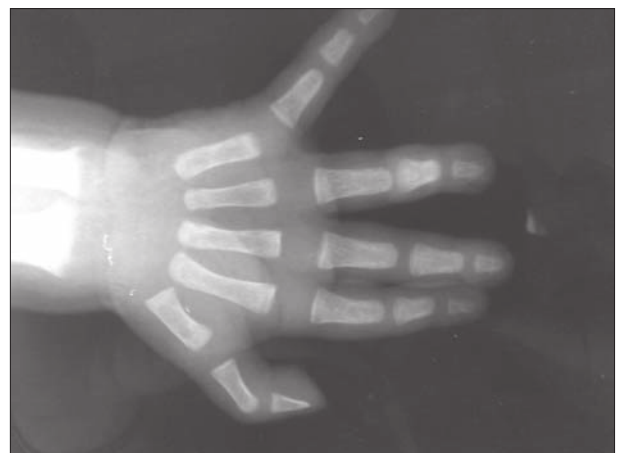


Figure 2. Radiography of the left wrist in our patient. There is metaphyseal fraying and cupping of the distal radius and ulna.

breastfed infants. The supplementation should start during the first months of life and continue throughout childhood and adolescence. The optimal daily intake of vitamin D for these groups is 400 IU daily [19, 20]. Vitamin D supplementation is necessary in infants and children who manifest clinical features of rickets in daily allowance of 25 to 250 µg (1,000–10,000 IU). Hypocalcaemia should also be treated with calcium supplements, or parenteral administration of calcium gluconate in case of manifest tetany or convulsions [21]. Despite current guidelines for vitamin D supplementation [19, 20], hypocalcemic seizures in infants continue to be reported [22]. One of the main reasons, particularly in developing countries, is cow's milk feeding since birth, which, in accordance with the inadequate rate of calcium and phosphorus (1:1) reduces calcium absorption. It is the cause of osteomalacia, severe hypocalcaemia with tetany as the hallmark, laryngospasm, and impaired cardiac function (prolonged QT interval on the electrocardiogram) [23]. Symptomatic hypocalcaemia, including seizures, occurs during periods of rapid growth long before any physical findings or radiologic evidence of vitamin D can be obtained. Some children with vitamin D deficiency can present with hypocalcaemia without the typical skeletal phenotype.

What seemed to be a rare entity has become a reality. The patient's mother fed her baby full cow's milk since the

second month of life. She also reported putting sunscreen when outdoors. The baby did not take any vitamin D supplements after birth. However, the first impression on our patient during admission, with clinical signs of rickets, suggested hypocalcaemia as the cause of afebrile seizures. Initial investigations confirmed the first impression (severe hypocalcaemia, vitamin D deficiency, secondary hyperparathyroidism). The baby was successfully managed following the intravenous administration of calcium gluconate, oral supplementation with calcium and vitamin D, and dietary changes. The patient was also given iron supplements, as we detected iron-deficiency anemia. The association between iron status in infants and the types of milk feeding is already well known [24], but there are some reported cases of the relationship between rickets and anemia and of the effects of vitamin D on erythropoiesis [25]. Vitamin D deficiency is associated with a greater risk of anemia, lower mean hemoglobin and higher usage of erythrocyte-stimulating agents. Another factor that may affect anemia in rickets is secondary hyperparathyroidism, as we found in our patient [26].

In conclusion, generalized convulsions in the afebrile infant represent a serious and etiopathogenically very heterogeneous problem. Extremely rare, as in the case of our patient, it may be due to severe hypocalcemia caused by a deficiency of vitamin D.

REFERENCES

- Friedman MJ, Shariëff GQ. Seizures in children. *Pediatr Clin N Am.* 2006; 53(2):257-77. [DOI: 10.1016/j.pcl.2005.09.010] [PMID: 16574525]
- Singh J, Moghal N, Pearce SH, Cheetham T. The investigation of hypocalcaemia and rickets. *Arch Dis Child.* 2003; 88(5):403-7. [DOI: 10.1136/adc.88.5.403] [PMID: 12716711]
- Shaw N. A practical approach to hypocalcaemia in children. *Endocr Dev.* 2009; 16:73-92. [DOI: 10.1159/000223690] [PMID: 19494662]
- Radlović V, Smoljanić Z, Radlović N, Leković Z, Ristić D, Dučić S, et al. X-linked hypophosphatemic rickets: case report. *Srp Arh Celok Lek.* 2014; 142(1-2):75-8. [DOI: 10.2298/SARH1402075R] [PMID: 24684036]
- Misra M, Pacaud D, Petryk A, Collett-Solberg PF, Kappy M. Drug and Therapeutics Committee of the Lawson Wilkins Pediatric Endocrine Society. Vitamin D deficiency in children and its management: review of current knowledge and recommendations. *Pediatrics.* 2008; 122(2):398-417. [DOI: 10.1542/peds.2007-189] [PMID: 18676559]
- Radlović N, Leković Z, Ristić D, Radlović V, Djuričić G, Dimitrijević A, et al. Case report of acute vitamin D intoxication in an infant. *Srp Arh Celok Lek.* 2014; 142(11-2):736-9. [DOI: 10.2298/SARH1412736R] [PMID: 25731008]
- Lovinger RD. Grand round series. Rickets. *Pediatrics.* 1980; 66(3):359-65. [PMID: 6999445]
- Greenbaum LA. Rickets and hypervitaminosis D. In: Kliegman RM, Stanton BF, Schol NF, St Geme III JW, Behrman RE, editors. *Nelson Textbook of Pediatrics.* 16th ed. Philadelphia: Elsevier; 2000. p.184-7.
- Weick MT. A history of rickets in the United States. *Am J Clin Nutr.* 1967; 20(11):1234-41. [PMID: 4862158]
- Kumar J, Muntner P, Kaskel FJ, Hailpern SM, Melamed ML. Prevalence and associations of 25-hydroxyvitamin D deficiency in US children. *Pediatrics.* 2009; 124(3):e362-70. [DOI: 10.1542/peds.2009-0051] [PMID: 19661054]
- Robinson PD, Hogler W, Craig ME, Verge CF, Walker JL, Piper AC, et al. The re-emerging burden of rickets: a decade of experience from Sydney. *Arch Dis Child.* 2006; 91(7):564-8. [DOI: 10.1136/adc.2004.069575] [PMID: 15956045]
- Ward LM. Vitamin D deficiency in the 21st century: a persistent problem among Canadian infants and mothers. *CMAJ.* 2005; 172(6):769-70. [DOI: 10.1503/cmaj.050177] [PMID: 15767611]
- Shah M, Salhab N, Patterson D, Seikaly MG. Nutritional rickets still afflict children in north Texas. *Tex Med.* 2000; 96(6):64-8. [PMID: 10876374]
- Mylott BM, Kump T, Bolton ML, Greenbaum LA. Rickets in the Dairy State. *WMJ.* 2004; 103(5):84-7. [PMID: 15553572]
- McAllister JC, Lane AT, Buckingham BA. Vitamin D deficiency in the San Francisco Bay Area. *J Pediatr Endocrinol Metab.* 2006; 19(3):205-8. [DOI: 10.1515/JPEM.2006.19.3.205] [PMID: 16607919]
- Wondale Y, Shiferaw F, Lulseged S. A systematic review of nutritional rickets in Ethiopia: status and prospects. *Ethiop Med J.* 2005; 43(3):203-10. [PMID: 16370553]
- Muhe L, Lulseged S, Mason KE, Simoes EA. Case-control study of the role of nutritional rickets in the risk of developing pneumonia in Ethiopian children. *Lancet.* 1997; 349(9068):1801-4. [DOI: 10.1016/S0140-6736(96)12098-5] [PMID: 9269215]
- Harris NS, Crawford PB, Yangzom Y, Pinzo L, Gyaltzen P, Hudes M. Nutritional and health status of Tibetan children living at high altitudes. *N Engl J Med.* 2001; 344(5):341-47. [DOI: 10.1056/NEJM200102013440504] [PMID: 11172165]
- Radlović N, Mladenović M, Simić D, Radlović P. Vitamin D in the light of current knowledge. *Srp Arh Celok Lek.* 2012; 140(1-2):110-4. [DOI: 10.2298/SARH1202110R] [PMID: 22462359]
- Braegger C, Campoy C, Colomb V, Decsi T, Domellof M, Fewtrell M, et al. Vitamin D in the healthy European paediatric population; ESPGHAN Committee on Nutrition. *J Pediatr Gastroenterol Nutr.* 2013; 56(6):692-701. [DOI: 10.1097/MPG.0b013e31828f3c05] [PMID: 23708639]
- Lee JY, So TY, Thackray J. A review on vitamin D deficiency treatment in pediatric patient. *J Pediatr Pharmacol Ther.* 2013; 18(4):277-91. [DOI: 10.5863/1551-6776-18.4.277] [PMID: 24719588]
- Hsieh DT, Chang T, Tsuchida TN, Vezina LG, Vanderver A, Siedel J, et al. New onset afebrile seizures in infants. *Neurology.* 2010; 74(2):150-6. [DOI: 10.1212/WNL.0b013e3181c91847] [PMID: 20065250]

23. Prentice A. Nutritional rickets around the world. *J Steroid Biochem Mol Biol.* 2013; 136:201-6. [DOI: 10.1016/j.jsbmb.2012.11.018] [PMID: 23220549]
24. Thorsdottir AV, Ramel A, Pálsson GI, Tomasson H, Thorsdottir I. Iron status of one-year-olds and association with breast milk, cow's milk or formula in late infancy. *Eur J Nutr.* 2013; 52(6):1661-8. [DOI: 10.1007/s00394-012-0472-8] [PMID: 23212531]
25. Sim JJ, Lac PT, Liu IL, Meguerditchian SO, Kumar VA, Kujubu DA, et al. Vitamin D deficiency and anaemia: a cross-sectional study. *Ann Hematol.* 2010; 89(5):447-52. [DOI: 10.1007/s00277-009-0850-3] [PMID: 19841921]
26. Elidrissy AT, Zolali MA, Hawsawi ZM. Anaemia in infants with vitamin D deficiency rickets: A single center experience and literature review. *J Appl Hematol.* 2012; 3(1):39-43.

Приказ тешког рахитиса услед недостатка витамина Д испољеног хипокалцијемским конвулзијама код одојчета

Биљана Вулетих^{1,2}, Славица Марковић^{1,2}, Зоран Игрутиновић^{1,2}, Владимир Радловић³, Зорица Рашковић^{1,2}, Јелена Танасковић-Несторовић^{1,2}, Александра Симовић^{1,2}

¹Педијатријска клиника, Клинички центар Крагујевац, Крагујевац, Србија;

²Универзитет у Крагујевцу, Факултет медицинских наука, Крагујевац, Србија;

³Универзитетска дечја клиника, Београд, Србија

КРАТАК САДРЖАЈ

Увод Хипокалцијемске конвулзије су ретка појава у пост-неонаталном периоду. Приказујемо одојче с хипокалцијемским конвулзијама узрокованим тешким недостатком витамина Д.

Приказ болесника Петомесечно мушко одојче примљено је марта 2013. године због понављаних генерализованих афебрилних конвулзивних напада резистентних на лечење клоназепамом. При клиничком прегледу детета установљени су класични знаци рахитиса, те је, по узимању крви за лабораторијска испитивања, дата инфузија десетопроцентног калцијум-глуконата у дози од 2 ml/kg брзином од 0,5 ml/min. Примењена терапија је довела до непосредног престанка конвулзија и нормализације стања свести детета. Лабораторијске анализе крви су показале изузетно ниске нивое слободног и укупног калцијума (0,36/1,24 mmol/l) и 25(OH) D (<3 ng/ml), повишене вредности алкалне фосфатазе (878 U/l) и паратиреоидног хормона (283 pg/ml) и низак однос

калцијума и креатинина (mg/mg) у узорку урина (0,03), док су вредности фосфора, pH, укупних протеина, албумина и креатинина у крви биле у референтним оквирима. Радиографски снимак ручја је показао типичне рахитисне промене. Ради пуне стабилизације хомеостазе калцијума, уз 2000 ИЈ витамина Д₃ дневно током два месеца и исхрану адаптираном формулом крављег млека, детету је у прве две недеље у терапију додат и калцијум-глуконат орално (80 mg/kg дневно). Примењена терапија је довела до потпуне стабилизације стања детета и брзог побољшања лабораторијских, радиографских и клиничких показатеља рахитиса.

Закључак Генерализоване конвулзије код афебрилног одојчета су тежак и етиопатогенетски веома хетероген проблем. Изузетно ретко, као код приказаног болесника, могу бити последица тешке хипокалцијемје узроковане дефицитом витамина Д.

Кључне речи: недостатак витамина Д; хипокалцијемја; конвулзије

Примљен • Received: 04/03/2015

Прихваћен • Accepted: 29/05/2015