

## Case Report of Imaging Analyses of the Dysplasia Epiphysealis Hemimelica (Trevor's Disease)

### 편측성 골단 이형성증(트레버 질환)의 영상소견: 2예 보고

Jang Ho Suh, MD, Kil Ho Cho, MD

Department of Diagnostic Radiology, College of Medicine, Yeungnam University, Daegu, Korea

Trevor's disease, also known as dysplasia epiphysealis hemimelica, is a rare developmental disorder presented with epiphyseal overgrowth involving one or multiple epiphyses. Here we report the radiologic findings of two cases of dysplasia epiphysealis hemimelica in a 4-year-old boy in the knee without symptom and a 10-year-old boy in the ankle with pain. The former was observed for eight years and the latter was treated with surgical resection.

#### Index terms

Trevor's Disease  
Dysplasia Epiphysealis Hemimelica  
Osteocartilag Overgrowth

Received March 27, 2013; Accepted April 14, 2013

Corresponding author: Kil Ho Cho, MD

Department of Diagnostic Radiology, College of Medicine, Yeungnam University, 170 Hyeonchung-ro, Nam-gu, Daegu 705-717, Korea.  
Tel. 82-53-620-3045 Fax. 82-53-653-5484  
E-mail: khcho@med.yu.ac.kr

This is an Open Access article distributed under the terms of the Creative Commons Attribution Non-Commercial License (<http://creativecommons.org/licenses/by-nc/3.0>) which permits unrestricted non-commercial use, distribution, and reproduction in any medium, provided the original work is properly cited.

## INTRODUCTION

Dysplasia epiphysealis hemimelica (DEH) or Trevor's disease is a rare non-hereditary developmental bone dysplasia characterized by an osteocartilaginous tumor arising from an epiphysis (1). The general prevalence has been reported be 1 in 1000000 and the etiology is unknown. Most patients are first seen between the ages of 2 and 14 years and three times more common in boys (2). DEH predominantly occurs in the lower limb with the talus, distal tibia, distal fibula, distal femur, proximal tibia and tarsal bones in the order of the frequency (3).

## CASE REPORT

### Case 1

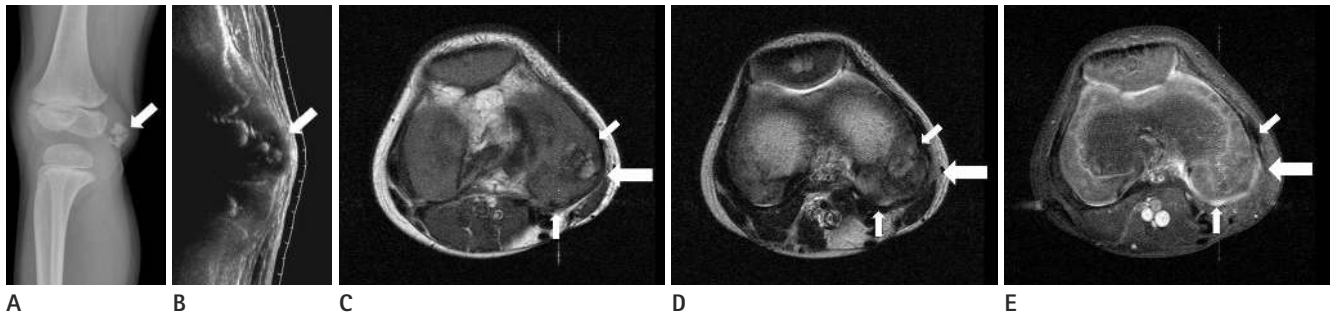
A 4-year-old boy presented to the orthopedics clinic, with incidentally found mass on the right knee with no symptoms. There was no history of trauma or previous joint swelling. The patient had normal gait and normal range of motion of the knee. Radiographs of the right knee showed multiple ossifica-

tions in the postero-medial aspect of the distal femoral epiphysis. The metaphyses of the femur and tibia were normal (Fig. 1A). Ultrasound and magnetic resonance imaging (MRI) revealed the presence of asymmetric epiphyseal cartilaginous overgrowth, which contained multiple ossifications (Fig. 1B-E). It was decided to observe the patient with no surgical intervention since no pain and normal range of movement of the knee.

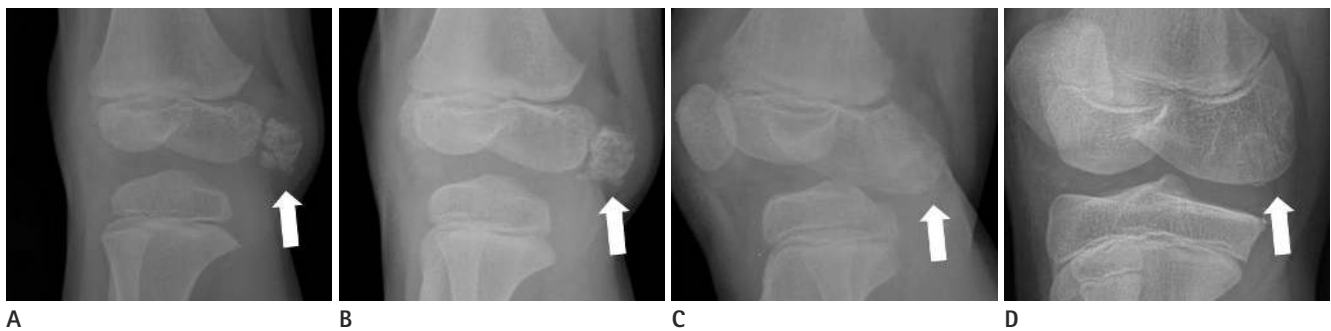
During the past eight years, serial follow-up radiographs showed that the epiphysis of the distal femur had been gradually normalized (Fig. 2) and the last follow-up MRI showed normal bone contour and signal intensity in the distal femur with disappearance of the DEH findings (Fig. 3).

### Case 2

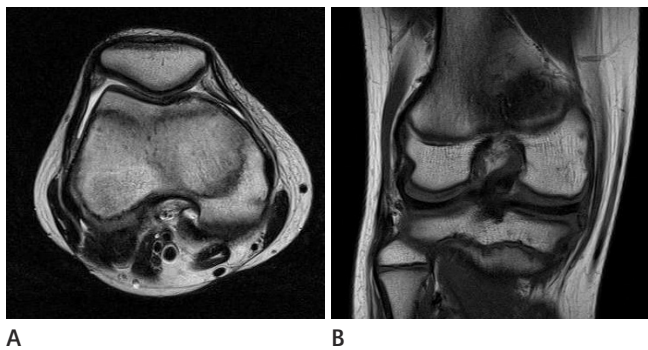
A 10-year-old boy presented to the orthopedic clinic, with ankle pain and mass on the anterolateral aspect of the left ankle, which was palpable for a month. There was a history of left ankle sprain about 8 months ago. Physical examination revealed a palpable hard mass (1 × 1 cm in size) of the anterior lateral aspect of the talus. Pain was induced on full dorsiflexion. Radio-



**Fig. 1.** 4-year-old man with Trevor's disease in the right distal femur. **A.** Initial oblique (**A**) radiograph shows multiple calcific foci in the postero-medial aspect of the epiphysis of the right distal femur (arrow). **B.** Sagittal sonography (**B**) shows epiphyseal cartilaginous overgrowth, containing multiple echogenic foci (arrow). **C-E.** Axial T2-weight image (**C**), axial T1-weight image (**D**) and axial enhanced T1-weight image (**E**) show the presence of asymmetric epiphyseal cartilaginous overgrowth (small arrows), which contain multiple ossifications, in the postero-medial aspect of the distal femur (arrows).



**Fig. 2.** 4-year-old man with Trevor's disease in the right distal femur. Follow-up oblique radiographs after 12 months (**A**), 24 months (**B**), 54 months (**C**) and 8 years (**D**) show that calcific foci are matured and becomes confluent with the epiphysis of the distal femur (arrows).



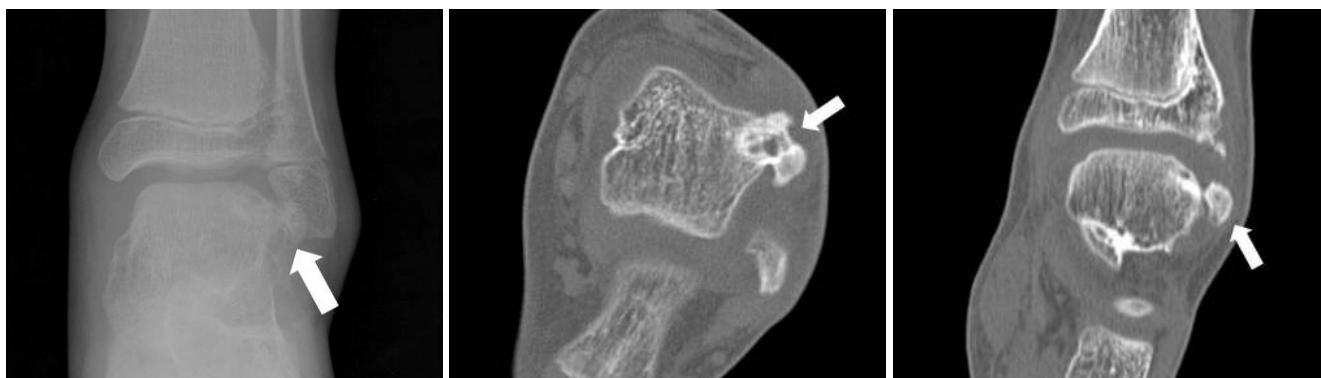**Fig. 3.** 4-year-old man with Trevor's disease in the right distal femur. Follow-up after 8 years, axial T2 weight image (**A**) and coronal T1 weight image (**B**) show normal bone contour and signal intensity in the distal femur with disappearance of the dysplasia epiphysealis hemimelica findings.

graph and computed tomography (CT) of the ankle showed excessive bony overgrowth from the anterolateral aspect of the talus with soft tissue swelling (Fig. 4). The abnormal over-growth portion of the talus was excised and for pathological examination which indicated dysplasia epiphysealis hemimelica. Two years later, the patient revisited with ankle pain. Radiograph and CT of the ankle revealed recurrence of the dysplasia epiphysealis hemi-

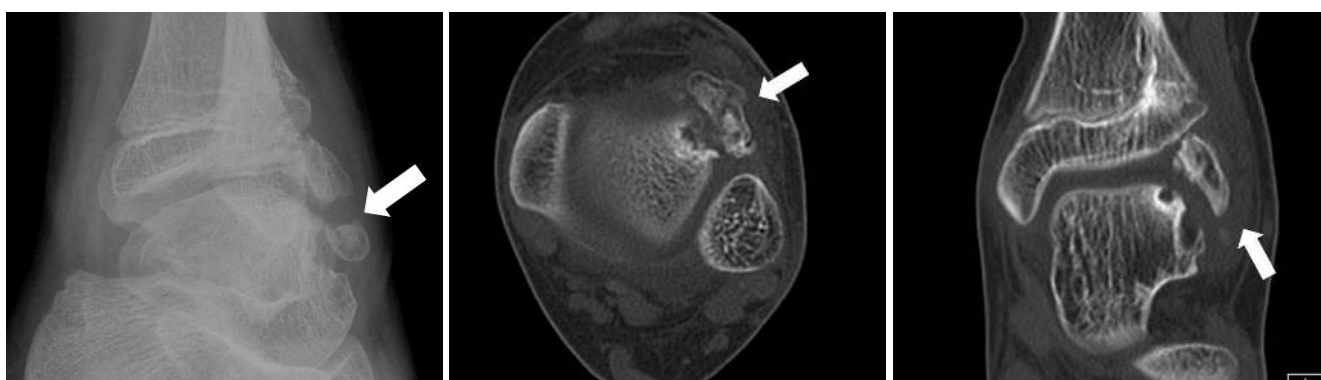
melica (Fig. 5). Surgical resection was repeated for the recurred mass with similar pathological results as before.

## DISCUSSION

The clinical manifestations of Trevor's disease can be varied. The most common presenting complaints are from a painless deformity around a joint to a painful joint with mechanical symptoms (1). The typical radiographic finding is asymmetric epiphyseal cartilaginous overgrowth, containing multiple ossification centers. The patterns of the epiphyseal chondral calcification are variable namely stippled, irregular or dense. The epiphyseal calcified spots of the lesion are often multi-centric, which are gradually enlarged with mineralization and become confluent with the main epiphysis. CT is useful for the detection of small foci of early calcification or ossification within the cartilaginous mass and can identify cortical and medullary continuity between the DEH lesion and the adjacent bone. MRI is the technique of choice to identify the dimensions of the unossified cartilage mass, the extent of epiphyseal involvement and the sta-



**Fig. 4.** 10-year-old man with Trevor's disease in the left talus. Initial AP radiograph (A), unenhanced axial (B) and coronal (C) CT show irregular ossified mass, arising talus, in the antero-lateral aspect of the talus (arrows).



**Fig. 5.** 10-year-old man with Trevor's disease in the left talus. Follow-up study after 2 years due to recurrent ankle pain, oblique radiograph (A), unenhanced axial (B) and coronal (C) CT show recurrent mass in the antero-lateral aspect of the talus (arrows).

tus of the epiphysis (4).

Differential diagnoses include myositis ossificans, infection, tumoral calcinosis, synovial chondromatosis, loose bodies, vascular or parasitic calcification on radiography. Biopsy is not necessary; however, if imaging results are not conclusive, biopsy should be performed to exclude chondrosarcoma and osteosarcoma (5).

Management options for the treatment of Trevor's disease include simple observation or surgical excision. By considering pain or deformity, appropriate treatment should be performed. As in our first case, asymptomatic DEH can be observed because there is no known risk of malignant transformation. Prognosis and symptoms depend on the site and size of the lesion and the degree of incongruity of the involved site. The recurrence rate of the deformity is reported to be high (6).

The two cases presented here were precisely diagnosed by CT or MRI prior to the management. Since the different symptoms and deformities of the each patient, the first was observed for

eight years and the other was surgically managed. In particular, there is significant that first case was confirmed by radiologic image that DEH findings gradually became confluent with the main epiphysis during observation for eight years and finally made normal bone contour and density without deformity.

## REFERENCES

1. Kuo RS, Bellemore MC, Monsell FP, Frawley K, Kozlowski K. Dysplasia epiphysealis hemimelica: clinical features and management. *J Pediatr Orthop* 1998;18:543-548
2. Shinozaki T, Ohfuchi T, Watanabe H, Aoki J, Fukuda T, Takagishi K. Dysplasia epiphysealis hemimelica of the proximal tibia showing epiphyseal osteochondroma in an adult. *Clin Imaging* 1999;23:168-171
3. Rosero VM, Kiss S, Terebessy T, Köllö K, Szöke G. Dysplasia epiphysealis hemimelica (Trevor's disease): 7 of our own cases and a review of the literature. *Acta Orthop* 2007;78:

- 856-861
4. Tyler PA, Rajeswaran G, Saifuddin A. Imaging of dysplasia epiphysealis hemimelica (Trevor's disease). *Clin Radiol* 2013;68:415-421
5. Lang IM, Azouz EM. MRI appearances of dysplasia epiphysealis hemimelica of the knee. *Skeletal Radiol* 1997;26:226-229
6. Keret D, Spatz DK, Caro PA, Mason DE. Dysplasia epiphysealis hemimelica: diagnosis and treatment. *J Pediatr Orthop* 1992;12:365-372

## 편측성 골단 이형성증(트레버 질환)의 영상소견: 2예 보고

서장호 · 조길호

트레버 질환 혹은 편측성 골단 이형성증은 성장기 뼈 골단 골연골의 과성장이 하나 혹은 여러 골단에 발생하는 드문 질환이다. 저자는 증상없이 내원한 4세 남자 환자의 오른쪽 무릎의 증례와 좌측 발목통증이 있던 10세 남자 환자 등 2예를 영상소견과 함께 보고한다. 전자는 보존적 치료를, 후자는 수술적 치료를 시행하였다.

영남대학교 의과대학 영상의학과