

Celiac disease-like enteropathy due to antihypertensive therapy with the angiotensin-II receptor type 1 inhibitor eprosartan

Hans Maier¹, Karlheinz Hehemann², Michael Vieth¹

¹*Institute of Pathology, Klinikum Bayreuth, Germany*

²*Practice of Internal Medicine, Beckum-Neubeckum, Germany*

SUMMARY

An 83-year-old woman with hypertension received the angiotensin-II receptor type 1 blocker (ARB) eprosartan for more than 10 years. Six months ago, the dosage of the drug was doubled, and the patient reported a sudden onset of diarrhea. Duodenal biopsies showed a celiac disease-like pathology with flattened mucosa and an increase of intraepithelial lymphocytes and eosinophils, but serology of celiac disease remained negative. Celiac disease-like changes have been previously reported to be associated with other ARBs. This is the first case following eprosartan medication. In celiac-disease-like pathology of the small bowel with negative serology, drug-induced changes, for example due to ARBs, should be excluded.

Keywords: celiac disease – negative serology – ARB – eprosartan

Enteropatie podobná celiakii způsobená antihypertenzivní terapií inhibítorem receptoru typu 1 angiotenzinu-II – eprosartanem

SOUHRN

83leté pacientka s hypertenzí byla více než 10 let léčena inhibítorem receptoru typu 1 angiotenzinu-II – eprosartanem. Před šesti měsíci byla dávka léků zdvojnásobena a u pacientky došlo k náhlému vzniku průjmů. Biopsie duodena prokázala změny podobné celiakii s oploštěním sliznice a zmnožením intraepiteliálních lymfocytů a eozinofilů. Sérologická vyšetření na celiakii však byla negativní. Změny podobné celiakii byly už dříve spojeny s léčbou inhibitory receptoru typu 1 angiotenzinu-II. Tento případ poprvé vznikl při léčbě eprosartanem. Při patologickém nálezu v tenkém střevu podobnému celiakii s negativní sérologií by měly být vyloučeny terapií indukované změny, např. terapií inhibítorem receptoru typu 1 angiotenzinu-II.

Klíčová slova: celiakie – negativní erologie – ACE inhibitory – eprosartan

Cesk Patol 2015; 51(2): 87 – 88

Duodenal changes caused by drugs mimicking the classical pathology of coeliac disease are a well-known pitfall in pathology. They have been recently described in patients treated with olmesartan, a newer member of angiotensin-II receptor type 1 inhibitors (ARBs) with a prolonged degradation time and higher effect on hypertension. It has been documented in one study on 22 patients (1) and two case reports (2,3). We report here similar changes during therapy with eprosartan, another drug of the ARB family.

CLINICAL HISTORY AND METHODS

An 83-year-old woman reported a sudden onset of diarrhea. A gastroscopy was performed, and biopsies from the duodenum were taken. After fixation with 4% buffered formaldehyde and embedding in paraffin, slices of 5 µm thickness were stained

with hematoxylin/eosin (H&E). Histology revealed a severe attenuation of the duodenal villi (Fig. 1). The amount of intraepithelial lymphocytes was over 25/100 epithelial cells, accompanied by eosinophilic granulocytes (Fig. 2). Subepithelial collagen deposits were not noticed. No cells with expression of IgG4 were present.

The serology for celiac disease was negative in our patient. Our inquiry of more detailed information on the clinical history and on the possible use of medications disclosed a long-standing history of systemic hypertension and an antihypertensive therapy with eprosartan for the last ten years. Six months ago, the daily dosage of 300 mg (half of a tablet) had been doubled to 600mg, apparently causing the gastrointestinal symptoms. There was no history of celiac disease in previous biopsies. After our diagnosis of eprosartan-induced diarrhea and concomitant mucosal changes of the small bowel, eprosartan was replaced through an application of the calcium channel blocker amlodipin with cessation of diarrhea. Control biopsies three and six months after the diagnosis showed only slightly improved mucosal architecture, indicating a delayed regeneration of the duodenal mucosa after application of ARBs like eprosartan.

DISCUSSION

Eprosartan belongs to the first generation of ARBs recommended for the therapy of hypertension, chronic heart failure,

✉ Correspondence address:

Hans Maier M.D.

Institute of Pathology, Klinikum Bayreuth,

Preuschwitzer Strasse 101, D-95445 Bayreuth, Germany

tel.: +49 921 400 5602, fax: +49 921 400 5609

e-mail: hans.maier@klinikum-bayreuth.de

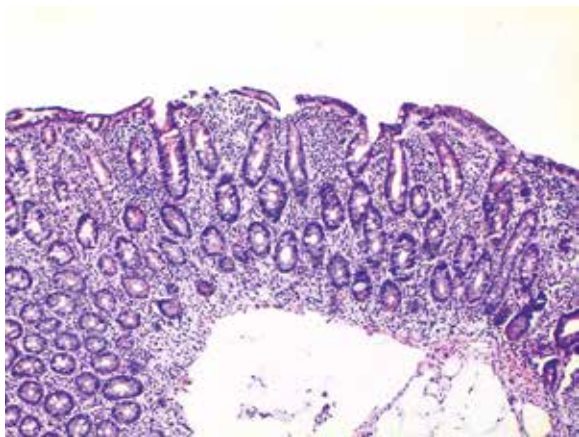


Fig. 1. Duodenal biopsy with subtotally flattening of the villi with raised cellularity of the lamina propria. H&E, x40.

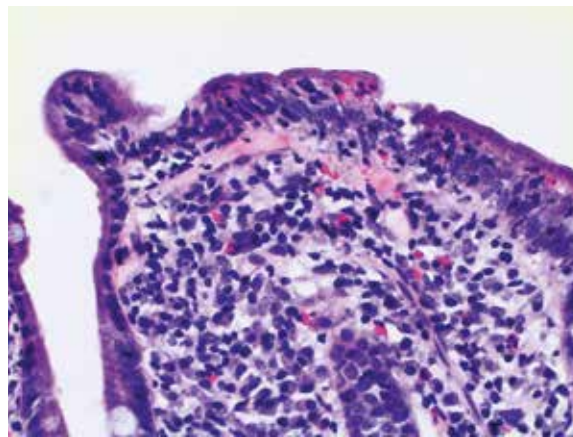


Fig. 2. Higher magnification exhibiting infiltrating lymphocytes and eosinophils within the surface epithelium. H&E, x100

and for protection from diabetic nephropathy and myocardial infarction. When applied per os, 90% of the drug is eliminated unchanged by feces, as a mirror of a poor oral bioavailability (4). About 10% is taken up rapidly from the gastrointestinal tract (4). It has been shown that the oral clearance of eprosartan is decreasing parallel to age, and that disturbances in renal and hepatic function may negatively influence the pharmacokinetics of eprosartan (4). In addition to celiac-disease-like pathology caused by olmesartan, our case is the first one reporting similar side effects using eprosartan.

Duodenal histology showing shortening or complete flattening of the villi combined with raised content of intraepithelial lymphocytes leads to a panel of differential diagnosis. The diagnosis of celiac disease itself needs clinical confirmation by serological testing which had been negative in our patient. Autoimmune duodenopathy is characterized by a significant infiltration by IgG4 positive cells but they were not found in the duodenal

biopsies of our case. Non-steroidal antirheumatic drugs (NSAR) might also mimic celiac disease-like pathology and should be excluded by the patient's medical history. Another cause for severe mucosal flattening and cell infiltration in young persons might be Crohn's disease. This presumptive diagnosis affords confirmation by bioptic examination of the ileum and colorectum.

In conclusion, in cases with sudden onset of a celiac-like pathology with negative serology, several differential diagnoses should be ruled out. The possibility of drug-induced changes, esp. such caused by ARB or NSAR medication, has to be excluded by inquiring for information on the patient's medication.

CONFLICT OF INTEREST

The authors declare that there is no conflict of interests regarding the publication of this paper.

REFERENCES

1. **Rubio-Tapia A, Herman ML, Ludvigsson JF, et al.** Severe spruelike enteropathy associated with olmesartan. *Mayo Clin Proc* 2012; 87(8): 732-738.
2. **Dreifuss SE, Tomizawa Y, Farber NJ, Davison JM, Sohnen AE.** Spruelike enteropathy associated with olmesartan: An unusual case of severe diarrhea. *Case Rep Gastrointest Med* 2013; 2013: 618071.
3. **Nielsen JA, Steephen A, Lewin M.** Angiotensin-II inhibitor (olmesartan)-induced collagenous sprue with resolution following discontinuation of drug. *World J Gastroenterology* 2013; 19(40): 6928-6930.
4. **Michel MC, Foster C, Brunner HR, Liu L.** A systematic comparison of the properties of clinically used angiotensin II type 1 receptor antagonists. *Pharmacol Rev* 2013; 65(2): 809-848.