

Central Serous Chorioretinopathy

Raffael Liegl Michael W. Ulbig

Department of Ophthalmology, Ludwig Maximilian University of Munich, Munich, Germany

Key Words

Central serous chorioretinopathy · Pathogenesis · Epidemiology · Risk factors

Abstract

The pathogenesis of central serous chorioretinopathy (CSC) is still not fully understood. The involvement of corticosteroids is undisputed, although their exact role has not been clarified; other parts of the underlying mechanism of CSC have been mainly elucidated by imaging techniques such as fluorescein and indocyanine green angiography. Even though most cases of CSC are self-limiting, severe as well as recurrent courses exist, and for these patients only a limited number of treatment options are available: laser photocoagulation, with a risk of scotoma and choroidal neovascularization, and photodynamic therapy. In this review article, we give an overview of its epidemiology, the current understanding of its pathogenesis as well as systemic and ocular risk factors. We illuminate modern diagnostic tools as well as current treatment options in the context of CSC, particularly in the light of a better understanding of corticosteroids and their receptors involved in its pathogenesis.

© 2014 S. Karger AG, Basel

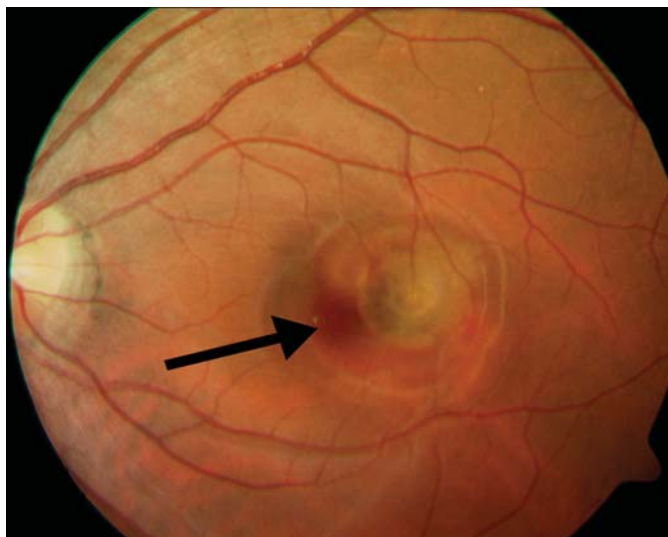
Introduction

In 1866 Albrecht von Graefe [1] described a disease that he referred to as ‘recurrent central retinitis’. Patients suffering from this condition showed a circumscribed se-

rous retinal detachment typically affecting the posterior pole, particularly the macular region (fig. 1). The exact underlying mechanism of that disease was not known in those days, nor is it fully understood today. Von Graefe introduced the idea of retinitis, implying that there was an inflammatory component of this disease, based on his observation that all patients with this condition during that time also suffered from syphilis [2]. Nowadays it has been common to refer to this condition as ‘central serous chorioretinopathy’ (CSC), a term mainly coined by Donald Gass in the late 1960s; however, other synonyms such as ‘(chorio)retinopathia centralis serosa’ or ‘central serous retinopathy’ are also still in use.

The evolution of the term ‘central serous chorioretinopathy’ has always been closely linked to the conception of the pathomechanism underlying this disease at the respective point in time. Horniker [3] was the first to revise von Graefe’s idea of an inflammation as the underlying reason for the disease, as he observed patients with this condition without any previous history of syphilis. Rather, he believed that it was a constitutional angioneurosis which caused vasospasm and subsequent exudation in these patients [3]. Later concepts included Gifford and Marquardt’s [4] ‘central angiospastic retinopathy’ in 1939 as they believed an angiopathy with an abnormal vessel muscle tone was the reason for this disorder.

The concept of a vasospastic disease did not change until fluorescein angiography (FA) was introduced in ophthalmology, allowing a better understanding of the disease. In 1965 Maumenee [5] was the first to publish his



Color version available online

Fig. 1. Color fundus photography of the left eye of a 35-year-old female patient with impressive PED in the macular region and RPE depigmentation (arrow).

observation on leakage, which he made during FA at the level of the retinal pigment epithelium (RPE), suggesting involvement of both the RPE and the choroid. More detailed observations and a further understanding of the condition, mainly through better-characterized FA findings, finally led to the term ‘idiopathic central serous chorioidopathy’ by Gass, which over time has been adjusted to ‘central serous chorioretinopathy’ owing to the knowledge about the hyperpermeability of the RPE [6, 7].

In this review article, we give an overview of the epidemiology of CSC, the current understanding of its pathogenesis as well as systemic and ocular risk factors. We illuminate modern diagnostic tools in the context of CSC as well as current treatment options, particularly in the light of a better understanding of corticosteroids and their receptors involved in the pathogenesis.

Epidemiology

Although CSC has not been in the focus of research over the last years, clinicians are often confronted with this disease as it is supposed to be the fourth most common nonsurgical retinopathy after age-related macular degeneration, diabetic retinopathy and branch retinal vein occlusion [8]. Historically, its occurrence has mainly been associated with men in their 30s to 40s. Indeed, although only one population-based study and no systemic epidemiologic survey of CSC has been carried out, a

large number of single studies support the idea of men being more often affected than women, presenting male-to-female ratios of up to 8:1 [9–14]. The mean age of patients affected is quoted variably in these studies but seems to be slightly higher than usually assumed, with a peak at around 40–45 years in men, although some studies suggest even higher mean ages for men [15–18] and particularly for women and patients with chronic CSC [8, 11, 19]. In addition, cases of CSC in children have been reported [20, 21].

In terms of occurrence among different races, there seems to be a shift in distribution toward people of Hispanic, Asian and Caucasian descent [22, 23]. People of African descent seem to be affected notably less frequently according to some authors, although it has been discussed that this conception might be wrong and derived from the reduced availability of medical infrastructure in poor countries for adequately diagnosing this condition [24]. Some authors also report on more aggressive courses of the disease in Black people [25, 26].

Pathogenesis

CSC has long been considered to be a vasospastic disease. This conception has been largely abandoned with the advent of diagnostic imaging techniques such as FA and indocyanine green angiography (ICGA). However, its pathogenesis still remains unclear in spite of these advances. Numerous hypotheses have been proclaimed and mainly involve the RPE as well as the choroid as being central contributors to subretinal fluid accumulation with subsequent detachment of the neurosensory retina [27].

The current idea of the pathophysiology of CSC mainly proclaims choroidal vascular hyperpermeability to be the major reason for the increased tissue hydrostatic pressure beneath the RPE that can eventually lead to disintegration of the continuity of the RPE [28]. The observation that the retinal detachment regresses once the fluorescein leakage from one or multiple sites stops, as found by FA, has been interpreted as showing that there was a lesion of the RPE leading to subretinal accumulation of fluid originating from the choroid [16, 29]. ICGA findings show a staining of the inner choroid in the midphase of the angiogram, suggesting choroidal vascular hyperpermeability which may arise from venous congestion and ischemia [30–35]. Under physiologic conditions, the balance between oncotic and hydrostatic pressure usually leads to fluid flowing from the retina toward the choroid [16]. In

CSC, however, an extensive hydrostatic pressure within the choroid leads to fluid being squeezed out of the choroidal vascular system and subsequently accumulating underneath the RPE [36, 37]. Once the tissue hydrostatic pressure beneath the RPE is high enough, it is believed that it pushes the RPE forward, which in turn results in discontinuity of the RPE barrier, leading to pigment epithelial detachment (PED) and pinpoint areas of leakage often referred to as ‘microrips’ or ‘blowouts’ [38, 39]. In addition, the damage to the RPE is presumed to lead to an aggravation of this condition, since the RPE may be restricted in its ability to pump fluid out of the subretinal space. This theory is further supported by the clinical finding of leaks in the RPE demonstrated by FA at the level of choroidal vascular hyperpermeability [40, 41]. However, choroidal thickening as seen by OCT and inner choroidal staining as signs of increased choroidal hyperpermeability can also be observed in other regions of the retina not directly adjacent to a PED or microrip. Although this might counteract the idea of a PED caused by fluid pushing from the choroid toward the RPE, one explanation includes the typical area of clinically observed PED in the foveal region with presumably weaker attachment of the thinner retina and therefore greater predisposition to serous retinal detachment [8].

The role of the RPE is still only vaguely understood and other ideas of the pathophysiology of CSC also include an abnormal polarity of some of the RPE cells leading to fluid being pumped from the choroid to the retina [42]. This concept, however, has some weaknesses as it fails to explain the occurrence of PED and why some depolarized RPE cells overwhelm the surrounding, normally aligned RPE cells in terms of fluid flow direction.

The mechanistic hypothesis proposing that fluid coming from hyperpermeable choroidal vessels leads to increased tissue hydrostatic pressure – which results in RPE damage – seems reasonable; however, it does not explain why the choroidal vascular system would develop an increased permeability.

Systemic and Ocular Risk Factors

Several risk factors for the development of CSC exist, but they are not fully understood, and only high serum glucocorticoid levels seem to be unambiguously related to the occurrence of CSC [18, 43]. Increased glucocorticoid and serum catecholamine levels have been found in patients with CSC [12, 44–47]. However, no increased risk for the development of CSC has been ob-

served after intake of sympathomimetic agents alone [27]. Furthermore, no improvement in the course of CSC was seen after intake of β -blockers, suggesting that the simultaneous upregulation of serum catecholamine levels in a situation of increased glucocorticosteroid levels is due to a stress response, rather than suggesting that the disease triggers this increased expression [48, 49]. With respect to corticosteroids, however, several studies proved an association of increased levels with CSC for corticosteroids of endogenous and particularly exogenous origin [50, 51]. Glucocorticoid as well as mineralocorticoid hormones belong to the same group referred to as corticosteroids synthesized from cholesterol. It is well known that corticosteroids have an impact on the RPE, Bruch’s membrane and the choriocapillaris, possibly altering their permeability directly or secondarily due to vascular autoregulation or vascular reactivity [52–54]. It remains unclear, though, why elevated serum corticosteroid levels may trigger CSC, while intraocular injections of triamcinolone or similar drugs are very rarely associated with the development of CSC [16, 55, 56].

One of the first risk factors identified was having a type A personality [23]. People referred to as having a type A personality are usually characterized by a highly status-conscious, ambitious and rigidly organized pattern of behavior [57]. Further risk factors that have been proposed include pregnancy, alcohol consumption, untreated hypertension, use of antibiotics, bone marrow or organ transplantation, infection of the respiratory tract and infection with *Helicobacter pylori* [12, 44, 58–63].

Clinical Presentation

CSC typically occurs unilaterally in younger patients and is characterized by decreased and distorted vision, often associated with metamorphopsia, micropsia, mild dyschromatopsia and reduced contrast sensitivity [64]. However, bilateral affection occurs and is more often seen in elderly patients.

CSC can occur in an acute or chronic form, but no generally accepted duration has been defined for the chronic form; many authors tend to speak of chronic CSC if symptoms last longer than 3 months, but other authors speak of chronicity if CSC alterations and symptoms are present for more than 6 months [65–67]. Visual acuity is usually reduced to 20/30 to 20/60 and can in some cases be corrected with a weak plus lens due to a slightly elevated retina level causing mild hypermetropia [16, 64]. While acute CSC usually resolves spontaneously with re-

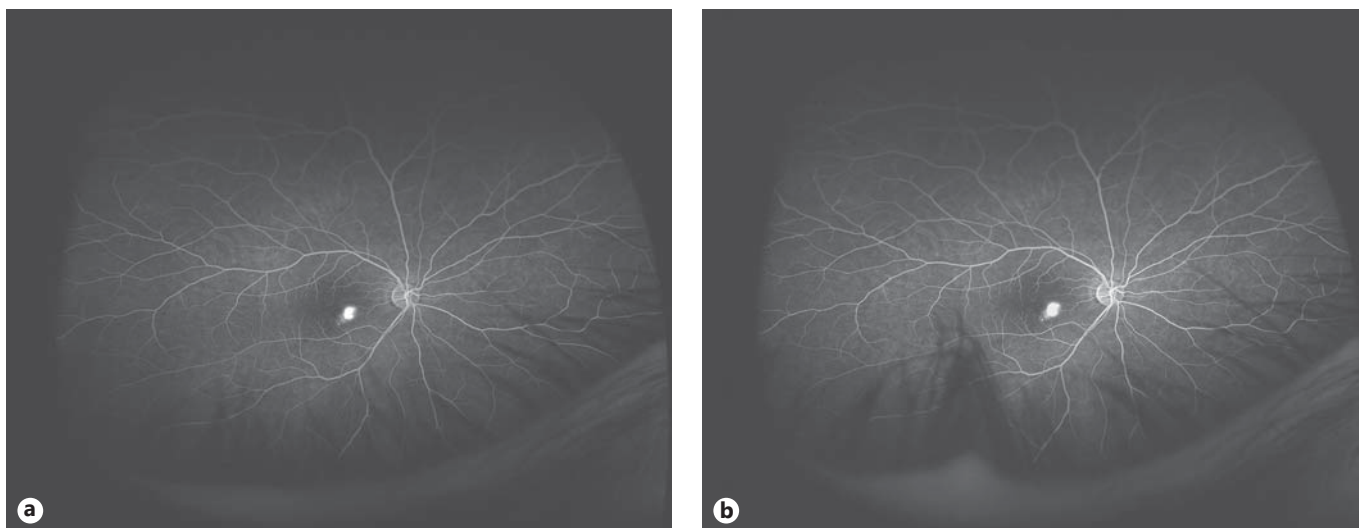


Fig. 2. Widefield angiography of the right eye of a 42-year-old male patient with typical inkblot leakage 30 s after fluorescein injection (a) and 5 min later (b). No other leakages could be detected in this patient, but leakages in the periphery even of asymptomatic eyes are not uncommon.

turn to normal or almost normal visual acuity, recurrent forms are not rare and may be seen in more than 50% of patients suffering from CSC [68, 69]. Clinically, it most commonly presents as a localized, circumscribed area of retinal detachment most often in the macular region. The subretinal fluid is usually clear in acute cases but may also have a hazy or fibrinous appearance, while additional blood is very uncommon in CSC. The RPE may show areas of disturbance or abnormal pigmentation variable in size within the detachment of the sensory retina, sometimes even leading to PED.

Chronic CSC, on the other hand, typically goes along with more advanced stages of RPE alteration, which may lead to a distinct and permanent loss of visual acuity. This form has also been termed ‘diffuse retinal pigment epitheliopathy’ and implies an advanced age at the time of the diagnosis [17]. Detachments of the neurosensory retina in these patients differ from those in patients with acute CSC as they appear less elevated and may show thinning of the retina as well as atrophy of the underlying RPE. The prolonged detachment may be caused by photoreceptor and RPE damage and results in unfavorable visual acuity; moreover, a minority of cases might even develop choroidal neovascularization (CNV) and RPE tears with subsequent risk of severe visual impairment [70, 71].

Another form of CSC is characterized by large, usually multiple, sectors of bullous, serous retinal and/or RPE detachments. It is a rare form and may occur secondary to

CSC. Typical features include greater numbers and sizes of areas of choroidal hyperpermeability and bullous retinal detachment which often extends by gravitation to the inferior part of the retina. It seems to be more frequent in Japanese people and has been reported after organ transplantation as well [72–74].

Imaging in CSC

Imaging techniques such as FA or ICGA have been very helpful tools for gaining a better understanding of the pathophysiology of CSC and for supporting a diagnosis of CSC. However, a better knowledge of risk factors and patient characteristics as well as gradual improvements in clinical description have led to the situation that most CSC cases can be sufficiently diagnosed without further need for imaging devices. Apart from invasive imaging tools such as FA and ICGA, novel developments including OCT with enhanced depth imaging and fundus autofluorescence imaging (FAF) may contribute to a deeper understanding of the disease.

Fluorescein Angiography

Angiographic findings for acute CSC are characterized by focal fluorescein leaks at the level of the RPE leading to subretinal accumulation of dye [75]. Three different manifestations have been described and include ‘smokestack leak’ and ‘inkblot leak’ patterns (fig. 2),

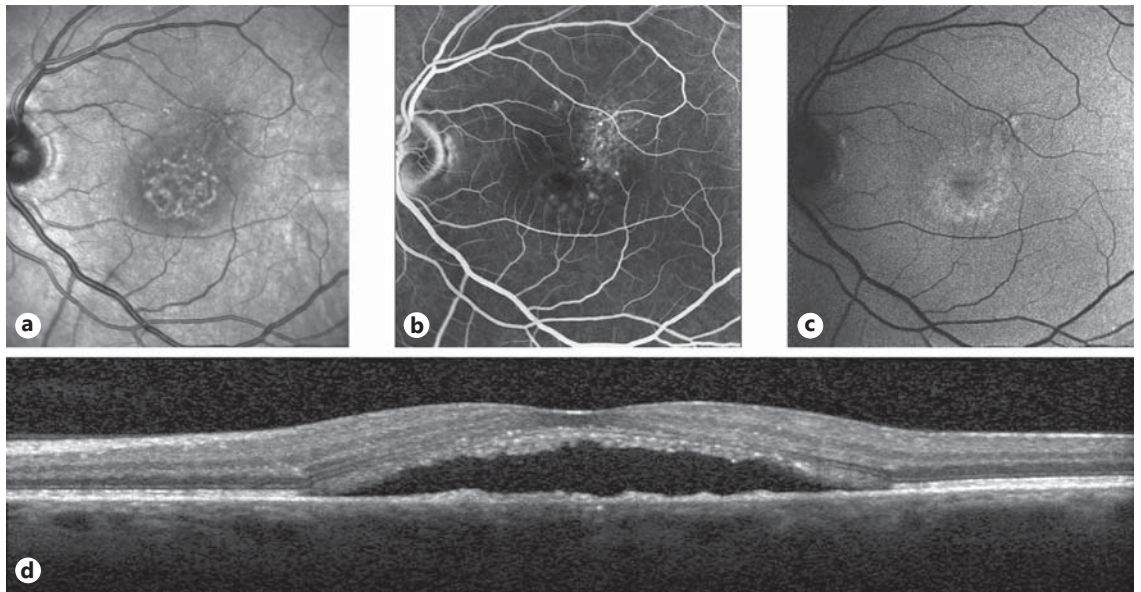


Fig. 3. Left eye of a 48-year-old male patient with a history of CSC showing typical features of CSC. **a** Red-free photography. **b** FA showing multiple inkblot leakages after 3 min. **c** FAF with hyperautofluorescence as a possible sign of acute CSC. **d** Corresponding SD-OCT with shallow PED and subretinal deposits, potentially a sign of fibrin.

depending on the nature of the protein in the subretinal fluid and the morphology of the altered RPE [76, 77].

A ‘smokestack leak’ is associated with pinpoint focal RPE leaks and present in only 7% of patients suffering from CSC. The majority (approx. 93%) has a more uniform dye spread also referred to as an ‘inkblot leak’. These pinpoint areas of hyperfluorescence tend to expand in the time course of the FA in a roundish fashion. The leakage points, regardless of their pattern, are usually distributed in a 1-mm-wide ring-shaped zone starting 0.5 mm from the center of the fovea. More than half of the leakages are found in the nasal quadrant, followed by the temporal quadrant, with approximately 35% of the leakages located there [9, 16, 76].

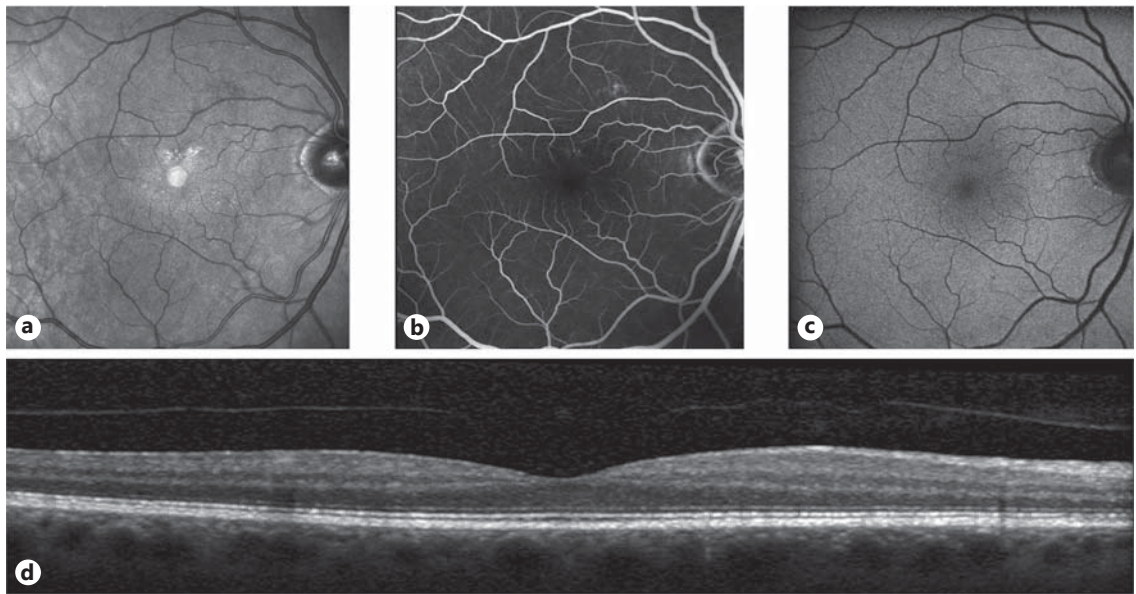
Indocyanine Green Angiography

In CSC an inner choroidal staining can typically be appreciated as a possible sign of fibrin. This staining appears in the midphase of the ICGA and fades in the late phase, which allows for differentiation from CNV [32, 34]. ICGA is particularly helpful in chronic CSC patients as it is often very difficult to interpret areas of leakage on FA images, and sometimes even patients with no signs of fluorescein leakage show increased choroidal vascular hyperpermeability; however, ICGA usually does not contribute to

treatment considerations, although some authors suggest the use of ICGA-guided photodynamic therapy (PDT) [78–81].

Optical Coherence Tomography

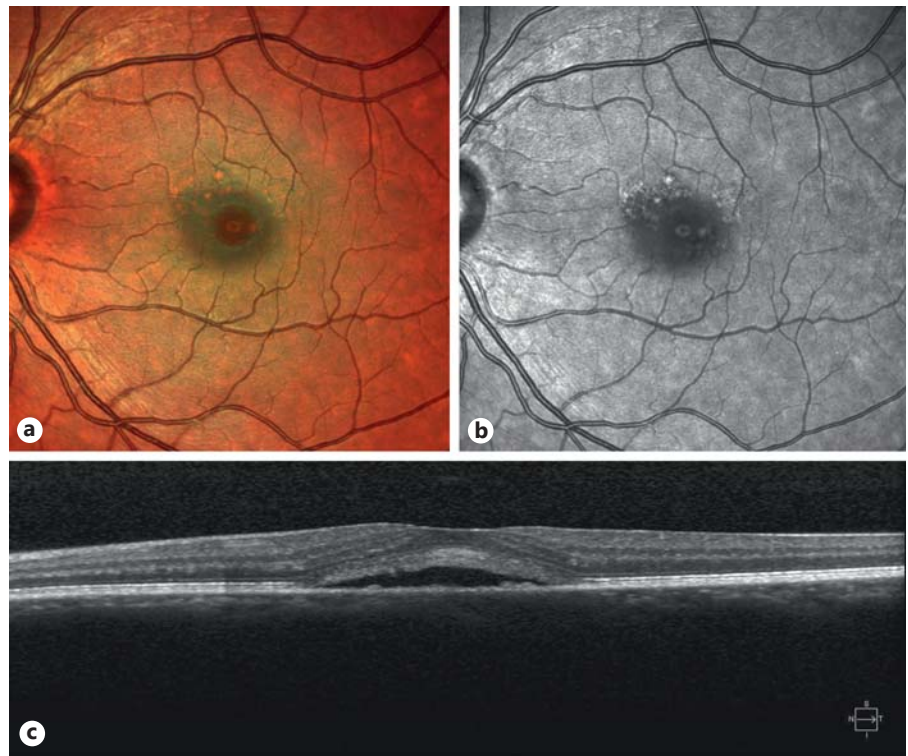
Spectral-domain OCT (SD-OCT) is a helpful tool in retinal diseases and also in CSC [82]. As a noninvasive diagnostic device, it allows to capture fast and high-resolution sectional images of the retina. Several aspects of CSC have been investigated using OCT: it has been shown that the diameter of the choroidal vessels was significantly wider in affected eyes than in normal control eyes [83]. Other groups showed differences in the architecture of the retinal area involved between acute and chronic CSC, implying that acute CSC patients have a significantly higher pure retinal layer volume but do not differ from chronic patients in terms of subretinal fluid [84]. Furthermore, enhanced depth imaging, a new development of OCT, has provided a deeper insight into choroidal thickness. Several groups were able to prove that the choroid is thicker in patients suffering from CSC in both the affected and the fellow eye compared with normal controls, strengthening the original idea of a hyperpermeable choroid [85–88]. Other OCT findings include photoreceptor elongation as well as other defects in the inner segment/outer segment band which may correlate with visual acuity prognosis [89–91] (fig. 3–5).



4

Fig. 4. Right asymptomatic eye of the same 48-year-old male patient as in figure 3. **a** Red-free photography. **b** FA image. **c** FAF image. **d** SD-OCT image.

Fig. 5. **a** Multicolor image gained by simultaneous SD-OCT (Heidelberg Engineering, Heidelberg, Germany) image acquisition with 3 different color-selective laser sources. The value of this imaging technique for CSC has not been fully evaluated but may lie in the documentation of very early fundus alterations in CSC. **b, c** Corresponding red-free photography (**b**) and SD-OCT image (**c**) of the same patient with a definite history of CSC.



Color version available online

5

Fundus Autofluorescence Imaging

The RPE has been thoroughly evaluated in different diseases and its role in the pathology of CSC seems to be indisputable [92–94]. This perception has been fortified by FAF findings. Due to the anatomic features of the RPE, detailed examination and imaging have been a challenge for many years. The introduction of FAF gave clinical

ophthalmologists a sophisticated tool for evaluating RPE changes (fig. 6). Excitation of the RPE, and specifically of lipofuscin, with light of specific wavelengths provokes a characteristic fluorescence [95–97]. Lipofuscin is a metabolite that develops during the depletion of aged outer photoreceptors and accumulates in the RPE [98]. Although lipofuscin, among many other fluorophores, has

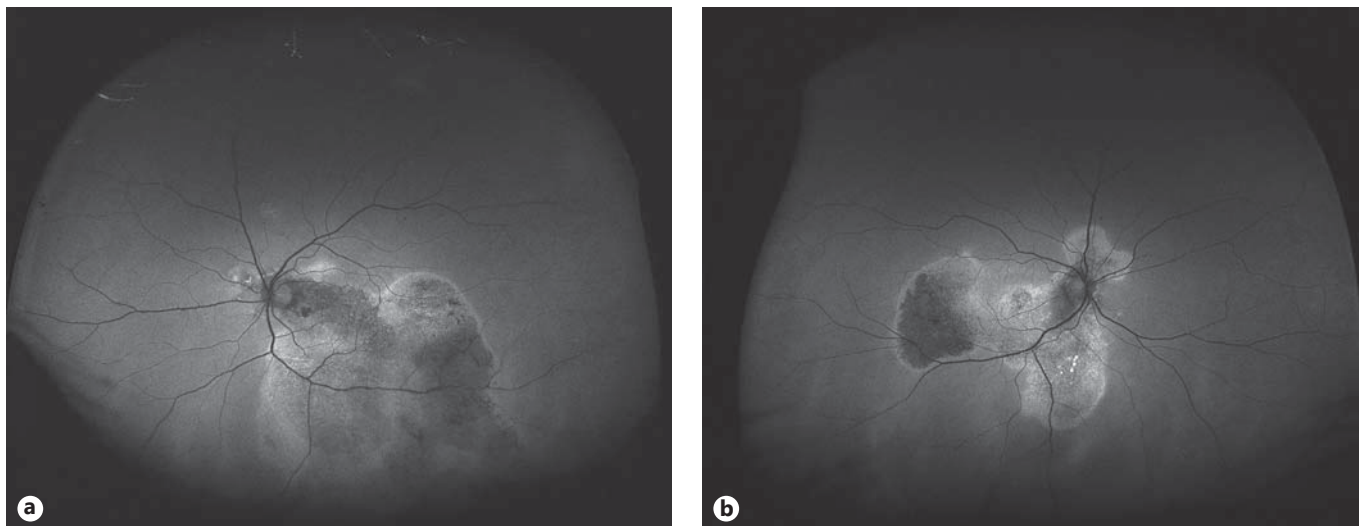


Fig. 6. Widefield FAF of the left (a) and right eye (b) of the same patient suffering from chronic CSC with typical tracks of pigment epithelial hypo- and hyperautofluorescence as a sign of long-lasting pigment epithelial lesions (hypoautofluorescence) mixed with acute pigment epithelial defects (hyperautofluorescence).

been supposed to have the strongest impact on retinal autofluorescence, newer studies could show that, particularly in CSC, even precursors of lipofuscin that had not already accumulated in the RPE and were still beneath the neurosensory retina might contribute to the autofluorescence observed in CSC [99].

Typical FAF patterns seen in acute CSC include increased autofluorescence at the site of leakage, probably indicating an increased activity of the RPE as a response to augmented volumes of subretinal fluid [100]. On the other hand, severe hypoautofluorescence – often associated with descending tracts that are surrounded by somewhat hyperautofluorescent borders as a sign of RPE dysfunction or atrophy – is appreciated particularly in chronic cases [99, 101].

Treatment

The course of the different pathogenic concepts of this disease is well reflected by the vast number of different treatment options that have been evaluated and proposed for CSC over time. These include observation and discontinuation of corticosteroids, laser approaches such as PDT, selective retinal therapy (SRT) and standard laser photocoagulation, intravitreal injections of anti-VEGF drugs and several systemic medications including carbonic anhydrase inhibitors, β -blockers and particularly aldosterone antagonists. However, even to-

day, no therapy of CSC may be deemed to be the gold standard, although some therapies provide better evidence for their efficiency than others; thus, of the large number of therapies suggested, only a few can be recommended.

As CSC is, in most cases, self-limiting with spontaneous resolution of the subretinal fluid, observation without additional treatment for the first 3 months is usually an appropriate first approach to handling this disease in patients without exogenous corticosteroid intake and no specific wish to accelerate the healing process. If possible, and after consulting the responsible physician, further management of risk factors includes discontinuation of steroids in patients taking these for other reasons, as well as reduction and avoidance of stress. In cases of chronicity or recurrence, however, other treatment options should be considered.

Photodynamic Therapy

Over the last couple of years, several groups have investigated a possible effect of PDT on CSC with beneficial results in terms of visual acuity and morphologic reconstitution [66, 80, 81, 102–105]. PDT is usually performed by administering 6 mg/m² verteporfin (Visudyne; Novartis Pharma) intravenously and subsequent activation of this dye by a laser light of 689 nm wavelength at a (full) fluence of 50 J/cm². The mechanism of action is postulated to include short-term choriocapillary hypoperfusion and long-term choroidal vascular

remodeling with subsequent reduction of vascular hyperpermeability and leakage [65, 102]. Some side effects including RPE alterations, CNV and choroidal ischemia have been reported [106]. In order to reduce these side effects, two modifications to conventional full-dose/fluence PDT have been proposed: (1) half-dose PDT in which the amount of verteporfin is reduced to 3 mg/m² with the same level of laser fluence (50 J/cm²) or (2) half-fluence PDT with the same concentration of verteporfin (6 mg/m²) but with only 25 J/cm² of laser fluence. Both approaches yielded favorable results in terms of visual acuity recovery as well as subretinal fluid resolution in a large number of studies with fewer side effects compared with conventional PDT [65, 81]. In respect of modality, significantly more studies have been carried out to evaluate half-dose PDT and only a few to investigate half-fluence PDT. Half-dose PDT is concordantly regarded as being just as effective as full-dose PDT and is therefore recommended in cases of recurrent or chronic CSC, particularly without severe PED [107–109]. Some authors even recommend it in acute cases with symptoms lasting less than 3 months [110]. Compared with laser photocoagulation, half-dose PDT may also facilitate an earlier resolution of macular detachment and the recovery of central retinal function [111]. One group studied even lower doses of verteporfin but obtained inferior results with one-third-dose PDT compared with half-dose PDT in terms of subretinal fluid resolution [112].

Selective Retinal Therapy

In contrast to standard laser photocoagulation, SRT is supposed to apply laser spots only to the RPE without risk of scotoma by damaging the neurosensory retina [113, 114]. SRT is performed with a Q-switched, frequency-doubled Nd:YLF laser beam with a wavelength of 527 nm [115]. This selective treatment of the RPE is meant to trigger the regeneration of the RPE and a long-term metabolic increase at the chorioretinal junction [116]. Three different studies and case series have been carried out to evaluate the effect of SRT in the setting of CSC [115, 117, 118]. However, all of them were conducted by the same group. A first case series in 2006, comprising 5 patients, showed promising preliminary results in terms of subretinal fluid regression with coexistent PED without any cases of RPE tears [115]. In the same year, another study with 27 patients could also show a very high subretinal fluid regression rate. It must be noted, though, that one third of these patients were treated in the first 3 months after the diagnosis of CSC. In general, these patients also

showed final results superior to those of the other study participants, but a tendency toward spontaneous regression cannot be evaluated [117]. In the third study, published in 2011, Klatt et al. [115] confirmed the previous results. Due to the low number of patients (n = 30) included, however, a larger prospective clinical trial is warranted to prove these findings. SRT is currently not commercially available, nor do the results so far prove sufficient effects in the treatment of CSC; therefore, SRT may be a promising treatment option in the future, but further studies are needed.

Laser Photocoagulation

As in other retinal diseases such as clinically significant macular edema in diabetic patients, laser spots are administered to focal leakages that have been identified by FA. The exact mechanism of laser photocoagulation is not known but may be based on sealing of leaking vessels as well as activation of the pumping function of the RPE. Several studies have been carried out to evaluate the role of laser photocoagulation in CSC and good evidence exists that photocoagulation leads to faster resolution of subretinal fluid [68, 103, 119, 120]. However, several studies showed that, in spite of faster subretinal fluid resolution, no significant impact on final visual acuity can be expected [13, 119, 121]. Unlike SRT, standard photocoagulation has also been proposed for chronic cases of CSC and diffuse retinal pigment epitheliopathy but does not have any effect on bullous retinal detachment, a rare form of CSC [27, 122]. Laser photocoagulation, however, needs thorough planning and careful execution and no laser spots should be applied to very central lesions; furthermore, long-term follow-up is necessary to detect cases of CNV, a rare but severe side effect.

Although laser photocoagulation has proved its general potency in CSC, possible side effects, particularly scotoma and the development of CNV, must be considered; therefore, laser photocoagulation should be mainly discussed for patients with long-standing CSC, possibly refractory to other treatment approaches, or with a history of CSC in the fellow eye with an unfavorable visual acuity outcome.

Carbonic Anhydrase Inhibitors

Prescription of oral acetazolamide is a widespread treatment option in CSC in spite of poor evidence in terms of outcome. Only one smaller case study and one prospective nonrandomized trial have been carried out to evaluate the influence of acetazolamide on the course of

CSC. While Gonzalez [123] could show a reduction of metamorphopsia and at least stabilization of visual acuity in a few patients, Pikkell et al. [124] could show that acetazolamide may shorten the subjective as well as objective time of clinical resolution but has no influence on final visual acuity prognosis or recurrence rates.

Mineralocorticoid Receptor Antagonists

The exact mode of action of glucocorticoids in the pathogenesis of CSC is still not known, even though their prominent role is beyond controversy. It therefore seems obvious that one should search for treatment options targeting this track. Glucocorticoids bind to their receptor but also to the mineralocorticoid receptor (MR) that belongs to the same family. MR are present in the kidney and the vasculature and were recently demonstrated to be expressed in different cell types of the neurosensory retina [125]. Based on the observation of CSC aggravation by glucocorticoids and the known affinity of glucocorticoids for MR, Zhao et al. [126] hypothesized a potential inappropriate/excessive binding of glucocorticoids to MR and proved their assumption in a rat model. Rat eyes received intravitreal injections of the glucocorticoid corticosterone. OCT before and after injection revealed significantly increased choroidal thickening but no thickening of retinal vessels after 24 h, a finding similar to CSC. The effect of this glucocorticoid may have been triggered by glucocorticoid receptors or MR; therefore, other rats received intravitreal injections of aldosterone, which specifically binds to MR. In these rats, the same effects in terms of choroidal thickening were noticed and therefore an important role of MR deduced. Hence, treatment with an MR antagonist was proposed, and 2 patients with chronic nonresolved CSC were treated with oral eplerenone for 5 weeks. A rapid resolution of the retinal detachment and choroidal vasodilation as well as improvement in visual acuity was observed in these 2 patients, and consequently a larger study followed. This nonrandomized pilot study included 13 patients with chronic CSC (>3 months) treated with 25 mg/day of oral eplerenone for a week followed by 50 mg/day for 1 month or 3 months; it was published in 2013 by Bousquet et al. [127]. All patients showed a significant decrease in central macular thickness at 1 month and 3 months under eplerenone treatment. Overall, not only a decrease in subretinal fluid but also an improvement in visual acuity was observed [127]. Nevertheless, further randomized trials are necessary to prove these conclusions.

Conclusions

CSC is a clinical picture that ophthalmologists are frequently confronted with. The therapeutic options are limited, although observation, reduction of stress and discontinuation of corticosteroids, where applicable, are often sufficient to overcome visual deterioration. Still, 40–50% of patients suffer from recurrent forms of CSC, and as for chronic CSC patients, less favorable results in terms of visual acuity and morphologic reconstitution can be expected for these patients. In these cases, the only therapies with good evidence for their efficiency are laser photocoagulation and PDT. Laser photocoagulation carries a risk of severe side effects including CNV and scotoma; PDT shows a lower risk of these but is associated with a high financial burden and therefore not available for every patient.

The first results of a study investigating MR antagonists are promising and agree with our own observations on CSC patients treated with spironolactone, another MR antagonist. MR antagonists such as eplerenone or spironolactone are relatively old drugs mainly used for cardiovascular conditions such as hypertension. The most common side effect is increased urinary frequency; other side effects are rare but include dry skin, rashes and gynecomastia.

Although further studies are needed to prove the value of MR antagonists in the treatment of CSC, from our perspective – against the background of the relatively small side effects of MR antagonists and very limited treatment options – it seems to be appropriate to recommend MR antagonists for patients suffering from CSC without signs of resolution within the first 8–12 weeks.

Disclosure Statement

None.

References

- 1 von Graefe A: Über zentrale rezidivierende Retinitis. *Graefes Arch Clin Exp Ophthalmol* 1866;12:211–215.
- 2 Horniker E: Über eine Form von zentraler Retinitis auf angioneurotischer Grundlage (Retinitis centralis angioneurotica). *Graefes Arch Clin Exp Ophthalmol* 1929;123:286–360.
- 3 Horniker E: Su di una forma retinite centrale di origine vasoneurotica (retinite central capillaro spastica). *Ann Ottal* 1927;55:578–600.
- 4 Gifford SR, Marquardt G: Central angiospastic retinopathy. *Arch Ophthalmol* 1939;21:211–228.

- 5 Maumenee AE: Macular diseases: clinical manifestations. *Trans Am Acad Ophthalmol Otolaryngol* 1965;69:605–613.
- 6 Gass JD: Pathogenesis of disciform detachment of the neuroepithelium. *Am J Ophthalmol* 1967;63(suppl):1–139.
- 7 Meyerle CB, Spaide RF: Central serous chorioretinopathy; in Albert DM, Miller JW, Azar DT, Blodi BA (eds): *Albert and Jakobiec's Principles and Practice of Ophthalmology*. Philadelphia, Saunders, 2008, vol 3, pp 1871–1880.
- 8 Wang M, Munch IC, Hasler PW, Prünke C, Larsen M: Central serous chorioretinopathy. *Acta Ophthalmol* 2008;86:126–145.
- 9 Spitznas M, Huke J: Number, shape, and topography of leakage points in acute type I central serous retinopathy. *Graefes Arch Clin Exp Ophthalmol* 1987;225:437–440.
- 10 Castro-Correia J, Coutinho MF, Rosas V, Maia J: Long-term follow-up of central serous retinopathy in 150 patients. *Doc Ophthalmol* 1992;81:379–386.
- 11 Wang M, Sander B, la Cour M, Larsen M: Clinical characteristics of subretinal deposits in central serous chorioretinopathy. *Acta Ophthalmol Scand* 2005;83:691–696.
- 12 Tittl MK, Spaide RF, Wong D, Pilotto E, Yannuzzi LA, Fisher YL, Freund B, Guyer DR, Slakter JS, Sorenson JA: Systemic findings associated with central serous chorioretinopathy. *Am J Ophthalmol* 1999;128:63–68.
- 13 Gilbert CM, Owens SL, Smith PD, Fine SL: Long-term follow-up of central serous chorioretinopathy. *Br J Ophthalmol* 1984;68:815–820.
- 14 Jamil AZ, Mirza KA, Qazi ZU, Iqbal W, Khaliq J, Fawad-ur R, Ahmed A: Features of central serous chorioretinopathy presenting at a tertiary care hospital in Lahore. *J Pak Med Assoc* 2013;63:478–482.
- 15 Kitzmann AS, Pulido JS, Diehl NN, Hodge DO, Burke JP: The incidence of central serous chorioretinopathy in Olmsted County, Minnesota, 1980–2002. *Ophthalmology* 2008;115:169–173.
- 16 Spaide RF: Central serous chorioretinopathy; in Kriegelstein GK, Weinreb RN (eds): *Medical Retina*. Heidelberg, Springer, 2005, pp 77–95.
- 17 Spaide RF, Campeas L, Haas A, Yannuzzi LA, Fisher YL, Guyer DR, Slakter JS, Sorenson JA, Orlock DA: Central serous chorioretinopathy in younger and older adults. *Ophthalmology* 1996;103:2070–2079, discussion 2079–2080.
- 18 Tsai DC, Chen SJ, Huang CC, Chou P, Chung CM, Huang PH, Lin SJ, Chen JW, Chen TJ, Leu HB, Chan WL: Epidemiology of idiopathic central serous chorioretinopathy in Taiwan, 2001–2006: a population-based study. *PLoS One* 2013;8:e66858.
- 19 Gäckle HC, Lang GE, Freissler KA, Lang GK: Central serous chorioretinopathy: clinical, fluorescein angiography and demographic aspects (in German). *Ophthalmologie* 1998;95:529–533.
- 20 Kim YC, Kim SD, Kim KS: A case of idiopathic central serous chorioretinopathy in a 12-year-old male treated with bevacizumab. *Korean J Ophthalmol* 2012;26:391–393.
- 21 Alwassia AA, Adhi M, Duker JS: Bilateral simultaneous central serous chorioretinopathy in a teenage girl with systemic arterial hypertension. *Int Ophthalmol* 2013;33:79–82.
- 22 Chan WM, Lai TY, Tano Y, Liu DT, Li KK, Lam DS: Photodynamic therapy in macular diseases of Asian populations: when East meets West. *Jpn J Ophthalmol* 2006;50:161–169.
- 23 Yannuzzi LA: Type-A behavior and central serous chorioretinopathy. *Retina* 1987;7:111–131.
- 24 Balo KP, Mihluedo H: Idiopathic central serous chorioretinopathy: two case reports observed in Togo (in French). *Med Trop (Mars)* 1996;56:381–383.
- 25 Katsimpris JM, Pournaras CJ, Sehgelmeble CW, Petropoulos IK: Severe bilateral central serous chorioretinopathy in a black patient: 16 years follow-up. *Graefes Arch Clin Exp Ophthalmol* 2007;245:460–463.
- 26 Desai UR, Alhalel AA, Campen TJ, Schiffman RM, Edwards PA, Jacobsen GR: Central serous chorioretinopathy in African Americans. *J Natl Med Assoc* 2003;95:553–559.
- 27 Nicholson B, Noble J, Forooghian F, Meyerle C: Central serous chorioretinopathy: update on pathophysiology and treatment. *Surv Ophthalmol* 2013;58:103–126.
- 28 Uyama M, Matsunaga H, Matsubara T, Fukushima I, Takahashi K, Nishimura T: Indocyanine green angiography and pathophysiology of multifocal posterior pigment epitheliopathy. *Retina* 1999;19:12–21.
- 29 Yannuzzi LA: Central serous chorioretinopathy: a personal perspective. *Am J Ophthalmol* 2010;149:361–363.
- 30 Okushiba U, Takeda M: Study of choroidal vascular lesions in central serous chorioretinopathy using indocyanine green angiography (in Japanese). *Nihon Ganka Gakkai Zasshi* 1997;101:74–82.
- 31 Prünke C, Flammer J: Choroidal capillary and venous congestion in central serous chorioretinopathy. *Am J Ophthalmol* 1996;121:26–34.
- 32 Spaide RF, Hall L, Haas A, Campeas L, Yannuzzi LA, Fisher YL, Guyer DR, Slakter JS, Sorenson JA, Orlock DA: Indocyanine green videoangiography of older patients with central serous chorioretinopathy. *Retina* 1996;16:203–213.
- 33 Guyer DR, Yannuzzi LA, Slakter JS, Sorenson JA, Ho A, Orlock D: Digital indocyanine green videoangiography of central serous chorioretinopathy. *Arch Ophthalmol* 1994;112:1057–1062.
- 34 Hayashi K, Hasegawa Y, Tokoro T: Indocyanine green angiography of central serous chorioretinopathy. *Int Ophthalmol* 1986;9:37–41.
- 35 Scheider A, Nasemann JE, Lund OE: Fluorescein and indocyanine green angiographies of central serous choroidopathy by scanning laser ophthalmoscopy. *Am J Ophthalmol* 1993;115:50–56.
- 36 Hussain D, Gass JD: Idiopathic central serous chorioretinopathy. *Ind J Ophthalmol* 1998;46:131–137.
- 37 Slakter JS, Yannuzzi LA, Guyer DR, Sorenson JA, Orlock DA: Indocyanine-green angiography. *Curr Opin Ophthalmol* 1995;6:25–32.
- 38 Gupta V, Gupta P, Dogra MR, Gupta A: Spontaneous closure of retinal pigment epithelium micropip in the natural course of central serous chorioretinopathy. *Eye (Lond)* 2010;24:595–599.
- 39 Goldstein BG, Pavan PR: 'Blow-outs' in the retinal pigment epithelium. *Br J Ophthalmol* 1987;71:676–681.
- 40 Piccolino FC, Borgia L: Central serous chorioretinopathy and indocyanine green angiography. *Retina* 1994;14:231–242.
- 41 Piccolino FC, Borgia L, Zinicola E, Zingirian M: Indocyanine green angiographic findings in central serous chorioretinopathy. *Eye (Lond)* 1995;9:324–332.
- 42 Spitznas M: Pathogenesis of central serous retinopathy: a new working hypothesis. *Graefes Arch Clin Exp Ophthalmol* 1986;224:321–324.
- 43 Bouzas EA, Karadimas P, Pournaras CJ: Central serous chorioretinopathy and glucocorticoids. *Surv Ophthalmol* 2002;47:431–448.
- 44 Haimovici R, Koh S, Gagnon DR, Lehrfeld T, Wellik S: Risk factors for central serous chorioretinopathy: a case-control study. *Ophthalmology* 2004;111:244–249.
- 45 Sun J, Tan J, Wang Z, Yang H, Zhu X, Li L: Effect of catecholamine on central serous chorioretinopathy. *J Huazhong Univ Sci Technol Med Sci* 2003;23:313–316.
- 46 Thoelen AM, Bernasconi PP, Schmid C, Messmer EP: Central serous chorioretinopathy associated with a carcinoma of the adrenal cortex. *Retina* 2000;20:98–99.
- 47 Loo JL, Lee SY, Ang CL: Can long-term corticosteroids lead to blindness? A case series of central serous chorioretinopathy induced by corticosteroids. *Ann Acad Med Singapore* 2006;35:496–499.
- 48 Polak BC, Baarsma GS, Snyers B: Diffuse retinal pigment epitheliopathy complicating systemic corticosteroid treatment. *Br J Ophthalmol* 1995;79:922–925.
- 49 Browning DJ: Nadolol in the treatment of central serous retinopathy. *Am J Ophthalmol* 1993;116:770–771.
- 50 Bouzas EA, Scott MH, Mastorakos G, Chrousos GP, Kaiser-Kupfer MI: Central serous chorioretinopathy in endogenous hypercortisolism. *Arch Ophthalmol* 1993;111:1229–1233.
- 51 Garg SP, Dada T, Talwar D, Biswas NR: Endogenous cortisol profile in patients with central serous chorioretinopathy. *Br J Ophthalmol* 1997;81:962–964.
- 52 Barnes PJ: Corticosteroid effects on cell signalling. *Eur Respir J* 2006;27:413–426.
- 53 Sakaue M, Hoffman BB: Glucocorticoids induce transcription and expression of the alpha 1B adrenergic receptor gene in DTT1 MF-2 smooth muscle cells. *J Clin Invest* 1991;88:385–389.

- 54 Oikarinen AI, Uitto J, Oikarinen J: Glucocorticoid action on connective tissue: from molecular mechanisms to clinical practice. *Med Biol* 1986;64:221–230.
- 55 Imasawa M, Ohshiro T, Gotoh T, Imai M, Iijima H: Central serous chorioretinopathy following vitrectomy with intravitreal triamcinolone acetonide for diabetic macular oedema. *Acta Ophthalmol Scand* 2005;83:132–133.
- 56 Bauml CR, Martidis A, Truong SN: Central serous chorioretinopathy associated with periocular corticosteroid injection treatment for HLA-B27-associated iritis. *Arch Ophthalmol* 2004;122:926–928.
- 57 Friedman M, Thoresen CE, Gill JJ, Ulmer D, Powell LH, Price VA, Brown B, Thompson L, Rabin DD, Breall WS, et al: Alteration of type A behavior and its effect on cardiac recurrences in post myocardial infarction patients: summary results of the recurrent coronary prevention project. *Am Heart J* 1986;112:653–665.
- 58 Errera MH, Kohly RP, da Cruz L: Pregnancy-associated retinal diseases and their management. *Surv Ophthalmol* 2013;58:127–142.
- 59 Casella AM, Berbel RF, Bressanim GL, Malaguido MR, Cardillo JA: *Helicobacter pylori* as a potential target for the treatment of central serous chorioretinopathy. *Clinics (Sao Paulo)* 2012;67:1047–1052.
- 60 Eom Y, Oh J, Kim SW, Huh K: Systemic factors associated with central serous chorioretinopathy in Koreans. *Korean J Ophthalmol* 2012;26:260–264.
- 61 Weenink AC, Borsje RA, Oosterhuis JA: Familial chronic central serous chorioretinopathy. *Ophthalmologica* 2001;215:183–187.
- 62 Spahn C, Wiek J, Burger T, Hansen L: Psychosomatic aspects in patients with central serous chorioretinopathy. *Br J Ophthalmol* 2003;87:704–708.
- 63 Fawzi AA, Holland GN, Kreiger AE, Heckenlively JR, Arroyo JG, Cunningham ET Jr: Central serous chorioretinopathy after solid organ transplantation. *Ophthalmology* 2006;113:805–813e5.
- 64 Kanski J, Bowling B: *Clinical Ophthalmology: A Systemic Approach*. London, Elsevier, 2011.
- 65 Karakus SH, Basarir B, Pinarci EY, Kirandi EU, Demirok A: Long-term results of half-dose photodynamic therapy for chronic central serous chorioretinopathy with contrast sensitivity changes. *Eye (Lond)* 2013;27:612–620.
- 66 Lim SH, Chang W, Sagong M: Efficacy of half-fluence photodynamic therapy depending on the degree of choroidal hyperpermeability in chronic central serous chorioretinopathy. *Eye (Lond)* 2013;27:353–362.
- 67 Chen SN, Hwang JF, Tseng LF, Lin CJ: Sub-threshold diode micropulse photocoagulation for the treatment of chronic central serous chorioretinopathy with juxtafoveal leakage. *Ophthalmology* 2008;115:2229–2234.
- 68 Ficker L, Vafidis G, While A, Leaver P: Long-term follow-up of a prospective trial of argon laser photocoagulation in the treatment of central serous retinopathy. *Br J Ophthalmol* 1988;72:829–834.
- 69 Fok AC, Chan PP, Lam DS, Lai TY: Risk factors for recurrence of serous macular detachment in untreated patients with central serous chorioretinopathy. *Ophthalmic Res* 2011;46:160–163.
- 70 Gueudry J, Genevois O, Adam PA, Muraine M, Brasseur G: Retinal pigment epithelium tear following central serous chorioretinopathy. *Acta Ophthalmol* 2009;87:691–693.
- 71 Ishida Y, Kato T, Minamoto A, Yokoyama T, Jian K, Mishima HK: Retinal pigment epithelial tear in a patient with central serous chorioretinopathy treated with corticosteroids. *Retina* 2004;24:633–636.
- 72 Akiyama K, Kawamura M, Ogata T, Tanaka E: Retinal vascular loss in idiopathic central serous chorioretinopathy with bullous retinal detachment. *Ophthalmology* 1987;94:1605–1609.
- 73 Gass JD: Bullous retinal detachment: an unusual manifestation of idiopathic central serous choroidopathy. *Am J Ophthalmol* 1973;75:810–821.
- 74 Friberg TR, Eller AW: Serous retinal detachment resembling central serous chorioretinopathy following organ transplantation. *Graefes Arch Clin Exp Ophthalmol* 1990;28:305–309.
- 75 Shahin MM: Angiographic characteristics of central serous chorioretinopathy in an Egyptian population. *Int J Ophthalmol* 2013;6:342–345.
- 76 Yanuzzi L: *The Retinal Atlas*. Philadelphia, Saunders, 2010.
- 77 Kitaya N, Nagaoka T, Hikichi T, Sugawara R, Fukui K, Ishiko S, Yoshida A: Features of abnormal choroidal circulation in central serous chorioretinopathy. *Br J Ophthalmol* 2003;87:709–712.
- 78 Stanga PE, Lim JJ, Hamilton P: Indocyanine green angiography in chorioretinal diseases: indications and interpretation – an evidence-based update. *Ophthalmology* 2003;110:15–21, quiz 22–23.
- 79 Shiraki K, Moriwaki M, Matsumoto M, Yanagihara N, Yasunari T, Miki T: Long-term follow-up of severe central serous chorioretinopathy using indocyanine green angiography. *Int Ophthalmol* 1997;21:245–253.
- 80 Smretschnig E, Ansari-Shahrezaei S, Hagen S, Glittenberg C, Krebs I, Binder S: Half-fluence photodynamic therapy in chronic central serous chorioretinopathy. *Retina* 2013;33:316–323.
- 81 Shin JY, Woo SJ, Yu HG, Park KH: Comparison of efficacy and safety between half-fluence and full-fluence photodynamic therapy for chronic central serous chorioretinopathy. *Retina* 2011;31:119–126.
- 82 Hee MR, Puliafito CA, Wong C, Reichel E, Duker JS, Schuman JS, Swanson EA, Fujimoto JG: Optical coherence tomography of central serous chorioretinopathy. *Am J Ophthalmol* 1995;120:65–74.
- 83 Yang L, Jonas JB, Wei W: Choroidal vessel diameter in central serous chorioretinopathy. *Acta Ophthalmol* 2013;91:e358–e362.
- 84 Ahn SE, Oh J, Oh JH, Oh IK, Kim SW, Huh K: Three-dimensional configuration of subretinal fluid in central serous chorioretinopathy. *Invest Ophthalmol Vis Sci* 2013;54:5944–5952.
- 85 Imamura Y, Fujiwara T, Margolis R, Spaide RF: Enhanced depth imaging optical coherence tomography of the choroid in central serous chorioretinopathy. *Retina* 2009;29:1469–1473.
- 86 Maruko I, Iida T, Sugano Y, Ojima A, Sekiryu T: Subfoveal choroidal thickness in fellow eyes of patients with central serous chorioretinopathy. *Retina* 2011;31:1603–1608.
- 87 Brandl C, Helbig H, Gamulescu MA: Choroidal thickness measurements during central serous chorioretinopathy treatment. *Int Ophthalmol* 2014;34:7–13.
- 88 Jirattanasopa P, Ooto S, Tsujikawa A, Yamashiro K, Hangai M, Hirata M, Matsumoto A, Yoshimura N: Assessment of macular choroidal thickness by optical coherence tomography and angiographic changes in central serous chorioretinopathy. *Ophthalmology* 2012;119:1666–1678.
- 89 Matsumoto H, Kishi S, Otani T, Sato T: Elongation of photoreceptor outer segment in central serous chorioretinopathy. *Am J Ophthalmol* 2008;145:162–168.
- 90 Kim SW, Oh J, Huh K: Correlations among various functional and morphological tests in resolved central serous chorioretinopathy. *Br J Ophthalmol* 2012;96:350–355.
- 91 Ojima Y, Hangai M, Sasahara M, Gotoh N, Inoue R, Yasuno Y, Makita S, Yatagai T, Tsujikawa A, Yoshimura N: Three-dimensional imaging of the foveal photoreceptor layer in central serous chorioretinopathy using high-speed optical coherence tomography. *Ophthalmology* 2007;114:2197–2207.
- 92 Almeida A, Kaliki S, Shields CL: Autofluorescence of intraocular tumours. *Curr Opin Ophthalmol* 2013;24:222–232.
- 93 Hopkins J, Walsh A, Chakravarthy U: Fundus autofluorescence in age-related macular degeneration: an epiphenomenon? *Invest Ophthalmol Vis Sci* 2006;47:2269–2271.
- 94 Göbel AP, Fleckenstein M, Schmitz-Valckenberg S, Brinkmann CK, Holz FG: Imaging geographic atrophy in age-related macular degeneration. *Ophthalmologica* 2011;226:182–190.
- 95 Feeney L: Lipofuscin and melanin of human retinal pigment epithelium: fluorescence, enzyme cytochemical, and ultrastructural studies. *Invest Ophthalmol Vis Sci* 1978;17:583–600.
- 96 Delori FC, Dorey CK, Staurenghi G, Arend O, Goger DG, Weiter JJ: In vivo fluorescence of the ocular fundus exhibits retinal pigment epithelium lipofuscin characteristics. *Invest Ophthalmol Vis Sci* 1995;36:718–729.

- 97 Delori FC, Staurengi G, Arend O, Dorey CK, Goger DG, Weiter JJ: In vivo measurement of lipofuscin in Stargardt's disease – fundus flavimaculatus. *Invest Ophthalmol Vis Sci* 1995;36:2327–2331.
- 98 Wolf G: Lipofuscin, the age pigment. *Nutr Rev* 1993;51:205–206.
- 99 Spaide RF, Klancknik JM Jr: Fundus autofluorescence and central serous chorioretinopathy. *Ophthalmology* 2005;112:825–833.
- 100 von Ruckmann A, Fitzke FW, Fan J, Halfyard A, Bird AC: Abnormalities of fundus autofluorescence in central serous retinopathy. *Am J Ophthalmol* 2002;133:780–786.
- 101 Eandi CM, Ober M, Iranmanesh R, Peiretti E, Yannuzzi LA: Acute central serous chorioretinopathy and fundus autofluorescence. *Retina* 2005;25:989–993.
- 102 Chan WM, Lam DS, Lai TY, Tam BS, Liu DT, Chan CK: Choroidal vascular remodeling in central serous chorioretinopathy after indocyanine green guided photodynamic therapy with verteporfin: a novel treatment at the primary disease level. *Br J Ophthalmol* 2003;87:1453–1458.
- 103 Cardillo Piccolino F, Eandi CM, Ventre L, Rigault de la Longrais RC, Grignolo FM: Photodynamic therapy for chronic central serous chorioretinopathy. *Retina* 2003;23:752–763.
- 104 Taban M, Boyer DS, Thomas EL, Taban M: Chronic central serous chorioretinopathy: photodynamic therapy. *Am J Ophthalmol* 2004;137:1073–1080.
- 105 Ober MD, Yannuzzi LA, Do DV, Spaide RF, Bressler NM, Jampol LM, Angelilli A, Eandi CM, Lyon AT: Photodynamic therapy for focal retinal pigment epithelial leaks secondary to central serous chorioretinopathy. *Ophthalmology* 2005;112:2088–2094.
- 106 Koytak A, Erol K, Coskun E, Asik N, Öztürk H, Öztürk Y: Fluorescein angiography-guided photodynamic therapy with half-dose verteporfin for chronic central serous chorioretinopathy. *Retina* 2010;30:1698–1703.
- 107 Lai TY, Chan WM, Li H, Lai RY, Liu DT, Lam DS: Safety enhanced photodynamic therapy with half dose verteporfin for chronic central serous chorioretinopathy: a short term pilot study. *Br J Ophthalmol* 2006;90:869–874.
- 108 Chan WM, Lai TY, Lai RY, Tang EW, Liu DT, Lam DS: Safety enhanced photodynamic therapy for chronic central serous chorioretinopathy: one-year results of a prospective study. *Retina* 2008;28:85–93.
- 109 Maruko I, Iida T, Sugano Y, Furuta M, Sekiryu T: One-year choroidal thickness results after photodynamic therapy for central serous chorioretinopathy. *Retina* 2011;31:1921–1927.
- 110 Chan WM, Lai TY, Lai RY, Liu DT, Lam DS: Half-dose verteporfin photodynamic therapy for acute central serous chorioretinopathy: one-year results of a randomized controlled trial. *Ophthalmology* 2008;115:1756–1765.
- 111 Lim JW, Kang SW, Kim YT, Chung SE, Lee SW: Comparative study of patients with central serous chorioretinopathy undergoing focal laser photocoagulation or photodynamic therapy. *Br J Ophthalmol* 2011;95:514–517.
- 112 Uetani R, Ito Y, Oiwa K, Ishikawa K, Terasaki H: Half-dose vs one-third-dose photodynamic therapy for chronic central serous chorioretinopathy. *Eye (Lond)* 2012;26:640–649.
- 113 Brinkmann R, Roeder J, Birngruber R: Selective retina therapy (SRT): a review on methods, techniques, preclinical and first clinical results. *Bull Soc Belge Ophthalmol* 2006;302:51–69.
- 114 Roeder J, Michaud NA, Flotte TJ, Birngruber R: Response of the retinal pigment epithelium to selective photocoagulation. *Arch Ophthalmol* 1992;110:1786–1792.
- 115 Klatt C, Saeger M, Oppermann T, Pörksen E, Treumer F, Hillenkamp J, Fritzer E, Brinkmann R, Birngruber R, Roeder J: Selective retina therapy for acute central serous chorioretinopathy. *Br J Ophthalmol* 2011;95:83–88.
- 116 Brinkmann R, Schüle G, Neumann J, Framme C, Pörksen E, Elsner H, Theisen-Kunde D, Roeder J, Birngruber R: Selective retina therapy: methods, technique, and online dosimetry (in German). *Ophthalmologe* 2006;103:839–849.
- 117 Elsner H, Pörksen E, Klatt C, Bunse A, Theisen-Kunde D, Brinkmann R, Birngruber R, Laqua H, Roeder J: Selective retina therapy in patients with central serous chorioretinopathy. *Graefes Arch Clin Exp Ophthalmol* 2006;244:1638–1645.
- 118 Klatt C, Elsner H, Pörksen E, Brinkmann R, Bunse A, Birngruber R, Roeder J: Selective retina therapy in central serous chorioretinopathy with detachment of the pigmentary epithelium (in German). *Ophthalmologe* 2006;103:850–855.
- 119 Leaver P, Williams C: Argon laser photocoagulation in the treatment of central serous retinopathy. *Br J Ophthalmol* 1979;63:674–677.
- 120 Robertson DM, Ilstrup D: Direct, indirect, and sham laser photocoagulation in the management of central serous chorioretinopathy. *Am J Ophthalmol* 1983;95:457–466.
- 121 Yap EY, Robertson DM: The long-term outcome of central serous chorioretinopathy. *Arch Ophthalmol* 1996;114:689–692.
- 122 Yannuzzi LA, Slakter JS, Kaufman SR, Gupta K: Laser treatment of diffuse retinal pigment epitheliopathy. *Eur J Ophthalmol* 1992;2:103–114.
- 123 Gonzalez C: Serous retinal detachment: value of acetazolamide (in French). *J Fr Ophthalmol* 1992;15:529–536.
- 124 Pikkell J, Beiran I, Ophir A, Miller B: Acetazolamide for central serous retinopathy. *Ophthalmology* 2002;109:1723–1725.
- 125 Zhao M, Valamanesh F, Celerier I, Savoldelli M, Jonet L, Jeanny JC, Jaisser F, Farman N, Behar-Cohen F: The neuroretina is a novel mineralocorticoid target: aldosterone up-regulates ion and water channels in Müller glial cells. *FASEB J* 2010;24:3405–3415.
- 126 Zhao M, Celerier I, Bousquet E, Jeanny JC, Jonet L, Savoldelli M, Offret O, Curan A, Farman N, Jaisser F, Behar-Cohen F: Mineralocorticoid receptor is involved in rat and human ocular chorioretinopathy. *J Clin Invest* 2012;122:2672–2679.
- 127 Bousquet E, Beydoun T, Zhao M, Hassan L, Offret O, Behar-Cohen F: Mineralocorticoid receptor antagonism in the treatment of chronic central serous chorioretinopathy: a pilot study. *Retina* 2013;33:2096–2102.