

# Cervical Cancer, Version 3.2019

Wui-Jin Koh, MD/Chair<sup>1\*</sup>; Nadeem R. Abu-Rustum, MD<sup>2\*</sup>; Sarah Bean, MD<sup>3</sup>; Kristin Bradley, MD<sup>4</sup>; Susana M. Campos, MD, MPH, MS<sup>5</sup>; Kathleen R. Cho, MD<sup>6</sup>; Hye Sook Chon, MD<sup>7</sup>; Christina Chu, MD<sup>8</sup>; Rachel Clark<sup>9</sup>; David Cohn, MD<sup>10</sup>; Marta Ann Crispens, MD<sup>11</sup>; Shari Damast, MD<sup>12</sup>; Oliver Dorigo, MD, PhD<sup>13</sup>; Patricia J. Eifel, MD<sup>14</sup>; Christine M. Fisher, MD, MPH<sup>15</sup>; Peter Frederick, MD<sup>16</sup>; David K. Gaffney, MD, PhD<sup>17</sup>; Ernest Han, MD, PhD<sup>18</sup>; Warner K. Huh, MD<sup>19</sup>; John R. Lurain III, MD<sup>20</sup>; Andrea Mariani, MD<sup>21</sup>; David Mutch, MD<sup>22</sup>; Christa Nagel, MD<sup>23</sup>; Larissa Nekhlyudov, MD, MPH<sup>5</sup>; Amanda Nickles Fader, MD<sup>24</sup>; Steven W. Remmenga, MD<sup>25</sup>; R. Kevin Reynolds, MD<sup>6</sup>; Todd Tillmanns, MD<sup>26</sup>; Stefanie Ueda, MD<sup>27</sup>; Emily Wyse<sup>28</sup>; Catheryn M. Yashar, MD<sup>29</sup>; Nicole R. McMillian, MS, CHES<sup>30</sup>; and Jillian L. Scavone, PhD<sup>30</sup>

## ABSTRACT

Cervical cancer is a malignant epithelial tumor that forms in the uterine cervix. Most cases of cervical cancer are preventable through human papilloma virus (HPV) vaccination, routine screening, and treatment of precancerous lesions. However, due to inadequate screening protocols in many regions of the world, cervical cancer remains the fourth-most common cancer in women globally. The complete NCCN Guidelines for Cervical Cancer provide recommendations for the diagnosis, evaluation, and treatment of cervical cancer. This manuscript discusses guiding principles for the workup, staging, and treatment of early stage and locally advanced cervical cancer, as well as evidence for these recommendations. For recommendations regarding treatment of recurrent or metastatic disease, please see the full guidelines on NCCN.org.

*J Natl Comp Canc Netw* 2019;17(1):64–84  
doi: 10.6004/jnccn.2019.0001

## NCCN CATEGORIES OF EVIDENCE AND CONSENSUS

**Category 1:** Based upon high-level evidence, there is uniform NCCN consensus that the intervention is appropriate.

**Category 2A:** Based upon lower-level evidence, there is uniform NCCN consensus that the intervention is appropriate.

**Category 2B:** Based upon lower-level evidence, there is NCCN consensus that the intervention is appropriate.

**Category 3:** Based upon any level of evidence, there is major NCCN disagreement that the intervention is appropriate.

**All recommendations are category 2A unless otherwise noted.**

**Clinical trials:** NCCN believes that the best management of any patient with cancer is in a clinical trial. Participation in clinical trials is especially encouraged.

## PLEASE NOTE

The NCCN Clinical Practice Guidelines in Oncology (NCCN Guidelines<sup>®</sup>) are a statement of evidence and consensus of the authors regarding their views of currently accepted approaches to treatment. Any clinician seeking to apply or consult the NCCN Guidelines is expected to use independent medical judgment in the context of individual clinical circumstances to determine any patient's care or treatment. The National Comprehensive Cancer Network<sup>®</sup> (NCCN<sup>®</sup>) makes no representations or warranties of any kind regarding their content, use, or application and disclaims any responsibility for their applications or use in any way.

**The complete NCCN Guidelines for Cervical Cancer are not printed in this issue of JNCCN but can be accessed online at NCCN.org.**

© National Comprehensive Cancer Network, Inc. 2019. All rights reserved. The NCCN Guidelines and the illustrations herein may not be reproduced in any form without the express written permission of NCCN.

## Disclosures for the NCCN Cervical Cancer Panel

At the beginning of each NCCN Guidelines Panel meeting, panel members review all potential conflicts of interest. NCCN, in keeping with its commitment to public transparency, publishes these disclosures for panel members, staff, and NCCN itself.

Individual disclosures for the NCCN Cervical Cancer Panel members can be found on page 84. (The most recent version of these guidelines and accompanying disclosures are available on the NCCN website at NCCN.org.)

**The complete and most recent version of these guidelines are available free of charge at NCCN.org**

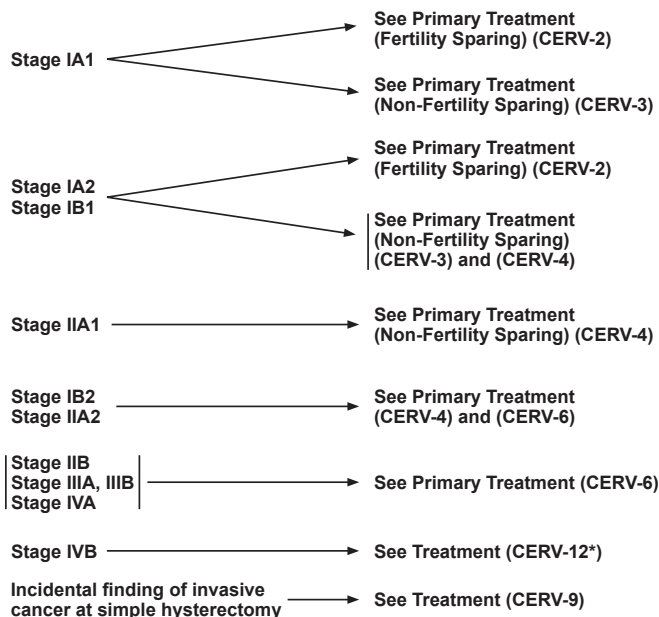
<sup>1</sup>Fred Hutchinson Cancer Research Center/Seattle Cancer Care Alliance; <sup>2</sup>Memorial Sloan Kettering Cancer Center; <sup>3</sup>Duke Cancer Institute; <sup>4</sup>University of Wisconsin Carbone Cancer Center; <sup>5</sup>Dana-Farber/Brigham and Women's Cancer Center; <sup>6</sup>University of Michigan Rogel Cancer Center; <sup>7</sup>Moffitt Cancer Center; <sup>8</sup>Fox Chase Cancer Center; <sup>9</sup>Massachusetts General Hospital Cancer Center; <sup>10</sup>The Ohio State University Comprehensive Cancer Center - James Cancer Hospital and Solove Research Institute; <sup>11</sup>Vanderbilt-Ingram Cancer Center; <sup>12</sup>Yale Cancer Center/Smilow Cancer Hospital; <sup>13</sup>Stanford Cancer Institute; <sup>14</sup>The University of Texas MD Anderson Cancer Center; <sup>15</sup>University of Colorado Cancer Center; <sup>16</sup>Roswell Park Comprehensive Cancer Center; <sup>17</sup>Huntsman Cancer Institute at the University of Utah; <sup>18</sup>City of Hope National Medical Center; <sup>19</sup>University of Alabama at Birmingham Comprehensive Cancer Center; <sup>20</sup>Robert H. Lurie Comprehensive Cancer Center of Northwestern University; <sup>21</sup>Mayo Clinic Cancer Center; <sup>22</sup>Siteman Cancer Center at Barnes-Jewish Hospital and Washington University School of Medicine; <sup>23</sup>Case Comprehensive Cancer Center/University Hospitals Seidman Cancer Center and Cleveland Clinic Taussig Cancer Institute; <sup>24</sup>The Sidney Kimmel Comprehensive Cancer Center at Johns Hopkins; <sup>25</sup>Fred & Pamela Buffett Cancer Center; <sup>26</sup>St. Jude Children's Research Hospital/The University of Tennessee Health Science Center; <sup>27</sup>UCSF Helen Diller Family Comprehensive Cancer Center; <sup>28</sup>Patient advocate; <sup>29</sup>UC San Diego Moores Cancer Center; and <sup>30</sup>National Comprehensive Cancer Network.

\*Discussion Section Writing Committee.

## WORKUP

- History and physical (H&P)
- Complete blood count (CBC) (including platelets)
- Cervical biopsy, pathologic review<sup>a</sup>
- Cone biopsy as indicated<sup>b</sup>
- Liver function test (LFT)/renal function studies
- Imaging<sup>c</sup>
- Smoking cessation and counseling intervention if indicated
- Consider HIV testing<sup>d</sup>
- Consider examination under anesthesia (EUA) cystoscopy/proctoscopy<sup>e</sup> (≥ stage IB2)
- Consider options for fertility sparing

## CLINICAL STAGE



\*Available online, in these guidelines, at NCCN.org.

<sup>a</sup>See Principles of Pathology (CERV-A).

<sup>b</sup>See Discussion for indications for cone biopsy.

<sup>c</sup>See Principles of Imaging (CERV-B\*).

<sup>d</sup>Consider HIV testing, especially in younger patients. Patients with cervical cancer and HIV should be referred to an HIV specialist and should be treated for cervical cancer as per these guidelines. Modifications to cancer treatment should not be made solely on the basis of HIV status.

<sup>e</sup>For suspicion of bladder/bowel involvement, cystoscopy/proctoscopy with biopsy is required.

All staging in guidelines is based on updated 2009 FIGO staging. (See ST-1\*)

Version 3.2019 12/17/18 © National Comprehensive Cancer Network, Inc. 2019 All rights reserved.  
The NCCN Guidelines® and this illustration may not be reproduced in any form without the express written permission of NCCN.

CERV-1

## Diagnosis and Workup

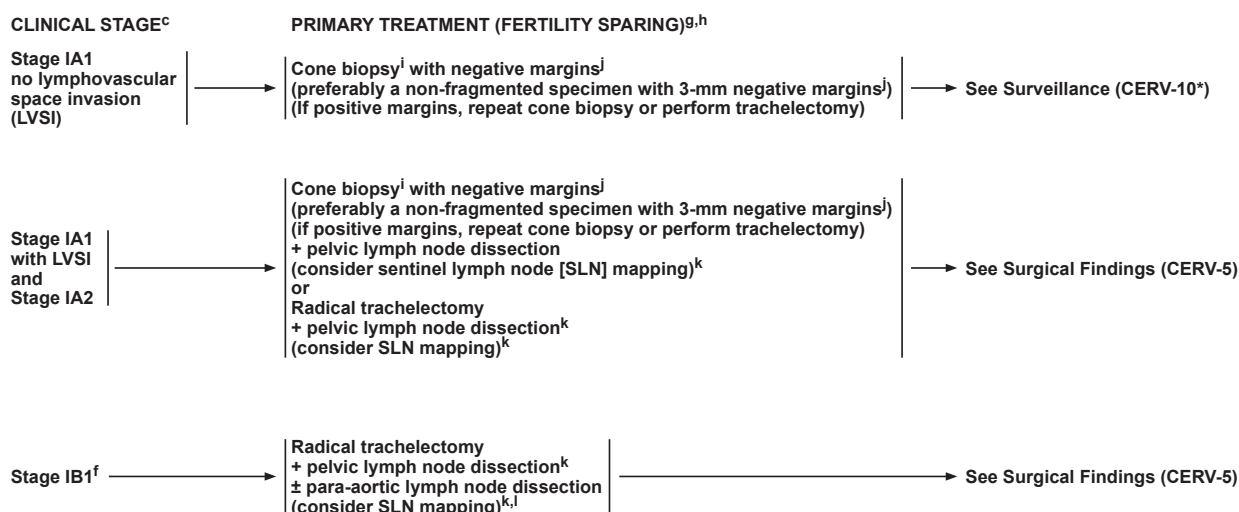
These NCCN Guidelines discuss squamous cell carcinoma, adenosquamous carcinoma, and adenocarcinoma of the cervix. Neuroendocrine carcinoma, small cell tumors, glassy-cell carcinomas, sarcomas, and other histologic types are not within the scope of these guidelines.

Currently, the International Federation of Gynecology and Obstetrics (FIGO) evaluation procedures for staging are limited to colposcopy, biopsy, conization of the cervix, cystoscopy, and proctosigmoidoscopy. More-complex radiologic and surgical staging procedures are not addressed in the FIGO classification. In the United States, however, CT, MRI, combined PET/CT, and surgical staging are often used to guide treatment options and design.<sup>1-5</sup>

The earliest stages of cervical carcinoma may be asymptomatic or associated with a watery vaginal discharge and postcoital bleeding or intermittent spotting. Often these early symptoms are not recognized by the patient. Because of the accessibility of the uterine cervix, cervical cytology or Papanicolaou (Pap) smears and cervical biopsies can usually result in an accurate diagnosis. Cone biopsy (ie, conization) is recommended if the cervical biopsy is inadequate to define invasiveness or if accurate assessment of microinvasive disease is required.

However, cervical cytologic screening methods are less useful for diagnosing adenocarcinoma, because adenocarcinoma in situ affects areas of the cervix that are harder to sample (ie, endocervical canal).<sup>6,7</sup> The College of American Pathologists (CAP) protocol for cervical carcinoma is a useful guide (available at [http://www.cap.org/apps/docs/committees/cancer/cancer\\_protocols/2012/Cervix\\_12protocol.pdf](http://www.cap.org/apps/docs/committees/cancer/cancer_protocols/2012/Cervix_12protocol.pdf)). This CAP protocol was revised in June 2012 and reflects recent updates in the AJCC/FIGO staging (ie, AJCC Cancer Staging Manual, 8<sup>th</sup> edition).

Workup for these patients with suspicious symptoms includes history and physical examination, complete blood count (CBC; including platelets), and liver and renal function tests. Recommended radiologic imaging includes chest radiograph, CT, or combined PET/CT, and MRI as indicated (eg, to rule out disease high in the endocervix).<sup>2,8</sup> For detailed imaging recommendations by stage and planned treatment approach, see "Principles of Imaging" in the NCCN Guidelines for Cervical Cancer, available online at NCCN.org). Smoking cessation and counseling, as well as HIV testing (especially in younger patients), are recommended. Cystoscopy and proctoscopy are only recommended if bladder or rectal extension is suspected. Options for fertility sparing should be considered.



<sup>c</sup>See Principles of Imaging (CERV-B\*).

<sup>f</sup>Fertility-sparing surgery for stage IB1 has been most validated for tumors ≤2 cm. Small cell neuroendocrine histology and adenoma malignum (also known as minimal deviation adenocarcinoma) are not considered suitable tumors for this procedure.

<sup>g</sup>There are no data to support a fertility-sparing approach in small neuroendocrine tumors, gastric type adenocarcinoma, or adenoma malignum. Total hysterectomy after completion of childbearing is at the patient's and surgeon's discretion, but is strongly advised in women with continued abnormal pap smears or chronic persistent HPV infection.

<sup>h</sup>Consultation with reproductive endocrinology fertility experts is suggested.

<sup>i</sup>Cold knife conization (CKC) is the preferred method of diagnostic excision, but loop electrosurgical excision procedure (LEEP) is acceptable, provided adequate margins and proper orientation are obtained. Endocervical curettage (ECC) should be added as clinically indicated.

<sup>j</sup>Negative for invasive disease or histologic high-grade squamous intraepithelial lesion (HSIL) at margins.

<sup>k</sup>See Principles of Evaluation and Surgical Staging (CERV-C\*).

<sup>l</sup>For SLN mapping, the best detection rates and mapping results are in tumors <2 cm.

\*Available online, in these guidelines, at NCCN.org.

Version 3.2019 12/17/18 © National Comprehensive Cancer Network, Inc. 2019 All rights reserved.  
The NCCN Guidelines® and this illustration may not be reproduced in any form without the express written permission of NCCN.

CERV-2

## Principles of Staging and Surgery

### Clinical Staging

Because noninvasive radiographic imaging may not be routinely available in low-resource countries, the FIGO system limits the imaging to chest radiography, intravenous pyelography, and barium enema. The staging of carcinoma of the cervix is largely a clinical evaluation. Although surgical staging is more accurate than clinical staging, surgical staging often cannot be performed in low-resource countries.<sup>4,9,10</sup>

The panel currently uses the 2009 FIGO definitions and staging system, which takes into account primary tumor characteristics (diameter in greatest dimension, cervical stromal invasion, locoregional spread) and distant metastasis.<sup>9,11</sup> Regional nodal metastasis is not included in the FIGO staging criteria. With the 2009 FIGO staging, stage IIA is now subdivided into stage IIA1 (tumor size ≤4 cm) and stage IIA2 (tumor size >4 cm), which is the only change from the previous 1994 FIGO staging system. FIGO directly aligns with AJCC staging with the exception of stage 0, which does not exist in the FIGO system.<sup>12,13</sup> Importantly, lymphovascular space invasion (LVSI) does not alter the FIGO classification.<sup>9</sup> FIGO did not include LVSI because pathologists do not always

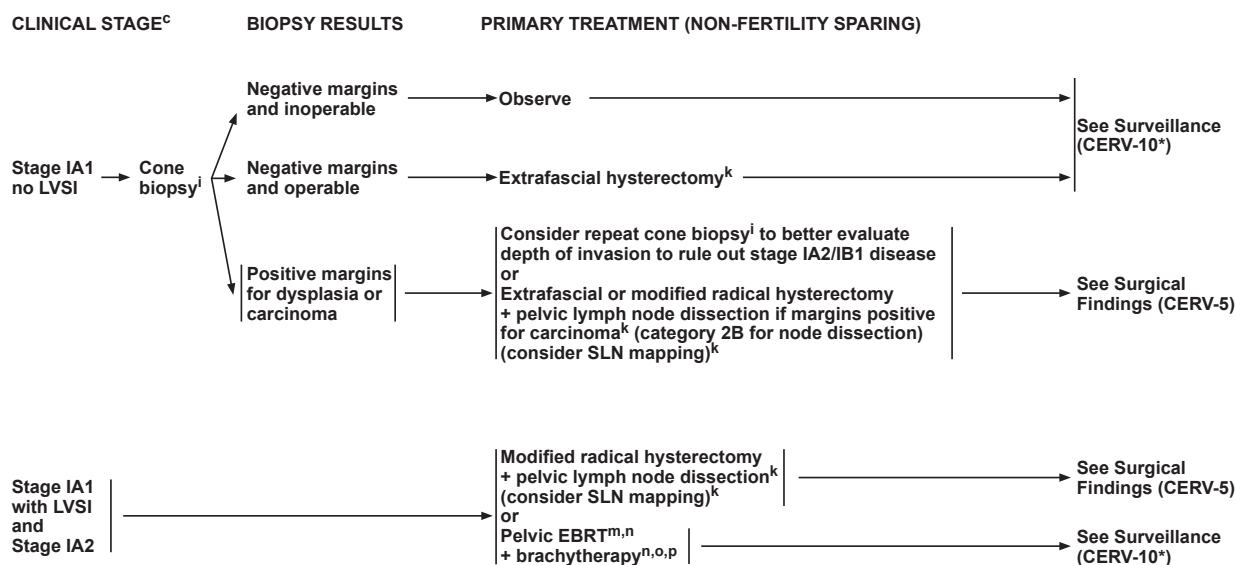
agree on whether LVSI is present in tissue samples. Some panel members believe that patients with stage IA1 who have extensive LVSI should be treated using stage IB1 guidelines.

The use of MRI, CT, or combined PET/CT scans may aid in treatment planning, but it is not accepted for formal staging purposes.<sup>8,10,14</sup> In addition, FIGO has always maintained that staging is intended for comparison purposes only and not as a guide for therapy. As a result, the panel uses the FIGO definitions as the stratification system for these guidelines, although the findings on imaging studies (ie, CT, MRI, PET/CT) are used to guide treatment options and design. MRI is useful to delineate disease extent and to guide decisions regarding fertility-sparing versus non-fertility-sparing treatment approaches,<sup>15–21</sup> whereas PET/CT may be useful to detect and/or rule out metastasis.<sup>22–26</sup>

### Surgical Staging

#### Pathologic Assessment

Surgicopathologic factors may be used to guide the extent of surgical staging and treatment decisions. Findings from pathologic assessment of the surgical specimen should be carefully documented. Important elements



<sup>c</sup>See Principles of Imaging (CERV-B\*).

<sup>i</sup>CKC is the preferred method of diagnostic excision, but LEEP is acceptable, provided adequate margins and proper orientation are obtained. ECC should be added as clinically indicated.

<sup>k</sup>See Principles of Evaluation and Surgical Staging (CERV-C\*).

<sup>m</sup>Radiation can be an option for medically inoperable patients or those who refuse surgery.

<sup>n</sup>See Principles of Radiation Therapy (CERV-D\*).

<sup>o</sup>These doses are recommended for most patients based on summation of conventional external-beam fractionation and low dose-rate (40–70 cGy/h) brachytherapy equivalents. Modify treatment based on normal tissue tolerance, fractionation, and size of target volume. (See Discussion)

<sup>p</sup>The traditional dose would be 70–80 Gy to total point A dose.

\*Available online, in these guidelines, at NCCN.org.

Version 3.2019 12/17/18 © National Comprehensive Cancer Network, Inc. 2019 All rights reserved.  
The NCCN Guidelines® and this illustration may not be reproduced in any form without the express written permission of NCCN.

CERV-3

of primary tumor evaluation include tumor site; primary tumor volume (in multiple dimensions); histologic type and grade; stromal invasion; surgical margin status; and the presence of lymphovascular invasion. When resected, the number of lymph nodes with isolated tumor cells, micrometastases, and macrometastases should be recorded. When sentinel lymph node (SLN) mapping is performed, SLNs should undergo ultrastaging for detection of low-volume metastasis; non-sentinel nodes do not require ultrastaging. Other important factors include tumor involvement of tissues/organs such as the parametrium, vaginal cuff, fallopian tubes, ovaries, peritoneum, omentum, and others.

The “Sedlis criteria,” which are intermediate risk factors used to guide adjuvant treatment decisions, include: (1) greater than one-third stromal invasion; (2) capillary lymphatic space involvement; or (3) cervical tumor diameters greater than 4 cm.<sup>27</sup> However, potentially important risk factors for recurrence may not be limited to the Sedlis criteria. Additional risk factors for consideration include tumor histology (eg, adenocarcinoma component)<sup>28,29</sup> and close or positive surgical margins.<sup>30,31</sup>

Recent findings suggest that predictive factors for lymph node metastasis in endocervical adenocarcinoma

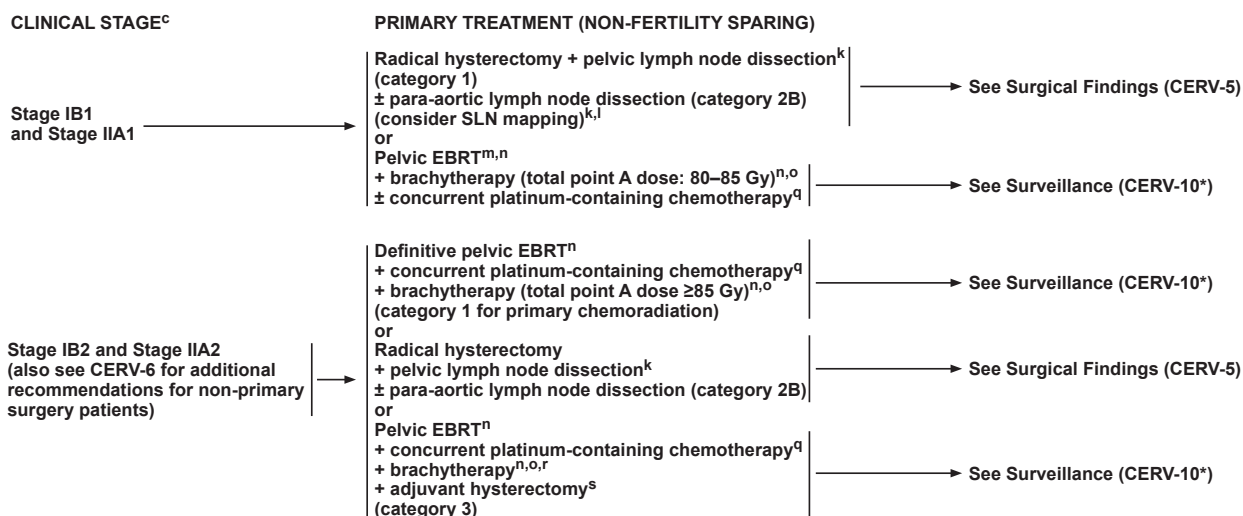
may differ from squamous cell carcinoma. Data from retrospective studies suggest that the pattern of cervical stromal invasion and presence of LVSI, but not primary tumor size, predict risk of nodal metastasis. Alternative classification systems incorporating stromal invasion pattern have been proposed for adenocarcinoma.<sup>32–34</sup> These systems remain to be validated for clinical use.

### Conservative/Fertility-Sparing Approaches

Fertility-sparing approaches may be considered in highly selected patients who have been thoroughly counseled regarding disease risk as well as prenatal and perinatal issues.<sup>35</sup> Consultation with reproductive endocrinology fertility experts is suggested.

Microinvasive disease (FIGO stage IA1 with no LVSI) is associated with an extremely low incidence of lymphatic metastasis,<sup>36–39</sup> and conservative treatment with conization is an option (category 2A) for individuals with no evidence of LVSI. In stage IA1 individuals with evidence of LVSI, a reasonable conservative approach is conization (with negative margins) in addition to SLN mapping algorithm or pelvic lymphadenectomy.

The goal of conization is en bloc removal of the ectocervix and endocervical canal; the shape of the cone can be tailored to the size, type, and location of the lesion



\*Available online, in these guidelines, at NCCN.org.

<sup>c</sup>See Principles of Imaging (CERV-B\*).

<sup>k</sup>See Principles of Evaluation and Surgical Staging (CERV-C\*).

<sup>l</sup>For SLN mapping, the best detection rates and mapping results are in tumors <2 cm.

<sup>m</sup>Radiation can be an option for medically inoperable patients or those who refuse surgery.

<sup>n</sup>See Principles of Radiation Therapy (CERV-D\*).

<sup>o</sup>These doses are recommended for most patients based on summation of conventional external-beam fractionation and low dose-rate (40–70 cGy/h) brachytherapy equivalents. Modify treatment based on normal tissue tolerance, fractionation, and size of target volume. (See Discussion)

<sup>q</sup>Concurrent platinum-containing chemotherapy with EBRT utilizes cisplatin as a single agent (or carboplatin if cisplatin intolerant) or cisplatin plus 5-fluorouracil.

<sup>r</sup>The traditional dose would be 75–80 Gy to total point A dose.

<sup>s</sup>This approach can be considered in patients whose extent of disease or uterine anatomy precludes adequate coverage by brachytherapy.

Version 3.2019 12/17/18 © National Comprehensive Cancer Network, Inc. 2019 All rights reserved.  
The NCCN Guidelines® and this illustration may not be reproduced in any form without the express written permission of NCCN.

CERV-4

(ie, narrow long cone in cases of suspected invasive adenocarcinoma). The panel recommends cold knife conization as the preferred approach. However, LEEP (loop electrosurgical excision procedure) is acceptable as long as adequate margins, proper orientation, and a non-fragmented specimen without electrosurgical artifact can be obtained.<sup>40–45</sup> Endocervical curettage should be added as clinically indicated.

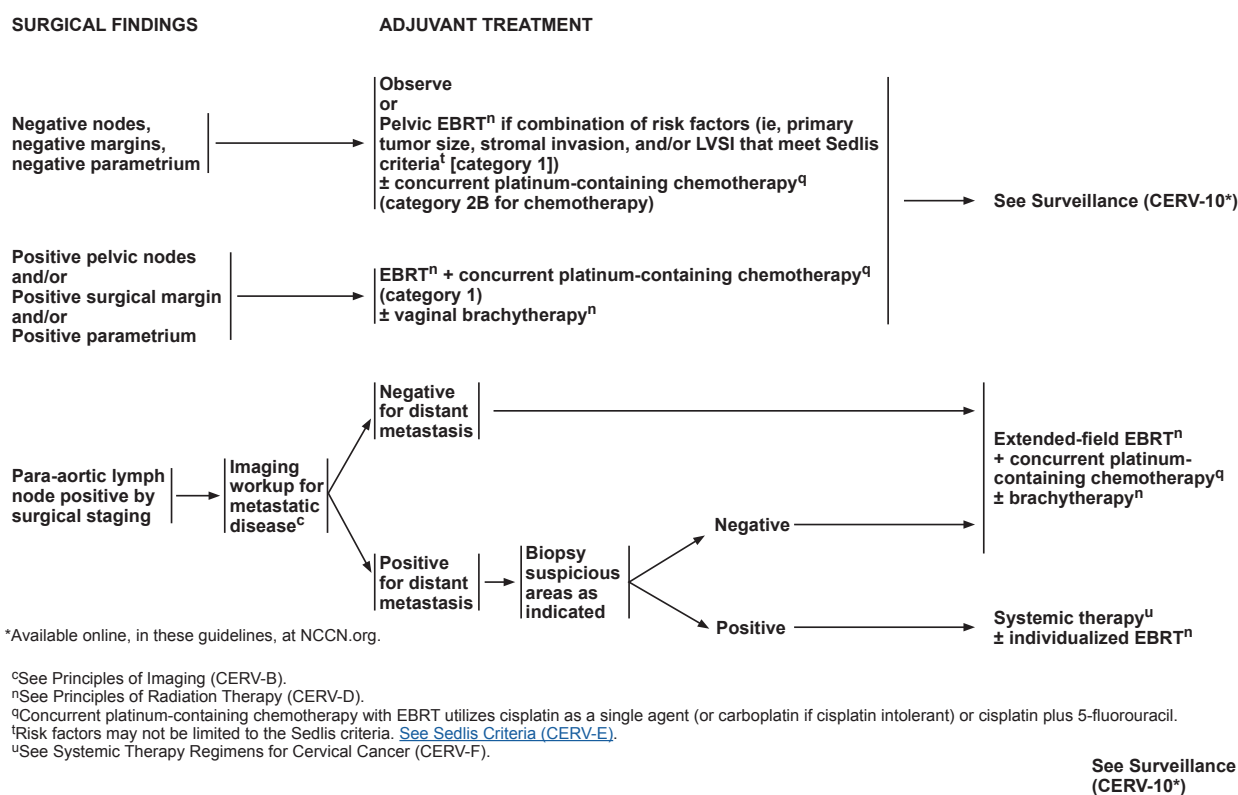
Select patients with stage IA2 or IB1 cervical cancer, especially for those with tumors of less than 2 cm in diameter, may be eligible for conservative surgery.<sup>46,47</sup> Radical trachelectomy may offer a reasonable fertility-sparing treatment option for patients with stage IA2 or IB1 cervical cancer with lesions that are less than or equal to 2 cm in diameter.<sup>48–50</sup> In a radical trachelectomy, the cervix, vaginal margins, and supporting ligaments are removed while leaving the main body and fundus of the uterus intact.<sup>51</sup> Laparoscopic pelvic lymphadenectomy accompanies the procedure and can be performed with or without SLN mapping (see “Lymph Node Mapping and Dissection” on page 69). Due to their aggressive nature, tumors of small cell neuroendocrine histology are considered inappropriate for radical trachelectomy.<sup>52</sup> Trachelectomy is also inappropriate for treating gastric type cervical adenocarcinoma and adenoma malignum

(minimal deviation adenocarcinoma) due to their diagnostic challenges and potentially aggressive nature.<sup>53</sup>

Vaginal radical trachelectomy (VRT) may be used for carefully selected patients with lesions of 2 cm diameter or less.<sup>54–56</sup> Abdominal radical trachelectomy (ART) provides a broader resection of the parametria<sup>48,56</sup> than the vaginal approach and is commonly used in stage IB1 lesions. Multiple case series have evaluated safety and outcomes with vaginal versus abdominal approaches to radical trachelectomy,<sup>54,57–59</sup> including systematic reviews on VRT<sup>60</sup> and ART.<sup>61</sup> A limited number of studies have specifically examined this approach in patients with larger stage IB1 tumors between 2 cm and 4 cm in diameter and reported safe oncologic outcomes; however, as expected, more patients in this subgroup will require adjuvant therapy that may reduce fertility.<sup>62–64</sup>

Studies that examined pregnancy in women who underwent radical trachelectomy have provided differing success rates. One case series of 125 patients with cervical cancer who underwent VRT reported 106 pregnancies among 58 women.<sup>55</sup> In a systematic review of 413 women who underwent ART, 113 women attempted pregnancy and 67 (59%) successfully conceived.<sup>58</sup> However, miscarriage and preterm labor rates were elevated among women who underwent radical trachelectomy.<sup>55,65–67</sup>





Version 3.2019 12/17/18 © National Comprehensive Cancer Network, Inc. 2019 All rights reserved.  
The NCCN Guidelines® and this illustration may not be reproduced in any form without the express written permission of NCCN.

CERV-5

### Non-Fertility-Sparing Approaches

The Querleu and Morrow surgical classification system<sup>68,69</sup> describes the degree of resection and nerve preservation for radical hysterectomy in 3D planes and updates the previously used Piver-Rutledge classifications.<sup>70</sup> Approaches to hysterectomy include simple/extrafascial hysterectomy (type A), modified radical hysterectomy (type B), and radical hysterectomy (type C).<sup>71,72</sup>

For patients with IA1 disease, cone excision, simple/extrafascial hysterectomy, and modified radical hysterectomy are options. Radical hysterectomy with bilateral pelvic lymph node dissection (with or without SLN mapping) is the preferred treatment approach for patients with FIGO stage IA2 through IIA1 cervical cancers. Radical hysterectomy is preferred over simple hysterectomy due to its wider paracervix margin of resection that also includes aspects of the cardinal and uterosacral ligaments, upper vagina, pelvic nodes, and at times, para-aortic nodes. In the United States, definitive chemoradiation is typically preferred over radical surgery for select patients with bulky FIGO IB2 lesions and the vast majority of FIGO stage IIA2 or greater cervical cancers. Abroad, select FIGO IB2 to IIB cases may be treated with radical hysterectomy or neoadjuvant chemotherapy followed by radical hysterectomy.

For recurrent or persistent cervical cancers that are confined to the central pelvis (ie, no distant metastasis), pelvic exenteration may be a potentially curative surgical option.<sup>73,74</sup> Discussion of the various approaches to pelvic exenteration are offered by Chi and colleagues,<sup>71</sup> and in the GOG Surgical Manual.<sup>72</sup>

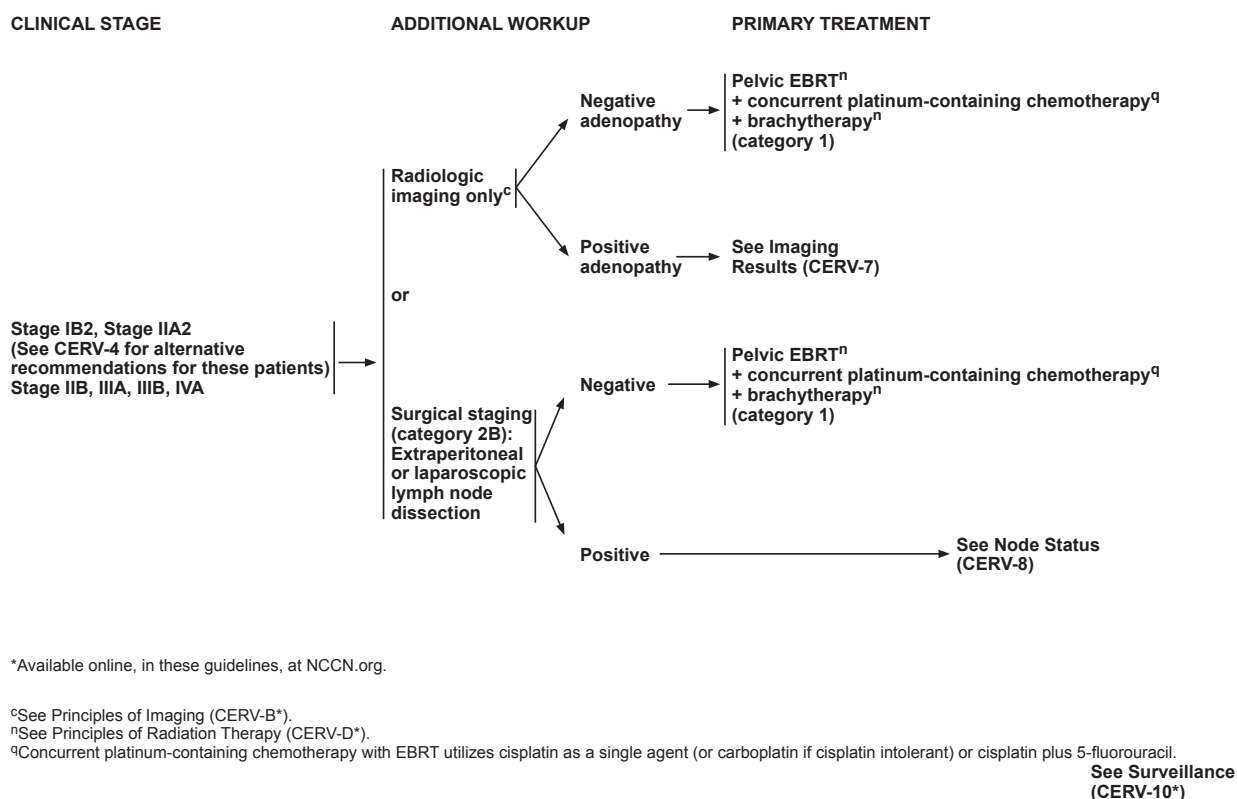
### Lymph Node Mapping and Dissection

#### Sentinel Lymph Node Mapping

Recent data suggest that SLN biopsy may be useful for decreasing the need for pelvic lymphadenectomy in patients with early-stage cervical cancer.<sup>75,76</sup>

Prospective studies generally support the feasibility of SLN detection in patients with early-stage cervical cancer and suggest that extensive pelvic lymph node dissection may be safely avoided in a significant proportion of early-stage cases.<sup>75-86</sup>

Meta-analyses of pooled data from SLN mapping studies have generated SLN detection rates of 89% to 92% and sensitivity of 89% to 90%.<sup>87,88</sup> Factors determined to be important for detection included laparoscopy, dual blue dye/radiocolloid tracer approaches, and pathologic assessment using immunohistochemistry. However, based on a recent metaanalysis, indocyanine



Version 3.2019 12/17/18 © National Comprehensive Cancer Network, Inc. 2019 All rights reserved.  
The NCCN Guidelines® and this illustration may not be reproduced in any form without the express written permission of NCCN.

CERV-6

green tracer appears to provide similar overall and bilateral detection rates to the standard dual blue dye/technetium-99 approach.<sup>89</sup> The randomized phase III FILM trial demonstrated that indocyanine green tracer identified more SLNs (overall and bilateral) than blue dye.<sup>90</sup>

Study data also highlight the limited sensitivity of this approach and potential to miss SLN micrometastases and isolated tumor cells using intraoperative assessment (ie, frozen section or imprint cytology).<sup>78,82,84</sup> The sensitivity of this approach appears to be better in patients with tumors ≤2 cm in diameter.<sup>75,77,79,91</sup> Ultrastaging of detected SLNs has been shown to provide enhanced detection of micrometastases.<sup>80,81</sup>

The SENTICOL longitudinal study demonstrated the utility of SLN mapping to uncover unusual lymph drainage patterns.<sup>79,92</sup> It also highlighted limited agreement between lymphoscintigraphy and intraoperative SLN mapping.<sup>92</sup> Additionally, this study revealed that bilateral SLN detection and biopsy provided a more reliable assessment of sentinel nodal metastases and led to fewer false negatives than unilateral SLN biopsy.<sup>76</sup> Generally, research supports ipsilateral lymphadenectomy if no sentinel nodes are detected on a given side of the pelvis as outlined in the SLN mapping algorithm.<sup>75,76,93</sup>

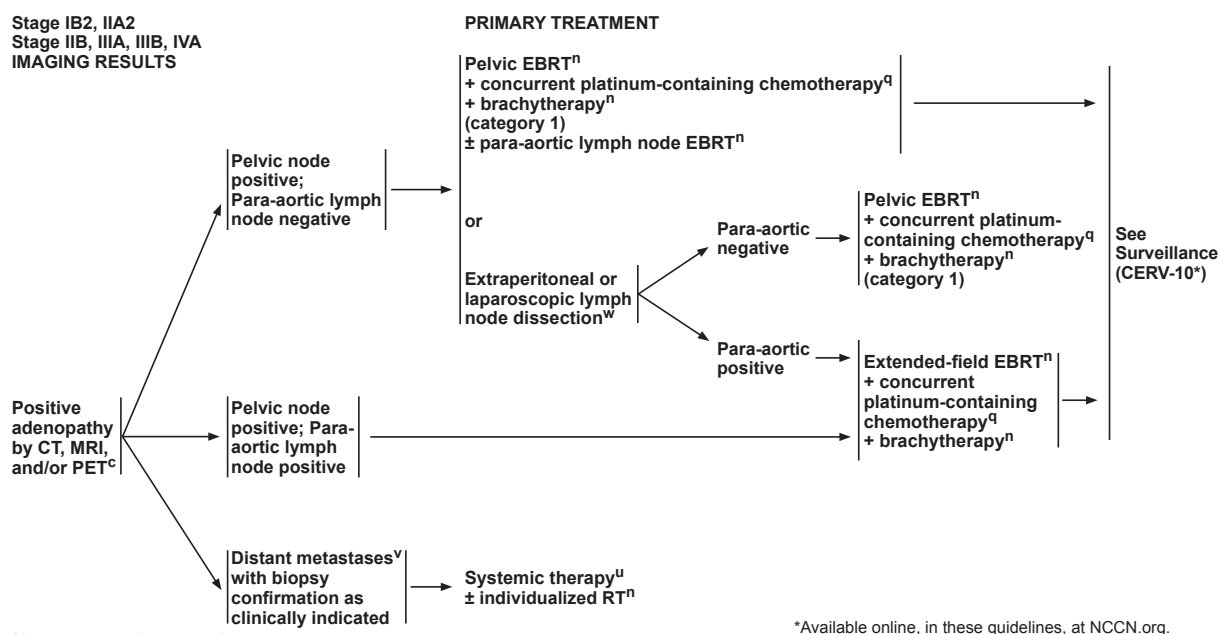
Based on these collective data, the panel recom-

mends consideration of the SLN mapping algorithm and emphasizes that best detection and mapping results are in tumors of less than 2 cm diameter. Adherence to the SLN mapping algorithm is important; surgeons should perform side-specific nodal dissection in any cases of failed mapping and remove all suspicious or grossly enlarged nodes regardless of SLN mapping.<sup>75</sup>

#### Para-Aortic Lymph Node Assessment

Studies of the incidence and distribution of lymph node metastases in women with stage IB to IIB cervical cancers suggest that para-aortic lymph node involvement is closely tied to the presence of pelvic lymph node metastases, larger primary tumor size (>2 cm), and metastasis to the common iliac nodes.<sup>94,95</sup>

Analysis of outcomes data from 555 women who participated in GOG trials (GOG 85, GOG 120, and GOG 165) revealed a more positive prognosis for patients who underwent surgical exclusion of para-aortic lymph node involvement versus those who underwent radiographic determination of para-aortic node involvement.<sup>4</sup> One study examined the efficacy of extending the radiation therapy (RT) field to the para-aortic region in patients with para-aortic lymph node involvement, and showed therapeutic benefit especially in patients with small-vol-



<sup>c</sup>See Principles of Imaging (CERV-B\*).

<sup>n</sup>See Principles of Radiation Therapy (CERV-D\*).

<sup>q</sup>Concurrent platinum-containing chemotherapy with EBRT utilizes cisplatin as a single agent (or carboplatin if cisplatin intolerant) or cisplatin plus 5-fluorouracil.

<sup>u</sup>See Systemic Therapy Regimens for Cervical Cancer (CERV-F).

<sup>v</sup>Patients with distant metastatic disease confined to the supraclavicular nodes may be treated definitively. (Kim JY, Kim JY, Kim JH, et al. Curative chemoradiotherapy in patients with stage IIV cervical cancer presenting with paraortic and left supraclavicular lymph node metastases. *Int J Radiat Oncol Biol Phys* 2012;84:741-747.)

<sup>w</sup>Consider postoperative imaging (abdominal/pelvic CT or MRI with contrast) to confirm the adequacy of node removal.

\*Available online, in these guidelines, at NCCN.org.

**See Surveillance  
(CERV-10\*)**

Version 3.2019 12/17/18 © National Comprehensive Cancer Network, Inc. 2019 All rights reserved.  
The NCCN Guidelines® and this illustration may not be reproduced in any form without the express written permission of NCCN.

**CERV-7**

ume nodal disease.<sup>96</sup> A randomized controlled trial examining surgical versus radiologic staging and treatment of para-aortic lymph node involvement is ongoing.<sup>97</sup>

The panel recommends para-aortic lymph node dissection for patients with stage IB1 or greater disease.

### Minimally Invasive Surgical Approaches

The standard and historical approach for radical hysterectomy is with an open abdominal approach.

Previous iterations of the guidelines had indicated that radical hysterectomy could be performed via either open laparotomy or minimally invasive surgery (MIS) laparoscopic approaches, using either conventional or robotic techniques. Data from previous retrospective reviews and prospective observational studies demonstrated oncologic outcomes after conventional laparoscopic radical hysterectomy that were comparable to open abdominal approaches after 3 to 6 years of follow-up.<sup>98-101</sup> Similarly, multicenter retrospective reviews and matched cohort studies showed comparable oncologic outcomes (disease recurrence and survival rates) for open abdominal and robotic radical hysterectomy after 3 to 5 years of follow-up.<sup>101-104</sup> Additionally, a systematic review and meta-analysis of data from 26 studies found that laparoscopic and robotic radical hysterecto-

my approaches appeared to provide equivalent intraoperative and short-term postoperative outcomes.<sup>105</sup>

However, several key contemporary reports have questioned the presumed therapeutic equivalency of open versus MIS approaches. A recently published prospective randomized trial demonstrated that minimally invasive radical hysterectomy was associated with lower rates of disease-free survival (DFS) and overall survival (OS) than open abdominal radical hysterectomy.<sup>106</sup> This phase III LACC trial (Clinicaltrials.gov Identifier: NCT00614211) was designed to provide a definitive comparison of outcomes data in patients with early-stage cervical cancer undergoing total abdominal radical hysterectomy or total laparoscopic radical hysterectomy/total robotic radical hysterectomy. At closure, 319 patients had received MIS (84% laparoscopy, 16% robotic) and 312 patients underwent a total abdominal radical hysterectomy. Ninety-two percent of participants in both surgical arms had stage IB1 disease. MIS was associated with lower rate of DFS than open surgery (3-year DFS, 91.2% vs 97.1%; hazard ratio [HR], 3.74; 95% CI, 1.63 to 8.58), as well as a decrease in OS (3-year OS, 93.8% vs 99.0%; HR, 6.00; 95% CI, 1.77 to 20.30).<sup>106</sup> MIS did not meet predetermined noninferiority criteria compared with standard-of-care laparotomy ( $P=.88$ ).

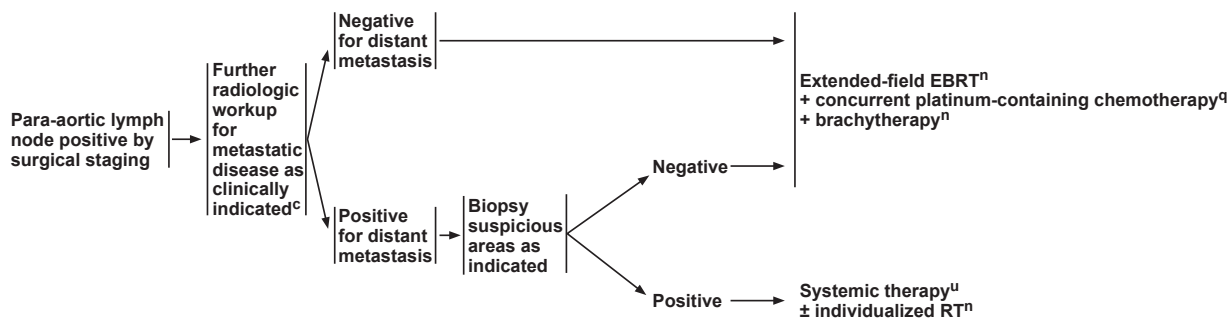


**Stage IB2, IIA2; Stage IIB, IIIA, IIIB, IVA  
SURGICAL NODE STATUS**

Pelvic lymph node positive  
and para-aortic lymph  
node negative by surgical  
staging

**PRIMARY TREATMENT**

Pelvic EBRT<sup>n</sup>  
+ concurrent platinum-containing chemotherapy<sup>q</sup>  
+ brachytherapy<sup>n</sup>  
(category 1)



\*Available online, in these guidelines, at NCCN.org.

<sup>c</sup>See Principles of Imaging (CERV-B\*).

<sup>n</sup>See Principles of Radiation Therapy (CERV-D\*).

<sup>q</sup>Concurrent platinum-containing chemotherapy with EBRT utilizes cisplatin as a single agent (or carboplatin if cisplatin intolerant) or cisplatin plus 5-fluorouracil.

<sup>u</sup>See Systemic Therapy Regimens for Cervical Cancer (CERV-F).

**See Surveillance  
(CERV-10\*)**

Version 3.2019 12/17/18 © National Comprehensive Cancer Network, Inc. 2019 All rights reserved.  
The NCCN Guidelines® and this illustration may not be reproduced in any form without the express written permission of NCCN.

**CERV-8**

Two other recent epidemiologic studies also showed that minimally invasive radical hysterectomy was associated with shorter OS than open surgery among women with stage IA2 to IB1 cervical cancer.<sup>107,108</sup> Melamed et al<sup>107</sup> reported on a SEER-based cohort study that compared women with stage IA2 or IB1 cervical cancer who underwent laparotomy (n=1,236) or MIS (n=1,225). Four-year mortality was higher among patients undergoing MIS versus laparotomy (9.1% vs 5.3%;  $P=.002$ ). Relative survival rates were stable before the adoption of MIS techniques (2000–2006), but a significant decline was noted in the years after adoption. Margul et al<sup>108</sup> examined National Cancer Database data from 2010 to 2013 to compare outcomes of patients with stage IB1 cervical cancer who underwent radical hysterectomy performed by open abdominal versus MIS approaches. Although MIS was associated with decreased surgical morbidity and costs, patients with tumor sizes  $\geq 2$  cm who underwent MIS had decreased 5-year survival compared with those undergoing open radical hysterectomy (81.3% vs 90.8%;  $P<.001$ ).<sup>108</sup>

These most recent findings stand in contradiction to the earlier referenced series that had suggested therapeutic equivalency of MIS compared with open approaches along with the MIS-associated potential advan-

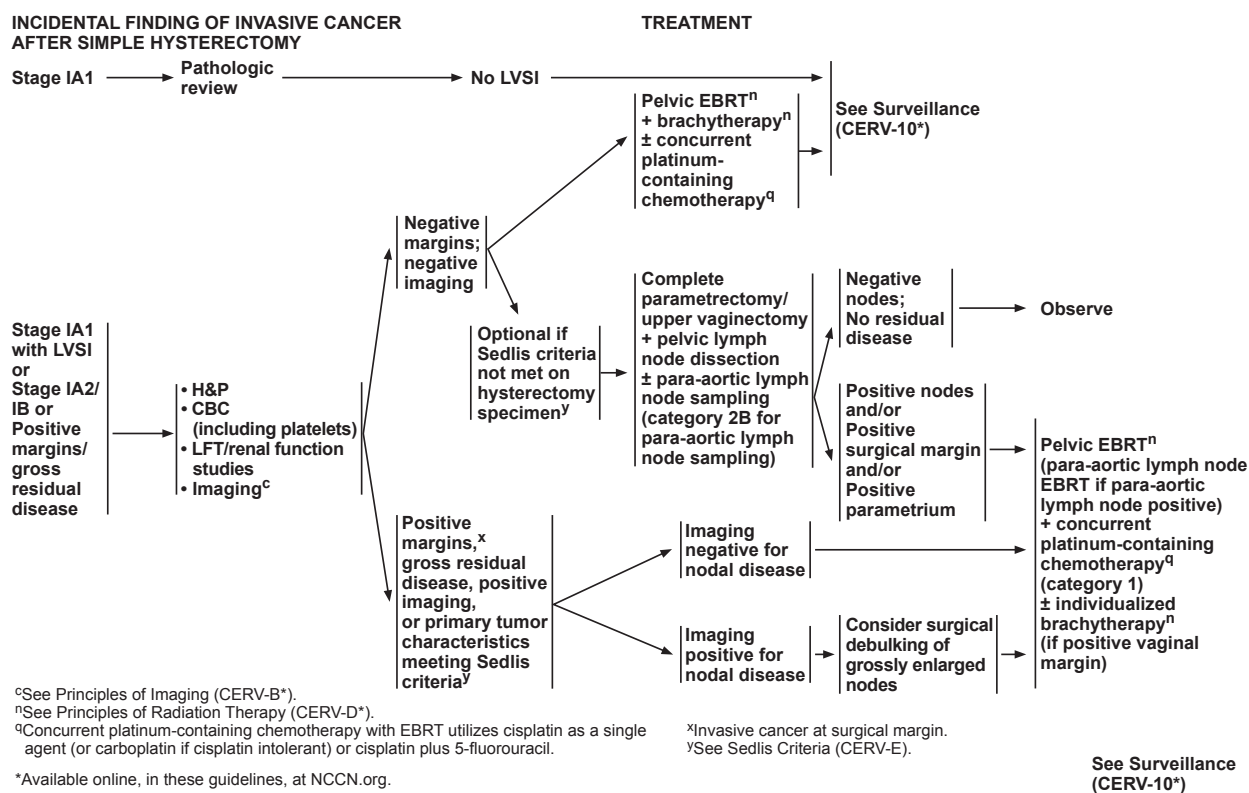
tages of decreased hospital stay and more rapid patient recovery.<sup>101,102,104,105,109–112</sup>

Given the recently presented findings of poorer oncologic outcomes and survival with the MIS techniques compared with open laparotomy, women should be carefully counseled about the oncologic risks and potential short-term benefits of the different surgical approaches.

## Primary Treatment

The primary treatment of early-stage cervical cancer is either surgery or RT. Surgery is typically reserved for early-stage disease, fertility-preservation, and smaller lesions, such as stage IA, IB1, and selected IIA1 cases.<sup>3</sup> The panel agrees that concurrent chemoradiation is generally the primary treatment of choice for stages IB2 to IVA disease based on the results of 5 randomized clinical trials (see Table 1, available online, in these guidelines, at NCCN.org).<sup>113,114</sup> Chemoradiation can also be used for patients who are not candidates for hysterectomy. Although few studies have assessed treatment specifically for adenocarcinomas, they are typically treated in a similar manner to squamous cell carcinomas.<sup>115–117</sup>

Pelvic RT or chemoradiation will invariably lead to ovarian failure in premenopausal women.<sup>118</sup> To preserve



Version 3.2019 12/17/18 © National Comprehensive Cancer Network, Inc. 2019 All rights reserved.  
The NCCN Guidelines® and this illustration may not be reproduced in any form without the express written permission of NCCN.

CERV-9

intrinsic hormonal function, ovarian transposition may be considered before pelvic RT for select women younger than 45 years of age with squamous cell cancers.<sup>119,120</sup>

### Important Phase III Clinical Trials Underpinning Treatment Recommendations

A randomized Italian study compared RT alone versus radical hysterectomy and lymph node dissection in patients with clinical early-stage disease (stage IB–IIA).<sup>121</sup> Adjuvant RT was given to those with parametrial extension, less than 3 cm of uninvolved cervical stroma, positive margins, or positive nodes. Identical outcomes were noted for patients treated with radiation versus surgery, with (or without) postoperative radiation, but higher complication rates were noted for the combined modality approach.

Concurrent chemoradiation, using platinum-containing chemotherapy (cisplatin alone [preferred] or cisplatin/fluorouracil), is the treatment of choice for stages IB2, II, III, and IVA disease based on the results of randomized clinical trials.<sup>122–127</sup> These trials have shown that the use of concurrent chemoradiation results in a 30% to 50% decrease in the risk of death compared with RT alone. Although the optimal concurrent chemotherapy regimen to use with RT requires further investigation, these trials clearly established a role for concurrent cis-

platin-containing chemoradiation. Based on these data, the NCI issued an alert stating that strong consideration should be given to using chemoradiation instead of RT alone for invasive cervical cancer.<sup>127</sup> Long-term follow-up of 3 of these trials has confirmed that concurrent cisplatin-containing chemoradiation improves progression-free survival (PFS) and OS when compared with RT with (or without) hydroxyurea.<sup>128–130</sup> A recent meta-analysis reported that chemoradiotherapy leads to a 6% improvement in 5-year survival (HR, 0.81;  $P < .001$ ).<sup>131</sup> A large, population-based registry analysis in Canada ( $n=4,069$ ) confirmed that chemoradiotherapy improved outcomes when compared with RT alone.<sup>132</sup>

Although chemoradiation is tolerated, acute and long-term side effects have been reported.<sup>131,133,134</sup> Concurrent single-agent cisplatin chemoradiation may be preferred over cisplatin/fluorouracil chemoradiation due to lesser toxicity.<sup>114,135</sup> Concurrent carboplatin (preferred if cisplatin intolerant) or non-platinum chemoradiation regimens are options for patients who may not tolerate cisplatin-containing chemoradiation.<sup>131,136–141</sup> Carboplatin has been added to the guidelines as a preferred radiosensitizing agent for patients who are cisplatin intolerant.

Note that when concurrent chemoradiation is used, the chemotherapy is typically given when the exter-

PRINCIPLES OF PATHOLOGY<sup>1</sup>

- Procedure:
  - ▶ Radical hysterectomy
- Pathologic assessment for carcinoma:
  - ▶ Uterus
    - ◊ Hysterectomy type (where applicable)
    - ◊ Tumor site
    - ◊ Tumor size, include greatest dimension and additional two dimensions
    - ◊ Histologic type
    - ◊ Histologic grade
    - ◊ Stromal invasion (depth of invasion in mm/cervical wall thickness in mm)
    - ◊ Longitudinal/length horizontal extent in mm
    - ◊ Circumferential/width horizontal extent in mm
    - ◊ Surgical resection margin status
      - If negative, include closest margin and distance to closest margin (in mm).<sup>a</sup>
      - If positive, include location of positive margin.<sup>a</sup>
    - ◊ Lymphovascular invasion
  - ▶ Other tissue/Organ involvement (parametrium, vaginal cuff, fallopian tubes, ovaries, peritoneum, omentum, other)
  - ▶ Lymph nodes (when resected)
    - ◊ SLNs should undergo ultrastaging for detection of low-volume metastasis.<sup>b</sup>
    - ◊ Non-SLNs do not require ultrastaging and can be processed as per routine protocols.
    - ◊ Include the number of lymph nodes with isolated tumor cells, micrometastasis, macrometastasis
  - ▶ Consider MMR/MSI testing or PD-L1 testing for patients with recurrent, progressive, or metastatic disease<sup>2,3</sup>

## Footnotes

<sup>a</sup>While reporting of this information is not required, knowledge of this information is useful for multidisciplinary treatment planning.

<sup>b</sup>Ultrastaging commonly entails thin serial sectioning of the gross SLN and review of multiple H&E stained sections and cytokeratin immunohistochemistry for all blocks of the SLN. There is not a standard protocol for lymph node ultrastaging.

## References

- <sup>1</sup>Krishnamurti U, Movahedi-Lankarani S, Bell DA, et al. Protocol for the Examination of Specimens from Patients with Primary Carcinoma of the Uterine Cervix. College of American Pathologists 2017.
- <sup>2</sup>Minion LE, Tewari KS. Cervical cancer - State of science: From angiogenesis blockade to checkpoint inhibition. *Gynecol Oncol* 2018; Mar;148(3):609-621.
- <sup>3</sup>Chung HC, Schellens JH, Delord J-P, et al. Pembrolizumab treatment of advanced cervical cancer: Updated results from the phase 2 KEYNOTE-158 study. *J Clin Oncol* 2018;36; (suppl; abstr 5522).

Version 3.2019 12/17/18 © National Comprehensive Cancer Network, Inc. 2019 All rights reserved.  
The NCCN Guidelines® and this illustration may not be reproduced in any form without the express written permission of NCCN.

CERV-A

nal-beam pelvic radiation is administered.<sup>114</sup> The panel believes that “systemic consolidation” (ie, adding chemotherapy after chemoradiation) should only be used in clinical trials (eg, OUTBACK [ANZGOG-0902/GOG 274, Clinicaltrials.gov Identifier: NCT01414608] and RTOG 724 [NCT00980954]).<sup>142</sup>

### Early-Stage Disease

After careful clinical evaluation and staging, the primary treatment of early-stage cervical cancer is either surgery or RT. The treatment schema is stratified using the FIGO staging system (see Table 1, available online, in these guidelines, at NCCN.org). A new fertility-sparing algorithm was added in 2012 for select patients with stage IA and IB1 disease [see “Primary Treatment (Fertility Sparing)” on page 66]. Fertility-sparing surgery is generally not recommended for patients with small cell neuroendocrine tumors, gastric type adenocarcinoma, or adenoma malignum (minimal deviation adenocarcinoma) because of its high-risk nature and a paucity of data.

### Stage IA1 Disease

Recommended options for stage IA1 disease depend on the results of cone biopsy and whether patients (1) want to preserve their fertility; (2) are medically operable; or

(3) have LVSI [see “Primary Treatment (Fertility Sparing)” and “Primary Treatment (Non-Fertility Sparing)” in the algorithm, pages 66–68]. The extent of the lymph node dissection depends on whether pelvic nodal disease and/or LVSI are present and the size of the tumors. SLN mapping can be considered.

### Fertility-Sparing

For patients who desire fertility preservation, cone biopsy with or without pelvic lymph node dissection is recommended.<sup>86,143,144</sup>

The goal of cone biopsy is margins that are negative for invasive disease and high-grade squamous intraepithelial lesion. For patients with negative margins after cone biopsy and no findings of LVSI, observation may be an option if fertility preservation is desired. For patients with positive margins after cone biopsy, options include repeat cone biopsy to better evaluate depth of invasion (to rule out stage IA2/IB1 disease) or a radical trachelectomy. In studies of patients who had positive margins after conization, predictors of residual disease included positive endocervical curettage, combined endocervical margin and endocervical curettage, and volume of disease.<sup>30,145,146</sup>

For patients with stage IA1 disease with LVSI, conization (with negative margins) plus laparoscopic pelvic

**SEDLIS CRITERIA FOR EXTERNAL PELVIC RADIATION AFTER RADICAL HYSTERECTOMY IN NODE-NEGATIVE, MARGIN-NEGATIVE, PARAMETRIA-NEGATIVE CASES<sup>1-4</sup>**

LVSI	Stromal Invasion	Tumor Size (cm) (determined by clinical palpation)
+	Deep 1/3	Any
+	Middle 1/3	≥2
+	Superficial 1/3	≥5
-	Middle or deep 1/3	≥4

LVSI: Lymphovascular space invasion

<sup>1</sup>Modified with permission from Sedlis A, Bundy BN, Rotman MZ, et al. A randomized trial of pelvic radiation therapy versus no further therapy in selected patients with stage IB carcinoma of the cervix after radical hysterectomy and pelvic lymphadenectomy: a gynecologic oncology study group. *Gynecol Oncol* 1999;73:177-183.

<sup>2</sup>Delgado G, Bundy B, Zaino R, et al. Prospective surgical-pathological study of disease-free interval in patients with stage IB squamous cell carcinoma of the cervix: a Gynecologic Oncology Group study. *Gynecol Oncol* 1990;38:352-357.

<sup>3</sup>Rotman M, Sedlis A, Piedmont MR, et al. A phase III randomized trial of postoperative pelvic irradiation in stage IB cervical carcinoma with poor prognostic features: follow-up of a gynecologic oncology group study. *Int J Radiat Oncol Biol Phys* 2006;65:169-176.

<sup>4</sup>Risk factors may not be limited to the Sedlis criteria.

Version 3.2019 12/17/18 © National Comprehensive Cancer Network, Inc. 2019 All rights reserved.  
The NCCN Guidelines® and this illustration may not be reproduced in any form without the express written permission of NCCN.

CERV-E

SLN mapping/lymphadenectomy is a reasonable strategy. In addition, these patients may also be treated with a radical trachelectomy and SLN mapping/pelvic lymph node dissection [see “Primary Treatment (Fertility Sparing),” page 66].<sup>59,144–150</sup>

After childbearing is complete, hysterectomy can be considered for patients who have had either radical trachelectomy or a cone biopsy for early-stage disease if they have chronic, persistent HPV infection, they have persistent abnormal Pap tests, or they desire this surgery.

For young (<45 years) premenopausal women with early-stage squamous cell carcinoma who opt for ovarian preservation (ie, hysterectomy only), the rate of ovarian metastases is low.<sup>151,152</sup>

**Non-Fertility-Sparing**

For medically and technically operable patients with stage IA1 disease who do not desire fertility preservation, extrafascial (ie, simple) hysterectomy is commonly recommended for patients without LVSI and with either negative margins after cone biopsy or with positive margins for dysplasia. For patients with positive margins for carcinoma, modified radical hysterectomy is recommended with SLN mapping/pelvic lymph node dissection (category 2B for node dissection). SLN mapping

can be considered. Physicians can also consider repeat cone biopsy to better evaluate depth of invasion. If LVSI is present, then modified radical hysterectomy with SLN mapping/pelvic lymph node dissection is recommended. For patients with negative margins after cone biopsy, observation is recommended for those who are medically inoperable or those who refuse surgery.

**Stage IA2 Disease**

Recommendations for stage IA2 depend on whether a patient wishes to preserve her fertility and if the disease is medically operable.

**Fertility-Sparing**

For patients who wish to preserve their fertility, radical trachelectomy and pelvic lymph node dissection is recommended. SLN mapping can also be considered. Cone biopsy followed by observation is another option if the margins are negative and pelvic lymph node dissection is negative.

**Non-Fertility-Sparing**

For medically operable patients who do not desire fertility preservation, recommended treatment includes either surgery or RT [see “Primary Treatment (Non-Fer-

**SYSTEMIC THERAPY REGIMENS FOR CERVICAL CANCER<sup>a</sup>**  
(Strongly consider clinical trial)

Chemoradiation		
<b>Preferred Regimens</b> <ul style="list-style-type: none"> <li>• Cisplatin</li> <li>• Carboplatin if patient is cisplatin intolerant</li> </ul>		
<b>Other Recommended Regimens</b> <ul style="list-style-type: none"> <li>• Cisplatin/fluorouracil</li> </ul>		
Recurrent or Metastatic Disease		
First-line combination therapy <sup>b,c</sup>	Possible first-line single-agent therapy <sup>c</sup>	Second-line therapy <sup>d</sup>
<b>Preferred Regimens</b> <ul style="list-style-type: none"> <li>• Cisplatin/paclitaxel/bevacizumab<sup>1</sup> (category 1)</li> <li>• Carboplatin/paclitaxel/bevacizumab</li> <li>• Topotecan/paclitaxel/bevacizumab<sup>1</sup> (category 1)</li> <li>• Cisplatin/paclitaxel (category 1)<sup>2,3</sup></li> <li>• Carboplatin/paclitaxel<sup>4,5</sup> (category 1 for patients who have received prior cisplatin therapy)</li> <li>• Topotecan/paclitaxel<sup>1</sup></li> </ul> <b>Other Recommended Regimens</b> <ul style="list-style-type: none"> <li>• Cisplatin/topotecan<sup>6</sup></li> </ul>	<b>Preferred Regimens</b> <ul style="list-style-type: none"> <li>• Cisplatin<sup>3</sup></li> </ul> <b>Other Recommended Regimens</b> <ul style="list-style-type: none"> <li>• Carboplatin<sup>7</sup></li> <li>• Paclitaxel<sup>8,9</sup></li> </ul>	<b>Preferred Regimens</b> <ul style="list-style-type: none"> <li>• Pembrolizumab for PD-L1–positive<sup>e</sup> or MSI-H/dMMR tumors</li> </ul> <b>Other Recommended Regimens</b> (All agents listed here are category 2B unless otherwise noted) <ul style="list-style-type: none"> <li>• Bevacizumab</li> <li>• Albumin-bound paclitaxel</li> <li>• Docetaxel</li> <li>• Fluorouracil</li> <li>• Gemcitabine</li> <li>• Ifosfamide</li> <li>• Irinotecan</li> <li>• Mitomycin</li> <li>• Pemetrexed</li> <li>• Topotecan</li> <li>• Vinorelbine</li> </ul>

<sup>a</sup>Cisplatin, carboplatin, docetaxel, and paclitaxel may cause drug reactions (See NCCN Guidelines for Ovarian Cancer—Management of Drug Reactions [OV-C]).

<sup>b</sup>Cost and toxicity should be carefully considered when selecting an appropriate regimen for treatment.

<sup>c</sup>If not used previously, these agents can be used as second-line therapy as clinically appropriate.

<sup>d</sup>References for second-line therapy are provided in the Discussion.

<sup>e</sup>Recommended for disease progression on or after chemotherapy in patients whose tumors express PD-L1 (CPS ≥1) as determined by an FDA-approved test.

Version 3.2019 12/17/18 © National Comprehensive Cancer Network, Inc. 2019 All rights reserved.  
The NCCN Guidelines® and this illustration may not be reproduced in any form without the express written permission of NCCN.

**CERV-F**  
**1 OF 2**

tility Sparing),” page 67]. The recommended surgical option is radical hysterectomy and bilateral pelvic lymph node dissection. SLN mapping can also be considered. Para-aortic node dissection is indicated for patients with known or suspected pelvic nodal disease. Less radical surgical approaches for patients with stage IA2 disease are the subject of ongoing investigation.<sup>146,153</sup>

Pelvic external beam RT (EBRT) with brachytherapy (traditionally 70–80 Gy to total point A dose) is a treatment option for patients who are medically inoperable or who refuse surgery.<sup>154</sup> These doses are recommended for most patients based on summation of conventional external-beam fractionation and low dose-rate (40–70 cGy/h) brachytherapy equivalents. Treatment should be modified based on normal tissue tolerance, fractionation, and size of target volume or on biologic equivalence calculations when using high dose-rate brachytherapy.

### Stage IB and IIA Disease

Depending on stage and disease bulk, patients with stage IB or IIA tumors can be treated with surgery, RT, or concurrent chemoradiation. Fertility-sparing surgery is only recommended for select patients with stage IB1 disease (see subsequent section). A combined PET/CT

scan can be performed to rule out extrapelvic disease before deciding how to treat these patients. The GOG considers that surgical staging is an option for patients with advanced cervical cancer. Radiologic imaging is recommended for assessing stage IB2 and IIA2 tumors (see “Principles of Imaging,” available online, in these guidelines, at NCCN.org).

### Stage IB1: Fertility-Sparing

For patients who desire fertility preservation, radical trachelectomy and pelvic lymph node dissection with (or without) para-aortic lymph node dissection is an option for stage IB1 disease, but typically only for tumors 2 cm or less [see “Primary Treatment (Fertility Sparing),” page 66].<sup>48,147–150,155</sup> SLN mapping can also be considered. Tumors that are 2 to 4 cm have to be carefully selected for a fertility-sparing approach because many of these patients may require postoperative adjuvant therapy due to pathologic risk factors (eg, Sedlis criteria or positive nodes). However, some surgeons suggest that a 2-cm cutoff may be used for vaginal trachelectomy, whereas a 4-cm cutoff may be used for abdominal trachelectomy.<sup>156</sup> In one study, oncologic outcomes were similar after 4 years when comparing radical trachelectomy with radical hysterectomy for patients with stage IB1 cervical car-



SYSTEMIC THERAPY REGIMENS FOR CERVICAL CANCER  
REFERENCES

- <sup>1</sup>Tewari KS, Sill MW, Long HJ 3rd, et al. Improved survival with bevacizumab in advanced cervical cancer. *N Engl J Med* 2014 Feb 20;370:734-43.
- <sup>2</sup>Monk BJ, Sill MW, McMeekin DS, et al. Phase III trial of four cisplatin-containing doublet combinations in stage IVB, recurrent, or persistent cervical carcinoma: A Gynecologic Oncology Group study. *J Clin Oncol* 2009;27:4649-4655.
- <sup>3</sup>Moore DH, Blessing JA, McQuellon RP, et al. Phase III study of cisplatin with or without paclitaxel in stage IVB, recurrent, or persistent squamous cell carcinoma of the cervix: a gynecologic oncology group study. *J Clin Oncol* 2004;22:3113-3119.
- <sup>4</sup>Moore KN, Herzog TJ, Lewin S, et al. A comparison of cisplatin/paclitaxel and carboplatin/paclitaxel in stage IVB, recurrent or persistent cervical cancer. *Gynecol Oncol* 2007;105:299-303.
- <sup>5</sup>Kitagawa R, Katsumata N, Shibata T, et al. Paclitaxel plus carboplatin versus paclitaxel plus cisplatin in metastatic or recurrent cervical cancer: the open-label randomized phase III trial JCOG0505. *J Clin Oncol* 2015;33:2129-2135.
- <sup>6</sup>Long HJ 3rd, Bundy BN, Grendys EC Jr., et al. Randomized phase III trial of cisplatin with or without topotecan in carcinoma of the uterine cervix: a Gynecologic Oncology Group Study. *J Clin Oncol* 2005;23:4626-4633.
- <sup>7</sup>Weiss GR, Green S, Hannigan EV, et al. A phase II trial of carboplatin for recurrent or metastatic squamous carcinoma of the uterine cervix: a Southwest Oncology Group study. *Gynecol Oncol* 1990;39:332-336.
- <sup>8</sup>Tinker AV, Bhagat K, Swenerton KD, Hoskins PJ. Carboplatin and paclitaxel for advanced and recurrent cervical carcinoma: the British Columbia Cancer Agency experience. *Gynecol Oncol* 2005;98:54-58.
- <sup>9</sup>McGuire WP, Blessing JA, Moore D, et al. Paclitaxel has moderate activity in squamous cervix cancer. A Gynecologic Oncology Group study. *J Clin Oncol* 1996;14:792-795.

Version 3.2019 12/17/18 © National Comprehensive Cancer Network, Inc. 2019 All rights reserved.  
The NCCN Guidelines® and this illustration may not be reproduced in any form without the express written permission of NCCN.

CERV-F  
2 OF 2

cinoma.<sup>48</sup> Stage IB1 small cell neuroendocrine histology, gastric type adenocarcinoma, and adenoma malignum are not considered suitable for fertility-sparing surgery.

#### Stage IB and IIA: Non-Fertility-Sparing

For stage IB1 and IIA1 disease, primary surgery consists of radical hysterectomy plus bilateral pelvic lymph node dissection (category 1), with (or without) para-aortic lymph node dissection (category 2B for para-aortic lymph node dissection).<sup>122,157</sup> SLN mapping can also be considered for stages IB1 and IIA1. Panel members feel that surgery is the most appropriate option for patients with stage IB1 or IIA1 disease, whereas concurrent chemoradiation is the most appropriate option for those with stage IB2 or IIA2 disease based on randomized trials.<sup>121-123,125,126</sup> Thus, the primary surgical option is a category 1 recommendation for patients with stage IB1 or IIA1 disease; however, primary chemoradiation is the category 1 recommendation for those with stage IB2 or IIA2 disease. Para-aortic node dissection may be performed for patients with larger tumors and suspected or known pelvic nodal disease. Some panel members feel that a pelvic lymph node dissection should be performed first and, if negative, then the radical hysterectomy should be performed. If the lymph nodes are posi-

tive, then the hysterectomy should be abandoned; these patients should undergo chemoradiation. For patients with stage IB or IIA tumors (including those who are not candidates for hysterectomy), another option is combined pelvic EBRT and brachytherapy with (or without) concurrent platinum-containing chemotherapy [see "Primary Treatment (Non-Fertility Sparing)," page 68]. Preferred radiosensitizing regimens include cisplatin or carboplatin for patients who are cisplatin intolerant. Other recommended regimens include cisplatin/fluorouracil. Although concurrent chemoradiation has been proven effective in the definitive treatment of more advanced-stage disease, this approach has not been specifically studied in patients with stage IB1 or IIA1 disease. Careful consideration of the risk/benefit ratio should be undertaken in these patients with smaller tumors.

For patients with clinical stage IB2 or IIA2 tumors who are treated with definitive radiation, concurrent cisplatin-containing chemotherapy has been shown to significantly improve patient survival. The panel recommends definitive EBRT with concurrent platinum-containing chemotherapy and brachytherapy (traditionally 75–80 Gy to total point A dose). Again, treatment should be modified based on normal tissue tolerance, fractionation, and size of target volume. Primary chemoradi-

ation has a category 1 recommendation [see “Primary Treatment (Non-Fertility Sparing),” page 68].<sup>122,123</sup>

For stage IB2 or IIA2 tumors, the panel had a major disagreement about recommending adjuvant hysterectomy (category 3) (also known as completion surgery) after primary chemoradiation.<sup>122</sup> Adjuvant hysterectomy after RT has been shown to improve pelvic control, but not overall survival, and is associated with increased morbidity.<sup>158</sup> A recent Cochrane review examined whether the addition of hysterectomy to standard nonsurgical treatments benefitted women with locally advanced cervical cancer, finding insufficient data to demonstrate a survival benefit associated with surgery.<sup>159</sup> The morbidity is higher after completion surgery but this may be reduced using a laparoscopic technique.<sup>160–163</sup> Although routine completion hysterectomy is not typically performed, this approach may be considered in patients whose extent of disease or uterine anatomy precludes adequate coverage by brachytherapy.

### Advanced Disease

This category has traditionally included patients with stage IIB to IVA disease (ie, locally advanced disease). However, many oncologists now include patients with IB2 and IIA2 disease in the advanced disease category. For patients with more advanced tumors who are undergoing primary chemoradiation, the volume of RT is critical and guided by assessment of nodal involvement in the pelvic and para-aortic nodes. Radiologic imaging studies (including PET/CT) are recommended for stage IB2 or greater disease, especially for evaluation of nodal or extrapelvic tumor (see “Principles of Imaging,” available online, in these guidelines, at NCCN.org). MRI is useful to describe local disease extent and assist in radiation treatment planning. However, needle biopsy of extrauterine abnormality can be considered for questionable imaging findings. Surgical staging (ie, extraperitoneal or laparoscopic lymph node dissection) is also an option (category 2B) for these patients.<sup>164</sup> Surgical staging may also detect microscopic nodal disease that is not discernable with radiologic imaging.<sup>165</sup>

For patients without nodal disease or with disease limited to the pelvis only through surgical staging, treatment consists of pelvic EBRT with concurrent platinum-containing chemotherapy and brachytherapy (category 1).<sup>113,114,123,125–127,166</sup> Currently, acceptable concurrent platinum-containing regimens include either weekly cisplatin (preferred), carboplatin (preferred if cisplatin intolerant), or cisplatin/fluorouracil, given every 3 to 4 weeks during RT. An international phase III randomized trial reported that concurrent cisplatin/gemcitabine and EBRT followed by 2 additional cycles of cisplatin/gemcitabine after RT improved PFS and OS when compared with a standard regimen of concurrent cisplatin with pel-

vic EBRT.<sup>167</sup> However, this trial is controversial because of changes in its statistical design and because the reported superior regimen of concurrent cisplatin/gemcitabine and EBRT has unresolved toxicity issues.<sup>167–170</sup>

However, for patients with positive para-aortic and pelvic lymph nodes by imaging, imaging workup for metastatic disease is recommended. Extended-field EBRT, concurrent platinum-containing chemotherapy, and brachytherapy is recommended (see “Primary Treatment” in the algorithm). Patients with positive para-aortic lymph nodes who are positive for distant metastases are treated with systemic chemotherapy (see “Systemic Therapy Regimens for Cervical Cancer,” page 76) with (or without) individualized EBRT.<sup>171</sup>

### Adjuvant Treatment

Adjuvant treatment is indicated after radical hysterectomy depending on surgical findings and disease stage. Observation is appropriate for patients with stage IA2, IB1, or IIA1 disease who have negative nodes, negative margins, negative parametria, and no cervical risk factors after radical hysterectomy (Sedlis criteria). However, adjuvant treatment is indicated after radical hysterectomy if pathologic risk factors are discovered.

Pelvic EBRT is recommended (category 1) with (or without) concurrent platinum-containing chemotherapy (category 2B for chemotherapy) for patients with stage IA2, IB1, or IIA1 disease who have *negative* lymph nodes after surgery but have large primary tumors, deep stromal invasion, and/or LVSI.<sup>27,172–175</sup> Recommended radiosensitizing regimens include cisplatin (preferred), carboplatin (preferred if cisplatin intolerant), or cisplatin/fluorouracil.

Adjuvant pelvic RT alone versus no further therapy was tested in a randomized trial (GOG 92) of selected patients with node-negative stage IB carcinoma of the cervix after hysterectomy and pelvic lymphadenectomy.<sup>27</sup> Patients were considered to have “intermediate-risk” disease and were eligible for this trial if they had at least 2 of the following risk factors (commonly referred to as Sedlis criteria): (1) greater than one-third stromal invasion; (2) capillary lymphatic space involvement; or (3) cervical tumor diameters more than 4 cm. Patients with positive lymph nodes or involved surgical margins were excluded. At 2 years, the recurrence-free rates were 88% for adjuvant RT versus 79% for the no-adjuvant-treatment group. After long-term follow-up (12 years), an updated analysis confirmed that adjuvant pelvic RT increased PFS; a clear trend towards improved OS was noted ( $P=.07$ ).<sup>172</sup> The role of concurrent cisplatin/RT in patients with intermediate-risk disease is currently being evaluated in an international phase III randomized trial (GOG 263, Clinicaltrials.gov Identifier: NCT01101451).

Potentially important risk factors for recurrence may not be limited to the Sedlis criteria (ie, stromal invasion, LVSI, primary tumor size). Additional risk factors for consideration include tumor histology (eg, adenocarcinoma component)<sup>28,29</sup> and close or positive surgical margins.<sup>30,31</sup>

Postoperative pelvic EBRT with concurrent platinum-containing chemotherapy (category 1)<sup>124</sup> with (or without) vaginal brachytherapy is recommended for patients with positive pelvic nodes, positive surgical margin, and/or positive parametrium; these patients are considered to have “high-risk” disease. Vaginal brachytherapy may be a useful boost for those with positive vaginal mucosal margins. Adjuvant concurrent chemoradiation significantly improves OS for patients with high-risk, early-stage disease (those with positive pelvic nodes, parametrial extension, and/or positive margins) who undergo radical hysterectomy and pelvic lymphadenectomy.<sup>124</sup> The Intergroup trial 0107/GOG 109 showed a statistically significant benefit of adjuvant pelvic radiation with concurrent cisplatin and fluorouracil in the treatment of patients with stage IA2, IB, or IIA disease who had positive lymph nodes, positive margins, and/or microscopic parametrial involvement found at surgery.<sup>124</sup> A recent study re-evaluated these findings from GOG 109 in a population-based cohort (n=3,053) in the National Cancer Database, confirming the survival benefit of adjuvant chemoradiation but suggesting that this benefit may be best realized in patients with lymph node involvement.<sup>176</sup>

Depending on the results of primary surgery, imaging may be recommended to determine whether distant metastases are present. In women who are positive for distant metastases, perform biopsy of suspicious areas as indicated. For patients without distant metastases, recommended treatment is extended-field EBRT (including pelvic and para-aortic lymph nodes) with concurrent platinum-containing chemotherapy and with (or without) brachytherapy. Recommended radiosensitizing regimens include cisplatin (preferred), carboplatin

(preferred if cisplatin intolerant), or cisplatin/fluorouracil. For patients with distant metastases, recommended treatment is systemic chemotherapy (see “Systemic Therapy Regimens for Cervical Cancer,” page 76) with (or without) individualized EBRT.<sup>171</sup>

Although neoadjuvant chemotherapy followed by surgery has been used in areas where RT is not available, data suggest no improvement in survival when compared with surgery alone for early-stage cervical cancer<sup>177–179</sup> or locally advanced cervical cancer.<sup>180,181</sup> A meta-analysis of data on patients with stage IB1 to IIA cervical cancer found that neoadjuvant chemotherapy may reduce the need for adjuvant RT by decreasing tumor size and metastases, but indicated no OS benefit.<sup>181</sup> However, data from a second meta-analysis suggested that response to neoadjuvant chemotherapy was a strong prognostic factor for PFS and OS.<sup>182,183</sup> Outside of the clinical trial, the panel does not recommend the use of neoadjuvant chemotherapy.

## Recurrent or Metastatic Disease

For recommendations regarding recurrent or metastatic disease, please see the full guidelines at NCCN.org.

## Summary

Cervical cancer is decreasing in the United States because of the wide use of screening; however, it is increasing in developing countries (approximately 275,000 deaths/year), because screening is not available to many women. Effective treatment for cervical cancer (including surgery and concurrent chemoradiation) can yield cures in 80% of women with early-stage disease (stages I–II) and in 60% of women with stage III disease. The hope is that immunization against HPV (using vaccines) will prevent persistent infection with the types of HPV against which the vaccine is designed, and will therefore prevent specific HPV cancer in women.<sup>184–186</sup>

## References

- Amit A, Schink J, Reiss A, Lowenstein L. PET/CT in gynecologic cancer: present applications and future prospects—a clinician's perspective. *Obstet Gynecol Clin North Am* 2011;38:1–21, vii.
- Patel S, Liyanage SH, Sahdev A, et al. Imaging of endometrial and cervical cancer. *Insights Imaging* 2010;1:309–328.
- ACOG practice bulletin. Diagnosis and treatment of cervical carcinomas. Number 35, May 2002. American College of Obstetricians and Gynecologists. *Int J Gynaecol Obstet* 2002;78:79–91.
- Gold MA, Tian C, Whitney CW, et al. Surgical versus radiographic determination of para-aortic lymph node metastases before chemoradiation for locally advanced cervical carcinoma: a Gynecologic Oncology Group Study. *Cancer* 2008;112:1954–1963.
- Monk BJ, Tian C, Rose PG, Lanciano R. Which clinical/pathologic factors matter in the era of chemoradiation as treatment for locally advanced cervical carcinoma? Analysis of two Gynecologic Oncology Group (GOG) trials. *Gynecol Oncol* 2007;105:427–433.
- Sherman ME, Wang SS, Carreon J, Devesa SS. Mortality trends for cervical squamous and adenocarcinoma in the United States. Relation to incidence and survival. *Cancer* 2005;103:1258–1264.
- Sasieni P, Castanon A, Cuzick J. Screening and adenocarcinoma of the cervix. *Int J Cancer* 2009;125:525–529.
- Siegel CL, Andreotti RF, Cardenas HR, et al. ACR Appropriateness Criteria(R) pretreatment planning of invasive cancer of the cervix. *J Am Coll Radiol* 2012;9:395–402.
- Pecorelli S, Zigliani L, Odicino F. Revised FIGO staging for carcinoma of the cervix. *Int J Gynaecol Obstet* 2009;105:107–108.
- Moore DH. Surgical staging and cervical cancer: after 30 years, have we reached a conclusion? *Cancer* 2008;112:1874–1876.
- Pecorelli S. Revised FIGO staging for carcinoma of the vulva, cervix, and endometrium. *Int J Gynaecol Obstet* 2009;105:103–104.
- Cervix Uteri Cancer Staging. American Joint Committee on Cancer; Available at: <http://cancerstaging.org/references-tools/quickreferences/Documents/CervixMedium.pdf>. Accessed July 3, 2014.
- How is cervical cancer staged? American Cancer Society; 2014. Avail-

- able at: <http://www.cancer.org/acs/groups/cid/documents/webcontent/003094-pdf.pdf>. Accessed July 3, 2014.
14. Hricak H, Gatsonis C, Coakley FV, et al. Early invasive cervical cancer: CT and MR imaging in preoperative evaluation—ACRIN/GOG comparative study of diagnostic performance and interobserver variability. *Radiology* 2007;245:491–498.
  15. Woo S, Kim HS, Chung HH, et al. Early stage cervical cancer: role of magnetic resonance imaging after conization in determining residual tumor. *Acta Radiol* 2016;57:1268–1276.
  16. Mitchell DG, Snyder B, Coakley F, et al. Early invasive cervical cancer: tumor delineation by magnetic resonance imaging, computed tomography, and clinical examination, verified by pathologic results, in the ACRIN 6651/GOG 183 Intergroup Study. *J Clin Oncol* 2006;24:5687–5694.
  17. Downey K, Jafar M, Attygalle AD, et al. Influencing surgical management in patients with carcinoma of the cervix using a T2- and ZOON-diffusion-weighted endovaginal MRI technique. *Br J Cancer* 2013;109:615–622.
  18. Lakhman Y, Akin O, Park KJ, et al. Stage IB1 cervical cancer: role of preoperative MR imaging in selection of patients for fertility-sparing radical trachelectomy. *Radiology* 2013;269:149–158.
  19. Downey K, Shepherd JH, Attygalle AD, et al. Preoperative imaging in patients undergoing trachelectomy for cervical cancer: validation of a combined T2- and diffusion-weighted endovaginal MRI technique at 3.0 T. *Gynecol Oncol* 2014;133:326–332.
  20. de Boer P, Adam JA, Buist MR, et al. Role of MRI in detecting involvement of the uterine internal os in uterine cervical cancer: systematic review of diagnostic test accuracy. *Eur J Radiol* 2013;82:e422–428.
  21. Thomeer MG, Gerestein C, Spronk S, et al. Clinical examination versus magnetic resonance imaging in the pretreatment staging of cervical carcinoma: systematic review and meta-analysis. *Eur Radiol* 2013;23:2005–2018.
  22. Park JY, Kim EN, Kim DY, et al. Comparison of the validity of magnetic resonance imaging and positron emission tomography/computed tomography in the preoperative evaluation of patients with uterine corpus cancer. *Gynecol Oncol* 2008;108:486–492.
  23. Lin SY, Tsai CS, Chang YC, et al. The role of pretreatment FDG-PET in treating cervical cancer patients with enlarged pelvic lymph node(s) shown on MRI: a phase 3 randomized trial with long-term follow-up. *Int J Radiat Oncol Biol Phys* 2015;92:577–585.
  24. Boughanim M, Lebouilleux S, Rey A, et al. Histologic results of para-aortic lymphadenectomy in patients treated for stage IB2/II cervical cancer with negative [18F]fluorodeoxyglucose positron emission tomography scans in the para-aortic area. *J Clin Oncol* 2008;26:2558–2561.
  25. Zhao Q, Feng Y, Mao X, Qie M. Prognostic value of fluorine-18-fluorodeoxyglucose positron emission tomography or PET-computed tomography in cervical cancer: a meta-analysis. *Int J Gynecol Cancer* 2013;23:1184–1190.
  26. Gee MS, Atri M, Bandos AI, et al. Identification of distant metastatic disease in uterine cervical and endometrial cancers with FDG PET/CT: analysis from the ACRIN 6671/GOG 0233 Multicenter Trial. *Radiology* 2018;287:176–184.
  27. Sedlis A, Bundy BN, Rotman MZ, et al. A randomized trial of pelvic radiation therapy versus no further therapy in selected patients with stage IB carcinoma of the cervix after radical hysterectomy and pelvic lymphadenectomy: A Gynecologic Oncology Group Study. *Gynecol Oncol* 1999;73:177–183.
  28. Ryu SY, Kim MH, Nam BH, et al. Intermediate-risk grouping of cervical cancer patients treated with radical hysterectomy: a Korean Gynecologic Oncology Group study. *Br J Cancer* 2014;110:278–285.
  29. Noh JM, Park W, Kim YS, et al. Comparison of clinical outcomes of adenocarcinoma and adenosquamous carcinoma in uterine cervical cancer patients receiving surgical resection followed by radiotherapy: a multicenter retrospective study (KROG 13–10). *Gynecol Oncol* 2014;132:618–623.
  30. Diaz ES, Aoyama C, Baquing MA, et al. Predictors of residual carcinoma or carcinoma-in-situ at hysterectomy following cervical conization with positive margins. *Gynecol Oncol* 2014;132:76–80.
  31. Estape RE, Angioli R, Madrigal M, et al. Close vaginal margins as a prognostic factor after radical hysterectomy. *Gynecol Oncol* 1998;68:229–232.
  32. Parra-Herran C, Taljaard M, Djordjevic B, et al. Pattern-based classification of invasive endocervical adenocarcinoma, depth of invasion measurement and distinction from adenocarcinoma in situ: interobserver variation among gynecologic pathologists. *Mod Pathol* 2016;29:879–892.
  33. Roma AA, Mistretta TA, Diaz De Vivar A, et al. New pattern-based personalized risk stratification system for endocervical adenocarcinoma with important clinical implications and surgical outcome. *Gynecol Oncol* 2016;141:36–42.
  34. Rutgers JK, Roma AA, Park KJ, et al. Pattern classification of endocervical adenocarcinoma: reproducibility and review of criteria. *Mod Pathol* 2016;29:1083–1094.
  35. Bentivegna E, Gouy S, Maulard A, et al. Oncological outcomes after fertility-sparing surgery for cervical cancer: a systematic review. *Lancet Oncol* 2016;17:e240–253.
  36. Ueki M, Okamoto Y, Misaki O, et al. Conservative therapy for microinvasive carcinoma of the uterine cervix. *Gynecol Oncol* 1994;53:109–113.
  37. Al-Kalbani M, McVeigh G, Nagar H, McCluggage WG. Do FIGO stage IA and small ( $\leq 2$  cm) IB1 cervical adenocarcinomas have a good prognosis and warrant less radical surgery? *Int J Gynecol Cancer* 2012;22:291–295.
  38. Webb JC, Key CR, Qualls CR, Smith HO. Population-based study of microinvasive adenocarcinoma of the uterine cervix. *Obstet Gynecol* 2001;97:701–706.
  39. Sevin BU, Nadjji M, Averette HE, et al. Microinvasive carcinoma of the cervix. *Cancer* 1992;70:2121–2128.
  40. Huang LW, Hwang JL. A comparison between loop electrosurgical excision procedure and cold knife conization for treatment of cervical dysplasia: residual disease in a subsequent hysterectomy specimen. *Gynecol Oncol* 1999;73:12–15.
  41. Miroshnichenko GG, Parva M, Holtz DO, et al. Interpretability of excisional biopsies of the cervix: cone biopsy and loop excision. *J Low Genit Tract Dis* 2009;13:10–12.
  42. Greenspan DL, Faubion M, Coonrod DV, et al. Compliance after loop electrosurgical excision procedure or cold knife cone biopsy. *Obstet Gynecol* 2007;110:675–680.
  43. Fanning J, Padratz J. Cold knife conization vs. LEEP. Are they the same procedure? *J Reprod Med* 2002;47:33–35.
  44. Simmons JR, Anderson L, Hernandez E, Heller PB. Evaluating cervical neoplasia. LEEP as an alternative to cold knife conization. *J Reprod Med* 1998;43:1007–1013.
  45. Kim MK, Kim MA, Kim JW, et al. Loop electrosurgical excision procedure findings for identification of patients with early-stage cervical cancer suitable for less radical surgery. *Int J Gynecol Cancer* 2012;22:1214–1219.
  46. Bouchard-Fortier G, Reade CJ, Covens A. Non-radical surgery for small early-stage cervical cancer. Is it time? *Gynecol Oncol* 2014;132:624–627.
  47. Kato T, Takashima A, Kasamatsu T, et al. Clinical tumor diameter and prognosis of patients with FIGO stage IB1 cervical cancer (JCOG0806-A). *Gynecol Oncol* 2015;137:34–39.
  48. Diaz JP, Sonoda Y, Leitao MM, et al. Oncologic outcome of fertility-sparing radical trachelectomy versus radical hysterectomy for stage IB1 cervical carcinoma. *Gynecol Oncol* 2008;111:255–260.
  49. Abu-Rustum NR, Tal MN, DeLair D, et al. Radical abdominal trachelectomy for stage IB1 cervical cancer at 15-week gestation. *Gynecol Oncol* 2010;116:151–152.
  50. Ramirez PT, Pareja R, Rendon GJ, et al. Management of low-risk early-stage cervical cancer: should conization, simple trachelectomy, or simple hysterectomy replace radical surgery as the new standard of care? *Gynecol Oncol* 2014;132:254–259.
  51. Dargent D, Martin X, Sacchetoni A, Mathevet P. Laparoscopic vaginal radical trachelectomy: a treatment to preserve the fertility of cervical carcinoma patients. *Cancer* 2000;88:1877–1882.
  52. Viswanathan AN, Deavers MT, Jhingran A, et al. Small cell neuroendocrine carcinoma of the cervix: outcome and patterns of recurrence. *Gynecol Oncol* 2004;93:27–33.
  53. Young RH, Clement PB. Endocervical adenocarcinoma and its variants: their morphology and differential diagnosis. *Histopathology* 2002;41:185–207.
  54. Cao DY, Yang JX, Wu XH, et al. Comparisons of vaginal and abdominal radical trachelectomy for early-stage cervical cancer: preliminary results of a multi-center research in China. *Br J Cancer* 2013;109:2778–2782.
  55. Plante M, Gregoire J, Renaud MC, Roy M. The vaginal radical trachelectomy: an update of a series of 125 cases and 106 pregnancies. *Gynecol Oncol* 2011;121:290–297.
  56. Abu-Rustum NR, Sonoda Y, Black D, et al. Fertility-sparing radical abdominal trachelectomy for cervical carcinoma: technique and review of the literature. *Gynecol Oncol* 2006;103:807–813.
  57. Einstein MH, Park KJ, Sonoda Y, et al. Radical vaginal versus abdominal



- trachelectomy for stage IB1 cervical cancer: a comparison of surgical and pathologic outcomes. *Gynecol Oncol* 2009;112:73–77.
58. Wethington SL, Cibula D, Duska LR, et al. An international series on abdominal radical trachelectomy: 101 patients and 28 pregnancies. *Int J Gynecol Cancer* 2012;22:1251–1257.
  59. Abu-Rustum NR, Sonoda Y. Fertility-sparing surgery in early-stage cervical cancer: indications and applications. *J Natl Compr Canc Netw* 2010;8:1435–1438.
  60. Beiner ME, Covens A. Surgery insight: radical vaginal trachelectomy as a method of fertility preservation for cervical cancer. *Nat Clin Pract Oncol* 2007;4:353–361.
  61. Pareja R, Rendon GJ, Sanz-Lomana CM, et al. Surgical, oncological, and obstetrical outcomes after abdominal radical trachelectomy—a systematic literature review. *Gynecol Oncol* 2013;131:77–82.
  62. Lintner B, Saso S, Tarnai L, et al. Use of abdominal radical trachelectomy to treat cervical cancer greater than 2 cm in diameter. *Int J Gynecol Cancer* 2013;23:1065–1070.
  63. Wethington SL, Sonoda Y, Park KJ, et al. Expanding the indications for radical trachelectomy: a report on 29 patients with stage IB1 tumors measuring 2 to 4 centimeters. *Int J Gynecol Cancer* 2013;23:1092–1098.
  64. Lanowska M, Mangler M, Speiser D, et al. Radical vaginal trachelectomy after laparoscopic staging and neoadjuvant chemotherapy in women with early-stage cervical cancer over 2 cm: oncologic, fertility, and neonatal outcome in a series of 20 patients. *Int J Gynecol Cancer* 2014;24:586–593.
  65. Shepherd JH, Spencer C, Herod J, Ind TEJ. Radical vaginal trachelectomy as a fertility-sparing procedure in women with early-stage cervical cancer-cumulative pregnancy rate in a series of 123 women. *BJOG* 2006;113:719–724.
  66. Park JY, Kim DY, Suh DS, et al. Reproductive outcomes after laparoscopic radical trachelectomy for early-stage cervical cancer. *J Gynecol Oncol* 2014;25:9–13.
  67. Gizzo S, Ancona E, Saccardi C, et al. Radical trachelectomy: the first step of fertility preservation in young women with cervical cancer (review). *Oncol Rep* 2013;30:2545–2554.
  68. Cibula D, Abu-Rustum NR, Benedetti-Panici P, et al. New classification system of radical hysterectomy: emphasis on a three-dimensional anatomic template for parametrial resection. *Gynecol Oncol* 2011;122:264–268.
  69. Querleu D, Morrow CP. Classification of radical hysterectomy. *Lancet Oncol* 2008;9:297–303.
  70. Piver MS, Rutledge F, Smith JP. Five classes of extended hysterectomy for women with cervical cancer. *Obstet Gynecol* 1974;44:265–272.
  71. Chi DS, Abu-Rustum NR, Plante M, Roy M. Cancer of the cervix. In: Rock JA, Jones HW, eds. *TeLinde's Operative Gynecology*, 10th ed. Philadelphia: Lippincott Williams and Wilkins; 2008:1227.
  72. Whitney CW, Spirtos NM. *Gynecologic Oncology Group Surgical Procedures Manual*. Philadelphia: Gynecologic Oncology Group; 2009. Available at: <https://gogmember.gog.org/manuals/pdf/surgman.pdf>. Accessed April 18, 2014.
  73. Sardain H, Lavoue V, Redpath M, et al. Curative pelvic exenteration for recurrent cervical carcinoma in the era of concurrent chemotherapy and radiation therapy. A systematic review. *Eur J Surg Oncol* 2015;41:975–985.
  74. Chiantera V, Rossi M, De Iaco P, et al. Morbidity after pelvic exenteration for gynecological malignancies: a retrospective multicentric study of 230 patients. *Int J Gynecol Cancer* 2014;24:156–164.
  75. Cormier B, Diaz JP, Shih K, et al. Establishing a sentinel lymph node mapping algorithm for the treatment of early cervical cancer. *Gynecol Oncol* 2011;122:275–280.
  76. Lecuru F, Mathevet P, Querleu D, et al. Bilateral negative sentinel nodes accurately predict absence of lymph node metastasis in early cervical cancer: results of the SENTICOL study. *J Clin Oncol* 2011;29:1686–1691.
  77. Altgassen C, Hertel H, Brandstadt A, et al. Multicenter validation study of the sentinel lymph node concept in cervical cancer: AGO Study Group. *J Clin Oncol* 2008;26:2943–2951.
  78. Bats AS, Buenerd A, Querleu D, et al. Diagnostic value of intraoperative examination of sentinel lymph node in early cervical cancer: a prospective, multicenter study. *Gynecol Oncol* 2011;123:230–235.
  79. Bats AS, Mathevet P, Buenerd A, et al. The sentinel node technique detects unexpected drainage pathways and allows nodal ultrastaging in early cervical cancer: insights from the multicenter prospective SENTICOL study. *Ann Surg Oncol* 2013;20:413–422.
  80. Cibula D, Abu-Rustum NR, Dusek L, et al. Bilateral ultrastaging of sentinel lymph node in cervical cancer: Lowering the false-negative rate and improving the detection of micrometastasis. *Gynecol Oncol* 2012;127:462–466.
  81. Cibula D, Abu-Rustum NR, Dusek L, et al. Prognostic significance of low volume sentinel lymph node disease in early-stage cervical cancer. *Gynecol Oncol* 2012;124:496–501.
  82. Fader AN, Edwards RP, Cost M, et al. Sentinel lymph node biopsy in early-stage cervical cancer: utility of intraoperative versus postoperative assessment. *Gynecol Oncol* 2008;111:13–17.
  83. Lecuru F, Bats A, Mathevet P, et al. Impact of sentinel lymph node biopsy on staging of early cervical cancer: Results of a prospective, multicenter study [abstract]. *J Clin Oncol* 2009;27(Suppl 18):Abstract CRA5506.
  84. Slama J, Dunder P, Dusek L, Cibula D. High false negative rate of frozen section examination of sentinel lymph nodes in patients with cervical cancer. *Gynecol Oncol* 2013;129:384–388.
  85. van de Lande J, Torrença B, Rajmakers PGHM, et al. Sentinel lymph node detection in early stage uterine cervix carcinoma: a systematic review. *Gynecol Oncol* 2007;106:604–613.
  86. Andikyan V, Khoury-Collado F, Denesopolis J, et al. Cervical conization and sentinel lymph node mapping in the treatment of stage I cervical cancer: is less enough? *Int J Gynecol Cancer* 2014;24:113–117.
  87. Wu Y, Li Z, Wu H, Yu J. Sentinel lymph node biopsy in cervical cancer: a meta-analysis. *Mol Clin Oncol* 2013;1:1025–1030.
  88. Kadkhodayan S, Hasanzadeh M, Treglia G, et al. Sentinel node biopsy for lymph nodal staging of uterine cervix cancer: a systematic review and meta-analysis of the pertinent literature. *Eur J Surg Oncol* 2015;41:1–20.
  89. Ruscito I, Gasparri ML, Braicu EI, et al. Sentinel node mapping in cervical and endometrial cancer: indocyanine green versus other conventional dyes—a meta-analysis. *Ann Surg Oncol* 2016;23:3749–3756.
  90. Frumovitz M, Plante M, Lee PS, et al. The FILM Trial: a randomized phase III multicenter study assessing near infrared fluorescence in the identification of sentinel lymph nodes (SLN) [Abstract]. *Gynecologic Oncology* 2018;149:7.
  91. Eiriksson LR, Covens A. Sentinel lymph node mapping in cervical cancer: the future? *BJOG* 2012;119:129–133.
  92. Bats AS, Frati A, Mathevet P, et al. Contribution of lymphoscintigraphy to intraoperative sentinel lymph node detection in early cervical cancer: analysis of the prospective multicenter SENTICOL cohort. *Gynecol Oncol* 2015;137:264–269.
  93. Darlin L, Persson J, Bossmar T, et al. The sentinel node concept in early cervical cancer performs well in tumors smaller than 2 cm. *Gynecol Oncol* 2010;117:266–269.
  94. Sakuragi N, Satoh C, Takeda N, et al. Incidence and distribution pattern of pelvic and paraaortic lymph node metastasis in patients with stages IB, IIA, and IIB cervical carcinoma treated with radical hysterectomy. *Cancer* 1999;85:1547–1554.
  95. Huang H, Liu J, Li Y, et al. Metastasis to deep obturator and para-aortic lymph nodes in 649 patients with cervical carcinoma. *Eur J Surg Oncol* 2011;37:978–983.
  96. Gouy S, Morice P, Narducci F, et al. Prospective multicenter study evaluating the survival of patients with locally advanced cervical cancer undergoing laparoscopic para-aortic lymphadenectomy before chemoradiotherapy in the era of positron emission tomography imaging. *J Clin Oncol* 2013;31:3026–3033.
  97. Frumovitz M, Querleu D, Gil-Moreno A, et al. Lymphadenectomy in locally advanced cervical cancer study (LiLACS): Phase III clinical trial comparing surgical with radiologic staging in patients with stages IB2–IVA cervical cancer. *J Minim Invasive Gynecol* 2014;21:3–8.
  98. Chen Y, Xu H, Li Y, et al. The outcome of laparoscopic radical hysterectomy and lymphadenectomy for cervical cancer: a prospective analysis of 295 patients. *Ann Surg Oncol* 2008;15:2847–2855.
  99. Puntambekar SP, Palep RJ, Puntambekar SS, et al. Laparoscopic total radical hysterectomy by the Pune technique: our experience of 248 cases. *J Minim Invasive Gynecol* 2007;14:682–689.
  100. Nam JH, Park JY, Kim DY, et al. Laparoscopic versus open radical hysterectomy in early-stage cervical cancer: long-term survival outcomes in a matched cohort study. *Ann Oncol* 2012;23:903–911.
  101. Wang YZ, Deng L, Xu HC, et al. Laparoscopy versus laparotomy for the management of early stage cervical cancer. *BMC Cancer* 2015;15:928.
  102. Sert BM, Boggess JF, Ahmad S, et al. Robot-assisted versus open radical hysterectomy: a multi-institutional experience for early-stage cervical cancer. *Eur J Surg Oncol* 2016;42:513–522.



103. Mendivil AA, Rettenmaier MA, Abaid LN, et al. Survival rate comparisons amongst cervical cancer patients treated with an open, robotic-assisted or laparoscopic radical hysterectomy: a five year experience. *Surg Oncol* 2016;25:66–71.
104. Park DA, Yun JE, Kim SW, Lee SH. Surgical and clinical safety and effectiveness of robot-assisted laparoscopic hysterectomy compared to conventional laparoscopy and laparotomy for cervical cancer: a systematic review and meta-analysis. *Eur J Surg Oncol* 2017;43:994–1002.
105. Shazly SA, Murad MH, Dowdy SC, et al. Robotic radical hysterectomy in early stage cervical cancer: a systematic review and meta-analysis. *Gynecol Oncol* 2015;138:457–471.
106. Ramirez PT, Frumovitz M, Pareja R, et al. Minimally invasive versus abdominal radical hysterectomy for cervical cancer. *N Engl J Med* 2018;379:1895–1904.
107. Melamed A, Margul DJ, Chen L, et al. Survival after minimally invasive radical hysterectomy for early-stage cervical cancer. *N Engl J Med* 2018;379:1905–1914.
108. Margul DJ, Yang J, Seagle BL, et al. Outcomes and costs of open, robotic, and laparoscopic radical hysterectomy for stage IB1 cervical cancer. *J Clin Oncol* 2018;36:5502.
109. Nevis IF, Vali B, Higgins C, et al. Robot-assisted hysterectomy for endometrial and cervical cancers: a systematic review. *J Robot Surg* 2016.
110. Lowe MP, Chamberlain DH, Kamelle SA, et al. A multi-institutional experience with robotic-assisted radical hysterectomy for early stage cervical cancer. *Gynecol Oncol* 2009;113:191–194.
111. Nezhat FR, Datta MS, Liu C, et al. Robotic radical hysterectomy versus total laparoscopic radical hysterectomy with pelvic lymphadenectomy for treatment of early cervical cancer. *JSLs* 2008;12:227–237.
112. Cantrell LA, Mendivil A, Gehrig PA, Boggess JF. Survival outcomes for women undergoing type III robotic radical hysterectomy for cervical cancer: a 3-year experience. *Gynecol Oncol* 2010;117:260–265.
113. Gaffney DK, Erickson-Wittmann BA, Jhingran A, et al. ACR Appropriateness Criteria(R) on advanced cervical cancer expert panel on radiation oncology-gynecology. *Int J Radiat Oncol Biol Phys* 2011;81:609–614.
114. Monk BJ, Tewari KS, Koh W-J. Multimodality therapy for locally advanced cervical carcinoma: state of the art and future directions. *J Clin Oncol* 2007;25:2952–2965.
115. Gien LT, Beauchemin MC, Thomas G. Adenocarcinoma: a unique cervical cancer. *Gynecol Oncol* 2010;116:140–146.
116. Baalbergen A, Veenstra Y, Stalpers LL, Ansink AC. Primary surgery versus primary radiation therapy with or without chemotherapy for early adenocarcinoma of the uterine cervix. *Cochrane Database Syst Rev* 2010:CD006248.
117. Park JY, Kim DY, Kim JH, et al. Outcomes after radical hysterectomy in patients with early-stage adenocarcinoma of uterine cervix. *Br J Cancer* 2010;102:1692–1698.
118. Wo JY, Viswanathan AN. Impact of radiotherapy on fertility, pregnancy, and neonatal outcomes in female cancer patients. *Int J Radiat Oncol Biol Phys* 2009;73:1304–1312.
119. Pahisa J, Martinez-Roman S, Martinez-Zamora MA, et al. Laparoscopic ovarian transposition in patients with early cervical cancer. *Int J Gynecol Cancer* 2008;18:584–589.
120. Morice P, Juncker L, Rey A, et al. Ovarian transposition for patients with cervical carcinoma treated by radiosurgical combination. *Fertil Steril* 2000;74:743–748.
121. Landoni F, Maneo A, Colombo A, et al. Randomised study of radical surgery versus radiotherapy for stage Ib-IIa cervical cancer. *Lancet* 1997;350:535–540.
122. Keys HM, Bundy BN, Stehman FB, et al. Cisplatin, radiation, and adjuvant hysterectomy compared with radiation and adjuvant hysterectomy for bulky stage IB cervical carcinoma. *N Engl J Med* 1999;340:1154–1161.
123. Morris M, Eifel PJ, Lu J, et al. Pelvic radiation with concurrent chemotherapy compared with pelvic and para-aortic radiation for high-risk cervical cancer. *N Engl J Med* 1999;340:1137–1143.
124. Peters WA, Liu PY, Barrett RJ, et al. Concurrent chemotherapy and pelvic radiation therapy compared with pelvic radiation therapy alone as adjuvant therapy after radical surgery in high-risk early-stage cancer of the cervix. *J Clin Oncol* 2000;18:1606–1613.
125. Whitney CW, Sause W, Bundy BN, et al. Randomized comparison of fluorouracil plus cisplatin versus hydroxyurea as an adjunct to radiation therapy in stage IIB-IVA carcinoma of the cervix with negative para-aortic lymph nodes: a Gynecologic Oncology Group and Southwest Oncology Group study. *J Clin Oncol* 1999;17:1339–1348.
126. Rose PG, Bundy BN, Watkins EB, et al. Concurrent cisplatin-based radiotherapy and chemotherapy for locally advanced cervical cancer. *N Engl J Med* 1999;340:1144–1153.
127. Thomas GM. Improved treatment for cervical cancer—concurrent chemotherapy and radiotherapy. *N Engl J Med* 1999;340:1198–1200.
128. Rose PG, Ali S, Watkins E, et al. Long-term follow-up of a randomized trial comparing concurrent single agent cisplatin, cisplatin-based combination chemotherapy, or hydroxyurea during pelvic irradiation for locally advanced cervical cancer: a Gynecologic Oncology Group Study. *J Clin Oncol* 2007;25:2804–2810.
129. Eifel PJ, Winter K, Morris M, et al. Pelvic irradiation with concurrent chemotherapy versus pelvic and para-aortic irradiation for high-risk cervical cancer: an update of radiation therapy oncology group trial (RTOG) 90-01. *J Clin Oncol* 2004;22:872–880.
130. Stehman FB, Ali S, Keys HM, et al. Radiation therapy with or without weekly cisplatin for bulky stage 1B cervical carcinoma: follow-up of a Gynecologic Oncology Group trial. *Am J Obstet Gynecol* 2007;197:1–6.
131. Chemoradiotherapy for Cervical Cancer Meta-Analysis C. Reducing uncertainties about the effects of chemoradiotherapy for cervical cancer: a systematic review and meta-analysis of individual patient data from 18 randomized trials. *J Clin Oncol* 2008;26:5802–5812.
132. Pearcey R, Miao Q, Kong W, et al. Impact of adoption of chemoradiotherapy on the outcome of cervical cancer in Ontario: results of a population-based cohort study. *J Clin Oncol* 2007;25:2383–2388.
133. King M, McConkey C, Latief TN, et al. Improved survival after concurrent weekly cisplatin and radiotherapy for cervical carcinoma with assessment of acute and late side-effects. *Clin Oncol (R Coll Radiol)* 2006;18:38–45.
134. Tan LT, Zahra M. Long-term survival and late toxicity after chemoradiotherapy for cervical cancer—the Addenbrooke's experience. *Clin Oncol (R Coll Radiol)* 2008;20:358–364.
135. Gaffney DK, Du Bois A, Narayan K, et al. Practice patterns of radiotherapy in cervical cancer among member groups of the Gynecologic Cancer Intergroup (GCIG). *Int J Radiat Oncol Biol Phys* 2007;68:485–490.
136. Cetina L, Garcia-Arias A, Uribe MdJ, et al. Concurrent chemoradiation with carboplatin for elderly, diabetic and hypertensive patients with locally advanced cervical cancer. *Eur J Gynaecol Oncol* 2008;29:608–612.
137. Dubay RA, Rose PG, O'Malley DM, et al. Evaluation of concurrent and adjuvant carboplatin with radiation therapy for locally advanced cervical cancer. *Gynecol Oncol* 2004;94:121–124.
138. Higgins RV, Naumann WR, Hall JB, Haake M. Concurrent carboplatin with pelvic radiation therapy in the primary treatment of cervix cancer. *Gynecol Oncol* 2003;89:499–503.
139. Lorvidhaya V, Chitapanarux I, Sangruchi S, et al. Concurrent mitomycin C, 5-fluorouracil, and radiotherapy in the treatment of locally advanced carcinoma of the cervix: a randomized trial. *Int J Radiat Oncol Biol Phys* 2003;55:1226–1232.
140. Wong LC, Ngan HY, Cheung AN, et al. Chemoradiation and adjuvant chemotherapy in cervical cancer. *J Clin Oncol* 1999;17:2055–2060.
141. Tharavichitkul E, Lorvidhaya V, Kamnerdsupaphon P, et al. Combined chemoradiation of cisplatin versus carboplatin in cervical carcinoma: a single institution experience from Thailand. *BMC Cancer* 2016;16:501.
142. Mileschkin LR, Narayan K, Moore KN, et al. A phase III trial of adjuvant chemotherapy following chemoradiation as primary treatment for locally advanced cervical cancer compared to chemoradiation alone: Outback (ANZGOG0902/GOG0274/RTOG1174) [abstract]. *J Clin Oncol* 2014 32:abstract TPS5632.
143. Koliopoulos G, Sotiriadis A, Kyrgiou M, et al. Conservative surgical methods for FIGO stage IA2 squamous cervical carcinoma and their role in preserving women's fertility. *Gynecol Oncol* 2004;93:469–473.
144. Wright JD, Nathavitharana R, Lewin SN, et al. Fertility-conserving surgery for young women with stage IA1 cervical cancer: safety and access. *Obstet Gynecol* 2010;115:585–590.
145. Tierney KE, Lin PS, Amezcua C, et al. Cervical conization of adenocarcinoma in situ: a predicting model of residual disease. *Am J Obstet Gynecol* 2014;210:366 e361–365.
146. Yoneda JY, Braganca JF, Sarian LO, et al. Surgical treatment of microinvasive cervical cancer: analysis of pathologic features with implications on radicality. *Int J Gynecol Cancer* 2015;25:694–698.
147. Bernardini M, Barrett J, Seaward G, Covens A. Pregnancy outcomes in patients after radical trachelectomy. *Am J Obstet Gynecol* 2003;189:1378–1382.
148. Boss EA, van Golde RJT, Beerendonk CCM, Massuger LFAG. Pregnancy after radical trachelectomy: a real option? *Gynecol Oncol* 2005;99:152–156.
149. Plante M, Renaud M-C, Hoskins IA, Roy M. Vaginal radical trachelectomy

- tomy: a valuable fertility-preserving option in the management of early-stage cervical cancer. A series of 50 pregnancies and review of the literature. *Gynecol Oncol* 2005;98:3–10.
150. Marchiole P, Benchaib M, Buenerd A, et al. Oncological safety of laparoscopic-assisted vaginal radical trachelectomy (LARVT or Dargent's operation): a comparative study with laparoscopic-assisted vaginal radical hysterectomy (LARVH). *Gynecol Oncol* 2007;106:132–141.
  151. Landoni F, Zanagnolo V, Lovato-Diaz L, et al. Ovarian metastases in early-stage cervical cancer (IA2-IIA): a multicenter retrospective study of 1965 patients (a Cooperative Task Force study). *Int J Gynecol Cancer* 2007;17:623–628.
  152. Shimada M, Kigawa J, Nishimura R, et al. Ovarian metastasis in carcinoma of the uterine cervix. *Gynecol Oncol* 2006;101:234–237.
  153. Kokka F, Bryant A, Brockbank E, Jeyarajah A. Surgical treatment of stage IA2 cervical cancer. *Cochrane Database Syst Rev* 2014;CD010870.
  154. Small W, Jr., Strauss JB, Jhingran A, et al. ACR Appropriateness Criteria(R) definitive therapy for early-stage cervical cancer. *Am J Clin Oncol* 2012;35:399–405.
  155. Raju SK, Papadopoulos AJ, Montalto SA, et al. Fertility-sparing surgery for early cervical cancer—approach to less radical surgery. *Int J Gynecol Cancer* 2012;22:311–317.
  156. Li J, Wu X, Li X, Ju X. Abdominal radical trachelectomy: Is it safe for IB1 cervical cancer with tumors  $\geq 2$  cm? *Gynecol Oncol* 2013;131:87–92.
  157. Landoni F, Maneo A, Cormio G, et al. Class II versus class III radical hysterectomy in stage IB-IIA cervical cancer: a prospective randomized study. *Gynecol Oncol* 2001;80:3–12.
  158. Keys HM, Bundy BN, Stehman FB, et al. Radiation therapy with and without extrafascial hysterectomy for bulky stage IB cervical carcinoma: a randomized trial of the Gynecologic Oncology Group. *Gynecol Oncol* 2003;89:343–353.
  159. Kokka F, Bryant A, Brockbank E, et al. Hysterectomy with radiotherapy or chemotherapy or both for women with locally advanced cervical cancer. *Cochrane Database Syst Rev* 2015;4:CD010260.
  160. Colombo PE, Bertrand MM, Gutowski M, et al. Total laparoscopic radical hysterectomy for locally advanced cervical carcinoma (stages IIB, IIA and bulky stages IB) after concurrent chemoradiation therapy: surgical morbidity and oncological results. *Gynecol Oncol* 2009;114:404–409.
  161. Touboul C, Uzan C, Mauguén A, et al. Prognostic factors and morbidities after completion surgery in patients undergoing initial chemoradiation therapy for locally advanced cervical cancer. *Oncologist* 2010;15:405–415.
  162. Huguet F, Cojocariu OM, Levy P, et al. Preoperative concurrent radiation therapy and chemotherapy for bulky stage IB2, IIA, and IIB carcinoma of the uterine cervix with proximal parametrial invasion. *Int J Radiat Oncol Biol Phys* 2008;72:1508–1515.
  163. Cetina L, Gonzalez-Enciso A, Cantu D, et al. Brachytherapy versus radical hysterectomy after external beam chemoradiation with gemcitabine plus cisplatin: a randomized, phase III study in IB2-IIB cervical cancer patients. *Ann Oncol* 2013;24:2043–2047.
  164. Kohler C, Mustea A, Marnitz S, et al. Perioperative morbidity and rate of upstaging after laparoscopic staging for patients with locally advanced cervical cancer: results of a prospective randomized trial. *Am J Obstet Gynecol* 2015;213:503 e501–507.
  165. Goff BA, Muntz HG, Paley PJ, et al. Impact of surgical staging in women with locally advanced cervical cancer. *Gynecol Oncol* 1999;74:436–442.
  166. Rose PG. Combination therapy: New treatment paradigm for locally advanced cervical cancer? *Nat Rev Clin Oncol* 2011;8:388–390.
  167. Duenas-Gonzalez A, Zarba JJ, Patel F, et al. Phase III, open-label, randomized study comparing concurrent gemcitabine plus cisplatin and radiation followed by adjuvant gemcitabine and cisplatin versus concurrent cisplatin and radiation in patients with stage IIB to IVA carcinoma of the cervix. *J Clin Oncol* 2011;29:1678–1685.
  168. Thomas G. Are we making progress in curing advanced cervical cancer? *J Clin Oncol* 2011;29:1654–1656.
  169. Swisher EM, Swensen RE, Greer B, et al. Weekly gemcitabine and cisplatin in combination with pelvic radiation in the primary therapy of cervical cancer: a phase I trial of the Puget Sound Oncology Consortium. *Gynecol Oncol* 2006;101:429–435.
  170. Rose PG, Degeest K, McMeekin S, Fusco N. A phase I study of gemcitabine followed by cisplatin concurrent with whole pelvic radiation therapy in locally advanced cervical cancer: a Gynecologic Oncology Group study. *Gynecol Oncol* 2007;107:274–279.
  171. Lutz ST, Chow EL, Hartsell WF, Konski AA. A review of hypofractionated palliative radiotherapy. *Cancer* 2007;109:1462–1470.
  172. Rotman M, Sedlis A, Piedmonte MR, et al. A phase III randomized trial of postoperative pelvic irradiation in stage IB cervical carcinoma with poor prognostic features: follow-up of a gynecologic oncology group study. *Int J Radiat Oncol Biol Phys* 2006;65:169–176.
  173. Monk BJ, Wang J, Im S, et al. Rethinking the use of radiation and chemotherapy after radical hysterectomy: a clinical-pathologic analysis of a Gynecologic Oncology Group/Southwest Oncology Group/Radiation Therapy Oncology Group trial. *Gynecol Oncol* 2005;96:721–728.
  174. Chernofsky MR, Felix JC, Mderspach LI, et al. Influence of quantity of lymph vascular space invasion on time to recurrence in women with early-stage squamous cancer of the cervix. *Gynecol Oncol* 2006;100:288–293.
  175. Marchiole P, Buenerd A, Benchaib M, et al. Clinical significance of lympho vascular space involvement and lymph node micrometastases in early-stage cervical cancer: a retrospective case-control surgico-pathological study. *Gynecol Oncol* 2005;97:727–732.
  176. Trifiletti DM, Swisher-McClure S, Showalter TN, et al. Postoperative chemoradiation therapy in high-risk cervical cancer: re-evaluating the findings of Gynecologic Oncology Group study 109 in a large, population-based cohort. *Int J Radiat Oncol Biol Phys* 2015;93:1032–1044.
  177. Gong L, Lou JY, Wang P, et al. Clinical evaluation of neoadjuvant chemotherapy followed by radical surgery in the management of stage IB2-IIB cervical cancer. *Int J Gynaecol Obstet* 2012;117:23–26.
  178. Eddy GL, Bundy BN, Creasman WT, et al. Treatment of (“bulky”) stage IB cervical cancer with or without neoadjuvant vincristine and cisplatin prior to radical hysterectomy and pelvic/para-aortic lymphadenectomy: a phase III trial of the gynecologic oncology group. *Gynecol Oncol* 2007;106:362–369.
  179. Ryzewska L, Tierney J, Vale CL, Symonds PR. Neoadjuvant chemotherapy plus surgery versus surgery for cervical cancer. *Cochrane Database Syst Rev* 2010;CD007406.
  180. Katsumata N, Yoshikawa H, Kobayashi H, et al. Phase III randomised controlled trial of neoadjuvant chemotherapy plus radical surgery vs radical surgery alone for stages IB2, IIA2, and IIB cervical cancer: a Japan Clinical Oncology Group trial (JCOG 0102). *Br J Cancer* 2013;108:1957–1963.
  181. Kim HS, Sardi JE, Katsumata N, et al. Efficacy of neoadjuvant chemotherapy in patients with FIGO stage IB1 to IIA cervical cancer: an international collaborative meta-analysis. *Eur J Surg Oncol* 2013;39:115–124.
  182. Landoni F, Sartori E, Maggino T, et al. Is there a role for postoperative treatment in patients with stage Ib2-Iib cervical cancer treated with neo-adjuvant chemotherapy and radical surgery? An Italian multicenter retrospective study. *Gynecol Oncol* 2014;132:611–617.
  183. Ye Q, Yuan HX, Chen HL. Responsiveness of neoadjuvant chemotherapy before surgery predicts favorable prognosis for cervical cancer patients: a meta-analysis. *J Cancer Res Clin Oncol* 2013;139:1887–1898.
  184. Arbyn M, Dillner J. Review of current knowledge on HPV vaccination: an appendix to the European Guidelines for Quality Assurance in Cervical Cancer Screening. *J Clin Virol* 2007;38:189–197.
  185. Rambout L, Hopkins L, Hutton B, Fergusson D. Prophylactic vaccination against human papillomavirus infection and disease in women: a systematic review of randomized controlled trials. *CMAJ* 2007;177:469–479.
  186. Chan JK, Berek JS. Impact of the human papilloma vaccine on cervical cancer. *J Clin Oncol* 2007;25:2975–2982.

## Individual Disclosures for Cervical Cancer Panel

Panel Member	Clinical Research Support/Data Safety Monitoring Board	Scientific Advisory Boards, Consultant, or Expert Witness	Promotional Advisory Boards, Consultant, or Speakers Bureau	Specialties
Nadeem R. Abu-Rustum, MD	GRAIL, Inc.; Olympus; prIME Oncology, Inc.; Stryker Corporation/Novadaq Technologies, Inc.; and UpToDate, Inc.	None	None	Gynecologic Oncology
Sarah Bean, MD	None	None	None	Pathology
Kristin Bradley, MD	None	None	None	Radiotherapy/Radiation Oncology
Susana M. Campos, MD, MPH, MS	None	Clovis Oncology	Genentech, Inc.	Medical Oncology
Kathleen R. Cho, MD	None	Resonant Therapeutics, Inc.	None	Pathology
Hye Sook Chon, MD	None	None	None	Gynecologic Oncology
Christina Chu, MD	None	None	None	Gynecologic Oncology
Rachel Clark, MD	None	None	None	Gynecologic Oncology
David Cohn, MD	None	Oncology Analytics, and UpToDate, Inc.	None	Gynecologic Oncology
Marta Ann Crispens, MD	Advaxis, Inc.; AstraZeneca Pharmaceuticals LP; BeiGene, Ltd.; Puma Biotechnology; Roche Laboratories, Inc.; Syndax Pharmaceuticals, Inc.; and TESARO, Inc.	AbbVie, Inc.	None	Gynecologic Oncology
Shari Damast, MD	None	None	None	Radiotherapy/Radiation Oncology
Oliver Dorigo, MD, PhD	Aduro BioTech, Inc., and Immunovaccine, Inc.	Geneos; Myriad Genetic Laboratories, Inc.; and Nektar Therapeutics	Foundation Medicine, Inc., and TESARO, Inc.	Gynecologic Oncology
Patricia J. Eifel, MD	None	None	None	Radiotherapy/Radiation Oncology
Christine M. Fisher, MD, MPH	None	Accuray Incorporated	None	Radiotherapy/Radiation Oncology
Peter Frederick, MD	None	None	None	Gynecologic Oncology
David K. Gaffney, MD, PhD	None	None	None	Radiotherapy/Radiation Oncology
Ernest Han, MD, PhD	None	None	None	Gynecologic Oncology
Warner K. Huh, MD	Antiva Biosciences, Inc.	Antiva Biosciences, Inc.	None	Gynecologic Oncology
Wui-Jin Koh, MD	None	None	None	Radiotherapy/Radiation Oncology
John R. Lurain III, MD	None	None	None	Gynecologic Oncology
Andrea Mariani, MD	None	None	None	Gynecologic Oncology
David Mutch, MD	None	None	Clovis Oncology	Gynecologic Oncology
Christa Nagel, MD	None	None	None	Gynecologic Oncology
Larissa Nekhlyudov, MD, MPH	None	None	None	Internal Medicine
Amanda Nickles Fader, MD	None	Merck & Co., Inc.	Ethicon, Inc.	Gynecologic Oncology
Steven W. Remmenga, MD	None	None	None	Gynecologic Oncology
R. Kevin Reynolds, MD	None	None	None	Gynecologic Oncology
Todd Tillmanns, MD	AstraZeneca Pharmaceuticals LP	None	None	Gynecologic Oncology
Stefanie Ueda, MD	None	None	None	Gynecologic Oncology
Emily Wyse	None	None	None	Patient Advocacy
Catheryn M. Yashar, MD	None	Cianna Medical, Inc., and MicroChips Biotech	None	Radiotherapy/Radiation Oncology

The NCCN Guidelines Staff have no conflicts to disclose.