

## **Characteristic optical coherence tomography findings in patients with primary vitreoretinal lymphoma: A novel aid to early diagnosis.**

Barry RJ<sup>1,2</sup>, Tasiopoulou A<sup>3</sup>, Murray PI<sup>1,2</sup>, Patel PJ<sup>3</sup>, Sagoo MS<sup>3,4</sup>, Denniston AK<sup>1,5</sup>, Keane PA<sup>3</sup>

### **Author affiliations:**

1. Academic Unit of Ophthalmology, University of Birmingham, Birmingham, UK
2. Birmingham & Midland Eye Centre, Birmingham, UK
3. NIHR Biomedical Research Centre at Moorfields Eye Hospital NHS Foundation Trust and UCL Institute of Ophthalmology, London, UK
4. Department of Oncology, St Bartholomew's Hospital, London, UK
5. Department of Ophthalmology, Queen Elizabeth Hospital, Birmingham, UK

### **Corresponding author:**

Pearse A Keane  
Moorfields Eye Hospital  
162 City Road  
London  
EC1V 2PD

+44(0)207 253 3411

Pearse.Keane@moorfields.nhs.uk

**Word count:** 2377 words

### **Key words:**

Diagnostic tests / investigation  
Imaging  
Inflammation  
Neoplasia  
Retina

### **Synopsis:**

Early identification of primary vitreoretinal lymphoma (PVRL) is challenging. As a result, diagnosis and treatment is often delayed. We demonstrate a selection of OCT features which will facilitate early diagnosis of this life-threatening disease.

## **ABSTRACT:**

### **Background:**

The diagnosis of primary vitreoretinal lymphoma (PVRL) poses significant difficulties; presenting features are non-specific, and confirmation usually necessitates invasive vitreoretinal biopsy. Diagnosis is often delayed, resulting in increased morbidity and mortality. Non-invasive imaging modalities such as spectral domain optical coherence tomography (SD-OCT) offer simple and rapid aids to diagnosis. We present characteristic SD-OCT images of patients with biopsy-positive PVRL and propose a number of typical features, which we believe are useful in identifying these lesions at an early stage.

### **Methods:**

Medical records of all patients attending Moorfields Eye Hospital between April 2010 and April 2016 with biopsy-positive PVRL were reviewed. Pre-treatment SD-OCT images were collected for all eyes, and were reviewed independently by two researchers for features suggestive of PVRL.

### **Results:**

Pre-treatment SD-OCT images of 32 eyes of 22 patients with biopsy-proven PVRL were reviewed. Observed features included hyper-reflective sub-retinal infiltrates (17/32), hyper-reflective infiltration in inner retinal layers (6/32), RPE undulation (5/32), clumps of vitreous cells (5/32) and sub-RPE deposits (3/32). Of these, the hyper-reflective subretinal infiltrates have an appearance unique to PVRL, with features not seen in other diseases.

**Conclusion:**

We have identified a range of SD-OCT features, which we believe to be consistent with a diagnosis of PVRL. We propose that the observation of hyper-reflective sub-retinal infiltrates as described is highly suggestive of PVRL. This case series further demonstrates the utility of SD-OCT as a non-invasive and rapid aid to diagnosis, which may improve both visual outcomes and survival of patients with intra-ocular malignancies such as PVRL.

## **INTRODUCTION:**

Primary vitreoretinal lymphoma (PVRL) most commonly represents an extra-nodal presentation of non-Hodgkin's lymphoma, being of B-lymphocyte origin in 80%. [1] PVRL poses significant diagnostic difficulties to the clinician. First, it is a rare condition, representing less than 0.01% of all ocular diagnoses, and therefore is often not considered in an initial differential diagnosis. [2,3] Second, clinical findings are non-specific, with PVRL masquerading as posterior or intermediate uveitis due to other causes. [4] Whilst characteristic features including the presence of large, non-clumped vitreous cells, and the observation of yellow sub-retinal deposits associated with RPE detachments have been proposed, these may be observed in a range of other disease processes and confirmation of the diagnosis usually necessitates invasive vitreoretinal biopsy. [5,6]

Cytology specimens obtained through vitreoretinal biopsy have been shown to generate false negative results in between 30% and 45% of analyses. [7,8] Vitreous samples are often insufficient, due to the cellular yield being lower than suggested by clinical examination, and results can be challenging to interpret unless the pathologist has prior experience in the diagnosis of PVRL. Furthermore, cytology samples degrade rapidly unless suitably fixed, rendering results inaccurate unless promptly analysed. [9] To counter some of these limitations, a number of immunological analyses have also been proposed using either vitreous or aqueous humour, with diagnosis supported by the presence of B-lymphocyte markers such as B220, and an elevated IL-

10:IL-6 ratio, suggesting a predominance of the B-lymphocyte response over the usual T-lymphocyte-derived inflammatory markers.[10] Such analyses are however only possible with highly-differentiated tumours, and may be limited by the development of a T-lymphocyte driven inflammatory response to tumour antigens.[11,12] Diagnosis is therefore often delayed.

PVRL is associated with primary central nervous system lymphoma (PCNSL) in up to 80% of cases, with the development of CNS disease often providing confirmatory evidence of the intra-ocular diagnosis.[1] Whilst early diagnosis of localized ocular disease is unlikely to influence eventual mortality rates, it has been shown to prolong survival.[13] Non-invasive imaging modalities such as spectral domain optical coherence tomography (SD-OCT) have previously been demonstrated as potential aids to diagnosis, although existing data are largely limited to case reports or very small case series,[14–17] or from patients following treatment where the diagnosis of PVRL has already been made.[18] Whilst such techniques have been proposed to enable earlier identification of PVRL and may reduce the dependence on invasive biopsy, there is a paucity of data derived from early cases prior to commencing lymphoma-specific treatment. To address this, we wish to present a large series of pre-treatment SD-OCT images from patients who were later proven to have biopsy-positive PVRL, and describe characteristic features which we believe are highly suggestive of PVRL in the earliest stages of the disease.

## **MATERIALS AND METHODS:**

Electronic patient records and correspondence for all patients attending Moorfields Eye Hospital, London, between April 2010 and April 2016 were searched for the term 'lymphoma'. All positive results were manually reviewed, and confirmed cases of PVRL identified on the basis of either a positive ocular tissue biopsy, or by positive central nervous system tissue biopsy for cases associated with PCNSL in the absence of ocular tissue biopsy. Demographic and clinical data was collected for all patients, and pre-treatment Heidelberg Spectralis SD-OCT images were collected for all eyes.

OCT images were anonymised before being independently assessed by two masked observers (RB and AT). Observers were first asked to review all images to compile a list of positive findings; no minimum frequency of occurrence was defined at this stage, since the aim was to explore all potential features suggestive of PVRL. These findings were then discussed with all authors, and a 'final' list of OCT features considered suggestive of PVRL defined. The observers were then asked to repeat the independent review process, documenting the presence or absence of all defined features on each OCT image.

## RESULTS:

SD-OCT images of 32 eyes of 22 patients with biopsy-proven PVRL were reviewed. For all patients, the earliest-available images were included in analysis, prior to any patient receiving lymphoma-specific treatment. This sample comprised 14 females and 8 males, with a median age at presentation of 69.5 years (range 61 to 89 years).

Representative examples of OCT images from two patients are shown in Figures 1 and 2. Figure 1 describes an example of delayed diagnosis in a 50-year-old patient presenting with visual loss, which recovered with the use of oral steroids for presumed inflammatory posterior uveitis. SD-OCT changes also resolved following treatment with oral steroids. However, 24 months later, the fellow eye became involved with subretinal infiltration, with the diagnosis of PVRL only being confirmed following biopsy of a brain lesion 32 months after initial presentation. Figure 2 displays SD-OCT images from an individual patient at a single time-point, demonstrating the full range of features suggestive of PVRL: Inner and outer retinal infiltrates, sub-RPE infiltration between RPE and Bruch's Membrane, hyper-reflective foci in posterior vitreous, and irregularity of the RPE.

Hyper-reflective lesions were observed across multiple retinal layers as summarized in Table 1, and shown in Figures 1-4. Hyper-reflective foci in the sub-retinal space were observed in 17/32 eyes (53.1%), either in the form of either discrete nodules (7/32 eyes; 21.9%) (Figure 3A) or appearing as a

confluent band (10/32 eyes; 31.3%) (Figure 3B). These lesions were accompanied by disruption of the photoreceptor inner segment / outer segment junction. There were 6/32 eyes (18.8%) that displayed hyper-reflective infiltration in the inner layers of the retina (Figure 3C). Irregularity of the RPE was observed in 5/32 eyes (15.6%) (Figure 3D). Hyper-reflective foci in the posterior vitreous were observed in 5/32 eyes (15.6%) (Figure 3E). Sub-retinal pigment epithelial (sub-RPE) deposits associated with steep elevation of the RPE were observed in 3/32 eyes (9.4%), considered consistent with the presence of a sub-RPE mass. Cystoid macular oedema was observed in 5/32 eyes (15.6%).

<b>OCT feature</b>	<b>n</b>	<b>%</b>
<hr/>		
Hyper-reflective foci in the sub-retinal space		
<i>Discrete nodules</i>	7	21.9
<i>Confluent band</i>	10	31.3
<i>Any</i>	17	53.1
Hyper-reflective infiltration in the inner layers of the retina	6	18.8
Sub-RPE deposits	3	9.4
Undulation of the RPE	5	15.6
Hyper-reflective foci in posterior vitreous	5	15.6
<b>Any of the above</b>	<b>30</b>	<b>93.8</b>
<hr/>		

**Table 1: Summary statistics.** Frequency (n) and percentage (%) of eyes displaying each OCT feature.



Differences between sub-RPE infiltrates observed in PVRL and choroidal infiltrates observed in choroidal lymphoma are illustrated in Figure 4.

Infiltration in PVRL is localised between the RPE and Bruch's Membrane. In this disease, the choroid is seen separately to the RPE and immediately deep to Bruch's Membrane. The infiltration displays a homogenous, hyper-reflective quality. In contrast, infiltration in choroidal lymphoma, usually of a mucosa-associated lymphoid tissue (MALT) type is seen deep to Bruch's Membrane, with no separation of the RPE and Bruch's Membrane, and the choroidal infiltration is seen immediately beneath the RPE / Bruch's Membrane complex.

## **DISCUSSION:**

PVRL is a notoriously difficult diagnosis to make, often masquerading as inflammatory or infective posterior uveitis. Apart from having a high index of suspicion, there are clinical clues that allow investigations to be directed appropriately. For example, vitreous cells in sheets, visual acuity better than predicted from the amount of “uveitic” involvement, and lack of cystoid macular oedema are clues to the true diagnosis. Despite these, it is a common diagnostic challenge and can lead to delays in the correct diagnosis in a disease that is ultimately life-threatening. The need for further clues on non-invasive imaging is paramount.

In this report, we present characteristic OCT features of PVRL, derived from a large series of SD-OCT images of consecutive eyes with biopsy-proven PVRL. Compared to previously-published reports,[14–18] our series represents early images taken from patients in whom there was considerable diagnostic uncertainty, prior to confirmatory tissue biopsy being available, and prior to commencement of lymphoma-specific therapy. Features observed on OCT have previously been demonstrated to show a degree of resolution following commencement of therapy,[16] and indeed we present further evidence of this in Figure 1. This series therefore provides considerable support for the use of SD-OCT as an aid to earlier diagnosis of PVRL, with greater opportunity for positively influencing patient outcomes.

We propose that the observation of any OCT feature shown in Figure 3 in a patient with compatible clinical findings should be considered strongly

suggestive of PVRL until proven otherwise. In particular, we suggest that a confluent hyper-reflective band in the subretinal space should be considered pathognomonic of PVRL (Figures 1B, 2B, 2C, 3B, and 3F). In some cases, gross infiltration of the sub-RPE can lead to large lesions with steep elevation of the overlying RPE and a homogeneously hyper-reflective appearance subtly different from that seen in drusenoid, fibrovascular, or serosanguineous pigment epithelial detachments (Figures 2D, 2E, 2F, 4A, 4B). We believe that such a finding is highly suggestive of PVRL, however, this finding is much less specific in cases with only limited infiltration of the sub-RPE space.

Furthermore, the sub-RPE infiltrates demonstrated in Figure 4 enable discrimination between PVRL and choroidal lymphoma, with infiltrates localised between the RPE and Bruch's Membrane in PVRL, compared to being deep to Bruch's Membrane in choroidal lymphoma. PVRL is strongly associated with PCNSL, and is a high-grade and aggressive non-Hodgkin's B cell lymphoma, whereas choroidal lymphoma is usually of the more indolent MALT type that is occasionally associated with systemic lymphoma. This distinction between the 2 types of primary intraocular lymphoma on a non-invasive imaging test is of particular clinical significance. The ability to differentiate these two entities on SD-OCT imaging will enable more targeted screening for staging purposes.

We advocate prompt referral of such cases to specialised uveitis services, and early consideration of oncology review. Whilst early diagnosis of PVRL is unlikely to alter mortality rates, there is evidence that early diagnosis of ocular lesions prior to the development of CNS disease results in a significant

prolongation of life,[13] and the ophthalmologist therefore has an important role in early recognition of this life-limiting condition.

The utility of OCT in the diagnosis of PVRL has previously been explored, with authors suggesting that the presence of hyper-reflective sub-retinal foci and outer retinal atrophy to be indicative of lymphomatous disease.[15] More recently, Morara et al. reported OCT findings of two patients with atypical presentations of PVRL, highlighting the presence of hyper-reflective sub-RPE lesions and the presence of an undulating choroid to be particularly suggestive features.[17] We have been able to demonstrate the presence of similar features in our larger patient sample, and at an earlier stage in the course of disease. Other ocular imaging that may contribute to diagnosis of PVRL includes fluorescein (FFA) and indocyanine green angiography (ICGA). On FFA, punctate hyperfluorescent window defects, round hypofluorescent lesions, masking and granularity are seen, with seldom signs of vasculitis or cystoid macular oedema. On ICGA, small hypofluorescent lesions in the early phase, become less apparent in the late frames. These tests have a positive predictive value of 89% and negative predictive value of 85%.[19]

The images displayed in Figure 1 serve as a particularly pertinent indicator of the potential for earlier diagnosis of PVRL based on SD-OCT findings. In retrospect, we believe that the sub-retinal infiltration displayed in image 1B is highly suggestive of PVRL, and the diagnosis could have been suspected at this stage. Unfortunately, as discussed above, infiltration due to PVRL often improves with steroid therapy leading to a degree of diagnostic confusion and

highlighting the need to stop steroid therapy for 2 weeks before a biopsy to improve diagnostic yield. We also wish to highlight a number of more subtle changes shown in several of the SD-OCT images reported as 'normal' at the time of examination which were also suggestive of PVRL; occasional hyper-reflective foci were present in the vitreous gel of the contra-lateral eye at diagnosis (Figure 1A), and mild sub-RPE infiltration was demonstrated on imaging taken at a follow-up visit when the patient was asymptomatic (Figure 1E). We do however acknowledge that we are able to make these observations having studied a large sample of SD-OCT images from the presented series of patients with known PVRL. We hope that through dissemination of our findings, we are able to prevent similar diagnostic delays in the future.

We speculate that the OCT features identified in our series represent infiltrating lymphoma cells at various levels in the retina. Observed lesions appear to respect anatomical planes; for example, lesions close to the RPE remain either sub-retinal (and therefore pre-RPE), or sub-RPE, without invading through the RPE itself. This would appear to correlate with localized proliferation of lymphoma cells, and is in contrast to the more destructive changes observed in conditions associated with choroidal neovascularization, where vascular proliferation occurs across the RPE. Furthermore, sub-RPE deposits on SD-OCT similar to those demonstrated in Figure 4 have previously been shown to correspond to collections of diffuse large B-cell lymphoma cells on histopathology and immunohistochemical analysis.[14] We

speculate that the hyper-reflective foci in the posterior vitreous represent inflammatory aggregates in the vitreous gel.

Such correlation of 'virtual' SD-OCT images with 'physical' pathology specimens may thus reduce the dependency on invasive tissue biopsy for diagnosis in the future. Unlike vitreous biopsy, SD-OCT is rapid, reproducible, easily interpreted, and associated with no risk to the eye in terms of infection or seeding of tumour cells. Although OCT features described herein appear to be specific to PVRL, larger studies are necessary to test this notion. Currently, it is still necessary to perform a biopsy to make tissue diagnosis, in order to confirm the type of lymphoma so that appropriate treatment can be given. Elevated aqueous humour IL10 levels, with IL10:IL6 ratios greater than 1 are often considered highly suggestive of lymphoma,[20] but can also be elevated in uveitis. In our centre, initial treatment is usually with systemic methotrexate and cytarabine based chemotherapy, with the addition of external beam radiotherapy if possible,[6] hence the need for tissue diagnosis. The alternative treatment is intravitreal treatment with methotrexate.[21]

The positive predictive value of any diagnostic test is dependent on the prevalence of the diagnosis in the target population, and OCT features must thus be considered in the context of the clinical presentation. Due to the retrospective nature of this study, we are unable to make direct comparison between the OCT analyses presented, and clinical features simultaneously present on fundal examination. Despite this, we believe that several of the OCT findings described should be considered highly suggestive of PVRL. We

hope that recognition of these OCT features will facilitate earlier diagnosis of localized ocular disease, enable initiation of prompt treatment, and ultimately lead to prolonged survival.[13] As demonstrated in this case-series, non-invasive imaging techniques such as SD-OCT provide the ophthalmologist with a rapid aid to diagnosis. It is hoped that increased awareness of characteristic OCT findings in PVRL may improve patient outcomes in this life-limiting disease.

**Contributors:**

RB and AT performed the initial clinical database search, identified confirmed cases of PVRL, collected all pre-treatment OCT images, and generated descriptive statistics as presented. RB produced the first draft of the manuscript and figures. All authors contributed to the study conception and design, reviewed the OCT images and statistical analysis, and edited the manuscript, contributing to the final approval of the version sent for approval.

**Competing interests:** None

**Funding:** None

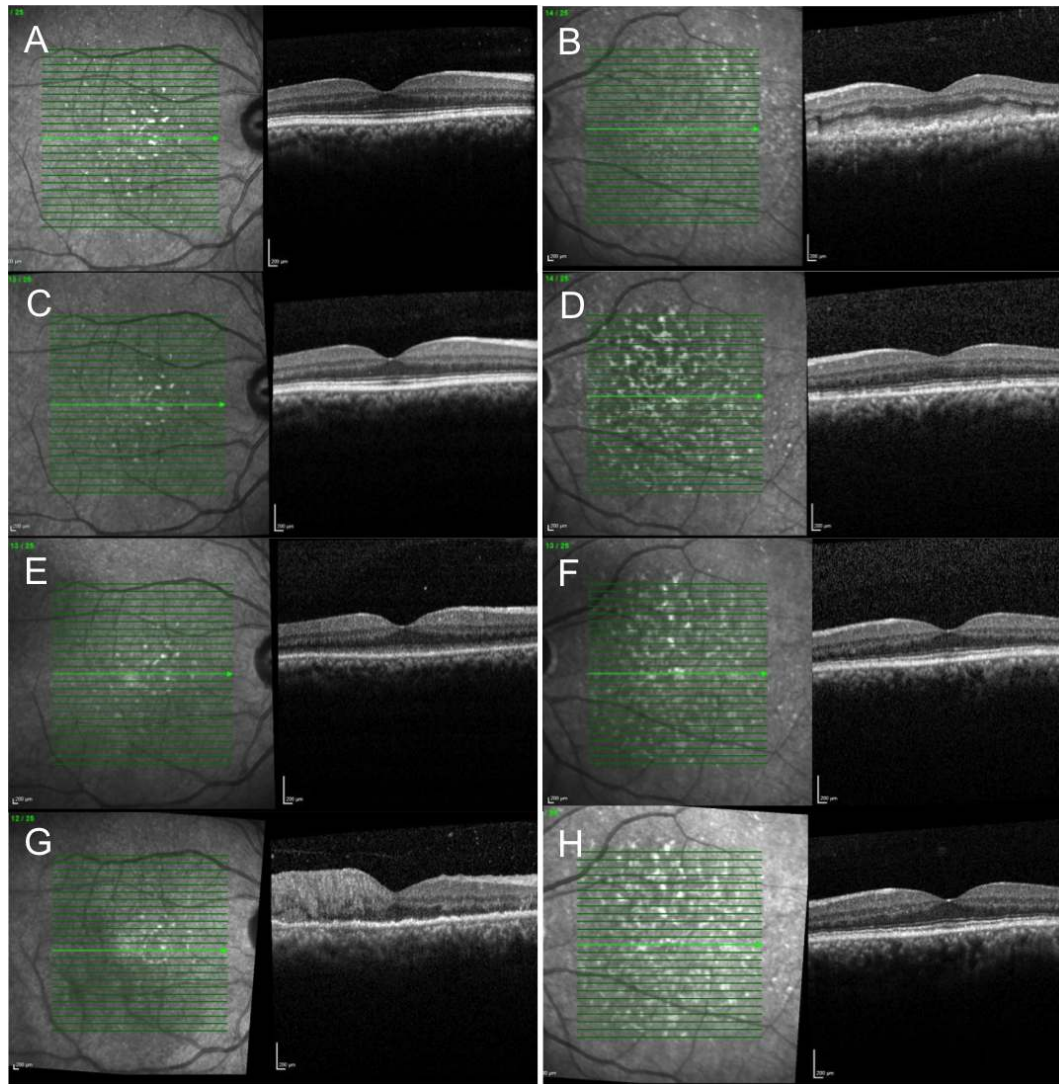
**Ethics approval:** This study was approved by Moorfields R&D department (Approval number ROAD17/031)

## REFERENCES:

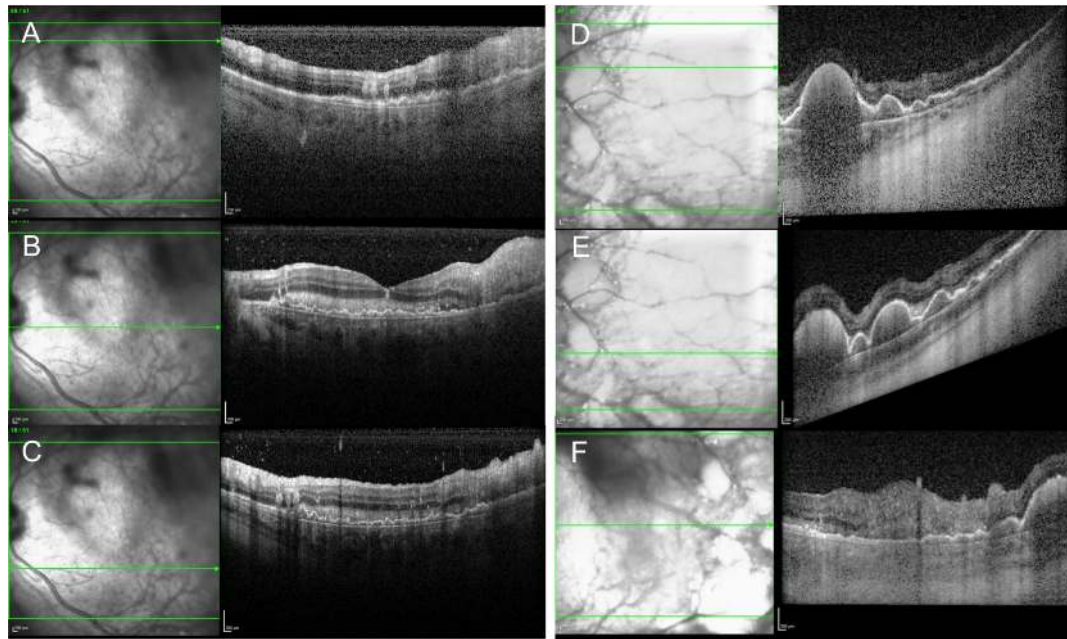
1. Chan C-C, Sen HN. Current concepts in diagnosing and managing primary vitreoretinal (intraocular) lymphoma. *Discov Med* 2013;15(81):93–100.
2. Mochizuki M, Singh AD. Epidemiology and Clinical Features of Intraocular Lymphoma. *Ocul Immunol Inflamm* 2009;17(2):69–72.
3. Chan CC, Rubenstein JL, Coupland SE, et al. Primary vitreoretinal lymphoma: a report from an International Primary Central Nervous System Lymphoma Collaborative Group symposium. *Oncologist* 2011;16(11):1589–99.
4. Gonzales JA, Chan CC. Biopsy techniques and yields in diagnosing primary intraocular lymphoma. *Int Ophthalmol* 2007;27(4):241–50.
5. Davis JL. Intraocular lymphoma: a clinical perspective. *Eye* 2013;27(2):153–62.
6. Sagoo MS, Mehta H, Swampillai AJ, et al. Primary intraocular lymphoma. *Surv Ophthalmol* 2014;59(5):503–16.
7. Chan CC, Wallace DJ. Intraocular lymphoma: update on diagnosis and management. *Cancer Control* 2004;11(5):285–95.
8. Kimura K, Usui Y, Goto H, et al. Clinical features and diagnostic significance of the intraocular fluid of 217 patients with intraocular lymphoma. *Jpn J Ophthalmol* 2012;56(4):383–9.
9. Coupland SE, Damato B. Understanding intraocular lymphomas. *Clin Experiment Ophthalmol* 2008;36(6):564–78.
10. Davis JL, Ruiz P, Shah M, et al. Evaluation of the reactive T-cell infiltrate in uveitis and intraocular lymphoma with flow cytometry of vitreous fluid (an American Ophthalmological Society thesis). *Trans Am Ophthalmol Soc* 2012;110:117–29.
11. Cummings TJ, Stenzel TT, Klintworth G, et al. Primary intraocular T-cell-rich large B-cell lymphoma. *Arch Pathol Lab Med* 2005;129(8):1050–3.
12. Bashir R, Chamberlain M, Ruby E, et al. T-cell infiltration of primary CNS lymphoma. *Neurology* 1996;46(2):440–4.
13. Hormigo A, Abrey L, Heinemann M-H, et al. Ocular presentation of primary central nervous system lymphoma: diagnosis and treatment. *Br J Haematol* 2004;126(2):202–8.
14. Vasconcelos-Santos DV, De Puy E Souza GH, de Faria BB, et al. Subretinal pigment epithelial infiltrates in primary vitreoretinal lymphoma. *J Ophthalmic Inflamm Infect* 2011;1(4):171.
15. Forooghian F, Merkur AB, White VA, et al. High-Definition Optical



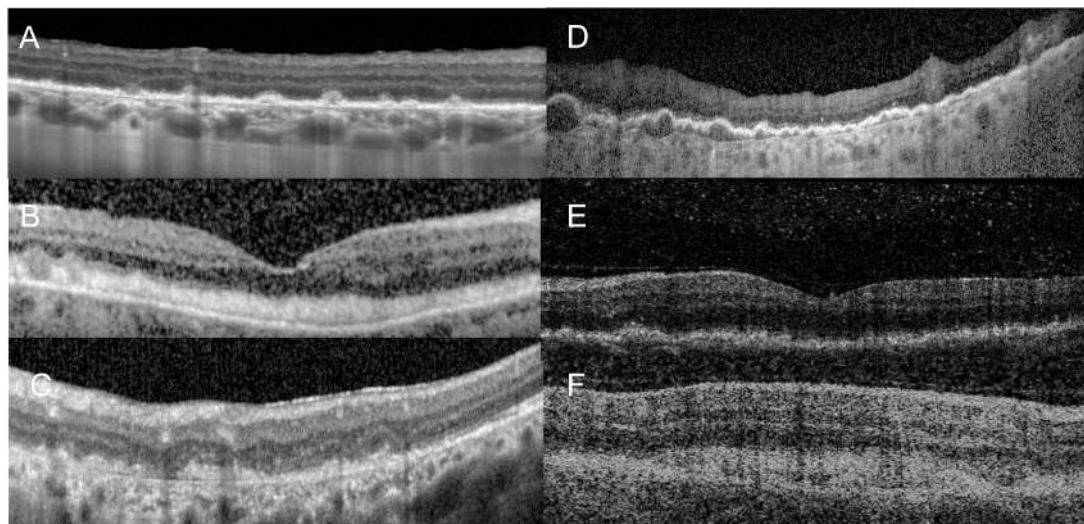
- Coherence Tomography Features of Primary Vitreoretinal Lymphoma. *OSLI Retina* 2012;42:e97-99.
16. Dolz-Marco R, Gallego-Pinazo R, Jung JJ, et al. Sequential multimodal imaging findings in a case of primary vitreoretinal lymphoma. *Retin Cases Brief Rep* 2014;8(4):314–7.
  17. Morara M, Foschi F, Veronese C, et al. Two cases of primary vitreoretinal lymphoma: a diagnostic challenge. *Int Ophthalmol* Published Online First: 30 December 2016 doi: 10.1007/s10792-016-0422-1.
  18. Saito T, Ohguro N, Iwahashi C, et al. Optical coherence tomography manifestations of primary vitreoretinal lymphoma. *Graefe's Arch Clin Exp Ophthalmol* 2016;254(12):2319–26.
  19. Fardeau C, Lee CPL, Merle-Béral H, et al. Retinal Fluorescein, Indocyanine Green Angiography, and Optic Coherence Tomography in Non-Hodgkin Primary Intraocular Lymphoma. *Am J Ophthalmol* 2009;147(5):886–894.
  20. Cassoux N, Giron A, Bodaghi B, et al. IL-10 Measurement in Aqueous Humor for Screening Patients with Suspicion of Primary Intraocular Lymphoma. *Investig Ophthalmology Vis Sci* 2007;48(7):3253.
  21. Frenkel S, Hendler K, Siegal T, et al. Intravitreal methotrexate for treating vitreoretinal lymphoma: 10 years of experience. *Br J Ophthalmol* 2008;92(3):383–8.



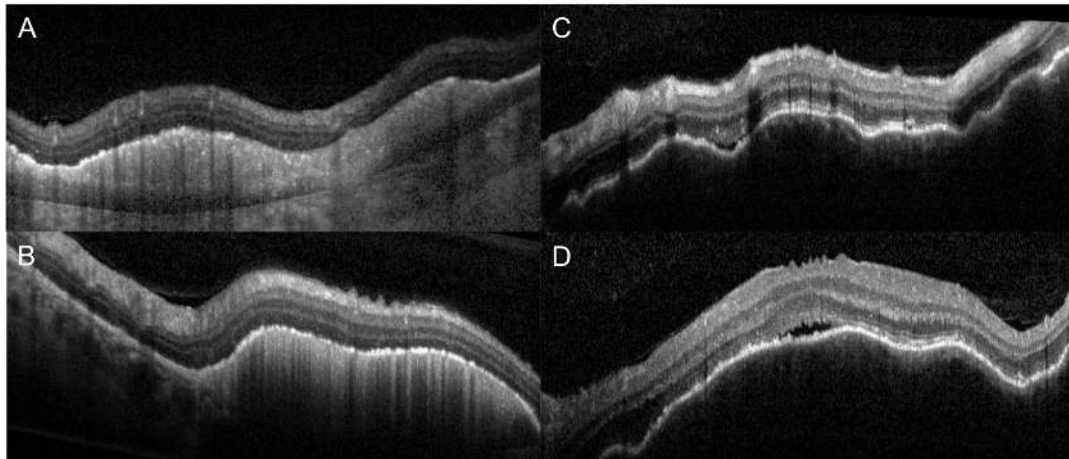
**Figure 1: Serial Heidelberg Spectralis SD-OCT images of a 50 year old Asian patient acquired over a 32 month period. A&B June 2014:** Initial presentation with reduced vision left eye. Clinical examination revealed cream-coloured lesions involving the left macula with OCT changes as shown (B). Diagnosed presumed inflammatory posterior uveitis and commenced oral steroids. Right eye asymptomatic and OCT images considered normal (A). Note irregular and indistinct RPE with overlying outer-retinal infiltration left eye (B), and subtle hyper-reflective foci in the posterior vitreous right eye (A). **C&D October 2014:** Left eye vision improved and OCT changes resolved following course of oral steroids (D). Right eye appears within normal limits (C). **E&F February 2016:** Routine follow-up with repeat OCT imaging. Patient asymptomatic and bilateral OCT scans reported as normal. Note possible sub-retinal / pre-RPE infiltrate right eye (E). **G&H June 2016:** Patient re-presented with reduced vision right eye, with cream-coloured macular lesions observed on clinical examination and florid changes demonstrated on OCT as shown (G). Note significant inner- and outer-retinal infiltration, irregularity of RPE and numerous hyper-reflective foci in posterior vitreous. OCT left eye within normal limits (H). Primary vitreo-retinal lymphoma was suspected at this stage, but only confirmed following development of a brain lesion with positive biopsy February 2017.



**Figure 2: Range of SD-OCT features of PVRL observed in the left eye of an individual patient at a single time-point. A-C: Posterior pole:** Inner- and outer-retinal infiltrate, sub-RPE infiltration, hyper-reflective foci in posterior vitreous, irregularity of RPE. **D-F: Temporal retina:** Homogenous, hyper-reflective deposits in sub-RPE space, between RPE and Bruch's Membrane.



**Figure 3: Representative OCT images displaying characteristic features of PVRL in different patients.** A discrete pre-RPE nodules; B sub-retinal infiltrate appearing as a confluent band; C mixed intra-retinal and sub-retinal infiltration appearing as discrete nodules; D irregular / indistinct RPE; E diffuse hyper-reflective foci in the posterior vitreous; F subretinal infiltrate appearing as a more diffuse confluent band.



**Figure 4: Comparison of sub-RPE infiltration observed in PVRL (A and B) and choroidal infiltration observed in choroidal lymphoma (C and D).** Infiltration in PVRL is localised between the RPE and Bruch's Membrane, with the choroid seen separately to the RPE and immediately deep to Bruch's Membrane. The infiltration displays a homogenous, hyper-reflective quality. In contrast, infiltration in choroidal lymphoma is seen deep to Bruch's Membrane, with no separation of the RPE and Bruch's Membrane, and the choroid is seen immediately beneath the RPE / Bruch's Membrane complex.