

Chemoprevention of Rat Oral Carcinogenesis by Naturally Occurring Xanthophylls, Astaxanthin and Canthaxanthin¹

Takuji Tanaka,² Hiroki Makita, Masami Ohnishi, Hideki Mori, Kumiko Satoh, and Akira Hara

First Department of Pathology, Gifu University School of Medicine, 40 Tsukasa-machi, Gifu City 500 [T. T., H. M., M. O., H. M.], and Department of Biochemistry, Gifu Pharmaceutical University, Gifu City 502 [K. S., A. H.], Japan

ABSTRACT

The chemopreventive effects of two xanthophylls, astaxanthin (AX) and canthaxanthin (CX) on oral carcinogenesis induced by 4-nitroquinoline 1-oxide (4-NQO) was investigated in male F344 rats. Rats were given 20 ppm of 4-NQO in their drinking water for 8 weeks to induce oral neoplasms or preneoplasms. Animals were fed diets containing 100 ppm AX or CX during the initiation or postinitiation phase of 4-NQO-induced oral carcinogenesis. The others contained the groups of rats treated with AX or CX alone and untreated. At the end of the study (week 32), the incidences of preneoplastic lesions and neoplasms in the oral cavity of rats treated with 4-NQO and AX or CX were significantly smaller than those of rats given 4-NQO alone ($P < 0.001$). In particular, no oral neoplasms developed in rats fed AX and CX during the 4-NQO exposure and in those given CX after the 4-NQO administration. Similarly, the incidences of oral preneoplastic lesions (hyperplasia and dysplasia) in rats treated with 4-NQO and AX or CX were significantly smaller than that of the 4-NQO-alone group ($P < 0.05$). In addition to such tumor inhibitory potential, dietary exposure of AX or CX decreased cell proliferation activity in the nonlesional squamous epithelium exposed to 4-NQO as revealed by measuring the silver-stained nucleolar organizer regions protein number/nucleus and 5'-bromodeoxyuridine-labeling index. Also, dietary AX and CX could reduce polyamine levels of oral mucosal tissues exposed to 4-NQO. These results indicate that AX and CX are possible chemopreventers for oral carcinogenesis, and such effects may be partly due to suppression of cell proliferation.

INTRODUCTION

It is well known that dietary factors play an important role in modulating the development of certain types of human cancer (1-6). Epidemiological data suggest a protective role for the nutrients (major or minor) and the nonnutrients in cancer development (7-10). Among the compounds evaluated thus far for their ability to inhibit experimentally induced cancer, the retinoids, compounds having vitamin A-like activity, appear to be the most promising (7, 8, 11, 12). However, from a review by Bertram *et al.* (13) dietary intake of β -carotene, the carotenoid with the highest provitamin A activity, rather than intake of vitamin A itself, seems best correlated with decreased cancer incidence. β -carotene with the highest provitamin A activity (one-sixth that of retinol) is a naturally occurring pigment in many dark-green and yellow-orange leafy vegetables and fruits (14). Besides serving as the major dietary source of retinol for humans, β -carotene and other carotenoids have been found to possess several biological functions (photoprotection and antioxidant properties, including singlet oxygen quenching, immunomodulation, and anticancer activity) in both humans and rodents (15-19).

Of approximately 600 carotenoids that exist in nature, they are generally contained in vegetables, fish, and sea algae; possibly, 10% of them can be considered as possible vitamin A precursors (20).

Received 5/1/95; accepted 7/19/95.

The costs of publication of this article were defrayed in part by the payment of page charges. This article must therefore be hereby marked *advertisement* in accordance with 18 U.S.C. Section 1734 solely to indicate this fact.

¹ This work was supported in part by a 1993 Grant from the Sagawa Cancer Foundation, a Grant from the Ministry of Health and Welfare, and a Grant-in-Aid for Cancer Research from the Ministry of Education, Science and Culture (No. 05671568) of Japan.

² To whom all correspondence and reprint requests should be addressed.

Among carotenoids ingested by mammals, lycopene, lutein, AX,³ CX, and fucoxanthin are not precursors of vitamin A in mammals (20). In contrast to the abundant studies on the antitumor effect of β -carotene (11, 12), there were only a few studies showing antitumor action of carotenoids without provitamin A activity. Micozzi *et al.* (8) estimated the carotenoid content of selected foods that have been consistently associated with a lower risk of various types of epithelial cancer in epidemiological studies. They found that green leafy vegetables were moderately high in α - or β -carotene (10-20% of total carotenoids) but very high in oxygenated carotenoids (xanthophylls), suggesting that some of these xanthophylls (which do not have vitamin A activity) may play a chemopreventive role. In fact, the antitumor effects of some xanthophylls (CX, fucoxanthin, and phytoene) were found in *in vitro* studies (21-25) and in the limited animal models for skin (26), gastric (27), duodenal (28), or mammary (29) tumors. These results may indicate that protective effects of carotenoids are independent of their provitamin A activity (30) and appear to be related to their effectiveness as an antioxidant and free radical scavenger (31). In hamster and rat oral carcinogenesis, vitamin A, retinoids, or β -carotene could suppress tumor development, but there are a few reports demonstrating a protective effect of carotenoids without provitamin A activity (32, 33). Although CX is reported to have a protective effect of hamster buccal pouch tumorigenesis (34, 35), no studies on the modifying effect of other xanthophylls, including AX on experimental carcinogenesis, have been reported. AX inhibited transplantable fibrosarcomas Meth A and Meth 1 in mice (36). Our recent study has shown a protective effect of AX rather than CX on mouse urinary bladder carcinogenesis induced by *N*-butyl-*N*-(4-hydroxybutyl)nitrosamine (37).

Neoplasms in the head and neck, including the oral cavity, possess some biological property, called "field cancerization" (32, 38-40), as does bladder carcinogenesis. Their multistage and multifocal nature has been revealed by histopathological, experimental, and molecular investigations. Patients with oral cancer have an increased incidence of developing second primary tumors of the oral cavity (41-43). In patients with oral cancer, abnormalities of the surrounding squamous epithelium are common; they range from dysplasia to carcinoma *in situ* (44). In oral carcinogenesis, several studies indicated the antitumor effects of retinoids but some showed no effects (7). The synthetic retinoid 13-*cis*-retinoic acid was found to prevent the incidence of new cancers in patients who had been treated for squamous cell carcinoma of the head and neck in a 1-year trial (39). The study was based on evidence its efficacy in preventing oral premalignancy (45). These findings have led to ongoing large-scale trials of 13-*cis*-retinoic acid or retinyl palmitate in the United States and Europe (46). The results of some trials have been reviewed by Benner *et al.* (46), and promising results have been reported. However, the high-dose exposure of retinoids may cause "hypervitaminosis A syndrome" as a side effect (47). Therefore, it is meaningful to examine the potential chemopreventive efficacy of carotenoids without provitamin A property for use in the recurrence or development of a second primary

³ The abbreviations used are: AX, astaxanthin; CX, canthaxanthin; 4-NQO, 4-nitroquinoline-1-oxide; AgNOR, silver-stained nucleolar organizer regions protein; BrdUrd, bromodeoxyuridine.

malignancy by using experimental animal models because carotenoids, including β -carotene and xanthophylls, lack a toxic, mutagenic, or carcinogenic effect (48, 49).

In the present study, possible chemopreventive effects of AX and CX on oral carcinogenesis initiated with 4-NQO were investigated in male F344 rats. Also, the effects of dietary AX and CX on cell proliferation activity oral mucosal epithelium were estimated by measuring the AgNOR number and BrdUrd-labeling index (50).

MATERIALS AND METHODS

Animals, Diet, and Chemicals. Four-week-old, male F344 rats (Shizuoka Laboratory Animal Center, Shizuoka, Japan) were used. All animals were housed in wire cages with free access to drinking water in black bottles and a basal diet, CE-2 (CLEA Japan, Inc., Tokyo, Japan), under controlled conditions of humidity ($50 \pm 10\%$), lighting (12-h light/12-h dark cycle), and temperature ($230 \pm 2^\circ\text{C}$). 4-NQO was obtained from Tokyo Kasei Kogyo Co., Ltd., Tokyo, Japan. 4-NQO was given to rats in tap water at a concentration of 20 ppm. Black bottles were used for 4-NQO exposure to protect it from decomposition by light. AX and CX were purchased from Nippon Roche, Tokyo, Japan. The experimental diets mixed with AX and CX in a powdered basal diet, CE-2, at a concentration of 0.01%, were prepared using a V-blender (Hitachi, Ltd., Tokyo, Japan) every 2 weeks in a dark room and stored in a dark cold room ($<4^\circ\text{C}$) until used. Rats were provided these diets in diet batches shielded by aluminum foil. The stability test of these chemicals was done by HPLC 1 week after feeding (0.01% AX diet contained 0.00980% AX and 0.01% CX diet contained 0.00973% CX).

Experimental Procedure. A total of 133 rats were randomly divided into eight groups. Groups 1 (24 rats), 2 (18 rats), 3 (17 rats), 4 (20 rats), and 5 (19 rats) received 20 ppm 4-NQO alone in drinking water for 8 weeks. Groups 2 and 3 were fed diets containing 0.01% AX and CX, respectively, for 10 weeks starting before 4-NQO exposure. Rats in groups 4 and 5 were fed diets mixed with AX and CX at a concentration of 0.01% for 22 weeks, starting 1 week after the stop of 4-NQO administration. Groups 6 (12 rats) and 7 (11 rats) were fed the AX- and CX-diet alone, respectively, during the experiment (32 weeks). Group 8 (12 rats) were served as an untreated control. Drinking water containing 4-NQO was prepared fresh every 2 days, and the experimental diets containing AX and CX were prepared weekly. All rats were carefully observed daily, and the consumption of drinking water and diet were recorded to estimate intake of chemicals. The experiment was terminated at 32 weeks after the start, and all animals were sacrificed by an ether overdose to assess the incidences of preneoplastic and neoplastic lesions in all organs, including the oral cavity. For measurement of BrdUrd-incorporated nuclei, the animals (five rats from each group) were given an i.p. injection of 50 mg/kg body weight BrdUrd (Sigma Chemical Co., St. Louis, MO) 1 h before killing. At autopsy, the tongues of all rats were bisected after inspection for gross lesions. One-half was fixed overnight in 10% buffered formalin for histopathological diagnosis, AgNOR enumeration, and BrdUrd-labeling index, and the other was used for measuring tissue polyamine levels. Tissues for histology and morphometry were embedded in paraffin, and three serial sections ($3 \mu\text{m}$ in thickness each) were made. One section was stained with hematoxylin and eosin for histological examination, and two others were stained by the one-step silver colloid method for AgNOR (51) and stained immunohistochemically for incorporated BrdUrd. Tongue lesions (hyperplasia, dysplasia, and neoplasms) were diagnosed according to the criteria described by Bánóczy and Csiba (52) and WHO (53).

Assay of Tissue Polyamine Levels. At sacrifice, one-half of the tongues of all rats were collected, and the amounts of diamine, spermine, and spermidine were determined by an enzymatic differential assay according to the method described by Koide (54). The data were confirmed by HPLC.

Morphometric Analysis of AgNOR and BrdUrd-labeling Index. For assessing proliferative activity of tongue epithelium, the numbers of AgNOR/nucleus and BrdUrd-incorporated nuclei were quantified. Quantitation of these values was performed on 100 interphase nuclei in a normal or nonlesional tongue epithelium from five rats of each group at the end of the study by using a computer-assisted image analysis system, SPICCA II (Japan Avionics Co., Tokyo, Japan), with an Olympus BH-2 microscope and a color CCD camera (Hamamatsu Photonics Co., Hamamatsu City, Japan; Ref. 51).

Statistical Analysis. Statistical analysis of differences in the body weight, liver weight, the incidence of lesions or AgNOR, and BrdUrd quantitation between groups was performed by using Fisher's exact probability test or Student's *t* test.

RESULTS

General Observations. Mean body, liver, and relative liver weights (g/100 g body weight) in all groups are shown in Table 1. Mean liver and relative liver weights in group 4 were significantly smaller than those of group 1 ($P < 0.005$ and $P < 0.001$, respectively). Mean body and liver weights in groups 6 and 7 were significantly lower than those of group 1 ($P < 0.05$ and $P < 0.001$, respectively). Average relative liver weight in group 6 was significantly smaller than that of group 1 ($P < 0.05$). Mean intakes of diets with or without xanthophylls were almost comparable in all groups (15.2–15.9 g/rat/day). In this study, dietary administration of AX or CX caused no clinical signs of toxicity, low survival rates, poor conditions, or histological changes suggesting toxicity in the liver, kidney, and lung. The skin color of rats fed the diets mixed with AX or CX was slightly pinkish. At autopsy, liver and adipose tissue in the peritoneum and subcutis was pinkish in color, suggesting accumulation of two xanthophylls in these tissues. Such changes in color were more prominent in rats given AX and CX during the postinitiation phase.

Incidences of Neoplasms and Preneoplastic Lesions in the Oral Cavity. Macroscopically, tumors and/or epithelial thickening of the oral cavity, especially tongue, were found in rats of groups 1–5. Animals in groups 6–8 did not have such macroscopic alterations. Histologically, tongue tumors were squamous cell papilloma and squamous cell carcinoma with keratinization. The incidences of tongue neoplasms are indicated in Fig. 1. 4-NQO treatment in the drinking water induced tongue squamous cell carcinomas with the incidence of 54% (13 of 24) in group 1. Four rats (17%) in group 1 had squamous cell papilloma. No such neoplasms developed in animals in groups 2–4. In rats of group 5, a few tongue neoplasms were found: one rat had squamous cell papilloma (5%) and one rat had squamous cell carcinoma (5%). The incidences of tongue neoplasms (squamous cell papilloma and carcinoma) in groups 2–5 were significantly smaller than that of group 1 ($P < 0.001$ or $P < 0.005$). Epithelial thickening could be classified into two histopathological lesions, such as squamous cell hyperplasia (simple and papillary hyperplasia) and dysplasia (mild, moderate, and severe dysplasia). The incidences of hyperplasia and dysplasia are shown in Fig. 2. The

Table 1 Body, liver, and relative liver weights in each group

Group no.	Treatment	No. of rats examined	Body wt (g)	Liver wt (g)	Relative liver wt (g/100 g body wt)
1	4-NQO alone	24	320 \pm 31 ^a	12.3 \pm 1.5	3.85 \pm 0.31
2	4-NQO+ 100 ppm AX	18	318 \pm 15	12.3 \pm 1.6	3.88 \pm 0.45
3	4-NQO+ 100 ppm CX	17	333 \pm 22	13.0 \pm 1.9	3.90 \pm 0.46
4	4-NQO \rightarrow 100 ppm AX	20	313 \pm 22	10.7 \pm 1.4 ^b	3.42 \pm 0.39 ^c
5	4-NQO \rightarrow 100 ppm CX	19	316 \pm 21	11.4 \pm 1.7	3.61 \pm 0.49
6	100 ppm AX	12	313 \pm 20 ^d	9.9 \pm 1.0 ^e	3.17 \pm 0.29 ^d
7	100 ppm CX	11	313 \pm 22 ^d	10.5 \pm 1.6 ^d	3.34 \pm 0.45
8	No treatment	12	334 \pm 18	11.7 \pm 0.9	3.51 \pm 0.36

^a Mean \pm SD.

^{b,c} Significantly different from group 1 by Student's *t* test (^b $P < 0.005$ and ^c $P < 0.001$).

^{d,e} Significantly different from group 8 by Student's *t* test (^d $P < 0.05$ and ^e $P < 0.001$).

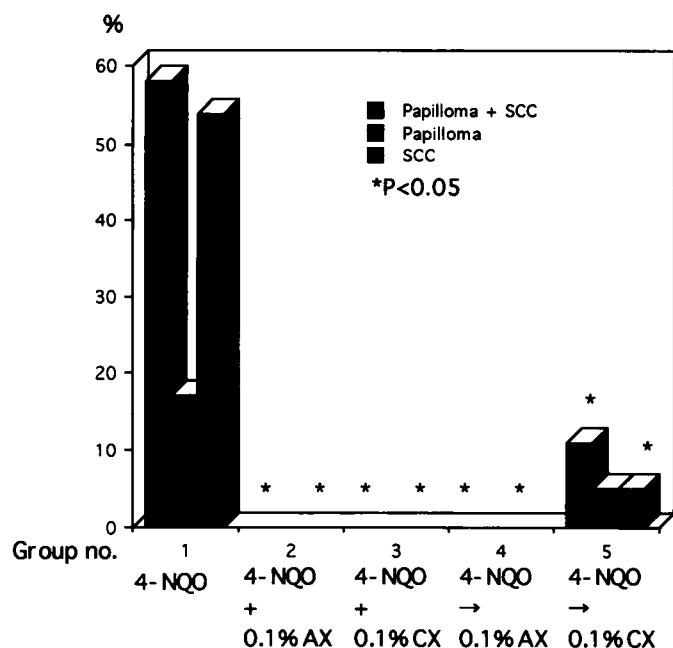


Fig. 1. Incidence of tongue neoplasms (squamous cell papilloma and carcinoma) in rats treated with 4-NQO and/or AX and CX.

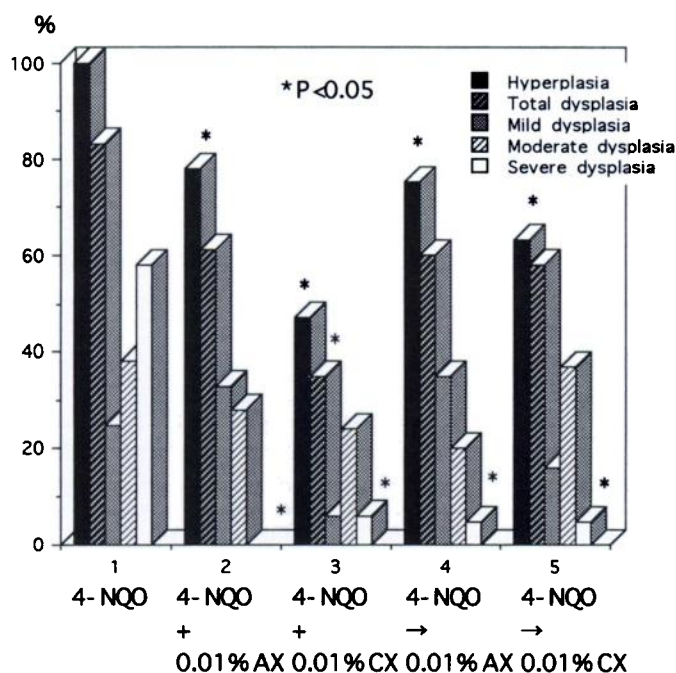


Fig. 2. Incidence of preneoplastic tongue lesions (hyperplasia and dysplasia) in rats treated with 4-NQO and/or AX and CX.

incidences of hyperplasia in groups 2–5 (78% in group 2; 47% in group 3; 75% in group 4; and 63% in group 5) were significantly lower than that of group 1 (100%; $P < 0.05$, $P < 0.001$, or $P < 0.005$). Similarly, the frequencies of severe dysplasia in groups 2–5 (0% in group 2; 6% in group 3; 5% in group 4; and 5% in group 5) were significantly smaller than that of group 1 (58%; $P < 0.001$).

Polyamine Levels in the Tongue Tissue. The results of polyamine levels (nmol/mg protein) in the tongue tissues are presented in Fig. 3. Mean concentrations of diamine (0.25 ± 0.36), spermidine (1.77 ± 0.40), spermine (2.01 ± 0.30), and the sum of these (4.03 ± 0.72) in group 1 were significantly greater than those of group

8 (diamine, 0.09 ± 0.13 ; spermidine, 1.21 ± 0.26 ; spermine, 1.59 ± 0.23 ; and the sum, 2.88 ± 0.36 ; $P < 0.001$). AX and CX feeding significantly reduced these tissue polyamine contents of rats in groups 2–5 ($P < 0.001$, $P < 0.05$, $P < 0.005$, or $P < 0.01$). These values in groups 6 and 7 were slightly smaller than those of group 8.

Results of AgNOR Enumeration and BrdUrd-labeling Index. The results of AgNOR enumeration and BrdUrd-labeling index are summarized in Fig. 4. The mean number of AgNOR/nucleus from normal squamous epithelium in groups 6 (AX alone), 7 (CX alone), and 8 (no treatment) were almost similar, being 1.54 – 1.70 /nucleus. The mean number of AgNOR/nucleus of nonlesional squamous epithelium in group 1 (2.49 ± 1.01 /nucleus) was significantly greater than that of group 8 (1.54 ± 0.78 /nucleus; $P < 0.05$). Average numbers of AgNOR in the cells of nonlesional areas of the tongues from groups 2–5 (1.75 ± 0.73 in group 2; 2.09 ± 0.79 in group 3; 1.90 ± 0.75 in group 4; and 2.06 ± 0.74 in group 5) were significantly smaller than that of group 1 ($P < 0.05$). As for BrdUrd-labeling index

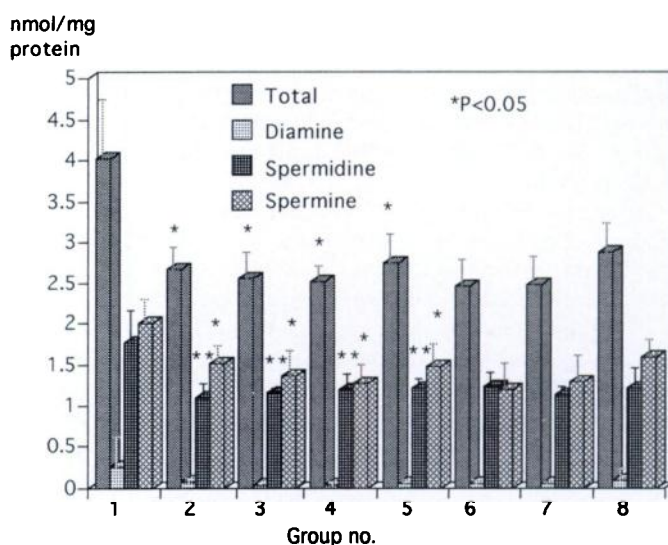


Fig. 3. Tissue polyamine levels (nmol/mg protein) of tongue of rats from each group.

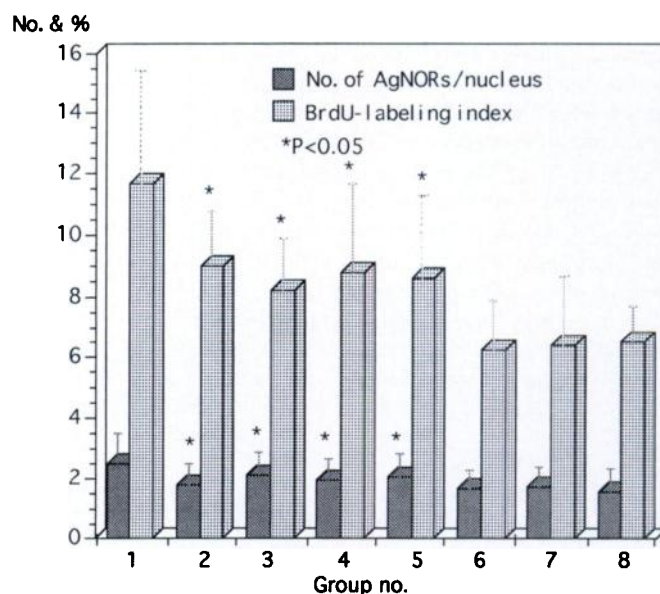


Fig. 4. Alteration of cell proliferation biomarkers. Number of AgNOR/nuclei and BrdUrd (BrdU)-labeling index (%) in the nonlesional squamous epithelium of rats treated with 4-NQO and/or AX and CX.

in nonlesional tongue squamous epithelium, the mean value in group 1 was $11.7 \pm 3.7\%$, being significantly greater than that of group 8 (6.5 ± 1.2 ; $P < 0.05$). AX or CX feeding during either initiation or postinitiation phase significantly decreased BrdUrd-labeling index as shown in Fig. 4 ($P < 0.05$).

DISCUSSION

The results in the present study clearly indicated that dietary administration of AX and CX significantly depressed the development of tongue neoplasms induced by 4-NQO. When AX was fed during either the initiation or postinitiation phase, no tongue tumors developed. Similarly, CX feeding during the initiation phase completely inhibited tongue carcinogenesis.

Several synthetic or natural antioxidants are known to inhibit chemical carcinogenesis (55). Some micronutrients with antioxidative property are also inhibitors of experimental oral carcinogenesis (32, 56, 57). A natural antioxidant β -carotene exerted a suppressing effect on hamster and rat oral tumor development (33, 57, 58). A similar regression of oral carcinogenesis was found after injection of CX into the local sites of developing tumors (35). The results described here confirm their findings and support the epidemiological data of an inverse relationship between carotenoid intake and risk for oral cancer (59). AX and CX might join with antioxidant micronutrients in cancer prevention (60).

Among the xanthophylls, CX and phytoene have been reported to inhibit carcinogenesis in several organs other than the oral cavity (26–29, 34, 35). Administration of CX after carcinogen exposure effectively reduced 7,12-dimethylbenz[*a*]anthracene-induced mammary tumors in rats (29). Also, treatment with CX or phytoene before and during carcinogen exposure inhibited skin tumors induced by UV-B or 7,12-dimethylbenz[*a*]anthracene, followed by UV-B (26). In *N*-methyl-*N'*-nitro-*N*-nitrosoguanidine-induced rat gastric carcinogenesis model, CX administration did not affect the tumor incidence in the glandular stomach but inhibited the progression of dysplasias to infiltrating adenocarcinomas (27). Grubbs *et al.* (29) described that diet supplementation with CX for 3 weeks before the carcinogen, methylnitrosourea, resulted in significant reduction in the number of mammary cancers. However, the feeding of CX after the administration of the carcinogen had no significant effect on mammary carcinogenesis in rats (29). These results may suggest that the modifying effects of CX were dependent on the timing of administration. In the current study, however, AX and CX clearly inhibited oral carcinogenesis when they were consumed during the initiation and postinitiation phases as reported by Suda *et al.* (58). Moreover, inhibitory effects of AX and CX on tongue tumorigenesis were greater than that of β -carotene found in our previous study (33). Although slight retardation of body weight and liver weight gain was observed in rats fed CX, apparent signs for clinical toxicity were not observed during the experiment, as seen other reports (26–29, 34, 35, 37). The correlation of calories, body weight, and tumor incidence was well known: a ~15.3% calorie restriction caused a 20.2% reduction of tumors, and an 11% weight loss reduced tumor incidence by 3.7% (61). In the current study, only a 1–2% body weight reduction was present in group 2 and groups 4–7. Therefore, the reduction of tumor incidence was not due to body weight loss.

Carotenoids have several biological functions (15–18). Xanthophylls like AX and CX have no provitamin A activity, but the antioxidative activity is shared by all carotenoids but to differing degrees (17, 18). Therefore, antitumor effects of carotenoids are independent from their provitamin A activities and may be due to their antioxidative properties (23, 30, 31). In the present study, pinkish coloring was seen in the adipose tissue, liver, and skin, suggesting

deposition of AX and CX in these tissue. The plasma and tissue (oral mucosa, liver, and adipose tissues) levels of xanthophylls (AX and CX) were basically higher in rats fed xanthophylls when compared to those of rats fed the basal diet alone (1.2–1.5-fold increase).⁴ Rats generally do not absorb most carotenoids very well systemically, unless they are fed for prolonged periods. Therefore, chemopreventive effects of AX and CX might be due to local absorption in the oral mucosa, especially in rats fed these xanthophylls during the postinitiation phase.

Several mechanisms by which AX and CX exert their antitumorigenic effects on experimental oral tumorigenesis could be considered. In the present study, AX and CX decreased cell proliferation of nonlesional squamous epithelium, as revealed by AgNOR enumeration and BrdUrd-labeling index. Similar findings were observed in our previous study, in which AX and CX reduced bladder tumorigenesis in mice in conjunction with decreased cell proliferation in nonlesional bladder epithelium. Cell proliferation is suggested to play an important role in multistage carcinogenesis (62), including oral tumorigenesis (63). Our recent works demonstrated protective effects of several plant phenolics on liver, colon, and tongue tumorigenesis in rats (64–70). These compounds have antioxidative activities with various degrees, and its chemopreventive property of carcinogenesis is considered to be partly due to inhibition of cell proliferation. A natural carotenoid, fucoxanthin, has recently been reported to inhibit cell proliferation and *N*-myc expression of a human neuroblastoma cell line, GOTO cells (71, 72). In the present study, inhibitory effects of AX and CX on 4-NQO-induced rat tongue tumorigenesis were paralleled with inhibition of cell proliferation of these two xanthophylls. Therefore, it is possible that a significant antitumor property of AX and CX may be partly due to its antiproliferative effect on a carcinogen-exposed epithelium in this experimental condition. Immunomodulation is one of the common biological functions of carotenoids (15–18). CX, AX, and β -carotene are known to enhance immune response (73–75). This function is also a potential explanation for tumor protection of CX (34, 76). More recently, a novel function of certain carotenoids, including β -carotene and CX, has been reported (77). Some natural and synthetic carotenoids inhibited chemically and physically induced neoplastic transformation in C3H/10T1/2 cells and increased the expression of connexin43, a gene that encodes a major gap junction protein might explain their suppressing effects on carcinogenesis. The latter findings are of interest because gap junctional communication appears to play an important role in cell growth control and carcinogenesis (78–80). In contrast to β -carotene, only a few studies on tumor inhibition of xanthophylls, which lack toxicity, have been conducted. Therefore, additional investigations of a mechanistic basis for chemopreventive action of xanthophylls, including AX and CX, are highly warranted.

ACKNOWLEDGMENTS

The authors thank Kyoko Takahashi, Tomomi Kawamoto, and Hiroko Hattori for their excellent technical assistance and Kazumasa Satoh for animal care.

REFERENCES

1. Weisburger, J. H. Nutritional approach to cancer prevention with emphasis on vitamins, antioxidants, and carotenoids. *Am. J. Clin. Nutr.*, 53: 226S–237S, 1991.
2. Tanaka, T. Cancer chemoprevention. *Cancer J.*, 5: 11–16, 1992.
3. Stavic, B. Role of chemopreventers in human diet. *Clin. Biochem.*, 27: 319–332, 1994.
4. Higginson, J., and Sheridan, M. J. Nutrition and human cancer. In: R. B. Alfin-Slater and D. Kritchevsky (eds.), *Cancer and Nutrition*, pp. 1–50. New York: Plenum Publishing Corp., 1991.

⁴ Manuscript in preparation.

5. Rogers, A. E., Zeisel, S. H., and Groopman, J. Diet and carcinogenesis. *Carcinogenesis (Lond.)*, *14*: 2205-2217, 1993.
6. Tanaka, T. Effect of diet on human carcinogenesis. *Crit. Rev. Oncol. Hematol.*, *17*: in press, 1995.
7. Hill, D. L., and Grubbs, C. J. Retinoids as chemopreventive and anticancer agents in intact animals (review). *Anticancer Res.*, *2*: 111-124, 1982.
8. Micozzi, M. S., Beccher, G. R., Taylor, P. R., and Khachik, F. Carotenoid analyses of selected raw and cooked food association with a low risk for cancer. *J. Natl. Cancer Inst.*, *82*: 282-285, 1990.
9. Block, G., Patterson, B., and Subar, A. Fruit, vegetables, and cancer prevention: a review of the epidemiological evidence. *Nutr. Cancer*, *18*: 1-29, 1992.
10. Steinmetz, K. A., and Potter, J. D. Vegetables, fruit, and cancer. I. Epidemiology. *Cancer Causes Control*, *2*: 325-357, 1991.
11. Hong, W. K., and Itri, L. M. Retinoids and human cancer. In: M. B. Sporn, A. B. Roberts, and D. S. Goodman (eds.), *The Retinoids: Biology, Chemistry, and Medicine*, pp. 597-630. New York: Raven Press, 1994.
12. Moon, R. C., Mehta, R. G., and Rao, K. V. N. Retinoids and cancer in experimental animals. In: M. B. Sporn, A. B. Roberts, and D. S. Goodman (eds.), *The Retinoids: Biology, Chemistry, and Medicine*, pp. 573-596. New York: Raven Press, 1994.
13. Bertram, J. S., Kolonel, L. N., and Meyskens, F. L. Rationale and strategies for chemoprevention of cancer in humans. *Cancer Res.*, *47*: 3012-3031, 1987.
14. Khachik, F., Beecher, G. R., and Whittaker, N. F. Separation, identification, and quantification of the major carotenoid and chlorophyll constituents in extracts of several green vegetables by liquid chromatography. *J. Agric. Food Chem.*, *34*: 603-616, 1986.
15. Bendich, A., and Olson, J. A. Biological actions of carotenoids. *FASEB J.*, *3*: 1927-1932, 1989.
16. Olson, J. A. Provitamin A function of carotenoids: the conversion of β -carotene into vitamin A. *J. Nutr.*, *119*: 105-108, 1989.
17. Lim, B. P., Nagao, A., Terao, J., Tanaka, K., Suzuki, T., and Takama, K. Antioxidant activity of xanthophylls on peroxy radical-mediated phospholipid peroxidation. *Biochim. Biophys. Acta*, *1126*: 178-184, 1992.
18. Palozza, P., and Krinsky, N. I. Astaxanthin and canthaxanthin are potent antioxidants in a membrane model. *Arch. Biochem. Biophys.*, *297*: 291-295, 1992.
19. Murakoshi, M., Nishino, H., Satomi, Y., Takayasu, J., Hasegawa, T., Tokuda, H., Iwashima, A., Okuzumi, J., Okabe, H., Kitano, H., and Iwasaki, R. Potent preventive action of α -carotene against carcinogenesis: spontaneous liver carcinogenesis and promoting stage of lung and skin carcinogenesis in mice are suppressed more effectively by α -carotene than by β -carotene. *Cancer Res.*, *52*: 6583-6587, 1992.
20. Straub, O. In: H. Pfander (ed.), *Key to Carotenoids*, pp. 1-296. Basel, Switzerland: Birkhauser-Verlag, 1987.
21. Krinsky, N. I. Carotenoids and cancer in animal models. *J. Nutr.*, *119*: 123-126, 1989.
22. Krinsky, N. I. Effects of carotenoids in cellular and animal systems. *Am. J. Clin. Nutr.*, *53*: 238S-246S, 1991.
23. Pung, A., Rundhaug, J. E., Yoshizawa, C. N., and Bertram, J. S. β -carotene and canthaxanthin inhibit chemically and physically induced neoplastic transformation in 10T1/2 cells. *Carcinogenesis (Lond.)*, *9*: 1533-1539, 1988.
24. Azzuine, M. A., Goswami, U. C., Kayal, J. J., and Bhide, S. V. Antimutagenic and anticarcinogenic effects of carotenoids and dietary palm oil. *Nutr. Cancer*, *17*: 287-295, 1992.
25. Huang, D. S., Odeleye, O. E., and Watson, R. R. Inhibitory effects of canthaxanthin on *in vivo* growth of murine tumor cells. *Cancer Lett.*, *65*: 209-213, 1992.
26. Mathews-Roth, M. M. Antitumor activity of β -carotene, canthaxanthin and phytoene. *Oncology*, *39*: 33-37, 1992.
27. Santamaria, L., Bianchi, A., Ravetto, C., Arnaboldi, A., Santagati, G., and Andreoni, L. Prevention of gastric cancer induced by *N*-methyl-*N'*-nitro-*N*-nitrosoguanidine in rats fed supplemental carotenoids. *J. Nutr. Growth Cancer*, *4*: 175-181, 1987.
28. Okuzumi, J., Takahashi, T., Yamane, T., Kitao, Y., Inagake, M., Ohya, K., Nishino, H., and Tanaka, Y. Inhibitory effects of fucoxanthin, a natural carotenoid, on *N*-ethyl-*N'*-nitro-*N*-nitrosoguanidine-induced mouse duodenal carcinogenesis. *Cancer Lett.*, *68*: 159-168, 1993.
29. Grubbs, C. J., Eto, I., Juliana, M. M., and Whitaker, L. M. Effect of canthaxanthin on chemically induced mammary carcinogenesis. *Oncology*, *48*: 239-245, 1991.
30. Bendich, A. Symposium conclusions: biological actions of carotenoids. *J. Nutr.*, *119*: 135-136, 1989.
31. Burton, G. W., and Ingold, K. U. Beta-carotene: an unusual type of lipid anti-oxidant. *Science (Washington DC)*, *224*: 569-573, 1984.
32. Tanaka, T. Chemoprevention of oral carcinogenesis. *Oral Oncol. Eur. J. Cancer*, *31B*: 3-15, 1994.
33. Tanaka, T., Makita, H., Ohnishi, M., Hirose, Y., Wang, A., Mori, H., Satoh, K., Hara, A., and Ogawa, H. Chemoprevention of 4-nitroquinoline 1-oxide-induced oral carcinogenesis by dietary curcumin and hesperidin: comparison with the protective effect of β -carotene. *Cancer Res.*, *54*: 4653-4659, 1994.
34. Shklar, G., and Schwartz, J. Tumor necrosis factor in experimental cancer regression with α -tocopherol, β -carotene, canthaxanthin and algae extract. *Eur. J. Cancer Clin. Oncol.*, *24*: 839-850, 1988.
35. Schwartz, J., and Shklar, G. Regression of experimental oral carcinomas by local injection of β -carotene and canthaxanthin. *Nutr. Cancer*, *11*: 35-40, 1988.
36. Tomita, Y. Studies on the role of nutrition and diet in prevention of cancer (in Japanese). *Bull. Phys. Fitness Res. Inst.*, *72*: 116-120, 1989.
37. Tanaka, T., Morishita, Y., Suzui, M., Kojima, T., Okumura, A., and Mori, H. Chemoprevention of mouse urinary bladder carcinogenesis by the naturally occurring carotenoid astaxanthin. *Carcinogenesis (Lond.)*, *15*: 15-19, 1994.
38. Slaughter, D. P., Southwick, H. W., and Smejkal, W. Field cancerization in oral stratified squamous epithelium: clinical implications of multicentric origin. *Cancer (Phila.)*, *6*: 963-968, 1953.
39. Hong, W. K., Lippman, S. M., and Wolf, G. T. Recent advances in head and neck cancer: larynx preservation and cancer chemoprevention. The Seventeenth Annual Richard and Hinda Rosenthal Foundation Award Lecture. *Cancer Res.*, *53*: 5113-5120, 1993.
40. Tanaka, T. Chemoprevention of human cancer: biology and therapy. *Crit. Rev. Oncol. Hematol.*, *16*: in press, 1995.
41. Day, G. L., and Blot, W. J. Second primary tumors in patients with oral cancer. *Cancer (Phila.)*, *70*: 14-19, 1992.
42. Cooper, J. S., Pajak, T. F., Rubin, P., Tupchong, L., Brady, L. W., Liebel, S. A., Laramarc, G. E., Marcial, V. A., Davis, L. W., and Cox, J. D. Second malignancies in patients with head and neck cancer: incidence, effect on survival and implications based on the RTOG experience. *Int. J. Radiat. Oncol. Biol. Phys.*, *17*: 449-456, 1989.
43. Byers, R. M. Multiple primary squamous cell carcinomas of the upper aerodigestive tract. *Adv. Exp. Med. Biol.*, *320*: 27-29, 1992.
44. Crissman, J. D., Visscher, D. W., and Sakr, W. Premalignant lesions of the upper aerodigestive tract: pathologic classification. *J. Cell. Biochem.*, *17F (Suppl.)*: 49-56, 1993.
45. Hong, W. K., Endicott, J., Itri, L. M., Doos, W., Batsakis, J. G., Bell, R., Fofonoff, S., Beyers, R., Atkinson, F. N., Vaughan, C., Toth, B. B., Kramer, A., Dimery, I. W., Skipper, S., and Strong, S. 13-*Cis*-retinoic acid in the treatment of oral leukoplakia. *N. Engl. J. Med.*, *315*: 1501-1505, 1986.
46. Benner, S. E., Lippman, S. M., and Hong, W. K. Retinoid chemoprevention of second primary tumors. *Semin. Hematol.*, *31*: 26-30, 1994.
47. Teilmann, K. Retinoids: toxicology and teratogenicity to date. *Pharmacol. Ther.*, *40*: 29-43, 1989.
48. Bendich, A. The safety of β -carotene. *Nutr. Cancer*, *11*: 207-214, 1988.
49. Mathews-Roth, M. M., Pathak, M. A., Pathak, M. A., Fitzpatrick, T. B., and Kass, E. H. A clinical trial of the effects of oral beta-carotene on the responses of human skin to solar radiation. *J. Invest. Dermatol.*, *59*: 349-353, 1972.
50. Barnes, D. M., and Gillett, C. E. Determination of cell proliferation. *J. Clin. Pathol.*, *48*: M2-M5, 1994.
51. Tanaka, T., Takeuchi, T., Hara, A., Ohno, T., Kojima, T., Morishita, Y., Mori, Y., Kawada, Y., Mori, H., and Inaba, S. Computer-assisted image analysis of silver-positive nucleolar organizer regions in preneoplastic and neoplastic lesions of the liver and urinary bladder induced by carcinogens in rats (in Japanese). *J. Clin. Exp. Med.*, *154*: 81-82, 1990.
52. Bánóczy, J., and Csiba, A. Occurrence of epithelial dysplasia in oral leukoplakia. *Oral Surg.*, *42*: 766-774, 1976.
53. World Health Organization. Collaborating Center for oral precancerous lesions: definition of leukoplakia and related lesions: an aid to studies on precancer. *Oral Surg.*, *46*: 518-539, 1978.
54. Koide, T. The clinical significance of tissue, blood and urine polyamine in renal cell carcinoma (in Japanese). *Jpn. J. Urol.*, *83*: 1228-1237, 1992.
55. Ito, N., and Hirose, M. Antioxidants: carcinogenic and chemopreventive properties. *Adv. Cancer Res.*, *53*: 247-302, 1989.
56. Gimenez-Conti, I. B., and Slaga, T. J. The hamster cheek pouch carcinogenesis model. *J. Cell Biochem.*, *17F (Suppl.)*: 83-90, 1993.
57. Shklar, G., and Schwartz, J. Oral cancer inhibition by micronutrients. The experimental basis for clinical trials. *Oral Oncol. Eur. J. Cancer*, *29B*: 9-16, 1993.
58. Suda, D., Schwartz, J., and Shklar, G. Inhibition of experimental oral carcinogenesis by topical β -carotene. *Carcinogenesis (Lond.)*, *7*: 711-715, 1986.
59. La Vecchia, C., Franceschi, S., Levi, F., Lucchini, F., and Negri, E. Diet and human oral carcinoma in Europe. *Oral Oncol. Eur. J. Cancer*, *29B*: 17-22, 1993.
60. Dorgan, J. F., and Schatzkin, A. Antioxidant micronutrients in cancer prevention. *Hematol. Oncol. Clin. N. Am.*, *5*: 43-68, 1991.
61. Albanes, D. Total calories, body weight, and tumor incidence in mice. *Cancer Res.*, *47*: 1987-1992, 1987.
62. Cohen, S. M., and Ellwein, L. B. Cell proliferation in carcinogenesis. *Science (Washington DC)*, *249*: 1007-1011, 1990.
63. Tanaka, T., Kojima, T., Okumura, A., Yoshimi, N., and Mori, H. Alterations of the nucleolar organizer regions during 4-nitroquinoline 1-oxide-induced tongue carcinogenesis in rats. *Carcinogenesis (Lond.)*, *12*: 329-333, 1991.
64. Tanaka, T., Yoshimi, N., Sugie, S., and Mori, H. Protective effects against liver, colon and tongue carcinogenesis by plant phenols. In: M.-T. Huang, C.-T. Ho, and C. Y. Lee (eds.), *Phenolic Compounds in Food and Their Effects on Health II. Antioxidants & Cancer Prevention*, pp. 326-337. Washington, DC: American Chemical Society, 1992.
65. Tanaka, T., Kojima, T., Kawamori, T., Yoshimi, N., and Mori, H. Chemoprevention of diethylnitrosamine-induced hepatocarcinogenesis by a simple phenolic acid protocatechuic acid in rats. *Cancer Res.*, *53*: 2775-2779, 1993.
66. Tanaka, T., Kojima, T., Kawamori, T., Wang, A., Suzui, M., Okamoto, K., and Mori, H. Inhibition of 4-nitroquinoline 1-oxide-induced rat tongue carcinogenesis by the naturally occurring plant phenolics caffeic, ellagic, chlorogenic and ferulic acids. *Carcinogenesis (Lond.)*, *14*: 1321-1325, 1993.
67. Tanaka, T., Kojima, T., Suzui, M., and Mori, H. Chemoprevention of colon carcinogenesis by the natural product of a simple phenolic compound protocatechuic acid: suppressing effects on tumor development and biomarkers expression of colon tumorigenesis. *Cancer Res.*, *53*: 3908-3913, 1993.
68. Tanaka, T., Kojima, T., Kawamori, T., and Mori, H. Chemoprevention of digestive organs carcinogenesis by natural product protocatechuic acid. *Cancer (Phila.)*, *75*: 1433-1439, 1995.
69. Tanaka, T. Chemoprevention of oral carcinogenesis. *Oral Oncol. Eur. J. Cancer*, *31B*: 3-15, 1995.
70. Tanaka, T. Cancer chemoprevention by natural products (Review). *Oncol. Rep.*, *1*: 1139-1155, 1994.

71. Okuzumi, J. Antiproliferative and antitumor promoting activities of fucoxanthin, a natural carotenoid. *J. Kyoto Pref. Univ. Med.*, 100: 551–566, 1991.
72. Okuzumi, J., Nishino, H., Murakoshi, M., Iwashima, A., Tanaka, Y., Yamane, T., Fujita, Y., and Takahashi, T. Inhibitory effects of fucoxanthin, a natural carotenoid, on *N-myc* expression and cell cycle progression in human malignant tumor cells. *Cancer Lett.*, 55: 75–81, 1990.
73. Bendich, A., and Shapiro, S. S. Effect of β -carotene and canthaxanthin on the immune responses of the rat. *J. Nutr.*, 116: 2254–2262, 1986.
74. Jyounouchi, H., Hill, R. J., Tomita, Y., and Good, R. A. Studies of immunomodulating actions of carotenoids. I. Effects of β -carotene and astaxanthin on immune lymphocyte functions and cell surface marker expression in *in vitro* culture system. *Nutr. Cancer*, 16: 93–105, 1991.
75. Jyounouchi, H., Zhang, L., and Tomita, Y. Studies of immunomodulating actions of carotenoids. II. Astaxanthin enhances *in vitro* antibody production to T-dependent antigens without facilitating polyclonal B-cell activation. *Nutr. Cancer*, 19: 269–280, 1993.
76. Bendich, A. Carotenoids and the immune response. *J. Nutr.*, 119: 112–115, 1989.
77. Bertram, J. S. Cancer prevention by carotenoids: mechanistic studies in cultured cells. *Ann. NY Acad. Sci.*, 691: 177–191, 1993.
78. Mesnil, M., and Yamasaki, H. Cell-cell communication and growth control of normal and cancer cells: evidence and hypothesis. *Mol. Carcinog.*, 7: 14–17, 1993.
79. Budunova, I. V. Alteration of gap junctional intercellular communication during carcinogenesis. *Cancer J.*, 7: 228–237, 1994.
80. Yamasaki, H. Gap junctional intercellular communication and carcinogenesis. *Carcinogenesis (Lond.)*, 11: 1051–1058, 1990.