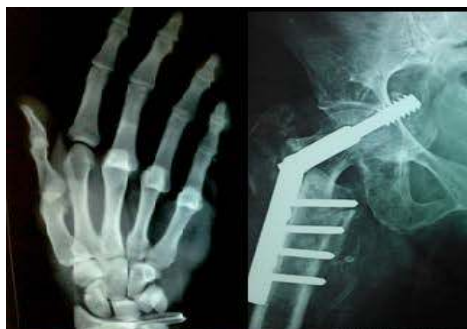



# International Journal of Orthopaedics Sciences

E-ISSN: 2395-1958  
P-ISSN: 2706-6630  
IJOS 2020; 6(1): 26-28  
© 2020 IJOS  
www.orthopaper.com  
Received: 16-11-2019  
Accepted: 20-12-2019

**Márcio Oliveira**  
Orthopedic Department of Vila  
Nova de Gaia/Espinho Hospital  
Center, Portugal

**Inês Casais**  
Orthopedic Department of Vila  
Nova de Gaia/Espinho Hospital  
Center, Portugal

**Ricardo Oliveira**  
Orthopedic Department of Vila  
Nova de Gaia/Espinho Hospital  
Center, Portugal

**Henrique Sousa**  
Orthopedic Department of Vila  
Nova de Gaia/Espinho Hospital  
Center, Portugal

**Domingues Rodrigues**  
Orthopedic Department of Vila  
Nova de Gaia/Espinho Hospital  
Center, Portugal

**Mafalda Santos**  
Orthopedic Department of Vila  
Nova de Gaia/Espinho Hospital  
Center, Portugal

**Corresponding Author:**  
**Márcio Oliveira**  
Orthopedic Department of Vila  
Nova de Gaia/Espinho Hospital  
Center, Portugal

## Chronic tibialis anterior rupture: An underdiagnosed condition

**Márcio Oliveira, Inês Casais, Ricardo Oliveira, Henrique Sousa, Domingues Rodrigues and Mafalda Santos**

DOI: <https://doi.org/10.22271/ortho.2020.v6.i1a.1828>

### Abstract

Rupture of the tibialis anterior tendon is a rare condition and the diagnosis is frequently delayed, due to subtle changes in foot and ankle function. However, chronic deficits can be visible over time namely progressive gait dysfunction, with a limited dorsiflexion and foot slapping.

The authors describe a case report of an isolated chronic anterior tibial tendon rupture, of a 16-year-old boy, treated with a free flap interposition with gracilis tendon.

The gracilis tendon can safely be used as a free flap interposition in chronic anterior tibial tendon rupture with large tendon defects, with excellent clinical results. Large gaps can be successfully bridged with this technique, with the advantage of sparing the other local tendons and lower donor site morbidity.

**Keywords:** Anterior tibial tendon, rupture, gracilis tendon

### Introduction

The tibialis anterior muscle is a long, narrow muscle in the anterior compartment of the lower leg. Just above the ankle, the muscular body ends and its long tendon extends across the medial side of the ankle and into the foot under superior and inferior extensor retinaculum. In the foot, inserts on the first metatarsal and first cuneiform bone<sup>[1]</sup>.

Tibialis anterior is the strongest dorsiflexor of the foot. This movement is critical to gait because clears the foot off the ground during the swing phase. On the other hand, it lift structures of the medial arch into adduction-supination, therefore is also a primary inverter of the foot. Due to its insertion on the medial foot, it also supports the medial longitudinal arch of the foot<sup>[1]</sup>.

Rupture of the tibialis anterior tendon is rare and may be traumatic or atraumatic, from acute laceration and trauma, or degenerative ruptures that can occur spontaneously<sup>[2, 3, 4]</sup>.

The diagnosis is frequently delayed, because many times patient does not seek immediate treatment, and physical examination shows subtle changes. Patients may not notice the functional deficit because dorsiflexion of the ankle can be compensated by extensor hallucis longus and extensor digitorum longus muscles<sup>[5]</sup>.

Chronic deficit can be visible over time due to gait problems with foot slapping, retracted stump pain, progressive pronation, flatfoot deformity, claw and hammer toe deformity from extensor tendon recruitment<sup>[5, 6]</sup>. Surgical procedure aims to restore the function of the tibialis anterior tendon to avoid these late complications.

The authors describe a case report of chronic anterior tibial tendon rupture, with retrospectively review of the operative results. We evaluate the pain, function and alignment results with the American Orthopaedic Foot and Ankle Society (AOFAS) Ankle-Hindfoot Scale, as well as through physical examination and imaging.

### Case report

A 16-year-old boy suffered an open wound at the dorsum of the left foot. At the emergency department the wound was cleaned, sutured and protected with a dressing wound. An antibiotherapy was performed for seven days with amoxicillin clavulanic acid. There was a good wound healing, without evident complications.

Nerveless, in the next few months the patient felt a progressive gait dysfunction, with a feeling of limited dorsiflexion and foot slapping. Thus, he was evaluated by Pediatric Orthopedic Surgeon five months after initial injury. Clinical evaluation shows a diminished strength in dorsiflexion and inversion of the foot, 3/5 according to Medical Research Council (MRC) scale, in comparison with contralateral. Gait pattern showed this limitation (Figure 1). A painful stump was palpable at the level of anterior tibiotalar joint.

A x-ray was performed bilaterally without significant findings. A magnetic resonance was obtained, shows a full-thickness defect at the distal insertion of the anterior tibial tendon, with proximal thickened until below the superior extensor retinaculum. The position of the proximal retracted stump was not well identified, with an estimated tendon gap of 2cm (Figure 2). No other significant findings were identified.

In order to prevent the progression of the symptoms, a surgical procedure was proposed to restore foot function. Surgical procedure was done through an anteromedial 12 cm incision, overlying the tibialis anterior tendon from the medial cuneiform to the superior extensor retinaculum where de stump were palpable. Dissection was performed through the inferior extensor retinaculum distally, and tibialis anterior tendon sheath. The proximal and distal tendon stumps were identified and released below and above the superior and inferior extensor retinaculum respectively. It was necessary to incise about 1 cm of proximal extensor retinaculum to complete release the proximal stump. However, we tried to minimize this incision to prevent bowstringing and adhesions between the reconstructed tendon and subcutaneous tissues. Similarly, the tendon sheath was released from significant adhesions to gain excursion for posterior closure.

Then, the nonviable tendon with granulation tissue was excised, leaving a distal tendon stump of 1cm and a defect of nearly 8 cm measured with the foot and ankle at rest. The tendon insertion site was debrided of the distal tendon remnant, as well as the proximal tendon stump to healthy tissue.

The tendon was then pulled out proximally to the superior extensor retinaculum to facilitate the repair. To reconstruct the large tendon defect, we used a free gracilis tendon autograft obtained from the ipsilateral leg. A 20 cm long gracilis tendon was harvested using a tendon stripper through a 3 cm long longitudinal incision over the pes anserinus. Next, the gracilis was looped to create a triple graft with almost 5 mm thickness, and a direct repair to the proximal stump was done with non resorbable *Ethibond* number 1 *Krakow* sutures, and reinforced with absorbable continuous suture in a circular fashion.

Under fluoroscopy, the medial cuneiform was identified and a 2.4 mm guide wire with eyelet was inserted perpendicular to the dorsal surface of the bone. Next we drill a 6mm tunnel from dorsal to plantar, through the two cortices.

Using the whipstitch and the eyelet of the guidewire, the tendon was pulled through the medial cuneiform bone tunnel and the suture pulled out through the sole of the foot. The tendon was then tensioned by hand, and a nitinol wire was used in the tunnel to facilitate the interference screw fixation. The tendon sheath of the anterior tibial tendon was then closed from proximal to distal with an absorbable suture. The extensor inferior retinaculum was not repaired at the end to prevent adhesions.

Patient was kept non-weightbearing, the ankle was protected

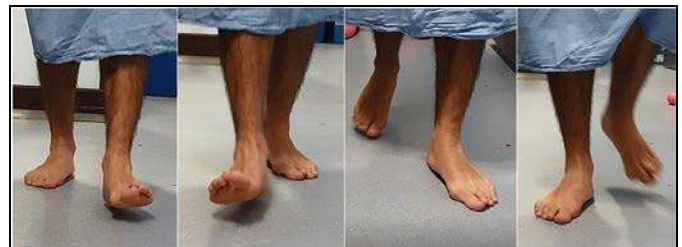with a posterior splint until stitches were removed in two weeks. Then, patient was allowed to partial weightbearing with a walker boot and crutches until eight weeks. During this time, patient was encourage to do active motion of foot and ankle without weightbearing. Then walker boot was removed and patient initiated partial weight bearing only with crutches, with progression as tolerated. Sports-related rehabilitation started at 3 months.

The average AOFAS Ankle-Hindfoot Scale improved from 65 to 100 postoperatively at 6 months follow-up. Stratification values shows that the patient was not greatly affected by pain (30/40), instead the complains were more related to function (30/50).

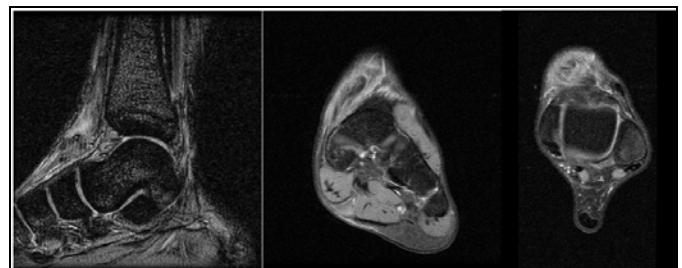
At physical examination the patient demonstrate improved ankle dorsiflexion and hindfoot inversion strength upon clinical evaluation. There was no swelling, no tenderness or pain and no scar-related complains (Figure 3).

At six months follow-up the patient had a normal gait pattern and running without complains, including contact sports activities. At this point, he was very satisfied with the results, with return to pre-injury activity level.

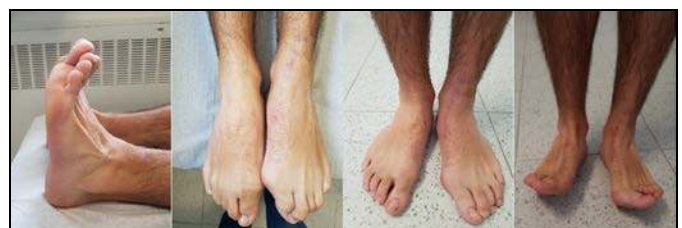No postoperative complications occurred.



**Fig 1:** Gait analysis. Terminal swing phase shows a diminished left ankle dorsiflexion and inversion of the foot, no activity of anterior tibial tendon is seen in comparison with contralateral. Midstance phase shows a slightly plantar arch collapse of the left foot.



**Fig 2:** Magnetic Resonance Imaging shows a full-thickness defect at the distal insertion of the anterior tibial tendon, with proximal thickened until below the superior extensor retinaculum. The tendon gap was in fact underestimated, corresponding to 2 cm in MRI and about 8 cm measured intraoperatively with the foot and ankle at rest.



**Fig 3:** At physical examination, there was normal and symmetric range of motion in dorsiflexion and plantarflexion. There was no swelling, no tenderness or pain and no scar-related complains. The patient was capable of toes and heel walk at 4 months follow-up.

## Discussion

Isolated anterior tibial tendon rupture is rare and literature is

sparse in respect of this topic. As such, a large number of different surgical techniques has been described on a surgeon preference basis. Management of these lesions has no clear consensus, despite this, the overall operative treatment of chronic anterior tibial tendon rupture has been associated to a high level of patient satisfaction and functional outcomes<sup>[7, 8]</sup>. We describe a rare cause of isolated tibial anterior tendon rupture: direct open traumatic rupture.

The goals of the surgery in TAT surgery is to treat the different complaints on admission as pain, loss of strength, instability during gait with forefoot dropping and stumbling. Similarly, this surgery aims to prevent complaints associated to chronic progression, as toes deformities secondary to a compensation mechanism of recruitment of long toe extensor tendons and Achilles tendon shortening<sup>[6]</sup>.

In our case, we choose the free flap interposition with gracilis tendon<sup>[9, 10]</sup>. The advantages of this procedure are the ability to bridge larger defects and does not require a distal tendon stump, instead a medial cuneiform tenodesis is performed. Other important advantage is the direct control of the tendon tension as we pull plantar way across the bone tunnel. Gracilis tendon harvest is a familiar procedure to orthopedic surgeons and its donor site morbidity is rare<sup>[11]</sup>. Finally, we preserve the remaining anatomy as we spare other local tendons to transfer.

The double gracilis tendon graft has an adequate strength for this function<sup>[12]</sup>. In our case report, we use a triple graft because the length was enough to fill the defect.

During the procedure, it is very important not to release the entire superior extensor retinaculum in order to prevent the bowstring of the tendon through the ankle joint. We did not choose a proximal *Pulvertaft* type suture to the native tendon to prevent a bulk of the proximal tendon and consequently superior retinaculum conflict.

We should carefully evaluate the imaging studies, namely MRI, because this could underestimate the severity of the lesion and his gap<sup>[13]</sup>. Therefore, the surgeon must choose the surgical technique according to intraoperative findings.

In our case, despite the delayed diagnosis, close to normal strength in ankle dorsiflexion and inversion was restored without donor site morbidity.

The gracilis tendon has already been used in many other foot and ankle procedures, namely reconstruction and instability: lateral ligaments, achilles, peroneus brevis, deltoid and spring ligaments and tibialis posterior<sup>[14]</sup>. Its use as free flap interposition in the reconstruction of the chronic tibialis anterior tendon is an easily and reproducible procedure with important advantages and good outcomes<sup>[9, 10]</sup>.

## Conclusion

The gracilis tendon can safely be used as a free flap interposition in chronic anterior tibial tendon rupture with large tendon defect, with excellent clinical results. The literature is not conclusive about the superiority of one single procedure, due to a small number of cases. However, large gaps can be successfully bridged with gracilis tendon graft, with the advantage of sparing the other local tendons and lower donor site morbidity.

## References

1. Willegger M, Seyidova N, Schuh R, Windhager R, Hirtler L. Anatomical footprint of the tibialis anterior tendon: surgical implications for foot and ankle reconstructions. *Biomed Res Int*. 2017; 2017:9542125.
2. Bernstein RM. Spontaneous rupture of the tibialis

- anterior tendon. *Am J Orthop (Belle Mead NJ)*. 1995; 24(4):354-356.
3. Crosby LA, Fitzgibbons TC. Unrecognized laceration of tibialis anterior tendon: a case report. *Foot Ankle*. 1988; 9(3):143-145.
4. Din R, Therkilsden L. Rupture of tibialis anterior associated with a closed midshaft tibial fracture. *J Accid Emerg Med*. 1999; 16(6):459.
5. Markarian GG, Kelikian AS, Brage M, Trainor T, Dias L. Anterior tibialis tendon ruptures: an outcome analysis of operative versus nonoperative treatment. *Foot Ankle Int*. 1998; 19(12):792-802.
6. Cohen DA, Gordon DH. The long-term effects of an untreated tibialis anterior tendon rupture. *J Am Podiatr Med Assoc*. 1999; 89(3):149-152.
7. Kopp FJ, Backus S, Deland JT, O'Malley MJ. Anterior tibial tendon rupture: results of operative treatment. *Foot Ankle Int*. 2007; 28(10):1045-7.
8. Claudia Christman-Skieller, MD, Michael K. Merz, MD, and Joseph P. Tansey, MD. A Systematic Review of Tibialis Anterior Tendon Rupture Treatments and Outcomes. *The American Journal of Orthopedics*, 2015.
9. Stavrou P, Symeonidis PD. Gracilis tendon graft for tibialis anterior tendon reconstruction: a report of two cases. *Foot & ankle international*. 2008; 29:742-745.
10. Yamazaki S, Majima T, Yasui K, Kikumoto T, Minami A. Reconstruction of chronic anterior tibial tendon defect using hamstring tendon graft: a case report. *Foot & ankle international*. 2007; 28:1190-1193.
11. Tashiro T, Kurosawa H, Kawakami A, Hikita A, Fukui N. Influence of medial hamstring tendon harvest on knee flexor strength after anterior cruciate ligament reconstruction. A detailed evaluation with comparison of single- and double-tendon harvest. *Am J Sports Med*. 2003; 31:522-9.
12. Schimizzi A, Wedemeyer M, Odell T, Thomas W, Mahar AT, Pedowitz R. Effects of a novel sterilization process on soft tissue mechanical properties for anterior cruciate ligament allografts. *Am J Sports Med*. 2007; 35:612-6.
13. Redfern D, Myerson M. The management of concomitant tears of the peroneus longus and brevis tendons. *Foot Ankle Int*. 2004; 25:695-707.
14. Elizabeth A Cody, Sydney C Karnovsky, Bridget DeSandis, Andrea Tychanski Papson, Jonathan T. Deland, Mark C Drakos. Hamstring Autograft for Foot and Ankle Applications. *Foot & Ankle International*, 2017.