

Chronological response of prostacyclin changes to moderately low doses of radiation in Rat cervical spinal cord

S.R. Mahdavi^{1*}, A.R. Nikoofar², H.R. Mirzaee³, B. Mofid³, R. Mohammadi⁴

¹ Department of Medical Physics, Babol University of Medical Sciences, Babol, Iran

² Department of Radiation Oncology, Iran University of Medical Sciences, Tehran, Iran

³ Department of Radiation Oncology, Sh. Beheshti University of Medical Sciences, Tehran, Iran

⁴ Department of Internal Medicine, Zanjan University of Medical Sciences, Zanjan, Iran

Background: Study of vascular and its secretory profile changes is an important issue in pathogenesis of radiation myelopathy. This paper reports the prostacyclin concentration changes after low-moderate doses of X-irradiation within a short period of time. **Materials and Methods:** Cervical cords of Wistar rats were irradiated to doses of 0.5, 1, 2, 4 and 6 Gy X-rays. After 24 hours, 2 and 13 weeks post-irradiation, prostacyclin contents were quantified and cords specimens were also stained routinely for histological studies. **Results:** Twenty four hours post-irradiation, showed a decrease in the content of prostacyclin after doses of 0.5 and 1 Gy $91.67 \pm 1.47\%$ $96.80 \pm 2.17\%$ of respectively age-matched control group. After 2 weeks the concentration of prostacyclin showed significant decreases after 6 Gy. After 13 weeks irradiation shows marked differences even after a small dose of 2 Gy ($p < 0.001$), and after doses of the low dose group. The differences between concentration values at doses of 4 Gy and 6 Gy were significant in comparison with the control ($p < 0.001$ and $p < 0.002$, respectively). **Conclusion:** Results suggested that the response of the vascular tissues to low and moderate doses of radiation occurs prior to that of the nervous tissue of the spinal cord. It means that the asymptomatic interval after radiation is characterized by sequential physiological changes which are imperfectly reflected in routine histological study and that even in the histologically unaffected spinal cord; severe impairment is present in substructures and biochemistry of irradiated spinal cord. Iran. J. Radiat. Res., 2006; 4 (3): 129-136

Keywords: Prostacyclin, radiation myelopathy, low irradiation dose, time effects.

INTRODUCTION

Recent advances reported the probable priority of vascular and its secretory profile changes in pathogenesis of radiation myelopathy (RM). Vascular hypothesis states

that vascular changes occur prior to any alterations in the white matter parenchyma possibly due to low dose radiosensitivity of vascular endothelium^(1, 2). Modern enzymatic and/or immunohistochemical techniques have been applied to animal models for studying the radiation-induced changes in the various biochemical mediators produced by different cells within the irradiated medium⁽²⁾. Prostacyclin *in vitro* measurement has shown its alteration shortly after low dose irradiation. Prostaglandins (PGs) have applications in diagnosis of different spinal cord disorders in a range from cerebrospinal fluid to intra spinal antibody microprobes or spinal cord homogenates. A basal level of PGs may exist in many laboratory samples and it is believed that injury to tissue induces release of prostaglandins⁽³⁾.

The possibility of the eicosanoids role in development of radiation toxicities have been reported by other investigations⁽³⁻⁷⁾. More recent studies have also shown that some prostaglandins are responsive to irradiation and their early changes can induce the late reactions of spinal cord so called radiation myelopathy^(3, 8, 9).

Purpose of this article is to study the model of prostaglandin I₂ (PGI₂) or prostacyclin concentration changes in response to the low doses of X-irradiation after a short period of time.

*Corresponding author:

Dr. Sied Rabi Mahdavi, Department of Medical Physics, Babol University of Medical Sciences, Babol, Iran.

Fax: +98 112 5231521

E-mail: srmahdavi@hotmail.com

MATERIALS AND METHODS

Animals

Male rats with 150-200 g weight were selected and grouped in 5 separate groups. X-ray of 200 kVp (HVL=1.5 mm Cu) at a dose rate of 146.5 cGy/min, generated from Siemens Stabilipan orthovoltage machine, was used to irradiate the rats cervical spinal cord through two parallel opposed lateral ports. The rats were fixed on a dedicated jig to produce a focal skin distance of 25 cm and a reproducible irradiation⁽¹⁰⁾. Doses of 0.5, 1, 2, 4 and 6 Gy were irradiated and the animals were autopsied after 24 hours, 2 and 13 weeks to remove the spinal cord. Each specimen then was divided into three parts for prostacyclin measurement and simultaneous histopathological studies for structural and ultra-structural changes. These experiments were performed according to the national laws of the conduct of experimentation in Tehran University of Medical Sciences.

Prostaglandin I₂ assay

Prostacyclin or prostaglandin I₂ (PGI₂) concentration is quantified by measuring the level of 6-keto-prostaglandin F_{1 α} (6kPGF_{1 α}), as a stable hydrolyzed product of unstable PGI₂ (prostacyclin) with proportional level in the medium to the prostacyclin content. Enzyme-Immuno Assay (EIA) kit was used to measure 6kPGF_{1 α} (Cayman Co.) which was based on the competition uptake between medium 6-keto PGF_{1 α} and a 6-keto Acetyl cholinesterase (AChE) conjugate (6-keto PGF_{1 α} tracer) for a limited number of 6-keto specific rabbit antiserum binding sites. The product of this enzymatic reaction had a distinct yellow color and could be absorbed strongly at 412 nm using ELISA technology.

The specimen were processed with perchloric acid and centrifuged to obtain the supernatant. The diluted supernatants were pipetted in the 96 well plates with tracer and antibodies. The plates were incubated for 18 hours, and then washed out and Ellman's reagent was added to each plate to be prepared for ELISA reading. The specificity

of this technique for detection of 6-keto prostaglandin F_{1 α} was measured to be 100%. The concentration of 6kPGF_{1 α} (in pg/ml) was obtained by the calibrated standard curve for each assay.

Histopathological study

The samples for electron and light microscopy were immersed into the appropriated fixatives immediately, and processed by routine procedures of staining and preparation. All sections were evaluated qualitatively and scored for histopathologic variable. Finally, the overall score was considered for each dose group in comparison with those of the age-matched control group (+ for mild, ++ for moderate, and +++ for severe reactions)⁽⁶⁾. Images of spinal cord sections were examined by a histopathologist for changes in white matter stroma and for vascular changes in comparison with control cases. Vessels were examined for structural changes including the wall rupture and their density alteration throughout the white matter parenchyma. The scores for each variable were summed to obtain the total effect (TE) of irradiation regarding to the specific variable.

Statistical analysis:

Student's *t*-test was used to analyze the difference between prostacyclin concentration of the irradiated and sham age-matched control groups. Spearman (Pearson ranked test) analysis was used to obtain the correlation between prostacyclin and histopathological changes.

RESULTS

Prostacyclin response

Twenty four hours post-irradiation, finding shows the first decrease in the content of prostacyclin after dose of 0.5 Gy with 91.67±1.47% of age-matched control group and quantified as 516.09±43.83 pg/ml (mean±SE). The measurement after dose delivery of 1 Gy showed an upward increase in content of prostacyclin with 96.80±2.17%

to control and quantified as 544.92 ± 64.49 pg/ml (figure 1).

The low dose region scattergram showed a non-significant increase in prostacyclin concentration after 2 Gy irradiation in comparison with the control ($p=0.11$), and at a dose of 4 Gy ($p=0.1$). A significant decrease occurred after 6 Gy ($p=0.03$). The p -values indicating the difference between prostacyclin concentrations of control and irradiated groups was significant (figure 2a).

Figure 2b shows the changes in the prostacyclin content, 2 weeks after irradiation with different doses of 2 to 6 Gy. The concentration of prostacyclin showed some fluctuations. Significant decreases are seen after 6 Gy irradiation.

The profile of prostacyclin content in the cervical spinal cord after 13 weeks showed marked differences compared to the other time points. Prostacyclin concentration was seen to be higher than the earlier times even after a small dose of 2 Gy ($p<0.001$) as well as after doses of the low dose group. The differences between concentrations values at doses of 4 Gy and 6 Gy in comparison with the control were significant ($p<0.001$ and $p<0.002$, respectively) (figure 2c).

Histopathological findings

Simultaneously, histopathological study was accomplished to find the possible

correlation between histopathological and prostacyclin changes. Various histological changes were detected within the irradiated spinal cord. No early histologic change was observed after 24 hours within the structure of the spinal cord. The frequency of vascular abnormalities was more obvious at 2 weeks post-irradiation. They were detected after low doses of 2, 4, and 6 Gy. Predominant vascular changes were consisted of red blood cells (RBC) and mono-nuclear infiltrations, vascular dilatation, congestion, hemorrhage and thrombosis (figure 3a, b). After 13 weeks of irradiation, a decrease in histopathological abnormalities, both in neuroglia cells and vascular bed relative to the changes after 2 weeks of irradiation, was observed. None of the irradiated animals with doses of 2, 4, and 6 Gy developed typical clinical manifestation of radiation myelopathy. Vascular effects were more prominent compared to the effects of radiation on neuroglial supporting cells (figure 3c, d).

We found ultrastructural changes after irradiation (even 24 hours) mostly seen as vesiculation and some degeneration in nuclear membrane. Ultrastructural changes in endothelial cells were identical at different post-irradiation times. After 13 weeks there were seen degenerative changes in cytoplasmic membrane, folding of nucleus, ballooning of mitochondria and dilatation of endoplasmic reticulum. In addition, we could detect multiple auto-lysosomes after 2 Gy, detachment of cytoplasmic and basal cell membrane after doses of 4 and 6 Gy, multiple rough endoplasmic reticulum, polysomes, mitochondria and lysosomes after dose of 2 Gy (figure 4).

DISCUSSION

Focusing on whether the major target of radiation damage or action is oligodendrocytes (glial theory) or the vascular endothelium (vascular hypothesis) two pathogenic mechanisms of radiation myelopathy were proposed (1, 11). In the vascular theory, circulation

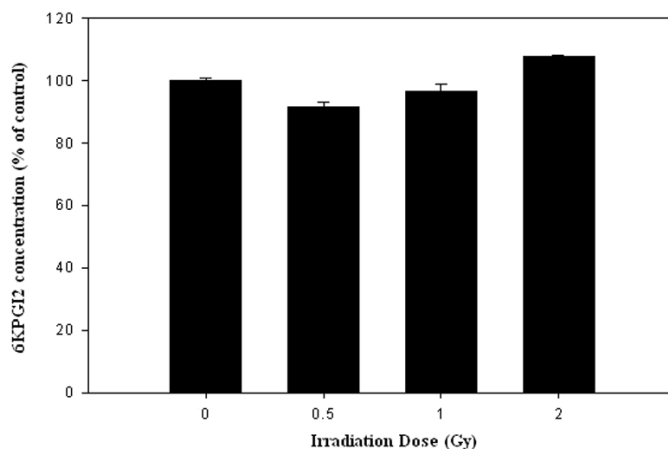


Figure 1. Prostacyclin changes are shown a) Percent of normalized value of 6kPgF1 α (prostacyclin) to age-matched control group 24 hours after low dose irradiation was shown. Concentration ratios were obtained as PGI2 (irradiated) / PGI2 (age matched control). The means \pm SEM were shown as percentage.

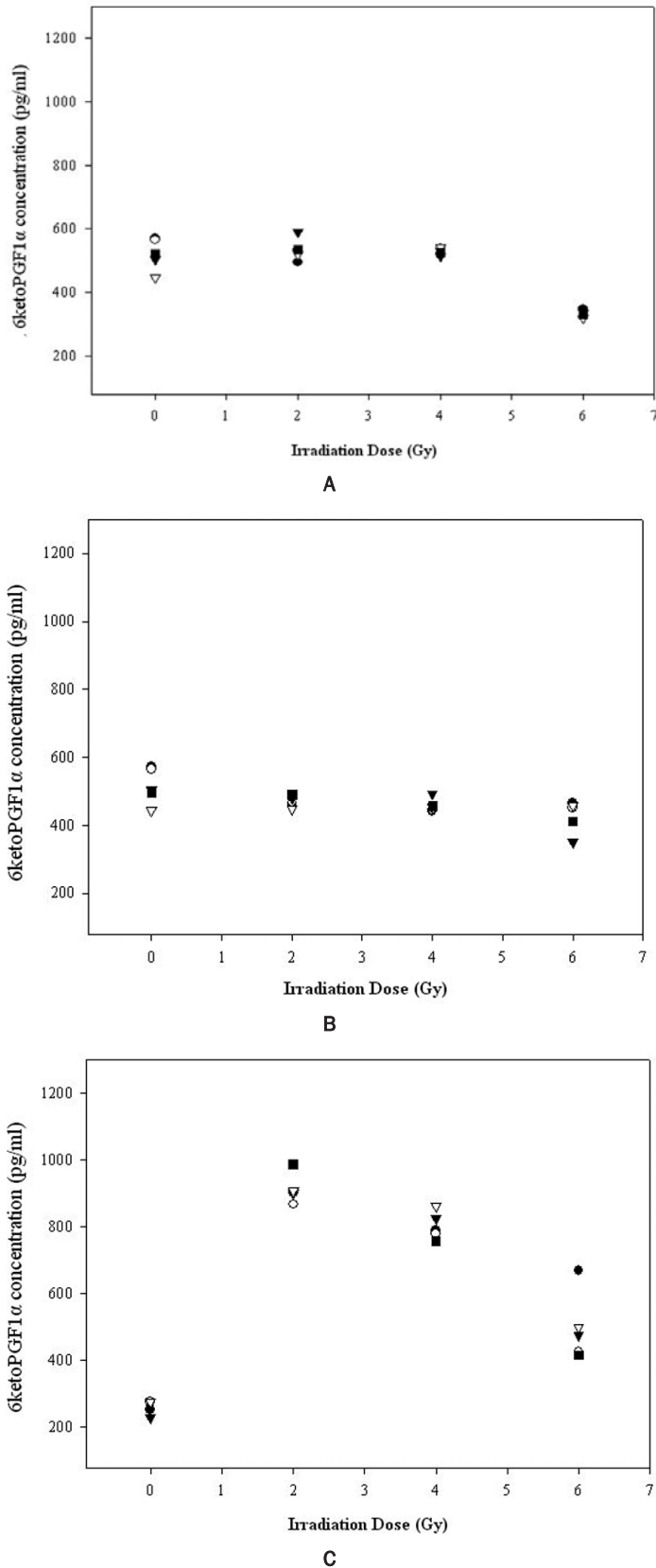
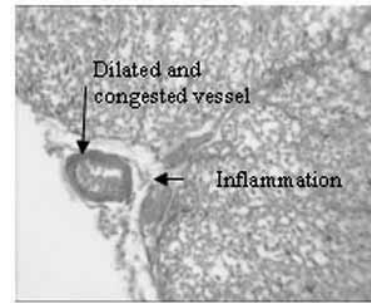
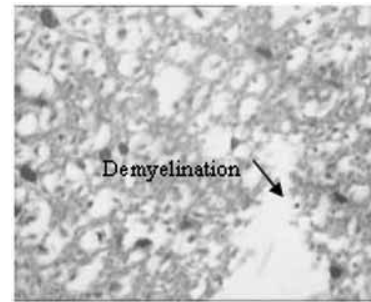


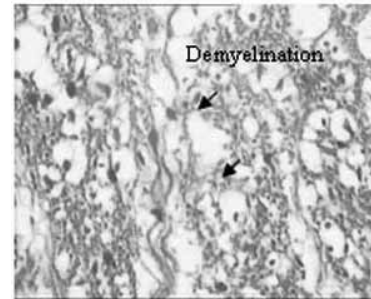
Figure 2. Changes of 6ketoPGF1α concentration vs. irradiation dose after; a) 24 hours, b) 2 weeks and c) 13 weeks post-irradiation were shown.



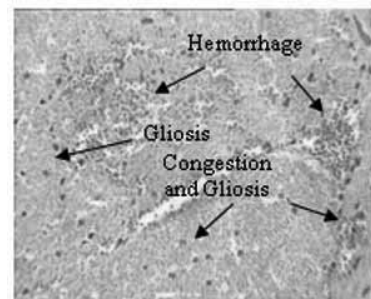
A



B



C



D

Figure 3. Cross sections (H&E staining) from histopathological changes of white matter are shown: a) Vascular dilatation and congestion along with edematous tissue in meninges ($\times 100$) with 4 Gy and (b) a large area of demyelination ($\times 400$) after 6 Gy after two weeks, c) nerve fibers and demyelination (arrows) ($\times 400$) with 2 Gy and d) congestion and gliosis ($\times 100$) with dose of 4Gy after 13 weeks post-irradiation.

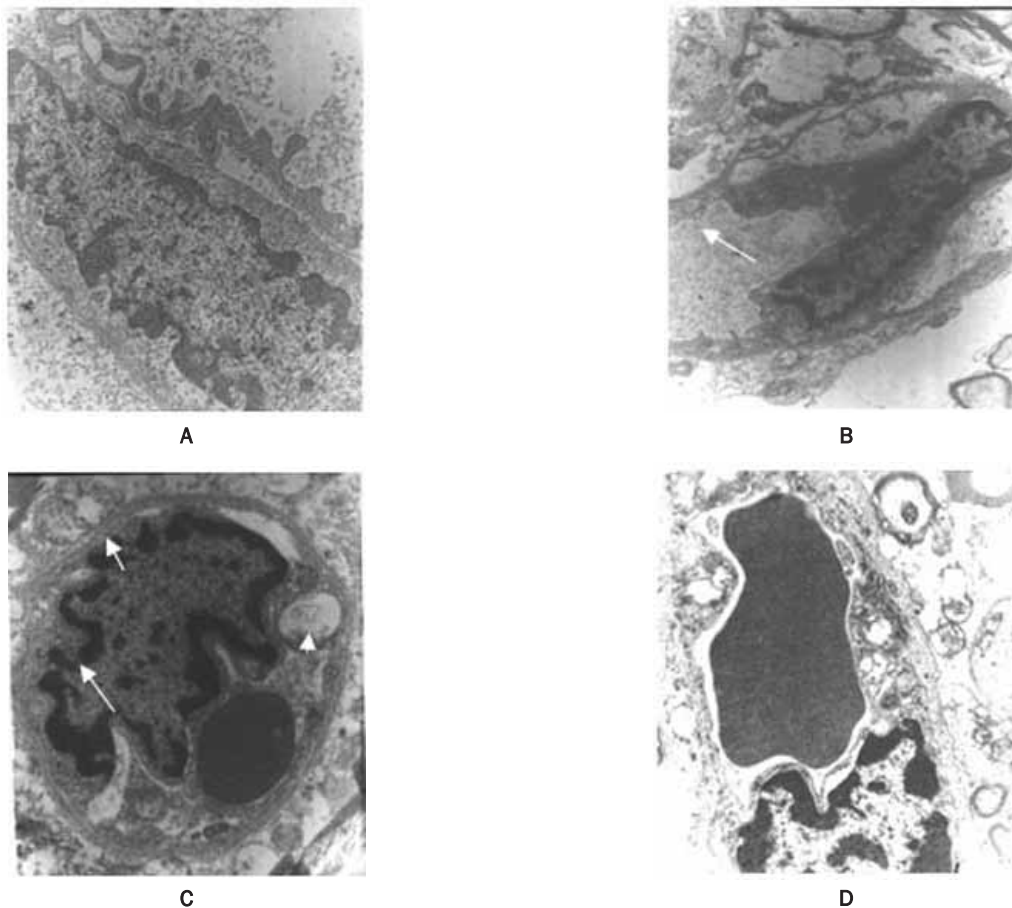


Figure 4. Photomicrographs of irradiated rat cervical spinal cord show: a) Vesicular formations at basal membrane releasing into the medium after 24 hours and dose of 6 Gy, b) basal cell membrane detachment from the vessel wall (arrow) after dose of 4 Gy, c) folding of cytoplasmic membrane (arrow), narrowing of cytoplasmic and basal cell membranes (short arrows), a secondary lysosome and ballooned mitochondria (arrow heads) close to nucleus with irradiation after dose of 2 Gy, and d) narrowing of basal membrane after 6Gy and 2 weeks post-irradiation.

disturbance following vascular injury induced white matter lesions. Different vascular mechanisms have been determined, but among them it is believed that alterations in vascular wall leading to hyperpermeability and change in their morphology play the essential role⁽⁴⁾. Experimental study of the effects of Boron Neutron Capture Therapy (BNCT) on the CNS shows the damage to CNS is caused primarily due to effects of high LET on the walls of blood vessels⁽¹²⁾.

There are similar reports that the earliest and most pronounced changes were seen in blood vessels, in close association with astrocyte enlargement. This led to the concept of a vascular-glia unit of tissue injury (TIU). The incidence and severity of

this TIU apparently increased with time after irradiation, until the development of necrosis⁽¹³⁾.

Our study showed ultrastructural and subcellular changes in endothelial cells from 24 hours after low dose irradiation. The capillary density decreased in this short term examination and similar pattern was also reported in other experiments⁽¹⁴⁾. We found that blood vessels, plugged with erythrocytes in and around the destructive vessels, can support the idea of changes in blood flow and endothelial surfaces^(15, 16). We also observed irregularities in the thickness of endothelial cell membrane (basement and cytoplasmic) with increased numbers of intracellular organelles, particularly vesicles in early time after irradiation, endoplasmic reticulum and

degeneration of mitochondria architecture; moreover, segmental endothelial cell loss, partial destruction and detachment of the basement membrane even at low doses, and early times after radiation were identified (figure 4).

Recently, it has been suggested that radiation may alter the secretory profile of mediators, such as prostaglandins, which can cause an inflammatory response, cellular proliferation, and cellular injury in the CNS (4, 9, 17). PGI₂ has a number of important physiological roles in vasoregulation, smooth muscle regulation, electrolyte balance, and neuroregulation, as well as pathological roles in inflammation and modification of platelet-vessel wall interactions (18-21).

Figures 1 and 2 shows an increase in prostacyclin concentration after low dose of 2 Gy 24 hours post-irradiation. This is an important dose point conventionally used in radiation therapy regimes. Very low doses of 0.5 and 1 Gy caused the decrease in the concentration of PGI₂ level in comparison with controls after 24 hours, when there is no histopathologic signs of radiation toxicities. The correlation between very low radiation dose and prostacyclin synthesis can also be interesting from the point of view of radiation protection where the low doses are prominent, or when the spinal cord is situated in the shielded area (9). This is in agreement with study of the low dose effect on cultured endothelial cell which showed an exponential decrease of 6-ketoPGF_{1α} in the region of 0.15-200 cGy irradiation dose (3, 21). The effects of oxidative stress on eicosanoid synthesis have also shown a similar pattern (6).

The correlation coefficient between prostacyclin and histopathological changes of white matter is negative for the dose region after 24 hours and 2 weeks, but it is positive after 13 weeks (figure 5). The possible explanation of this finding is that the radiation affects the synthesis of prostacyclin at both sources responsible to produce prostacyclin (22). Decrease in PGI₂ concentration early after irradiation can be due to severe acute inflammatory condition which was confirmed histopathologically at dose of 6 Gy. After 2

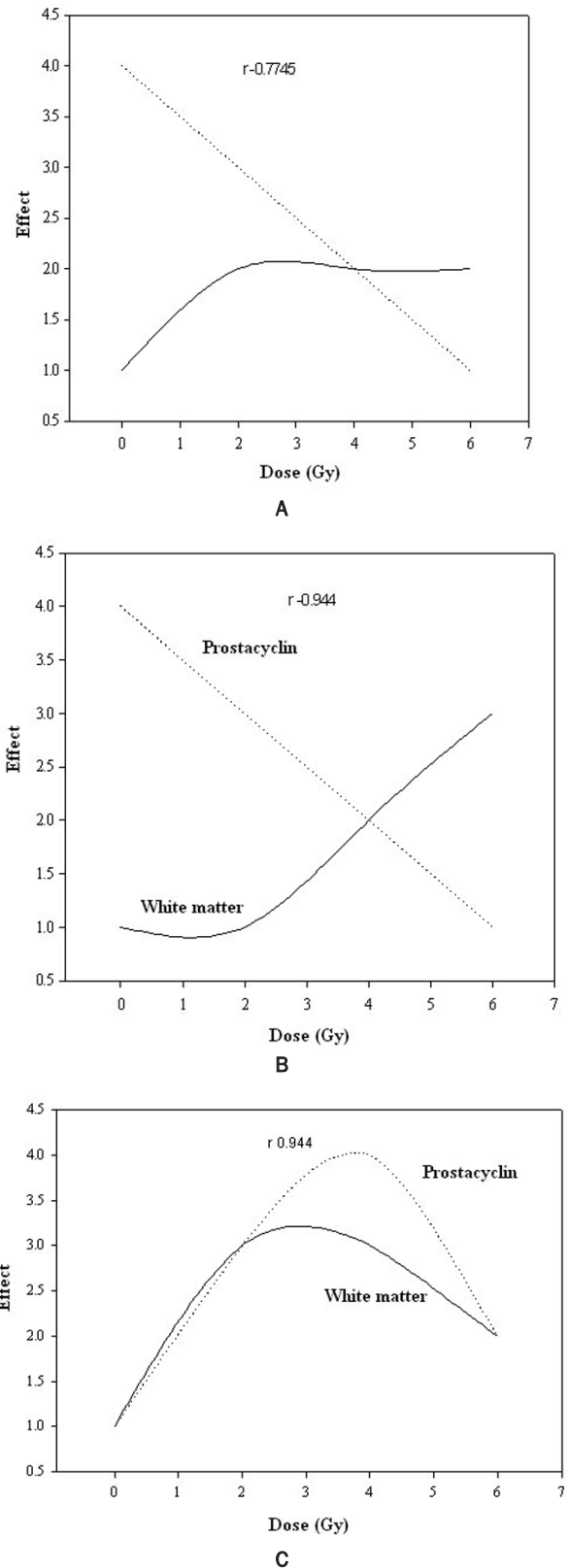


Figure 5. Correlation between prostacyclin and white matter changes with irradiation dose after: a) 24 hours, b) 2 weeks and c) 13 weeks irradiation ("r" is correlation coefficient).

weeks when the vascular density was decreased the prostacyclin concentration was also decreased, but after 13 weeks the histopathological findings showed severe increase in lower effects of radiation level of prostacyclin. After 13 weeks the radiation effects were marked at oligodendrocytes in the form of gliosis. Severe glial reactions may be a possible cause of prostacyclin hyper synthesis (3, 6).

CONCLUSION

Our results, further, suggest that the response of the vascular tissues to low and moderate doses of radiation occurs prior to that of the nervous tissue of the spinal cord. Our study also supports the hypothesis that the asymptomatic interval after irradiation is characterized by sequential physiological changes that may imperfectly reflected in routine histological study. Moreover, severe impairment in substructures and biochemistry of irradiated spinal cord may be present even in the histologically unaffected spinal cord. Induction of prostacyclin at certain times may assist body to overcome late effects of radiation; however, it needs more extensive investigations on prostacyclin receptor gene modulation, analogs and antagonists of prostacyclin and cytokines release from astrocyte and microglia, in addition to the substances which are able to modulate the tolerance of spinal cord such as platelet-derived growth factor and/or other prostaglandins.

REFERENCES

- Shinobu O and Okeda R (2001) Review article: Pathology of radiation myelopathy. *Neuropathology*, **21**: 247-265.
- Schultheiss TE and Stephens LC (1992) Invited review: Permanent radiation myelopathy. *The British Journal of Radiology*, **65**: 737-753.
- Vanegas H and Schaible HG (2001) Prostaglandins and cyclooxygenases in the spinal cord, *Progress in Neurobiology*, **64**: 327-363.
- Siegal T and Pfeffer MR (1995). Radiation-induced changes in the profile of spinal cord serotonin, prostaglandin synthesis, and vascular permeability. *Int J Radiat Oncol Biol Phys*, **31**: 57-64.
- Hosoi Y, Yamamoto M, Ono T, et al. (1993) Prostacyclin production in cultured endothelial cells is highly sensitive to low doses of ionizing radiation. *Int J Radiat Oncol Biol Phys*, **63**: 631-638.
- Estrada-Garcia L, Carrera-Rotllan J, Puig-parellada P (2002) Effects of oxidative stress and antioxidant treatments on eicosanoid synthesis and lipid peroxidation in long term human umbilical vein endothelial cells culture. *Prostaglandins & Other Lipid Mediators*, **67**: 13-25.
- Liang BC (1999) Radiation-associated neurotoxicity. *Hospital Physician*, April: 54-58.
- Shirazi A, Mahdavi SR, and Trott KR (2004) Radiation myelopathy: a radiobiological review. *Rep Pract Oncol Radiother*, **9**: 119-27.
- Allen JB, Sagerman RH and Stuart MJ (1981). Irradiation decreases vascular prostacyclin formation with no concomitant effect on platelet thromboxane production. *The Lancet*, **28**: 1193-1196.
- Mahdavi SR, Shirazi AR, Gharaati H, Zabihzadeh M (2005) Dosimetry, Control and Irradiation of rat cervical spinal cord". *Journal of Babol University of Medical Sciences*, **7**: 7-13.
- Schultheiss TE, Kun LE, Ang KK, et al. (1995) Radiation response of the central nervous system. *Int J Radiat Oncol Biol Phys*, **31**: 1093-1112.
- Morris GM, Coderre JA, Whitehouse EM, et al. (1994) Boron neutron capture therapy: a guide to the understanding of the pathogenesis of late radiation damage to the rat spinal cord. *Int J radiat Oncol Biol Phys*, **28**: 1107-1112.
- Cavanagh JB and Hopewell JW (1972) Mitotic activity in the subependymal plate of rats and the long-term consequence of X-irradiation. *J Neurol Sci*, **15**: 471-482.
- Reinhold HS, Calvo W, Hopewell JW and van den Berg AP (1990) Development of blood vessel-related radiation damage in the fimbria of the central nervous system. *Int J Radiat Oncol Biol Phys*, **18**: 37-42.
- Okada S, Okeda R, Matsushita S and Kawano A (1998) Histopathological and morphometric study of the late effects of heavy-ion irradiation on the spinal cord of the rat. *Radiat Res*, **150**: 299-304.
- Reinhold HS and Hopwell JW (1980) Late changes in the architecture of blood vessels of the rat brain after irradiation. *BJR*, **53**: 693- 696.
- Siegal T, Pfeffer MR, Meltzer A, Shezen E, Nimrod A, Ezov N, Ovadia H (1996) Cellular and secretory mechanisms related to delayed radiation-induced microvessel dysfunction in the spinal cord of rats. *Int J Radiat Oncol Biol Phys*, **36**: 649-659.
- Catella-lawson F, and Crofford LJ (2001) Cyclooxygenase inhibition and thrombogenicity. *Am J Med*, **110**: 28-32.
- Szekacs B, Nadasy GL, Vajo Z, Juhasz I, Feher J, Monos E (1996) Prostacyclin and thromboxane production of rat and cat arterial tissue is altered independently by several vasoactive substances. *Prostaglandins*, **52**: 221-235.
- Lindemann S, Gierer C and Darius H (2003) Prostacyclin

- inhibits adhesion of polymorphonuclear leukocytes to human vascular endothelial cells due to adhesion molecule independent regulatory mechanisms. *Basis Res Cardiol*, **98**: 8-15.
21. Hosoi Y, Yamamoto M, Ono T and Sakamoto K (1993) Prostacyclin production in cultured endothelial cells is highly sensitive low doses of ionizing radiation. *Int J Radiat Biol*, **63**: 631-638.
22. Menendez JC, Casanova D, Amado JA, Salas E, Garcia-Unzueta MT, Fernandez F, Perez De La Lastra L, Berrazueta JR (1998) Effects of radiation on endothelial function. *Int J Radiat Oncol Biol Phys*, **41**: 905-913.