

Classification, diagnosis, and approach to treatment for angioedema: consensus report from the Hereditary Angioedema International Working Group

M. Cicardi¹, W. Aberer², A. Banerji³, M. Bas⁴, J. A. Bernstein⁵, K. Bork⁶, T. Caballero⁷, H. Farkas⁸, A. Grumach⁹, A. P. Kaplan¹⁰, M. A. Riedl¹¹, M. Triggiani¹², A. Zanichelli¹ & B. Zuraw¹¹ on behalf of HAWK, under the patronage of EAACI (European Academy of Allergy and Clinical Immunology)*

¹Department of Biomedical and Clinical Sciences Luigi Sacco, University of Milan, Luigi Sacco Hospital Milan, Milan, Italy; ²Department of Dermatology, Medical University of Graz, Graz, Austria; ³Division of Rheumatology, Allergy and Immunology, Massachusetts General Hospital, Boston, MA, USA; ⁴Department of Otorhinolaryngology, Klinikum rechts der Isar, Technische Universität München, Munich, Germany; ⁵Division of Immunology/Allergy Section, Department of Internal Medicine, University of Cincinnati College of Medicine, Cincinnati, OH, USA; ⁶Department of Dermatology, Johannes Gutenberg University, Mainz, Germany; ⁷Department of Allergy, Hospital La Paz Institute for Health Research (IdiPaz), Biomedical Research Network on Rare Diseases–U754 (CIBERER), Madrid, Spain; ⁸3rd Department of Internal Medicine, National Angioedema Center, Semmelweis University, Budapest, Hungary; ⁹Department of Clinical Medicine, Faculty of Medicine ABC, Sao Paulo, Brazil; ¹⁰Medical University of South Carolina, Charleston, SC; ¹¹Division of Rheumatology, Allergy and Immunology, Department of Medicine, University of California – San Diego, La Jolla, CA, USA; ¹²Department of Medicine, University of Salerno, Salerno, Italy

To cite this article: Cicardi M, Aberer W, Banerji A, Bas M, Bernstein JA, Bork K, Caballero T, Farkas H, Grumach A, Kaplan AP, Riedl MA, Triggiani M, Zanichelli A, Zuraw B on behalf of HAWK, under the patronage of EAACI (European Academy of Allergy and Clinical Immunology). Classification, diagnosis, and approach to treatment for angioedema: consensus report from the Hereditary Angioedema International Working Group. *Allergy* 2014; **69**: 602–616.

Keywords

angioedema; clinical immunology; dermatology; education; urticaria.

Correspondence

Marco Cicardi, Department of Biomedical and Clinical Sciences Luigi Sacco, University of Milan, Luigi Sacco Hospital Milan, Italy.
Tel.: +390250319829
Fax: +390250319828
E-mail: marco.cicardi@unimi.it

*Hereditary Angioedema International Working Group members are given in Appendix.

Accepted for publication 21 January 2014

DOI:10.1111/all.12380

Edited by: Thomas Bieber

Angioedema is defined as localized and self-limiting edema of the subcutaneous and submucosal tissue, due to a temporary increase in vascular permeability caused by the release of vasoactive mediator(s). It frequently occurs as part of urticaria, which is characterized by two symptoms: wheals, edema of superficial skin layers, and angioedema, edema of deep skin layers (1). When angioedema recurs without significant wheals, the patient should be diagnosed to have angioedema as a distinct disease. Quincke, in his paper on

Abstract

Angioedema is defined as localized and self-limiting edema of the subcutaneous and submucosal tissue, due to a temporary increase in vascular permeability caused by the release of vasoactive mediator(s). When angioedema recurs without significant wheals, the patient should be diagnosed to have angioedema as a distinct disease. In the absence of accepted classification, different types of angioedema are not uniquely identified. For this reason, the European Academy of Allergy and Clinical Immunology gave its patronage to a consensus conference aimed at classifying angioedema. Four types of acquired and three types of hereditary angioedema were identified as separate forms from the analysis of the literature and were presented in detail at the meeting. Here, we summarize the analysis of the data and the resulting classification of angioedema.

‘circumscribed edema’ that he called ‘angioneurotic edema’ (2), was the first author who considered angioedema to be a separate entity. Because of that, angioedema is still frequently referred to as Quincke edema. Shortly thereafter, Osler (3), in his seminal paper ‘Hereditary angioneurotic edema’, gave the first exhaustive description of an angioedema standing as a specific nosology entity, which was later renamed hereditary angioedema (HAE). In 1963, Donaldson and Evans identified C1 inhibitor (C1-INH) deficiency as the

genetic defect underlying the disease described by Osler (4). Nine years later, Caldwell et al. (5) identified an angioedema patient in whom the deficiency of C1-INH was not hereditary, but acquired, related to a concomitant lymphosarcoma. In subsequent years, angioedema research has been focused at unraveling the pathophysiology of angioedema related to C1-INH deficiency, eventually shown to be bradykinin-mediated, a conclusion proven correct by the clinical response to a specific antagonist (6). The advent in 1980 of angiotensin-converting enzyme inhibitors (ACEI), which encompass angioedema as a side-effect, changed the fate of this disease. Even if this side-effect occurs in <1% of treated subjects, the millions of people receiving an ACEI worldwide increased the incidence of angioedema (7) and angioedema became the second most common cause of hospitalization for allergic diseases after asthma (8). In 2000, Bork et al. (9) described a form of HAE without C1-INH deficiency further widening the spectrum of angioedema types.

Thus, diagnosis of angioedema needs to be refined by the specification of the type. In the absence of an accepted classification, different types of angioedema are not uniquely identified. For this reason, the European Academy of Allergy and Clinical Immunology (EAACI) gave its patronage to a consensus conference aimed at classifying angioedema. This

conference was held from September 30, 2012 to October 2, 2012 in Gargnano del Garda, Italy. Attendance was based on the HAWK group of angioedema experts, established in 2010 to provide evidence-based recommendations for the treatment for HAE (10). Four types of acquired and three types of HAE were identified as separate forms from the analysis of the literature and were presented in detail at the meeting. Here, we summarize the analysis of the data and the resulting classification of angioedema (Fig. 1).

Idiopathic histaminergic acquired angioedema (IH-AAE)

Continuous administration of an antihistamine stops disease recurrences in a significant proportion of non-HAE patients, and this angioedema can be defined as ‘histaminergic’. The term implies a role for the cutaneous mast cell and/or the blood basophil and suggests that bradykinin or other vasoactive substances will not be predominantly released. Histamine release suggests the possibility of an allergic cause and identifying such causes is the starting point in the evaluation of patients with angioedema. Allergy is suspected if the recurrence of symptoms is sequential related to an exogenous stimulus and confirmed by a positive skin prick test and/or detection of clinical significant specific IgE. Stimuli such as

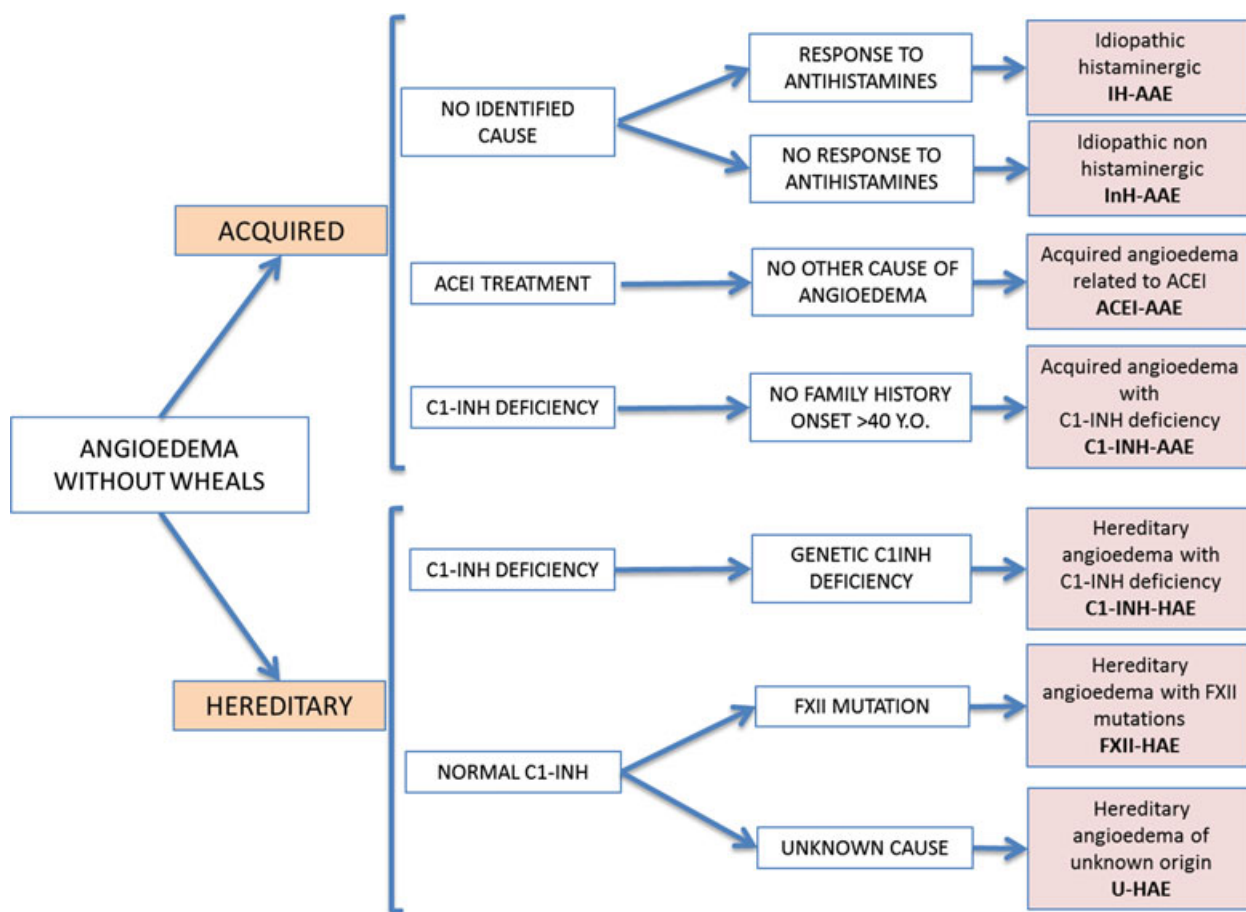


Figure 1 Classification of angioedema without wheals.

medication and/or foods, insect bites/stings or other environmental allergens, or physical stimuli may be detected by an experienced allergist: they are frequently involved in patients with acute angioedema, but only in a minority with recurrent attacks. Furthermore, an unequivocal causal relationship between infection or autoimmune disease and angioedema is frequently difficult to confirm. When allergy and other causes have been ruled out and an etiology cannot be identified, the histaminergic angioedema is defined to be idiopathic or spontaneous. A series of 929 consecutive patients with angioedema without urticaria presenting over a 10-year period at a large angioedema specialty center (11) identified 124 patients (16%) where a specific factor could be identified (a food, drug, insect bite, environmental allergen, or other physical stimulus), 55 (7%) with autoimmune disease or infection, 85 (11%) being ACE inhibitor related, 197 (25%) suffering from HAE, and 294 cases of idiopathic angioedema. Among the latter 294 patients with unknown etiology, the vast majority (254 or 87%) responded well to long-term antihistamines and were thus classified as being idiopathic histaminergic.

In idiopathic angioedema that is histaminergic, patients by definition respond to high-dose antihistamines used prophylactically on a daily basis (12). However, the mechanism by which histamine release is initiated in this disorder is unknown.

Clinical presentation

Due to the lack of publications addressing the problem of clinical presentation of this form of angioedema, the following data have been derived by the discussion among experts. IH-AAE develops rapidly reaching a maximum within 6 h; precipitating factors are not identified; drug history is irrelevant to the angioedema; the face is mostly affected; gastrointestinal and laryngeal mucosa are spared and death due to the angioedema has not been reported; there is no preferred age for onset; attacks are prevented by antihistamine and respond to corticosteroids and epinephrine as acute treatment; family history for angioedema is negative; there are no associated diseases.

Diagnosis

Major diagnostic tools include exclusion of causes of angioedema when potentially present based on the clinical features: causative agents associated autoimmune/infectious disease, C1-INH deficiency, and mutation in factor XII. In the absence of an algorithm specific for angioedema, we suggest employing the guidelines for diagnosis of urticaria (1). If anaphylaxis is suspected, measurement of serum mast cell tryptase; skin prick testing or specific IgE antibodies, can be indicated; rheumatoid factor, antinuclear antibodies, C3/C4 complement levels, and C1q antibodies if connective tissue disease or urticarial vasculitis is suspected. Screening for infectious foci when no obvious cause of angioedema is detectable is rarely helpful. In the only published study of angioedema without urticaria (11), appropriate treatment for a concomitant infection markedly improved the angioedema

in all patients with dental granuloma: three of five patients with sinusitis and five of seven patients with urinary tract infection. In two patients infected with *Helicobacter pylori* who experienced gastroesophageal reflux, angioedema improved after proper eradication therapy in one case only.

In conclusion, IH-AAE seems to be the most common form of angioedema. Some of its clinical and pathogenetic features are similar to idiopathic recurrent urticaria. It is diagnosed on clinical features, exclusion findings, and therapeutic response. Antihistamine and corticosteroids represent the basic treatment.

Idiopathic nonhistaminergic acquired angioedema

This type of angioedema identifies nonfamilial, nonhereditary forms in which known causes of angioedema have been excluded as for IH-AAE, but recurrences persist upon antihistamine treatment. Search of the medical literature matching the terms idiopathic, nonhistaminergic, and angioedema provides just a few papers (11, 13–16). Nevertheless, experts placed an effort in providing a definition of this angioedema for the strong belief that it could encompass a distinct, homogeneous group of patients. Cicardi et al. (12) first used this term for describing a group of patients with angioedema: these patients presented with remarkable response to tranexamic acid given for prophylaxis. A similar favorable effect of tranexamic acid was reported in another series of angioedema patients with analogous characteristics, but defined as 'sporadic idiopathic bradykinin angioedema' (17). The term 'bradykinin-mediated' is sometimes substituted for 'nonhistaminergic' assuming that bradykinin mediates this angioedema. Even if experts agree that bradykinin is involved in InH-AAE, experimental evidence confirming this hypothesis is still limited. Cugno et al. (18) showed that one patient with InH-AAE had high levels of bradykinin in the venous blood effluent from the swollen arm, while in a similar situation, but with IH-AAE, bradykinin levels were normal. Additional evidence supportive of bradykinin as the mediator in this situation comes from scattered case reports showing efficacy of the bradykinin receptor antagonist icatibant in reverting angioedema that is not responsive to antihistamine (19–21). Until such findings are confirmed in a significant series of patients, we prefer to maintain the term nonhistaminergic for patients with angioedema not prevented by antihistamine. Furthermore, at least in some patients with angioedema not responsive to antihistamines, a role for vasoactive mediators other than bradykinin, for example cysteinyl leukotrienes, prostaglandins, or platelet-activating factor, should be considered.

Clinical presentation

Only two series of patients, 40 Italian and 35 French, can be found in the literature to be considered representative of InH-AAE (11, 17). Analysis of the Italian and French case lists shows a slightly higher frequency of male gender (1.35 and 1.5, respectively) and age of onset at 36 and 42 year old. Nearly all patients reported a facial location; abdominal

symptoms were present in <30% and upper airways' involvement in 35% and 26%. Invasive management (endotracheal intubation) for upper airway edema was reported for a single patient in the Italian group. The mean duration of symptoms was below 48 h and the frequency of recurrences high, with more than half of the patients needing continuous prophylaxis with tranexamic acid.

Diagnosis

The clinical history is the first step to diagnosis. In the absence of laboratory testing or biomarkers, the evidence supporting that histamine is not the putative mediator is based on the patient's negative response to continuous treatment with antihistamines. Based on recent recommendations for urticaria and angioedema (22), we can agree on the fact that second-generation antihistamines (azelastine, bilastine, cetirizine, desloratadine, ebastine, fexofenadine, levocetirizine, loratadine, mizolastine, and rupatadine) at licensed doses represent the first approach for these patients. Up to four times increase in doses can be employed prophylactically before concluding that InH-AAE is the diagnosis.

Treatment

There is no conclusive evidence for an effective treatment for attacks of idiopathic nonhistaminergic angioedema. Efficacy of tranexamic acid has been reported in two case series, but no detailed data are available (11, 17). Case reports indicate that icatibant can relieve symptoms of angioedema in these patients, whereas no data specifically report on the efficacy of corticosteroids (19–21).

Most data on the prevention of idiopathic nonhistaminergic angioedema refer to the use of tranexamic acid. Cicardi et al. (12) showed that up to 3 g/day of tranexamic acid induced complete (11/15) or partial (4/15) prevention of idiopathic nonhistaminergic angioedema. These data were further extended by Du-Thanh et al. (17) who showed that up to 90% of patients had complete or partial remission of angioedema attacks while on tranexamic acid. For patients with thrombophilia, in whom tranexamic acid is contraindicated, alternative agents adapted from treatment for chronic urticaria such as cyclosporine and anti-IgE antibody (omalizumab) can be considered, but experience is still limited (23).

The different responses of patients with InH-AAE to either tranexamic acid or immunosuppressive, for example corticosteroids or cyclosporine, and biological agents such as omalizumab clearly indicate the heterogeneity of this form of angioedema with regard to mediators involved in its pathogenesis. Further studies are needed to identify subgroups of patients with InH-AAE to better define prevention and treatment strategies.

Acquired angioedema related to angiotensin-converting enzyme inhibitors (ACEI-AAE)

The inhibition of ACE, which is involved in the breakdown of bradykinin to inactive peptides, results in elevated plasma

levels of bradykinin that further increase during ACEI-AAE (24, 25). The suggestion that ACEI-AAE is bradykinin-mediated is reinforced by evidence that genomic and plasma variability of proteins interfering with bradykinin catabolism is associated with risk of ACEI-AAE (26–31).

Incidence

Analysis of large cohorts of hypertensive patients suggests angioedema to occur in <0.5% of patients taking ACEI, but 3–4.5-fold more often in black than in Caucasian subjects (32–36). A meta-analysis of clinical trials evaluating angioedema as a side-effect, reported an incidence of angioedema of 0.30% (95% CI 0.28–0.32) with ACEI, 0.11% (95% CI 0.09–0.13) with ARB, 0.13% (95% CI 0.08–0.19) with direct renin inhibitors, and 0.07% (95% CI 0.05–0.09) with placebo (37). Based on these data, there was an agreement among experts that an ARB-related angioedema should not be included as a specific form of angioedema.

Clinical symptoms

Acquired angioedema related to angiotensin-converting enzyme inhibitors is more frequent in female than male patients and in individuals over 65 years of age (32, 38). The latency between the initiation of ACEI therapy and the onset of symptoms can vary greatly from a few hours to several years, but it is more likely to occur early after initiation of ACEI therapy (34, 39–42).

Acquired angioedema related to angiotensin-converting enzyme inhibitors usually localizes to the face, followed by lips, eyelids, tongue, neck, and upper airways (43). ACEI-induced gastrointestinal angioedema has rarely been reported although underdiagnoses of this complication cannot be excluded (44, 45). Deaths from laryngeal edema due to ACEI-AAE have been reported (43, 46, 47).

Diagnosis

There is no test specifically modified during ACEI-AAE, and therefore, it is diagnosed upon onset of not otherwise explained angioedema in patients taking ACEI.

Therapy of ACEI-AAE

To prevent ACEI-AAE recurrences, the drug should be immediately discontinued. Surprisingly, ACEI withdrawal is not 100% effective. Long-term follow-up of 111 patients with ACEI-AAE demonstrated that after discontinuation from ACEI, 51 patients (46%) had further recurrences of angioedema with a frequency that was milder in 32 and remained unchanged in 18 (48). The switch to a different antihypertensive therapy, including an ARB, did not seem to influence the relapse. On the other hand, continued use of ACEI in spite of angioedema results in a marked increase in the incidence of recurrent angioedema with serious morbidity (39, 40). The reason for persistence of angioedema after ACEI withdrawal is not clear. It is possible to speculate that such

patients are slow bradykinin 'catabolizers' and have 'hidden' InH-AAE disclosed by ACEI.

Pathophysiology suggests that bradykinin-targeted drugs, licensed to treat HAE due to C1 inhibitor deficiency, could be effective to reverse symptoms in ACEI-AAE (8, 49–52). Due to the lack of efficacy of corticosteroids and epinephrine, some of them have been used off label in ACEI-AAE. In an uncontrolled study, in 20 patients with ACEI-AAE, icatibant led to a rapid and complete disappearance of symptoms (mean 4.5 h) (53). A multicenter, double-blind study with icatibant in 30 patients with ACEI-AAE (Clin Trial Gov. No: NCT01154361) was completed, and the first data are expected in 2014. Potential effect of C1-INH is supported by published case reports (54–56). To verify these initial positive observations and the efficacy of kallikrein antagonist ecallantide, randomized studies are planned (ClinicalTrials.gov Identifier: NCT01843530 and NCT01036659).

When the course is fulminant despite drug therapy, or airway obstruction remains impending, securing of airways is indicated. Depending on the location of angioedema, different forms of airway securement may be selected (57).

Acquired angioedema with C1 inhibitor deficiency

The nongenetic nature of acquired angioedema with C1 inhibitor deficiency (C1-INH-AAE) implies that no mutations in C1-INH gene (SERPING1) and no family history of angioedema can be associated with this disease. In the absence of epidemiological studies, prevalence of C1-INH-AAE in the general population is estimated to be 1 : 10 that of the hereditary form, that is, around 1 : 500 000 (58).

Pathophysiology and associated diseases

Studies on plasma from patients with C1-INH-AAE indicate consumption of C1-INH and classical pathway complement components and, during attacks, activation of contact system with release of bradykinin, which causes angioedema (59–63). The lymphoproliferative disease, frequently found in these patients, could directly contribute to the consumption of C1 and C1-INH (5, 64–66). Evidence that curing the associated lymphoma could cure biochemical and clinical signs of angioedema confirms that lymphoma can be responsible for C1-INH-AAE (49, 67, 68).

Acquired angioedema with C1 inhibitor deficiency can be caused by autoantibodies neutralizing C1-INH function (50)-binding epitopes mapped around its reactive center (51, 52, 69–73). Although initially identified as an independent form of acquired C1-INH deficiency, large case series demonstrated that C1-INH-AAE with autoantibodies and with lymphoproliferative diseases largely overlaps and should be considered the same disease (49, 74, 75). Other conditions, mainly SLE, are reported in C1-INH-AAE, which appears as a syndrome with different possible associations (76). However, 20 of the 180 cases reported in the literature had no underlying disease associated with their C1-INH-AAE.

Clinical presentation and diagnosis

Acquired angioedema with C1 inhibitor deficiency starts after the age of 40 years in 94% of patients. Family history of angioedema is never present. Angioedema predominantly involves the face, tongue, uvula, and upper airways although any place in the body can swell (77, 78). Gastrointestinal swelling attacks are less common in C1-INH-AAE patients compared to C1-INH-HAE patients (77, 78).

Plasma levels of C1-INH function below 50% of normal are the confirmatory test when diagnosis of C1-INH-AAE is suspected. Antigen levels of C1-INH are similarly reduced. However, the presence of cleaved C1-INH may give apparently normal C1-INH antigen in about 20% of patients (76, 79). Significant reduction in C4 plasma levels is almost invariably present. In some patient, at disease onset, C1-INH deficiency and consumption of complement components can only be evident during angioedema attacks (80). The majority (70% or more) of C1-INH-AAE patients have a low C1q levels and anti-C1-INH antibodies (76). When clinical and biochemical data are not clear-cut to exclude hereditary C1-INH deficiency, genetic analysis to exclude SERPING1 mutations may be necessary to confirm C1-INH-AAE.

C1-INH-AAE patients should have routine clinical testing to rule out underlying lymphoproliferative and autoimmune diseases and MGUS. Testing should include a CBC with differential, sedimentation rate, C-reactive protein, serum protein electrophoresis, urine analysis for light chain proteins, and if there are peripheral blood abnormalities suggestive of a concomitant disease, then bone marrow biopsy should be performed to rule out malignancies (81).

Treatment

Treatment of C1-INH-AAE should consider the underlying disease as well as the frequency and severity of angioedema. Curing the underlying disease, when present, can cure angioedema, and this option should be considered. However, when the underlying disease does not per se require treatment (as for slow-growing lymphoproliferative diseases), taking into consideration the burden derived from angioedema symptoms versus the toxicity of treatment should always be considered in the decision-making process. Symptomatic treatment for angioedema recurrences can in fact be provided using bradykinin-targeted drugs. In the absence of controlled trials, these treatments are used off label in C1-INH-AAE.

Some case reports suggest the possibility to treat C1-INH-AAE with rituximab, a recombinant monoclonal antibody that targets CD20 surface antigens on B cells (49, 67, 82–85). Most of these cases had fewer and less severe attacks after treatment, and some actually went into remission and experienced no further attacks.

Treatment for angioedema symptoms in patients with C1-INH-AAE has been performed with C1-INH replacement therapy (86). The majority of patients respond positively, but some may be resistant to this treatment due to an extremely rapid catabolism of C1-INH (70). There are a few case

reports on the use of C1-INH as prophylactic therapy: as for on demand, there are patients who do not respond to this treatment (67, 87). Efficacy of on demand subcutaneous icatibant, the antagonist of bradykinin receptor, has been reported in a small series of patients, including some resistant to plasma-derived C1-INH (88–91). Similar efficacy, but in a very limited number of patients, is reported with the subcutaneous plasma kallikrein inhibitor ecallantide (92). Attenuated androgens, effective in prophylaxis of hereditary C1-INH deficiency, are less effective in C1-INH-AAE (77, 93). However, antifibrinolytic agents (i.e., tranexamic acid) tend to be more effective in C1-INH-AAE than in the hereditary form and experts recommend this as the drug of choice for attack prophylaxis in C1-INH-AAE (76, 86).

Hereditary angioedema with C1 inhibitor deficiency (C1-INH-HAE)

Hereditary angioedema with C1-INH deficiency (C1-INH-HAE) is a rare disease with minimal prevalence varying from 1.09/100 000 to 1.51/100 000 inhabitants (94–96) and an estimated prevalence of 1/10 000–1/100 000 inhabitants (97, 98).

Genetic defect and pathophysiology

C1-INH-HAE is due to mutations in one of the two alleles of C1-INH gene, SERPING1. A few homozygous mutations were described, mostly in patients with consanguineous parents (99–101). Structural abnormalities of the SERPING1 in patients with C1-INH-HAE are very heterogeneous (102–105), with prevalence of de novo mutations around 25% of cases (106, 107). The mutations described in C1-INH-HAE are collected in large universal genetic databases (OMIM ID 106100, Human Gene Mutation Database 119041) and in a database specific to this disease (<http://hae.enzim.hu>) (108).

Mutations in SERPING1 result in reduced plasma levels of C1-INH and instability of the contact system with facilitated release of bradykinin, identified as the key mediator of angioedema. Two phenotypic variants have been described (109). Type I is characterized by a quantitative decrease in C1-INH, which results in diminished functional activity (C1-INH-HAE type I), and type II is characterized by normal or high levels of C1-INH, which is dysfunctional.

Clinical presentation

C1-INH-HAE is clinically manifested by recurrent, localized subcutaneous or submucosal edema lasting for 2–5 days. The most commonly involved organs include the skin, upper respiratory airways, and gastrointestinal tract. The clinical expression is highly variable among the patients, from asymptomatic cases to patients suffering from disabling and life-threatening attacks with a demonstrated humanistic and economic burden (110, 111). Almost all patients with C1-INH-HAE present recurrences of abdominal pain caused by temporary bowel obstruction because of mucosal edema (98, 112). It is common that patients with C1-INH-HAE undergo

unnecessary surgery misdiagnosing for surgical emergency a gastrointestinal angioedema.

Diagnosis

Suspected with above-mentioned symptoms, diagnosis of C1-INH-HAE needs laboratory confirmation (98). Patients with C1-INH-HAE present with low C4, and to a lesser extent low C2, because of consumption due to the activation of the classical complement pathway lacking its physiological inhibitor C1-INH. Measurement of C4 levels is used for screening of C1-INH-HAE because it is decreased even in between attacks and only exceptionally can be normal (113). Diagnosis is confirmed by the evidence of plasma C1-INH levels below 50% of the normal values (93). Based on the relative frequency of the two phenotypic variants of C1-INH-HAE, 15% of patients will have normal quantitative plasma levels of C1-INH. For this portion of patients, diagnosis requires measurement of C1-INH activity in plasma. Two methods (chromogenic or immunoenzymatic), based on measurement of the capacity of plasma to inhibit the esterase activity of a fix amount of C1s, are currently available to measure C1-INH activity. Neither is routinely performed in diagnostic laboratories (114). The chromogenic assay is usually preferred due to higher positive predictive value close to 100%. Blood samples for functional assay should be cautiously taken and handled to avoid *in vitro* loss of activity. Recently, an international collaborative study established the WHO 1st international standards for C1-inhibitor, plasma, and concentrate (115). It is suggested by experts that diagnosis of C1-INH-HAE should be based on two reduced readings of C4 and quantitative and/or functional C1-INH, separated by 1–3 months (116). Use of low C4 levels plus low C1-INH functional activity for the diagnosis of C1-INH deficiency has a specificity of 98–100% and a negative predictive value of 96% (117, 118). Patients with C1-INH-HAE usually do not consume C1 complex, and reduction in plasma levels of C1q is rare in nonhomozygous forms (99–101, 119, 120).

Genetic testing is needed during the first year of age, when C1-INH plasma levels may be falsely low and to distinguish C1-INH-AAE when diagnosis is not clear-cut (116). Heterogeneity of mutations responsible for C1-INH-HAE makes genetic diagnosis relatively complicated.

Treatment

Treatment of patients with C1-INH-HAE is aimed at avoiding mortality and reducing morbidity. As morbidity is function of frequency and severity of attacks and mortality of progression of laryngeal edema, effective treatments should prevent and/or revert angioedema symptoms. Several drugs, tested in double-blind placebo-controlled studies, detain such an efficacy and are available, with differences from country to country (Table 1) (6, 121–128). Several international consensus papers, released since 2004, guide the treatment of C1-INH-HAE, and here, we will provide just the general principles derived from these guidelines (10, 116, 129–132). After

Table 1 Drugs for treatment of C1-INH-HAE

Drug	Trade name	Company	Drug description	Mechanism of action	Admin route	Indications and doses			Regulatory status	
						Acute	LTP*	STP†	USA approvals	EU approvals
C1-INH	Bernert®	CSL Behring	Human plasma-derived C1-INH	Replacement of deficient protein	I.V.	20 IU/kg	No	Adults: 1000 IU 1–6 h before procedure Children: 15–30 IU/kg 1–6 h preprocedure	Acute treatment‡ Self-administration	EMA approved Acute treatment, STP Self-admin
C1-INH	Cebitor® Cimzye®	Sanquin, Viropharma	Human plasma-derived C1-INH	Replacement of deficient protein	I.V.	1000 IU + 1000 IU if no response in 1 h	1000 IU every 3–4 days	1000 IU preprocedure	LTP Self-admin	Acute treatment, LTP STP Self-admin
C1-INH	Rhucin® /Ruconest®	Pharming NV/Sobi/ Sanitarus	Recombinant human C1-INH (produced in transgenic rabbits)	C1-INH replacement	I.V.	50 U/kg	No	No	NA	Acute treatment Self-admin Acute treatment
Icatibant acetate	Firazyr®	Shire	Synthetic peptide (10 aa)	Blockage of B2R	Subcutaneous	30 mg	No	No	Acute treatment§ Self-administration	Acute treatment Self-admin
Ecallantide	Kalbitor®	Dyax Corp	Recombinant human protein (60 aa)	Selective inhibitor of plasma kallikrein	Subcutaneous	30 mg	No	No	FDA approved for acute treatment	Not approved
Human plasma		Several	Solvent Detergent Treated/Fresh Frozen Human plasma	Replacement of deficient protein	I.V.	Adults: 2 U	No	Adults: 2–4 U Children: 10 mL/kg 1–6 h preprocedure†	Available‡	Available
Epsilon amino caproic acid (EACA)	Amicar® Ipsilon®	Rottapharm, Xanodyne Pharmaceuticals	Cyclic derivative of epsilon amino caproic acid	Antiplasmin-plasminogen activity	Oral, I.V.	No	Adults: 1–3 g/6–8 h		Available**	Available
Tranexamic acid	Amcharibrin® Cyklokapron® Transamin®	Pfizer, New York, NY	Attenuated androgen	Anabolic action on C1-INH	Oral, I.V.	No	500–3000 mg/day	No	Available††	Available
Stanozolol	Winstrol®	Winthrop, Barcelona, Spain	(17-alpha-alkylated androgens)	Anabolic action on C1-INH	Oral	No	2 mg/day or less	4–6 mg/day (divided into 2–3 doses) 5 days pre and 3 postprocedure	FDA approved for LTP	Available
Danazol	Danazol® Danocrine® Danol® Ladogal®	Sanofi-Aventis, Paris, France	Attenuated androgen (17-alpha-alkylated androgen)	Anabolic action on C1-INH	Oral	No	200 mg/day or less	Adults: 400–600 mg/ day 5 days preprocedure and 3 postprocedure	Available‡‡	Available Approved in some countries for LTP

Table 1 (Continued)

Drug	Trade name	Company	Drug description	Mechanism of action	Admin route	Indications and doses			Regulatory status	
						Acute	LTP*	STP†	USA approvals	EU approvals
Oxandrolon	Oxandrin®	Savient Pharmaceuticals, East Brunswick, NJ	Attenuated androgen (17- α -alkylated androgen)	Anabolic action on C1-INH	Oral	No	10 mg/day or less	STP†	Available§§	Not available

*Long-term prophylaxis.

†Short-term prophylaxis.

‡Approved/Availability Latin American countries.

§Approved Argentina, Brazil, Mexico; available Argentina.

||Approved Argentina, Colombia, Mexico, Brazil; available Brazil, Mexico.

¶Available.

**Available in all.

††Available.

‡‡Available.

§§Available under specific prescription in Brazil.

being diagnosed as C1-INH-HAE, all patients should have readily available, a drug of proved efficacy in reverting attacks. Control of the disease should first be attempted administering this drug as soon as the patient realizes that angioedema symptoms start to develop. To have timely intervention, it is highly recommended that patients are trained to home treatment for either subcutaneous or intravenous administration (132). If this approach does not reduce the burden of the disease with significant improvement of the quality of life, continuous prevention treatment should be considered. Antifibrinolytic agents, attenuated androgens, and plasma-derived C1-INH are available for this approach. Although their efficacy had been proved in controlled studies, antifibrinolytics are now rarely used for prophylaxis due a reduced efficacy compared to the other two products (133). Risk/benefit balance of starting long-term prophylaxis and the product to use for this purpose should always be carefully evaluated and individualized to each single patient (10, 116).

A final approach to treat patients with C1-INH-HAE is to prevent attacks on a short term. This approach is mainly addressed to avoid angioedema complications of medical maneuvers, namely oral procedures that may trigger upper airways edema. Specific indications present in therapeutic consensus documents are derived from expert opinion and uncontrolled series of patients (134–136). Plasma-derived C1-INH, given at doses effective for on demand and as close as possible to the procedure, appears as the most rational approach because it is promptly effective and has a sufficient half-life (116, 137, 138).

Hereditary angioedema with normal C1 inhibitor and factor XII mutation (FXII-HAE) and of unknown origin (U-HAE)

In 1985, a large family in which five women suffered from recurrent angioedema of the skin associated with relapsing episodes of abdominal pain attacks and episodes of upper airway obstruction was observed (9). Surprisingly, all of the women had normal C1-INH function. In 2000, this family and nine additional families with similar symptoms and a normal C1-INH function were identified (9). Interestingly, in these 10 families, a total of 36 women, but not a single man, were affected. In this initial description, the terms 'hereditary angioedema with normal C1-INH' or 'hereditary angioedema type III' were proposed. Through 2003, all the patients described in the literature were women, and therefore, it was assumed that the clinical phenotype might be limited to the female sex (139–141). However, in 2006, a family with dominantly inherited angioedema and normal C1-INH was described in which not only five female but also three male family members were clinically affected (142).

Factor XII genetic defect

In May 2006, genetic mutations in six index patients of 20 families and in 22 patients of the corresponding six families were identified: two different missense mutations have been

verified which were assumed to be the cause of the disease according to the co-segregation pattern of mutations and the clinical symptoms in women (143). The location of these mutations was the same locus, 5q33-qter as the Hageman factor, or coagulation F12 gene (Online Mendelian Inheritance in Man # 610619). One mutation leads to a threonine-to-lysine substitution (Thr328Lys) and the other to a threonine-to-arginine substitution (Thr328Arg). Both of these mutations were located on the exon 9. It was also found that the index patients of 14 further families with HAE and normal C1-INH did not show these mutations (143). More recently, a large deletion of 72 base pairs (c.971_1018 + 24del72) and a duplication of 18 base pairs (c.892_909dup) both located in the same region of F12 have been described (144, 145). At present, we have patients with HAE with normal C1-INH and mutation in the F12 gene and patients with normal C1-INH and unknown genetic defect (146–150). Hence, for patients with family history of angioedema and normal C1-INH, we propose to use the term factor XII-HAE (FXII-HAE) when mutation in F12 gene can be detected and unknown HAE (U-HAE) when no genetic defect can be identified. FXII-HAE should be used also for patients carrying mutations in the coagulation F12 gene even when family history of angioedema is not present, as family studies showed that angioedema symptoms segregate with the mutations (143). It is further recommended that the term HAE type III no longer be used, because HAE type I and II identify two specific types of C1-INH deficiency.

Clinical presentation

Because many case lists of HAE and normal C1-INH were presented as HAE type III before FXII-HAE subgroup was identified, separating the characteristics of U-HAE from FXII-HAE is difficult. Sex prevalence in U-HAE is not clearly reported, while almost just women are affected with FXII-HAE. F12 gene mutations are transmitted as an autosomal dominant trait with low penetrance: asymptomatic carriers are >90% in male gender and around 40% in female (146, 149, 150). The clinical symptoms include recurrent skin swellings, abdominal pain attacks, tongue swelling, and upper airways edema. No difference in clinical symptoms due to the presence of F12 gene mutations has been identified (146, 147, 151). Urticaria does not occur at any time in any of these patients. The skin swellings typically last 2–5 days; they affect mainly the extremities and the face. The abdominal attacks likewise last 2–5 days and are manifested as severe crampy pain. In a comprehensive study, 138 patients with U-HAE/FXII-HAE from 43 unrelated families were examined (146). A majority of patients had symptoms of skin swelling (92.8%), tongue swelling (53.6%), and abdominal attacks (50%). Laryngeal edema (25.4%) and uvular edema (21.7%) also were frequent, whereas edema episodes of other organs were rare (3.6%). In many women, the clinical symptoms were provoked by oral contraceptives, hormonal replacement therapy, or pregnancy.

Diagnosis

Diagnosis of U-HAE is purely based on clinical findings and requires that patients have the (i) above-mentioned clinical symptoms, (ii) one or more family members also affected with these symptoms, (iii) the exclusion of familial and hereditary chronic urticaria with urticaria-associated angioedema, (iv) normal C1-INH activity and protein in plasma, and (v) no HAE-associated mutation in F12 gene. FXII-HAE has analogous clinical criteria, but with the presence of an HAE-associated mutation in F12 gene, which may also identify solitary cases.

The laboratory diagnosis of FXII-HAE is purely genetic, while there are no confirmatory laboratory tests for U-HAE. The existence of sporadic cases of U-HAE can be assumed, but not confirmed for the moment as such a diagnosis is solely based on family history of angioedema.

Therapeutic approach

Patients with U-HAE/FXII-HAE do not respond to corticosteroids and antihistamines (152). Based on the presumed pathophysiology, several potential treatment options are available for U-HAE/FXII-HAE, including C1-INH agents, icatibant, ecallantide, progesterone, danazol, and tranexamic acid. However, there are no published controlled studies using any of these novel therapies in these patients.

Final Consensus

Angioedema identifies recurrent edema caused by the release of one of several existing vasoactive mediators. When angioedema arises together with wheals, these patients with recurrent angioedema and wheals should be diagnosed as having urticaria.

Statement 1: Angioedema is diagnosed when a patient presents with recurrent angioedema symptoms in the absence of wheals

Angioedema can be differentiated based on specific characteristics. The discussion among experts suggested first distinguishing hereditary from nonhereditary forms. Angioedema should be considered hereditary in the presence of a specific risk factor for transmission to offspring. Identified risk factors supporting a diagnosis of HAE are as follows.

Statement 2: Angioedema is defined as hereditary when (i) there is family history of angioedema within a second-degree relative; (ii) there is a mutation in the SERPING1 or the F12 gene that has been demonstrated to be associated with angioedema; and (iii) there is a familial deficiency of C1-INH. All other forms of angioedema should be considered as acquired

Based on the present knowledge, experts distinguished seven specific forms of angioedema within the two categories of

Table 2 Characteristics of different forms of angioedema

	Acquired				Hereditary		
	IH-AAE	InH-AAE	ACEI-AAE	C1-INH-AAE	C1-INH-HAE	FXII-HAE	U-HAE
Peripheral AE	+	++ (11, 17)	+– (54)	++ (77, 78)	+++ (98, 112)	++ (146, 150)	+++ (146, 150)
Facial AE	+++	++ (11, 17)	+++ (54)	+++ (77, 78)	++ (98, 112)	++ (146, 150)	++ (146, 150)
Abdominal AE	–	+ (11, 17)	+– (49, 50, 54)	++ (77, 78)	+++ (98, 112)	+++ (146, 150)	+++ (146, 150)
Upper respiratory AE	+–	++ (11, 17)	+++ (51, 54)	+++ (77, 78)	+++ (98, 112)	+++ (146, 150)	+++ (146, 150)
Age at onset	Any	Any	>65 (58)	>40	<20	<30	<30
Speed of onset	<6	12	12 (70)	24	24–36	24–36	24–36
Duration	<24 h	24–48	12–48 (70)	36–72	36–72	36–72	36–72
Male/Female	1 : 1	1 : 1	2 : 1(46, 58)	1 : 1	1 : 1	10 : 1	1 : 1
Ethnic predilection	Unknown	Unknown	Black (54, 56, 57)	None	None	German/French/Spanish	Unknown
Diagnostic characteristic	Unidentified etiology, prevented by antihistamine	Unidentified etiology, Nonprevented by antihistamine	Onset while on ACEI treatment (9, 48, 53–55)	Nongenetic C1-INH deficiency	Genetic C1-INH deficiency	Angioedema-associated mutation in FXII gene	Familial angioedema without identified genetic marker

Based on experts' opinion and reference reported in brackets.

Table 3 Evidence for treatment efficacy in different forms of angioedema

	Acquired				Hereditary		
	IH-AAE	InH-AAE	ACEI-AAE	C1-INH-AAE	C1-INH-HAE	FXII-HAE	U-HAE
Antihistamine prophylaxis	Prevention	None	None	None	None	None	None
C1 inhibitor acute	None	None	Case report (76–78)	Case list (70, 86)	Controlled studies (121, 126–128)	Case reports (152)	Case reports (152)
C1 inhibitor prophylaxis	None	None	NA	Case list (67, 87)	Controlled studies (126, 127)	Case reports (152)	Case reports (152)
Icatibant acute	None	Case report (19–21)	Case list (75)	Case list (88–91)	Controlled studies (6)	Case reports (152)	Case report (150)
Ecallantide acute	None	None	None	Case reports (92)	Controlled studies (122)	None	None
Att. Androgen prophylaxis	None	None	NA	Case list (77, 93)	Controlled studies (124)	Case report (152)	Case report (152)
Antifibrinolytic prophylaxis	None	Case list (11, 17)	NA	Case list (86)	Controlled studies (123, 125)	Case reports (150)	Case reports (150)

Based on experts' opinion and references reported in brackets.

acquired and hereditary. Characteristics for diagnosis are reported in Table 2.

Statement 3: Angioedema should be diagnosed as follows:

1 Acquired

- 1.1 Idiopathic histaminergic acquired angioedema (IH-AAE)
- 1.2 Idiopathic nonhistaminergic acquired angioedema (InH-AAE)
- 1.3 Acquired angioedema related to angiotensin-converting enzyme inhibitor (ACEI-AAE)

1.4 Acquired angioedema with C1-INH deficiency (C1-INH-AAE)

2 Hereditary

- 2.1 Hereditary angioedema with C1-INH deficiency (C1-INH-HAE)
- 2.2 Hereditary angioedema with FXII mutation (FXII-HAE)
- 2.3 Hereditary angioedema of unknown origin (U-HAE)

Drugs approved to treat angioedema are limited to C1-INH-HAE; their use in the other forms is off label. Specific indications are reported in Table 3.

Statement 4: licensed therapy of angioedema is limited to C1-INH-HAE. Other forms can just be treated off label based on small noncontrolled studies and expert experience

In conclusion, the present knowledge allows recognizing angioedema as a separate nosology entity, which is comprised of different forms that can be diagnosed based on specific criteria. The absence of studies on angioedema, other than C1-INH-HAE, prevents designing an evidence-based therapeutic strategy: development of controlled studies to properly treat angioedema-related mortality and disability should be an objective for the future.

Author contributions

All authors and listed members of HAWK, contributed to the discussion of the topics of the manuscript during the meeting, provided critical reading and final approval. The authors contributed to define the general structure and repeatedly reviewed the manuscript throughout its drafting. Inherent literature and first draft of each part were provided as follows: MC introduction; WA & APK IH-AAE; AG & MT InH-AAE; HF & MB ACEI-AAE; JAB & AZ C1-INH-AAE; TC & MAR C1-INH-HAE; AB & KB FXII/Unknown HAE; BZ & MC final consensus; TC Table 1; MC Tables 2 and 3; AG figure. MC work coordination.

Conflicts of interest

MC: Consultant for CSL Behring, Viropharma, Dyax, SOBI, Pharming, BioCryst, Sigma Tau; Research/educational grant from Shire, CSL Behring. WA: Advisor and speaker for CSL Behring, Shire, and ViroPharma; funding

to attend conferences and other educational events from CSL Behring, Pharming, Shire, and ViroPharma; donations to his departmental fund and participated in clinical trials for Shire. AB: Clinical Research funding from Dyax, Shire, CSL, Viropharma, Santarus; Advisory Board: Dyax, Santarus, Shire. MB: Consultant for Shire. JAB: Principal Investigator, Consultant, and Speaker for: Viropharma, CSL Behring, Dyax, and Shire; Principal Investigator and Consultant for: Pharming; Editorial Board: Journal of Angioedema; Medical Advisory Board: HAEA organization. KB: Consultant for CSL Behring, Shire, and Viropharma. TC: Speaker fees from Shire HGT, Inc./Jerini AG, and ViroPharma; Consultancy fees from Shire HGT, Inc./Jerini AG, ViroPharma, and CSL Behring; Funding for travel and meeting attendance from CSL Behring and Shire HGT, Inc.; Has participated in clinical trials for Dyax, Pharming, CSL Behring, and Shire HGT, Inc./Jerini AG. AG: has served on Advisory Boards and as speaker for Shire. HF: Speaker Shire and Swedish Orphan Biovitrium; Consultant for CSL Behring, Pharming, Shire, Swedish Orphan Biovitrium, and Viropharma; Travel expenses from CSL Behring, Pharming, Shire, Swedish Orphan Biovitrium, and Viropharma. APK: Grant support from Dyax, Shire, CSL Behring, Viro Pharma; Consultant for Dyax, Genentech, BioCryst; Lecture Series: Robert Michael Educational Institute, Dyax. MAR: Research funding: CSL Behring, Dyax, Pharming, Shire, ViroPharma; Consultant: BioCryst, CSL Behring, Dyax, Isis, Santarus, Shire, ViroPharma; Speaker: CSL Behring, Dyax, Shire, ViroPharma. MT: research grant from CSL Behring, consultant for Shire, Viropharma, and SOBI. BZ: Research funding: Shire; Consultant: CSL Behring, Dyax, Isis, BioCryst; Speaker: Dyax, RMEI.

References

- Zuberbier T, Asero R, Bindslev-Jensen C, Walter Canonica G, Church MK, Gimenez-Arnau A et al. EAACI/GA(2)LEN/EDF/WAO guideline: definition, classification and diagnosis of urticaria. *Allergy* 2009;**64**:1417–1426.
- Quinke H. Uber akutes umschriebenes hautodem. *Monatshe Prakt Dermatol* 1882;**1**:129–131.
- Osler W. Hereditary angio-neurotic oedema. *Am J Med Sci* 1888;**95**:362–367.
- Donaldson VH, Evans RR. A biochemical abnormality in hereditary angioneurotic edema: absence of serum inhibitor of C¹ esterase. *Am J Sci* 1963;**31**:37–44.
- Caldwell JR, Ruddy S, Schur PH, Austen KF. Acquired C1 inhibitor deficiency in lymphosarcoma. *Clin Immunol Immunopathol* 1972;**1**:39–52.
- Cicardi M, Banerji A, Bracho F, Malbran A, Rosenkranz B, Riedl M et al. Icatibant, a new bradykinin-receptor antagonist, in hereditary angioedema. *N Engl J Med* 2010;**363**:532–541.
- Byrd JB, Adam A, Brown NJ. Angiotensin-converting enzyme inhibitor-associated angioedema. *Immunol Allergy Clin North Am* 2006;**26**:725–737.
- Lin RY, Cannon AG, Teitel AD. Pattern of hospitalizations for angioedema in New York between 1990 and 2003. *Ann Allergy Asthma Immunol* 2005;**95**:159–166.
- Bork K, Barnstedt SE, Koch P, Traupe H. Hereditary angioedema with normal C1-inhibitor activity in women. *Lancet* 2000;**356**:213–217.
- Cicardi M, Bork K, Caballero T, Craig T, Li HH, Longhurst H et al. Evidence-based recommendations for the therapeutic management of angioedema owing to hereditary C1 inhibitor deficiency: consensus report of an International Working Group. *Allergy* 2012;**67**:147–157.
- Zingale LC, Beltrami L, Zanichelli A, Maggioni L, Pappalardo E, Cicardi B et al. Angioedema without urticaria: a large clinical survey. *CMAJ* 2006;**175**:1065–1070.
- Cicardi M, Bergamaschini L, Zingale LC, Gioffre D, Agostoni A. Idiopathic nonhistaminergic angioedema. *Am J Med* 1999;**106**:650–654.
- Kaplan AP. Angioedema. *World Allergy Organ J* 2008;**1**:103–113.
- Tedeschi A, Asero R, Lorini M, Marzano AV, Cugno M. Different rates of autoreactivity in patients with recurrent idiopathic angioedema associated or not with wheals. *J Investig Allergol Clin Immunol* 2012;**22**:87–91.
- Farkas H. Current pharmacotherapy of bradykinin-mediated angioedema. *Expert Opin Pharmacother* 2013;**14**:571–586.
- Rye Rasmussen EH, Bindslev-Jensen C, Bygum A. Angioedema—assessment and treatment. *Tidsskr Nor Laegeforen* 2012;**132**:2391–2395.
- Du-Thanh A, Raison-Peyron N, Drouet C, Guillot B. Efficacy of tranexamic acid in sporadic idiopathic bradykinin angioedema. *Allergy* 2010;**65**:793–795.

18. Cugno M, Nussberger J, Cicardi M, Agostoni A. Bradykinin and the pathophysiology of angioedema. *Int Immunopharmacol* 2003;**3**:311–317.
19. Colas C, Montoiro R, Fraj J, Garces M, Cubero JL, Caballero T. Nonhistaminergic idiopathic angioedema: clinical response to icatibant. *J Invest Allergol Clin Immunol* 2012;**22**:520–521.
20. Del Corso I, Puxeddu I, Sardano E, Geraci S, Breggia M, Rocchi V et al. Treatment of idiopathic nonhistaminergic angioedema with bradykinin B2 receptor antagonist icatibant. *Ann Allergy Asthma Immunol* 2012;**108**:460–461.
21. Montinaro V, Loizzo G, Zito A, Castellano G, Gesualdo L. Successful treatment of a facial attack of angioedema with icatibant in a patient with idiopathic angioedema. *Am J Emerg Med* 2013;**31**:1295.
22. Sanchez-Borges M, Asero R, Ansotegui IJ, Baiardini I, Bernstein JA, Canonica GW et al. Diagnosis and treatment of urticaria and angioedema: a worldwide perspective. *World Allergy Organ J* 2012;**5**:125–147.
23. Sands MF, Blume JW, Schwartz SA. Successful treatment of 3 patients with recurrent idiopathic angioedema with omalizumab. *J Allergy Clin Immunol* 2007;**120**:979–981.
24. Pellacani A, Brunner HR, Nussberger J. Plasma kinins increase after angiotensin-converting enzyme inhibition in human subjects. *Clin Sci (Colch)* 1994;**87**:567–574.
25. Nussberger J, Cugno M, Cicardi M. Bradykinin-mediated angioedema. *N Engl J Med* 2002;**347**:621–622.
26. Adam A, Cugno M, Molinaro G, Perez M, Lepage Y, Agostoni A. Aminopeptidase P in individuals with a history of angioedema on ACE inhibitors. *Lancet* 2002;**359**:2088–2089.
27. Molinaro G, Cugno M, Perez M, Lepage Y, Gervais N, Agostoni A et al. Angiotensin-converting enzyme inhibitor-associated angioedema is characterized by a slower degradation of des-arginine(9)-bradykinin. *J Pharmacol Exp Ther* 2002;**303**:232–237.
28. Blais C Jr, Rouleau JL, Brown NJ, Lepage Y, Spence D, Munoz C et al. Serum metabolism of bradykinin and des-Arg9-bradykinin in patients with angiotensin-converting enzyme inhibitor-associated angioedema. *Immunopharmacology* 1999;**43**:293–302.
29. Byrd JB, Touzin K, Sile S, Gainer JV, Yu C, Nadeau J et al. Dipeptidyl peptidase IV in angiotensin-converting enzyme inhibitor associated angioedema. *Hypertension* 2008;**51**:141–147.
30. La Corte AL, Carter AM, Rice GI, Duan QL, Rouleau GA, Adam A et al. A functional XPNPEP2 promoter haplotype leads to reduced plasma aminopeptidase P and increased risk of ACE inhibitor-induced angioedema. *Hum Mutat* 2011;**32**:1326–1331.
31. Duan QL, Nikpoor B, Dube MP, Molinaro G, Meijer IA, Dion P et al. A variant in XPNPEP2 is associated with angioedema induced by angiotensin I-converting enzyme inhibitors. *Am J Hum Genet* 2005;**77**:617–626.
32. Miller DR, Oliveria SA, Berlowitz DR, Fincke BG, Stang P, Lillienfeld DE. Angioedema incidence in US veterans initiating angiotensin-converting enzyme inhibitors. *Hypertension* 2008;**51**:1624–1630.
33. Brown NJ, Ray WA, Snowden M, Griffin MR. Black Americans have an increased rate of angiotensin converting enzyme inhibitor-associated angioedema.[see comment]. *Clin Pharmacol Ther* 1996;**60**:8–13.
34. Kostis JB, Kim HJ, Rusnak J, Casale T, Kaplan A, Corren J et al. Incidence and characteristics of angioedema associated with enalapril. *Arch Intern Med* 2005;**165**:1637–1642.
35. Burkhart DG, Brown NJ, Griffin MR, Ray WA, Hammerstrom T, Weiss S. Angiotensin converting enzyme inhibitor-associated angioedema: higher risk in blacks than whites. *Pharmacoepidemiol Drug Saf* 1996;**5**:149–154.
36. Toh S, Reichman ME, Houstoun M, Ross Southworth M, Ding X, Hernandez AF et al. Comparative risk for angioedema associated with the use of drugs that target the renin-angiotensin-aldosterone system. *Arch Intern Med* 2012;**172**:1582–1589.
37. Makani H, Messerli FH, Romero J, Wever-Pinzon O, Korniyenko A, Berrios RS et al. Meta-analysis of randomized trials of angioedema as an adverse event of renin-angiotensin system inhibitors. *Am J Cardiol* 2012;**110**:383–391.
38. Kostis JB, Packer M, Black HR, Schmieder R, Henry D, Levy E. Omapatrilat and enalapril in patients with hypertension: the Omapatrilat Cardiovascular Treatment vs. Enalapril (OCTAVE) trial. *Am J Hypertens* 2004;**17**:103–111.
39. Brown NJ, Snowden M, Griffin MR. Recurrent angiotensin-converting enzyme inhibitor-associated angioedema. *JAMA* 1997;**278**:232–233.
40. Agostoni A, Cicardi M, Cugno M, Zingale LC, Gioffre D, Nussberger J. Angioedema due to angiotensin-converting enzyme inhibitors. *Immunopharmacology* 1999;**44**:21–25.
41. Slater EE, Merrill DD, Guess HA, Roylance PJ, Cooper WD, Inman WH et al. Clinical profile of angioedema associated with angiotensin converting-enzyme inhibitors. *JAMA* 1988;**260**:967–970.
42. Campo P, Fernandez TD, Canto G, Mayorga C. Angioedema induced by angiotensin-converting enzyme inhibitors. *Curr Opin Allergy Clin Immunol* 2013;**13**:337–344.
43. Dean DE, Schultz DL, Powers RH. Asphyxia due to angiotensin converting enzyme (ACE) inhibitor mediated angioedema of the tongue during the treatment of hypertensive heart disease. *J Forensic Sci* 2001;**46**:1239–1243.
44. Dobbels P, Van Overbeke L, Van-beckevoort D, Hiele M. Acute abdomen due to intestinal angioedema induced by ACE inhibitors: not so rare? *Acta Gastroenterol Belg* 2009;**72**:455–457.
45. Benson BC, Smith C, Laczek JT. Angiotensin converting enzyme inhibitor-induced gastrointestinal angioedema: a case series and literature review. *J Clin Gastroenterol* 2013;**47**:844–849.
46. Cupido C, Rayner B. Life-threatening angio-oedema and death associated with the ACE inhibitor enalapril. *S Afr Med J* 2007;**97**:244–245.
47. Messerli FH, Nussberger J. Vasopeptidase inhibition and angio-oedema. *Lancet* 2000;**356**:608–609.
48. Beltrami L, Zanichelli A, Zingale L, Vaccini R, Carugo S, Cicardi M. Long-term follow-up of 111 patients with angiotensin-converting enzyme inhibitor-related angioedema. *J Hypertens* 2011;**29**:2273–2277.
49. Branell L, Bouillet L, Javaut N, Mekinian A, Boccon-Gibod I, Blanchard-Delaunay C et al. Acquired C1-inhibitor deficiency: 7 patients treated with rituximab. *J Clin Immunol* 2012;**32**:936–941.
50. Jackson J, Sim RB, Whelan A, Feighery C. An IgG autoantibody which inactivates C1-inhibitor. *Nature* 1986;**323**:722–724.
51. Donaldson VH, Wagner CJ, Davis AE 3rd. An autoantibody to C1-inhibitor recognizes the reactive center of the inhibitor. *J Lab Clin Med* 1996;**127**:229–232.
52. Alsenz J, Bork K, Loos M. Autoantibody-mediated acquired deficiency of C1 inhibitor. *N Engl J Med* 1987;**316**:1360–1366.
53. Bas M, Greve J, Steller K, Bier H, Stark T, Hoffmann TK et al. Therapeutic efficacy of icatibant in angioedema induced by angiotensin-converting enzyme inhibitors: a case series. *Ann Emerg Med* 2010;**56**:278–282.
54. Gelee B, Michel P, Haas R, Boishardy F. [Angiotensin-converting enzyme inhibitor-related angioedema: emergency treatment with complement C1 inhibitor concentrate]. *Rev Med Interne* 2008;**29**:516–519.
55. Nielsen EW, Gramstad S. Angioedema from angiotensin-converting enzyme (ACE) inhibitor treated with complement 1 (C1) inhibitor concentrate. *Acta Anaesthesiol Scand* 2006;**50**:120–122.
56. Steinbach O, Schweder R, Freitag B. C1-Esterase-Inhibitor bei ACE-Hemmer-induziertem schwerem Angioedem der

- Zunge. *Anaesthesiol Reanim* 2001;**26**:133–137.
57. Bentsianov BL, Parhiscar A, Azer M, Har-El G. The role of fiberoptic nasopharyngoscopy in the management of the acute airway in angioneurotic edema. *Laryngoscope* 2000;**110**:2016–2019.
 58. Cicardi M, Zanichelli A. Acquired angioedema. *Allergy Asthma Clin Immunol* 2010;**6**:14.
 59. Cugno M, Cicardi M, Agostoni A. Activation of the contact system and fibrinolysis in autoimmune acquired angioedema: a rationale for prophylactic use of tranexamic acid. *J Allergy Clin Immunol* 1994;**93**:870–876.
 60. Cugno M, Cicardi M, Coppola R, Agostoni A. Activation of factor XII and cleavage of high molecular weight kininogen during acute attacks in hereditary and acquired C1-inhibitor deficiencies. *Immunopharmacology* 1996;**33**:361–364.
 61. Cugno M, Cicardi M, Bottasso B, Coppola R, Paonessa R, Mannucci PM et al. Activation of the coagulation cascade in C1-inhibitor deficiencies. *Blood* 1997;**89**:3213–3218.
 62. Nussberger J, Cugno M, Amstutz C, Cicardi M, Pellacani A, Agostoni A. Plasma bradykinin in angio-oedema. *Lancet* 1998;**351**:1693–1697.
 63. Fields T, Ghebrehwet B, Kaplan AP. Kinin formation in hereditary angioedema plasma: evidence against kinin derivation from C2 and in support of “spontaneous” formation of bradykinin. *J Allergy Clin Immunol* 1983;**72**:54–60.
 64. Hauptmann G, Lang JM, North ML, Oberling F, Mayer G, Lachmann P. Acquired c1-inhibitor deficiencies in lymphoproliferative diseases with serum immunoglobulin abnormalities. A study of three cases. *Blut* 1976;**32**:195–206.
 65. Schreiber AD, Zweiman B, Atkins P, Goldwein F, Pietra G, Atkinson B et al. Acquired angioedema with lymphoproliferative disorder: association of C1 inhibitor deficiency with cellular abnormality. *Blood* 1976;**48**:567–580.
 66. Hauptmann G, Petitjean F, Lang JM, Oberling F. Acquired C1 inhibitor deficiency in a case of lymphosarcoma of the spleen. Reversal of complement abnormalities after splenectomy. *Clin Exp Immunol* 1979;**37**:523–531.
 67. Levi M, Hack CE, van Oers MH. Rituximab-induced elimination of acquired angioedema due to C1-inhibitor deficiency. *Am J Med* 2006;**119**:e3–e5.
 68. Castelli R, Deliliers DL, Zingale LC, Pogliani EM, Cicardi M. Lymphoproliferative disease and acquired C1 inhibitor deficiency. *Haematologica* 2007;**92**:716–718.
 69. Jackson J, Feighery C. Autoantibody-mediated acquired deficiency of C1 inhibitor. *N Engl J Med* 1988;**318**:122–123.
 70. Alsenz J, Lambris JD, Bork K, Loos M. Acquired C1 inhibitor (C1-INH) deficiency type II. Replacement therapy with C1-INH and analysis of patients’ C1-INH and anti-C1-INH autoantibodies. *J Clin Invest* 1989;**83**:1794–1799.
 71. Jackson J, Sim RB, Whaley K, Feighery C. Autoantibody facilitated cleavage of C1-inhibitor in autoimmune angioedema. *J Clin Invest* 1989;**83**:698–707.
 72. He S, Tsang S, North J, Chohan N, Sim RB, Whaley K. Epitope mapping of C1 inhibitor autoantibodies from patients with acquired C1 inhibitor deficiency. *J Immunol* 1996;**156**:2009–2013.
 73. Mandle R, Baron C, Roux E, Sundel R, Gelfand J, Aulak K et al. Acquired C1 inhibitor deficiency as a result of an autoantibody to the reactive center region of C1 inhibitor. *J Immunol* 1994;**152**:4680–4685.
 74. Cicardi M, Beretta A, Colombo M, Gioffre D, Cugno M, Agostoni A. Relevance of lymphoproliferative disorders and of anti-C1 inhibitor autoantibodies in acquired angio-oedema. *Clin Exp Immunol* 1996;**106**:475–480.
 75. D’Incan M, Tridon A, Ponard D, Dumestre-Perard C, Ferrier-Le Bouedec M, Betail G et al. Acquired angioedema with C1 inhibitor deficiency: is the distinction between type I and type II still relevant? *Dermatology* 1999;**199**:227–230.
 76. Zingale LC, Castelli R, Zanichelli A, Cicardi M. Acquired deficiency of the inhibitor of the first complement component: presentation, diagnosis, course, and conventional management. *Immunol Allergy Clin North Am* 2006;**26**:669–690.
 77. Cicardi M, Zanichelli A. The acquired deficiency of C1-inhibitor: lymphoproliferation and angioedema. *Curr Mol Med* 2010;**10**:354–360.
 78. Bouillet-Claveyrolas L, Ponard D, Drouet C, Massot C. Clinical and biological distinctions between type I and type II acquired angioedema. *Am J Med* 2003;**115**:420–421.
 79. Zuraw BL, Curd JG. Demonstration of modified inactive first component of complement (C1) inhibitor in the plasmas of C1 inhibitor-deficient patients. *J Clin Invest* 1986;**78**:567–575.
 80. Zuraw BL, Altman LC. Acute consumption of C1 inhibitor in a patient with acquired C1-inhibitor deficiency syndrome. *J Allergy Clin Immunol* 1991;**88**:908–918.
 81. Zuraw BL, Bernstein JA, Lang DM, Craig T, Dreyfus D, Hsieh F et al. A focused parameter update: Hereditary angioedema, acquired C1 inhibitor deficiency, and angiotensin-converting enzyme inhibitor-associated angioedema. *J Allergy Clin Immunol* 2013;**131**:1491–1493.
 82. Hassan A, Amarger S, Tridon A, Ponard D, Souteyrand P, D’Incan M. Acquired angioedema responding to rituximab. *Acta Derm Venereol* 2011;**91**:733–734.
 83. Lam D, Levy N, Nickerson J, Gruenberg D, Lansigan F. Acquired angioedema and marginal zone lymphoma. *J Clin Oncol* 2012;**16**:e551–e553.
 84. Sanchez-Cano D, Callejas-Rubio J, Lara-Jimenez M, Lopez-Trascasa M, Circadi M, Ortego-Centeno N. Successful use of rituximab in acquired C1 inhibitor deficiency secondary to Sjogren’s syndrome. *Lupus* 2008;**17**:228–229.
 85. Ziakas PD, Giannouli S, Psimenou E, Evangelia K, Tzioufas AG, Voulgarelis M. Acquired angioedema: a new target for rituximab? *Haematologica* 2004;**89**:ELT13.
 86. Agostoni A, Cicardi M. Hereditary and acquired C1-inhibitor deficiency: biological and clinical characteristics in 235 patients. *Medicine (Baltimore)* 1992;**71**:206–215.
 87. Bork K, Witzke G. Long-term prophylaxis with C1-inhibitor (C1 INH) concentrate in patients with recurrent angioedema caused by hereditary and acquired C1-inhibitor deficiency. *J Allergy Clin Immunol* 1989;**83**:677–682.
 88. Bright P, Dempster J, Longhurst H. Successful treatment of acquired C1 inhibitor deficiency with icatibant. *Clin Exp Dermatol* 2010;**35**:553–554.
 89. Bygum A, Broesby-Olsen S. Rapid resolution of erythema marginatum after icatibant in acquired angioedema. *Acta Derm Venereol* 2011;**91**:185–186.
 90. Weller K, Magerl M, Maurer M. Successful treatment of an acute attack of acquired angioedema with the bradykinin-B2-receptor antagonist icatibant. *J Eur Acad Dermatol Venereol* 2011;**25**:119–120.
 91. Zanichelli A, Bova M, Coerezza A, Petraroli A, Triggiani M, Cicardi M. Icatibant treatment for acquired C1-inhibitor deficiency: a real-world observational study. *Allergy* 2012;**67**:1074–1077.
 92. Patel NS, Fung SM, Zanichelli A, Cicardi M, Cohn JR. Ecallantide for treatment of acute attacks of acquired C1 esterase inhibitor deficiency. *Allergy Asthma Proc* 2013;**34**:72–77.
 93. Agostoni A, Aygoren-Pursun E, Binkley KE, Blanch A, Bork K, Bouillet L et al. Hereditary and acquired angioedema: problems and progress: proceedings of the third C1 esterase inhibitor deficiency workshop and beyond. *J Allergy Clin Immunol* 2004;**114**(Suppl 3):S51–S131.
 94. Stray-Pedersen A, Abrahamsen TG, Froland SS. Primary immunodeficiency

- diseases in Norway. *J Clin Immunol* 2000;**20**:477–485.
95. Roche O, Blanch A, Caballero T, Sastre N, Callejo D, Lopez-Trascasa M. Hereditary angioedema due to C1 inhibitor deficiency: patient registry and approach to the prevalence in Spain. *Ann Allergy Asthma Immunol* 2005;**94**:498–503.
 96. Bygum A. Hereditary angio-oedema in Denmark: a nationwide survey. *Br J Dermatol* 2009;**161**:1153–1158.
 97. Cicardi M, Agostoni A. Hereditary angioedema. *N Engl J Med* 1996;**334**:1666–1667.
 98. Longhurst H, Cicardi M. Hereditary angioedema. *Lancet* 2012;**379**:474–481.
 99. Lopez-Lera A, Favier B, de la Cruz RM, Garrido S, Drouet C, Lopez-Trascasa M. A new case of homozygous C1-inhibitor deficiency suggests a role for Arg378 in the control of kinin pathway activation. *J Allergy Clin Immunol* 2010;**126**:1307–1310.
 100. Blanch A, Roche O, Urrutia I, Gamboa P, Fontan G, Lopez-Trascasa M. First case of homozygous C1 inhibitor deficiency. *J Allergy Clin Immunol* 2006;**118**:1330–1335.
 101. Bafunno V, Divella C, Sessa F, Tiscia GL, Castellano G, Gesualdo L et al. De novo homozygous mutation of the C1 inhibitor gene in a patient with hereditary angioedema. *J Allergy Clin Immunol* 2013;**132**:748–750.
 102. Roche O, Blanch A, Duponchel C, Fontan G, Tosi M, Lopez-Trascasa M. Hereditary angioedema: the mutation spectrum of SERPING1/C1NH in a large Spanish cohort. *Hum Mutat* 2005;**26**:135–144.
 103. Lopez-Lera A, Garrido S, Roche O, Lopez-Trascasa M. SERPING1 mutations in 59 families with hereditary angioedema. *Mol Immunol* 2011;**49**:18–27.
 104. Kalmar L, Bors A, Farkas H, Vas S, Fandl B, Varga L et al. Mutation screening of the C1 inhibitor gene among Hungarian patients with hereditary angioedema. *Hum Mutat* 2003;**22**:498.
 105. Pappalardo E, Caccia S, Suffritti C, Tordai A, Zingale LC, Cicardi M. Mutation screening of C1 inhibitor gene in 108 unrelated families with hereditary angioedema: functional and structural correlates. *Mol Immunol* 2008;**45**:3536–3544.
 106. Tosi M, Carugati A, Hernandez C, Boucontet L, Pappalardo E, Agostoni A et al. De novo C1 inhibitor mutations in hereditary angioedema. *Mol Immunol* 1998;**35**:406–406.
 107. Pappalardo E, Cicardi M, Duponchel C, Carugati A, Choquet S, Agostoni A et al. Frequent de novo mutations and exon deletions in the C1 inhibitor gene of patients with angioedema. *J Allergy Clin Immunol* 2000;**106**:1147–1154.
 108. Kalmar L, Hegedus T, Farkas H, Nagy M, Tordai A. HAEdb: a novel interactive, locus-specific mutation database for the C1 inhibitor gene. *Hum Mutat* 2005;**25**:1–5.
 109. Rosen FS, Pensky J, Donaldson V, Charache P. Hereditary angioneurotic edema: two genetic variants. *Science* 1965;**148**:957–958.
 110. Lumry WR, Castaldo AJ, Vernon MK, Blaustein MB, Wilson DA, Horn PT. The humanistic burden of hereditary angioedema: impact on health-related quality of life, productivity, and depression. *Allergy Asthma Proc* 2010;**31**:407–414.
 111. Wilson DA, Bork K, Shea EP, Rentz AM, Blaustein MB, Pullman WE. Economic costs associated with acute attacks and long-term management of hereditary angioedema. *Ann Allergy Asthma Immunol* 2010;**104**:314–320.
 112. Bork K, Staubach P, Eckardt AJ, Hardt J. Symptoms, course, and complications of abdominal attacks in hereditary angioedema due to C1 inhibitor deficiency. *Am J Gastroenterol* 2006;**101**:619–627.
 113. Donaldson VH, Rosen FS. Action of complement in hereditary angioneurotic edema: the role of C'1-esterase. *J Clin Invest* 1964;**43**:2204–2213.
 114. Wagenaar-Bos IG, Drouet C, Aygoren-Pursun E, Bork K, Bucher C, Bygum A et al. Functional C1-inhibitor diagnostics in hereditary angioedema: assay evaluation and recommendations. *J Immunol Methods* 2008;**338**:14–20.
 115. Thelwel C, Rigsby P, Longstaff C, ISTH-SSC Subcommittee on Factor XI and Contact System. An international collaborative study to establish the WHO 1st international standards for C1-inhibitor, plasma and concentrate. *J Thromb Haemost* 2011;**9**:2097–2099.
 116. Caballero T, Farkas H, Bouillet L, Bowen T, Gompel A, Fagerberg C et al. International consensus and practical guidelines on the gynecologic and obstetric management of female patients with hereditary angioedema caused by C1 inhibitor deficiency. *J Allergy Clin Immunol* 2012;**129**:308–320.
 117. Tarzi MD, Hickey A, Forster T, Mohammadi M, Longhurst HJ. An evaluation of tests used for the diagnosis and monitoring of C1 inhibitor deficiency: normal serum C4 does not exclude hereditary angioedema. *Clin Exp Immunol* 2007;**149**:513–516.
 118. Gompels MM, Lock RJ, Morgan JE, Osborne J, Brown A, Virgo PF. A multi-centre evaluation of the diagnostic efficiency of serological investigations for C1 inhibitor deficiency. *J Clin Pathol* 2002;**55**:145–147.
 119. Brecy H, Hartmann L. Distinction between hereditary and acquired angioneurotic oedema according to the complement system. *Biomedicine* 1975;**23**:328–334.
 120. Brasher GW, Starr JC, Hall FF, Spiekerman AM. Complement component analysis in angioedema. Diagnostic value. *Arch Dermatol* 1975;**111**:1140–1142.
 121. Zuraw B, Cicardi M, Levy RJ, Nuijens JH, Relan A, Visscher S et al. Recombinant human C1-inhibitor for the treatment of acute angioedema attacks in patients with hereditary angioedema. *J Allergy Clin Immunol* 2010;**126**:821–827.
 122. Cicardi M, Levy RJ, McNeil DL, Li HH, Sheffer AL, Campion M et al. Ecallantide for the treatment of acute attacks in hereditary angioedema. *N Engl J Med* 2010;**363**:523–531.
 123. Frank MM, Sergent JS, Kane MA, Alling DW. Epsilon aminocaproic acid therapy of hereditary angioneurotic edema. A double-blind study. *N Engl J Med* 1972;**286**:808–812.
 124. Gelfand JA, Sherins RJ, Alling DW, Frank MM. Treatment of hereditary angioedema with danazol. Reversal of clinical and biochemical abnormalities. *N Engl J Med* 1976;**295**:1444–1448.
 125. Blohme G. Treatment of hereditary angioneurotic oedema with tranexamic acid. A random double-blind cross-over study. *Acta Med Scand* 1972;**192**:293–298.
 126. Zuraw BL, Busse PJ, White M, Jacobs J, Lumry W, Baker J et al. Nanofiltered C1 inhibitor concentrate for treatment of hereditary angioedema. *N Engl J Med* 2010;**363**:513–522.
 127. Waytes AT, Rosen FS, Frank MM. Treatment of hereditary angioedema with a vapor-heated C1 inhibitor concentrate. *N Engl J Med* 1996;**334**:1630–1634.
 128. Craig TJ, Levy RJ, Wasserman RL, Bewtra AK, Hurewitz D, Obtulowicz K et al. Efficacy of human C1 esterase inhibitor concentrate compared with placebo in acute hereditary angioedema attacks. *J Allergy Clin Immunol* 2009;**124**:801–808.
 129. Craig T, Aygoren-Pursun E, Bork K, Bowen T, Boysen H, Farkas H et al. WAO Guideline for the Management of Hereditary Angioedema. *World Allergy Organ J* 2012;**5**:182–199.
 130. Bowen T, Cicardi M, Farkas H, Bork K, Kreuz W, Zingale L et al. Canadian 2003 international consensus algorithm for the diagnosis, therapy, and management of hereditary angioedema. *J Allergy Clin Immunol* 2004;**114**:629–637.
 131. Bowen T, Cicardi M, Farkas H, Bork K, Longhurst HJ, Zuraw B et al. 2010 International consensus algorithm for the diagnosis, therapy and management of hereditary

- angioedema. *Allergy Asthma Clin Immunol* 2010;**6**:24.
132. Longhurst HJ, Farkas H, Craig T, Aygoren-Pursun E, Bethune C, Bjorkander J et al. HAE international home therapy consensus document. *Allergy Asthma Clin Immunol* 2010;**6**:22.
 133. Zanichelli A, Vacchini R, Badini M, Penna V, Cicardi M. Standard care impact on angioedema because of hereditary C1 inhibitor deficiency: a 21-month prospective study in a cohort of 103 patients. *Allergy* 2011;**66**:192–196.
 134. Bork K, Hardt J, Staubach-Renz P, Witzke G. Risk of laryngeal edema and facial swellings after tooth extraction in patients with hereditary angioedema with and without prophylaxis with C1 inhibitor concentrate: a retrospective study. *Oral Surg Oral Med Oral Pathol Oral Radiol Endod* 2011;**112**:58–64.
 135. Farkas H, Zotter Z, Csuka D, Szabo E, Nebenfuhrer Z, Temesszentandras G et al. Short-term prophylaxis in hereditary angioedema due to deficiency of the C1-inhibitor—a long-term survey. *Allergy* 2012;**67**:1586–1593.
 136. Grant JA, White MV, Lee HH, Fitts D, Kalfus IN, Uknis ME et al. Preprocedural administration of nanofiltered C1 esterase inhibitor to prevent hereditary angioedema attacks. *Allergy Asthma Proc* 2012;**33**:348–353.
 137. Martinez-Saguer I, Rusicke E, Aygoren-Pursun E, von Hentig N, Klingebiel T, Kreuz W. Pharmacokinetic analysis of human plasma-derived pasteurized C1-inhibitor concentrate in adults and children with hereditary angioedema: a prospective study. *Transfusion* 2010;**50**:354–360.
 138. Cocchio C, Marzella N, Cinryze, a human plasma-derived C1 esterase inhibitor for prophylaxis of hereditary angioedema. *P T* 2009;**34**:293–328.
 139. Bork K, Fischer B, Dewald G. Recurrent episodes of skin angioedema and severe attacks of abdominal pain induced by oral contraceptives or hormone replacement therapy. *Am J Med* 2003;**114**:294–298.
 140. Binkley KE, Davis A 3rd. Clinical, biochemical, and genetic characterization of a novel estrogen-dependent inherited form of angioedema. *J Allergy Clin Immunol* 2000;**106**:546–550.
 141. Martin L, Degenne D, Toutain A, Ponard D, Watier H. Hereditary angioedema type III: an additional French pedigree with autosomal dominant transmission. *J Allergy Clin Immunol* 2001;**107**:747–748.
 142. Bork K, Gul D, Dewald G. Hereditary angio-oedema with normal C1 inhibitor in a family with affected women and men. *Br J Dermatol* 2006;**154**:542–545.
 143. Dewald G, Bork K. Missense mutations in the coagulation factor XII (Hageman factor) gene in hereditary angioedema with normal C1 inhibitor. *Biochem Biophys Res Commun* 2006;**343**:1286–1289.
 144. Bork K, Wulff K, Meinke P, Wagner N, Hardt J, Witzke G. A novel mutation in the coagulation factor 12 gene in subjects with hereditary angioedema and normal C1-inhibitor. *Clin Immunol* 2011;**141**:31–35.
 145. Kiss N, Barabas E, Varnai K, Halasz A, Varga LA, Prohaszka Z et al. Novel duplication in the F12 gene in a patient with recurrent angioedema. *Clin Immunol* 2013;**149**:142–145.
 146. Bork K, Gul D, Hardt J, Dewald G. Hereditary angioedema with normal C1 inhibitor: clinical symptoms and course. *Am J Med* 2007;**120**:987–992.
 147. Bork K, Wulff K, Hardt J, Witzke G, Staubach P. Hereditary angioedema caused by missense mutations Figure 1: Classification of angioedema without wheals the factor XII gene: clinical features, trigger factors, and therapy. *J Allergy Clin Immunol* 2009;**124**:129–134.
 148. Cichon S, Martin L, Hennies HC, Muller F, Van Driessche K, Karpushova A et al. Increased activity of coagulation factor XII (Hageman factor) causes hereditary angioedema type III. *Am J Hum Genet* 2006;**79**:1098–1104.
 149. Marcos C, Lopez Lera A, Varela S, Linares T, Alvarez-Eire MG, Lopez-Trascasa M. Clinical, biochemical, and genetic characterization of type III hereditary angioedema in 13 Northwest Spanish families. *Ann Allergy Asthma Immunol* 2012;**109**:195–200.
 150. Vitrat-Hincky V, Gompel A, Dumestre-Perard C, Boccon-Gibod I, Drouet C, Cesbron JY et al. Type III hereditary angio-oedema: clinical and biological features in a French cohort. *Allergy* 2010;**65**:1331–1336.
 151. Bork K. Hereditary angioedema with normal C1 inhibitor activity including hereditary angioedema with coagulation factor XII gene mutations. *Immunol Allergy Clin North Am* 2006;**26**:709–724.
 152. Bork K. Diagnosis and treatment of hereditary angioedema with normal C1 inhibitor. *Allergy Asthma Clin Immunol* 2010;**6**:15.

Appendix

HAWK (Hereditary Angioedema International Working Group):

Emel Aygören-Pürsün, Germany; María-Luisa Baeza, Spain; Noemi-Anna Bara, Romania; Alicia Lara Becerra, Mexico; Karen Binkley, Canada; Janne Bjorkander, Sweden; Isabelle Boccon-Gibot, France; Paolo Borrelli, Italy; Laurence Bouillet, France; Maria Bova Italy; Tom Bowen, Canada; Manuel Branco-Ferreira, Portugal; Anette Bygum, Denmark; Mauro Cancian, Italy; Maria Graça Castel-Branco, Portugal; Sven Cichon, Swiss; Enrico Cillari Italy; Stefan Cimbollek, Spain; Timothy J. Craig, US; Alvin Davis, US; Isabella Del Corso, Italy; Christian Drouet, France; Josè Fabiani, Argentina; Michael Frank, US; Mark Gompels, UK; Teresa González-Quevedo, Spain; Richard Gower, US; Clive Grattan, UK; Adriane Groffik, Germany; Mar Guilarte, Spain; Erik Hack,

The Netherlands; Maria E. Hernandez Landeros, Mexico; Iris Leibovich, Israel; Henri Li, US; Bob Lock, UK; Hilary Longhurst, UK; William R Lumry, US; Markus Magerl, Germany; Alex Malbran, Argentina; Ludovic Martin, France; Inmaculada Martinez-Saguer, Germany; Juan J. Matta Campos, Mexico; Marcus Maurer, Germany; Enikő Mihály, Romania; Paola Minale, Italy; Dumitru Moldovan, Romania; Vincenzo Montinaro, Italy; Sergio Neri, Italy; Sandra Nieto, Mexico; Patrick Nordenfelt, Sweden; Krystyna Obtuloviz, Poland; Celso Pereira, Portugal; Roberto Perricone, Italy; Nieves Prior, Spain; Paolina Quattrocchi, Italy; Thomas Rennè, Sweden; Avner Reshfer, Israel; Oliviero Rossi, Italy; Anna Sala-Cunill, Spain; Peter Spaeth, Swiss; Petra Staubach-Renz, Germany; Marcin Stobiecki Poland; Lilian Varga, Hungary; Walter Wuillemin, Swiss; Giuseppina Zanierato, Italy; Alessandra Zoli, Italy.