

Clear Cell Papillary Renal Cell Carcinoma

Jianping Zhao, MD, PhD; Eduardo Eyzaguirre, MD

• Clear cell papillary renal cell carcinoma (ccpRCC) is a recently recognized entity and represents the fourth most common variant of renal cell carcinoma (RCC). It has unique morphologic and immunohistochemical features and demonstrates an indolent clinical behavior. Microscopically, it may mimic other RCCs with clear cell features, such as clear cell RCC, translocation RCC, and papillary RCC with clear cell changes. A high index of suspicion is required to keep ccpRCC in the differential diagnosis of RCCs with features of clear cell and/or papillary architecture. In equivocal cases, immunohistochemistry is generally sufficient to substantiate the diagnosis of ccpRCC. In this review, we discuss the clinical, gross, and histopathologic features, immunohistochemical and genetic profiling, and prognosis of ccpRCC.

(*Arch Pathol Lab Med.* 2019;143:1154–1158; doi: 10.5858/arpa.2018-0121-RS)

Clear cell papillary renal cell carcinoma (ccpRCC) was introduced as a new tumor entity by the 2016 World Health Organization (WHO) classification of renal neoplasia because of its unique morphologic, immunohistochemical, and genetic features, and its indolent clinical behavior.^{1–4} It was initially described in 2006 in conjunction with end-stage renal disease.⁵ However, sporadic cases of ccpRCC have been described in patients without kidney disease.⁶ This tumor comprises 1% to 4% of all resected renal tumors, and it represents the fourth most common variant of renal cell carcinoma (RCC).⁷ Microscopically, this tumor has both clear cell and papillary features, and the nuclei are often low grade, with characteristic linear arrangement away from the basal aspect of cells.² Because of its overlapping morphology, ccpRCC can be easily misdiagnosed with other subtypes of RCC, such as low-grade clear cell RCC (ccRCC), papillary RCC (PRCC) with clear cell changes, and translocation RCC.⁸ It is important to note that this is an indolent tumor with good clinical outcomes that has not shown any recurrences, metastases, or lymph node involvement.⁹ Therefore, it is crucial to correctly differentiate ccpRCC from other subtypes of RCC that have a much

worse prognosis. In equivocal cases, a number of immunohistochemical stains will aid in arriving at the correct diagnosis, including cytokeratin 7 (CK7), α -methylacyl-CoA racemase (AMACR), carbonic anhydrase IX (CA IX), CD10, and transcription factor E3 (TFE3).¹⁰

CLINICAL FEATURES

Clinically, patients with ccpRCC are asymptomatic, and the tumor is typically detected as an incidental finding in normally functioning kidneys or during the follow-up of patients with end-stage renal disease. The age at presentation varies from 18 to 88 years, with no sex predilection.¹ Radiology imaging will show tumors as solid or cystic heterogeneous lesions with smooth margins, growing within or beyond the renal cortex (Figure 1).¹¹ Notably, ccpRCC has an indolent clinical behavior, and no recurrences or metastases have been reported to date.

GROSS PATHOLOGY

Grossly, these tumors are small, with an average size of 2.6 cm. They are usually encapsulated, with a well-defined, thin, fibrous capsule (Figure 2). The cut surface is variable, frequently pink-tan with cystic change without areas of necrosis. Clear cell papillary RCC commonly presents as a small, solitary tumor, but patients can infrequently have multifocal and/or bilateral tumors, or it can coexist with other renal tumors.^{12,13} The great majority of tumors are stage I at presentation.

HISTOPATHOLOGY

Microscopically, ccpRCC is usually well-circumscribed with a fibrous capsule. The overall architecture pattern can be tubular, papillary, solid, cystic, acinar, or a combination of these, but the most frequent architecture is the tubular-papillary pattern with characteristic branching tubules (Figure 3). In some tumors, small acini or closely packed cells with scant cytoplasm give the impression of a solid tumor. The neoplastic cells have a cuboidal to columnar shape with clear cytoplasm. The nuclei are often small, round to oval in shape, with regular nuclear membranes and inconspicuous to small nucleoli, consistent with WHO/International Society of Urological Pathology (ISUP) grade 1 or 2. Characteristically, the nuclei are typically localized in a linear fashion toward the luminal surface and away from the basement membrane, namely reverse polarity (Figure 4). The tumor has variable amounts of fibrotic, collagenous, or smooth muscle stroma and scattered small blood vessels. Calcifications, hemosiderin deposition, and lymphoplasmacytic inflammatory infiltrate or nonnecrotizing granulomas have also been described in the stroma of ccpRCC. Some

Accepted for publication May 24, 2018.

Published online January 23, 2019.

From the Department of Pathology, University of Texas Medical Branch, Galveston.

The authors have no relevant financial interest in the products or companies described in this article.

Corresponding author: Eduardo Eyzaguirre, MD, Department of Pathology, University of Texas Medical Branch, 301 University Boulevard, Galveston, TX 77555 (email: eeyzagu@utmb.edu).

tumors may have a predominant smooth muscle component and were previously named as renal angiomyoadenomatous tumors (RATs).^{14,15} Clear cell papillary RCC and RAT have been classified recently into the same spectrum of ccpRCC by the 2016 WHO guideline.¹ To date, no aggressive behavior, such as extrarenal invasion, lymphovascular invasion, high WHO/ISUP grade, necrosis, or sarcomatoid/rhabdoid changes, has been documented.

IMMUNOHISTOCHEMISTRY AND GENETIC PROFILE

Immunohistochemical stains are essential for accurately diagnosing ccpRCC when its morphologic characteristics are equivocal.⁴ The tumor shows diffuse and uniform immunoreactivity for CK7 (Figure 5), and a characteristic [cuplike] membranous pattern for CA IX (without staining in the luminal borders; Figure 6).^{1-3,7} Recently, GATA-3 has emerged as a specific marker for ccpRCC, and it stains positive in about one-third of cases.¹⁶ In addition, ccpRCC strongly labels for high-molecular weight cytokeratin (34 β E12), paired box gene 2 (PAX2), PAX8, vimentin, E-cadherin, β -catenin, c-MET, CK19, p27, p53, HIF1, and GLUT-1.¹⁷ On the other hand, the tumor is generally negative for CD10, RCC antigen, AMACR, TFE3, and translocation factor EB (TFEB). Therefore, ccpRCC has a unique immunohistochemical phenotype (CK7⁺, CA IX⁺ [cuplike], AMACR⁻, 34 β E12⁺, CD10⁻, TFE3⁻),^{1,10} which allows differentiation of this tumor from other types of renal cancer with overlapping histologic features.

Genetically, ccpRCC has a molecular profile different from those of ccRCC and PRCC. ccpRCC usually lacks chromosome 3p deletion and *VHL* gene mutation, which are typical findings of ccRCC.^{17,18} In contrast to PRCC, ccpRCC has no copy number abnormality of chromosomes 7, 17, and Y.^{17,18} Some somatic mutations, such as *MET*, *PTEN*, *ERBB4*, and *STK11*, have been identified in ccpRCC by using next-generation sequencing.^{19,20} Noncoding RNA profiling revealed overexpression of *miR-200* family in ccpRCC.^{20,21} A recent study showed that ccpRCC has a microRNA expression profile distinct from those of ccRCC or PRCC, supporting that ccpRCC is a unique entity distinct from ccRCC or PRCC.²¹ The clinical significance of these findings is unclear, and further studies are needed to help in understanding the role of these changes in the pathogenesis and clinical behavior of ccpRCC.

DIFFERENTIAL DIAGNOSIS

Because ccpRCC is a clinically indolent tumor, a correct diagnosis will be crucially important for a patient's treatment plan and the impact on a patient's life. Three major relevant RCCs should be considered in the differential diagnosis, including ccRCC, PRCC, and Xp11 translocation RCC. All of them can have overlapping morphologic features with ccpRCC, such as prominent clear cell cytoplasm, and acinar, solid, papillary architecture (Figure 7).

Clear cell RCC is the most common variant of RCC (70%).^{1,10} Grossly, the cut surface typically looks yellow, often with cysts, hemorrhage, and necrosis. Tumor cells commonly have clear cytoplasm, and can have cystic, solid areas, like ccpRCC, but papillary areas are uncommon. The tumor usually has abundant small, thin-walled blood vessels. Nuclei commonly show random arrangement and may have high-grade features, such as prominent nucleoli or bizarre nuclei. Immunohistochemical staining of ccRCC

usually shows a diffuse expression of CD10, CA IX (boxlike membranous pattern), AE1/AE3, CAM5.2, EMA, PAX8, PAX2, and vimentin, and a lack of CK7, AMACR, and 34 β E12 expression.¹ Most ccRCCs have *VHL* gene mutation or chromosome 3p deletion, and it is the typical manifestation of von Hippel-Lindau (*VHL*) syndrome. It may also be associated with other familial renal cancer syndromes, such as Cowden syndrome, Birt-Hogg-Dubé syndrome, and tuberous sclerosis complex.^{1,22} Uncommonly, ccpRCC can present as multifocal bilateral disease, raising the differential diagnosis of *VHL* syndrome-associated RCC. In addition, ccpRCC-like tumors have been described in patients with *VHL* syndrome; however, the characteristic immunophenotype and molecular features of ccRCC are preserved in these tumors, allowing for differentiation from ccpRCC.⁴

Papillary RCC is the second most common variant of RCC (18%).^{1,10} It often presents as a well-circumscribed tumor with a fibrous pseudocapsule, and a variable cut surface with areas of hemorrhage, necrosis, and cystic degeneration. Most PRCCs have papillary architecture with delicate fibrovascular cores, which often contain foamy macrophages, hemosiderin, and psammoma bodies. Some tumors may have extensive clear cell cytoplasm, raising the differential diagnosis with ccRCC and ccpRCC. Immunohistochemical stains will typically show positivity for CK7, CD10, AE1/AE3, CAM5.2, EMA, vimentin, RCC antigen, AMACR, and 34 β E12, and negativity for CA IX.¹ Genetically, PRCC is typically associated with gain of chromosome 7 or 17 and loss of chromosome Y.

Xp11 translocation RCC is the renal tumor characterized by chromosomal translocations with breakpoints involving the *TFE3* gene, which maps to the Xp11.2 locus. This neoplasm is primarily seen in young patients (40% of pediatric RCCs) but may occur as an aggressive tumor in adults (1.6%–4% of adult RCCs).^{1,23,24} The most common architectural pattern of this tumor is papillary or nested, with epithelioid clear cells and abundant psammomatous calcifications. The nuclei are usually high grade, and the cytoplasm can be granular or eosinophilic. Stromal hyaline nodules can also be seen. It can also present with unusual morphology mimicking other types of RCCs, including multilocular cystic RCC-like features and tubular growth reminiscent of collecting duct carcinoma. This tumor shows nuclear staining for TFE3, which is highly specific and sensitive. The antibody used is against the C-terminal portion of TFE3 and can detect chimeric (mutant) TFE3 protein. In addition, the tumor usually shows positive staining for cathepsin-K, PAX8, CD10, E-cadherin, AMACR, and RCC antigen, but weak or no expression of AE1/AE3, CAM5.2, CK7, and EMA.²⁴

Finally, 2 RCC entities have been recently described as showing some overlapping morphologic and immunohistochemical features of ccpRCC, including tuberous sclerosis complex-associated papillary RCC²⁵ and transcription elongation factor B subunit 1 (*TCEB1*)-mutated RCC.^{26,27} Tuberous sclerosis complex-associated PRCC usually presents as tumor nodules circumscribed by thick, fibrous stroma with prominent large clear cells lining papillary structures, and the nuclei are oriented toward the basement membrane. These tumors are strongly and diffusely positive for CK7, CD10, CA IX (boxlike), AMACR, and vimentin, but negative for SDHB, TFE3, and RCC antigen.²⁵ Only a few *TCEB1*-mutated RCC cases have been reported, which show well-circumscribed tumors composed of clear cells with voluminous cytoplasm in variable architectural patterns

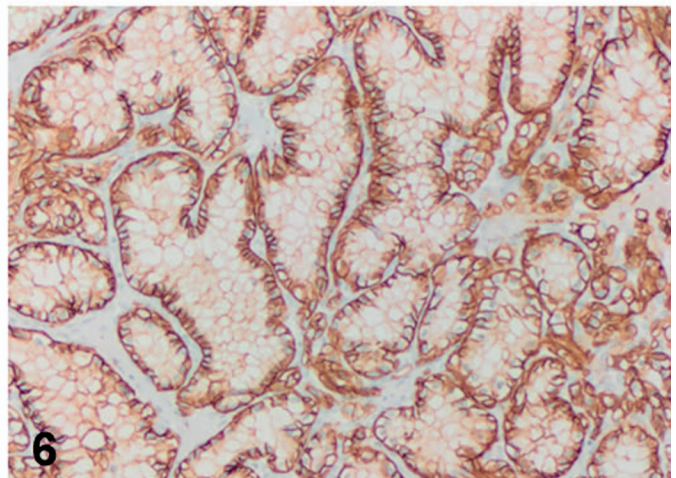
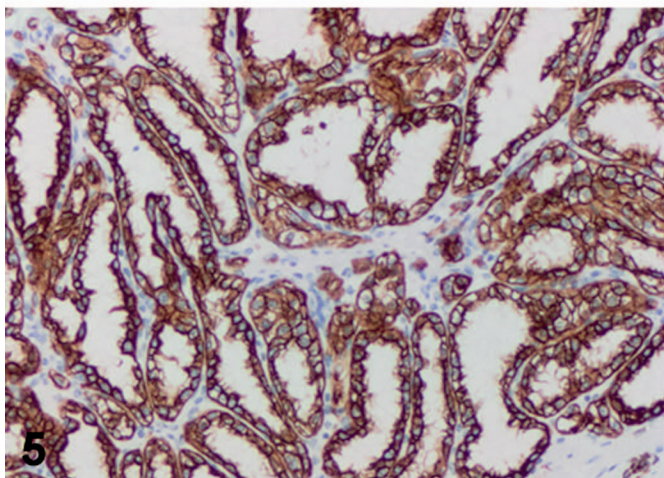
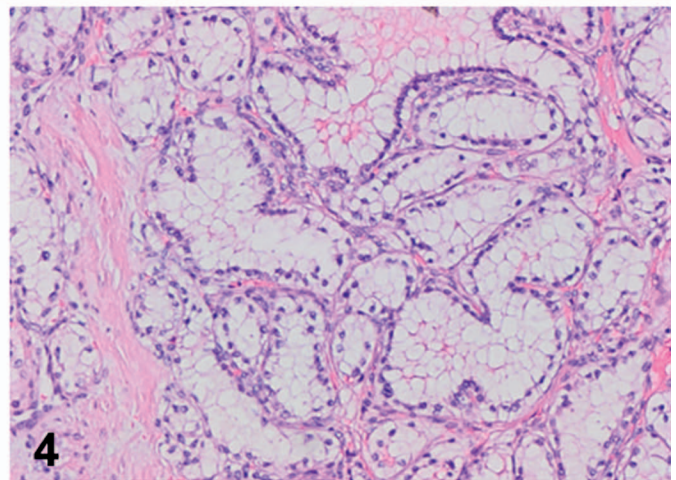
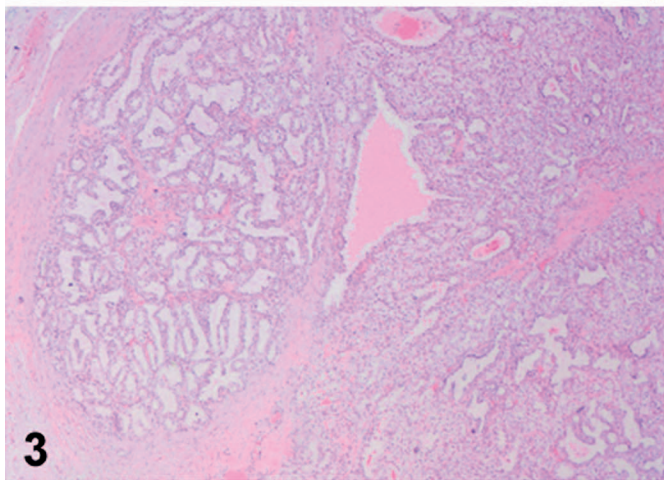
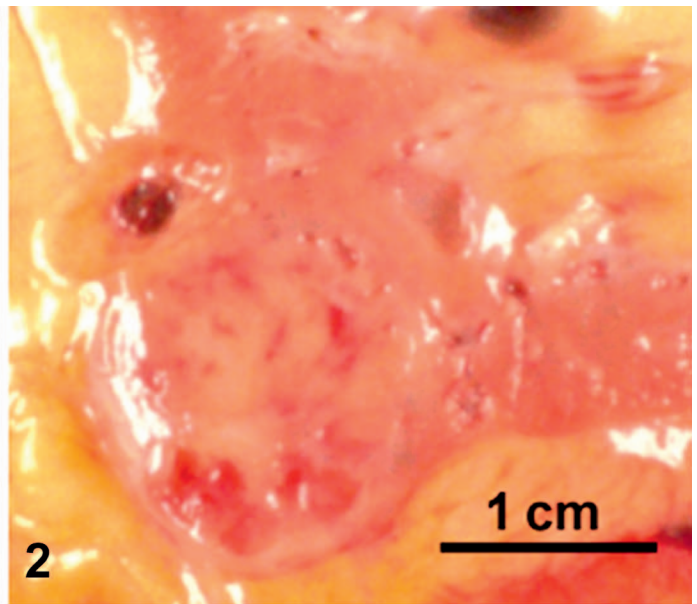
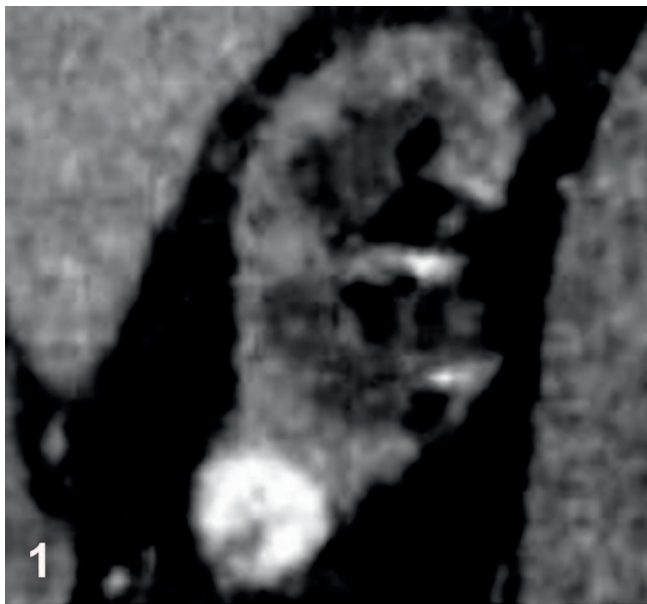


Figure 1. Computed tomography (CT) scan with contrast of a clear cell papillary renal cell carcinoma as a solid heterogeneous lesion with smooth margin, which grows beyond the renal cortex.

Figure 2. Gross image of the clear cell papillary renal cell carcinoma depicted in Figure 1. The tumor is encapsulated with a well-defined, thin, fibrous capsule, and the cut surface is pink-tan with cystic change.

Figure 3. Clear cell papillary renal cell carcinoma shows tubular, papillary, cystic architecture with fibrous capsule (hematoxylin-eosin, original magnification $\times 20$).

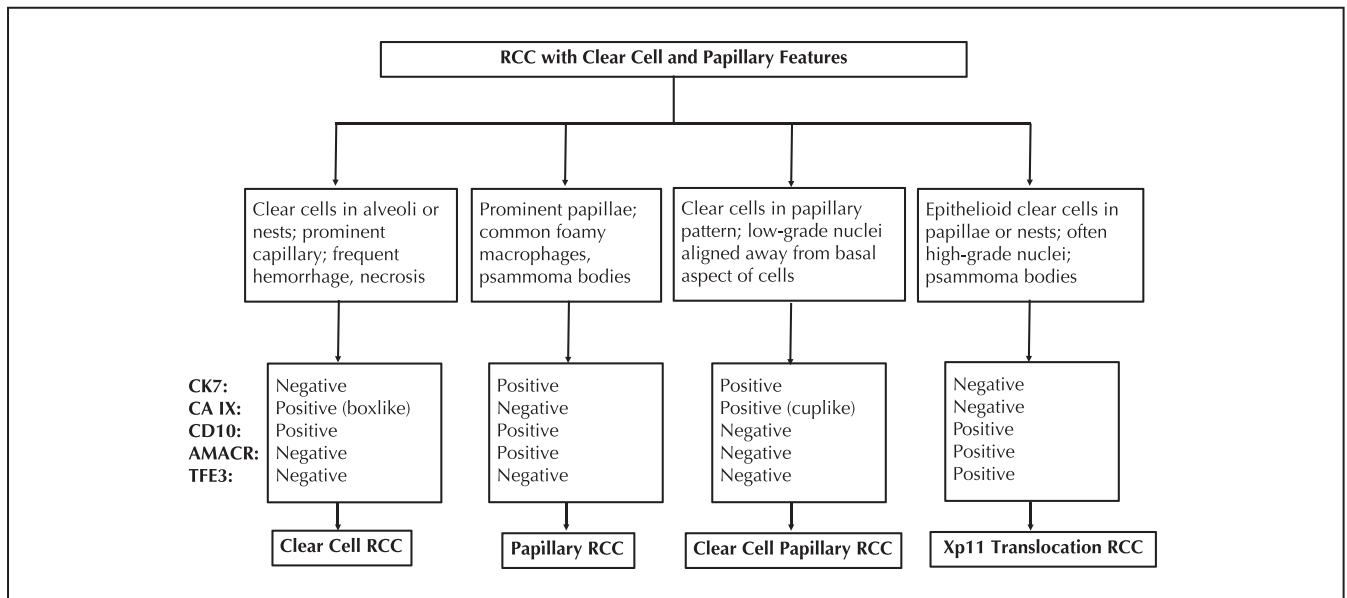


Figure 7. A diagnostic algorithm for renal cell carcinoma (RCC) with clear cell and papillary features, including clear cell RCC, papillary RCC, clear cell papillary RCC, and Xp11 translocation RCC. Abbreviations: AMACR, α -methylacyl-CoA racemase; CA IX, carbonic anhydrase IX; CK7, cytokeratin 7; TFE3, transcription factor E3 (TFE3).

(including tubular-papillary), with intervening prominent, thick fibromuscular bands imparting a multinodular architecture to the tumor. These tumors can show focal ccpRCC-like nuclear features. *TCEB1*-mutated RCCs typically express CK7 and CA IX (boxlike), variable CD10 expression, and are negative for 34E1 β .^{26,27}

PROGNOSIS AND TREATMENT

Clear cell papillary RCC is a tumor with indolent clinical behavior and a favorable prognosis.^{1–4,9} At presentation, this tumor is low stage, with a low WHO/ISUP grade. Based on follow-up studies of 362 ccpRCC patients in the literature (with a mean of 38 months), tumor recurrence, metastasis, or disease-related death has not been reported to date.¹⁷ Partial or total nephrectomy is the primary treatment for a solitary ccpRCC. If the diagnosis can be made preoperatively by a core biopsy, a more conservative approach may be used to treat this indolent tumor, including minimal surgical procedures such as ablation, partial nephrectomy, or active surveillance with strict follow-up.^{2,17}

References

- Moch H, Humphrey PA, Ulbright TM, Reuter VE. *WHO Classification of Tumours of the Urinary System and Male Genital Organs*. 4th ed. Lyon, France: 2016. *WHO Classification of Tumours*; vol 8.
- Kuroda N, Ohe C, Kawakami F, et al. Clear cell papillary renal cell carcinoma: a review. *Int J Clin Exp Pathol*. 2014;7(11):7312–7318.
- Alexiev BA, Drachenberg CB. Clear cell papillary renal cell carcinoma: incidence, morphological features, immunohistochemical profile, and biologic behavior: a single institution study. *Pathol Res Pract*. 2014;210(4):234–241.
- Williamson SR, Zhang S, Eble JN, et al. Clear cell papillary renal cell carcinoma-like tumors in patients with von Hippel-Lindau disease are unrelated to sporadic clear cell papillary renal cell carcinoma. *Am J Surg Pathol*. 2013; 37(8):1131–1139.

- Tickoo SK, dePeralta-Venturina MN, Harik LR, et al. Spectrum of epithelial neoplasms in end-stage renal disease: an experience from 66 tumor-bearing kidneys with emphasis on histologic patterns distinct from those in sporadic adult renal neoplasia. *Am J Surg Pathol*. 2006;30(2):141–153.
- Aron M, Chang E, Herrera L, et al. Clear cell-papillary renal cell carcinoma of the kidney not associated with end-stage renal disease: clinicopathologic correlation with expanded immunophenotypic and molecular characterization of a large cohort with emphasis on relationship with renal angiomyoadenomatous tumor. *Am J Surg Pathol*. 2015;39(7):873–888.
- Zhou H, Zheng S, Truong LD, Ro JY, Ayala AG, Shen SS. Clear cell papillary renal cell carcinoma is the fourth most common histologic type of renal cell carcinoma in 290 consecutive nephrectomies for renal cell carcinoma. *Hum Pathol*. 2014;45(1):59–64.
- Dhakal HP, McKenney JK, Khor LY, Reynolds JP, Magi-Galluzzi C, Przybycin CG. Renal neoplasms with overlapping features of clear cell renal cell carcinoma and clear cell papillary renal cell carcinoma: a clinicopathologic study of 37 cases from a single institution. *Am J Surg Pathol*. 2016;40(2):141–154.
- Williamson SR. What is the malignant potential of clear cell papillary renal cell carcinoma? *Urol Oncol*. 2016;34(9):420–421.
- Alshenawy HA. Immunohistochemical panel for differentiating renal cell carcinoma with clear and papillary features. *Pathol Oncol Res*. 2015;21(4):893–899.
- Wang K, Zarzour J, Rais-Bahrami S, Gordetsky J. Clear cell papillary renal cell carcinoma: new clinical and imaging characteristics. *Urology*. 2017;103: 136–141.
- Anderson DA, Tretiakova MS. Primary renal carcinoid with bilateral multiple clear cell papillary renal cell carcinomas. *Case Rep Pathol*. 2017;2017: 9672368.
- Park JH, Lee C, Suh JH, Moon KC. Clear cell papillary renal cell carcinoma: a report of 15 cases including three cases of concurrent other-type renal cell carcinomas. *Korean J Pathol*. 2012;46(6):541–547.
- Hes O, Comperat EM, Rioux-Leclercq N. Clear cell papillary renal cell carcinoma, renal angiomyoadenomatous tumor, and renal cell carcinoma with leiomyomatous stroma relationship of 3 types of renal tumors: a review. *Ann Diagn Pathol*. 2016;21:59–64.
- Deml KF, Schildhaus HU, Comperat E, et al. Clear cell papillary renal cell carcinoma and renal angiomyoadenomatous tumor: two variants of a morphologic, immunohistochemical, and genetic distinct entity of renal cell carcinoma. *Am J Surg Pathol*. 2015;39(7):889–901.

Figure 4. The neoplastic cells have clear cytoplasm, and the nuclei are localized in a linear fashion away from the basement membrane (hematoxylin-eosin, original magnification $\times 100$).

Figure 5. Cytokeratin 7 immunohistochemical stain shows strong diffuse positivity (original magnification $\times 100$).

Figure 6. Carbonic anhydrase IX immunohistochemical stain shows a characteristic cuplike membranous pattern without staining in the luminal borders (original magnification $\times 100$).

16. Mantilla JG, Antic T, Tretiakova M. GATA3 as a valuable marker to distinguish clear cell papillary renal cell carcinomas from morphologic mimics. *Hum Pathol.* 2017;66:152–158.
17. Massari F, Ciccarese C, Hes O, et al. The tumor entity denominated “clear cell-papillary renal cell carcinoma” according to the WHO 2016 new classification, have the clinical characters of a renal cell adenoma as does harbor a benign outcome. *Pathol Oncol Res.* 2018;24(3):447–456.
18. Aydin H, Chen L, Cheng L, et al. Clear cell tubulopapillary renal cell carcinoma: a study of 36 distinctive low-grade epithelial tumors of the kidney. *Am J Surg Pathol.* 2010;34(11):1608–1621.
19. Fisher KE, Yin-Goen Q, Alexis D, et al. Gene expression profiling of clear cell papillary renal cell carcinoma: comparison with clear cell renal cell carcinoma and papillary renal cell carcinoma. *Mod Pathol.* 2014;27(2):222–230.
20. Lawrie CH, Larrea E, Larrinaga G, et al. Targeted next-generation sequencing and non-coding RNA expression analysis of clear cell papillary renal cell carcinoma suggests distinct pathological mechanisms from other renal tumour subtypes. *J Pathol.* 2014;232(1):32–42.
21. Munari E, Marchionni L, Chitre A, et al. Clear cell papillary renal cell carcinoma: micro-RNA expression profiling and comparison with clear cell renal cell carcinoma and papillary renal cell carcinoma. *Hum Pathol.* 2014;45(6):1130–1138.
22. Crino PB, Nathanson KL, Henske EP. The tuberous sclerosis complex. *N Engl J Med.* 2006;355(13):1345–1356.
23. Parihar A, Tickoo SK, Kumar S, Arora VK. Xp11 translocation renal cell carcinoma morphologically mimicking clear cell-papillary renal cell carcinoma in an adult patient: report of a case expanding the morphologic spectrum of Xp11 translocation renal cell carcinomas. *Int J Surg Pathol.* 2015;23(3):234–237.
24. Armah HB, Parwani AV. Xp11.2 translocation renal cell carcinoma. *Arch Pathol Lab Med.* 2010;134(1):124–129.
25. Yang P, Cornejo KM, Sadow PM, et al. Renal cell carcinoma in tuberous sclerosis complex. *Am J Surg Pathol.* 2014;38(7):895–909.
26. Udager AM, Mehra R. Morphologic, molecular, and taxonomic evolution of renal cell carcinoma: a conceptual perspective with emphasis on updates to the 2016 World Health Organization classification. *Arch Pathol Lab Med.* 2016;140(10):1026–1037.
27. Hakimi AA, Tickoo SK, Jacobsen A, et al. *TCEB1*-mutated renal cell carcinoma: a distinct genomic and morphological subtype. *Mod Pathol.* 2015;28(6):845–853.