

Research article

Clinical and immunohistochemical study of eight cases with thymic carcinoma

Masaki Tomita*, Yasunori Matsuzaki, Masao Edagawa, Masayuki Maeda, Tetsuya Shimizu, Masaki Hara and Toshio Onitsuka

Address: Department of Surgery II, Miyazaki Medical College, Kihara 5200, Kiyotake, Miyazaki, 889-1692, Japan

E-mail: Masaki Tomita* - mtomita@post.miyazaki-med.ac.jp; Yasunori Matsuzaki - matuzaki@fc.miyazaki-med.ac.jp; Masao Edagawa - meda@fc.miyazaki-med.ac.jp; Masayuki Maeda - MASA@post.miyazaki-med.ac.jp; Tetsuya Shimizu - kairiku@fc.miyazaki-med.ac.jp; Masaki Hara - haramasa@fc.miyazaki-med.ac.jp; Toshio Onitsuka - ono@fc.miyazaki-med.ac.jp

*Corresponding author

Published: 23 May 2002

BMC Surgery 2002, **2**:3

Received: 14 December 2001

Accepted: 23 May 2002

This article is available from: <http://www.biomedcentral.com/1471-2482/2/3>

© 2002 Tomita et al; licensee BioMed Central Ltd. Verbatim copying and redistribution of this article are permitted in any medium for any purpose, provided this notice is preserved along with the article's original URL.

Abstract

Background: Thymic carcinoma is a rare neoplasm with extremely poor prognosis. To evaluate the biological characteristics of thymic carcinoma, we reviewed 8 patients.

Methods: There were 2 men and 6 women: ages ranged from 19 to 67 years old (mean 54.8 years). None of these patients had concomitant myasthenia gravis and pure red cell aplasia. No patient had stage I disease, 1 stage II, 5 stage III, and 2 stage IV. The pathologic subtypes of thymic carcinoma included 5 squamous cell carcinomas, 1 adenosquamous cell carcinomas, 1 clear cell carcinoma, and 1 small cell carcinoma. Immunohistochemical study was performed using antibodies against p53, bcl-2, Ki-67, carcinoembryonic antigen (CEA), epithelial membrane antigen (EMA), nm23-H1, vascular endothelial growth factor (VEGF), basic fibroblast growth factor (FGF-2) and factor VIII.

Results: Curative resection could be done in 4 patients (50%). Our data indicates a trend toward an association between complete resection and patient survival. Expression of p53, bcl-2, CEA, EMA, nm23-H1, VEGF and FGF-2 was detected in 5/8, 3/8, 4/8, 5/8, 6/8, 5/8 and 3/8, respectively. Mean Ki-67 labeling index and microvessel density was 7.01 and 34.36 (per 200× field), respectively. When compared with our previous studies, immunohistochemical staining of these proteins in thymomas, the expression rates of these proteins in thymic carcinomas were higher than those in thymomas.

Conclusions: In this small series, it is suggested that a complete resection suggests a favorable result. Immunohistochemical results reveal that the expression of these proteins might indicate the aggressiveness of thymic carcinoma.

Background

Thymic carcinoma is a rare type of malignant tumor [1,2]. It is more invasive and with a poorer prognosis than ordi-

nary thymoma [3–8]. At diagnosis, it is usually invasive or metastatic and complete curative resection is sometimes not possible to achieve. There are no uniform manage-

ment protocols and thymic carcinoma is treated by the same guidelines used for thymomas, despite having a more aggressive histologic appearance and clinical outcome [6–8].

In addition, in spite of numerous previous studies about expression of oncogene proteins in human cancers, very little attention has been given to the biological characteristics of thymic carcinoma [9–13].

To evaluate the outcome and biological characteristics of thymic carcinomas, we reviewed patients undergoing treatment including surgery at our hospital. In addition to clinical analysis, we also investigated expression of some cancer-related proteins to evaluate their biological characteristics. Since previous studies of ours demonstrated the expression p53, bcl-2, Ki-67, carcinoembryonic antigen (CEA), epithelial membrane antigen (EMA), nm23-H1, vascular endothelial growth factor (VEGF), basic fibroblast growth factor (FGF-2) and microvessels in thymomas [14,15], we performed immunohistochemistry using same antibodies as in our previous studies.

Methods

Patients

Between 1988 and 2000, 8 patients with thymic carcinoma who were treated surgically at Miyazaki Medical College were included in this study. Two patients who did not receive surgical options during this period were excluded. There were 2 men and 6 women: ages ranged from 19 to 67 years old (mean 54.8 years). None of these patients had concomitant myasthenia gravis and pure red cell aplasia. Postoperative staging was made according to the Masaoka staging system [16]. No patient had stage I disease, 1 stage II, 5 stage III, and 2 stage IV. The pathologic subtypes of thymic carcinoma included 5 squamous cell carcinomas, 1 adenosquamous cell carcinomas, 1 clear cell carcinoma, and 1 small cell carcinoma. The histologic grading was based on cell differentiation, which was modified from Suster and Rosai's classification system [4]. Carcinoid tumors, well-differentiated (keratinizing) squamous cell carcinoma, and mucoepidermoid carcinoma were delegated to low-grade tumors, and all other types were classified as high-grade tumors. In our series, only one patient with squamous cell carcinoma had low-grade tumor. Table 1 summarizes the clinical characteristics of these patients. The mean follow-up period ranged from 12 to 83 months (mean 30.8 months). The follow-up information, including cause of death, was acquired through clinic follow-up notes and direct or family contact.

Immunohistochemical studies

Surgically resected tissue samples previously fixed in formalin and embedded in paraffin were used. The specific

antibodies against p53 (Dako, Glostrup, Denmark), bcl-2 (Dako), EMA (Dako), CEA (Dako), nm23-H1 (Novocastrol Laboratories, Newcastle, UK), Ki-67 (Immunotech, Marseille, France), VEGF (Santa Cruz Biotechnology, California, U.S.A.), FGF-2 (Santa Cruz Biotechnology) and factor VIII (Dako) were used in this study.

Before staining, serial 4 μm -thick sections were pre-treated with microwave heating in 10 mM citric acid buffer for 4 \times 5 min. These sections were immersed in 0.6% H_2O_2 in methanol for 20 min. at room temperature to block endogenous peroxidase activity. After blocking non-specific protein bindings by an overnight incubation with Block Ace (Dainippon, Inc., Osaka, Japan), the sections were incubated with primary antibodies against human p53 (1:100), bcl-2 (1:100), Ki-67 (1:100), CEA (1:100), EMA (1:100), nm23-H1 (1:100), VEGF (1:50), FGF-2 (1:50) and Ki-67 (1:50), respectively, at 4°C overnight. Subsequently, sections were incubated with the secondary antiserum (1:500) for one hour, followed by an incubation with peroxidase anti peroxidase (PAP) complex for 30 min. at room temperature. The sections were visualized using a diaminobenzidine (DAB)/Metal Concentration (10 \times) and Stable Peroxide Substrate Buffer (1 \times) system (Pierce, Rockford, Illinois, U.S.A.). The sections were then washed with water and counterstained with hematoxylin. Immunohistological results were assessed semiquantitatively by two authors. The staining for p53, bcl-2, EMA, CEA, nm23-H1, VEGF and FGF-2 proteins with the respective antibodies was considered positive if more than 10% of tumor cells were immunoreactive. The Ki-67 labeling index was determined by light microscopy with an oil-immersion objective (magnification \times 1,000) randomly counting 1,000 tumor epithelial cells and expressing the results as a percentage of positive cells. Microvessel density was determined by counting in the area of the most intense vascularization (hot spot) of each tumor, and the average count (per 200 \times field) was recorded.

Results

Clinical Results

Preoperative biopsy using a 14-gauge Tru-cut biopsy needle was performed for 3 patients, however only one was diagnosed as thymic carcinoma and others were failed to obtain a decisive diagnosis. Preoperative diagnoses of other remaining 5 patients were invasive thymomas by radiological examinations. Therefore, only one patient underwent preoperative chemotherapy that consisted of intra-arterial infusion of cisplatin 100 mg and subsequent systemic administration of cisplatin 25 mg and etoposide 100 mg. In this case, a partial response was obtained. Surgical procedure was performed through median sternotomy. Curative resection could be done in 4 patients (50%). In other 4 of remaining patients, the resection was incomplete due to invasion into adjacent organs and/or dissem-

Table 1: Clinical characteristics

Case	Age	Sex	Histology	Grading	Stage	Resection	Preoperative therapy	Postoperative therapy
1	54	F	Clear cell carcinoma	high	III	complete	none	radiotherapy
2	64	F	SCC	low	III	complete	none	radiotherapy
3	19	F	SCC	high	II	complete	chemotherapy	none
4	65	F	Small cell carcinoma	high	III	complete	none	radiotherapy
5	67	M	Adenosquamous cell carcinoma	high	III	incomplete	none	none
6	47	F	SCC	high	IVa	incomplete	none	radiotherapy
7	55	F	SCC	high	III	incomplete	none	radiotherapy
8	59	M	SCC	high	IVa	incomplete	none	chemotherapy radiotherapy

SCC: squamous cell carcinoma.

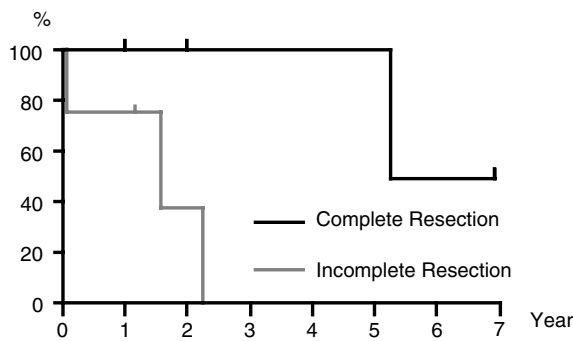


Figure 1
Survival of patients having complete resection compared with incomplete resection.

inated lesions. Postoperative radiotherapy was given with a total dose of 40–60 Gy for 6 patients. One patient who underwent incomplete resection and radiotherapy, was also received chemotherapy that consisted of cisplatin 60 mg/m² and etoposide 120 mg/m². The median survival times for all patients was 43.8 month and the overall cumulative survival was 46.7% at 3 years. Operative mortality, defined as death within 30 days of surgery, did not occur. However, one patient, who underwent incomplete resection, died on postoperative day 39 of rapid tumor growth and respiratory failure.

Although our series included small size of patient population, we investigated a relationship between some clinical factors and survival. The median survival times for patients with completely and incompletely resected disease were 73.0 and 17.6 months, respectively. As shown in Fig. 1, there was a difference in survival between completely and incompletely resected patients. Clinical stage, squamous cell carcinoma and postoperative irradiation did

not show favorable results in our series (data not shown). Prognostic value of histologic grading could not be investigated because there was only one patient with low-grade tumor in our series.

Immunohistochemical results

Positive immunohistochemical stainings with p53 and Ki-67 were confined to the nucleus of the tumor cells (Fig. 2). Lymphocytes and stromal cells were consistently unstained. Immunoreactivity of bcl-2, CEA, EMA, nm23-H1, VEGF and FGF-2 were predominantly observed in the cytoplasm of the tumor cells (Fig. 2). Positive immunostaining of p53, bcl-2, CEA, EMA, nm23-H1, VEGF and FGF-2 was detected in 5/8 (62.5%), 3/8 (37.5%), 4/8 (50%), 5/8 (62.5%), 6/8 (75%), 5/8 (62.5%) and 3/8 (37.5%), respectively. The Ki-67 labeling index (mean ± S.D.) was 7.01 ± 6.37 and microvessel density (mean ± S.D.) was 34.36 ± 16.7 (per 200× field). Table 2 summarizes these immunohistochemical results.

We previously investigated the expression of these proteins in thymomas [14,15]. These studies demonstrated that positive immunostaining of p53, bcl-2, CEA, EMA, nm23-H1, VEGF and FGF-2 was found in 13/38 (34.2%), 6/38 (15.8%), 6/38 (15.8%), 10/38 (26.3%), 22/38 (57.9%), 12/38 (31.6%) and 5/38 (13.2%), respectively [14,15]. They also showed that Ki-67 labeling index and microvessel density of thymomas were 2.57 ± 4.52 and 8.7 ± 6.99, respectively [14,15]. When compared these results, the expression rates of these proteins in thymic carcinoma were higher than those in thymomas, indicating the aggressiveness of thymic carcinoma.

Discussion

In the present study, the size of patient population is small and follow-up period is variable and relatively short. In spite of these limitations, our data showed that a complete resection suggests a favorable result. Previous

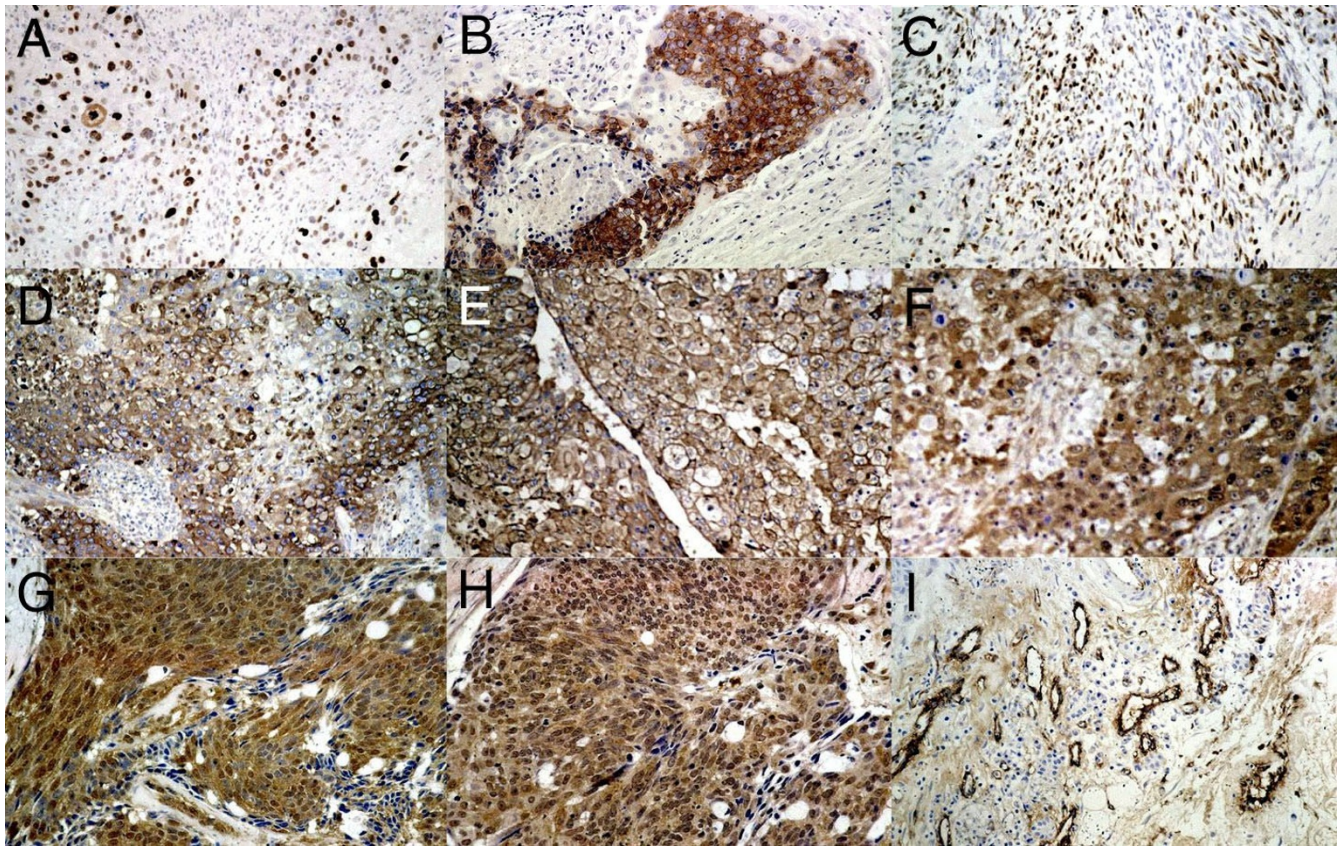


Figure 2
Positive staining of p53 (A), bcl-2 (B), Ki-67 (C), CEA (D), EMA (E), nm23-H1 (F), VEGF (G), FGF-2 (H) and factor VIII (I) in thymic carcinoma. Magnification 100x.

Table 2: Immunohistochemical results

Case	p53	bcl-2	Ki-67	CEA	EMA	nm23	VEGF	FGF-2	MVD
1	-	+	2.9	-	-	-	-	-	15.1
2	+	-	10.2	-	+	+	+	-	17.2
3	-	-	0.6	-	-	-	-	-	19.1
4	-	-	14.6	+	+	+	-	-	44.3
5	+	-	10.6	+	+	+	+	+	34.6
6	+	-	15.3	-	+	+	+	-	36.2
7	+	+	0.9	+	+	+	+	+	45.1
8	+	+	1.1	+	-	+	+	+	63.3

MVD: microvessel density (per 200x field)

studies also showed similar results [6,8]. On the other hand, Hsu *et al*[5] showed a lack of efficacy of complete resection, even though they showed longer median survival. We believe that surgical resection of the tumor is the best treatment for thymic carcinoma.

Our small series could not show a favorable result of clinical stage, squamous cell carcinoma and postoperative radiotherapy, while previous studies demonstrated a favorable result. Liu *et al* [8] found that clinical stage had statistically significant influence on patients' survival.

Some previous studies demonstrated that squamous cell carcinoma was associated with a better outcome than other histological types [6,7,17]. Masaoka *et al*[17] reported that 5-year survival was 65.6% in squamous cell carcinoma and 14.3% in other type. Although we could not investigate a prognostic value of histologic grading, Liu *et al*[8] also reported that histologic grading had significant influence on patients' survival. With regard to the role of irradiation in the treatment of thymic carcinoma, Shimotsato *et al* [18] reported an apparent cure from radiotherapy for an unresected squamous cell thymic carcinoma with lung invasion. There had been demonstrated a trend towards squamous cell carcinomas being radiosensitive [18,19]. Our results were not consistent with these previous studies. However the number of patients in our series was too small to permit meaningful correlation between survival and clinical stage, histologic subtype and radiotherapy. We believe that this discrepancy might be due to limited number of patients and combined treatment.

Our immunohistochemical results revealed that expression rates of p53, bcl-2, CEA, EMA and Ki-67 in thymic carcinomas were higher than those in thymomas. Since these proteins are related to tumor growth in many cancers, it is suggested that higher expression rates of these proteins might indicate the aggressiveness of thymic carcinoma.

Some previous studies also reported expression of these proteins in thymic carcinomas. With regard to p53 expression in thymic carcinoma, previous studies had also reported similar findings. Tateyama *et al* [9] reported 13 of 13 (100%), Hayashi *et al*[10] showed 5 of 6 (83.3%), Chen *et al*[11] reported 12 of 17 (71%) and Hino *et al* [12] found 14 of 19 (74%) thymic carcinomas were positive for p53 immunostaining. Tateyama *et al*[9] also reported that p53 gene mutation occurred early in the tumorigenesis of thymic tumors and p53 may be a useful adjunct to differentiate thymic carcinoma from thymoma. Bcl-2 is a proto-oncogene inhibiting apoptosis and Chen *et al*[11] showed that bcl-2 expression correlates with aggressiveness in thymic epithelial neoplasms. With regard to CEA expression, Savino *et al*[20] reported that CEA might act as a growth factor for proliferating thymic epithelial cells. Some previous studies also reported expression of EMA in thymic carcinoma. Truong *et al* [3] showed 13 of 13 and Fukai *et al*[13] showed 13 of 14 thymic carcinomas were positive for EMA. Fukai *et al*[13] concluded that immunolabeling for EMA appears to be a useful tool for determining the degree of malignant disease among thymic epithelial neoplasms. Therefore, taken together with our results, expression of p53, bcl-2, CEA, EMA and Ki-67 might be implicated in malignant potential of thymic carcinoma.

In the present result, 75% of our series showed positive for nm23-H1 expression. To our knowledge, there are no previous studies for nm23-H1 expression in thymic carcinoma. Expression of nm23-H1 is thought to play a specific biological role in suppressing tumor metastasis [21]. The role of high frequency of nm23-H1 expression in thymic carcinoma deserves further investigation.

Angiogenesis is essential for tumor growth and an enhanced vascular supply might reflect a malignant potential [22]. Our result also showed that microvessel density and expression of VEGF and FGF-2 in thymic carcinomas were higher than those in thymomas. Therefore, angiogenesis might be also related with the aggressiveness of thymic carcinoma.

The outcome of thymic carcinoma treatment must be investigated using the same histologic typing and staging. Thus, our series might be inadequate to analyze the biological characteristics of thymic carcinoma. In spite of limited number of patients and combined treatment, we found that a complete resection suggests a favorable result. Furthermore, immunohistochemical results might indicate the aggressiveness of thymic carcinoma. Further study is warranted to define the biological characteristics and precise treatment strategy for thymic carcinoma.

Competing interests

None declared.

Author's Contributions

MT collected and compiled the data and reviewed the manuscript with YM. Immunohistological results were assessed by MT and MM. TS participated in the design of the study. ME and MM conducted the study and commented on the data analysis and manuscript. TO conceived of the study, reviewed the data collection and analytical processes, and wrote the body of the manuscript. All authors read and approved the final manuscript.

Acknowledgements

The authors wish to thank Mrs. Yasuko Tobayashi for her skillful technical assistance.

References

1. Levine GD, Rosai J: **Thymic hyperplasia and neoplasia: a review of current concepts.** *Hum Pathol* 1978, **9**:495-514
2. Wick MR, Weiland LH, Scheithauer BW, Bernatz PE: **Primary thymic carcinomas.** *Am J Surg Pathol* 1982, **6**:451-470
3. Truong LD, Mody DR, Cagle PT, Jackson YG, Schwartz MR, Wheeler TM: **Thymic carcinoma. A clinicopathologic study of 13 cases.** *Am J Surg Pathol* 1990, **14**:151-166
4. Sustter S, Rosai J: **Thymic carcinoma. A clinicopathologic study of 60 cases.** *Cancer* 1991, **67**:1025-1032
5. Hsu CP, Chen CY, Chen CL, Lin CT, Hsu NY, Wang JH, Wang PY: **Thymic carcinoma. Ten years' experience in twenty patients.** *J Thorac Cardiovasc Surg* 1994, **107**:615-620
6. Blumberg D, Burt ME, Bains MS, Downey RJ, Martini N, Rusch V, Ginsberg RJ: **Thymic carcinoma: current staging does not predict prognosis.** *J Thorac Cardiovasc Surg* 1998, **115**:303-308

7. Chung DA: **Thymic carcinoma—analysis of nineteen clinico-pathological studies.** *Thorac Cardiovasc Surg* 2000, **48**:114-119
8. Liu HC, Hsu WH, Chen YJ, Chan YJ, Wu YC, Huang BS, Huang MH: **Primary thymic carcinoma.** *Ann Thorac Surg* 2002, **73**:1076-1081
9. Tateyama H, Eimoto T, Tada T, Mizuno T, Inagaki H, Hata A, Sasaki M, Masaoka A: **p53 protein expression and p53 gene mutation in thymic epithelial tumors. An immunohistochemical and DNA sequencing study.** *Am J Clin P* 1995, **104**:375-381
10. Hayashi Y, Ishii N, Obayashi C, Jinnai K, Hanioka K, Imai Y, Itoh H: **Thymoma: tumour type related to expression of epidermal growth factor (EGF), EGF-receptor, p53, v-erb B and ras p21.** *Virchows Arch* 1995, **426**:43-50
11. Chen FF, Yan JJ, Jin YT, Su JJ: **Detection of bcl-2 and p53 in thymoma: expression of bcl-2 as a reliable marker of tumor aggressiveness.** *Hum Pathol* 1996, **27**:1089-1092
12. Hino N, Kondo K, Miyoshi T, Uyama T, Monden Y: **High frequency of p53 protein expression in thymic carcinoma but not in thymoma.** *Br J Cancer* 1997, **76**:1361-1366
13. Fukai I, Masaoka A, Hashimoto T, Yamakawa Y, Mizuno T, Tanamura O: **The distribution of epithelial membrane antigen in thymic epithelial neoplasms.** *Cancer* 1992, **70**:2077-2081
14. Tomita M, Matsuzaki Y, Onitsuka T: **Relationship between expression of cancer-related proteins and tumor invasiveness in thymoma.** *Eur J Cardiothorac Surg* 2002, **21**:596
15. Tomita M, Matsuzaki Y, Edagawa M, Maeda M, Shimizu T, Hara M, Onitsuka T: **Correlation between tumor angiogenesis and invasiveness in thymic epithelial tumors.** *J Thorac Cardiovasc Surg*
16. Masaoka A, Monden Y, Nakahara K, Tanioka T: **Follow-up study of thymomas with special reference to their clinical stages.** *Cancer* 1981, **48**:2485-2492
17. Masaoka A, Yamakawa Y, Fujii Y: **Well-differentiated thymic carcinoma: is it thymic carcinoma or not?** *J Thorac Cardiovasc Surg* 1999, **117**:628-630
18. Shimosato Y, Kameya T, Nagai K, Suemasu K: **Squamous cell carcinoma of the thymus. An analysis of eight cases.** *Am J Surg Pathol* 1977, **1**:109-121
19. Tsuchiya R, Koga K, Matsuno Y, Mukai K, Shimosato Y: **Thymic carcinoma: proposal for pathological TNM and staging.** *Pathol Int* 1994, **44**:505-512
20. Savino W, Durand D, Dardenne M: **Immunohistochemical evidence for the expression of the carcinoembryonic antigen by human thymic epithelial cells in vitro and in neoplastic conditions.** *Am J Pathol* 1985, **121**:418-425
21. Steeg PS, Bevilacqua G, Kooper L, Thorgeirsson UP, Talmadge JE, Littot LA, Sobel ME: **Evidence for a novel gene associated with low tumor metastatic potential.** *J Natl Cancer Inst* 1988, **80**:200-204
22. Fox SB, Gatter KC, Harris AL: **Tumour angiogenesis.** *J Pathol* 1996, **179**:232-237

Pre-publication history

The pre-publication history for this paper can be accessed here:

<http://www.biomedcentral.com/1471-2482/2/3/prepub>

Publish with **BioMed Central** and every scientist can read your work free of charge

"BioMedcentral will be the most significant development for disseminating the results of biomedical research in our lifetime."

Paul Nurse, Director-General, Imperial Cancer Research Fund

Publish with **BMC** and your research papers will be:

- available free of charge to the entire biomedical community
- peer reviewed and published immediately upon acceptance
- cited in PubMed and archived on PubMed Central
- yours - you keep the copyright

Submit your manuscript here:

<http://www.biomedcentral.com/manuscript/>



editorial@biomedcentral.com