

UC Irvine

UC Irvine Previously Published Works

Title

Clinical and pathological evidence for a frontal variant of Alzheimer disease.

Permalink

<https://escholarship.org/uc/item/78n319zs>

Journal

Archives of neurology, 56(10)

ISSN

0003-9942

Authors

Johnson, JK
Head, E
Kim, R
[et al.](#)

Publication Date

1999-10-01

DOI

10.1001/archneur.56.10.1233

Copyright Information

This work is made available under the terms of a Creative Commons Attribution License, available at <https://creativecommons.org/licenses/by/4.0/>

Peer reviewed

Clinical and Pathological Evidence for a Frontal Variant of Alzheimer Disease

Julene K. Johnson, PhD; Elizabeth Head, PhD; Ronald Kim, MD; Arnold Starr, MD; Carl W. Cotman, PhD

Objective: To evaluate the clinical and pathological features of a subgroup of patients with Alzheimer disease (AD) who exhibited early and disproportionately severe impairments on tests of frontal lobe functioning. We hypothesized that these patients would exhibit a greater degree of either neurofibrillary tangle (NFT) or senile plaque pathology in the frontal lobes than would patients with typical AD.

Design and Outcome Measures: We examined the neuropsychological profiles and senile plaque and NFT accumulation in the frontal, entorhinal, temporal, and parietal cortices in 3 patients with AD who exhibited disproportionate frontal impairments during early stages of dementia (frontal AD) and 3 matched patients with typical AD (typical AD).

Results: Compared with the typical AD group, the frontal AD group performed significantly worse on 2 tests of frontal lobe functioning and on the Wechsler

Adult Intelligence Scale–Revised Block Design test. No significant group differences were found on other tests. Analysis of brain tissue samples demonstrated that, despite comparable entorhinal, temporal, and parietal NFT loads, the frontal AD group showed a significantly higher NFT load in the frontal cortex than the typical AD group. Senile plaque pathology in the frontal and entorhinal cortices did not differentiate the 2 groups.

Conclusions: We identified a subgroup of patients with pathologically confirmed AD who presented in the early stages of dementia with disproportionate impairments on tests of frontal lobe functioning and had a greater-than-expected degree of NFT pathology in the frontal lobes, suggesting the existence of a frontal variant of AD that has distinctive clinical and pathological features.

Arch Neurol. 1999;56:1233-1239

ALZHEIMER DISEASE (AD) is a neurodegenerative disorder characterized by a progressive decline in cognition that affects multiple systems, such as memory, language, executive functions, and visuospatial skills. Throughout the course of the disease, a heterogeneous profile of preserved and impaired functions is observed, suggesting the involvement of selective cognitive systems or brain regions. This cognitive heterogeneity led researchers^{1,2} to postulate the existence of subgroups of patients with AD in the 1980s. That is, although most patients diagnosed with AD have multiple cognitive impairments, some patients have relatively prominent impairments in 1 cognitive domain. For example, prominent and early impairments in visuospatial skills³⁻⁸ and language^{5,9} have been documented in patients with histologically confirmed AD.

Although several studies have identified subgroups of patients with AD at the clinical level, only a few researchers have conducted clinicopathological studies of atypical cases. This is of particular importance because focal cognitive impairments are often associated with non-AD pathology.¹⁰ Faden and Townsend¹¹ first described a patient with cortical blindness who later developed dementia. At autopsy, this patient showed prominent atrophy in the occipital lobe that contained numerous cortical neuritic plaques suggestive of AD. Quantitative measures of pathology, however, were not done. Hof and colleagues^{12,13} later described a series of 14 patients with pathologically confirmed AD who presented clinically with severe visuospatial impairments referred to as Balint syndrome. These patients had a greater-than-expected degree of neurofibrillary tangle (NFT) and neuritic plaque pathology in the occipitoparietal and

From the Institute for Brain Aging and Dementia, University of California at Irvine.

PATIENTS AND METHODS

PATIENTS

We reviewed 63 recent, pathologically confirmed AD cases (Consortium to Establish a Registry for Alzheimer's Disease [CERAD] criteria²¹) from the UCI Alzheimer's Disease Research Center's Tissue Repository. Of these patients, 19 (30%) had a greater degree of NFT pathology in the frontal than in the entorhinal cortex. Based on this observation, we further investigated the pathological and clinical features of a subset of patients. From the 63 patients, we then selected 16 who had well-characterized clinic visits at the UCI Alzheimer's Disease Research Center during the mild stages of dementia (Mini-Mental State Examination²² score ≥ 18). When reviewing the neuropsychological profiles, a subset of 3 patients with disproportionately severe impairments on 2 tests of frontal lobe function (ie, Trail Making Test A and FAS fluency; frontal AD group) was observed. For purposes of comparison, we selected a second group of 3 patients with "typical" AD (typical AD group) who were matched for Mini-Mental State Examination score, educational level, and extent of NFT pathology in the entorhinal cortex, in an effort to control for disease severity. Demographic information is shown in **Table 1**, and both groups are described further in the next sections.

CLINICAL PROFILE

All patients were clinically evaluated at the UCI Alzheimer's Disease Research Center by a staff neurologist and neuropsychologist using standard clinical protocols (including CERAD tests) consisting of standard neurological, physical, and neuropsychological examinations; routine laboratory blood analysis; electrocardiogram; chest radiograph; family interviews; and neuroimaging (ie, magnetic resonance imaging and single photon emission computed tomography). No patients had a history of severe head injury, psychiatric disorders, or other neurological disorders.

A subset of neuropsychological tests from the standard clinical protocol was selected a priori (**Table 2**) to profile multiple cognitive abilities, including frontal lobe functioning, memory, visuospatial, and language skills. Measures of frontal lobe functioning included Trail Making Test A²³ and the Controlled Oral Word Association Test (FAS fluency).²⁴ Impairments on Trail Making Test A are common in patients with frontal lobe lesions^{23,25} and are also associated with disproportionate frontal hypometabolism.²⁶ In addition, impairments on letter fluency have also been found to correlate with frontal lobe damage.^{27,28} The CERAD Word List task²⁹ was used to measure short-term verbal memory. In addition, the 30-item version of the Boston Naming Test,³⁰ CERAD Animal Naming,²⁹ and the Wechsler Adult Intelligence Scale-Revised (WAIS-R) Vocabulary test³¹ were used to measure language abilities. The WAIS-R Digit Span task³¹ and the Symbol Digit Modalities Test³² were used to measure attention. The Kendrick Digit Copy task³³ was used to estimate psychomotor speed. Finally, the CERAD Constructional Praxis²⁹ and the WAIS-R Block Design³¹ tasks were used to profile visuospatial skills. All

tests were administered and scored according to standard protocols. Age- and education-adjusted norms were applied when available.

NEUROPATHOLOGICAL STUDIES

Informed consent for the brain autopsies, approved by the UCI institutional review board, was obtained from the patient or next of kin before death. All patients were diagnosed as having AD by an Alzheimer's Disease Research Center neuropathologist (R.K.) according to CERAD criteria.²¹ No patient showed cell loss, microvacuolation, or gliosis in layers II and III of the frontal cortex typical of frontotemporal dementia (FTD). In addition, there was no evidence of Lewy body or Pick body formation. Brain tissue samples were postfixed in either 4% paraformaldehyde or 10% buffered formalin. The 50- μ m-thick sections from the middle frontal gyrus (area 8), hippocampus with entorhinal cortex, inferoparietal cortex (area 7), temporal cortex (area 22), and occipital lobe (area 17) were prepared using a vibratome.

For β -amyloid immunostaining, free-floating tissue sections from each brain region were pretreated with 90% formic acid for 4 minutes, treated for 30 minutes with 3% hydrogen peroxide in 10% methanol to block endogenous peroxidase activity, and incubated overnight in polyclonal anti- β -amyloid (from B. J. Cummings at 1:500) at room temperature. For visualizing NFTs, adjacent sections were immunostained using the monoclonal anti-*PHF-1* (from S. Greenberg at 1:800). Standard immunohistochemical protocols were followed as previously described.³⁴

To quantify the extent of NFT and senile plaque pathology, image analysis techniques were used. Slides of the frontal, entorhinal, inferoparietal, and temporal cortices were analyzed without previous knowledge of diagnosis using procedures described by Cummings and Cotman.³⁴ Neurofibrillary tangle pathology staging was conducted using the method described by Braak and Braak.^{35,36} Sections of transentorhinal and entorhinal regions and hippocampus, inferoparietal, and occipital cortex were evaluated by 2 independent judges (E.H. and R.K.) who were unaware of the group assignments. Patients were assigned to 1 of 3 Braak and Braak stages: I/II (transentorhinal), III/IV (limbic), or V/VI (isocortical).

DATA ANALYSIS

A repeated-measures analysis of variance was used to compare the neuropsychological profiles and demographic information to determine group differences. A Scheffé test was used for all post hoc analyses. The frontal and typical AD groups were compared for differences in age, educational level, age of onset, disease duration, interval between the clinical evaluation and death, postmortem interval, and scores on the neuropsychological tests. The second analysis used independent *t* tests to determine whether measures of entorhinal, frontal, inferoparietal, and temporal NFT loads differed between the typical and frontal AD groups. In addition, we also conducted the same analysis to determine whether the β -amyloid loads differed in the frontal and entorhinal cortices. All statistical analyses were conducted using a software system (SAS for Windows; SAS Institute Inc, Cary, NC) and a 0.05 error level.

DEMOGRAPHICS

inferoparietal lobes. Other studies documented atypical distributions of pathology in patients with focal cognitive impairments involving language,¹⁴⁻¹⁷ visuospatial impairments,^{18,19} and praxis.²⁰ Except for the patients studied by Hof and colleagues, all of the clinicopathological studies listed previously involved only single patients. Therefore, it is necessary to conduct additional clinicopathological studies to help understand the manner in which AD evolves.

We observed a subset of patients with clinically diagnosed AD who presented in the mild stages of dementia with prominent frontal lobe impairments. On the basis of our review of the clinical and neuropathological features of patients with pathologically confirmed AD at the University of California at Irvine (UCI) Alzheimer's Disease Research Center's Tissue Repository, we hypothesized that patients with disproportionate impairments of frontal lobe functioning would exhibit a greater-than-expected degree of either NFT or neuritic plaque pathology in the frontal lobes.

Table 1. Patient Demographics*

	Alzheimer Disease Group	
	Typical (n = 3)	Frontal (n = 3)
Age of onset, y	64.7 ± 9.6	71.7 ± 8.1
Disease duration, y	6.7 ± 4.7	8.0 ± 2.0
Education, y	11.7 ± 1.5	13.3 ± 2.3
Men/women, No.	2/1	2/1
Evaluation to death interval, y	3.8 ± 1.9	4.8 ± 0.3
Postmortem interval, y	8.3 ± 6.9	4.2 ± 0.8

*Data are given as mean ± SD, unless otherwise indicated. No significant group differences were found ($P > .05$).

No significant differences ($P > .05$) in educational level, sex, age of onset, disease duration, interval between clinical evaluation and death, or postmortem interval were noted between the 2 groups. A repeated-measures analysis of variance with the neuropsychological results resulted in a nonsignificant main effect of disease group. However, the task × disease group interaction was significant ($F_{25,75} = 16.59$; $P < .001$), suggesting that some but not all tasks were performed differently by the 2 groups. Post hoc Scheffé test results indicated that significant group differences existed on Trail Making Test A, FAS fluency, and WAIS-R Block Design.

NEUROPSYCHOLOGICAL PROFILE

Mean scores on the neuropsychological measures for the typical and frontal AD groups are shown in Table 2. Compared with the typical AD group, the frontal AD group performed significantly worse on Trail Making Test A ($P = .002$) and FAS fluency ($P = .02$). Scores on Trail Making Test A for the frontal AD group ranged from 100 to 167 seconds for completion and did not overlap with the typical AD group, whose scores ranged from 47 to 69 seconds. Scores on Trail Making Test A obtained by the frontal AD group were greater than 3 SD below the norm for their age and educational level, reflecting a severe impairment. In contrast, scores obtained by the typical AD group ranged from normal to a mild impairment. The frontal AD group also consistently showed below-average performance on the FAS fluency; in contrast, all patients in the typical AD group performed within the

Table 2. Neuropsychological Test Results*

	Alzheimer Disease Group		P
	Typical	Frontal	
Mini-Mental State Examination	23.33 (20, 22, 28)	20.33 (18, 21, 22)	.33
Trail Making Test A (seconds to complete)	56.00 (47, 52, 69)	140.67 (100, 155, 167)	.002†
FAS fluency‡	40.67 (32, 45, 45)	19.00 (13, 17, 27)	.02†
WAIS-R Digit Span			
Forward digits	9.00 (8, 8, 11)	5.67 (4, 6, 7)	.08
Reverse digits	6.00 (4, 6, 8)	3.00 (2, 3, 4)	.17
Symbol Digit Modalities Test§	22.67 (11, 22, 35)	6.00 (0, 8, 10)	.14
CERAD Word List			
Trials 1-3 (total)	11.00 (5, 12, 16)	7.33 (4, 5, 13)	.22
5-min delayed recall	1.33 (0, 1, 3)	0.33 (0, 0, 1)	.33
Boston Naming Test (30-item version)	17.00 (10, 14, 27)	22.00 (12, 25, 29)	.87
CERAD Animal Naming	10.67 (8, 11, 13)	8.33 (2, 9, 14)	.21
WAIS-R Vocabulary (scaled score)	9.67 (8, 8, 13)	10.33 (7, 12, 12)	.96
CERAD Constructional Praxis	10.00 (9, 10, 11)	7.67 (7, 8, 8)	.06
WAIS-R Block Design (scaled score)	5.67 (5, 5, 7)	1.00 (1, 1, MD)	.01†
Kendrick Digit Copy¶	93.33 (80, 100, 100)	67.00 (43, 66, 92)	.29

*Scores are given as means (individual scores). WAIS-R indicates Wechsler Adult Intelligence Scale-Revised; CERAD, Consortium to Establish a Registry for Alzheimer's Disease; and MD, missing data.

†Significant group differences (analysis of variance, Scheffé post hoc adjustment, $P < .05$).

‡The number of words beginning with F, A, S in 1 minute.

§Written test of the number of symbol-number pairs in 90 seconds.

||The number of animals in 1 minute.

¶The number of numbers copied in 2 minutes.

normal range. Significant group differences were also found on the WAIS-R Block Design ($P = .01$). In contrast, no significant group differences ($P > .05$) were found on other neuropsychological tests.

NEUROPATHOLOGICAL STUDIES

Analysis of brain tissue samples from these patients demonstrated that, despite comparable entorhinal NFT loads, the frontal AD group showed a significantly higher NFT load ($t_4 = 14.3$; $P < .001$) in the frontal cortex than the typical AD group (**Figure 1**). In addition, there were no significant group differences in the degree of NFT pathology in the parietal ($t_4 < 1$; $P = .40$) or temporal ($t_4 < 1$; $P = .82$) cortices. **Table 3** represents the individual NFT “load” values for patients in the frontal and typical AD groups. Photomicrographs taken from the frontal and en-

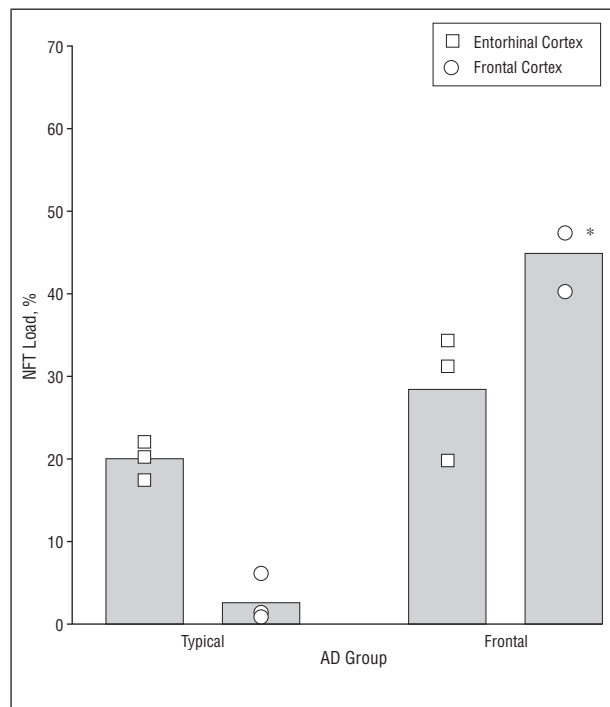


Figure 1. Neurofibrillary tangle (NFT) loads in the frontal cortex of patients in the frontal Alzheimer disease (AD) group are significantly higher than those in the typical AD group, despite similar entorhinal cortex loads. Bars indicate means for each group, and individual load values are represented; asterisk, 2 overlapping values; NFT load, proportion of area occupied by NFT. Note that maximal NFT burden for all 3 patients in the frontal AD group is in the frontal cortex.

torhinal regions of a representative patient in each group also highlight the differences in NFT pathology (**Figure 2**). In contrast, β -amyloid pathology in the frontal and entorhinal cortices did not significantly differ between the 2 groups ($t_4 < 1$; $P = .37$). Likewise, all patients in both groups fell into Braak and Braak stage V/VI.

COMMENT

In this study, we identified a subgroup of patients with pathologically confirmed AD who presented clinically with early and disproportionate frontal lobe impairments on neuropsychological tests and exhibited an unusually high degree of frontal tangle pathology at autopsy. This finding is similar to those of other studies^{12-15,18,19} that correlate focal clinical symptoms and atypical distributions of pathology in AD. Our results are also similar to those of Binetti and colleagues,³⁷ who identified 7 of 35 mildly demented patients with AD with severe impairments on frontal lobe tests. Binetti et al also found no significant differences on other neuropsychological tests.

The most distinctive clinical feature of patients with frontal AD in this study was the severe impairment on tests of frontal lobe functioning during the mild stages of dementia. That is, on 2 tests that specifically measured frontal lobe function, the frontal AD group performed 3 SD below the norm and significantly worse than the typical AD group. Using the same criteria outlined in this study, we determined that 14% of patients with clinically diagnosed AD who presented to our clinic in the mild stages of dementia show a similar pattern of cognitive deficits. Compared with the typical AD group, the frontal AD group also performed significantly worse on the WAIS-R Block Design task, a finding that is typically associated with parietal damage.^{38,39} However, the WAIS-R Block Design test not only involves visuospatial processing but also the sequencing of blocks into specific patterns. Patients with frontal lobe damage can also exhibit impairments on the Block Design task due to behavioral abnormalities such as inattention to details, impairments in planning, and impulsivity.⁴⁰ Thus, the impairment on Block Design may not reflect a visuospatial impairment per se.

Despite severe impairments on the tests of frontal lobe functioning, the performance of the frontal AD group on other neuropsychological tests was similar to the typical AD group. This suggests that the severe frontal impairment in these patients was the primary distinguish-

Table 3. Neurofibrillary Tangle (NFT) “Load” Values for the 6 Patients*

Area	Alzheimer Disease Group					
	Frontal, Patient No.			Typical, Patient No.		
	1	2	3	1	2	3
Frontal (area 8)	47.30	47.40	40.20	6.10	0.64	1.16
Entorhinal	34.30	19.80	31.10	20.10	17.36	21.92
Temporal (area 22)	2.62	1.67	0.75	2.10	0.30	2.05
Parietal (area 7)	1.18	1.61	0.29	3.50	0.27	2.36

*The NFT load represents the proportion of area occupied by NFT. Note that the maximal NFT burden for all 3 patients in the frontal Alzheimer disease group is in the frontal cortex.

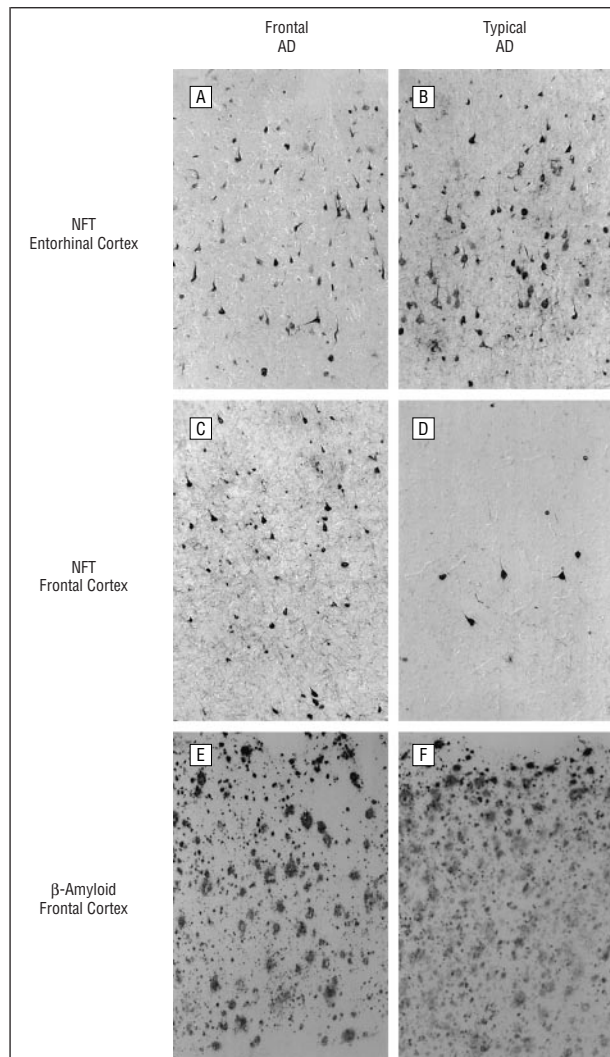


Figure 2. Differences in neurofibrillary tangle (NFT) and β -amyloid in patients in the frontal (A, C, and E) and typical (B, D, and F) Alzheimer disease (AD) groups. Entorhinal NFT pathology is similar (A and B), whereas frontal lobe NFT is extensive in the frontal AD group (C) compared with the typical AD group (D). Frontal NFT pathology in the frontal AD group is greater than in the entorhinal cortex, illustrating the shift in NFT pathology. β -Amyloid is similar in the 2 groups (E and F). Neurofibrillary tangles were visualized using anti-PHF, and β -amyloid was visualized using anti-A β 1-42 (original magnification $\times 100$).

ing neuropsychological feature on top of an otherwise typical AD profile. Although patients with AD often exhibit impairments on tests of frontal lobe functioning, the impairments observed in the frontal AD group were even more pronounced than usual. It is not yet possible to determine whether the frontal lobe impairments represented the first changes in cognition.

Patients with frontal AD share some clinical features with other frontal dementia syndromes associated with non-AD pathology. For example, patients with FTD or frontal lobe dementia also exhibit significant impairments on tests of frontal lobe functioning.^{41,42} These frontal lobe syndromes, however, are typically distinguished from AD by a lack of memory and visuospatial impairments in the early stages.⁴³ Clearly, the frontal AD group in the present study exhibited memory and visuospatial impairments that were similar to the

typical AD group. In addition, although the average age at onset tends to be younger in FTD, the frontal AD group had a similar age at onset to the typical AD group. Thus, although the frontal AD group exhibits some clinical features that are similar to other frontal lobe dementias, the clinical profile of the frontal AD group is more similar to that of AD.

The second distinguishing feature between the typical and frontal AD groups was the presence of an approximately 10-fold higher NFT load in the frontal cortex in the frontal AD group. Increased tangle pathology in the frontal AD group was not a reflection of disease severity; both groups were similar in terms of hippocampal NFT and Braak and Braak stage. In addition, the frontal cortex in patients with frontal AD seems to be the most severely affected of the 5 brain regions sampled, suggesting an anterior shift in NFT pathology. On the other hand, patients with typical AD showed maximal NFT pathology in the entorhinal cortex. In contrast, the degree of β -amyloid accumulation did not distinguish the groups. The frontal AD group also lacked the superficial cortical microvacuolar changes, neuronal loss, or gliosis characteristic of FTD. This dissociation strongly suggests a role for the abnormal phosphorylation of tau and the formation of NFTs in the pathogenesis of frontal lobe dysfunction in the frontal AD group. However, there may be other pathological features that contribute to frontal lobe dysfunction, and we cannot yet rule out this possibility.

The association between NFT pathology and neuropsychological deficits is consistent with other studies reporting a correlation between the severity of dementia and NFT and plaque pathology in AD.⁴⁴⁻⁴⁶ However, global tests of cognitive function such as the Mini-Mental State Examination are typically used in these analyses. Our results and those of recent studies^{47,48} highlight the value of using specific neuropsychological tasks to test the function of specific cortical circuits.

The reasons for the behavioral and pathological heterogeneity in AD are not yet well understood. However, several researchers^{1,2,49} hypothesized that the clinical pattern is a result of the type, location, and degree of pathology. More specifically, focal impairments may indicate specific disruption of neural circuits that subservise specific cognitive functions. Especially during the early stages of AD, the neuropathology is typically restricted to specific brain regions or networks.³⁵ Neurofibrillary lesions in AD begin in the limbic and temporoparietal regions and only later progress to the frontal and occipital cortices.³⁵ This predictable sequence is thought to occur with minimal individual variation.³⁶ Therefore, any deviation from this projected sequence of pathological lesions is significant and may help clarify the basis for atypical presentations of AD.

In this study, an increase in tangles but not plaques was observed in the frontal AD group. This finding suggests that tangles, rather than plaques, may contribute to the atypical clinical presentation of the frontal AD group. In the other subgroups of AD described previously, both plaques and tangles were increased in the

regions of maximal pathology.^{12-15,18,19} It is possible that the focal deficits are indicative of a selective, early, and prominent vulnerability of certain brain regions that are typically thought to acquire pathology at a later stage in AD. In the scenario of the frontal AD patients, the disproportionate frontal NFT pathology may reflect a relative vulnerability of the frontal lobes, namely tau pathology. Thus, 2 possibilities exist: (1) NFT pathology has an earlier onset in patients with frontal AD, or (2) NFT pathology accumulates at a faster rate in patients with frontal AD. In addition, possible genetic contributions in the frontal AD group may be consistent with a recent report of tau mutations underlying a type of FTD.⁵⁰⁻⁵⁴

This study provides evidence for the presence of a subgroup of patients with AD who present with both early and prominent frontal lobe impairments and have unusually high degrees of frontal tangle pathology at autopsy. These findings suggest the existence of a frontal variant of AD that has distinctive clinical and pathological features. Although most studies characterizing the clinical and pathological features of patients with atypical AD involve only case studies, this study should be expanded with additional patients. Future studies should also attempt to investigate frontal lobe functioning with more specific tests to better characterize and test specific frontal circuits involved. It will also be important to identify patients with frontal AD to address potential clinical management issues; frontal lobe impairments are often associated with specific behavioral problems that require specialized patient management. Identification of a frontal variant of AD adds to the list of conditions that must be considered in the differential diagnosis of prominent frontal lobe dysfunction. Finally, if the cause of these forms of dementia is different from that of typical AD, this would suggest that interventions may also be different.

Accepted for publication January 22, 1999.

This study was supported by grants T32-AG00096, AG-05142, and AG-00538 from the National Institute on Aging, Bethesda, Md.

We thank Masuru H. Oshita, Institute for Brain Aging and Dementia, for help in tissue preparation and Robert Newcomb, PhD, University of California at Irvine Statistical Consulting Center, for statistical advice.

Reprints: Julene K. Johnson, PhD, Institute for Brain Aging and Dementia, University of California at Irvine, 1100 Medical Plaza, Irvine, CA 92697-4285 (e-mail: jkj@uci.edu).

REFERENCES

- Martin A, Brouwers P, Lalonde F, Cox C, Teleska P, Fedio P. Towards a behavioral typology of Alzheimer's patients. *J Clin Exp Neuropsychol*. 1986;8:594-610.
- Becker JT, Huff FJ, Nebes RD, Holland A, Boller F. Neuropsychological function in Alzheimer's disease. *Arch Neurol*. 1988;45:263-268.
- Cogan DG. Visual disturbances with focal progressive dementing disease. *Am J Ophthalmol*. 1985;100:68-72.
- Crystal H, Horoupian DS, Katzman R, Jotkowitz S. Biopsy-proved Alzheimer disease presenting as a right parietal lobe syndrome. *Ann Neurol*. 1981;12:186-188.
- Price BH, Gurvit H, Weintraub S, Geula C, Leimkuhler E, Mesulam M. Neuropsychological patterns and language deficits in 20 consecutive cases of autopsy-confirmed Alzheimer's disease. *Arch Neurol*. 1993;50:931-937.
- Neary D, Snowden JS, Bowen DM, et al. Neuropsychological syndromes in presenile dementia due to cerebral atrophy. *J Neurol Neurosurg Psychiatry*. 1986;49:163-174.
- Berthier ML, Leiguarda R, Starkstein SE, Sevlever G, Taratuto AL. Alzheimer's disease in a patient with posterior cortical atrophy. *J Neurol Neurosurg Psychiatry*. 1990;54:1110-1111.
- Kaida K, Takeda K, Nagata N, Kamakura K. Alzheimer's disease with asymmetric parietal lobe atrophy: a case report. *J Neurol Sci*. 1998;160:96-99.
- Morris JC, Cole M, Banker BQ, Wright D. Hereditary dysphasic dementia and the Pick-Alzheimer spectrum. *Ann Neurol*. 1984;16:455-466.
- Black SE. Focal cortical atrophy syndromes. *Brain Cogn*. 1996;31:188-229.
- Faden MAJ, Townsend JJ. Myoclonus in Alzheimer disease: a confusing sign. *Arch Neurol*. 1976;33:278-280.
- Hof PR, Bouras C, Constantinidis J, Morrison, JH. Balint's syndrome in Alzheimer's disease: specific disruption of the occipito-parietal visual pathway. *Brain Res*. 1989;493:368-375.
- Hof PR, Bouras C, Constantinidis J, Morrison JH. Selective disconnection of specific visual association pathways in cases of Alzheimer's disease presenting with Balint's syndrome. *J Neuropathol Exp Neurol*. 1990;49:168-184.
- Green J, Morris JC, Sandon J, McKeel DW, Miller JW. Progressive aphasia: a precursor of global dementia? *Neurology*. 1990;40:423-429.
- Greene JDW, Patterson K, Xuereb J, Hodges JR. Alzheimer disease and nonfluent progressive aphasia. *Arch Neurol*. 1996;53:1072-1078.
- Pogacar S, Williams RS. Alzheimer's disease presenting as slowly progressive aphasia. *Rhode Island Med J*. 1984;67:181-185.
- Kempler D, Metter EJ, Riege WH, et al. Slowly progressive aphasia with language memory and PET data. *J Neurol Neurosurg Psychiatry*. 1990;53:987-993.
- Hof PR, Bouras C. Object recognition deficit in Alzheimer's disease: possible disconnection of the occipito-temporal component of the visual system. *Neurosci Lett*. 1991;122:53-56.
- Levine DN, Lee JM, Fisher CM. The visual variant of Alzheimer's disease. *Neurology*. 1993;43:305-313.
- Jagust WJ, Davies P, Tiller-Borcich JK, Reed BR. Focal Alzheimer's disease. *Neurology*. 1990;40:14-19.
- Mirra SS, Heyman A, McKeel D, et al. The Consortium to Establish a Registry for Alzheimer's Disease (CERAD), II: standardization of the neuropathologic assessment of Alzheimer's disease. *Neurology*. 1991;41:479-486.
- Folstein MF, Folstein SE, McHugh PR. Mini-mental state: a practical method for grading the cognitive status of patients for the clinician. *J Psychiatry Res*. 1975;12:189-198.
- Reitan RM. Validity of the Trail Making Test as an indicator of organic brain damage. *Percept Mot Skills*. 1958;8:271-276.
- Spreen O, Benton AL. *Neurosensory Center Comprehensive Examination for Aphasia (NCCEA)*. Rev ed. Victoria, British Columbia: Neuropsychology Laboratory, University of Victoria; 1977.
- Picton PW, Stuss DT, Marshall KC. Attention and the brain. In: Friedman SL, Klivington KA, Petersen RW, eds. *The Brain, Cognition, and Education*. New York, NY: Academic Press; 1986:19-79.
- Haxby JV, Crady CL, Koss E, et al. Heterogeneous anterior-posterior metabolic patterns in dementia of the Alzheimer type. *Neurology*. 1988;38:1853-1863.
- Parks RW, Lowenstein DA, Dodrill KL, et al. Cerebral metabolic effects of a verbal fluency test: a PET scan study. *J Clin Exp Neuropsychol*. 1988;10:565-575.
- Perret E. The left frontal lobe of man and the suppression of habitual responses in verbal categorical behavior. *Neuropsychologia*. 1974;12:323-330.
- Morris JC, Heyman A, Mohs RC, et al. The Consortium to Establish a Registry for Alzheimer's Disease (CERAD), I: clinical and neuropsychological assessment of Alzheimer's disease. *Neurology*. 1989;39:1159-1165.
- Kaplan E, Goodglass H, Weintraub S. Boston Naming Test. Philadelphia, Pa: Lea & Febiger; 1983.
- Wechsler D. *Wechsler Adult Intelligence Scale-Revised*. New York, NY: Harcourt Brace Jovanovich; 1981.
- Smith A. *Symbol Digit Modalities Test (SDMT)*. Rev ed. Los Angeles, Calif: Western Psychological Services; 1982.
- Kendrick DC. *Kendrick Cognitive Tests for the Elderly*. Windsor, Berkshire, England: NFER-Nelson; 1985.
- Cummings BJ, Cotman CW. Image analysis of β -amyloid load in Alzheimer's disease and relation to dementia severity. *Lancet*. 1995;346:1524-1528.
- Braak H, Braak E. Neuropathological staging of Alzheimer-related changes. *Acta Neuropathol*. 1991;82:239-259.
- Braak H, Braak E. Staging of Alzheimer's disease-related neurofibrillary changes. *Neurobiol Aging*. 1995;16:271-284.

37. Binetti G, Mangi E, Padovani A, Cappa SF, Bianchetti A, Trabucchi M. Executive dysfunction in early Alzheimer's disease. *J Neurol Neurosurg Psychiatry*. 1996; 60:91-93.
38. Warrington EK, James M, Maciejewski C. The WAIS as a lateralizing and localizing diagnostic instrument. *Neuropsychologia*. 1986;24:223-239.
39. Grossman M. Drawing deficits in brain damaged patients' freehand pictures. *Brain Cogn*. 1988;8:189-205.
40. Johanson AM, Gustafson L, Risberg J. Behavioural observations during performance of the WAIS Block Design Test related to abnormalities of regional cerebral blood flow in organic dementia. *J Clin Exp Neuropsychol*. 1986;8:201-209.
41. Panchana NA, Boone KB, Miller BL, Cummings JL, Berman N. Comparison of neuropsychological functioning in Alzheimer's disease and frontotemporal dementia. *J Int Neuropsychol Soc*. 1996;2:505-510.
42. Mendez MF, Cherrier M, Perryman KM, Pachana N, Miller BL, Cummings JL. Frontotemporal dementia versus Alzheimer's disease. *Neurology*. 1996;47:1189-1194.
43. Knopman DS, Mastric AR, Frey WH, Sung JH, Rustan T. Dementia lacking distinctive histologic features: a common non-Alzheimer degenerative dementia. *Neurology*. 1990;40:251-256.
44. Arriagada PV, Growdon JH, Hedley-Whyte ET, Hyman BT. Neurofibrillary tangles but not senile plaques parallel duration and severity of Alzheimer's disease. *Neurology*. 1992;42:631-639.
45. Gomez-Isla T, Price J, McKeel D, Morris J, Growdon J, Hyman B. Profound loss of layer II entorhinal cortex neurons occurs in very mild Alzheimer's disease. *J Neurosci*. 1996;16:4491-4500.
46. Hyman BT, Marzloff K, Arriagada PV. The lack of accumulation of senile plaque or amyloid burden in Alzheimer's disease suggests a dynamic balance between amyloid deposition and resolution. *J Neuropathol Exp Neurol*. 1993;52:594-600.
47. Kanne SM, Balota DA, Storandt M, McKeel DW Jr, Morris JC. Relating anatomy to function in Alzheimer's disease: neuropsychological profiles predict regional neuropathology 5 years later. *Neurology*. 1998;50:979-985.
48. Neilson KA, Cummings BJ, Cotman CW. Constructional praxis in Alzheimer's disease correlates with neuritic neuropathology in occipital cortex. *Brain Res*. 1996; 741:284-293.
49. Damasio AR, van Hoesen GW, Hyman BT. Reflections of the selectivity of neuropathological changes in Alzheimer's disease. In: Schwartz MF, ed. *Modular Deficits in Alzheimer-Type Dementia*. Cambridge, Mass: MIT Press; 1990:83-100.
50. Basun H, Almkvist O, Axelman K, et al. Clinical characteristics of a chromosome 17-linked rapidly progressive familial frontotemporal dementia. *Arch Neurol*. 1997; 54:539-544.
51. Baker M, Kwok JBJ, Kucera S, et al. Localization of frontotemporal dementia with Parkinsonism in an Australian kindred to chromosome 17q21-22. *Ann Neurol*. 1997;42:794-798.
52. Clark LN, Poorkaj P, Wszolek Z, et al. Pathogenic implications of mutations in the tau gene in pallido-ponto-nigral degeneration and related neurodegenerative disorders linked to chromosome 17. *Proc Natl Acad Sci U S A*. 1998;22:13103-13107.
53. Hutton M, Lendon CL, Rizzu P, et al. Association of missense and 5'-splice-site mutations in tau with the inherited dementia FTDP-17. *Nature*. 1998;393:702-705.
54. Spillantini MG, Goedert M. Tau protein pathology in neurodegenerative diseases. *Trends Neurosci*. 1998;21:428-433.