

Clinical and Vascular Outcome in Internal Carotid Artery Versus Middle Cerebral Artery Occlusions After Intravenous Tissue Plasminogen Activator

Italo Linfante, MD; Rafael H. Llinas, MD; Magdy Selim, MD, PhD; Claudia Chaves, MD; Sandeep Kumar, MD; Robert A. Parker, ScD; Louis R. Caplan, MD; Gottfried Schlaug, MD, PhD

Background and Purpose—Early reperfusion is a predictor of good outcome in acute ischemic stroke. We investigated whether middle cerebral artery (MCA) occlusions have a better clinical outcome and proportion of recanalization compared with internal carotid artery (ICA) occlusion after standard treatment with intravenous (IV) tissue plasminogen activator (tPA).

Patients—In a retrospective analysis of our prospective stroke database between January 7, 1998, and January 30, 2002, we identified 36 consecutive patients who were treated with IV tPA within 3 hours after symptom onset of a stroke in the distribution of a documented ICA or MCA occlusion. The National Institutes of Health Stroke Scale (NIHSS) score was recorded before tPA, at 24 hours, 3 days, and 3 months after stroke. Three-month outcome was recorded by modified Rankin scale. Magnetic resonance angiography or computed tomographic angiography was obtained before tPA. The presence of recanalization was assessed by transcranial Doppler and/or magnetic resonance angiography within 3 days after stroke onset.

Results—Nineteen patients had MCA occlusion, and 17 had ICA-plus-MCA occlusion before tPA. Although there was no difference in age and NIHSS at day 0 between the 2 groups, the MCA group had a lower day 3 NIHSS score compared with the ICA group ($P=0.006$) in an ANCOVA. In addition, patients who had a MCA occlusion had lower day 1 and 3 NIHSS scores compared with the ICA group ($P=0.04$ and $P=0.03$, respectively; Wilcoxon rank sum). Similarly, NIHSS was significantly lower in patients who recanalized on days 1 and 3 ($P=0.004$ and $P=0.003$ respectively, Wilcoxon rank sum). When we adjusted for NIHSS score at day 0 in an ANCOVA, the adjusted mean was lower in the group that recanalized compared with the group that did not recanalize ($P<0.001$). There was a significant difference between the proportion of recanalization in the MCA group (15 of 17 recanalized, 88%) at 3 days after tPA compared with that of the ICA group (5 of 16 recanalized, 31%; $P=0.001$, Fisher exact test). The 3-month modified Rankin scale was not different between the 2 groups.

Conclusions—Despite comparable age and NIHSS scores before IV tPA, MCA occlusions have lower day 1 and 3 NIHSS scores and higher proportion of recanalization compared with ICA occlusions. A combined IV/intra-arterial or mechanical thrombolysis may be needed to achieve early recanalization in ICA occlusions. (*Stroke*. 2002;33:2066-2071.)

Key Words: carotid artery, internal ■ computed tomography ■ magnetic resonance imaging
■ middle cerebral artery ■ stroke ■ thrombolysis ■ tissue plasminogen activator

Early reperfusion, either spontaneous or induced by thrombolysis, is a predictor of good outcome presumably by saving tissue at risk of infarction.¹⁻¹⁰ Previous observations preceding the tissue plasminogen activator (tPA) National Institute of Neurological Disorders and Stroke (NINDS) trial¹ have shown that internal carotid artery (ICA) occlusions may be more resistant than middle cerebral artery (MCA) occlusions to intravenous (IV) tPA administered within 6 to 8 hours after symptom onset.¹¹⁻¹⁵ There are no

overall differences in stroke severity between patients with an isolated MCA occlusion and those with ICA-plus-MCA occlusion with regard to their National Institutes of Health Stroke Scale (NIHSS) score before tPA.¹⁶ Currently in most centers, all acute MCA syndromes are treated with a standard IV tPA protocol, regardless of whether they have an isolated MCA occlusion or an ICA-plus-MCA occlusion. Magnetic resonance angiography (MRA), computed tomographic angiography (CTA), and transcranial Doppler (TCD) may be

Received January 16, 2002; final revision received March 20, 2002; accepted April 12, 2002.

From the Department of Neurology (I.L., R.H.L., C.C., S.K., L.R.C., G.S.) and Biometrics Center (R.A.P.), Beth Israel Deaconess Medical Center, Boston, Mass.

Correspondence to Italo Linfante, MD, Department of Neurology, Division of Cerebrovascular Diseases, Beth Israel Deaconess Medical Center, East Campus DA 779, 330 Brookline Ave, Boston, MA 02115. E-mail ilinfant@caregroup.harvard.edu

© 2002 American Heart Association, Inc.

Stroke is available at <http://www.strokeaha.org>

DOI: 10.1161/01.STR.0000021001.18101.A5

obtained within the time constraint of standard tPA treatment and can show the arterial occlusion responsible for the acute symptoms.^{16–23} Because several authors have shown that intra-arterial (IA) thrombolysis can achieve early recanalization,^{24–28} it would be valuable to obtain data on arterial occlusions that may be resistant to standard IV tPA protocol. In the present study, we tested the hypothesis that clinical outcome is different in ICA versus MCA occlusions after IV tPA within 3 hours after symptom onset. In addition, to evaluate whether the difference in clinical outcome is due to the presence of recanalization, we compared NIHSS scores of patients who recanalized versus those who did not recanalize, regardless of the type of their pre-tPA arterial occlusion.

Patients and Methods

Clinical Evaluation

Patients were identified in a retrospective analysis of a prospective stroke database of the Beth Israel Deaconess Medical Center from January 7, 1998, to January 30, 2002. We selected consecutive patients who were treated with IV tPA within 3 hours after symptom onset of a stroke in the distribution of an imaging-documented stenosis or occlusion of the ICA plus MCA or of the MCA alone. The onset of the stroke was taken from the time patients were last seen at their baseline neurological status. Each patient was evaluated acutely by a stroke fellow (I.L., R.H.L., M.S., or S.K.) and a stroke attending physician (I.L., G.S., or L.R.C.). As outcome measures, we used the NIHSS and the modified Rankin scale (mRs) scores. The NIHSS score was recorded by a clinician certified in the administration of the scale before the administration of tPA, 24 hours and 3 days after the initial evaluation, and at the 3-month follow-up visit. The mRs score was also recorded at the 3-month follow-up visit.¹ The treating physicians in all cases were the stroke fellows. Patients received 0.9 mg/kg of IV tPA according to the NINDS guidelines.¹ Vital signs and patient clinical status were managed according to the American Heart Association guidelines for the use of IV tPA.²⁹

Imaging

MRI studies were performed on a Siemens Medical Systems Vision 1.5 scanner. Pulse sequences and typical parameters for diffusion-weighted imaging (DWI), T₂-weighted imaging, susceptibility-weighted imaging, perfusion-weighted imaging (PWI), and MRA used for these studies have been described in detail elsewhere.³⁰

Computed tomography (CT)/CTA was performed on a GE light-speed multidetector helical scanner. Scanning parameters were 120 kV and 240 mA, with a 512×512 image matrix size and a 25-cm acquisition field of view. A conventional nonhelical axial study was obtained first with a contiguous 3-mm section from the foramen magnum to the circle of Willis. Five-millimeter sections were then obtained to the vertex. CTA was reconstructed from the helical acquisitions at a 1-mm interval onto a 512×512 matrix after injection of contrast medium as per standard protocol. CT angiograms were reconstructed by multiprojection volume reconstruction or maximum intensity projection algorithms.

TCD was performed using an EME-Nicolet TC 4040 with a 2-MHz hand-held probe. Complete insonation of the intracranial vessels was obtained according to the technique described by Aaslid et al.³¹

Imaging study before thrombolysis included either MRI (DWI, T₂-weighted imaging, susceptibility-weighted imaging, MRA, or PWI) or CT scan with CTA (CT/CTA). A CT/CTA was used in patients who had contraindications for MRI or for whom the MRI scanner was not readily available at the time of the acute evaluation. The presence of arterial occlusion before tPA was assessed by MRA or CTA. The presence of recanalization after tPA was assessed by TCD, MRA, or CTA between 24 hours and 3 days after symptom onset.

TABLE 1. Demographics and Pre-tPA Clinical Features (n=36)

Age (median, mean±SD)	80, 76±14 (range 41 to 98 years of age)
Sex	16 men, 20 women
Race	White
Hypertension	30 (83%)
Atrial fibrillation	12 (33%)
Diabetes	14 (39%)
CAD	26 (72%)
NIHSS pre-tPA	18±5 (7–32)
Stroke subtype	
Cardioembolic	13 (36%)
Large vessels	22 (61%)
Undetermined	1
Vessel occlusion	
M1 or M2	19 (53%)
ICA/MCA	17 (47%)
Imaging pre-tPA	
MRI/MRA	27 (75%)
CT/CTA	9 (25%)

CAD indicates coronary artery disease.

Assessment of Arterial Lesion

The presence of arterial stenosis/occlusion or patency before and after tPA were adjudicated and recorded by 3 observers (L.R.C., C.C., G.S.). An artery was classified as occluded or severely stenotic only if there was no signal detected by either MRA or CTA. For the grading of a normal, stenotic, or occluded vessel on TCD, the adjudicator followed the parameters described by Demchuk et al.³² After tPA the adjudicators reported a vessel as not recanalized if no signal was detected by either MRA or CTA and partial or completely recanalized if a signal was detected on MRA or CTA.

Statistical Analysis

Data are summarized as mean±SD. Parameter estimates from regression models, including the ANCOVA, are given as estimate±SE of the estimate. Preliminary analyses compared results between groups using the Wilcoxon rank sum test to avoid assumptions of normality. Although there were no significant differences between groups on the baseline NIHSS scores, we also used an ANCOVA to assess whether the NIHSS score on day 3 was significantly different between groups (ICA versus MCA, recanalized versus nonrecanalized) adjusting for the baseline NIHSS score, and allowing for different regression slopes between NIHSS scores on day 3 and day 0 for the 2 groups when necessary. The Fisher exact test was used to compare the proportion of recanalization between ICA and MCA occlusions. All tests were performed using SAS version 8.02 (SAS Institute, Inc).

Results

Patients

Between July 1, 1998, and January 30, 2002, 47 patients with ischemic stroke were treated with tPA in our center. Thirty-six consecutive patients were treated with IV tPA within 3 hours after onset of a stroke secondary to a documented stenosis or occlusion of the ICA plus MCA or of the MCA alone. The demographics, risk factors, and stroke subtypes for the 36 patients are summarized in Table 1. Nineteen patients had either M₁ or M₂ occlusions and 17 had ICA-plus-MCA occlusions before tPA. There was no significant difference between the 2 groups for age, NIHSS score, and time from

TABLE 2. Time Parameters (Minutes)

	Time From Symptom Onset to tPA		
	All Patients (n=36)	MCA (n=19)	ICA/MCA (n=17)
	135±38	135±36	136±40
MRI (n=27) 13 MCA; 14 ICA/MCA	128±40	127±41	130±39
CT (n=9) 6 MCA; 3 ICA/MCA	148±33	147±28	148±51

Differences are not statistically significant.

symptom onset to tPA bolus before tPA between the ICA and the MCA groups and between the MRI and CT groups (Table 2).

Imaging

Magnetic Resonance Imaging

Twenty-seven patients had a multisequence MRI protocol. In all patients who had MRI before tPA, DWI and PWI showed signal changes in the area of distribution of the occluded artery documented by MRA acquired within the same session. A large DWI/PWI mismatch (PWI>DWI) was detected in all patients with the exception of 2 in whom the PWI were not analyzable. MRA before tPA showed absence of signal in the M₁ or M₂ segment of the MCA in 13 patients. Fourteen patients showed no signal in the intracranial ICA plus ipsilateral MCA. In these patients, subsequent neck MRA showed severe stenosis or occlusion of the ICA extracranially as well. A follow-up imaging study at 3 days (MRI or CT) showed an ischemic stroke in all patients in the vascular distribution expected by the initial DWI lesion and by the vascular lesion on MRA or CTA.

CT Scanning

Nine patients had CT/CTA before tPA. The occluded vessel on CTA corresponded with the patient's acute symptoms. Early ischemic changes were detected on CT in 4 of these 9 patients. Six patients did not show any contrast in M₁ or M₂ and M₃ in the intracranial ICA plus ipsilateral MCA. In the patients with intracranial ICA occlusion, a subsequent neck MRA or carotid Doppler showed severe stenosis or occlusion of the extracranial ICA as well.

Outcome

Overall, 11 patients had a favorable outcome at 3 months follow-up (mRs score ≤2), and 5 were not assessed. The mean NIHSS score at 3 days for all 36 patients was 9. We had 11 asymptomatic hemorrhages on follow-up study and 2 symptomatic. Ten patients died within the 3-month follow-up. Six of these deaths were of neurological causes (1 MCA and 5 ICA) due to complications of large cerebral infarctions and of intracranial hemorrhage. Four patients in the MCA group died of non-neurological causes. Three had known severe coronary artery disease and died of a myocardial infarction before the 3-month follow-up visit. One patient died of complications from metastasis of a previously undiagnosed adenocarcinoma of the proximal colon.

NIHSS scores were similar at baseline for both the MCA and ICA groups (16.79±4.54 points versus 18.75±5.67 points; $P=0.46$), but significantly lower for the MCA group on days 1 and 3 (day 1, 8.06±4.96 versus 14.29±8.28,

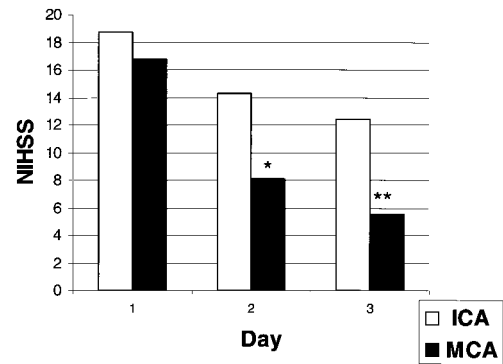


Figure 1. Comparison of NIHSS scores at days 1 (pre-tPA), 2, and 3 after tPA in patients with ICA-plus-MCA occlusion (□) vs patients with isolated MCA occlusion (■). * $P=0.04$; ** $P=0.03$ (Wilcoxon rank sum).

$P=0.04$; day 3, 5.53±4.67 versus 12.47±8.77, $P=0.03$) (Figure 1). Although the difference in NIHSS score at day 0 was not statistically significant, we also used an ANCOVA, comparing day 3 values after adjusting for baseline NIHSS score and group. We found that there was a statistically significant difference in the regression of the day 3 NIHSS score on the day 0 NIHSS score with a much steeper slope for ICA patients (regression coefficients±SE were 0.44±0.23 [MCA] versus 1.24±0.24 [ICA]; $P=0.03$). The NIHSS score for the ICA group was 5.28±1.78 (mean±SE) higher than for the MCA group ($P=0.006$).

NIHSS scores were similar at baseline for the group that subsequently recanalized and the group that did not (16.48±4.36 versus 19.40±5.78, $P=0.19$), but significantly lower for the group of patients that recanalized on days 1 and 3 (7.70±4.96 versus 17.00±7.23 [day 1], $P=0.004$; 5.40±4.66 versus 15.00±7.91 [day 3], $P=0.003$) (Figure 2). Although the difference in NIHSS score at day 0 was not statistically significant, we also used an ANCOVA, comparing day 3 values after adjusting for baseline NIHSS score and group. We found that there was some evidence for differences in the regression of the day 3 NIHSS score on the day 0 NIHSS score with a much steeper slope for patients without recanalization, but the difference was not statistically significant (regression coefficients, 0.48±0.22 [recanalized pa-

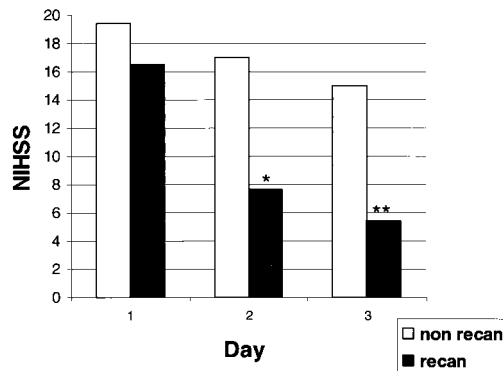


Figure 2. Comparison of NIHSS scores at days 1 (pre-tPA), 2, and 3 after tPA in patients who recanalized (■) vs patients who did not recanalize (□). * $P=0.004$; ** $P=0.003$ (Wilcoxon rank sum).

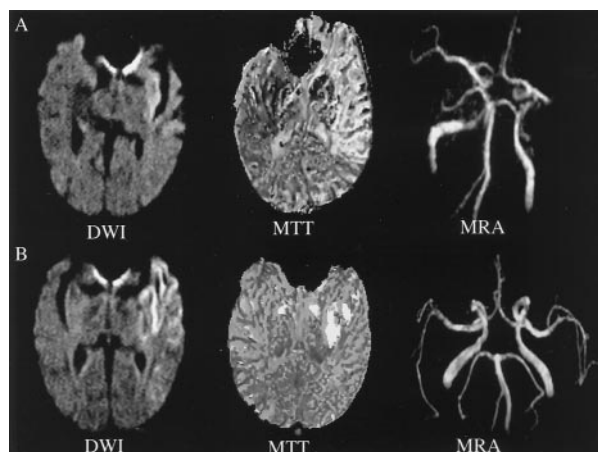


Figure 3. Case example of 73-year-old man with acute onset of left hemispheric syndrome (NIHSS score 21). A, MRI shows hyperintensity in the left insular cortex on DWI and a large area of prolonged mean transit time (MTT) on PWI in the distribution of the left MCA. MRA shows a left M₁ occlusion. He was treated with 0.9 mg/kg IV tPA 2 hours and 30 minutes after symptom onset. B, On MRI obtained 24 hours after symptom onset, DWI shows a small growth of the initial lesion and that the area of prolonged MTT has almost normalized and there is reperfusion in the M₁ segment on MRA with visualization of both M₂s. His NIHSS score was 6 at 3 days and 2 at 1 month.

tients] versus 1.12 ± 0.26 [patients who did not recanalize]; $P=0.07$). Thus, we assumed a common slope for both groups in the ANCOVA, so that the adjusted mean is 7.36 ± 1.87 higher in the group without recanalization compared with the group with recanalization ($P<0.001$). Allowing for different slopes in the 2 groups did not affect this conclusion.

With regard to proportions of recanalization, there was a significant difference between the MCA group (15 of 17 [88%] had partial or complete recanalization) at 3 days after tPA compared with the ICA group (5 of 16 [31%] had partial or complete recanalization; $P=0.001$, Fisher exact test, 2-sided). Images from 2 case examples are shown in Figures 3 and 4.

The 3-month mRS score was not different between patients with ICA-plus-MCA occlusion and patients with MCA occlusion alone.

Discussion

Data from this small cohort show that patients with MCA occlusions have better NIHSS scores at days 1 and 3 and a higher proportion of recanalization compared with patients with ICA occlusions after treatment with a standard IV tPA protocol. The 2 groups were not statistically different with respect to age, NIHSS score before tPA, and time from stroke onset to tPA bolus.

The resistance of large blood clots to tPA has been suggested by experimental studies.³³ In addition, previous observations by conventional angiography have shown that ICA occlusions are more resistant than MCA occlusions to IV tPA administered within 6 to 8 hours after symptom onset.^{11–15} The mechanism of arterial occlusion may also be important to predict the likelihood of reperfusion. In fact, fibrin-rich embolic occlusions may recanalize more often than in situ thromboses engrafted on atherosclerotic lesions.³³

In addition, the presence of a blood clot in the ICA might prevent the delivery of an adequate dose of tPA to the occluded MCA.^{11–15}

Trouillas et al³⁴ showed that proximal ICA occlusions are associated with a poor outcome in a multivariate regression analysis of a series of 100 patients. Our study shows similar results, but presents some differences. Trouillas et al³⁴ used a lower dose (0.8 mg/kg) of tPA, and patients were treated within 6 hours after symptom onset. Only 20 patients were treated within 3 hours. In addition, there was no imaging of the arterial occlusion before tPA. The site of arterial occlusion was inferred by post-tPA vascular imaging and a noncontrast CT scan. Even with these limitations, they were able to show that 45% of patients had minimal or no disability at 3 months. This would increase to 53% if proximal ICA occlusions were excluded from the analysis.

Christou et al³⁵ reported results similar to ours using a standard IV tPA protocol and TCD to assess the arterial occlusion before tPA and the presence of eventual recanalization. In our study, the arterial occlusion before tPA was assessed by MRA or CTA. The gold standard for assessing arterial occlusion is still digital subtraction angiography, and the sensitivity of MRA in imaging intracranial occlusive disease is under investigation.³⁶ On the other hand, CTA seems to show good agreement with digital subtraction angiography.²³ In our study, to maximize accuracy in detecting a true arterial occlusion, an artery was judged as occluded or severely stenotic only if (1) no signal was detected by MRA or CTA and (2) DWI and PWI showed signal changes in the area of distribution of the occluded artery on MRA.^{37,38}

Schellinger et al³⁸ evaluated the relationship between arterial occlusion, recanalization, and clinical outcome in 51 acute stroke patients imaged within 3 hours and 20 minutes

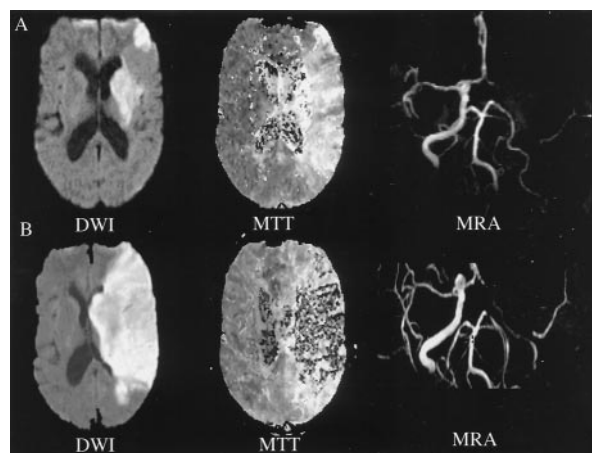


Figure 4. Case example of 50-year-old woman with acute onset of left hemispheric syndrome (NIHSS score 16). A, MRI shows a small hyperintensity in the left basal ganglia on DWI and a large area of prolonged mean transit time (MTT) on PWI in the left MCA territory. MRA shows ICA-plus-MCA occlusion. She was treated with 0.9 mg/kg IV tPA 2 hours and 30 minutes after symptom onset. B, On MRI obtained 24 hours after symptom onset, DWI shows growth of the initial lesion in the territory of distribution of the left MCA. MRA shows no reperfusion of either ICA or MCA on MRA. Her NIHSS score was 11 at 3 days and 14 at 1 month.

after symptom onset by MRI. They showed that early recanalization is associated with (1) better clinical outcome, (2) resolution of the DWI/PWI mismatch, and (3) smaller infarcts compared with patients who do not recanalize. Previously, Jansen et al³⁹ reported similar results in a series of 35 patients. In our study, the assessment of recanalization by MRA or TCD was obtained within 3 days after tPA. This approach may have led us to overestimate the proportion of recanalization that were truly induced by tPA. Nevertheless, our patients were treated earlier (135 minutes after symptom onset) and showed a statistically significant better NIHSS score at days 1 and 3 compared with those who did not recanalize.

In the present series, the difference in day 3 NIHSS score was not reflected in the 3-month mRs scores. Our patients had a higher median age (80 years) and a higher NIHSS score before tPA compared with published series.^{1,9,38} Both variables are known to be associated with worse outcome.^{9,40} The small number of patients in our cohort and these variables may have played a role in the lack of difference at 3 months by mRs score, despite significant improvement in their clinical status as shown by day 1 and 3 NIHSS scores after tPA.

It has been reported that a small proportion of patients with ICA occlusions recanalize and improve their neurological deficit.^{11–15,38} Therefore, their exclusion from tPA treatment cannot be justified. On the other hand, these patients may benefit from an alternative intervention, such as combined IV/IA or mechanical thrombolysis.

In conclusion, patients with MCA occlusions have a better outcome than ICA occlusions after tPA treatment within 3 hours after symptom onset. The site of arterial occlusion may need to be considered in deciding between standard IV tPA protocol or an alternative intervention such as IV/IA and/or mechanical thrombolysis to achieve early recanalization.

References

1. The National Institute of Neurological Disorders and Stroke rtPA Stroke Study Group. Tissue plasminogen activator for acute ischemic stroke. *N Engl J Med*. 1995;333:1581–1587.
2. Baird AE, Austin MC, McKay WJ, Donnan GA. Changes in cerebral tissue perfusion during the first 48 hours of ischaemic stroke: relation to clinical outcome. *J Neurol Neurosurg Psychiatry*. 1996;61:26–29.
3. Heiss WD, Grond M, Thiel A, von Stockhausen HM, Rudolf J. Ischaemic brain tissue salvaged from infarction with alteplase. *Lancet*. 1997;349:1599–1600.
4. Barber PA, Davis SM, Infeld B, Baird AE, Donnan GA, Jolley D, Lichtenstein M. Spontaneous reperfusion after ischemic stroke is associated with improved outcome. *Stroke*. 1998;29:2522–2528.
5. Grond M, Stenzel C, Schmulling S, Rudolf J, Naveling M, Lechleutner A, Schneeweis S, Heiss WD. Early intravenous thrombolysis for acute ischemic stroke. *Stroke*. 1998;29:1544–1549.
6. Heiss WD, Grond M, Thiel A, von Stockhausen HM, Rudolf J, Gaemi M, Lottgem J, Stenzel C, Pawlick G. Tissue at risk for infarction rescued by early reperfusion: a positron emission tomography study in systemic recombinant tissue plasminogen activator thrombolysis of acute stroke. *J Cereb Blood Flow Metab*. 1998;18:1298–1307.
7. Marks MP, Tong DC, Baulieu C, Albers GW, de Crespigny A, Moseley ME. Evaluation of early reperfusion and IV tPA therapy using diffusion- and perfusion-weighted MRI. *Neurology*. 1999;52:1792–1798.
8. Tanne D, Bates VE, Verro P, Kasner SE, Binder JR, Patel SC, Mansbach HH, Daley S, Schultz LR, Karanja PN, Scott P, Dayno JM, Vereczkey-Porter K, Benesh C, Book D, Coplin WM, Dulli D, Levine SR. Initial clinical experience with IV tissue plasminogen activator for acute ischemic stroke: a multicenter survey. The tPA Stroke Survey Group. *Neurology*. 1999;53:424–427.
9. Albers GW, Bates V, Clark WM, Bell R, Verro P, Hamilton SA. Intravenous tissue-type plasminogen activator for treatment of acute stroke: the Standard Treatment with Alteplase to Reverse Stroke (STARS) study. *JAMA*. 2000;283:1145–1150.
10. Marler JR, Tilley BC, Lu M, Brott TG, Lyden PC, Grotta JC, Broderick JP, Levine SR, Frankel MP, Horowitz SH, Haley EC, Lewandowski CA, Kwiatkowski TP. Early stroke treatment associated with better outcome: the NINDS rt-PA stroke study. *Neurology*. 2000;55:1649–1655.
11. Mori E, Yoneda Y, Tabuchi M, Yoshida T, Ohkawa S, Oshumi Y, Kitano K, Tutsumi A, Yamadori A. Intravenous recombinant tissue plasminogen activator in acute carotid artery territory stroke. *Neurology*. 1992;42:976–982.
12. von Kummer R, Hacke W. Safety and efficacy of Intravenous recombinant tissue plasminogen activator and heparin in acute middle cerebral artery stroke. *Stroke*. 1992;23:646–652.
13. von Kummer R, Forstig M, Sartor K, Hacke W. Safety and efficacy of Intravenous recombinant tissue plasminogen activator in acute stroke. In: Hacke W, del Zoppo DJ, Hirschberg M, eds. *Thrombolytic Therapy in Acute Ischemic Stroke*. Heidelberg, Germany: Springer; 1991:161–167.
14. Jensen O, von Kummer R, Forstig M. Thrombolytic therapy in acute occlusion of the intracranial internal carotid artery bifurcation. *AJNR Am J Neuroradiol*. 1995;16:1977–1986.
15. Del Zoppo G, Poock K, Pessin M, Wolpert SM, Furlan AJ, Ferbert A, Alberts MJ, Zivin JA, Wechsler L, Busse O, Greenle R, Brass L, Mohr JP, Feldman E, Hacke W, Higashida RT, Wechsler L, Gent M, Rowley H, Ahuja A, Callahan F, Clark WM, Kase C, Biller J, Gress D, Otis SM. Recombinant tissue plasminogen activator in acute thrombotic or embolic stroke. *Ann Neurol*. 1992;32:78–86.
16. Mitwalli AE, Saad M, Christou I, Malkoff M, Alexandrov AV. Clinical and sonographic patterns of tandem internal carotid artery/middle cerebral artery occlusion in tissue plasminogen activator-treated patients. *Stroke*. 2002;33:99–102.
17. Baird AE, Warach S. Magnetic resonance imaging of acute stroke. *J Cereb Blood Flow Metab*. 1998;18:583–609.
18. Sunshine J, Tarr R, Lanzieri C, Landis D, Selman W, Lewin J. Hyperacute stroke: ultrafast MR imaging to triage patients prior to therapy. *Radiology*. 1999;212:325–332.
19. Fisher M, Albers GW. Application of diffusion-perfusion magnetic resonance imaging in acute ischemic stroke. *Neurology*. 1999;52:1750–1756.
20. Hunter GJ, Hamberg LM, Ponzo JA, Huang-Hellinger FR, Morris PP, Rabinov, Farkas J, Lev MH, Shafer PW, Ogilvy CS, Schwamm L, Buonanno FS, Koroshetz WJ, Wolf GL, Gonzales RG. Assessment of cerebral perfusion and arterial anatomy in hyperacute stroke with three-dimensional functional CT: early clinical results. *AJNR Am J Neuroradiol*. 1998;19:29–37.
21. Christou I, Feldberg RA, Demchuck AM, Burgin WS, Dubey N, Grotta JC, Alexandrov AV, Malkoff MD. Intravenous tissue-type plasminogen activator for internal carotid artery occlusion: outcome and mechanism of recovery. *Stroke*. 2000;31:308.
22. Feske SK, Henderson GV. IV tPA for acute ischemic stroke: outcome based on vascular diagnosis. *Stroke*. 2000;31:315.
23. Verro P, Tanenbaum LN, Borden NM, Souvik S, Eshkar N. CT angiography in acute ischemic stroke preliminary results. *Stroke*. 2000;33:276–278.
24. Furlan AJ, Higashida RT, Wechsler L, Gent M, Rowley H, Kase C, Pessin M, Ahuja A, Callahan F, Clark WM, Silver F, Rivera F. Intra-arterial prourokinase for acute ischemic stroke. The PROACT study: a randomized controlled trial. *Prolyse in Acute Thromboembolism*. *JAMA*. 1999;282:2003–2011.
25. Ernst R, Pancioli A, Tomsick T, Kissella B, Woo D, Kanter K, Jauch E, Carozzella J, Spliker J, Broderick J. Combined intravenous and intra-arterial recombinant tissue plasminogen activator in acute ischemic stroke. *Stroke*. 2000;31:2552–2557.
26. Bellon RJ, Putman CM, Budzik RF, Pergolizzi RS, Reinking GF, Norbash AM. Rheolytic thrombectomy of the occluded internal carotid artery in the setting of acute ischemic stroke. *AJNR Am J Neuroradiol*. 2001;22:526–530.
27. Qureshi AI, Zulfiqar A, Suri MFK, Kim SH, Shatla AA, Ringer AJ, Lopes DK, Guterman LR, Hopkins LN. Intra-arterial, third generation recombinant tissue plasminogen activator (Retepase) for acute ischemic stroke. *Neurosurgery*. 2001;49:41–50.
28. Hill MD, Barber PA, Demchuck AM, Newcommon NJ, Cole-Haskayne A, Ryckborst K, Sopher L, Button A, Hu W, Hudon ME, Morrish W, Frayne R, Sevvick RJ, Buchan AM. Acute intravenous-intraarterial revas-

- cularization therapy for severe ischemic stroke. *Stroke*. 2002;33:279–282.
29. Adams HP Jr, Brodt TG, Furlan AJ, Gomez CR, Grotta J, Helgason CM, Kwiatkowski T, Lyden PD, Marler JR, Torner J, Feinberg W, Mayberg M, Thies W. Guidelines for thrombolytic therapy for acute stroke: a supplement to the guidelines for the management of patients with acute ischemic stroke: a statement for healthcare professionals from a special writing group of the Stroke Council, American Heart Association. *Circulation*. 1996;94:1167–1174.
 30. Schlaug G, Benfield A, Baird AE, Siewert B, Lovblad KO, Parker RA, Edelman RR, Warach S. The ischemic penumbra operationally defined by diffusion and perfusion MRI. *Neurology*. 1999;53:1528–1537.
 31. Aaslid R, Markwalder TM, Nornes H. Noninvasive transcranial doppler ultrasound recordings of flow velocity in basal cerebral arteries. *J Neurosurg*. 1982;57:769–774.
 32. Demchuk AM, Christou I, Wein TH, Felberg RA, Malkoff M, Grotta JC, Alexandrov AV. Specific transcranial doppler flow findings related to the presence and site of the arterial occlusion. *Stroke*. 2000;31:140–146.
 33. Zivin JA, Fisher M De Girolami U, Hemnway CC, Stashack JA. Tissue plasminogen activator reduces cerebral damage after cerebral embolism. *Science*. 1985;230:1289–1292.
 34. Trouillas P, Nighoghossian N, Derex L, Adeline P, Honnorat J, Neuschwander P, Riche G, Getenet JC, Li W, Froment JC, Turjman F, Malicier D, Fournier G, Ledoux X, Berthezene Y, French P, Dechavanne M. Thrombolysis with intravenous tPA in a series of 100 cases of acute ischemic carotid territory stroke: determination of etiological, topographic and radiological outcome factors. *Stroke*. 1998;29:2529–2540.
 35. Christou I, Burgin WS, Alexandrov AV, Grotta JC. Arterial status after intravenous TPA therapy for ischaemic stroke: a need for further intervention. *Int Angiol*. 2001;20:208–213.
 36. Benesh C, Chimowitz MI. Best treatment for intracranial arterial stenosis? Fifty years of uncertainty. The WASID Investigators. *Neurology*. 2000;55:465–466.
 37. Staroselskaya I, Chaves C, Silver B, Linfante I, Edelman R, Caplan LR, Warach S, Baird A. Relationship of arterial lesion and MR diffusion-perfusion mismatch in acute ischemic stroke. *Arch Neurol*. 2001;58:1069–1074.
 38. Schellinger PD, Fiebach JB, Jansen O, Ringleb PA, Mohr A, Steiner T, Heiland S, Schwab S, Pohlner O, Rysse H, Orakcioglu B, Sartor K, Hacke W. Stroke magnetic resonance imaging within 6 hours after onset of hyperacute cerebral ischemia. *Ann Neurol*. 2001;49:460–469.
 39. Jansen O, Schellinger P, Fiebach J, Hacke W, Sartor K. Early recanalisation in acute ischaemic stroke saves tissue at risk defined by MRI. *Lancet*. 1999;353:2036–2037.
 40. Tanne D, Gorman MJ, Bates VE, Kasner SE, Scott P, Verro P, Binder JR, Dayno JM, Levine SR, Schultz LR. Intravenous tissue plasminogen activator for acute ischemic stroke in patients aged 80 years and older: the tPA stroke survey experience. *Stroke*. 2000;31:370–375.