

## **Clinical characteristics of combined pulmonary fibrosis and emphysema**

Yoshiaki Kitaguchi<sup>1</sup>, Keisaku Fujimoto<sup>1</sup>, Masayuki Hanaoka<sup>1</sup>, Satoshi Kawakami<sup>2</sup>, Takayuki Honda<sup>3</sup>, Keishi Kubo<sup>1</sup>

<sup>1</sup> First Department of Internal Medicine, Shinshu University School of Medicine, Matsumoto 390-8621, Japan

<sup>2</sup> Department of Radiology, Shinshu University School of Medicine, Matsumoto 390-8621, Japan

<sup>3</sup> Department of Laboratory Medicine, Shinshu University School of Medicine, Matsumoto 390-8621, Japan

### **Correspondence:**

Keisaku Fujimoto,

First Department of Internal Medicine, Shinshu University School of Medicine, 3-1-1 Asahi, Matsumoto 390-8621, Japan.

E-mail : [keisaku@shinshu-u.ac.jp](mailto:keisaku@shinshu-u.ac.jp) Fax: +81-263-36-3722

### **Summary at a glance**

This study describes the clinical characteristics of patients with concurrent pulmonary fibrosis and emphysema (CPFE) and compares these to patients with COPD. It should therefore be noteworthy that the prevalence of lung cancer might be high in CPFE patients.

## **Abstract**

**Background and objective:** We have sometimes seen patients with combined pulmonary fibrosis and emphysema (CPFE) and speculate that they have some different clinical characteristics to COPD patients. This study clarifies the clinical characteristics of CPFE patients.

**Methods:** This was a retrospective study of 47 stable patients with concurrent emphysema and diffuse parenchymal lung disease with fibrosis, based on the findings of chest CT (CPFE patients). The clinical characteristics of CPFE patients were compared with those of emphysema dominant COPD patients without parenchymal lung disease (COPD patients).

**Results:** Forty-six of the 47 CPFE patients were male. Paraseptal emphysema was particularly common in the CPFE group. Honeycombing, ground-glass opacities and reticular opacities were present in 75.6%, 62.2% and 84.4% of CPFE patients, respectively. Twenty-two of the 47 CPFE patients (46.8%) had lung cancer. Pulmonary function tests showed that the CPFE group had milder airflow limitation and lower diffusing capacity than the COPD group. Desaturation during 6-minute walking test in CPFE patients tended to be more severe than in COPD patients, if the level of FEV<sub>1</sub> or 6 minute-walking distance was equal.

**Conclusion:** CPFE patients had some different clinical characteristics in comparison to COPD patients and may also have a high prevalence of lung cancer.

**Key words**

COPD, Emphysema, Pulmonary fibrosis, Interstitial Lung Disease, Lung cancer

**Clinical characteristics of CPFE**

**Short title**

## Introduction

Emphysema is characterized by the permanent abnormal enlargement of airspaces distal to the terminal bronchioles, accompanied by destruction of their walls. The characteristics of emphysema do not, by definition, include thickening of the alveolar septa and fibrosis. Emphysema and the idiopathic interstitial pneumonias, including idiopathic pulmonary fibrosis (IPF), are conditions defined by distinct clinical, functional, radiological, and pathological characteristics. Pulmonary fibrosis and emphysema can co-exist. In 1993 Hiwatari *et al.* reported nine patients with pulmonary emphysema and IPF among 152 pulmonary emphysema patients. Those patients were all males and heavy smokers.<sup>1</sup> Odani *et al.* reported 31 patients with pulmonary emphysema and IPF among 14,900 patients who underwent chest CT and 13 of the 31 (42%) also had lung cancer.<sup>2</sup> Cottin *et al.* conducted a retrospective study of 61 patients with combined pulmonary fibrosis and emphysema (CPFE) and comprehensively described the syndrome.<sup>3</sup>

Patients who met the imaging criteria for CPFE as described previously by Cottin *et al.*<sup>3</sup> had been sometimes seen. They had a high prevalence of lung cancer, which was very surprising for us. We hypothesized that patients with CPFE had some different clinical characteristics to COPD patients. Further characterization of the syndrome of CPFE is necessary and this study clarifies the clinical characteristics of CPFE patients.

## Methods

### Subjects

This study retrospectively analyzed 47 stable patients with concurrent emphysema of grade 2 or more based on chest CT<sup>4</sup> and idiopathic diffuse parenchymal lung disease with fibrosis.<sup>5</sup> Study participants were recruited from outpatients attending Shinshu University Hospital between October 2004 and June 2007 with concurrent COPD, interstitial pneumonia, and lung cancer (CPFE patients). Exclusion criteria included the presence of connective tissue disease and any other interstitial lung disease, such as drug-induced interstitial lung disease, pneumoconiosis, hypersensitivity pneumonitis, sarcoidosis, pulmonary histiocytosis, lymphangioleiomyomatosis and eosinophilic pneumonia.

The clinical characteristics of pulmonary CPFE patients were compared with those of stable emphysema dominant COPD patients without parenchymal lung disease with fibrosis. The definition of emphysema dominant COPD was emphysema of grade 2 or more on chest CT.<sup>4</sup> Eighty-two stable emphysema dominant COPD patients were recruited from the outpatient clinics of Shinshu University Hospital between October 2004 and June 2005 (COPD patients). The diagnosis of COPD was based on the clinical history and symptoms including dyspnoea while exercising and pulmonary function characterized by irreversible airflow limitation ( $FEV_1/FVC < 70\%$  after inhalation of a  $\beta_2$ -agonist) in accordance with the GOLD guidelines.<sup>6</sup>

This study was approved by the institutional Human Ethics Committee.

### Protocol and measurements

For each patient, information was abstracted on the history of the current illness, including complications, history of smoking and exposure to noxious particles or gases other than tobacco, physical and laboratory examinations, pulmonary function tests, (including reversibility of airflow limitation by 20  $\mu$ g of inhaled procaterol

hydrochloride, exercise capacity and exercise-induced desaturation by the 6-minute walking test), and the findings on chest high resolution CT (HRCT).

### ***Evaluation of CPFE patients by HRCT***

A helical CT scanner (LightSpeed, General Electric, Milwaukee, Wisconsin) with a slice thickness of 10 mm was used for conventional contiguous scanning to screen for chest abnormalities, followed by HRCT scanning at full inspiration with 1-3 mm collimation (120 kVp, 200 mA, pitch 1.0). Four slices 1 mm thick were obtained at three anatomic levels at full inspiration, i.e., near the superior margin of the aortic arch (level of the upper lung field), at the level of the carina (level of the middle lung field), and at the level of the orifice of the inferior pulmonary veins (level of the lower lung field). To evaluate emphysema, HRCT images were photographed with a window setting appropriate for the lungs (window level from -700 to -900 HU; width from 800 to 1000 HU). Emphysema on HRCT was defined as well-demarcated areas of decreased attenuation and margined by either a very thin wall (<1 mm) or no wall at all, and/or multiple bullae (>1 cm) predominantly in the upper lung fields. Emphysema was scored visually in the upper, middle and lower lung fields of both lungs according to the methods of Goddard *et al.*<sup>4</sup> The score in each of the six lung fields was calculated according to the percentage of each lung field that was a low attenuation area (%LAA): score 0 - %LAA<5%; score 1 - 5%≤%LAA<25%; score 2 - 25%≤%LAA<50%; score 3 - 50%≤%LAA<75%; score 4 - 75%≤%LAA. The severity of emphysema was graded based on the sum of the scores in all six lung fields: grade 0 - total score=0; grade 1 - total scores=1-6; grade 2 - total scores=7-12; grade 3- total scores=13-18; grade 4- total scores=19-24. Emphysema was classified into three phenotypes; namely, centriacinar emphysema, panacinar emphysema and paraseptal emphysema.

Data on the presence of diffuse parenchymal lung disease with significant pulmonary fibrosis on HRCT, defined as thick-walled bulla, honeycombing, reticular opacities, ground-glass opacities, consolidation, traction bronchiectasis, peribronchovascular interstitial thickening and architectural distortion, were collected. A thick-walled bulla was defined as a sharply demarcated area, measuring 2 cm or more in diameter, and possessing a wall more than 1 mm thick. Some Japanese investigators suggested that similar radiological findings were also characteristic of CPFE (data not published).

CT images were analyzed independently by two pulmonologists (Y.K. and K.F.) with no knowledge of the patients' clinical information. The CPFE group was characterized by the coexistence of significant emphysema of grade 2 or more (%LAA≥25%) and diffuse parenchymal lung disease with significant pulmonary fibrosis. The COPD group was characterized by the presence of significant emphysema of grade 2 or more (%LAA≥25%) without any significant pulmonary fibrosis.

### ***Pulmonary function tests***

Both spirometry and the measurement of DLco were performed using a pulmonary function testing system (Chestac-55V; Chest Co. Ltd., Tokyo, Japan). To evaluate the reversibility of airflow limitation, FEV<sub>1</sub> was measured before and 20 min after the inhalation of a  $\beta_2$ -agonist (20  $\mu$ g procaterol hydrochloride). The FRC was measured using a Body Box (Medgraphic, Ann Harbor, MI), after which the subjects immediately inspired to TLC and maximally expired to RV, thus allowing for calculation of lung

volumes and of RV/TLC. Pulmonary function testing was performed by two technicians according to the ATS criteria. Two or three tests were repeated to guarantee repeatability.

### **6MWD**

The patients were instructed to walk from one end of a measured corridor (50 m) to the other at their own pace. The test result consisted of the distance the patient could walk in 6 min. The patients were allowed to rest when necessary, but they were encouraged to complete as many lengths of the corridor as possible. Pulse oximetric saturation (SpO<sub>2</sub>) was monitored throughout the walk using a SpO<sub>2</sub> monitor (Pulsox-8; Teijin Ltd., Osaka, Japan), and the lowest SpO<sub>2</sub> was recorded.

### **Data analysis**

The values shown in the text and tables are mean  $\pm$  SEM. The variables were compared with the use of nonparametric Mann-Whitney's U tests. Simple correlations between variables were examined by calculating Pearson's product correlation coefficient. All statistical analyses were performed with the use of Windows-compatible software program (Stat Flex version.5.0, Artech Ltd., Osaka, Japan). A P-value of less than 0.05 was considered to be significant in all statistical analyses.

## **Results**

### **Clinical characteristics**

The clinical status of both groups is described in Table 1. CPFE patients had significantly higher BMI and a higher prevalence of early stage COPD and lung cancer than did COPD patients.

Among patients with CPFE, 13 (27.0%) also had a history of exposure to noxious particles or gases other than tobacco; six patients (12.8%) to asbestos and five patients (10.6%) to agrochemical compounds. Of the COPD patients, 35 (42.7%) also had a history of exposure to noxious particles or gases other than tobacco, eight patients (9.8%) asbestos and nine patients (11.0%) agrochemical compounds.

### **Findings of chest HRCT**

Paraseptal emphysema was more common in the CPFE group (Table 2) than in the COPD group. On chest CT all CPFE patients showed the coexistence of emphysema with an upper lung field predominance and diffuse parenchymal lung disease with significant pulmonary fibrosis with a lower lung field predominance. The prevalence of honeycombing, ground-glass opacities and reticular opacities were 75.6%, 62.2% and 84.4% in CPFE patients, respectively. Thick-walled bullae were observed in more than one half of the CPFE patients. Lung cancer observed by chest CT was as follows: 11 patients had tumours in the combined fibrotic and emphysematous region, nine patients in the emphysematous region and two patients in the fibrotic region. No patient had atelectasis secondary to a central lung cancer.

### **Pulmonary function tests**

There was no significant difference in VC between the COPD and CPFE groups, however the FEV<sub>1</sub> and FEV<sub>1</sub>/FVC were significantly higher in the CPFE group (Table



3). Twenty-seven of the 47 CPFE patients (57.4%) had a FEV<sub>1</sub>/FVC ratio after inhalation of a  $\beta_2$ -agonist within the normal range (non-COPD), eight patients stage I, eight patients stage II and four patients stage III (Table 1). The diffusing capacity was significantly lower in the CPFE group than in the COPD group (Table 3).

Figure 1 shows the relationship between desaturation ( $\Delta$  SpO<sub>2</sub>) and the 6 minute walking test and  $\Delta$  SpO<sub>2</sub> and FEV<sub>1</sub>%. Desaturation during a 6-minute walking test in CPFE patients tended to be more severe than in COPD patients, if the level of FEV<sub>1</sub> or the 6 minute walking distance were equal.

### ***Pathological findings***

A pathological diagnosis of diffuse parenchymal lung disease with fibrosis was obtained in six of 47 CPFE patients. Four CPFE patients underwent an open lung biopsy and two CPFE patients underwent a lobectomy because of lung cancer. The pathological diagnosis of three patients was usual interstitial pneumonia (UIP) and that of three patients was non-specific interstitial pneumonia (NSIP). Figures 2 and 3 show images from the two CPFE patients who had open lung biopsy.

### **Discussion**

This study described the clinical characteristics of patients with CPFE and compared these to patients with COPD. Almost all of the patients in this study were male and heavy smokers. The value of serum KL-6 was high. CPFE was characterized by subnormal spirometry (mild airflow limitation and mild lung hyperinflation), severe impairment of gas exchange and desaturation during exercise. Desaturation during a 6-minute walking test tended to be more severe in CPFE patients than in COPD patients, if the level of FEV<sub>1</sub> or the 6-minute walking distance was equal. Paraseptal emphysema was particularly common in the CPFE group in comparison to the COPD group. As previously described<sup>1 2 3 7</sup>, the chest CT of all CPFE patients showed the coexistence of emphysema with an upper lung field predominance and diffuse parenchymal lung disease with significant pulmonary fibrosis more predominant in the lower lung fields. The prevalence of honeycombing, ground-glass opacities and reticular opacities were particularly high. Lung cancer was found in nearly one half of the CPFE patients, with squamous cell carcinoma the most common histological type.

CPFE has been reported previously. In 1993 Hiwatari *et al.* described nine patients with pulmonary emphysema followed by IPF and all of these patients were male and heavy smokers.<sup>1</sup> In 2004 Odani *et al.* reported 31 patients diagnosed with coexisting pulmonary emphysema and idiopathic pulmonary fibrosis among 14900 patients examined by chest CT.<sup>2</sup> The CT of all patients showed the coexistence of emphysema with an upper lung field predominance and diffuse parenchymal lung disease with significant pulmonary fibrosis predominantly in the lower lung fields. The incidence of lung cancer was 42% (13 patients) and squamous cell carcinoma was the most common histological type. Centriacinar emphysema was present in 24 of the 31 (77%) patients, and paraseptal emphysema in 11 of 31 patients (35%). Honeycombing, which is one of the most common findings of UIP, was present in 24 of the 31 patients (77%). The authors concluded that strict follow-up was required for these patients, because the prevalence of lung cancer was very high. In 2005 Cottin *et al.* conducted a retrospective study of 61 patients with combined pulmonary fibrosis and emphysema.<sup>3</sup> They reported that 60 of 61 CPFE patients were male, dyspnoea on exertion was present in all patients,

basal crackles were found in 87% and finger clubbing in 43%. Pulmonary function tests showed preserved lung volumes and strongly impaired DLCO. Pulmonary arterial hypertension was present in 47% of patients at diagnosis and the five year survival was 55%. Pulmonary arterial hypertension was a critical determinant of the prognosis. Mura *et al.* investigated the additional functional impairment caused by emphysema in IPF patients by comparing 21 patients who had both IPF and emphysema with 21 patients who had IPF alone.<sup>8</sup> They concluded that among smokers with IPF, the presence and the extent of emphysema have a profound influence on physiologic function in terms of both further impairment and confounding effects to contribute to functional impairment and dyspnoea on exertion. Daniil *et al.* reported nine of 21 IPF patients who met the imaging criteria for CPFE<sup>9</sup> as previously described by Cottin *et al.*<sup>3</sup> All nine patients were farmers and had significant exposure to agrochemical compounds. They suggested that exposure to agrochemical compounds could be a potential triggering event, which is capable of causing airway and interstitial disease in genetically susceptible smokers. In the present study, five of 47 CPFE patients (16.0%) and nine of 82 COPD patients (11.0%) had a history of exposure to agrochemical compounds. There was no significant difference between the two groups. However, there is a possibility that a variety of agrochemical compounds and application methods might make a difference in the findings.

Odani *et al.* reported that 42% of patients with concurrent emphysema and pulmonary fibrosis had lung cancer, which is similar to the 46.8% found in the 47 CPFE patients in the present study.<sup>2</sup> These results are amazing, however, there is a possibility that the characteristics of lung cancer in Japan might differ from in other developed countries and the racial difference might have influenced the results. Autopsy studies showed that adenocarcinoma was more common than squamous cell carcinoma in Japan than in the United States<sup>10</sup> and that the male/female ratio of lung cancer was lower than the ratio found in the United States and Europe.<sup>11</sup> On the other hand, the WHO Mortality Database (1960-2000), reported that age-standardized lung cancer mortality rates were not particularly high in Japan.<sup>12</sup>

Nakayama *et al.* reported that 18 of 127 COPD patients (14%) had concurrent lung cancer.<sup>13</sup> Araki *et al.* reported that an autopsy study of elderly Japanese patients with IPF showed that lung cancer developed in approximately 23% of the IPF patients.<sup>14</sup> Therefore, the prevalence of lung cancer might be higher in CPFE patients than in COPD patients and IPF patients. Lung cancer profoundly influences the prognosis of CPFE patients, as their lung function may be too poor to allow surgery or chemotherapy.

Generalisability is a potential problem in the present study. Of the 497 patients with lung cancer, 22 also had CPFE Shinshu University Hospital, the site of patient recruitment, is a major hospital and might have more patients with lung cancer compared with other general hospitals.

Little is known about the pathophysiology of CPFE. IPF and pulmonary emphysema have distinct clinical and pathological characteristics, and have been considered to be separate disorders. In spite of such differences, animal experiments have suggested that the same lung injury might result in either fibrosis or emphysema. Connective tissue synthesis during the healing phase is the critical determinant.<sup>15</sup> Hoyle *et al.* reported that the overexpression of platelet-derived growth factor-B (PDGF-B) induced distinct abnormalities in the developing and adult lung of transgenic mice and led to a complex

phenotype that included aspects of both emphysema and fibrotic lung disease.<sup>16</sup> Landblad *et al.* showed that the overexpression of TNF-alpha driven by the surfactant protein C promoter in transgenic mice induces pathologic changes consistent with both emphysema and pulmonary fibrosis.<sup>17</sup> These pathologic changes might represent an experimental animal model of CPFE.<sup>3 18</sup> According to another studies, the overexpression of IL-13<sup>19</sup> and transforming growth factor-beta1<sup>20</sup> in transgenic mice induced both pulmonary fibrosis and emphysema. The tissue effects of these factors might depend on the balance of apoptosis, proteolysis and fibrosis and might regulate the degree of emphysema and/or fibrosis in the injured lung. Further studies are needed to elucidate these phenomena.

In conclusion, CPFE patients had some different clinical characteristics to COPD patients, and the prevalence of lung cancer might be higher in CPFE patients.

## References

1. Hiwatari N, Shimura S, Takishima T. Pulmonary emphysema followed by pulmonary fibrosis of undetermined cause. *Respiration* 1993; 60: 354-8.
2. Odani K, Murata Y, Yoshida S. Computed Tomographic Evaluation in the Cases of Coexistence of Pulmonary Emphysema with Idiopathic Pulmonary Fibrosis. *Danso Eizo kenkyukai Zasshi* (Japanese Journal of Tomography) 2004; 31: 25-9.
3. Cottin V, Nunes H, Brillet PY, Delaval P, Devouassoux G et al. Combined pulmonary fibrosis and emphysema: a distinct underrecognised entity. *Eur. Respir. J.* 2005; 26: 586-93.
4. Goddard PR, Nicholson EM, Laszlo G, Watt I. Computed tomography in pulmonary emphysema. *Clin. Radiol.* 1982; 33: 379-87.
5. Gotway MB, Freemer MM, King TE Jr. Challenges in pulmonary fibrosis. 1: Use of high resolution CT scanning of the lung for the evaluation of patients with idiopathic interstitial pneumonias. *Thorax* 2007; 62: 546-53.
6. Global Initiative for Chronic Obstructive Lung Disease. Global Strategy for the Diagnosis, Management, and Prevention of Chronic Obstructive Pulmonary Disease. NHLBI/WHO workshop report. Bethesda, National Heart, Lung and Blood Institute, April 2001; Update of the Management Sections, GOLD website (<http://www.goldcopd.com>). Date updated: November 2008.
7. Grubstein A, Bendayan D, Schactman I, Cohen M, Shitrit D et al. Concomitant upper-lobe bullous emphysema, lower-lobe interstitial fibrosis and pulmonary hypertension in heavy smokers: report of eight cases and review of the literature. *Respir. Med.* 2005; 99: 948-54.
8. Mura M, Zompatori M, Pacilli AM, Fasano L, Schiavina M et al. The presence of emphysema further impairs physiologic function in patients with idiopathic pulmonary fibrosis. *Respir. Care* 2006; 51: 257-65.
9. Daniil Z, Koutsokera A, Gourgoulianis K. Combined pulmonary fibrosis and emphysema in patients exposed to agrochemical compounds. *Eur. Respir. J.* 2006; 27: 434.
10. Tanaka I, Matsubara O, Kasuga T, Takemura T, Inoue M. Increasing incidence and changing histopathology of primary lung cancer in Japan. A review of 282 autopsied cases. *Cancer* 1988; 62: 1035-9.
11. Morita T, Yamaguchi K, Shimamine T, Mori W, Urano Y. An autopsy study of lung cancer in University of Tokyo for the last 27 years, from 1958 to 1984, with special reference to the characteristics of lung cancer in Japan. *Acta. Pathol. Jpn.* 1987; 37: 1375-88.
12. Marugame T, Yoshimi I. Comparison of cancer mortality (lung cancer) in five countries: France, Italy, Japan, UK and USA from the WHO Mortality Database (1960-2000). *Jpn. J. Clin. Oncol.* 2005; 35: 168-70.
13. Nakayama M, Satoh H, Sekizawa K. Risk of cancers in COPD patients. *Chest* 2003; 123: 1775-6.
14. Araki T, Katsura H, Sawabe M, Kida K. A clinical study of idiopathic pulmonary fibrosis based on autopsy studies in elderly patients. *Intern. Med.* 2003; 42: 483-9.
15. Niewoehner DE, Hoidal JR. Lung fibrosis and emphysema: divergent responses to a common injury? *Science* 1982; 217: 359-60.
16. Hoyle GW, Li J, Finkelstein JB, Eisenberg T, Liu JY et al. Emphysematous lesions, inflammation, and fibrosis in the lungs of transgenic mice overexpressing

- platelet-derived growth factor. *Am. J. Pathol.* 1999; 154: 1763-75.
17. Lundblad LK, Thompson-Figueroa J, Leclair T, Sullivan MJ, Poynter ME et al. Tumor necrosis factor-alpha overexpression in lung disease: a single cause behind a complex phenotype. *Am. J. Respir. Crit. Care Med.* 2005; 171: 1363-70.
  18. Cottin V, Cordier JF. Combined pulmonary fibrosis and emphysema: an experimental and clinically relevant phenotype. *Am. J. Respir. Crit. Care Med.* 2005; 172: 1605-6.
  19. Fulkerson PC, Fischetti CA, Hassman LM, Nikolaidis NM, Rothenberg ME. Persistent effects induced by IL-13 in the lung. *Am. J. Respir. Cell Mol. Biol.* 2006; 35: 337-46.
  20. Lee CG, Cho S, Homer RJ, Elias JA. Genetic control of transforming growth factor-beta1-induced emphysema and fibrosis in the murine lung. *Proc. Am. Thorac. Soc.* 2006; 3: 476-7.

Table 1. Comparison of the clinical characteristics of patients with combined pulmonary fibrosis and emphysema (CPFE) and patients with emphysema dominant COPD without fibrosis (COPD).

	CPFE (n=47)	COPD (n=82)
Age, years	70.3±1.3	70.5±0.7
Gender, F/M	1/46	8/74
BMI, kg/m <sup>2</sup>	22.9±0.4**	20.5±0.3
Smoking history, pack·years	58.7±4.4	59.4±3.0
Exposure to noxious particles or gases other than tobacco	13 (27.0%)	35 (42.7%)
Non-COPD	27 (57.4%)	0 (0.0%)
COPD	20 (42.6%)**	82 (100.0%)
Stage I	8 (17.0%)	8 (9.8%)
Stage II	8 (17.0%)**	34 (41.5%)
Stage III	4 (8.5%)**	30 (36.6%)
Stage IV	0 (0.0%)	10 (12.2%)
Lung cancer	22 (46.8%)**	6 (7.3%)
Squamous cell carcinoma	12 (54.5%)**	3 (50.0%)
Small cell carcinoma	2 (9.1%)	0 (0.0%)
Adenocarcinoma	7 (31.8%)	3 (50.0%)
LCNEC	1 (4.5%)	0 (0.0%)

Values are number (%) or mean±SEM. \*p<0.05 and \*\*p<0.01 vs. COPD.

Table 2. Chest high resolution CT (HRCT) findings in patients with combined pulmonary fibrosis and emphysema (CPFE, n=47) and emphysema dominant COPD without fibrosis (COPD, n=82).

	CPFE	COPD
LAA score	13.2±0.9**	18.9±0.7
Upper lung field	5.6±0.3**	6.7±0.2
Middle lung field	4.3±0.3**	6.2±0.2
Lower lung field	3.3±0.4**	5.9±0.3
Emphysema type		
Centriacinar, %	11 (24.4%)**	49 (59.8%)
Panacinar+centriacinar, %	7 (15.6%)*	26 (31.7%)
Paraseptal, %	15 (33.3%)**	7 (8.5%)
Paraseptal+centriacinar, %	12 (26.7%)**	0 (0.0%)
IP distribution		
Upper lung field	8 (17.0%)	
Middle lung field	18 (38.3%)	
Lower lung field	47 (100.0%)	
IP pattern		
Thick-walled bulla, n (%)	26 (57.8%)	
Honeycombing, n (%)	34 (75.6%)	
Reticular opacity, n (%)	38 (84.4%)	
Ground glass opacity, n (%)	28 (62.2%)	
Consolidation, n (%)	6 (13.3%)	
Traction bronchiectasis, n (%)	18 (40.0%)	
Peribronchovascular thickening, n (%)	4 (8.9%)	
Architectural distortion, n (%)	7 (15.6%)	

Values are the mean±SEM. \*p<0.05 and \*\*p<0.01 vs. COPD.

LAA low attenuation area; IP interstitial pneumonia;

Table 3. Pulmonary function tests and laboratory data in patients with combined pulmonary fibrosis and emphysema (CPFE) and emphysema dominant COPD without fibrosis (COPD).

	CPFE (n=47)	COPD (n=82)
%VC	94.7±3.5	96.6±2.4
FEV1, % of pred.	79.0±3.1**	54.7±2.7
FEV1/FVC, %	71.8±2.0**	48.0±1.2
FRC, % of pred.	89.9±5.8**	112.5±2.7
RV, % of pred.	114.7±10.3**	181.7±5.5
RV/TLC, %	37.3±1.9**	50.5±1.1
%DLco, %	39.6±2.5**	57.7±2.2
PaO <sub>2</sub> , torr	68.6±2.3	70.0±1.3
PaCO <sub>2</sub> , torr	39.3±0.9	40.5±0.6
α1-AT, mg/dl	153±15	190±38
CRP, mg/dl	1.1±0.3	0.5±0.1
KL-6, U/ml	1058±166	-

Values are the mean±SEM. \*\*p<0.01 vs. COPD.

CRP – C-reactive protein; α1-AT - alpha1-antitrypsin



### Figure legends

**Figure 1.** Relationship between desaturation ( $\Delta\text{SpO}_2$ ) and 6MWD and  $\Delta\text{SpO}_2$  and FEV<sub>1</sub>% in patients with combined pulmonary fibrosis and emphysema (CPFE) and emphysema dominant COPD without fibrosis (COPD).

**Figure 2.** Imaging and histology from a 66 year old man with combined pulmonary fibrosis and emphysema (CPFE). a) CT of both upper lung fields shows emphysema. b) CT of both lower lung fields shows reticular opacities and traction bronchiectasis. c) and d) Histological diagnosis obtained by open lung biopsy shows emphysema with non-specific interstitial pneumonia.

**Figure 3.** Imaging and histology of a 69 year old man with combined pulmonary fibrosis and emphysema (CPFE). a) CT of both upper lung fields shows emphysema. b) CT of both lower lung fields shows reticular opacity, thick-walled bulla and lung cancer. c) and d) Histological diagnosis obtained by lobectomy was emphysema, usual interstitial pneumonia and squamous cell carcinoma.

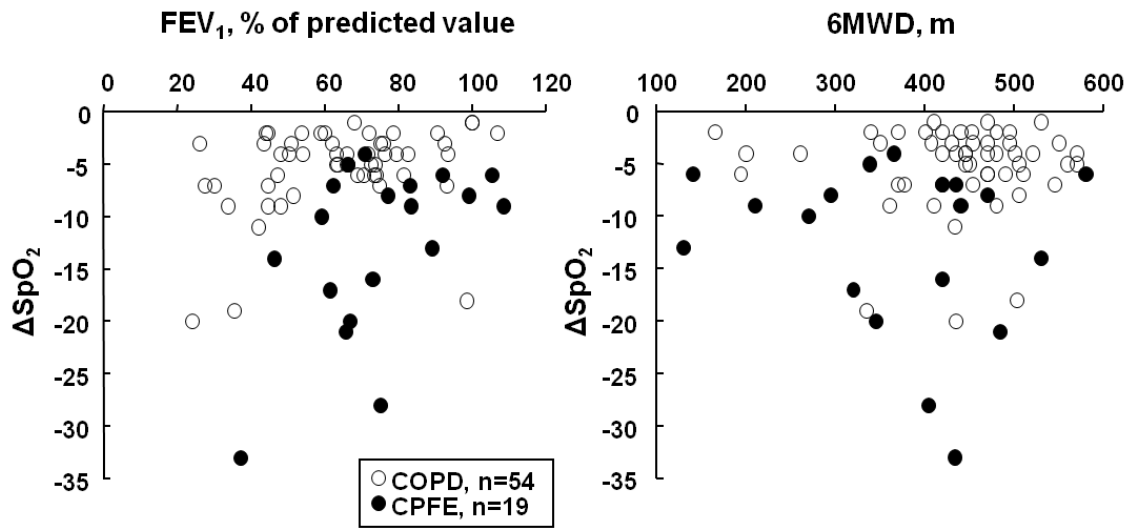
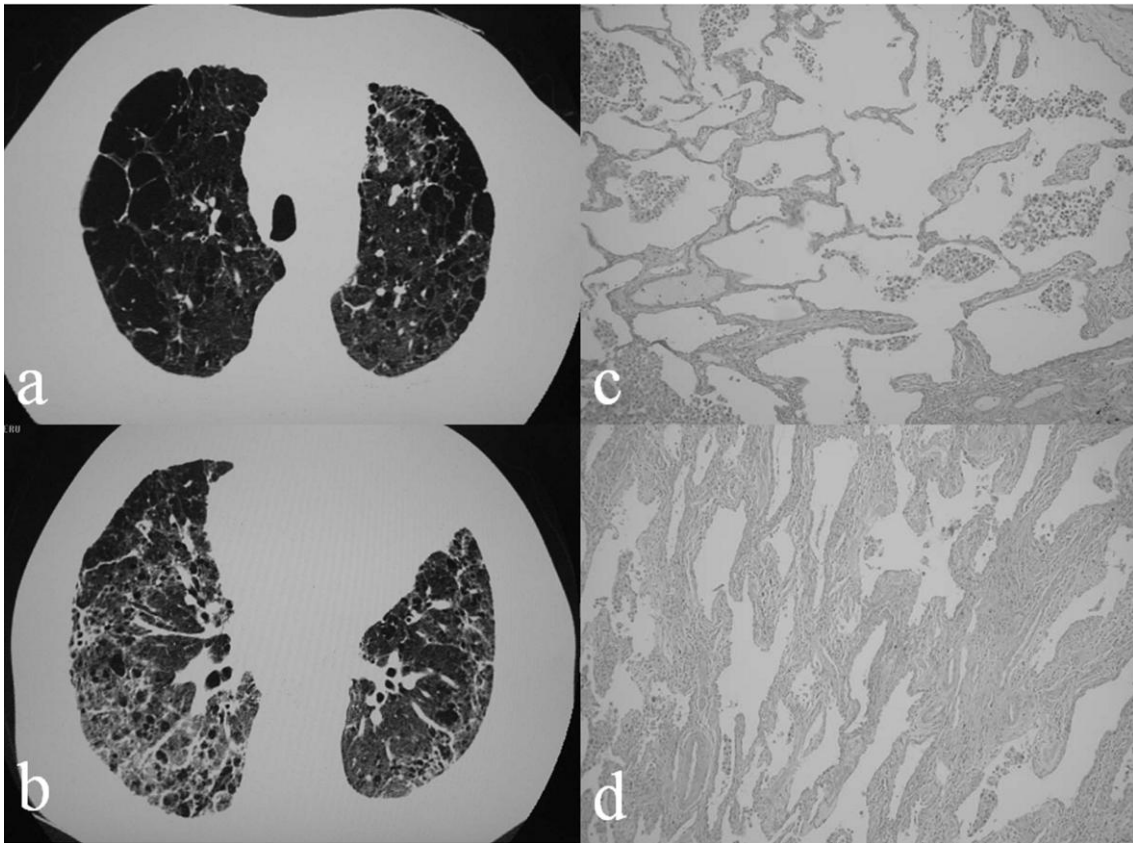
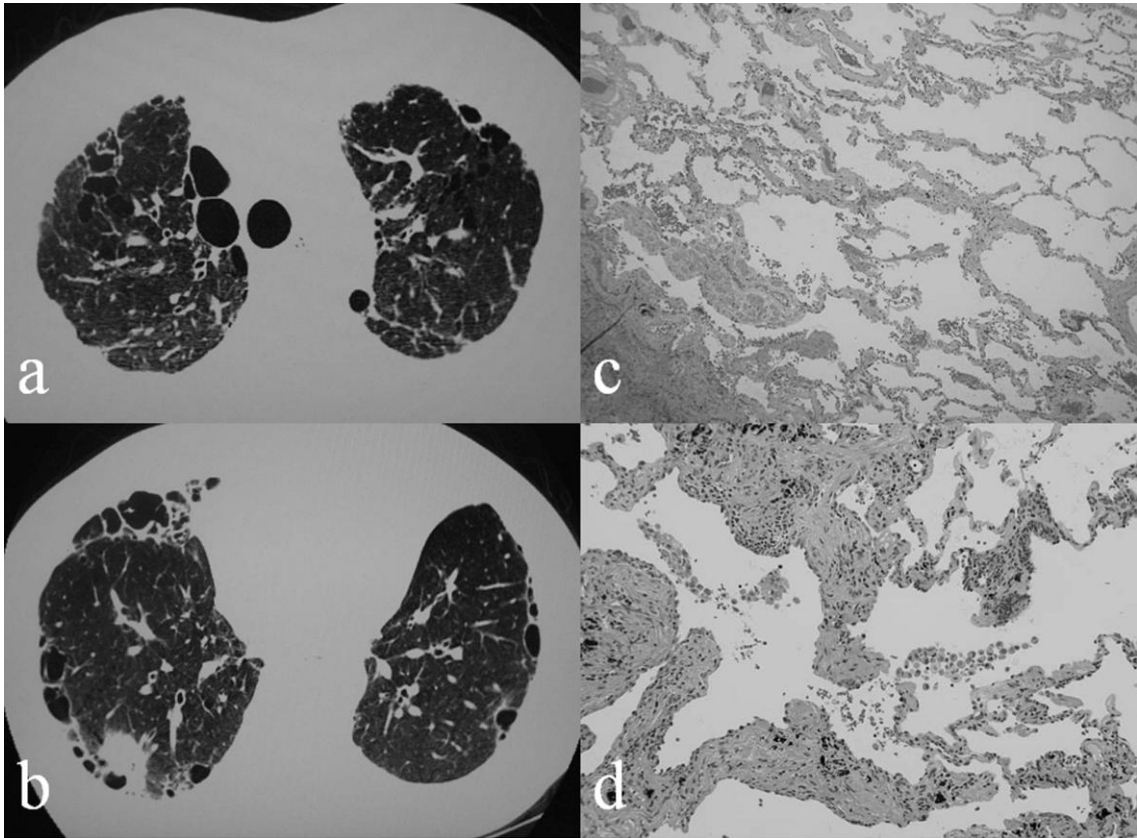


Figure 1.



**Figure 2.**



**Figure 3.**