

Clinical course of focal choroidal excavation in Vogt–Koyanagi–Harada disease

Yuko Nishikawa^{1-3,*}Kaoru Fujinami^{1,2,4,5,*}Ken Watanabe^{1,2}Toru Noda^{1,2}Kazushige Tsunoda^{1,2}Kunihiko Akiyama^{1,2}

¹Department of Ophthalmology, National Hospital Organization, Tokyo Medical Center, Tokyo, Japan;

²Laboratory of Visual Physiology, National Institute of Sensory Organs, National Tokyo Medical Center, Tokyo, Japan;

³Department of Ophthalmology, Osaka Medical College, Takatsuki, Osaka, Japan;

⁴Department of Ophthalmology, Keio University School of Medicine, Tokyo, Japan;

⁵UCL Institute of Ophthalmology, London, UK

*These authors contributed equally to this work

Abstract: We describe focal choroidal excavation (FCE) in a case of Vogt–Koyanagi–Harada (VKH) disease and compare the findings with different chorioretinal conditions. A 55-year-old man was diagnosed with VKH based on panuveitis and exudative retinal detachments. Spectral-domain optical coherence tomography demonstrated a dome-shaped protrusion with a nonconforming pattern at the fovea, which had been detected as a conforming pattern 1 year before the onset. The FCE pattern returned into a conforming pattern following corticosteroid therapy. These findings suggest that the natively existent FCE could be affected by pathophysiological changes of VKH as well as other chorioretinal conditions.

Keywords: choroidal excavation, focal choroidal excavation, Vogt–Koyanagi–Harada disease, optical coherence tomography

Introduction

Focal choroidal excavation (FCE) was first described by Jampol et al¹ as an anomalous excavation of the choroid; it is typically observed by optical coherence tomography (OCT).^{1,2} This condition has been associated with several chorioretinal conditions and asymptomatic status, including central serous chorioretinopathy, choroidal neovascularization, and best vitelliform macular dystrophy.¹⁻¹² However, the mechanisms underlying the formation of FCE remain uncertain.

Wakabayashi et al² described two patterns of FCE: 1) conforming pattern – excavations that involved the outer retinal layers up to and including the external limiting membrane; and 2) nonconforming pattern – excavations that involved only the retinal pigment epithelium (RPE).

Recently, a case report of FCE associated with Vogt–Koyanagi–Harada (VKH) disease has been published,¹³ which documented cross-sectional observation. Here we describe a clinical course of FCE associated with VKH before and after treatment and compare the morphological findings of FCE in four subjects with different chorioretinal conditions.

Case report

A 55-year-old man (subject 1) presented with bilateral metamorphopsia, with decimal visual acuity being 0.8 in the right eye and 1.2 in the left. The clinical diagnosis of VKH was made based on bilateral panuveitis and multifocal exudative retinal detachments at the posterior poles (Figure 1). High-dose corticosteroid therapy with gradual tapering was initiated 3 days after presentation. The serous detachments entirely resolved within 9 weeks and visual acuity in the right eye improved to 1.2.

Serial spectral-domain OCT (SD-OCT) images obtained at the preuveitic, uveitic, and posttreatment phase are shown in Figure 2. SD-OCT obtained 1 year before

Correspondence: Kaoru Fujinami
Laboratory of Visual Physiology,
National Institute of Sensory Organs,
National Tokyo Medical Center,
2-5-1 Higashigaoka, Meguro-ku,
Tokyo 152-8902, Japan
Tel +81 3 3411 0111
Fax +81 3 3411 0185
Email kfj21kfj21kfj21@kmf.biglobe.ne.jp

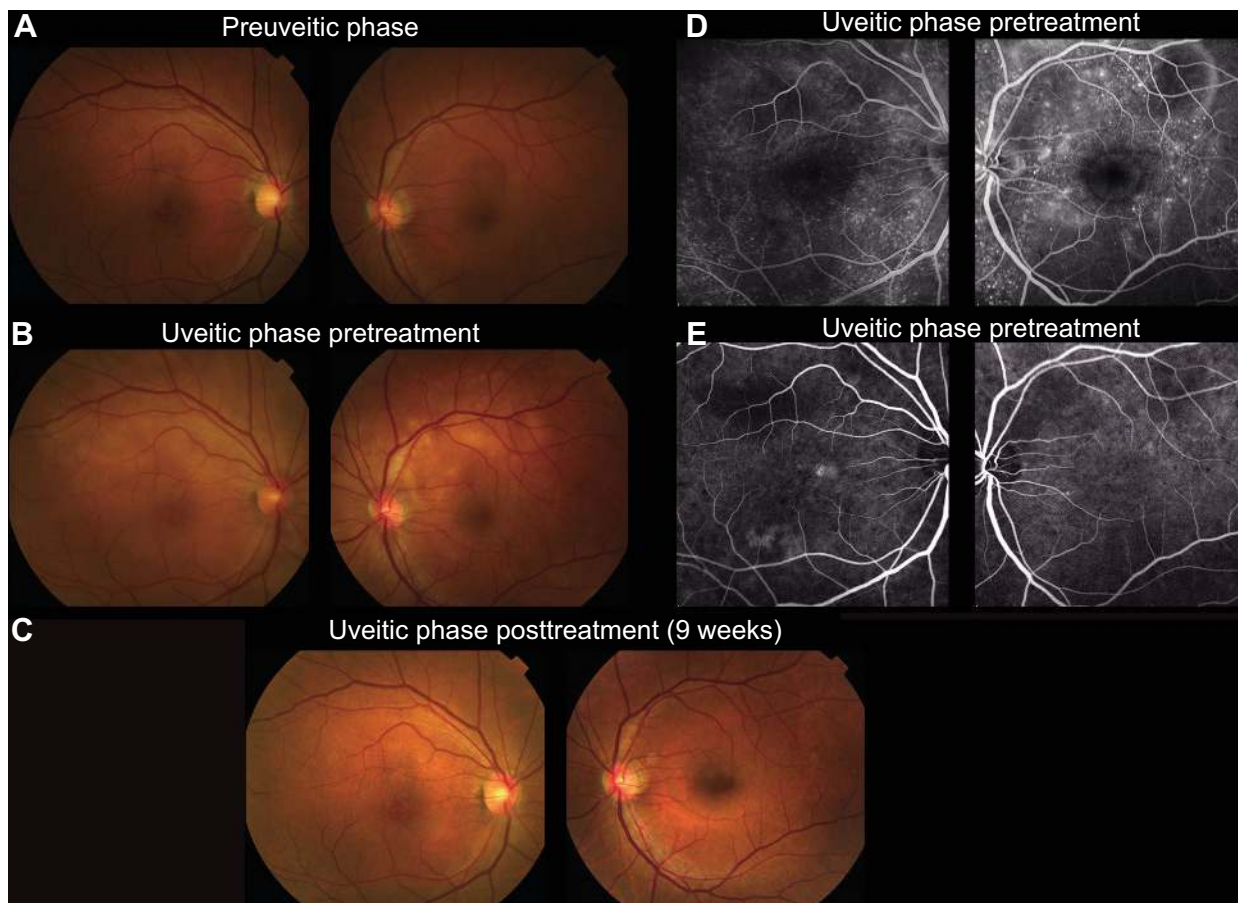


Figure 1 Fundus photographs, fluorescein angiograms, and indocyanine green angiograms of a case with Vogt-Koyanagi-Harada disease (subject 1).

Notes: (A) Fundus photography at preuveitic phase (1 year before the onset of uveitis) showed subtle RPE disturbance at the fovea in the right eye with normal findings in the left eye. (B) At the onset, fundus photography revealed bilateral multifocal exudative retinal detachments throughout the posterior pole in each eye, with the subtle RPE disturbance unchanged in the right eye. (C) Nine weeks after treatment, the exudative detachments had resolved in each eye. (D) Fluorescein angiography at the onset demonstrated multiple punctate hyperfluorescent lesions and multilobular pools of subretinal dye in each eye. (E) Indocyanine green angiography at the onset identified multiple hypofluorescent spots in each eye with a hyperfluorescent lesion at the superior nasal fovea.

Abbreviation: RPE, retinal pigment epithelial.

the onset of VKH due to symptoms of a floater and visual disturbance demonstrated a dome-shaped posterior protrusion of the RPE and outer retinal layers into the choroidal cavity (ie, conforming FCE) at the fovea in the right eye. SD-OCT at the uveitic phase identified multiple bilateral sensory retinal detachments, with the FCE now involving only the RPE (ie, nonconforming FCE). Nine weeks after the treatment, the nonconforming FCE returned into a conforming pattern.

The FCE pattern and its alteration during treatment of the case with VKH were compared to those of four subjects with FCE associated with other chorioretinal conditions (Figure 3). This comparison group consisted of two patients with age-related macular degeneration (AMD; subjects 2 and 3), one subject with a macular hole (MH; subject 4), and one asymptomatic individual (subject 5). Treatment with intravitreal ranibizumab injections and vitrectomy had been performed in the patients with AMD and MH, respectively.

A conforming FCE was observed in three patients (subjects 2, 3, and 5) and pattern alteration from nonconforming to conforming FCE was found after treatment in one subject (subject 4). In the two subjects with AMD, a hyperreflective material around the FCE was absorbed, resulting in a well-demarcated conforming FCE after treatment.

Discussion

A detailed clinical course of FCE at the fovea was documented in a case with VKH disease. SD-OCT images obtained at the preuveitic, uveitic, and posttreatment phase suggested the preexistence of FCE before the onset of VKH, and the FCE pattern change (from conforming to nonconforming pattern during the period of choroidal inflammation) was observed during the follow-up.

The FCE identified at the preuveitic phase in our case supported the congenital/acquired posterior pole

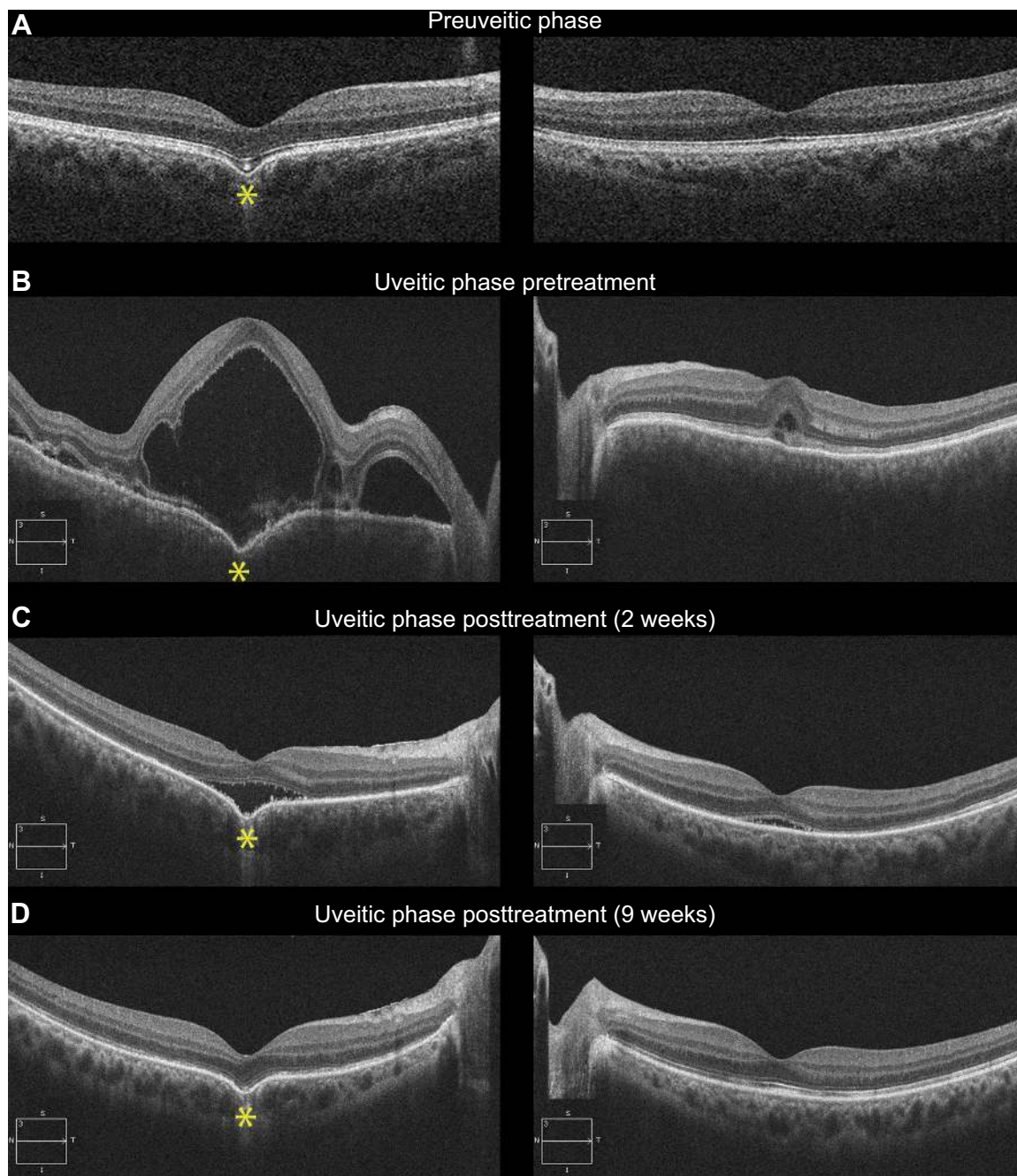


Figure 2 Serial spectral-domain optical coherence tomographic images of a case with Vogt–Koyanagi–Harada disease (subject 1).

Notes: (A) Spectral-domain optical coherence tomography at the preuveitic phase (1 year before the onset) showed a dome-shaped posterior protrusion of the hyperreflective bands of the RPE and outer retinal layers into the choroidal cavity (ie, conforming pattern of FCE) at the fovea in the right eye, with normal findings in the left eye (FCE asterisk). (B) At the onset, multiple bilateral sensory retinal detachments were demonstrated in each eye, with the FCE involving only the RPE (ie, nonconforming FCE) (FCE asterisk). (C) Two weeks after treatment, the serous detachments had partially resolved, with residual subretinal fluid at the fovea in each eye, with a nonconforming FCE at the right fovea (FCE asterisk). (D) Nine weeks after treatment, the serous detachments had entirely resolved, resulting in the reappearance of a conforming FCE at the right fovea (FCE asterisk).

Abbreviations: FCE, focal choroidal excavation; RPE, retinal pigment epithelium.

malformation, as previously suggested.^{1,4,9,11,12} On the other hand, Hashida et al¹³ speculated that a direct pressure effect on the choroidal layer by subretinal fibrin disrupted the choroidal integrity and focal choroidal atrophy/thinning following inflammation and resulted in a formation of FCE in a case

with VKH.^{4,7,13} Although such a remarkable subretinal fibrin was not detected, the association between the FCE formation and choroidal inflammation could not be excluded entirely in our case, considering other possible subclinical inflammatory events prior to this disease history.

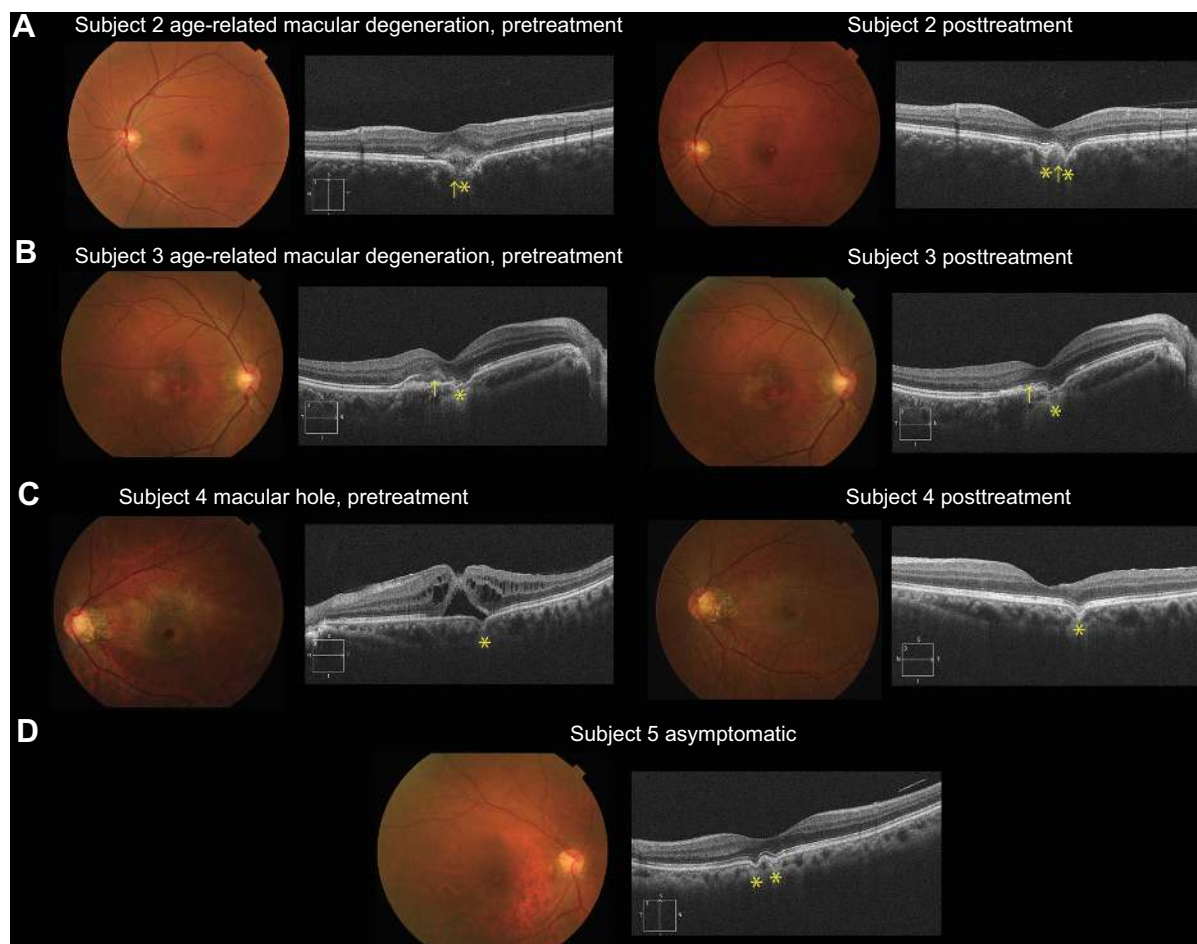


Figure 3 Fundus photographs and spectral-domain optical coherence tomographic images of four cases with focal choroidal excavation (subjects 2, 3, 4, and 5).

Notes: (A) Subject 2 (54-year-old man with age-related macular degeneration): Fundus photography at onset showed subtle RPE disturbance at the fovea, and SD-OCT demonstrated an FCE filled with a hyperreflective material (left; FCE asterisk; material arrowed). After treatment with intravitreal ranibizumab injections, a juxtafoveal hypopigmented spot was seen surrounded by RPE disturbance; the hyperreflective material in the FCE had been absorbed and a well-demarcated conforming FCE was observed (right; FCE asterisk; absorbed material arrowed). (B) Subject 3 (67-year-old man with age-related macular degeneration): Fundus photography at onset revealed subtle RPE disturbance at the fovea surrounded by a hypopigmented area at the macula; SD-OCT detected a FCE and subretinal hyperreflective material above the irregular RPE (left; FCE asterisk; material arrowed). After intravitreal ranibizumab injections, the fundus appearance had not changed and a conforming FCE was clearly observed with the irregular RPE (right; FCE asterisk; absorbed material arrowed). (C) Subject 4 (55-year-old woman with macular hole): Fundus photography showed a hyperreflective membrane at the macula with RPE loss at the fovea; SD-OCT demonstrated an impending MH with retinoschisis and a juxtafoveal nonconforming FCE (left; FCE asterisk). After vitrectomy, the MH had sealed following removal of vitreomacular traction and a conforming FCE was observed (left; FCE asterisk). (D) Subject 5 (72-year-old asymptomatic woman): Fundus photography revealed no abnormalities and SD-OCT detected conforming FCEs at the fovea (left; FCE asterisk).

Abbreviations: FCE, focal choroidal excavation; MH, macular hole; RPE, retinal pigment epithelium; SD-OCT, spectral-domain optical coherence tomography.

An alteration of the FCE pattern observed in VKH was also found in the comparison group with other chorioretinal conditions. In subject 4 with an MH, the nonconforming FCE at presentation associated with vitreomacular traction changed to conforming FCE after treatment. In two subjects with AMD, a hyperreflective material around the FCE was observed to be absorbed, resulting in a well-demarcated conforming FCE via treatment (subjects 2 and 3). These findings suggest that the cavity within FCE can be filled with subretinal fluid associated with inflammation and exudative material generated by choroidal neovascularization. The decreased adhesion within the FCE between RPE and

photoreceptor could complicate MHs. Given the proximity between the FCE and the active lesions, the involved retina around the active lesion may well show disorganization of retinal layers in the pathological process; then the conforming pattern is hard to maintain, unsurprisingly. In addition, it is possible that the cavity within FCE may potentially accelerate the pathophysiological changes of chorioretinal disorders.

Acknowledgments

This research was supported in part by research grants from the Ministry of Health, Labor and Welfare, Japan and Grant-in-Aid for Scientific Research from Japan Society for the

Promotion of Science. KF is supported by a Grant-in-Aid for Young Scientists (B) of the Ministry of Education, Culture, Sports, Science and Technology (Japan). The sponsor or funding organization had no role in the design or conduct of this research.

Disclosure

The authors have no proprietary or commercial interest in any materials discussed in this article. The authors report no other conflicts of interest in this work.

References

- Jampol LM, Shankle J, Schroeder R, Tornambe P, Spaide RF, Hee MR. Diagnostic and therapeutic challenges. *Retina*. 2006;26(9):1072–1076.
- Wakabayashi Y, Nishimura A, Higashide T, Ijiri S, Sugiyama K. Unilateral choroidal excavation in the macula detected by spectral-domain optical coherence tomography. *Acta Ophthalmol*. 2010;88(3):e87–e91.
- Margolis R, Mukkamala SK, Jampol LM, et al. The expanded spectrum of focal choroidal excavation. *Arch Ophthalmol*. 2011;129(10):1320–1325.
- Ellabban AA, Tsujikawa A, Ooto S, et al. Focal choroidal excavation in eyes with central serous chorioretinopathy. *Am J Ophthalmol*. 2013;156(4):673–683.
- Obata R, Takahashi H, Ueta T, Yuda K, Kure K, Yanagi Y. Tomographic and angiographic characteristics of eyes with macular focal choroidal excavation. *Retina*. 2013;33(6):1201–1210.
- Say EA, Jani PD, Appenzeller MF, Houghton OM. Focal choroidal excavation associated with polypoidal choroidal vasculopathy. *Ophthalmic Surg Lasers Imaging Retina*. 2013;44(4):409–411.
- Lee CS, Woo SJ, Kim YK, et al. Clinical and spectral-domain optical coherence tomography findings in patients with focal choroidal excavation. *Ophthalmology*. 2014;121(5):1029–1035.
- Or C, Forooghian F. Vitelliform focal choroidal excavation. *Ophthalmic Surg Lasers Imaging Retina*. 2014;45 Online:e26–e28.
- Xu H, Zeng F, Shi D, Sun X, Chen X, Bai Y. Focal choroidal excavation complicated by choroidal neovascularization. *Ophthalmology*. 2014;121(1):246–250.
- Parodi MB, Zucchiatti I, Fasce F, Bandello F. Bilateral choroidal excavation in best vitelliform macular dystrophy. *Ophthalmic Surg Lasers Imaging Retina*. 2014;45 Online:e8–e10.
- Suzuki M, Gomi F, Hara C, Sawa M, Nishida K. Characteristics of central serous chorioretinopathy complicated by focal choroidal excavation. *Retina*. 2014;34(6):1216–1222.
- Lee JH, Lee WK. Choroidal neovascularization associated with focal choroidal excavation. *Am J Ophthalmol*. 2014;157(3):710–718.e1.
- Hashida N, Fok A, Nishida K. Choroidal excavation in vogt-koyanagi-harada disease. *Case Rep Ophthalmol*. 2014;5(2):222–225.

Clinical Ophthalmology

Publish your work in this journal

Clinical Ophthalmology is an international, peer-reviewed journal covering all subspecialties within ophthalmology. Key topics include: Optometry; Visual science; Pharmacology and drug therapy in eye diseases; Basic Sciences; Primary and Secondary eye care; Patient Safety and Quality of Care Improvements. This journal is indexed on

Submit your manuscript here: <http://www.dovepress.com/clinical-ophthalmology-journal>

Dovepress

PubMed Central and CAS, and is the official journal of The Society of Clinical Ophthalmology (SCO). The manuscript management system is completely online and includes a very quick and fair peer-review system, which is all easy to use. Visit <http://www.dovepress.com/testimonials.php> to read real quotes from published authors.