

Clinical Delivery System for Intraperitoneal Hyperthermic Chemotherapy

John S. Spratt,¹ Robert A. Adcock, Marie Muskovin, William Sherrill, and John McKeown

Department of Surgery, Section of Surgical Oncology [J. S. S.], Price Institute of Surgical Research [R. A. A., W. S.], The Cancer Center [M. M.], University of Louisville, Louisville, Kentucky 40202

ABSTRACT

A 35-year-old man was treated for pseudomyxoma peritonei by surgery and by thermal infusion and chemotherapy with a machine designed specifically for the treatment of cancers of serosal surfaces. After extensive abdominal resection and closure, the patient's peritoneal cavity was instilled with 2.5 liters of 5% lactated Ringer's solution. He was then attached to hyperthermic perfusion system which elevated the i.p. temperature by warming (to 42°) and recirculating the effusion solution. When the 42° i.p. temperature was attained (after 1.5 hr), chemotherapy was added to the recirculating effusion. A second procedure followed 8 days later.

The patient's postoperative course was uneventful except for minor pulmonary atelectasis with bacteremia. Hyperthermic perfusion was tolerated well and was evaluated as safe for intracavitary cancer treatment.

INTRODUCTION

A major problem encountered in cancer management is the development of peritoneal and pleural effusions. These effusions have been variably managed by aspiration with needle or drainage tubes, intracavitary injection of radionuclides and chemotherapeutic agents, diuretics, systemic chemotherapy, and restriction of salt and water intake. The effusions are a source of significant morbidity to the host from the discomfort of distention, restriction of pulmonary reserve, frequency of recurrence after treatment, intestinal dysfunction, and protein loss, and they contribute to the early demise of the patient. These effusions occur from cancers arising from many organs capable of growing on serosal surfaces by extension or metastasis. Also, serosal surface cancer implantation and growth can occur in the absence of effusions. When this is predictable based on the characteristics of the cancer or when serosal implantation is diagnosed before the serosal space is obliterated by cancer and adhesions, intracavitary treatment is possible. A previous study on pseudomyxoma peritonei stimulated the present work.

A new delivery system for intracavitary treatment has been developed and has undergone preliminary evaluation (11). The first model of TIFS² was designed and constructed by Dr. Charles E. Dunlap and Dr. Stanley R. Bull at the University of Missouri, Columbia, in response to performance specifications of Dr. John S. Spratt, and is described by Palta (8).

Pertinent characteristics of the pathophysiology of malignant ascites have been presented (1, 2, 7, 9), as have been the effects of induced hyperthermia (5). The administration of peritoneal chemotherapy (4, 9, 12) and the therapeutic potential of hyperthermia and cancer (13-15) have also been pre-

sented.

A system for the management and removal of intracavitary effusions should incorporate the methods of treatment which have been described as well as new and potentially effective methods beneficial to the patient.

The treatment should be: (a) effective against the anatomical, physical, and pathological conditions of the intracavitary compartments; (b) effective in applying the current knowledge of hyperthermia and adjunctive chemotherapy; (c) capable of removing and filtering malignant debris; and (d) safe for chronic treatment programs.

MATERIALS AND METHODS

The TIFS was designed to manage aseptically intracavitary effusions through the combined actions of dynamic fluid flow, free-cell and debris filtration, hyperthermia, and adjunctive pharmacotherapy. The unit is designed to remove, infuse, or recirculate fluids of manageable viscosity. The current system is driven by a Cole-Parmer Model 7555-40 variable-speed pump (Cole-Parmer Instrument Co., Chicago, Ill.) accommodating 0.952-cm outside diameter (0.635-cm inside diameter) Tygon medical grade tubing. It passes the fluid stream through a sequential dual-filter system and a subsequent warming coil and conduit from which it may be passed or recontained. The sequential dual-filter system is composed of a 40- μ m Pall SQ40 blood transfusion filter (Pall Corporation, Glen Cove, N. Y.) and a 3- μ m Gelman 12104 filter (Gelman Instrument Co., Ann Arbor, Mich.). The blood transfusion filter was incorporated to protect the main filter from clogging by large clots. The filter elements are presterilized and disposable with inlet and outlet tubing for aseptic operation. The filter system has a combined surface area of 1700 sq cm and is suitable for the largest effusion volumes (approximately 5 liters) to be processed in a reasonably short time. An Abbott Model 4663 disposable blood-warming coil (Abbott Laboratories, North Chicago, Ill.) placed in a circulating water bath (B. Braun Instruments, San Mateo, Calif.) provides the heat exchange surface. Temperature controls maintain the circulating fluid at a constant temperature. Heat is provided by B. Braun Models 1450 immersion and 1460 booster heaters. A B. Braun Model 1430 temperature safety monitor overrides the heating system if present maximum temperatures are exceeded by 0.5° within the range of 30-50°. A schematic of the TIFS is presented in Chart 1.

CASE REPORT

The treated patient was a 35-year-old man with a 2-year history of early satiety and abdominal distention. Initially, after a nondiagnostic examination, he underwent an exploratory laparotomy. After his abdomen was opened, extensive mucin was evacuated, and an omental biopsy was taken. On a limited exploration, no primary tumor was found. Histopathological

¹ To whom requests for reprints should be addressed.

² The abbreviations used are: TIFS, thermal infusion filtration system; CEA, carcinoembryonic antigen.

Received July 25, 1979; accepted October 24, 1979.

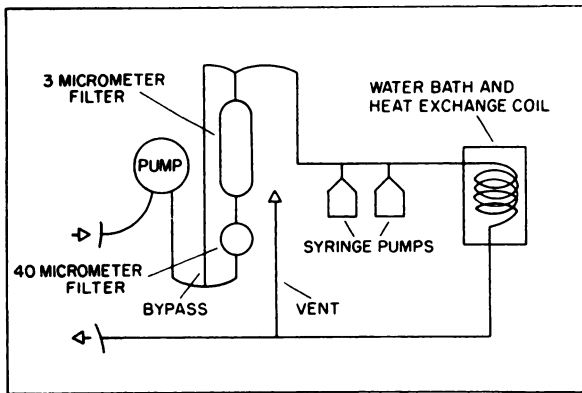


Chart 1. Flow schematic of the thermal infusion filtration system. Arrows, direction of fluid flow.

examination disclosed a low-grade adenocarcinoma (pseudomyxoma peritonei) with many mucin-containing cysts lining the peritoneum. The surgery provided some symptomatic relief. However, in less than 1 year, his abdominal girth began to increase and symptoms recurred. His admitting examination was completely within normal limits except for obvious moderate abdominal distention (girth at umbilicus, 80 cm; weight, 63 kg) and a CEA value of 126.5 ng/ml. His preoperative evaluation included an exercise tolerance test to evaluate his tolerance to hyperthermia.

Anecdotally, the patient (C. L. of Oregon, Norton-Children's Hospital No. 62 24 22 4) contacted Dr. Spratt by phone in November 1978 after reading a 1969 paper located on a MEDLARS search (6). He had contacted all major cancer centers regarding treatment of pseudomyxoma peritonei and had been given no encouragement. At the time of contact, TIFS had been constructed, and the mechanical and dog runs had been completed. He insisted on being the first patient to be run on TIFS at his own expense. His extensive reading on pseudomyxoma peritonei had made him very knowledgeable on his problem, and he interrogated us extensively at each step of the planning and in the postoperative period.

At operation on February 24, 1979, general endotracheal anesthesia was induced. A Swan-Ganz catheter was inserted to monitor cardiac output. Thermal probes were placed in the esophagus and rectum. At closure and before thermal perfusion and chemotherapy, a third probe was placed directly into the peritoneal cavity. A Foley catheter was inserted to monitor urinary output. The laparotomy was carried out through the midline, excising *en bloc* his previous laparotomy scar.

The peritoneal cavity was again found to contain extensive mucin. The omentum was thickened. The extensive mucin and peritoneal seeding obscured visibility, and the exploration proceeded cautiously. The appendix was found to be intact, but a mass was first thought to be present at the base. The mesentery of the transverse colon was also thickened. Pathology verified the extensiveness of the neoplasm. The gelatinous fluid in his abdomen contained numerous low-grade mucin-producing adenocarcinoma cells. The appendix was normal but had neoplasm on its serosal surface. Multiloculated mucin-filled cysts lined with low-grade mucin-producing adenocarcinoma were extensively present in the omentum, transverse mesocolon, hilus of the spleen, distal pancreas, splenic flexure, and peritoneal cavity. When the entire distribution of tumor was re-

viewed, the pathologist concluded that the pancreas was the organ of origin and that the primary cancer was a cystadenocarcinoma of the pancreas (3). The gross distribution of tumor was such that the bulk could be resected by removing the ascending colon, the transverse colon and the omentum. Upon entering the lesser peritoneal sac and attempting to mobilize the splenic flexure, extensive involvement by mucin and mucinous tumor cysts was encountered in the lesser peritoneal sac, distal pancreas, splenic pedicle, and left subphrenic space. The surgical resection was then extended to include the spleen and the distal pancreas. The intestine was anastomosed by an end-to-end ileo-descending colostomy with approximation of the adjacent mesentery. On completion of this resection, the peritoneum was studded extensively with mucin-producing tumor although the grosser masses were all removed. Glisson's capsule was involved superficially, but no metastasis to the hepatic parenchyma was evident.

Two Argyle Saratoga Model 28 sumps (Sherwood Medical Industries, Inc., St. Louis, Mo.) were inserted through the smallest incision that would accommodate them, and an O-chromic catgut purse-string suture (Ethicon, Inc., Somerville, N. J.) was placed around their peritoneal entry point to minimize leakage. One catheter was placed in the upper left quadrant with the end laid into the left subphrenic region. The second was placed in the lower right quadrant with the end placed on the pouch of Douglas. The midline abdominal incision was then closed to the peritoneum with continuous O-chromic catgut and to the fascia with figure-of-8 No. 28 stainless steel wire sutures (Ethicon). The skin was closed with interrupted 4-0 silk (Ethicon).

The 2 catheters were then attached to the TIFS unit for immediate perfusion filtration of remaining i.p. cells and debris. The peritoneal cavity was primed with lactated Ringer's solution (2.5 liters), and the temperature of the cycling fluid was conservatively elevated every 15 min for 1.5 hr until the thermal probe directly in the peritoneal cavity reached 42°. His rectal temperature reached 39.5° after 1.5 hr. During a remaining 15-min interval, the filter unit was bypassed, and 105 mg of *N, N', N''*-triethylenethiophosphoramidate (thiotepa; Lederle Laboratories, Pearl River, N. Y.) were administered (1175 sq m × 60) in the line going directly to the peritoneal cavity. After perfusion, the catheters were left in place. The patient's postoperative course was uncomplicated.

The protocol called for i.p. amethopterin (methotrexate; Lederle) therapy 5 days after administration of the thiotepa. Under light general anesthesia, the Saratoga sumps were then reattached to the TIFS. The system was again primed with 2.5 liters of lactated Ringer's solution, and the temperature was steadily elevated. When the temperature of the peritoneal fluid stabilized at 42°, methotrexate (75 mg) was administered. The perfusion was then continued for 30 min, and methotrexate levels in the perfusate and in the serum were measured at 5, 15, and 30 min. After treatment, the peritoneal cavity was drained of residual fluid, and the Saratoga sumps were removed. Thiotepa levels were not determined.

The chemotherapy protocol was designed to give a cell cycle-nonspecific agent (thiotepa), followed 5 days later with a cell cycle-specific agent (methotrexate). Thiotepa was chosen because of its previously demonstrated safety with i.p. use (4). A full systemic dose of 60 mg/sq m was infused. Methotrexate, 40 mg/sq m, was then administered on Day 5. Mild

Table 1
Laboratory values

	Sodium (mEq/liter)	Potassium (mEq/liter)	Chlorine (mEq/liter)	Carbon dioxide (mEq/liter)	Alkaline phosphatase (g/100 ml)	Total pro- tein (g/ 100 ml)	Albumin (g/100 ml)	Glucose (mg/100 ml)	CEA (ng/ml)	Hemoglobin (mg/100 ml)	Hematocrit (vol. %)	Platelets ($\times 10^5/cm$)	Wt. (kg)	5-min ex- ercise tolerance (beats/ min)
Preoperative ^a	145	5.1	105	29	71	8.5	4.4	98	126.5	15	43.9	4.8	65.3	170
Postoperative range ^b	133-134	3.6-4.3	97-106	21-31	66-84	4.2-6.2	2.1-2.9	93-137	105 ^c	2.7-13.1	24.7-37.9	2.0-5.9	55.8-70.3	—
Discharge ^d	143	4.2	98	29	107	6.1	2.8	112	22.6	11.7	36.2	7.6	55.8	102

^a Values are those of 1 day before surgery.

^b Values are the ranges of 13 days after surgery.

^c Value at fifth day after surgery.

^d Values are those of 21 days after surgery.

hematological suppression was seen on Day 4, but the blood counts returned to normal by Day 5. No systemic effects were noted with the methotrexate.

RESULTS

Pertinent laboratory data were obtained before, during, and after the surgical and perfusion procedures and are presented in Table 1. Preoperative values were taken the day before surgery. Postoperative ranges are those values recorded for 13 days after the first hyperthermic treatment. The discharge values are those on the 21st day after surgery.

No satisfactory method for determining differential concentrations of thiotepa in the perfusate and the serum existed. However, the differential methotrexate concentrations were determined during the second hyperthermic treatment and are presented in Table 2. There was a 1000-fold difference between the 2 compartments (peritoneal fluid and serum) at each 5-min interval up to 30 min.

The patient's postoperative course was uneventful except for a minor pulmonary atelectasis with bacteremia following the second hyperthermic treatment. He was normothermic 48 hr after each treatment.

In spite of the extensive intraabdominal resection, the patient's body weight after the first perfusion (63.0 kg) was the same as on admission. His weight increased to 69.8 kg after the second perfusion. This increase suggests a retained edema. His weight did drop to 55.3 kg at discharge. Several units of serum albumin were administered during the postoperative period to return serum albumin levels to normal and to mobilize peritoneal edema. Albumin levels dropped acutely.

During the 1.5-hr period of hyperthermia, i.p. debris was being filtered by the sequential 40- and 3- μ m filters in the system. These filters were bypassed during chemotherapy. Significant debris accumulated in both the 40- μ m prefilter and 3- μ m cell filter. There was no attempt to quantify the recovery of cells at this time. The cells were identified as mesothelial, but no differentiation of reactant normal *versus* malignant cells was possible cytologically. No attempt was made to culture cells at this time.

The pulsatile flow of the circulating effusion during both treatments was 15 liters/hr. This rate appeared to be tolerated well by the patient. There was no hemorrhage apparent after 24 hr. The hyperthermia did not induce any shock or hyperpyrexia.

DISCUSSION

This treatment plan consisted of the administration of a non-cycle-specific agent (thiotepa) followed 5 days later by the

Table 2
Methotrexate concentration during hyperthermic perfusion

Seventy-five mg of methotrexate were instilled into perfusate at 0 time. The time at which chemotherapy was administered was approximately 1.5 hr after perfusion began in both the first and second treatments.

Time after administration (min)	Concentration of methotrexate (ng/ml)	
	Blood ($\times 10^{-7}$)	Perfusate ($\times 10^{-4}$)
5	2.4	1.76
15	7.5	1.59
30	9.9	1.08

cycle-specific agent methotrexate with i.p. hyperthermia. Methotrexate has been used by Dedrick *et al.* (4) adjunctive to peritoneal dialysis. Since low-grade cancers such as pseudomyxoma peritonei generally show poor response to systemic chemotherapy, this chemotherapeutic rationale was considered feasible and at least as effective as systemic treatment. The presence of methotrexate in the serum during the procedure indicated absorption from the peritoneal perfusate. The concentration of the peritoneal perfusate, however, was 1000 times greater than that of the serum. This indicated a margin of safety to the patient with regard to the toxic effects of methotrexate.

We did not anticipate any undesirable effects upon the patient at 42° peritoneal hyperthermia since our own experience in the laboratory and Larkin's (5) experience indicated this range to be safe for up to 2 hr. In fact, no ill effects became apparent. Prior exercise tolerance determined that the patient could withstand a stress pulse of 170 beats/min for 5 min. The maximum cardiac rate induced during the procedure was 145 beats/min, well below his stress tolerance. Preoperative stress tests should be done routinely before the induction of hyperthermia to determine the maximum pulse rate tolerable to the cardiovascular conditioning of the individual patient. In this patient, the planned level of hyperthermia was reached at a much lower heart rate. That safety margin might not always be present. The patient's postoperative course was uncomplicated.

The question of therapeutic efficacy of TIFS is at present academic. The advantage of treatment awaits further application and subsequent short- and long-term assessment. Because of the great distance (Oregon to Louisville), follow-up monitoring has not been as close as desired. Also, we would have preferred to develop a protocol for periodic retreatment as indicated by rising CEA values. However, the patient remains active and comfortable and is at work with no recurring symptomatology 8 months after treatment (October 5, 1979). Although his laboratory chemistry and hematological parameters have remained normal, his CEA value remains consistently higher than normal, suggesting continued activity of the pseudomyxoma peritonei. CEA values (ng/ml) were: February 14, 1979, 105; February 23, 1979, 22.6; April 19, 1979, 79; and September 7, 1979, 161.

As experience with the TIFS unit increases, models of treatment may be developed to provide effective hyperthermic chemotherapy of other neoplasms of the abdominal cavity that are known to have a high probability for local or regional recurrence. The immediate postoperative period in these high-risk cases might even be the optimum time for use since tumor burden would be minimal during this period.

The application of TIFS to treatment of cancers of the pleural cavity appears feasible and remains to be explored in the laboratory.

In addition to the promise of hyperthermia, 2 mechanical considerations of the unit make its potential appealing for the treatment of i.p. cancers: (a) the fluid dynamics of the system is intended to provide maximal fluid-surface contact with the peritoneal compartments while minimizing effects of irritation; (b) the mechanical filtration process should, hypothetically, permit the removal of malignant cells which may be free floating or shed from the surface of the serosa by virtue of the fluid momentum as it passes through the intracavitary environment.

There is considerable evidence which supports a therapeutic advantage to removal of neoplastic cells since free-floating cells are viable in ascitic media. This is especially true in pleural effusions.

TIFS could also be used for high-dose intracavitary antibiotic therapy for peritonitis by taking advantage of its filtration system to remove bacteria. This approach has already shown benefit with a much cruder and less versatile system than TIFS (12).

Dedrick *et al.* (4) recently took a more studied look at the administration of i.p. chemotherapy. They noted that pharmacokinetic calculations indicate that hydrophilic anticancer drugs administered i.p. in large volumes may be expected to maintain a significantly greater concentration in the peritoneal space than in the plasma. They considered that this concentration difference was adequate to offer a potentially exploitable biochemical advantage in the treatment of patients with presumed microscopic residual ovarian cancer confined to the peritoneal cavity.

Their model has many of the characteristics of TIFS. Tumors treated must be of small thickness, and large volumes of drug-containing solution must be used to ensure exposure of the entire peritoneal surface. Care must be exercised to avoid the coadministration of drugs which might lessen either hepatic or renal clearance of the chemotherapeutic agent, and its ratio of plasma clearance to peritoneal permeability should be high. The added impact of hyperthermia to such a system needs further study.

Considerable development remains to be done in areas of hyperthermia and cancer management. The integrated design of this unit represents a step in this needed technology.

ACKNOWLEDGMENTS

The authors wish to express their appreciation to Dr. Larry Clark, clinical chemistry; Dr. Herbert Reiman, pathology; Drs. George Webb and Michael Woodward, anesthesiology; and the operating room staff of Norton-Children's Hospital, Louisville, Ky.

REFERENCES

1. Bronskill, M. J., Bush, R. S., and Ege, G. N. A quantitative measurement of peritoneal drainage in malignant ascites. *Cancer (Phila.)*, 40: 2375-2380, 1977.
2. Cailleua, R., Mackay, B., Young, R. K., and Reeves, W. J. Tissue culture studies on pleural effusions from breast carcinoma patients. *Cancer Res.*, 34: 801-809, 1974.
3. Compagno, J., Oertel, J. E. Mucinous cystic neoplasms of the pancreas with overt and latent malignancy (cystadenocarcinoma and cystadenoma). A clinical pathology study of 41 cases. *Am. J. Clin. Pathol.*, 69: 573-580, 1978.
4. Dedrick, R. L., Myers, C. E., Bungay, P. M., and DeVita, V. T., Jr. Pharmacokinetic rationale for peritoneal drug administration in the treatment of ovarian cancer. *Cancer Treat. Rep.*, 62: 1-11, 1978.
5. Larkin, J. M., Edwards, W. S., Smith, D. E., and Clark, P. J. Systemic chemotherapy: description of a method and physiologic tolerance in clinical subjects. *Cancer (Phila.)*, 40: 3155-3159, 1977.
6. Long, R. T., Spratt, J. S., and Dowling, E. Pseudomyxoma peritonei. *Am. J. Surg.*, 117: 162-169, 1969.
7. Meyers, M. S. Distribution of intra-abdominal malignant seeding. Dependence on dynamics of flow of ascitic fluid. *Am. J. Roentgenol. Radium Ther. Nucl. Med.*, 119: 198-206, 1973.
8. Palta, J. R. Design and Testing of a Therapeutic Infusion Filtration System. M. S. thesis, University of Missouri, Columbia, Mo., 1977.
9. Rosato, F. E., and Wallach, M. W. The management of malignant effusions from breast cancer. *J. Surg. Oncol.*, 6: 441-449, 1974.
10. Shingleton, W. W., Parker, R. T., and Mahaley, S. Abdominal perfusion for cancer chemotherapy with hypothermia and hyperthermia. *Surgery*, 50: 260-265, 1961.
11. Spratt, J. S., Adcock, R. A., Sherrill, W., and Travathen, S. Hyperthermic

- peritoneal perfusion system in canines. *Cancer Res.*, *40*: 253–255, 1980.
12. Stephen, M., and Loewenthal, J. Continuing peritoneal lavage in high risk peritonitis. *Surgery*, *85*: 603–606, 1979.
 13. Titscher, R., Kokron, O., and Ketnansky, K. Local therapy of malignant pleural effusion. *Neoplasma (Bratisl.)*, *21*: 465–469, 1974.
 14. vonArdeene, M., and Reitnaur, P. G. The amplification of the selective tumor acidification by local hyperthermia. *Naturwissenschaften*, *65*: 159–160, 1978.
 15. vonArdeene, M., and Reitnaur, P. G. Supplementary information on pH, hyperthermia and cell survival. Tumor hyperacidification and multistep cancer therapy (letter). *J. Natl. Cancer Inst.*, *67*: 3–4, 1978.