

# Clinical implications of sonographic detection of uterine anomalies for reproductive outcome

S. KUPESIC

Department of Obstetrics and Gynecology, Medical School University of Zagreb, Sveti Duh Hospital, Zagreb, Croatia

**KEYWORDS:** Hysteroscopy, Obstetric complications, Reproductive outcome, Saline contrast sonohysterography, Septate uterus, Three-dimensional ultrasound, Transvaginal color Doppler, Uterine anomalies

## ABSTRACT

*The purpose of this review article was to analyze the literature on the prevalence, diagnosis and treatment of the congenital uterine anomalies and to discuss current dilemmas on their influence on reproductive outcome. Congenital uterine anomalies are commonly associated with repeated pregnancy failure, in particular an increased risk of first- and second-trimester miscarriages and preterm delivery. Recent reports on two-dimensional and three-dimensional transvaginal ultrasound and saline contrast sonohysterography appear promising for diagnosis and classification of congenital uterine anomalies. The ability to visualize both the uterine cavity and the fundal uterine contour on a three-dimensional scan facilitates the diagnosis of uterine anomalies and enables differentiation between septate and bicornuate uteri. Color Doppler ultrasound allows visualization of intraseptal vascularity and may help in distinguishing the avascular from the vascular septum. Less connective tissue in the septum may result in poor decidualization and placentation, while an increased amount of muscle tissue in the septum can cause miscarriage by the production of local uncoordinated myometrial contractility. Hysteroscopic septum excision is an effective procedure which improves live-birth rates. Because of its simplicity, minimal invasiveness, low morbidity and low cost, a more liberal approach to the treatment of uterine anomalies is being advocated.*

## INTRODUCTION

Mechanical factors account for almost 30% of all cases of infertility. Although tubal factors are more common, uterine factors are an important clinical entity<sup>1</sup>. The implantation of the fertilized oocyte is affected by the morphology, thickness and vascularity of the endometrium and by the shape of the uterine cavity. Congenital uterine anomalies vary in frequency and are usually estimated to represent 3–4% in the general population, although less than half of those affected have clinical symptoms<sup>2,3</sup>. During the first trimester of preg-

nancy the risk of spontaneous miscarriage in patients with septate uterus is between 28 and 45%, whereas the frequency of spontaneous miscarriage during the second trimester in these patients is approximately 5%<sup>1,3</sup>. Hysteroscopic septum resection is accompanied by a significant improvement in the reproductive performance of the patients. This review focuses on the diagnosis of and adverse reproductive outcome associated with uterine anomalies. It also discusses clinical dilemmas including the relative value of invasive and non-invasive diagnostic techniques, the value of hysteroscopic surgery, and the role of postoperative ultrasound.

## EMBRYOLOGICAL DEVELOPMENT OF THE UTERUS

Embryologically, the uterus develops from fusion of the paramesonephric ducts, which join in the midline at about the 10th week of gestation to form the unified body of the uterus. Abnormalities in the resorption of the fused midline tissues occur by the 20th week and can result in the formation of uterine septa of variable length and position.

Apoptosis has recently been proposed as a mechanism by which the uterine septum regresses<sup>4</sup>. Bcl-2, a protein involved with regulating apoptosis, was found to be absent from the septa of four uteri using a monoclonal antibody for Bcl-2 and immunohistochemical analysis<sup>4</sup>. The absence of Bcl-2 results in failure of regression of the septum.

The partial uterine septum is limited to the uterine fundus, whereas the complete septum extends from the fundus into the cervical canal<sup>5</sup>. On occasion a longitudinal vaginal septum will also be present. In rare cases cervical duplication may be seen in conjunction with complete uterine and vaginal septa, often confounding attempts at clinical diagnosis<sup>5–7</sup>.

The first case of a complete uterine septum with cervical duplication and a complete longitudinal vaginal septum was recently reported<sup>8</sup>. This was followed by a case report of three sisters with different degrees of septate uterus, one of whom had this abnormality<sup>9</sup> and a further report of three other patients with such an anomaly<sup>10</sup>.

Correspondence: Dr S. Kupesic, Department of Obstetrics and Gynecology, Medical School University of Zagreb, Sveti Duh Hospital, Sveti Duh 64, 10000 Zagreb, Croatia (e-mail: sanja.kupesic@zg.tel.hr)

After these reports, the classic theory of unidirectional (caudal to cranial) Müllerian duct development was challenged and the alternative bidirectional theory was proposed. This theory suggests that fusion and resorption begin at the isthmus and proceed simultaneously in both the cranial and caudal directions<sup>11</sup>. According to the latter theory, septate uterus could develop from failure of fusion of the most caudal Müllerian ducts, resulting in a normal uterine fundus with a complete septum, cervical duplication, and a longitudinal vaginal septum.

Ergun *et al.*<sup>9</sup> reported a rare familial aggregation of septate uteri among three sisters, while Mikkilä *et al.*<sup>12</sup> described the X-linked laterality sequence in a family with carrier manifestations.

## CLASSIFICATION OF UTERINE ANOMALIES

The American Fertility Society<sup>5</sup>, based on the previous work of Buttram and Gibbons<sup>13</sup>, classified the anomalies of the female reproductive tract into groups according to the degree of failure of normal development with similar clinical manifestations, treatment, and possible prognoses for their reproductive performance<sup>14</sup>. The various Müllerian anomalies are the consequence of four major disturbances in the development of the female genital system during fetal life:

- 1 failure of one or more Müllerian ducts to develop (agenesis, unicornuate uterus without rudimentary horn);
- 2 failure of the ducts to canalize (unicornuate uterus with rudimentary horn without proper cavities);
- 3 failure to fuse or abnormal fusion of the ducts (uterus didelphys, bicornuate uterus);
- 4 failure of resorption of the midline uterine septum (septate uterus, arcuate uterus).

## PREVALENCE

Congenital Müllerian defects are a fascinating clinical problem encountered by obstetricians. The true incidence in the general population is hard to determine for two main reasons: most data are derived from studies of patients presenting with reproductive problems, and accurate diagnosis and complete assessment of the uterine morphology have not always been performed. In addition, an analysis of the reproductive performance of women with malformed uteri needs to take into account not only those presenting with reproductive failure but also those who are asymptomatic and with normal reproductive outcome. Raga *et al.*<sup>15</sup> have collected the results of women who at some point decided to stop their reproductive life, plus those patients who had reproductive problems and attended an infertility clinic. This report of more than 3000 cases is far from being representative of the general population but seems to be more comprehensive than previous reports in its attempt to calculate the incidence of Müllerian defects and their impact on reproductive potential. The authors suggest that the frequency of uterine malformations in fertile patients is 3.8% and that in infertile patients it is almost twice as high.

Byrne *et al.*<sup>16</sup> used standard ultrasound examinations to establish the prevalence of Müllerian duct abnormalities in

girls and women who were evaluated for reasons unrelated to the presence of uterine anomalies. Prospective ultrasound examinations for non-obstetric indications in 2065 consecutive girls and women (aged 8–93 years) showed that eight had anomalies, including bicornuate uterus, septate uterus and double uterus. In this first attempt to determine the prevalence of uterine anomalies in the general population using non-invasive methodology, the rate of anomalies was 3.87 per 1000 women (95% confidence interval, 1.67–7.62), or approximately 1 in 250 women.

Maneschi *et al.*<sup>17</sup> assessed the prevalence of uterine anomalies in women undergoing hysteroscopy for abnormal uterine bleeding and compared the reproductive outcome in women with Müllerian anomalies to those in women with a normal uterine cavity. They showed that a Müllerian anomaly could be detected in about 10% of women undergoing hysteroscopy for abnormal uterine bleeding. This finding is similar to those reported in studies dealing with the frequency of diagnosis of uterine anomalies in women undergoing tubal sterilization investigated by X-ray hysterosalpingography (X-ray HSG), when septate/bicornuate and arcuate uteri were found in 1.9–3.6% and 11.5%, respectively, of women with no history of reproductive problems<sup>2,18,19</sup>. Maneschi *et al.* confirmed that hysteroscopy is a valuable technique in assessing the uterine cavity and showed that the prevalence of septate/bicornuate and arcuate uteri in women with abnormal uterine bleeding and no history of reproductive problems ranged between 3% and 7%<sup>17</sup>. The discrepancy between reports is due to the inaccuracy of the diagnostic methods employed, to the lack hitherto of a uniform system of classification and to the fact that many of these defects are asymptomatic and therefore remain undiagnosed.

## POOR REPRODUCTIVE HISTORY

Congenital uterine malformations have been associated with poor reproductive outcome, including an increased risk of first- and second-trimester miscarriage, preterm delivery, abruptio placentae, intrauterine growth restriction, fetal distress, and fetal and maternal death<sup>20–23</sup>. Pregnancy loss in patients with uterine septa has been reported to be as high as 90% after other causes for miscarriage have been excluded<sup>24–26</sup>. Although congenital uterine malformations are associated with poor reproductive performance, each type may have a different impact on reproduction<sup>25</sup>.

Raga *et al.*<sup>15</sup> tried to establish the actual incidence and reproductive performance of the different types of uterine malformation in women willing to conceive during their reproductive life. They aimed to define which abnormalities were related to a poor prognosis and which should be surgically corrected (if possible) before conception was attempted. Both the bicornuate uterus and the septate uterus showed a live-birth rate of 62%. With both types of abnormality, early miscarriages (25–38%) and preterm deliveries (25–47%) were quite common. The arcuate uterus was associated with a live-birth rate of 82.7%. The authors concluded that uterine anomalies are relatively frequent in fertile women and more frequent in infertile patients<sup>15</sup>. Nevertheless, fertile patients with normal reproductive performance do exist and Müllerian

defects can permit a normal obstetric outcome. The reproductive performance of the unicornuate and didelphys uteri was poor, while that of the septate and bicornuate uteri was better than expected. These data reinforce the idea that metroplasty is not absolutely necessary in affected patients<sup>24</sup>.

In patients with septate uteri, Buttram<sup>27</sup> reported a 67% miscarriage rate, 33% prematurity and 28% live births. The preoperative reproductive performance in this study was characterized by an 88.5% miscarriage rate and only a 4.6% term delivery rate. Table 1 reports on reproductive outcome in women with an untreated septate uterus<sup>25,28–39</sup> but the data should be regarded with caution as they possibly exclude reports on women with septate uterus and normal reproductive outcome. The accidental finding of a septate uterus is not an indication for surgical intervention because it is not always associated with poor obstetric performance. However, when a septate uterus is associated with adverse reproductive outcome, surgical intervention should be considered.

Premature delivery has been reported in 12–25%<sup>28,40–43</sup> of women with septate or bicornuate uteri and in 5–13% with arcuate uteri<sup>28,44</sup>. Malpresentation has been reported in 30–78% of women irrespective of the degree of the Müllerian anomaly<sup>28,41,44–46</sup>. Cesarean section has been reported in 36–83% of pregnancies in women with arcuate and septate or bicornuate uteri<sup>44–46</sup>.

Grimbizis *et al.*<sup>14</sup> found that hysteroscopic resection of the septum was accompanied by a significant improvement in pregnancy outcome: the miscarriage rate dropped to 25% and the term delivery rate increased to 63.7% (although 4.5% of the pregnancies were still ongoing at the time of their publication).

A significant improvement in pregnancy outcome after hysteroscopic metroplasty was also described by other investigators, with postoperative miscarriage rates between 5 and 20% and live-birth rates between 73 and 87%<sup>25,32–36,47,48</sup>. However, these were retrospective analyses and the absence of a control group (consisting of patients with symptomatic untreated septate uterus) represents a serious limitation in the definition of the efficacy of the hysteroscopic metroplasty. Nevertheless, the assisted reproductive treatment procedures

done before and after the operation were the same and the improvement of pregnancy outcome seems to be impressive, as corroborated by Fedele and Bianchi<sup>49</sup>.

Preuthippan and Linasmita<sup>50</sup> reported the reproductive outcome of 28 patients with septate uterus who underwent hysteroscopic metroplasty. There were a total of 20 pregnancies after a mean period of  $24 \pm 1.4$  (range, 6–42) months following hysteroscopic treatment, of which 15 (75.0%) were carried to term, three (15.0%) were spontaneous miscarriages, and two (10.0%) were in progress at the time of publication. The rate of pregnancy wastage in the post-treatment group was 15% compared with 96.3% in the pretreatment group.

Porcu *et al.*<sup>51</sup> reported on reproductive outcome and obstetric prognosis of 63 patients after hysteroscopic metroplasty. They found that obstetric prognosis of these patients was statistically improved ( $P = 0.001$ ) and resulted in 45 pregnancies.

Grimbizis *et al.*<sup>52</sup>, in a review of the literature, reported that overall term delivery rates in patients with untreated uterine malformations were only approximately 50% and obstetric complications were more frequent. Unicornuate and didelphys uterus were associated with term delivery rates of 45%, and the pregnancy outcome of patients with untreated bicornuate and septate uterus was also poor with term delivery rates of only 40%. Arcuate uterus was associated with a slightly better but still impaired pregnancy outcome with term delivery rates of 65%. Women reported in the different series who underwent hysteroscopic septum resection comprised a highly selected group of symptomatic patients with term delivery and live birth rates of only 5%. Hysteroscopic treatment seemed to restore an almost normal prognosis for the outcome of their pregnancies with term delivery rates of 75% and live birth rates of 85%. The conclusion of this group of authors was that hysteroscopic septum resection can be applied as a therapeutic procedure in symptomatic patients and also as a prophylactic procedure in asymptomatic patients in order to improve their chances of a successful delivery.

Hickok<sup>53</sup> presented a retrospective review of 40 patients undergoing hysteroscopic treatment of a septate uterus, 36 of whom were available for postsurgical follow-up. The clinical outcomes measured were immediate and delayed complications, as well as the percentage of successful pregnancies before and after treatment. Only 58% of the women conceived in the follow-up period, a much lower number than previously reported. However, the percentage of those pregnancies that were successful is similar to that reported previously.

The achievement of pregnancy is another important parameter in estimating the effect of hysteroscopic metroplasty on reproduction<sup>54</sup>. Grimbizis *et al.*<sup>14</sup> reported that all patients with recurrent miscarriage and normal fertility who were trying to become pregnant conceived spontaneously at least once after their treatment. Daly *et al.*<sup>25</sup> have reported normal postoperative monthly fecundity rates. Thus, it seems that the application of hysteroscopic metroplasty does not impair the fertility potential of women with a history of recurrent miscarriages. Table 2 compares data on reproductive outcome before and after hysteroscopic metroplasty for the septate uterus<sup>25,33–39</sup>.

**Table 1** Reproductive outcome in women with an untreated septate uterus

Reference	Pregnancies (n (%))	Miscarriages (n (%))	Preterm deliveries (n (%))
Heinonen <i>et al.</i> <sup>28</sup>	81	21 (25.9)	7 (8.6)
Zupi <i>et al.</i> <sup>29</sup>	37	15 (40.5)	0
Daly <i>et al.</i> <sup>30</sup>	40	34 (85.0)	5 (12.5)
Israel and March <sup>31</sup>	9	9 (100)	0
Valle and Sciarra <sup>32</sup>	42	30 (71.4)	12 (28.6)
Fayez <sup>33</sup>	57	49 (86.0)	8 (14.0)
March and Israel <sup>34</sup>	240	212 (88.3)	21 (8.8)
Perino <i>et al.</i> <sup>35</sup>	27	24 (88.9)	3 (11.1)
Daly <i>et al.</i> <sup>25</sup>	150	130 (86.7)	13 (8.7)
Choe and Baggish <sup>36</sup>	38	31 (81.6)	6 (15.8)
Cararach <i>et al.</i> <sup>37</sup>	176	159 (90.3)	11 (6.3)
Pabuccu <i>et al.</i> <sup>38</sup>	108	96 (88.9)	11 (10.2)
Valle <sup>39</sup>	299	258 (86.3)	28 (9.4)
Total	1304	1068 (81.9)	125 (9.6)

Table 2 Comparison of reproductive outcome before and after hysteroscopic metroplasty for the septate uterus

Reference	Patients (n)	Before metroplasty				After metroplasty			
		Pregnancies (n)	Miscarriages (n (%))	Preterm deliveries (n (%))	Term deliveries (n (%))	Pregnancies (n)	Miscarriages (n (%))	Preterm deliveries (n (%))	Term deliveries (n (%))
Fayez <sup>33</sup>	12	21	19 (90.5)	2 (9.5)	0	16	2 (12.5)	0	14 (87.5)
March and Israel <sup>34</sup>	57	240	212 (88.3)	21 (8.8)	7 (2.9)	56	8 (14.3)	4 (7.1)	44 (78.6)
Perino <i>et al.</i> <sup>35</sup>	24	27	24 (88.9)	3 (11.1)	0	15	1 (6.7)	0	14 (93.3)
Daly <i>et al.</i> <sup>25</sup>	55	150	130 (86.7)	13 (8.7)	7 (4.7)	75	15 (20.0)	5 (6.7)	55 (73.3)
Choe and Baggish <sup>36</sup>	14	38	31 (81.6)	6 (15.8)	1 (2.6)	12	1 (8.3)	1 (8.3)	10 (83.3)
Cararach <i>et al.</i> <sup>37</sup>	62	176	160 (90.9)	11 (6.3)	5 (2.8)	41	12 (29.3)	0	29 (70.7)
Pabuccu <i>et al.</i> <sup>38</sup>	49	108	96 (88.9)	11 (10.2)	1 (0.9)	44	2 (4.5)	2 (4.5)	40 (90.9)
Valle <sup>39</sup>	115	299	258 (86.3)	28 (9.4)	13 (4.3)	103	12 (11.7)	7 (6.8)	84 (81.6)
Total	388	1059	930 (87.8)	95 (9.0)	34 (3.2)	362	53 (14.6)	19 (5.2)	290 (80.1)

In my view, hysteroscopic metroplasty is appropriate in patients with recurrent miscarriages due to its efficacy and the absence of harmful effects on the achievement of pregnancy.

### PRIMARY INFERTILE PATIENTS

Patients with secondary infertility usually have a history of spontaneous miscarriages, while patients with primary infertility have no such history. In these patients, the uterine anomaly is detected as part of the infertility evaluation. Therefore, the treatment of this group is more controversial than that of the group with a poor reproductive history.

Marcus *et al.*<sup>55</sup> reported the outcome of 24 patients with various congenital uterine anomalies without previous metroplasty undergoing *in vitro* fertilization (IVF); 19 (70.8%) of them became pregnant after a mean of 2.1 attempts per patient, and the pregnancy rates were similar irrespective of the type of anomaly. In another study, Guirgis and Shrivastar<sup>56</sup> treated 14 patients with bicornuate uterus and without previous metroplasty by gamete intrafallopian transfer; eight (51.7%) of them achieved a pregnancy after a mean of 2.1 attempts per patient. The ovarian response to stimulation, the implantation rates and the pregnancy rates observed in these two studies were similar to those for the general infertile population.

On the other hand, Daly *et al.*<sup>25</sup> reported that seven (53.8%) out of 13 patients with infertility conceived after septum resection and, more recently, Goldenberg *et al.*<sup>26</sup> have observed pregnancies after hysteroscopic metroplasty in 18 (54%) out of 34 patients with uterine septum and primary infertility. Thus, in their view the chances of conception in patients with septate uterus and primary infertility seem to be similar to those of the general infertile population either with or without septum resection. This may also be an indirect sign that uterine septum is not an infertility factor in itself. However, metroplasty has a beneficial effect in avoiding pregnancy loss.

Most embryos that are transferred during an IVF procedure fail to implant for unknown reasons. The embryonic implantation rate depends to a large extent on the embryonic quality, endometrial receptivity and uterine integrity.

Most infertility programs involve X-ray HSG to assess the uterine cavity in patients who will undergo IVF-embryo transfer (ET). This is despite the fact that previous studies have reported that hysteroscopy reveals undetected endometrial abnormalities in 20–50% of patients who are about to undergo or who have undergone IVF-ET<sup>57,58</sup>.

Among 144 women who had preclinical miscarriage after IVF, Dicker *et al.*<sup>59</sup> found uterine abnormalities (mainly septa) in 14 cases (9.7%) and surmised that an incomplete uterine septum may be an important factor predisposing to early pregnancy wastage. Kirsop *et al.*<sup>60</sup> also reported improved results with IVF after hysteroscopic treatment of uterine abnormalities.

Syrop *et al.*<sup>61</sup> showed that 18.2% of patients in whom IVF-ET repeatedly failed had abnormalities of the uterine cavity. La Sala *et al.*<sup>62</sup> reported on one hundred IVF patients in whom two IVF-ET cycles failed despite transferring two very high quality embryos. In 18 patients, hysteroscopy showed

an important unsuspected endouterine anomaly. Although these anomalies were significant they were not revealed by either X-ray HSG or ultrasound.

Contrary to La Sala *et al.*, Marcus *et al.*<sup>55</sup>, in a study of women at Bourn Hall Clinic, an infertility referral center, showed that those with congenital uterine malformations have clinical pregnancy and multiple pregnancy rates that are similar to the rates of the general infertile population being treated by IVF-ET (37.3% and 31.6%, respectively).

The large series of Testart *et al.*<sup>63</sup> analyzed the results of 81 691 oocyte collection procedures in 500 IVF centers. Pregnancy failure occurred in 26.3%, mainly as a miscarriage during the first 3 months (18.5%). Although the authors did not elaborate on the incidence of congenital uterine anomalies in the study group, the adverse reproductive outcome was similar to that obtained in the study of Marcus *et al.*<sup>55</sup>. It is unclear what determines whether the pregnancies of women with congenital uterine malformations will have a normal outcome, miscarriage, or end in premature labor<sup>63</sup>. In the Bourn Hall series, the multiple pregnancy rate in the group of patients who had three embryos transferred was 40% compared with 0% in the group who had one or two embryos transferred, and the preterm delivery rate in the study group was 46.2% compared with 24% of all deliveries after IVF-ET<sup>55,64</sup>. The Cesarean section rate in patients affected with uterine anomaly was much higher (76.9%) than that reported in the general population. The reason for the high rate of Cesarean section in the study group of Marcus *et al.*<sup>55</sup> is multifactorial, with prematurity and malpresentation being the main factors. Analysis of obstetric outcomes showed that there was a trend for patients with unicornuate uteri and uterus didelphys to have a low spontaneous miscarriage rate and a high near-term delivery rate (66.7%), compared with women with bicornuate and septate uteri in whom the spontaneous miscarriage rate was 30%, and the near-term delivery rate was 10%. There may be a benefit of cervical cerclage in prolonging the length of gestation in women with Müllerian anomalies who have conceived by IVF-ET. Golan *et al.*<sup>42</sup> reported that one third of women with congenital uterine malformation in their series had cervical incompetence and noted improvement in the obstetric outcome with cervical cerclage.

Clearly, the role of hysteroscopic metroplasty in patients with primary infertility remains controversial. Some investigators recommend the treatment in this situation<sup>59,62</sup>, but others do not<sup>19,55</sup>. Table 3 reports on reproductive outcome

after hysteroscopic metroplasty for the septate uterus in women with primary infertility<sup>25,33,35,38,65,66</sup>. On balance, in my view, metroplasty should be considered not only because of its beneficial effect on fecundity, but also because of the benefit of reduced rates of miscarriage and preterm delivery if these women conceive.

## ETIOLOGY OF ADVERSE EFFECTS OF A SEPTATE UTERUS

Several mechanisms have been proposed to explain the adverse effect of a septate uterus on the course of pregnancy. The diminished size of the uterine cavity as well as cervical incompetence have been suggested as possible etiological factors<sup>14,54</sup>. However, according to the most widely accepted theory, the septum is thought to consist of fibroelastic tissue with inadequate vascularization and altered relations between myometrial and endometrial vessels.

The poor response to estrogen of the endometrial mucosa covering the septum, including irregular differentiation and estrogenic maturation, is probably because of the scanty vascularization of the septal connective tissue<sup>67,68</sup>. As a result, implantation may be compromised and decidual and placental growth inadequate, resulting in early pregnancy loss and infertility. In addition, impaired fetal growth and abruptio placentae may occur as a result of an already poorly vascularized placenta and distorted uterine cavity, causing second- and third-trimester complications. Therefore, removing the septum may eliminate an unsuitable site for implantation, improve endometrial function, expand uterine capacity, and dramatically enhance reproductive outcome in selected patients.

Contrary to this classic concept, Dabirashrafi *et al.*<sup>69</sup> found significantly less connective tissue, a greater proportion of muscle tissue and more vessels in the septum. They therefore suggested that pregnancy wastage is caused by poor decidualization and placentation due to the reduced amounts of connective tissue, as well as by higher or uncoordinated contractility due to the increased muscle content<sup>69</sup>. It also has been suggested that estrogen and progesterone receptor deficiency in malformed uteri may further increase abnormal uterine contractions that lead to fetal wastage.

Pellerito *et al.*<sup>70</sup> performed magnetic resonance imaging (MRI) of patients with a septate uterus and found a muscular septal component (differentiated from fibrous tissue by its higher signal intensity). This was confirmed by histological examination of biopsy specimens.

**Table 3** Reproductive outcome after hysteroscopic metroplasty for septate uterus in women with primary infertility

Reference	Patients who had metroplasty for a septate uterus (n)	Patients with primary infertility (n (%))	Pregnancy rate after treatment (%)
Fayez <sup>33</sup>	19	7 (36.8)	71.4
Perino <i>et al.</i> <sup>35</sup>	24	8 (33.3)	62.5
Daly <i>et al.</i> <sup>25</sup>	70	15 (21.4)	46.7
Marabini <i>et al.</i> <sup>65</sup>	40	14 (35.0)	42.9
Pabuccu <i>et al.</i> <sup>38</sup>	59	10 (17.0)	60.0
Colacurci <i>et al.</i> <sup>66</sup>	69	21 (30.4)	28.6
Total	281	75 (26.7)	52.8

**Table 4** Benefits and limitations of techniques for obtaining information on uterine configuration in infertile patients

<i>Technique</i>	<i>Benefits</i>	<i>Limitations</i>
X-ray hysterosalpingography	Provides valuable information about the uterine cavity; allows concomitant assessment of tubal patency; reveals results of the surgical intervention; reveals complications after surgery (such as uterine perforation)	Procedure-related pain; complications: pelvic inflammatory disease; exposure to radiation and iodinated contrast material
Hysteroscopy	Allows direct assessment of the intrauterine abnormalities; enables biopsy and/or removal of the endometrial lesions; facilitates treatment at the time of diagnosis	Invasiveness; no information regarding tubal patency and serosal surface of the uterus; risk of infection, bleeding, and air embolism
Laparoscopically-guided hysteroscopy	Differentiates between a septate and bicornuate uterus; monitors hysteroscopic surgery (reduces the risk of perforation); allows diagnosis and treatment of coexisting pelvic pathology (such as endometriosis)	Invasiveness; increases morbidity of the patients
Magnetic resonance imaging	Enables correct classification of the uterine malformations; identifies coincidental gynecological diseases; obtains information on septal morphology (fibrous vs. myometrial tissues) which may be important in determining appropriate surgical approach	High cost; lack of information on tubal patency
Transabdominal 2DUS	Minimally invasive; low cost; easy to perform; allows assessment of urological anomalies	Inaccurate (does not differentiate accurately between different forms of double uterus)
Transvaginal 2DUS	Improved visualization due to the use of higher frequency probes and avoidance of subcutaneous fat	Operator-dependent
Transvaginal color Doppler	Obtains information on vascularity of the septal region which may be important in determining treatment options; detects deficient endometrial development	
Saline contrast sonohysterography	Improves information obtained by transvaginal ultrasound; provides information on tubal patency; video-tape recording enables subsequent review of findings	Operator-dependent
Transvaginal 3DUS	Immediate acquisition and storage of volume data; retrospective analysis of the stored data; multiplanar capability enables unlimited number of scan planes; coronal view of the uterus enables analysis of the relationship between endometrium and myometrium of the uterine fundus; depicts cornual angles; evaluates external uterine contours; delineates the entire cervical canal; interactive review at any time (without presence of the patient); rotation and magnification of the volume enables detailed exploration of the uterine cavity; reduction of the imaging time; network consultation and exchange of the data	Time required to learn to manipulate and interact with 3D volume data; shadowing caused by uterine leiomyoma; decreased volume of the uterine cavity and concomitant endometrial lesions may cause false-negative findings
3D saline contrast sonohysterography	Same as for 3DUS; shortened time of saline contrast sonohysterography (less painful due to reduction of time during which uterine cavity must remain distended); facilitates visualization of small endoluminal lesions	

2D, two-dimensional; 3D, three-dimensional; US, ultrasound.

## DIAGNOSTIC METHODS

Many methods are used to identify Müllerian tract defects. Among these are a pelvic examination, X-ray HSG, hysteroscopy, laparoscopy, MRI, transvaginal two-dimensional ultrasound (2DUS), and transvaginal three-dimensional ultrasound (3DUS)<sup>24,71-73</sup>. Table 4 reviews the benefits and limitations of X-ray HSG, hysteroscopy with and without guided laparoscopy, MRI, transvaginal 2DUS, transvaginal color Doppler, saline contrast sonohysterography (SCSH), transvaginal 3DUS and 3D saline contrast sonohysterography (3D SCSH) for obtaining information on uterine configuration in infertile patients.

X-ray HSG provides valuable information about the endometrial cavity and about tubal patency. However, the usefulness of X-ray HSG is limited as a technique to classify uterine anomalies because it does not provide definitive information about the external contour of the uterus. Although X-ray HSG provides a good outline of the uterine cavity, the distinction between different types of lateral fusion disorders is often impossible.

Hysteroscopy allows both direct visualization of the uterine cavity and operative intervention when used to remove septa. However, as is the case with X-ray HSG, it cannot be used to reliably evaluate the external contour of the uterus. An advantage of hysteroscopy is the direct visualization of the endometrium and the fact that it can be performed as an outpatient procedure. However, one should be aware that it may be accompanied by the risk of complications such as uterine perforation, infection and bleeding.

Concurrent laparoscopy is essential for a successful outcome of the procedure. This method is necessary to confirm a normal external uterine configuration before attempts at resection. If the anomaly is of a bicornuate variety, a hysteroscopic approach is contraindicated. Throughout the procedure, laparoscopic visualization is useful for assessing the resection and identifying uterine perforation promptly should it occur. In addition, the laparoscope can be used to identify and treat factors that may affect fertility, such as pelvic adhesions and endometriosis. Twenty-five percent of patients in Hickok's study were found to have previously undiagnosed endometriosis<sup>53</sup>.

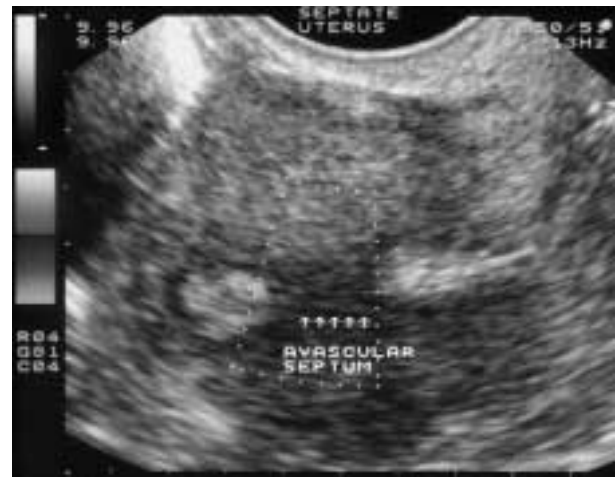By its ability to delineate both internal and external uterine architecture, MRI may provide an alternative diagnostic method for the evaluation of Müllerian tract anomalies. However, it is an expensive modality not suitable for office practice.

Ultrasound has the advantages of minimal invasiveness, relatively low cost, and ease of performance. Several investigators have reported that transabdominal 2DUS is a useful technique for the evaluation of Müllerian tract anomalies<sup>70,72-76</sup>. Transabdominal 2DUS was the first echographic technique used for this purpose. However, transvaginal sonography, because of its ability to be closer to the pelvic organs, allows better anatomical delineation of pelvic structures in addition to providing images with better contrast and detail resolution (Figure 1).

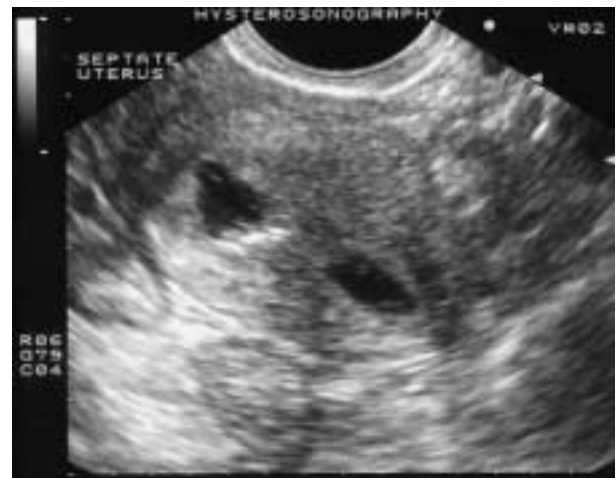When used as a screening test, transvaginal 2DUS has provided sensitivity rates of around 70%<sup>74</sup>. However, the distinction between the different types of anomalies is often

impossible. Another problem with 2DUS is that a transverse or oblique transverse view of the uterus is not optimal in diagnosing uterine abnormalities. Furthermore, ultrasound is operator-dependent and hard-copy images can be difficult for a third party to interpret.

Optimal imaging of the endometrium and myometrium may require distension of the uterine cavity with saline or another contrast medium to separate the walls of the uterus, to outline the endometrial contour, and to detect endoluminal lesions (Figure 2). Before SCSH, each patient has to be examined by conventional transvaginal ultrasound to assess the appearance of the uterus before fluid instillation and to determine the orientation of the uterus to facilitate cervical cannulation. The procedure has to be performed during the follicular phase after the cessation of menstrual bleeding. After placing a speculum into the vagina the cervix is identified and cleansed with a povidone-iodine solution. It is preferable to use a balloon-bearing catheter which, after being inflated with saline, occludes the internal os. The



**Figure 1** Transvaginal scan with color Doppler facilities demonstrates a septate uterus. Note the two separate endometrial echoes divided by a thick septum.



**Figure 2** Septate uterus at sonohysterography. Note the two separate endometrial echoes divided by a thick septum.

speculum is then removed and the vaginal probe is inserted to observe injection of sterile saline and distension of the uterine cavity.

In the study of Keltz *et al.*<sup>77</sup> the sensitivity and specificity of SCSH were both 100% when compared with surgery. The specificity of X-ray HSG was significantly (20.0%) lower than SCSH ( $P = 0.015$ ) using surgical confirmation as the gold standard. The accuracy of diagnosis by SCSH of a uterine defect was 100% (12 of 12) when compared with surgery, whereas X-ray HSG accurately diagnosed a uterine defect in only 45.5% (5 of 11) of cases based on surgical confirmation ( $P < 0.01$ ). However, X-ray HSG demonstrated a uterine abnormality in 11 of 14 (78.6%) cases of uterine abnormalities diagnosed by SCSH, and X-ray HSG concurred with 9 of 13 (69.2%) normal SCSH studies.

Saline contrast sonohysterography offers a sensitive and specific method of screening and diagnosing intrauterine defects in recurrent pregnancy loss. The high rate of intrauterine defects demonstrated in the study performed by Keltz *et al.*<sup>77</sup> provides further evidence of the importance of evaluating the uterine cavity after recurrent miscarriages. Although X-ray HSG has been the standard screening test in recurrent pregnancy loss, its relatively low specificity and accuracy may favor the use of SCSH by skilled examiners for intrauterine screening. With increased training and experience with endovaginal sonography, gynecologists will find SCSH a simple and accurate technique for the investigation of intrauterine pathology. The main objection to the study by Keltz *et al.*<sup>77</sup> is that it analyzed a selective group of patients (34 women of reproductive age with at least two consecutive pregnancy losses) who had been referred for SCSH. Twenty-two of the patients had X-ray hysterosalpingograms within 1 year of the SCSH while five patients underwent subsequent X-ray HSG. Therefore, retrospective reviews of the radiological reports may be the cause of the low sensitivity and specificity of X-ray HSG in this study. Soares *et al.*<sup>78</sup> evaluated the diagnostic accuracy of SCSH in uterine cavity diseases in infertile patients and compared results with those of X-ray HSG and transvaginal ultrasound. Saline contrast sonohysterography had the same diagnostic accuracy as the gold standard for polypoid lesions and endometrial hyperplasia. X-ray HSG had a sensitivity of 50% and a positive predictive value of 28.6% for polypoid lesions and a sensitivity of 0% for endometrial hyperplasia. Saline contrast sonohysterography and X-ray HSG had similar sensitivities (75%) in the detection of intrauterine adhesions. Saline contrast sonohysterography was the more accurate diagnostic test for polypoid lesions and endometrial hyperplasia compared to X-ray HSG. In this study SCSH was of limited use in the diagnosis of intrauterine adhesions and minor uterine malformations, although its global results in diagnosing uterine malformations were superior to those obtained by X-ray HSG. Based on available data and my personal experience X-ray HSG is highly sensitive in the diagnosis of more major uterine malformations; however, it is not sufficiently sensitive in the diagnosis of minor uterine abnormalities.

Transvaginal 3DUS is a non-invasive imaging technique with the ability to generate accurate images of the endometrial cavity and of the external contour of the uterus. Jurkovic

*et al.*<sup>79</sup> reported that with the ability to view three orthogonal planes, they were able to obtain an image equal to that of X-ray HSG and superior to that of transvaginal 2DUS images. By obtaining a coronal view of the uterus and through meticulous analysis of three orthogonal planes, the authors reported 98% sensitivity and 100% specificity, compared with 88% sensitivity and 94% specificity with transvaginal 2DUS. With arcuate uteri the sensitivity and specificity of transvaginal 3DUS were 100% compared with 67% and 94%, respectively, for transvaginal 2DUS. With major Müllerian anomalies, the sensitivity and specificity of transvaginal 3DUS were both 100% compared with 100% sensitivity and 95% specificity for transvaginal 2DUS. However, the positive predictive value reported for major anomalies was 100% for 3D compared with 50% for 2DUS.

More recently, Jurkovic *et al.*<sup>80</sup> elaborated on the use of ultrasound screening for congenital uterine anomalies in an unselected population, estimating their prevalence to be 5–6%. It is important to establish actual incidence and effect on reproductive performance of the different types of uterine malformations in women willing to conceive in order to define which abnormalities are related to a poor prognosis and which should be surgically corrected prior to an attempt to conceive. Raga *et al.*<sup>81</sup> were able to identify all patients with uterine malformations when 3DUS was used to examine both the cavity and the external contour of the uterus. One of the most useful scan planes obtained on 3DUS is the coronal view of the uterus, which is usually not obtainable on 2DUS because of anatomical limitations (the vaginal probe has limited mobility within the confines of the vagina). These coronal views show the relationship between the endometrium and the myometrium at the uterine fundus, delineate the entire cervical canal, and depict the cornual angles (Figures 3–5). The coronal plane is especially helpful in cases of complicated anatomy or multiple findings. To obtain a 3D concept of the uterine cavity and any abnormalities, thorough and meticulous scanning in both the sagittal and coronal planes is required while the cavity is distended with saline or an echo-enhancing contrast agent (Figure 6)<sup>79</sup>. The benefits and limitations of 3D SCSH are listed in Table 4.

With 3DUS, a volume of sonographic data is rapidly acquired and stored. This volume of data can then be analyzed retrospectively after the SCSH examination has been completed, which shortens the amount of time during which the uterine cavity must remain distended<sup>82</sup>. Because all of the original sonographic data are contained in the saved volume, there is no loss of information, as may occur when only selected static images are available for interpretation<sup>83</sup>. Even with videotape recording of SCSH, the findings remain operator-dependent, and any observation not clearly documented on the tape is lost. The multiplanar capability of 3DUS permits an unlimited number of scan planes to be obtained from the original data set. This data set is available for interactive review at any time after the patient has been discharged or before surgical intervention. Additional findings not initially detected during the real-time examination can be made by ‘scrolling’ through the volume data; the volume can also be rotated and magnified as needed to explore any portion of the uterine cavity or to clarify details. This can be accomplished



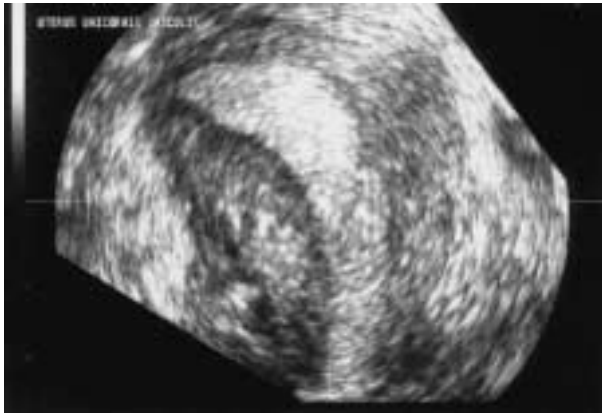


Figure 3 Frontal reformatted section of a unicornuate uterus.

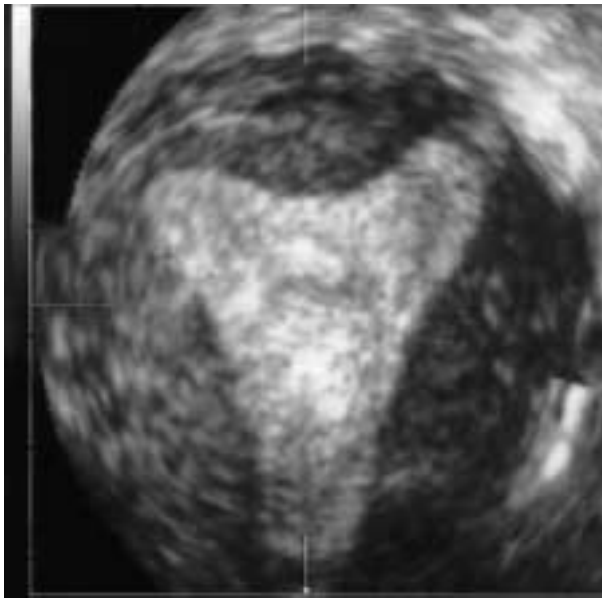


Figure 4 Frontal reformatted section of an arcuate uterus. Note the absence of the fundal indentation in the myometrium and slight concavity of the uterine cavity.

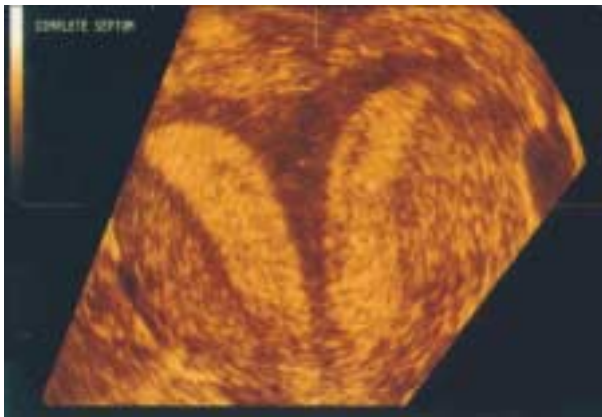


Figure 5 Frontal reformatted section of the septate uterus. Note the complete division of the uterine cavity and the concave shape of the uterine muscle. Since the fundal cleft is  $< 1$  cm (0.7 cm), this uterine anomaly is defined as a septate uterus. This was confirmed by laparoscopically guided hysteroscopy.

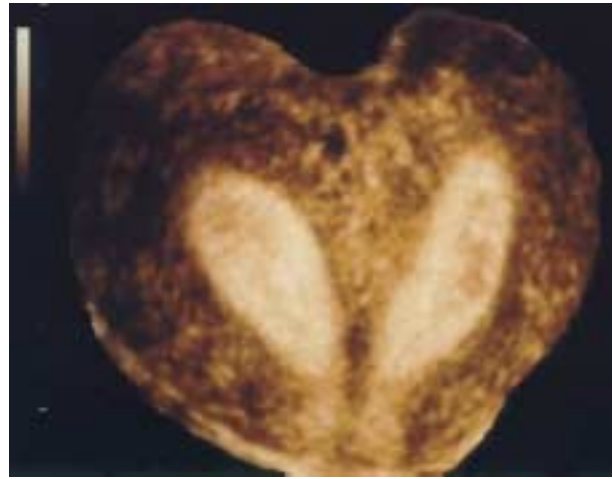


Figure 6 Frontal reformatted section of the uterine cavity after instillation of echo-enhancing contrast. Note the clear division of the uterine cavity and fundal cleft exceeding 1 cm.

without inconveniencing the patient by prolonged or repeated vaginal scanning. Because all potential imaging planes are captured within the volume data set, imaging times could theoretically be reduced, because rescanning should not be necessary<sup>83</sup>. The saved volume data also facilitate consultation with patients and colleagues, either on site or remotely.

To my knowledge, there are only four published studies using 3D multiplanar imaging in which 3D SCSH was compared with another modality. Ayida *et al.*<sup>84</sup> compared transvaginal 2D and 3DUS with and without instillation of saline in 10 infertile patients. They found that 3D SCSH did not provide any additional clinically relevant information, although they reported that preliminary 3D imaging (before fluid instillation) identified an unsuspected subseptate uterus.

Bonilla-Musoles *et al.*<sup>85</sup> studied 36 patients with postmenopausal bleeding who underwent 3D SCSH; they compared the findings with those of transvaginal 2DUS, 2D SCSH, and hysteroscopy with histological correlation. They found that visualization of the uterine cavity and endometrial thickness was better on 3D SCSH. There was excellent correlation between the 3D SCSH and hysteroscopic findings, most notably for small endoluminal lesions. There were no cases of uterine malformations in this study.

Weinraub *et al.*<sup>82</sup> also described the use of 3D SCSH. Their study focused on the evaluation of suspected uterine cavity disease in 32 women who had previously undergone sonography, X-ray HSG, or hysteroscopy. Three-dimensional SCSH provided additional information on the topographical orientation of polypoid structures, submucous fibroids and intrauterine synechiae.

Lev-Toaff *et al.*<sup>83</sup> compared the findings of 3D SCSH with those of 2D SCSH and X-ray HSG. Of 20 women who underwent 3D SCSH for various indications, 13 also underwent 2D SCSH, and 12 had X-ray HSG. The authors found that reviewing the saved volume data in the multiplanar format was particularly useful, because it permitted detailed exploration of the endometrial cavity, uterine wall (myometrium), and external uterine contour. The coronal plane was favored

**Table 5** Sensitivity, specificity and positive and negative predictive values of various imaging modalities for the diagnosis of septate uterus in 420 patients with history of infertility and recurrent miscarriages

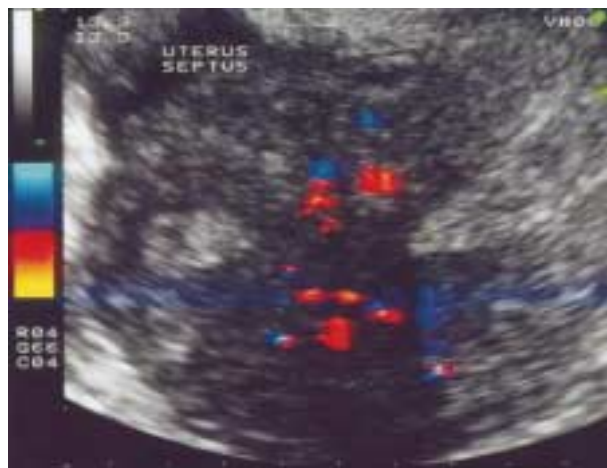Imaging modality	Sensitivity (%)	Specificity (%)	PPV (%)	NPV (%)
Transvaginal sonography	95.21	92.21	95.86	91.03
Transvaginal color Doppler	99.29	97.93	98.03	98.61
Saline contrast sonohysterography	98.18	100.00	100.00	95.45
Three-dimensional ultrasound	98.38	100.00	100.00	96.00

Reproduced from Kupesic and Kurjak<sup>86</sup>, with permission from the American Institute of Ultrasound in Medicine. PPV, positive predictive value; NPV, negative predictive value.

for displaying the relationship between lesions and the uterine cavity. A disadvantage of 3D SCSH is the time required to learn to manipulate the 3D volume data, although this decreases with experience.

Kupesic and Kurjak<sup>86</sup> attempted to evaluate the combined use of transvaginal 2DUS, transvaginal color and pulsed Doppler sonography, SCSH and transvaginal 3DUS in the preoperative diagnosis of septate uterus. A total of 420 infertile patients undergoing operative hysteroscopy were included in this study. The final diagnosis of the uterine disorder was confirmed by hysteroscopy, and 278 patients had an intra-uterine septum corrected surgically. Forty-three of the patients with a septate uterus had a history of repeated spontaneous miscarriage, 71 had had one spontaneous miscarriage (56 in the first trimester, and 15 in the second trimester), 82 had primary infertility and 20 had had premature delivery, including six with breech and two with transverse presentations. A positive history of ectopic pregnancy was found in 76 patients.

Each patient underwent transvaginal ultrasound and transvaginal color Doppler examination during the luteal phase of their cycle. Color and pulsed Doppler were superimposed to visualize intraseptal and myometrial vascularity in each patient (Figure 7). Eighty-six patients undergoing hysteroscopy were examined by 3DUS, while distension of

**Figure 7** Transvaginal color Doppler scan demonstrating two separate endometria during the secretory phase of the menstrual cycle and richly perfused septum.

the uterine cavity with saline was performed in 76 patients. Table 5 summarizes the sensitivity, specificity and positive and negative predictive values of transvaginal sonography, transvaginal color and pulsed Doppler ultrasound, SCSH and 3DUS for the diagnosis of the septate uterus.

Our group<sup>86</sup> has found no correlation between septal height and occurrence of obstetric complications ( $P > 0.05$ ). We found that miscarriages and late pregnancy complications occurred with the same rate in patients with small septa that were dividing less than one third of the uterine cavity (86 of 126), and those with septa covering more than two thirds of the uterine cavity (108 of 152) (Table 6). The same was true of septal thickness: obstetric complications were found in the same proportion of the patients with thin (64 of 92) and those with thick (130 of 186) septa ( $P > 0.05$ ). Indeed, previous obstetric performance correlated significantly with septal vascularity. Patients with vascularized septa had significantly higher prevalence of early pregnancy failure and late pregnancy complications (169 of 198) than those with avascularized septa (25 of 80) ( $P < 0.05$ ) (Figure 8). This may reflect an increased amount of muscle in the septum producing local uncoordinated myometrial contractility. In our study, early miscarriages occurred at a significantly higher rate than did those in a control group (41% vs. 15%). Late miscarriages and premature deliveries developed in 35 of 278 (12.6%)

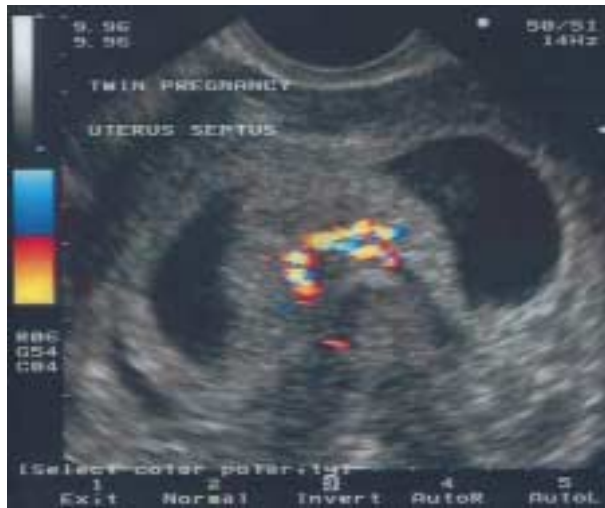**Table 6** Rate of obstetric complications regarding septal morphology and vascularity

Septal characteristic	Patients (n (%))	Obstetric complications (n (%))	Significance
Height			$P > 0.05$
Partial septum	126 (45.32)	86 (68.25)	
Complete septum	152 (54.68)	108 (71.05)	
Thickness			$P > 0.05$
< 1 cm (thin)	92 (33.09)	64 (69.56)	
> 1 cm (thick)	186 (66.91)	130 (69.89)	
Vascularity			$P < 0.05$
Vascularized	198 (71.22)	169 (85.35)	
Avascular	80 (28.78)	25 (31.25)	

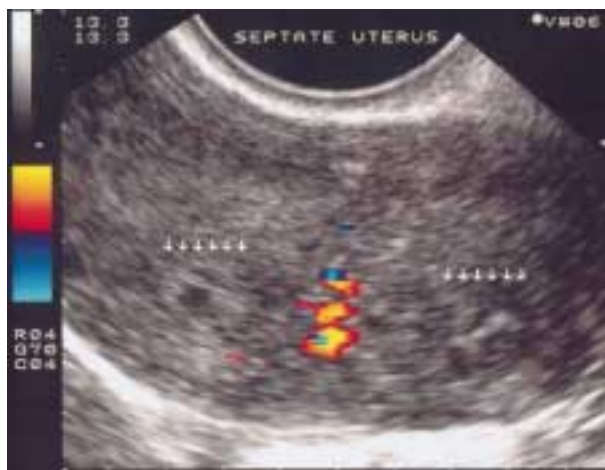Obstetric complications: 114 early miscarriages; 35 late miscarriages and premature deliveries; 2 cases of intrauterine growth restriction; 2 intra-uterine fetal deaths; 1 placental abruption; 1 placenta previa; 6 breech presentations; 2 transverse presentations; 9 cases of cervical incompetence; 76 ectopic pregnancies. Fifty-four patients had two concomitant obstetric complications. Reproduced from Kupesic and Kurjak<sup>86</sup>, with permission from the American Institute of Ultrasound in Medicine.

patients compared to the rate of 7% for normal pregnancies. Intrauterine growth restriction occurred in two (8.7%) pregnancies with a septate uterus, compared to 6% among our general patient population. Intrauterine fetal death occurred in one patient, and placental abruption and placenta previa were also found in one patient. Breech presentation was found in six (26.1%) pregnancies complicated by an intrauterine septum, whereas transverse presentation occurred in two (8.7%) patients. Since abnormal fetal presentation was significantly more frequent in patients with a septate uterus, there was also a higher rate of Cesarean section (34.8%). Cervical incompetence during pregnancy appeared in nine (25.7%) women with an intrauterine septum.

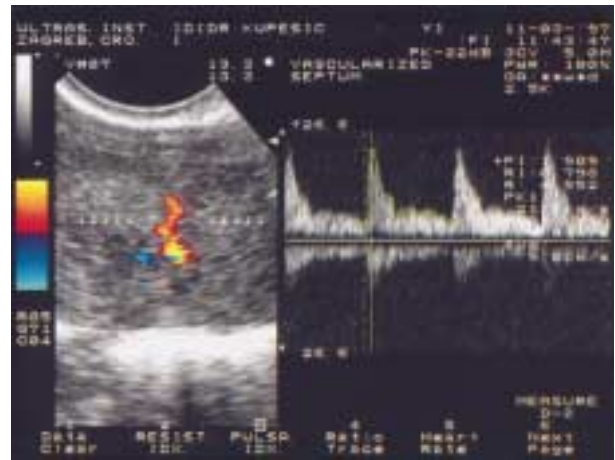By using transvaginal ultrasound it was possible to perform a precise assessment of the uterine morphology, including the endometrial lining and outer shape of the uterine muscle. Color Doppler ultrasound allowed simultaneous visualization of uterine morphology and vascular network



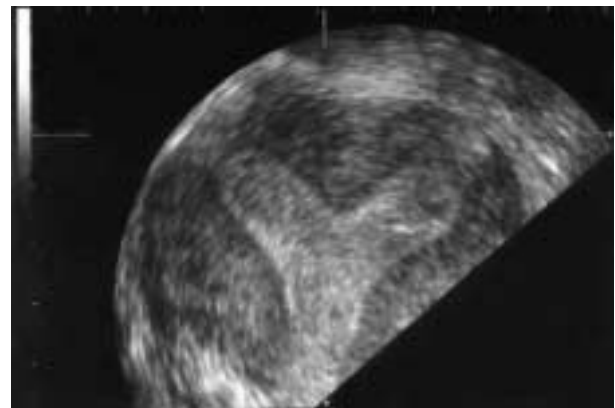
**Figure 8** Transvaginal color Doppler scan of a twin pregnancy. Color Doppler reveals rich vascularity within the septal area. The patient started bleeding and miscarriage occurred after 2 days.



**Figure 9** Septate uterus demonstrated by color Doppler imaging. Vascularity within the septal area is easily observed by this technique.



**Figure 10** In the same patient as in Figure 9, color signals explored by pulsed Doppler waveform analysis show moderate-to-high resistance blood flow (resistance index, 0.80) typical of radial arteries.



**Figure 11** Three-dimensional scan of a septate uterus characterized by a normal outer uterine contour and thick septum extending into the uterine cavity.

giving accurate information on the type of anomaly and the extent of the defect. The visualization of the myometrial portion is further enhanced by detection of the myometrial vessels by color Doppler ultrasound<sup>87</sup>. Furthermore, Doppler imaging can detect deficient intraseptal vascularity and/or inadequate endometrial development in patients with a septate uterus<sup>88</sup> (Figures 9 and 10). Three-dimensional ultrasound enabled planar reformatted sections through the uterus which allowed precise evaluation of the fundal indentation and the length of the septum (Figure 11). Shadowing caused by the uterine leiomyoma, irregular endometrial lining and decreased volume of the uterine cavity (in cases of intrauterine adhesions) are obvious limitations of 3DUS.

## HYSTEROSCOPIC SURGERY

Traditionally hysteroscopy is required in patients with recurrent ( $\geq 3$ ) miscarriages. It is my belief that this approach should be changed with recent advances made by 3DUS. In patients with only one or two miscarriages, in whom there

are no other identifiable causes for pregnancy loss, treatment should be considered<sup>36,89</sup> because endoscopic surgery is simple to perform and associated with low morbidity.

In a study involving hysteroscopic examination of 60 patients after an early miscarriage, uterine anomalies (mainly an incomplete uterine septum) were found in one quarter of the cases<sup>90</sup>. The investigators concluded that a partial uterine septum is a major factor predisposing a patient to missed miscarriage. Thus, a history of missed miscarriage may be considered an indication for intervention.

Cararach *et al.*<sup>37</sup> suggested that coexisting associated features such as dysmenorrhea or abnormal bleeding should prompt earlier intervention. Age is another consideration, because older women may benefit from prompt treatment to optimize outcome. Choe and Baggish<sup>36</sup> suggested that the uterine septum should be corrected as early as possible, especially in patients > 35 years of age, to increase fecundity.

Similar data on the impact of hysteroscopic metroplasty are obtained when analyzing the likelihood of subsequent preterm delivery. In women with a history of preterm delivery, treatment should be offered to reduce the likelihood of a recurrence. Daly *et al.*<sup>25</sup> pointed out that metroplasty prolonged the average gestation and improved perinatal outcome.

The resectoscope with its relatively low cost and wide availability offers a simple and effective method of treating most partial septa. The theoretical risk of thermal endometrial damage has not been substantiated<sup>91</sup>. However, because of the resectoscope's larger operating sheath, scissors or a laser used through an operating hysteroscope would be preferable for operations on a complete septum involving the cervix<sup>1</sup>.

Fedele *et al.*<sup>92</sup> observed that a small residual septum of < 1 cm after hysteroscopic metroplasty does not impair reproductive outcome. In case of doubt, one should leave a small portion of septum behind rather than risk damage to the myometrial tissue over the fundal area and possible perforation and subsequent uterine rupture during pregnancy. Since our study<sup>86</sup> found no correlation between septal dimension and rate of obstetric complications, further prospective investigations are necessary to elaborate these initial results. Querleu *et al.*<sup>89</sup> used ultrasound to guide the incision and stopped the incision when the distance between the upper limit of the section and the serosal surface of the uterine fundus was 10 mm.

In patients with a complete septate uterus, it is generally believed that the cervical portion of the septum should be spared and the dissection started at the level of the internal os to avoid secondary cervical incompetence. The incidence of cervical incompetence after removal of the complete septum is rare. Among 43 reported cases<sup>89,93-95</sup> there was only one case (2.3%) that included cervical incompetence. Moreover, Israel and March<sup>31</sup> had to perform a Cesarean section for dystocia because of a persistent cervical septum.

## POSTOPERATIVE ULTRASOUND

Resecting (i.e. removing the septum) may increase the chance of bleeding and might result in intrauterine adhesion formation. There have been some pathological studies showing that residual septa on the anterior and posterior walls,

after septal incision, retract underneath the endometrium, and then the endometrium overgrows the area. Before these patients attempt pregnancy, it is important to have some kind of uterine cavity visualization to make sure that there are no residual problems in the cavity. A well-performed transvaginal ultrasound, particularly 3DUS, can accomplish the task.

In my view, once the postoperative examination reveals normal findings, there is no reason to delay attempts at pregnancy for more than 3 cycles.

## TERMINATION OF PREGNANCY

Surgical termination of pregnancy remains a safe and effective procedure. In certain circumstances, however, such as very early gestations or in the presence of uterine abnormalities, its failure rate and subsequent morbidity may be increased<sup>96</sup>. Those patients with uterine and/or cervical anomalies who undergo surgical termination of pregnancy are at increased risk of uterine perforation and adhesion formation. They are also more likely to be subjected to repeat surgical attempts at termination and may have problems in conceiving and maintaining future pregnancies.

Jermy *et al.*<sup>96</sup> recently advocated the use of transvaginal sonography as an integral part of the management of pregnancy termination in patients affected with a uterine anomaly. Its introduction would allow the accurate preoperative assessment of the site, gestational age and viability of the pregnancy. Accurate instrumentation of the cavity may be facilitated during surgery and the cavity confirmed as empty following the procedure.

## CURRENT DIAGNOSTIC AND THERAPEUTIC CHALLENGES

Evaluation of the efficacy of detection of uterine anomalies in asymptomatic women, as well as analysis of the patients undergoing metroplasty, presents a number of problems. First, there is lack of randomized prospective trials comparing pregnancy rate and pregnancy outcome in a treated and an untreated group. The ability to perform such clinical trials has been limited by the need to do a laparoscopy to provide reassurance that the uterus is externally unified and convex or aplana. As imaging modalities such as 3DUS with greater sensitivities and specificities in diagnosing uterine anomalies become available, a clinical trial with a non-treatment arm may become more feasible. In the absence of a prospective controlled trial, most retrospective series have compared the reproductive outcome before and after surgery. Such observational studies provide some information on the reproductive performance of patients who have undergone metroplasty for a septate uterus. Furthermore, it is known that half of the first-trimester spontaneous miscarriages that occur are caused by chromosomal abnormalities. One should be aware of objective difficulties of identifying the underlying cause of such first-trimester miscarriages. Lastly, in most institutions it is still not possible to eliminate the laparoscope from the diagnosis of septate uterus. Due to the expense of 3DUS equipment, the need for expertise of the sonographer performing 3DUS studies, and the disadvantage of using it



intraoperatively, in most infertility departments 3DUS cannot at the present time replace invasive methods of diagnosis such as laparoscopically-guided hysteroscopy. In my view, the benefits of 3DUS will gradually change this clinical practice.

## REFERENCES

- Homer HA, Tin-Chiu L, Cooke ID. The septate uterus: a report of management and reproductive outcome. *Fertil Steril* 2000; 73: 1–14
- Sorensen SS. Estimated prevalence of Müllerian anomalies. *Acta Obstet Gynecol Scand* 1988; 67: 441–5
- Gaucherand P, Awada A, Rudigoz RC, Dargent D. Obstetrical prognosis of septate uterus: a plea for treatment of the septum. *Eur J Obstet Gynecol Scand* 1988; 54: 109–12
- Lee DM, Osathanondh R, Yeh J. Localization of Bcl-2 in the human fetal Müllerian tract. *Fertil Steril* 1998; 70: 135–40
- The American Fertility Society classifications of adnexal adhesions, distal tubal occlusion, tubal occlusion secondary to tubal ligation, tubal pregnancies, Müllerian anomalies, and intrauterine adhesions. *Fertil Steril* 1998; 49: 944–55
- Freedman MF. Uterine abnormalities. *Semin Reprod Endocrinol* 1986; 4: 39–54
- Patton PE, Novy MJ. Reproductive potential of the anomalous uterus. *Semin Reprod Endocrinol* 1988; 6: 217–33
- McBean JH, Brumsted JR. Septate uterus with cervical duplication: a rare malformation. *Fertil Steril* 1994; 62: 415–7
- Ergun A, Pabuccu R, Atay V, Kucuk T, Duru NK, Gungor S. Three sisters with septate uteri: another reference to bidirectional theory. *Hum Reprod* 1997; 12: 140–2
- Balasz J, Moreno E, Martinez-Romans S, Molini JL, Torne A, Sanchez-Martin F, Vanrell JA. Septate uterus with cervical duplication and longitudinal vaginal septum: a report of three new cases. *Eur J Obstet Gynecol Reprod Biol* 1996; 65: 241–3
- Muller PP, Musset R, Netter A, Solal R, Vinourd JC, Gillet JY. Etat du haut appareil urinaire chez les porteuses de malformations uterines: etude de 133 observations. *La Presse Med* 1967; 75: 1331–6
- Mikkila SP, Janas M, Karikoski R, Tarkkila T, Simola KO. X-linked laterality sequence in a family with carrier manifestations. *Am J Med Genet* 1994; 49: 435–8
- Buttram VC Jr, Gibbons WE. Müllerian anomalies: a proposed classification (an analysis of 144 cases). *Fertil Steril* 1979; 32: 40–8
- Grimbizis G, Camus M, Clasen K, Tournaye H, De Munck L, Devroey P. Hysteroscopic septum resection in patients with recurrent abortions or infertility. *Hum Reprod* 1998; 13: 1188–93
- Raga F, Bauset C, Remohi J, Bonilla-Musoles F, Simon C, Pellicer A. Reproductive impact of congenital Müllerian anomalies. *Hum Reprod* 1997; 12: 2277–81
- Byrne J, Nussbaum-Blask A, Taylor WS, Rubin A, Hill M, O'Donnell R, Shulman S. Prevalence of Müllerian duct anomalies detected at ultrasound. *Am J Med Genet* 2000; 94: 9–12
- Maneschi F, Zupi E, Marconi D, Valli E, Romanini C, Mancuso S. Hysteroscopically detected asymptomatic Müllerian anomalies. *J Reprod Med* 1995; 40: 684–8
- Ashton D, Amin HK, Richart RM, Neuwirth RS. The incidence of asymptomatic uterine anomalies in women undergoing transcervical tubal sterilization. *Obstet Gynecol* 1988; 72: 28–30
- Simon C, Martinez L, Pardo F, Tortajada M, Pellicer A. Müllerian defects in women with normal reproductive outcome. *Fertil Steril* 1991; 56: 1192–3
- Toaff ME, Lev-Toaff AS. Communicating uteri: review and classification of two previously unreported types. *Fertil Steril* 1984; 41: 661–79
- Kamm ML, Beernik HE. Uterine anomalies in habitual abortion and premature labor. *Obstet Gynecol* 1962; 20: 713–8
- Greiss FC, Mauzy CH. Genital anomalies in women: an evaluation of diagnosis, incidence, and obstetric performance. *Am J Obstet Gynecol* 1961; 82: 330–9
- Lewis BV, Brant HA. Obstetric and gynecologic complications associated with Müllerian duct abnormalities. *Obstet Gynecol* 1966; 28: 315–22
- Acien P. Reproductive performance of women with uterine malformations. *Hum Reprod* 1993; 8: 122–6
- Daly DC, Maier D, Soto-Albers C. Hysteroscopic metroplasty: six years' experience. *Obstet Gynecol* 1989; 73: 201–5
- Goldenberg M, Sivan E, Sharabi Z, Mashiach S, Lipitz S, Seidman DS. Reproductive outcome following hysteroscopic management of intrauterine septum and adhesions. *Hum Reprod* 1995; 10: 2663–5
- Buttram CV. Müllerian anomalies and their management. *Fertil Steril* 1983; 40: 159–63
- Heinonen PK, Saarkisoski S, Pystynen P. Reproductive performance of women with uterine anomalies. *Acta Obstet Gynecol Scand* 1982; 61: 157–62
- Zupi E, Solima E, Marconi D, Valli E, Romanini C. Uterine anomalies: prevalence and reproductive outcome in women undergoing diagnostic hysteroscopy. *Gynaecol Endosc* 1996; 5: 147–50
- Daly DC, Walters CA, Soto-Albers CE, Riddick DH. Hysteroscopic metroplasty: surgical techniques and obstetric outcome. *Fertil Steril* 1983; 39: 623–8
- Israel R, March CM. Hysteroscopic incision of the septate uterus. *Am J Obstet Gynecol* 1984; 149: 66–73
- Valle FR, Sciarra JJ. Hysteroscopic treatment of the septate uterus. *Obstet Gynecol* 1986; 67: 253–7
- Fayez AJ. Comparison between abdominal and hysteroscopic metroplasty. *Obstet Gynecol* 1986; 68: 399–403
- March MC, Israel R. Hysteroscopic management of recurrent abortion caused by septate uterus. *Am J Obstet Gynecol* 1987; 156: 834–42
- Perino A, Mencaglia L, Hamou J, Cittadini E. Hysteroscopy for metroplasty of uterine septa: report of 24 cases. *Fertil Steril* 1987; 48: 321–3
- Choe KJ, Baggish SM. Hysteroscopic treatment of septate uterus with neodymium-YAG laser. *Fertil Steril* 1992; 57: 81–4
- Cararach M, Penella J, Ubeda A, Labastida R. Hysteroscopic incision of the septate uterus: scissors versus resectoscope. *Hum Reprod* 1994; 9: 87–97
- Pabuccu R, Atay V, Urman B, Ergun A, Orhon E. Hysteroscopic treatment of septate uterus. *Gynaecol Endosc* 1995; 4: 213–5
- Valle RF. Hysteroscopic treatment of partial and complete uterine septum. *Int J Fertil Menopausal Studies* 1996; 41: 310–5
- McShane MP, Reilly JR, Schiff I. Pregnancy outcome following Tompkins metroplasty. *Fertil Steril* 1983; 40: 190–4
- Ludmir J, Samuels P, Brooks S, Mennuti MT. Pregnancy outcome of patients with uncorrected uterine anomalies managed in a high risk obstetric setting. *Obstet Gynecol* 1990; 75: 906–10
- Golan A, Langer R, Neuman M, Wexler S, Segev E, David MP. Obstetric outcome in women with congenital uterine malformations. *J Reprod Med* 1992; 37: 233–6
- Ben-Rafael Z, Seidman DS, Recabi K, Bider D, Mashiach S. Uterine anomalies: a retrospective, matched-control study. *J Reprod Med* 1991; 36: 723–7
- Sorensen SS, Trauelsen AG. Obstetric implication of Müllerian anomalies in oligomenorrheic women. *Am J Obstet Gynecol* 1987; 156: 1112–8
- Stein AL, March CM. Pregnancy outcome in women with Müllerian duct anomalies. *J Reprod Med* 1990; 35: 411–5
- Kupesic S, Kurjak A. Diagnosis and treatment outcome of the septate uterus. *Croatian Med J* 1998; 39: 185–90
- Fedele L, Arcaini L, Parazzini F, Vercellini P, Di Nola G. Reproductive prognosis after hysteroscopic metroplasty in 102 women: life-table analysis. *Fertil Steril* 1993; 59: 768–72
- Jacobsen IJ, DeCherney A. Results of conventional and hysteroscopic surgery. *Hum Reprod* 1997; 12: 1376–81
- Fedele L, Bianchi S. Hysteroscopic metroplasty for septate uterus. *Obstet Gynecol Clin N Am* 1995; 22: 473–89
- Preutthipan S, Linasmita V. Reproductive outcome following hysteroscopic treatment of the septate uterus: a result of 28 cases at Ramathibodi Hospital. *J Med Assoc Thai* 2001; 84: 166–70
- Porcu G, Cravello L, D'Ercole C, Cohen D, Roger V, de Montgolfier R, Blanc B. Hysteroscopic metroplasty for septate uterus and repetitive abortions: reproductive outcome. *Eur J Obstet Gynecol Reprod Biol* 2000; 88: 81–4

- 52 Grimbizis GF, Camus M, Tarlatzis BC, Bontis JN, Devroey P. Clinical implications of uterine malformations and hysteroscopic treatment results. *Hum Reprod Update* 2001; 7: 161–74
- 53 Hickok LR. Hysteroscopic treatment of the uterine septum: a clinician's experience. *Am J Obstet Gynecol* 2000; 182: 1414–20
- 54 Worthen JN, Gonzalez F. Septate uterus. sonographic diagnosis and obstetric complications. *Obstet Gynecol* 1984; 64: 34–7
- 55 Marcus S, Al-Shawaf T, Brinsden P. The obstetric outcome of in vitro fertilization and embryo transfer in women with congenital uterine malformation. *Am J Obstet Gynecol* 1996; 175: 85–9
- 56 Guirgis RR, Shrivastar P. Gamete intrafallopian transfer (GIFT) in women with bicornuate uteri. *J Vitro Fert Embryo Transfer* 1990; 7: 283–4
- 57 Balmaceda JP, Cuiffardi I. Hysteroscopy and assisted reproductive technology. *Obstet Gynecol Clin North Am* 1995; 22: 507–18
- 58 Shamma FN, Lee G, Gutmann JN, Lavy G. The role of office hysteroscopy in in vitro fertilization. *Fertil Steril* 1992; 58: 1237–9
- 59 Dicker D, Ashkenazi J, Dekel A, Orvieto R, Feldberg D, Yeshaya A, Ben-Rafael Z. The value of hysteroscopic evaluation in patients with preclinical in-vitro fertilisation abortions. *Hum Reprod* 1996; 11: 730–1
- 60 Kirsop R, Porter R, Torode H, Smith D, Saunders D. The role of hysteroscopy in patients having failed IVF/GIFT transfer cycles. *Aust NZ J Obstet Gynaecol* 1991; 31: 263–4
- 61 Syrop CH, Sahakian V. Transvaginal sonography detection of endometrial polyps with fluid contrast augmentation. *Obstet Gynecol* 1992; 79: 1041–3
- 62 La Sala GB, Montanari R, Dessanti L, Cigarini C, Sartori F. The role of diagnostic hysteroscopy and endometrial biopsy in assisted reproductive technologies. *Fertil Steril* 1998; 70: 378–80
- 63 Testart J, Plachot M, Mandelbaum J, Salat-Baroux J, Frydman R, Cohen J. World collaborative report on IVF/ET and GIFT; 1989 results. *Hum Reprod* 1992; 7: 362–9
- 64 Marcus SF, Brinsden PR, Macnamee MC, Rainsbury PA, Elder KT, Edwards RG. Comparative trial between an ultrashort and long protocol of luteinising hormone releasing hormone agonist for ovarian stimulation in in vitro fertilization. *Hum Reprod* 1993; 2: 238–43
- 65 Marabini A, Gubbini G, Stagnozzi R, Stefanetti M, Filoni M, Bovicelli A. Hysteroscopic metroplasty. *Ann N Y Acad Sci* 1994; 734: 488–92
- 66 Colacurci N, De Placido G, Mollo A, Carravetta C, De Franciscis P. Reproductive outcome after hysteroscopic metroplasty. *Eur J Obstet Gynecol Reprod Biol* 1996; 66: 147–50
- 67 Candiani GB, Fedele L, Zamferletti D, De Virgiliis D, Carinelli S. Endometrial patterns in malformed uteri. *Acta Eur Fertil* 1983; 14: 311–8
- 68 Fedele L, Bianchi S, Marchini M, Franchi D, Tozzi L, Dorta M. Ultrastructural aspects of endometrium in infertile women with septate uterus. *Fertil Steril* 1996; 65: 750–2
- 69 Dabirashrafi H, Bahadori M, Mohammad K, Alavi M, Moghadami-Tabrizi N, Zandinejad K, Ghafari V. Septate uterus. new idea on the histologic features in this abnormal uterus. *Am J Obstet Gynecol* 1995; 172: 105–7
- 70 Pellerito JS, McCarthy SM, Doyle MB, Glickman MG, DeCherney AH. Diagnosis of uterine anomalies: relative accuracy of MR imaging, endovaginal sonography, and hysterosalpingography. *Radiology* 1992; 183: 795–800
- 71 Letterie GS, Wilson J, Miyazawa K. Magnetic resonance imaging of Müllerian tract abnormalities. *Fertil Steril* 1988; 50: 365–9
- 72 Fedele L, Ferrazzi E, Dorta M, Vercellini P, Candiani GB. Ultrasonography in the differential diagnosis of 'double' uteri. *Fertil Steril* 1988; 50: 361–4
- 73 Randolph JR Jr, Ying YK, Maier DB, Schmidt CL, Riddick DH, Randolph JR Jr. Comparison of real-time ultrasonography, hysterosalpingography, and laparoscopy/hysteroscopy in the evaluation of uterine abnormalities and tubal patency. *Fertil Steril* 1986; 46: 828–32
- 74 Nicolini U, Bellotti M, Bonazzi B, Zamberletti D, Candiani GB. Can ultrasound be used to screen uterine malformations? *Fertil Steril* 1987; 47: 89–93
- 75 Masri MN, Setchell ME, Chard T. Transvaginal ultrasound for diagnosis of uterine malformations. *Br J Obstet Gynaecol* 1990; 97: 1043–5
- 76 Bonilla-Musoles F, Simon C, Serra V, Sampaio M, Pellicer A. An assessment of hysterosalpingosonography (HSSG) as a diagnostic tool for uterine cavity defects and tubal patency. *J Clin Ultrasound* 1992; 20: 175–81
- 77 Keltz MD, Olive DL, Kim AH, Arici A. Sonohysterography for screening in recurrent pregnancy loss. *Fertil Steril* 1997; 67: 670–4
- 78 Soares SR, Barbosa dos Reis, MMB, Camargos AF. Diagnostic accuracy of sonohysterography, transvaginal sonography, and hysterosalpingography in patients with uterine cavity diseases. *Fertil Steril* 2000; 73: 406–11
- 79 Jurkovic D, Geipel A, Gruboeck K, Jauniaux E, Natucci M, Campbell S. Three-dimensional ultrasound for the assessment of uterine anatomy and detection of congenital anomalies: a comparison with hysterosalpingography and two-dimensional sonography. *Ultrasound Obstet Gynecol* 1995; 5: 233–7
- 80 Jurkovic D, Gruboeck K, Tailor A, Nicolaides KH. Ultrasound screening for congenital uterine anomalies. *Br J Obstet Gynaecol* 1997; 104: 1320–1
- 81 Raga F, Bonilla-Musoles F, Blanes J, Osborne NG. Congenital Müllerian anomalies: diagnostic accuracy of three-dimensional ultrasound. *Fertil Steril* 1996; 65: 523–8
- 82 Weinraub Z, Maymon R, Shulman A, Bukovsky J, Kratochwil A, Lee A, Herman A. Three-dimensional saline contrast hysterosonography and surface rendering of uterine cavity pathology. *Ultrasound Obstet Gynecol* 1996; 8: 277–82
- 83 Lev-Toaff AS, Pinheiro LW, Bega G, Kurtz AB, Goldberg BB. Three-dimensional multiplanar sonohysterography. *J Ultrasound Med* 2001; 20: 295–306
- 84 Ayida G, Kennedy S, Barlow D, Chamberlain P. Contrast sonography for uterine cavity assessment: a comparison of conventional two-dimensional with three-dimensional transvaginal ultrasound: a pilot study. *Fertil Steril* 1996; 66: 848–50
- 85 Bonilla-Musoles F, Raga R, Osborne NG, Chamberlain P. Three-dimensional hysterosonography for the study of endometrial tumors: comparison with conventional transvaginal sonography, hysterosalpingography, and hysteroscopy. *Gynecol Oncol* 1997; 65: 245–52
- 86 Kupesic S, Kurjak A. Septate uterus: Detection and prediction of obstetrical complications by different forms of ultrasonography. *J Ultrasound Med* 1998; 17: 631–6
- 87 Sparac V, Kupesic S, Ilijas M, Zodan T, Kurjak A. Histologic architecture and vascularization of hysteroscopically excised intrauterine septa. *J Am Assoc Gynecol Laparosc* 2001; 8: 111–6
- 88 Kupesic S, Kurjak A. Uterine and ovarian perfusion during the periovulatory period assessed by transvaginal color Doppler. *Fertil Steril* 1993; 3: 439–43
- 89 Querleu D, Brasme TL, Parmentier D. Ultrasound-guided transcervical metroplasty. *Fertil Steril* 1990; 54: 995–8
- 90 Golan A, Schneider D, Avrech O, Raziell A, Bukovsky I, Caspi E. Hysteroscopic findings after missed abortion. *Fertil Steril* 1992; 58: 508–10
- 91 De Cherney AH, Russel JB, Graebe RA, Polan ML. Resectoscopic management of müllerian fusion defects. *Fertil Steril* 1986; 45: 726–8
- 92 Fedele L, Bianchi S, Marchini M, Mezzopane R, Di Nola G, Tozzi L. Residual uterine septum of less than 1 cm after hysteroscopic metroplasty does not impair reproductive outcome. *Hum Reprod* 1996; 11: 727–9
- 93 Mencaglia L, Tantini C. Hysteroscopic treatment of septate and arcuate uterus. *Gynaecol Endosc* 1996; 5: 151–4
- 94 Lin BL, Iwata Y, Miyamoto N, Hayashi S. Three contrast methods: an ultrasound technique for monitoring transcervical operations. *Am J Obstet Gynecol* 1987; 56: 469–72
- 95 Nisolle M, Donnez J. Endoscopic treatment of uterine malformations. *Gynaecol Endosc* 1996; 5: 155–60
- 96 Jermy K, Oyelese O, Bourne T. Uterine anomalies and failed surgical termination of pregnancy: the role of routine preoperative transvaginal sonography. *Ultrasound Obstet Gynecol* 1999; 14: 431–3