

CLINICAL INDICATIONS, ADVANTAGES AND LIMITS OF THE EXPANSION-CONDENSING OSTEOTOMES TECHNIQUE FOR THE CREATION OF IMPLANT BED

G. DE VICO, M. BONINO, D. SPINELLI, A. POZZI, A. BARLATTANI

University of Rome "Tor Vergata" Department of Odontostomatology
President: Prof. A. Barlattani

SUMMARY

Clinical indications, advantages and limits of the expansion-condensing osteotomes technique for the creation of implant bed

The "screw shaped" expansion-condenser are hand instruments that were introduced for the first time at the end of the 70' in order to improve bone density before the positioning of a dental implant. Thanks to these hand instruments it is possible to compact the bone apically and along the walls of the implant bed (Fig. 3) improving a lot the bone density and the primary stability of the implant even in situations where the starting bone quality is low (es. D3-D4 as in the classification y Lekholm and Zarb 1985) or in cases of severe bone atrophy. Allowing a manageable raising of the shnaiderian membrane through trans-alveolar way, this technique avoids in many cases the necessity to have recourse to the realisation of bone vestibular "gates" when it comes to the techniques of the big sinus lift. The knowledge of the bone visco-elastic and hystologic properties together with the maximum respect of the surgical protocol allows us to obtain % of success superior than traditional surgical protocol in D3-D4 bone class.

Key words: oral implantology, bone condensing, ridge expansion.

RIASSUNTO

Indicazioni e limiti all'utilizzo degli espanso-compattatori in implantologia orale

Gli espanso-compattatori sono strumenti manuali introdotti per la prima volta alla fine degli anni '70 al fine di migliorare la densità ossea in vista del posizionamento di un impianto dentale. Grazie alla loro azione progressiva e costante all'interno delle compagini mascellari, sono in grado di compattare ed espandere le trabecole ossee migliorando la stabilità implantare primaria sia in situazioni iniziali di osso di scarsa qualità (es: D3-D4), sia in casi di atrofie severe. Permettono inoltre un maggior controllo durante la preparazione del letto implantare nei protocolli di piccolo e grande rialzo del seno mascellare. Di contro, questi strumenti, determinando un insulto alla micro-circolazione vasale per compressione trabecolare necessitano dello scrupoloso rispetto del protocollo operativo e della profonda conoscenza delle caratteristiche visco-elastiche dell'osso.

Parole chiave: implantologia, compattazione ossea, espansione ossea.



Introduction

The "screw shaped" expansion-condenser are hand instruments (Fig. 1) that belongs to the group of the *osteotomes* (from the Greek *osteon*, trad. bone and *temno* trad. to cut), and for this reason

are able to form or shape bone in preparation for the placement of dental implants.

They were introduced for the first time at the end of the 70' by Doctor Hilt Tatum (1) in order to improve bone density before the positioning of a dental implant and they have been put as objects of important scientific researches all over the world (2-12, 23).

The goal of this work is to present a precise revision of the international literature with a particular reference to the “indications” and to the “limits” which are linked to the utilisation of the expansion-condensing osteotomes in oral implantology. There are three main indications to the utilisation of the expansion-condensing osteotomes in oral implantology:

- bone compaction
- ridge expansion
- elevation of the schnaiderian membrane in the sinus lift procedure.

Clinical procedures

1. BONE COMPACTION. It's now reconised that the long term success of a dental implant is linked to a number of factors (13). Among them, one of the main traits for a successful osteointegration is of course the acquisition of a good primary implant stability. This stability depends from different traits like the morphology of the implant, which kind of surgery protocol is used, but above all from the bone quantity and quality. There are some clinical situations for example, in which the bone quality is so low to compromise this important starting condition. It's for this reason that at the end of the seventies Doctor Hilt Tatum proposed a kit of hand instruments (Fig. 2) in order to improve the bone density before the positioning of

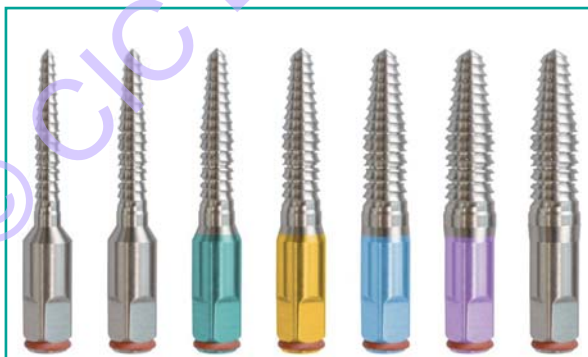

Figure 1
Osteotomes BTLock.

a dental implant (1). The biological principle which inspired the idea of it is the trabecular visco-elastic, which is a trait that makes the bone able to be compressed and manipulated. Thanks to these hand instruments it is possibile to compact the bone apically and along the walls of the implant bed (Fig. 3) improving a lot the bone density and the primary stability of the implant even in situations where the starting bone quality is low (es. D3-D4 as in the classification y Lekholm and Zarb 1985). When the bone quality is really bad, a grafting material can be used by putting it in the implant bed, compacting it with the *osteotomes* long the walls (8). This operation will allow to obtain a better primary stabilisation of the fixture.

2. RIDGE EXPANSION. The expansion-condensing osteotomes allow to expand the alveolar ridge bucco-lingually in a easier and less invasive way than the traditional surgery techniques that involve to spread the buccal and lingual plates of the bone. (3).



Figure 2
Tatum's osteotomes.

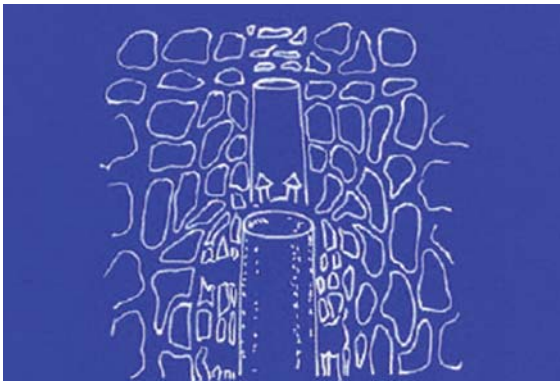


Figure 3
Bone condensing plan.

These technique can be used together in cases where the width of the alveolar ridge is less than 3 mm.

Protocol A: width of the alveolar ridge ≥ 3 mm. In these cases the operative sequence expects the utilisation of just one drill, usually a $\text{Ø } 1.3\text{-}2$ mm (Fig. 4) which will determine the axis and the depth of the work, and afterwards in a sequence the expansion-condensing osteotomes till reaching a good diameter of the implant bed able to guarantee a good primary implant stability (Fig. 5). The dimensions of the working parts of every single instrument are put in a way that the coronal di-




Figure 4
Pilot drill.

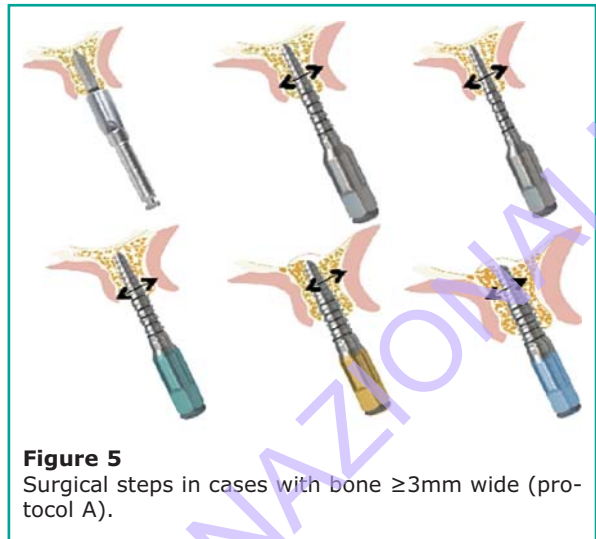

Figure 5
Surgical steps in cases with bone $\geq 3\text{mm}$ wide (protocol A).

ameter of the first instrument is corresponded with the apical diameter of the next one (Fig. 1). This characteristic, joined to aslow and gradual movements, allows to have a continuous control of the entity of the expansion of the vestibular bone plate, allowing the immediate suspension of the process at the very first sign of complication. Even if sometimes, despite our attentions, some fractures happens at the vestibular portion, especially on its most coronal part (Fig. 6).

When happens these fractures, as long as they don't compromise the primary stability implant stability, are of no importance, since they reconsolidate in the following osteointegration phases (20-29). Possibly, the gaps among the *fractures* can be filled with autologos bone chips which are taken from the close sites or with grafting material (Fig. 7).

A fundamental condition for the success of both this and all the other protocols which expect the utilisation of the expansion-condensing osteotomes, is that every instrument must remain in the implant bed, at the fixed work depth, at least one minute before proceeding with the next one. At the same way in the moment of their removal, in case there is an excessive resistance, it should be waited another minute before proceeding ahead. All this is very important in order to give the exact time for the bone to adapt itself at the new spatial conformation and to avoid the ialinization of peri-implant bone.

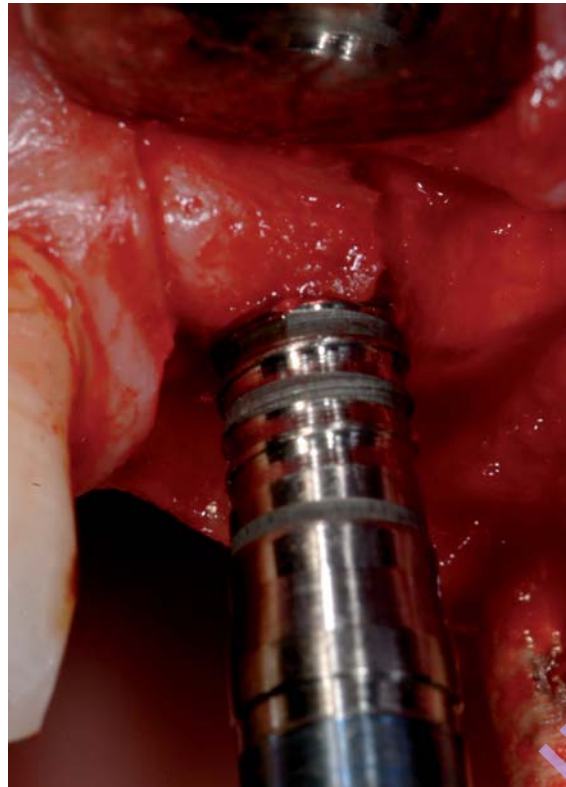


Figure 6
Fractures can appear during final preparation with osteotomes.

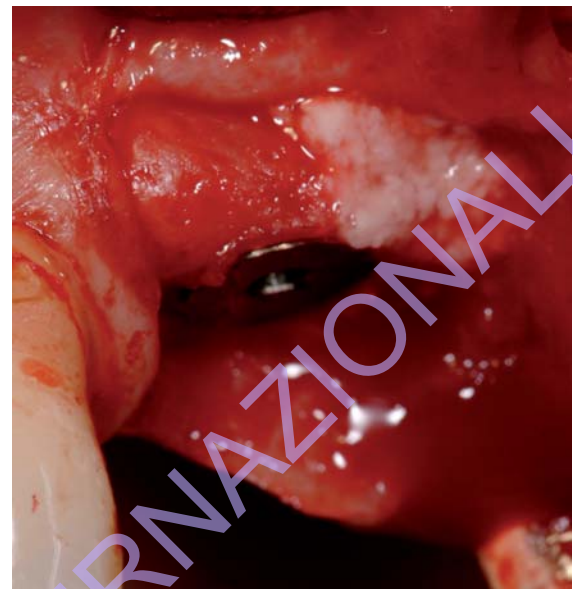

Figure 7
Provided they don't compromise primary implant stability, these fractures consolidate during the osteointegration phase.

Protocol B: width of the remaining bone ridge < di 3 mm or in D1-D2 bone class.

In these cases, the described technique must be associated always to a split crest technique (Figs 8-12). In this way after the initial osteotomies the expansion-condensing osteotomes can take the place of the traditional cuneal osteotomes allowing a major control of the entity of the movement of the vestibular cortical bone joined to a major comfort for the patient instead of the traditional technique with surgical mallet (3, 5, 14). In some rare cases, moreover, in presence of very bad atrophies of the bone it's possible to proceed with a splitting in two times. So, at the end of the first surgery phase and before the closure some wedges made with spongiosa riassorbibile or collagen are put in order to maintain distant the two corticals (30). Afterwards, after 45 days approx, that is when all the mechanisms for the bone reparation are activated,

but the mineralization is still not finished, there is the second phase of splitting making the best of the natural elasticity of the bony corn, until the positioning of the implant. In this way there's much less risk of determine some sharp fractures of the vestibular cortical and following necrosis (15).

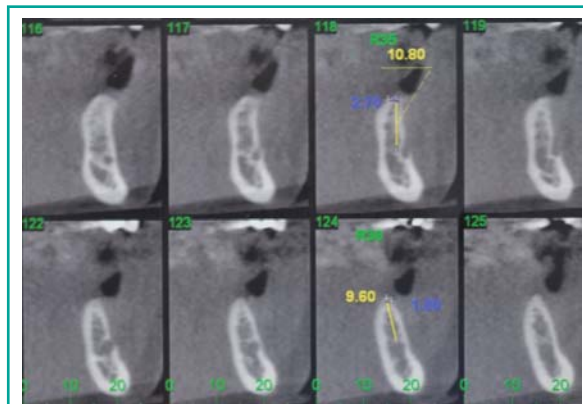


Figure 8
Denta-scan shows a serious mandibular atrophy.

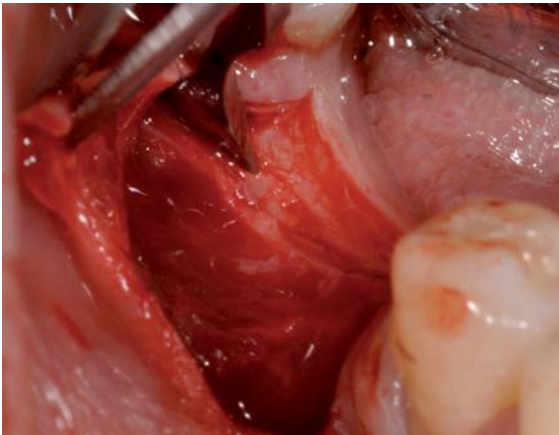


Figure 9
The initial osteotomies.

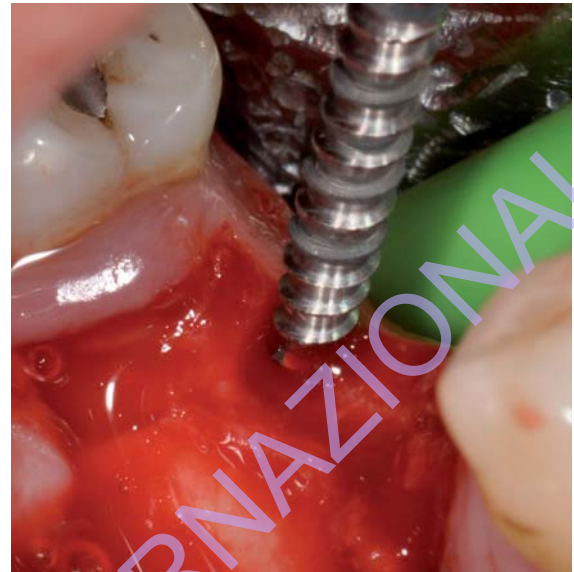

Figure 11
The osteotomes guarantee a greater control of the bone expansion.

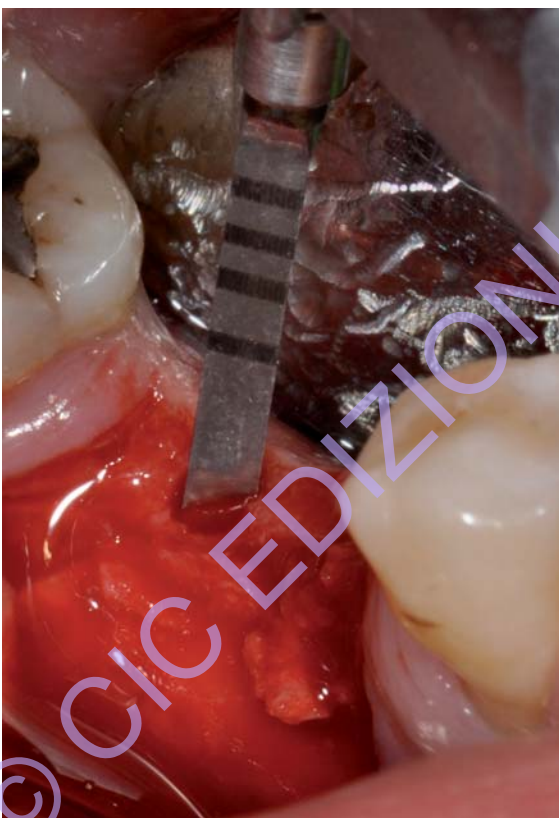

Figure 10
After osteotomies the pilot drill guides the depth preparation.

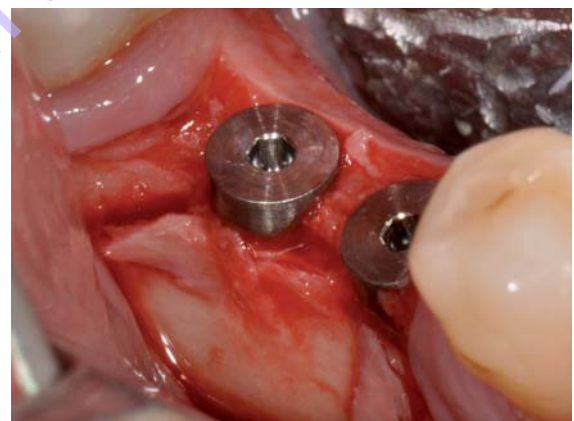


Figure 12
In this way we can put implants of correct dimensions also in cases of serious atrophy.

3. SINUS FLOOR ELEVATION. The third major indication for using osteotomes is when alveolar bone in the posterior maxilla has resorbed so

much that less than 10 mm remains between the crest of the ridge and the sinus floor (Fig. 13) (16, 17). The bone condensing osteotomes can be used in these cases in order to elevate the Shnaiderian membrane in both the minus and the big sinus lift technique (Figs 14, 15) (7-18). We want to remember that instruments never have to

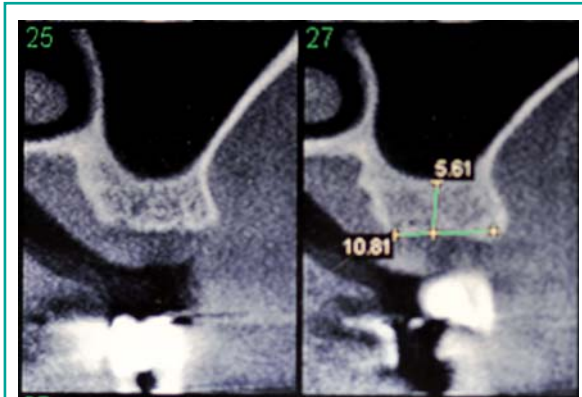


Figure 13
The post-extraction atrophy and the sinus pneumatization prevent in much cases implant placement.

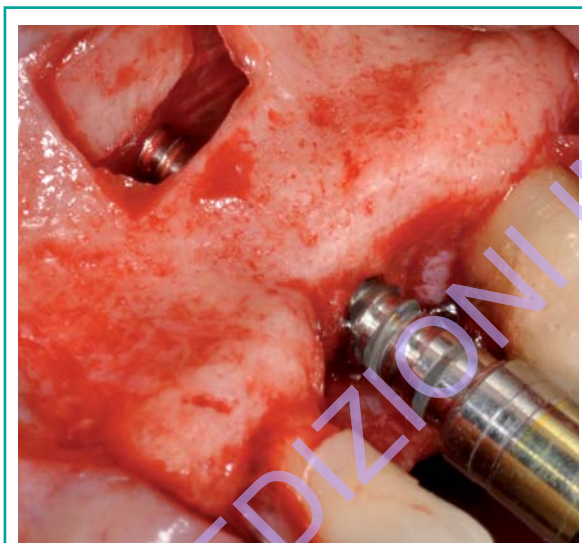


Figure 14
The osteotomes guarantee a greater control during bone preparation with big control of the sinus membrane.

entry inside the sinus, and that the elevation of the membrane is due to the hydraulic pressure of bloody and the grafting materials, according to Pascal principle. An interesting application is the PEMSL technique (post-extractive-minor-sinus-lift) (18). According to this technique in presence of a good inter-radicular post-extractive bone setus (width ≥ 3 mm and height ≥ 7 mm), is possible, by using bone condensing osteotomes, put an implant of correct size and simultaneously have a

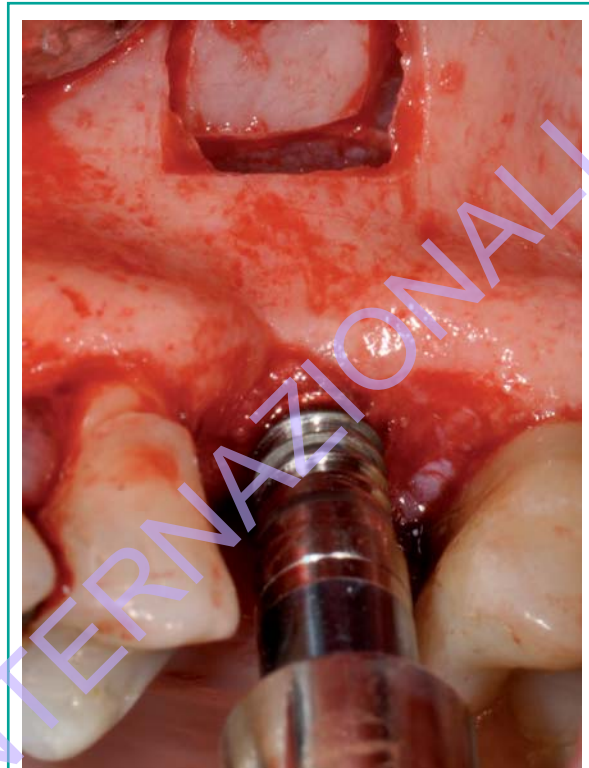


Figure 15
The osteotomes technique in the big sinus lift.

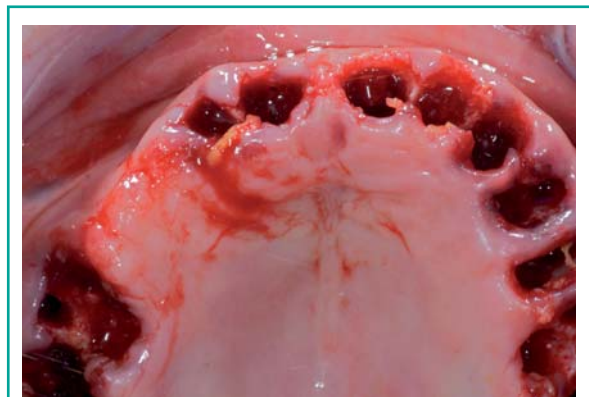


Figure 16
Post-extractive bone crest. The protocol foresees the implant preparation in the inter-dental and inter-radicular bone set.

minus sinus lift (Figs 16, 17). In these cases, by using the screw shaped osteotomes instead of the traditional osteotomes with surgical mallet, we

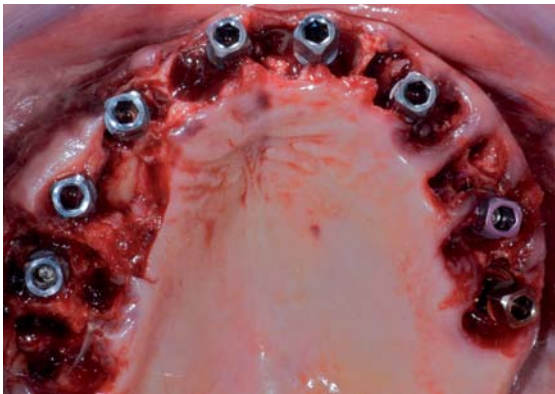


Figure 17
Thanks to the osteotome technique all the implants have been correctly positioned also in this critical situation.



Figure 18
Simulated implant preparation on the left it's easy to verify the very good bone preservation with the osteotomes protocol.

increase the confort for the patient during the surgery, and we annul totally the risk of paroxysmal positional vertigo as a complication of osteotome sinus floor elevation (19).

Clinical advantages

From Our clinical experience and from the analysis of the international literature emerge several clinical advantages. First of all, the preparation of an implant bed through the protocol of the expansion-condensing osteotomes guarantees the **maximum preservation of the remaining bone**. The surgery protocol includes as a matter of fact the utilisation of just one drill able in cutting the bone followed in sequence by manual instruments of progressively growing diameter. In this way it is very reduced the missing of the bone respective to the traditional protocol exclusively through drillings (Fig. 18). And all this together with the increasing of bone properties will contribute to guarantee an **improvement of the primary implant stability**. After that, the bone condensing osteotomes that are used manually and put each of them over an esagonal screwdriver (Fig. 19), in their progres-



Figure 19
Every osteotome is mounted during bone preparation on an esagonal screwdriver.

sive action inside the bone cancel completely the risk of over-heating thanks to a big control of heat generation. Moreover and thanks to the manual action they guarantee a **major tactile sensibility** and a **major visibility and control** of the axis and of the depth of the job (Fig. 20). For this reason, for the preparation of the implant bed in the pterigoidea area, these instruments should be preferred to the traditional drilling protocol, in order to avoid the damage of the close nerve and vascular structures (31).

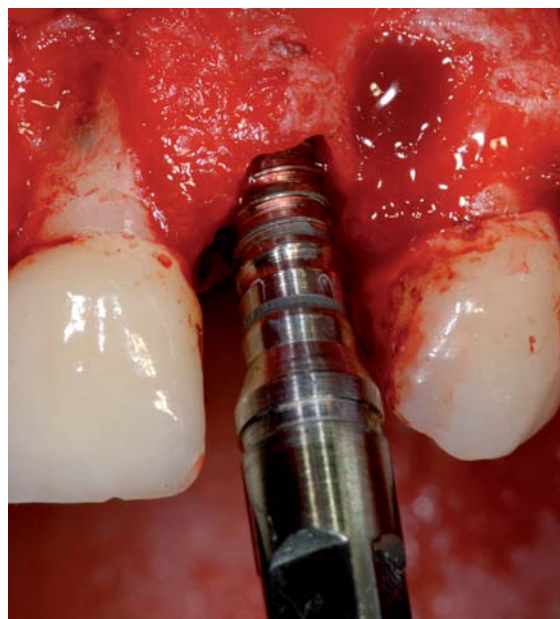

Figure 20

The osteotomes allow also in difficult cases a greater control of the axes and the depth of the implant preparation.

Limits

Starting from the matter of fact that these instruments for reasons of obstacle find difficult to be used in posterior sectors above all in patients with a limitate open of the mouth, the main limits linked to the utilisation of the expansion-condensing osteotomes happen because of two factors: clinical and histological. Clinically, as described above, it's necessary at least a 3mm width of the remaining bone crest; if this doesn't happen other alternative surgery techniques will be used (eg. Split Crest).

What is important, though, is the densimetric analysis of the bone that is very important in this technique because bone condensing osteotomes are not indicated in D1-D2 bone class for the risk to determinate an important damage to the vessels microcirculation for compression and trabecular fractures (12), causes a 2-3 months average extension of the times for healing and complete osteoin-

tegration respect to the normal protocol (20), and in some cases the loosening of the implant after loading.

The condensed bone in this way will have to put in act a double repairing mechanism, from one side represented by the normal processes of osteointegration and on the other side from the processes of the reparation post fracture like (22). There are real BMU (bone modelling unit) which at first have to create new spaces for the new vessels and afterwards filling all the gaps bone-implant. This would explain why the major part of the istomorphometrics studies followed on groups of implant put with this protocol in D1-D2 bone class were reporting % di BIC (bone implant contact) on average always lower than the implant which were put in a traditional way, even after 28 days (12, 21). In front of these conclusions there is the consideration of the fact that a series of studies (24-26) were showing, on the other side, % di BIC always superior in the groups of implants put in D3-D4 bone class, joined to a more intense signal of bone formation, with % success of very high implants instead of the almost total failures reported in similar studies (12, 20, 21).

Discussion

The our experience in the application of this technique in all bone classes allows us to elaborate a surgical protocol depending on the respect of some golden rules. First of all the "passive fit" principle suggested by Stavropoulos e Lang (20) should be re-examined according to the new considerations about the primary implant stability and the new implant design. That is achieving of good primary stability and torque insertion values can not be obtained damaging micro-vessels without dangerous bone peri-implant remodelling. Moreover the "passive fit" principle is not in line with current international trend that foresees an immediate patients rehabilitation. An intelligent preparation of the implant bed by using expanding-condensing osteotomes, in D3-D4 bone class and also

in D1-D2 bone class in association with split-crest technique, allows to keep microdeformations value under 3000 μ strains that Frost (27) thinks would be the maximum limit after which the bone would be incapable to heal and would go in necrosis. To increase the value of research of this “no stress implant fitting” there is the confirm of the fact that actually some experimental studies (28) demonstrated that the osteointegration happens 1-2 weeks before in those parts of the fixture that initially are not touching the mineralised bone instead of those one that touch the bone and that are responsible of the primary stability.

Conclusions

The technique of the expansion-condensing osteotomes allows the implant positioning even in cases of important bone atrophy, without using surgery techniques that are more difficult and invasive, improving at the same time and clearly the stability of the implant through trabecular compactation. Allowing a manageable raising of the Schneiderian membrane through trans-alveolar way, this technique avoids in many cases the necessity to have recourse to the realisation of bone vestibular “gates” when it comes to the techniques of the big sinus lift. Nevertheless the technique in these cases needs more learning time but at the end the comfort for the patients and the results are excellent. The knowledge of the bone visco-elastic and histologic properties together with the maximum respect of the surgical protocol allows us to obtain % of success superior than traditional surgical protocol in D3-D4 bone class.

References

1. Tatum H. Maxillary and Sinus Implant Reconstructions. Dent Clin North Am 1986.
2. Osborn JF. Die Alveolar-Extensions Plastik. Quintessenz 1985; 36:239-246.
3. Scipioni A, Bruschi GB. The edentulous ridge expansion technique: a five year study. Int J Period Res Dent 1994; 14: 451-459.
4. Summers RB. A new concept in maxillary implant surgery: the osteotome technique. Compendium of Continuing Education in Dentistry 1994; 15: 152-158.
5. Simion M, Baldoni M, Zaffe D. Jawbone enlargement using immediate implant placement associated with a split crest technique and guided tissue regeneration. Int J Period Res Dent 1992; 12: 462-473.
6. Saadoun AP, Le Gall MG. Implant site preparation with osteotomes: principles and clinical application. Pract Periodont Aesthetic Dent. 1996; 8: 453-483.
7. Summers RB. Sinus floor elevation with osteotomes. Journal of Esthetic Dentistry 1998; 10: 164-171.
8. Hahn J. Clinical Uses of Osteotomes. Journal of Oral Implantology. Vol. XXV-1-1999.
9. Hahn J and Co. Aesthetic Enhancement of Anterior Dental Implants With The Use of Tapered Osteotomes And Soft Tissue Manipulation. Journal of Oral Implantology. Vol. XXV-1-1999.
10. Strietzel FP, Novak M. Changes in the alveolar ridge level in implantation using the osteotome technique. Mund-Kiefer und Gesichtschirurgie 1999; 3: 309-313.
11. Strietzel FP, Novak M, Kuchler I, Friedmann A. Peri-implant alveolar bone loss with respect to bone quality after use of the osteotome technique. Results of a retrospective study. Clinical Oral Impl Res 2002; 13: 508-513.
12. Büchter A, et coll. Interface Reaction at dental implants inserted in condensed bone. Clin Oral Impl Res 2005; 16: 509-517.
13. Albrektsson T et al. The long term efficacy of currently used dental implants: a review and proposed criteria of success. International Journal of Oral Maxillofacial Implants 1986; 1: 11-25.
14. Assenza B, Leghissa G, Tortora P. Espansione controllata delle creste atrofiche nei mascellari. Inserimento contemporaneo degli impianti. Italian Oral Surgery 2004; 1: 7-15.
15. Assenza B, Bondioli G. L'espansione ossea controllata in mandibola: due tecniche a confronto in osso D1 e D2. Italian Oral Surgery 2007; 1: 33-46.
16. Rossi A, Chiapasco M. Il rialzo del seno mascellare a scopo implantologico: classificazione del deficit osseo, tecniche di trattamento e biomateriali impiegabili. Implantologia Orale 2004; 1: 41-57.
17. Chiapasco M et al. Il rialzo del seno mascellare a scopo implantologico. Implantologia Orale 2005; 1: 9-34.
18. Di Girolamo M et al. Metodica implantare nei settori posteriori del mascellare superiore: PEMSL (post-extractive-minor-sinus-lift). Implantologia 2006; 3: 215-222.
19. Di Girolamo M, Napolitano B, Arullani CA, Bruno E, Di Girolamo S. Paroxysmal vertigo as a complication

- of osteotome sinus floor elevation. *Eur Arch Otorhinolaryngol* 2005; 262 (8): 631-3.
20. Stavropoulos A, Lang NP et al. Immediate loading of single SLA implants: drilling vs osteotomes for the preparation of the implant site. *Clin Oral Impl Res* 2008; 19: 55-65.
 21. Büchter A et al. Biological and biomechanical evaluation of bone remodelling and implant stability after using an osteotome technique. *Clin Oral Impl Res* 2005; 16: 1-8.
 22. Frost HM. A brief review for orthopaedic surgeons: fatigue damage (microdamage in bone, its determinants and clinical implications). *Journal of Orthopaedic Science* 1998; 3: 272-281.
 23. Anitua E. Ridge expansion with motorized expander drills. *Dental Dialogue* 2004; 2: 3-14.
 24. Chaushu G et al. Immediate loading of single-tooth implants: immediate vs non immediate implantation. A clinical report. *International Journal of Oral and Maxillofacial Implants* 2001; 16: 267-272.
 25. Calandriello R. et al. Immediate functional loading of Branemark system implants with enhanced initial stability: a prospective 1 to 2 year clinical and radiographic study. *Clinical Implant Dentistry and Related Research* 2003; 5:10-20.
 26. Nkenke E et al. Histomorphometric and fluorescence microscopic analysis of bone remodelling after installation of implants using an osteotome technique. *Clin Oral Impl Res* 2002; 13: 595-602.
 27. Frost H.M. Mechanical determinants of bone modeling. *Metabolic Bone Disease and Related Research* 1982; 4: 217-229.
 28. Berglundh T. et al. De novo alveolar bone formation adjacent to endosseous implants. *Clin Oral Implants Res* 2003; 14: 251-262.
 29. Rambla-Ferrer J, Penarrocha-Diago M, Guarinos-Carbò J. Analysis of the use of expansion osteotomes for the creation of implant beds. Technical contributions and review of the literature. *Med Oral Patol Oral Cir Bucal* 2006; 11: E267-71.
 30. Bravi F, Bruschi GB, Ferrini F. Uno studio clinico retrospettivo multicentrico decennale di 1715 impianti inseriti con la tecnica di espansione della cresta edentula. *Rivista Internazionale di Parodontologia e Odonoiatria Ricostruttiva*. Volume 27 numero 2007; 6: 557-565.
 31. Fernandez J et al. Placements of screw type implants in the pterygomaxillary pyramidal region: surgical procedure and preliminary results. *Int Journal Oral Maxillofacial Implants* 1997; 12: 814-819.

Correspondence to:

Dott. Giovanni De Vico
Via Flaminia Vecchia 798
00191 Roma
E-mail: giovannidevico@hotmail.com