

Original Investigation

Clinical Presentation of Ocular Surface Squamous Neoplasia in Kenya

Stephen Gichuhi, MMed; Ephantus Macharia, HND; Joy Kabiru, MMed; Alain M'bongo Zindamoyen, MMed; Hilary Rono, MMed; Ernest Ollando, MMed; Leonard Wanyonyi, HND; Joseph Wachira, MMed; Rhoda Munene, MMed; Timothy Onyuma, MMed; Mandeep S. Sagoo, FRCOphth; Helen A. Weiss, PhD; Matthew J. Burton, PhD

IMPORTANCE There is a trend toward treating conjunctival lesions suspected to be ocular surface squamous neoplasia (OSSN) based on the clinical impression.

OBJECTIVE To describe the presentation of OSSN and identify clinical features that distinguish it from benign lesions and subsequently evaluate their recognizability.

DESIGN, SETTING, AND PARTICIPANTS Prospective multicenter study in Kenya from July 2012 through July 2014 of 496 adults presenting with conjunctival lesions. One histopathologist examined all specimens. Six additional masked ophthalmologists independently examined photographs from 100 participants and assessed clinical features.

EXPOSURES Comprehensive history, slitlamp examination, and photography before excision biopsy.

MAIN OUTCOMES AND MEASURES Frequency of clinical features in OSSN and benign lesions were recorded. Proportions and means were compared using χ^2 , Fisher exact test, or t test as appropriate. Interobserver agreement was estimated using the κ statistic. Examiners' assessments were compared with a reference.

RESULTS Among 496 participants, OSSN was the most common (38%) histological diagnosis, followed by pterygium (36%) and actinic keratosis (19%). Patients with OSSN were slightly older (mean [SD] age, 41 [11.6] vs 38 [10.9] years; $P = .002$) and tended to have lower levels of education than patients with benign lesions ($P = .001$). Females predominated (67% of OSSN vs 64% of benign lesions; $P = .65$). Human immunodeficiency virus infection was common among patients with OSSN (74%). The most common location was the nasal limbus (61% OSSN vs 78% benign lesions; $P < .001$). Signs more frequent in OSSN included feeder vessels (odds ratio [OR], 5.8 [95% CI, 3.2-10.5]), moderate inflammation (OR, 3.5 [95% CI, 1.8-6.8]), corneal involvement (OR, 2.7 [95% CI, 1.8-4.0]), leukoplakia (OR, 2.6 [95% CI, 1.7-3.9]), papilliform surface (OR, 2.1 [95% CI, 1.3-3.5]), pigmentation (OR, 1.5 [95% CI, 1.0-2.2]), temporal location (OR, 2.0 [95% CI, 1.2-3.2]), circumlimbal location (6.7% vs 0.3%; $P < .001$), severe inflammation (6.7% vs 0.3%; $P < .001$), and larger mean (SD) diameter (6.8 [3.2] vs 4.8 [2.8] mm; $P < .001$). All OSSN signs were also observed in benign lesions. There was slight to fair interobserver agreement in assessment of most signs and diagnosis (κ , 0.1-0.4). The positive predictive value of clinical appearance in identifying OSSN was 54% (interquartile range, 51%-56%) from photographs in which prevalence was 32%.

CONCLUSIONS AND RELEVANCE With overlapping phenotypes and modest interobserver agreement, OSSN and benign conjunctival lesions are not reliably distinguished clinically. Point-of-care diagnostic tools may help.

JAMA Ophthalmol. 2015;133(11):1305-1313. doi:10.1001/jamaophthalmol.2015.3335
Published online September 17, 2015.

← Invited Commentary
page 1321

← Related article page 1314

+ Supplemental content at
jamaophthalmology.com

Author Affiliations: Author affiliations are listed at the end of this article.

Corresponding Author: Stephen Gichuhi, MMed, International Center for Eye Health, London School of Hygiene and Tropical Medicine, Keppel Street, London WC1E 7HT, England (stephen.gichuhi@lshtm.ac.uk).

Ocular surface squamous neoplasia (OSSN) is a spectrum of disease ranging from noninvasive intraepithelial dysplasia of the conjunctiva and cornea to invasive squamous cell carcinoma.¹ Worldwide, the incidence of OSSN is highest in the southern hemisphere (16°S), with the peak occurring in Africa.²

The benchmark for diagnosis of OSSN is histopathologic analysis; however, the availability of this service is limited in Africa.^{3,4} The decision to excise conjunctival lesions usually depends on the clinical impression. Most lesions are excised without subsequent histopathological confirmation of the diagnosis or information on tumor involvement of the excision margins. Even in countries with good access to pathology services, many lesions suspected of being OSSN are treated without histological confirmation of the diagnosis. In 2003, a standard-of-care survey in the United States showed that 51% of respondents always perform biopsies before instituting therapy for suspected OSSN lesions.⁵ This proportion was unchanged when the same survey was repeated in 2012.⁶ There are several reports from other regions where primary treatment for suspected OSSN tumors is provided using topical agents (mitomycin, fluorouracil, and interferon alfa-2b) without excision for histopathological diagnosis.⁷⁻¹⁰ The rationale for this practice is to reduce the complications of excision such as limbal stem cell deficiency with large lesions or symblepharon. Population surveys to determine the prevalence of pinguecula or pterygium also rely on a clinical diagnosis to distinguish them from OSSN and other benign lesions.¹¹⁻¹³

Several studies have tried to identify clinical features that may distinguish OSSN. A study in Tanzania found that OSSN lesions had a shorter mean duration than benign lesions (3.7 vs 8.8 months; $P = .03$) whereas feeder vessels were more frequently associated with OSSN than benign lesions ($P = .03$).¹⁴ Male sex, temporal and superior locations, lack of corneal involvement, and papillomatous and nodular appearance were associated with higher-grade OSSN lesions in a US study.¹⁵ The OSSN lesions in human immunodeficiency virus (HIV)-infected individuals may be more likely to be of a higher grade of malignancy than those in HIV-negative patients.¹⁶

The aim of this study was to describe the clinical presentation of OSSN in Kenya and determine what clinical features might help to distinguish it from benign lesions. The main focus was on the frequency of clinical features in OSSN that could help to differentiate OSSN from other benign conjunctival lesions in this setting and the interobserver variability in the recognition of these features.

Methods

Ethical Approval

This study was part of an integrated set of investigations into OSSN in Kenya. It was formally reviewed and approved by the Kenyatta National Hospital-University of Nairobi Ethics and Research Committee and the London School of Hygiene and Tropical Medicine Ethics Committee. This study adhered to the tenets of the Declaration of Helsinki. All participants gave in-

At a Glance

- Among 496 individuals with ocular surface lesions, ocular surface squamous neoplasia (OSSN) was the most common cause (38%), followed by pterygium (36%) and actinic keratosis (19%).
- Mean age was 41 years for OSSN and 38 years for benign lesions.
- Females predominated (67% of OSSN and 64% of benign lesions).
- The rate of human immunodeficiency virus infection among patients with OSSN was high (74%).
- Ocular surface squamous neoplasia and benign conjunctival lesions have overlapping phenotypes and cannot always be reliably distinguished on clinical grounds; interobserver agreement was modest.

formed written consent to take part in the study before enrollment and did not receive a stipend to participate.

Participants

Recruitment was between July 2012 and July 2014 in 4 eye care centers: Kenyatta National Hospital in Nairobi; PCEA Kikuyu Eye Unit, approximately 25 km from Nairobi in central Kenya; Kitale district hospital, in the north Rift Valley 490 km from Nairobi; and Sabatia Eye Hospital, 300 km from Nairobi in the western highlands bordering Lake Victoria. We prospectively recruited all consenting, consecutive self-presenting adult patients (at least 18 years of age) with any conjunctival lesion (first presentation or a recurrence) suspected to be OSSN scheduled for surgery. Pregnant women and breastfeeding mothers were excluded.

Clinical Assessment

A comprehensive history was taken using a structured questionnaire, and the eyes were examined with a slit lamp. The widest diameter of the lesion was measured using the slit-lamp beam and scale. A pair of photographs of each lesion was taken, 1 in primary gaze and the other with the lesion in the center of the field. We used a Nikon D90 digital camera with Micro Nikkor 105-mm F2.8 AFS zoom lens and the R1 close-up speedlight. All photographs were taken at 1:1 magnification ratio.

Surgery and Histopathologic Analysis

All lesions were excised under local anesthetic using an operating microscope with a 3-mm clear margin. Cryotherapy was not applied because the participants were further invited to enroll in a treatment trial postoperatively. Specimens were placed directly into buffered formalin and subsequently examined at the histopathology laboratory at the MP Shah Hospital, Nairobi. One pathologist examined all the histology slides. Participants with mild, moderate, or severe conjunctival intraepithelial neoplasia (CIN 1, 2, or 3, respectively), together with any who had carcinoma in situ or invasive squamous cell carcinoma, were classified as having OSSN. A 3-grade system was used to classify carcinomas histologically as either well, moderately, or poorly differentiated in accordance with the American Joint Committee on Cancer.¹⁷ Benign lesions included pterygium, actinic keratosis, papillomas, pyogenic

granulomas, nevi, and rhinosporidiosis. The diagnosis of actinic keratosis was based on the presence of elastotic stromal degeneration, acanthosis, hyperkeratosis, and parakeratosis in the presence of normal cellular polarity. By the accepted criteria for dysplasia, such lesions were classified as CIN only if there was loss of polarity.

Patients with OSSN were invited to enroll in a case-control study that involved testing for HIV and CD4 count. Testing for HIV was initially performed using Vironostika antigen/antibody kit then later changed to rapid tests using Alere Determine HIV-1/2 Ag/Ab and Trinity Unigold. CD4 count was tested using FACSCount (Becton Dickinson). Those with benign lesions were not tested. Voluntary testing and counseling were offered at the health facility.

Interobserver Study

To determine the interobserver variability in the assessment of the clinical features, 6 final-year ophthalmology residents in the University of Nairobi Department of Ophthalmology at Kenyatta National Hospital independently assessed photographs from the last 100 consecutive participants enrolled into the study from 1 center. They were masked to the diagnosis. Images were projected onto a screen. The clinical case mix was the same in this sample of patients compared with the whole data set that included patients from all 4 study centers. Cases with features that may suggest malignancy, such as very large tumors filling the orbit, were excluded from this assessment. The graders were asked to determine whether each feature was either present, absent, or difficult to determine.

Statistical Analysis

Data were managed in an Access database (Microsoft), cleaned, and transferred into STATA, version 12.1 (StataCorp), for analysis. In this analysis, we compared the clinical features of OSSN and benign lesions. Large orbital tumors and non-OSSN malignant neoplasms were excluded. Categorical variables were compared using the Pearson χ^2 test, odds ratios (ORs), or Fisher exact test where appropriate. Logistic regression analysis was used to obtain adjusted ORs. To determine whether continuous variables were normally distributed, we generated quantile-quantile plots and compared the variances in both groups using the standard deviation test. Where the deviations differed the *t* test was conducted with unequal variances.

The interobserver agreement between graders was compared using the κ statistic without weighting and graded using the Landis and Koch method as poor, slight, fair, moderate, substantial, or almost perfect.¹⁸ To calculate an average value, the κ statistics for each grader were transformed to *z* scores using the Fisher *z* transformation, averaged, and then back-transformed to κ .

Results

Five hundred thirty-seven participants with conjunctival lesions were enrolled. Histology reports were available for 496 participants. Eighteen tissue specimens were autolyzed on ar-

rival at the pathology laboratory, perhaps from poorly reconstituted formalin (one was a batch of 16 from 1 center), and 22 were presumed lost in transit. Seven (1.4%) were large orbital tumors. A total of 488 participants were therefore included in the analysis of clinical features.

Histopathological Diagnosis

Ocular surface squamous neoplasia was the most common type of ocular surface lesion (38%) (eTable 1 in the Supplement). This was followed by pterygium (36%) and actinic keratosis (19%), which were the most common benign lesions. All stages of OSSN were seen, with the most frequent being moderately differentiated squamous cell carcinoma. There was 1 case of sarcomatoid spindle cell carcinoma and a wide range of benign lesions.

Demographic Characteristics

The demographic characteristics of participants, subdivided by the pathologic type, are presented in Table 1. Approximately two-thirds were female (65%), with no sex difference between patients with OSSN and benign lesions. Most individuals presenting with conjunctival lesions were young to middle-aged adults (mean [SD] age, 39 [11.3] years). Participants with OSSN were slightly older than those with benign lesions ($P = .002$) and more likely to be widowed and to have a lower level of education. Those who did not have any formal education had the highest risk of OSSN after adjustment for age and marital status.

Clinical History

The primary symptoms at presentation are given in eTable 2 in the Supplement. Overall, the presenting symptoms were similar by disease group ($P = .14$). The most frequent presenting complaint was a lump or swelling (67%); less frequent were pain (12%), redness (6%), and itchiness (5%).

Additional information on the clinical history is presented in eTable 3 in the Supplement. Median (interquartile range [IQR]) duration from onset of symptoms to presentation was longer for OSSN than benign tumors (8 [4-21] vs 5 [2-17] months; $P = .03$), and a history of prior conjunctival excision was more frequent in patients with OSSN than those with benign lesions (18% vs 6%; $P < .001$). The mean [SD] number of prior excision procedures in patients who had undergone them was, however, similar in both groups (1.4 [0.8] vs 1.3 [0.7]; $P = .66$). There was no evidence of a difference between OSSN and benign lesions in terms of a family history of eye cancer or cancer at another site.

There was significant evidence that participants with OSSN had longer sun exposure in their current ($P = .02$) and previous ($P = .003$) occupation but little evidence that they had a current predominantly outdoor occupation (64% vs 57%; $P = .14$) or worked outdoors in previous employment (57% vs 48%; $P = .22$). There was no significant difference in the proportion who wore hats or sunglasses or who smoked cigarettes (eTable 3 in the Supplement). However, among smokers, the mean (SD) number of cigarettes smoked daily was higher among patients with OSSN (12 [11] vs 7 [6]; $P = .03$).

Table 1. Demographic Characteristics of Participants With Ocular Surface Squamous Neoplasia (OSSN) and Benign Conjunctival Lesions Including Orbital Disease

Demographic Characteristic	OSSN (n = 187)	Benign Lesions (n = 308)	OSSN vs Benign Lesions			
			Crude OR (95% CI)	P Value	Adjusted OR ^a (95% CI)	P Value
Sex, No. (%)						
Male	62 (33.2)	110 (35.7)	1 [Reference]	.56	1 [Reference]	.65
Female	125 (66.8)	198 (64.3)	1.1 (0.8-1.6)		1.1 (0.8-1.6)	
Age, mean (SD), y	41 (11.6)	38 (10.9)	NA	.002 ^b	NA	NA
Marital status, No. (%)						
Single	30 (16.0)	42 (13.6)	1 [Reference]	.04	1 [Reference]	.05
Married	123 (65.8)	231 (75.0)	0.8 (0.4-1.3)		0.5 (0.3-0.9)	
Divorced or separated	11 (5.9)	18 (5.8)	0.9 (0.4-2.1)		0.5 (0.2-1.3)	
Widowed	23 (12.3)	17 (5.5)	1.9 (0.9-4.2)		0.9 (0.4-2.2)	
Highest education level, No. (%)						
More than secondary	17 (9.1)	66 (21.4)	1 [Reference]	.001	1 [Reference]	<.001
Completed secondary school	58 (31.0)	85 (27.6)	2.7 (1.4-5.0)		2.7 (1.4-5.1)	
Some secondary school	13 (7.0)	37 (12.0)	1.4 (0.6-3.1)		1.4 (0.6-3.4)	
Completed primary school	57 (30.5)	74 (24.0)	3.0 (1.6-5.8)		3.1 (1.6-5.9)	
Some primary school	24 (12.8)	38 (12.3)	2.5 (1.2-5.2)		2.4 (1.1-5.3)	
None	18 (9.6)	8 (2.6)	8.7 (2.9-26.5)		10.8 (3.3-34.8)	

Abbreviations: NA, not applicable; OR, odds ratio; OSSN, ocular surface squamous neoplasia.

^a Adjusted for education, age group, and marital status. Sex did not change the multivariable model, so it was not included.

^b *t* Test.

Of 133 patients with OSSN tested for HIV, 98 (74%) were positive. The median (IQR) CD4 count of 91 patients with OSSN was 265 (125-670) cells/mm³. Some participants did not return for histology results after surgery and thus were not tested for HIV or CD4. Participants with OSSN were more likely to be receiving antiretroviral therapy (ART) than those with benign lesions (38% vs 15%; *P* < .001). There was no significant difference (*P* = .30) in mean (SD) duration of ART use in those with OSSN (2.9 [3.0] years) compared with those with benign lesions (3.5 [2.9] years) (eTable 3 in the [Supplement](#)). According to the Kenya Ministry of Health HIV guidelines, HIV-infected patients with CD4 levels of 350 cells/mm³ or less at first contact would be eligible for ART.¹⁹ It is difficult to know how many of our patients were eligible for ART because they were already in various stages of HIV care.

Clinical Features

Clinical features are described in **Table 2** and illustrated in **Figure 1** and **Figure 2**. There were a wide variety of presentation patterns for each type of OSSN. We illustrate this with a range of moderately differentiated squamous cell carcinoma tumors in Figure 1F through 1O. Overall, OSSN lesions were larger than benign lesions (mean [SD] diameter, 6.8 [3.2] vs 4.8 [2.8] mm; *P* < .001). All the features seen in OSSN also occurred in benign lesions (Table 2), and this overlap is illustrated in Figure 2. Ocular surface squamous neoplasia lesions were more likely to be at the temporal limbus (27.8% vs 16.2%; *P* = .002), be circumlimbal (6.7% vs 0.3%; *P* < .001), and have severe inflammation (6.7% vs 0.3%; *P* < .001) and leukoplakia (72.1% vs 49.7%; *P* < .001).

A gelatinous appearance occurred with almost equal frequency in both groups, whereas a fibrovascular appearance was more frequent in benign lesions and a papilliform appearance in OSSN. Ocular surface squamous neoplasia was more likely to be pigmented, have a feeder vessel, and involve the cornea. Regional lymphadenopathy was rare (*n* = 7 [1.5%]) in OSSN even in those with large orbital tumors.

Patients With Large Orbital Tumors

All 7 participants with large orbital tumors had squamous cell carcinoma. Four were female and 3 were male. Their age ranged from 30 to 85 years. Only 1 had undergone prior excision surgery, although no histology report was available. The tumors had been first noted 7 months to 15 years earlier. Five had HIV infection, and 3 were receiving ART. Despite having large tumors for a long time, only 2 of them had regional lymphadenopathy.

Interobserver Variation in Recognition of Clinical Features

Interobserver variation is described in eTable 4 in the [Supplement](#). Overall, there was fair to moderate agreement in assessment of most signs and the clinical diagnosis. Most features were easily recognized by the graders. They recognized similar proportions of features to an experienced examiner. Using clinical features to make a diagnosis of OSSN had a median (IQR) sensitivity of 86% (81%-88%), specificity of 60% (53%-69%), and positive predictive value of 54% (51%-56%) among the 6 examiners (eTable 5 in the [Supplement](#)).

Table 2. Comparison of the Clinical Features of Ocular Surface Squamous Neoplasia (OSSN) With Benign Conjunctival Lesions on Slitlamp Examination

	No. (%) ^a		OR (95% CI)	P Value
Clinical Feature	OSSN (n = 180)	Benign Lesions (n = 308)		
Lesion location				
Nasal limbus	110 (61.1)	241 (78.3)	0.4 (0.3-0.7)	<.001
Temporal limbus	50 (27.8)	50 (16.2)	2.0 (1.2-3.2)	.002
Superior limbus	2 (1.1)	2 (0.7)	1.7 (0.1-23.9)	.59
Inferior limbus	1 (0.6)	4 (1.3)	0.4 (0.0-4.3)	.43
Circumlimbal	12 (6.7)	1 (0.3)	21.9 (3.2-940.2)	<.001
Mostly corneal	1 (0.6)	0 (0.0)	∞	.19
Both nasal and temporal limbus	3 (1.7)	1 (0.3)	5.2 (0.4-274.0)	.11
Caruncle	0 (0.0)	3 (1.0)	0 (0.0-2.2)	.18
Eyelid	1 (0.6)	6 (2.0)	0.3 (0.0-2.4)	.21
Inflammation at the lesion site				
None	21 (11.7)	74 (24.0)	1 [Reference]	<.001
Minimal	50 (27.8)	111 (36.0)	1.6 (0.9-2.9)	
Mild	46 (25.6)	71 (23.1)	2.3 (1.2-4.3)	
Moderate	51 (28.3)	51 (16.6)	3.5 (1.8-6.8)	
Severe	12 (6.7)	1 (0.3)	42.3 (3.7-478.3)	
Leukoplakia	129 (72.1)	152 (49.7)	2.6 (1.7-3.9)	<.001
Erythroplakia	30 (16.7)	53 (17.2)	1.0 (0.6-1.6)	.88
Gelatinous appearance	121 (67.2)	188 (61.0)	1.3 (0.9-2.0)	.19
Fibrovascular appearance	18 (10.0)	81 (26.3)	0.3 (0.2-0.6)	<.001
Papilliform appearance	41 (22.8)	38 (12.0)	2.1 (1.3-3.5)	.003
Brown lesion pigmentation	96 (53.3)	133 (43.2)	1.5 (1.0-2.2)	.04
Lesion feeder vessels	163 (90.6)	195 (63.3)	5.8 (3.2-10.5)	<.001
Corneal involvement	118 (64.5)	120 (39.5)	2.7 (1.8-4.0)	<.001
Lesion diameter, mean (SD), mm	6.8 (3.2)	4.8 (2.8)	NA	<.001 ^b

Abbreviations: NA, not applicable; OR, odds ratio; OSSN, ocular surface squamous neoplasia.

^a The numbers assessed may vary in different cells if the item assessed did not apply to all participants. Data are number (percentage) unless otherwise specified.

^b t Test.

Discussion

There appears to be a tendency to treat patients presumed to have OSSN without a tissue diagnosis. However, we found a high degree of overlap in the clinical features of OSSN and benign lesions. Although some features were more frequent in OSSN than in the benign group, they still occurred at a fairly high frequency in the benign group. In our view, the differences are insufficient to depend on clinical features as an indicator of the underlying diagnosis. Moreover, there was only modest ($\kappa = 0.4$) interobserver agreement in the assessment of the diagnosis and a positive predictive value (54%) no better than chance when clinical features were used to make the diagnosis. The difficulty observed in determining surface appearance may be partly attributed to the lack of a stereoscopic view from photographs. The agreement in determining the presence of most clinical features was better than that for overall diagnostic classification as OSSN or benign.

The age and sex distribution of patients with OSSN was consistent with prior series from Africa, where young adults and especially women predominate.^{2,20} In temperate regions, it is predominantly a disease of older men.^{21,22} There was no difference in the sex distribution of OSSN and

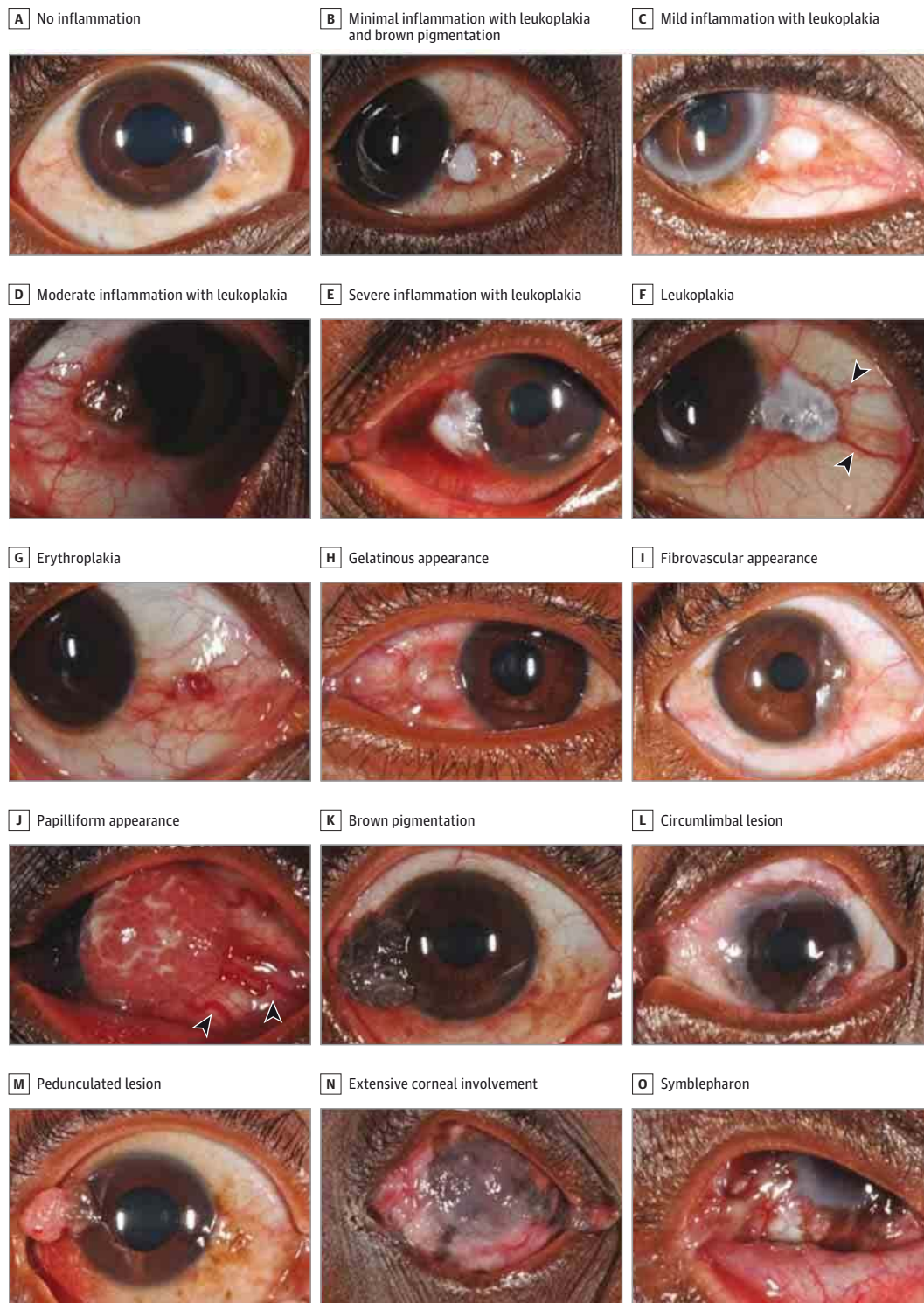
benign lesions. Higher education may increase awareness and earlier health care-seeking behavior. Median duration before presentation did not, however, conform to this trend, and showed the opposite of what has been previously reported.

The medical history of patients with OSSN and benign lesions is similar. The difference in occupational history with a longer exposure to solar UV radiation in those with OSSN than benign lesions is consistent with UV radiation being a major risk factor for OSSN.² There was also increased exposure to cigarette smoking with OSSN lesions, which has so far not been clearly described as a risk factor for OSSN.

Although some clinical features showed differences between OSSN and benign lesions, it may be difficult to tell the two apart. For instance, OSSN lesions were larger than benign lesions, but a 2.0-mm difference between 6.8 and 4.8 mm is relatively small. A circumlimbal pattern was more frequent in OSSN; however, it only occurred in 3% of the conjunctival lesions. Whereas OSSN was twice as likely to be temporal, 16% of benign lesions were located temporally, compared with 28% of OSSN lesions. Such a difference in proportion is difficult to rely on in the clinical setting.

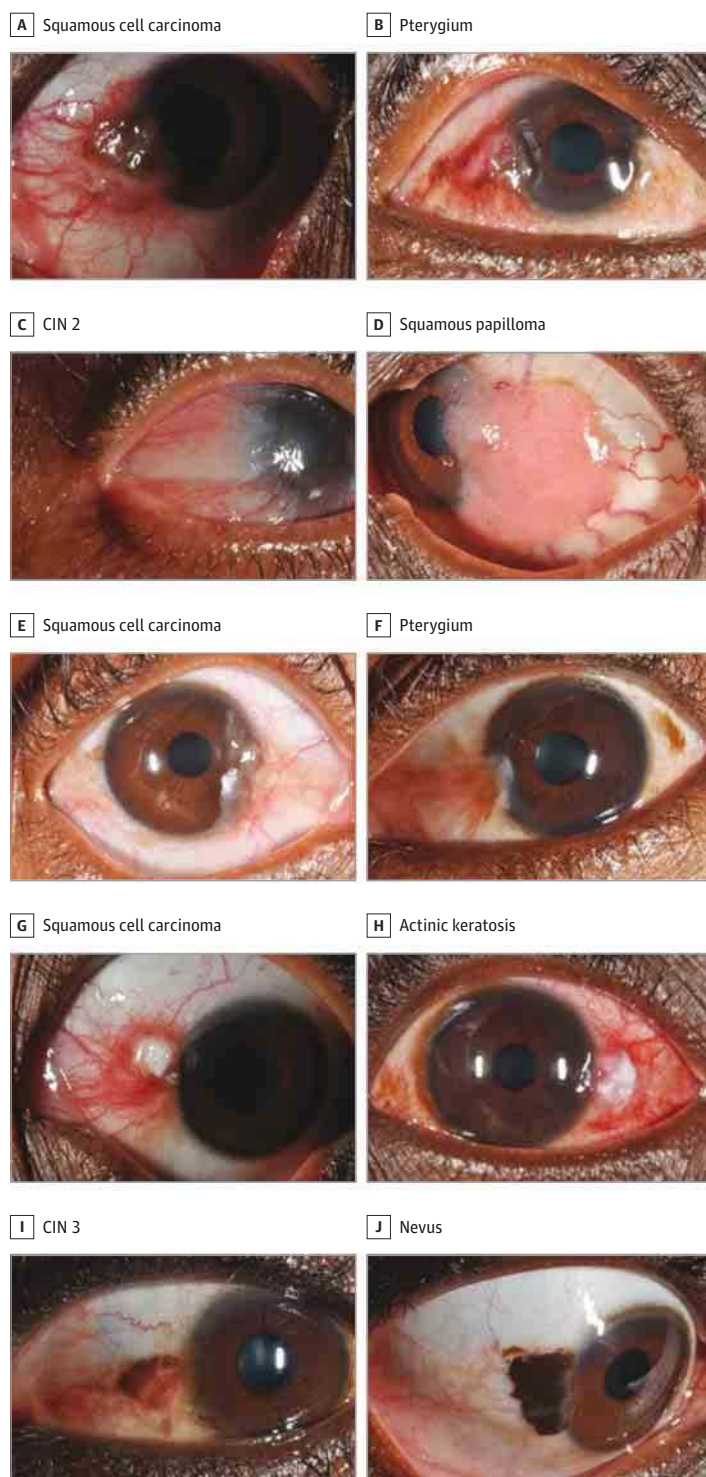
The preponderance of nasal conjunctival lesions is consistent with earlier reports and may be due to the previously

Figure 1. Grades of Inflammation, Clinical Features, and Growth Patterns of Ocular Surface Squamous Neoplasia



Five grades of inflammation associated with ocular surface squamous neoplasia are shown in A through E. Various clinical features seen in moderately differentiated squamous cell carcinoma are shown from F through O. F through K show different tumor surface appearances, and various growth patterns are seen in L through O. F, Leukoplakia—note patches of keratosis visible as white adherent plaques. Feeder vessels (distinctly dilated blood vessels larger than the rest of the conjunctival vessels) are also shown (arrowheads). G, Erythroplakia—note red subconjunctival popular hemorrhage-like appearance. J, Papilliform appearance—note large feeder vessels (arrowheads).

Figure 2. Overlapping Clinical Features of Ocular Surface Squamous Neoplasia and Benign and/or Premalignant Lesions



A gelatinous surface with pigmentation in (A) a moderately differentiated squamous cell carcinoma and (B) a pterygium. A papilliform surface in (C) conjunctival intraepithelial neoplasia (CIN) 2 and (D) a squamous papilloma. Note that the squamous papilloma in addition shows multiple feeder vessels. A fibrovascular appearance in (E) a moderately differentiated squamous cell carcinoma and (F) a pterygium. The pterygium has some brown pigmentation also seen on the temporal side of the same eye. Leukoplakia with inflammation in (G) a well-differentiated squamous cell carcinoma and (H) an actinic keratosis showing even more inflammation. Brown pigmentation in (I) CIN 3 and (J) a nevus.

described observation that incident temporal sunlight is focused nasally with a 20-fold magnification in intensity.²³ Pterygia and actinic keratosis are considered premalignant and have some similarities with OSSN in their pathophysiologic characteristics, including association with solar UV

radiation, p53 gene mutation, and human papillomavirus infection.²⁴⁻²⁷ Being on the same causal pathway may also explain the overlap of clinical features. Furthermore, we would also expect benign changes to occur before malignant ones. This may explain why patients with OSSN were older

than those with benign disease, most of whom had pterygia or actinic keratosis.

Differences between OSSN and benign lesions in the proportions of moderate and severe inflammation ($P < .001$) may not in isolation be easily applied in the clinical setting. Ocular surface squamous neoplasia was more likely to show leukoplakia than benign lesions; however, 50% of benign lesions also had it. This situation is also seen with other features such as the lesion surface appearance, pigmentation, feeder vessels, and corneal involvement in Table 2 and Figure 2.

This study has a number of limitations. The 6 examiners in the interobserver component did not have access to the patient's full history, which may help to inform the clinical diagnosis, nor did they assess the lesions at the slit lamp because this would have been logistically impossible. Second, this was a hospital-based study, which may introduce selection bias in the types of patients seen. However, the objective of the study was to compare patients with OSSN and benign lesions presenting to clinicians in a health care facility setting, so this potential bias would not affect comparability of the 2 types of disease. Finally, distinguishing pterygia and OSSN by histopathologic characteristics is sometimes difficult. Studies in Aus-

tralia and the United States found histopathological features of OSSN in 9.8% and 1.7%, respectively, of lesions previously classified as pterygia.^{28,29}

Conclusions

The clinical features of OSSN and benign conjunctival lesions overlap. Both disease groups have common pathophysiological mechanisms, and this may explain their overlapping clinical appearance. Although individual features are identified by different examiners with reasonable consistency, they do not reliably distinguish the 2 disease groups. Examination of photographs alone cannot replace clinical examination and biopsy, indicating that teleophthalmologic approaches for the diagnosis of OSSN require more study. Therefore, in the African context where the range of risk factors is perhaps wider and the clinical behavior of the disease more aggressive compared with temperate regions, we conclude that biopsy should be performed before treatment. The occurrence of malignant changes described in pterygia and other benign lesions further underscores the need for histopathologic analysis.

ARTICLE INFORMATION

Submitted for Publication: April 20, 2015; final revision received July 21, 2015; accepted July 26, 2015.

Published Online: September 17, 2015.
doi:10.1001/jamaophthalmol.2015.3335.

Author Affiliations: London School of Hygiene and Tropical Medicine, London, England (Gichuhi, Weiss, Burton); Department of Ophthalmology, University of Nairobi, Nairobi, Kenya (Gichuhi); PCEA Kikuyu Eye Unit, Kikuyu, Kenya (Macharia, Kabiru, Zindamoyen); Eye Department, Kitale District Hospital, Kitale, Kenya (Rono); Sabatia Eye Hospital, Wodanga, Kenya (Ollando, Wanyonyi); Ophthalmology Department, Kenyatta National Hospital, Nairobi, Kenya (Wachira, Munene); Department of Pathology, MP Shah Hospital, Nairobi, Kenya (Onyuma); UCL Institute of Ophthalmology, London, England (Sagoo); Moorfields Eye Hospital, London, England (Sagoo, Burton); St Bartholomew's Hospital, London, England (Sagoo).

Author Contributions: Drs Gichuhi and Burton had full access to all the data in the study and take responsibility for the integrity of the data and the accuracy of the data analysis.

Study concept and design: Gichuhi, Sagoo, Burton.

Acquisition, analysis, or interpretation of data:

Gichuhi, Macharia, Kabiru, Zindamoyen, Rono, Ollando, Wanyonyi, Wachira, Munene, Onyuma, Weiss, Burton.

Drafting of the manuscript: Gichuhi.

Critical revision of the manuscript for important intellectual content: Macharia, Kabiru, Zindamoyen, Rono, Ollando, Wanyonyi, Wachira, Munene, Onyuma, Sagoo, Weiss, Burton.

Statistical analysis: Gichuhi, Weiss, Burton.

Obtained funding: Gichuhi, Burton.

Administrative, technical, or material support:

Macharia, Zindamoyen, Rono, Ollando, Wanyonyi, Wachira, Munene, Onyuma, Sagoo.

Study supervision: Zindamoyen, Sagoo, Burton.

Conflict of Interest Disclosures: All authors have completed and submitted the ICMJE Form for Disclosure of Potential Conflicts of Interest and none were reported.

Funding/Support: Dr Gichuhi received funding from the British Council for Prevention of Blindness fellowship program. Dr Burton is supported by the Wellcome Trust (grant 098481/Z/12/Z).

Role of the Funder/Sponsor: The funding organizations had no role in the design and conduct of the study; collection, management, analysis, and interpretation of the data; preparation, review, or approval of the manuscript; and decision to submit the manuscript for publication.

REFERENCES

- Lee GA, Hirst LW. Ocular surface squamous neoplasia. *Surv Ophthalmol*. 1995;39(6):429-450.
- Gichuhi S, Sagoo MS, Weiss HA, Burton MJ. Epidemiology of ocular surface squamous neoplasia in Africa. *Trop Med Int Health*. 2013;18(12):1424-1443.
- Adesina A, Chumba D, Nelson AM, et al. Improvement of pathology in sub-Saharan Africa. *Lancet Oncol*. 2013;14(4):e152-e157.
- Rambau PF. Pathology practice in a resource-poor setting: Mwanza, Tanzania. *Arch Pathol Lab Med*. 2011;135(2):191-193.
- Stone DU, Butt AL, Chodosh J. Ocular surface squamous neoplasia: a standard of care survey. *Cornea*. 2005;24(3):297-300.
- Adler E, Turner JR, Stone DU. Ocular surface squamous neoplasia: a survey of changes in the standard of care from 2003 to 2012. *Cornea*. 2013;32(12):1558-1561.
- Nutt RJ, Clements JL, Dean WH. Ocular surface squamous neoplasia in HIV-positive and HIV-negative patients and response to 5-fluorouracil in Angola. *Clin Ophthalmol*. 2014;8:2435-2440.
- Russell HC, Chadha V, Lockington D, Kemp EG. Topical mitomycin C chemotherapy in the management of ocular surface neoplasia: a 10-year review of treatment outcomes and complications. *Br J Ophthalmol*. 2010;94(10):1316-1321.
- Besley J, Pappalardo J, Lee GA, Hirst LW, Vincent SJ. Risk factors for ocular surface squamous neoplasia recurrence after treatment with topical mitomycin C and interferon alpha-2b. *Am J Ophthalmol*. 2014;157(2):287-293.e2, e282.
- Nanji AA, Moon CS, Galor A, Sein J, Oellers P, Karp CL. Surgical versus medical treatment of ocular surface squamous neoplasia: a comparison of recurrences and complications. *Ophthalmology*. 2014;121(5):994-1000.
- Le Q, Xiang J, Cui X, Zhou X, Xu J. Prevalence and associated factors of pinguecula in a rural population in Shanghai, Eastern China. *Ophthalmic Epidemiol*. 2015;22(2):130-138.
- Marmamula S, Khanna RC, Rao GN. Population-based assessment of prevalence and risk factors for pterygium in the South Indian state of Andhra Pradesh: the Andhra Pradesh Eye Disease Study. *Invest Ophthalmol Vis Sci*. 2013;54(8):5359-5366.
- Viso E, Gude F, Rodríguez-Ares MT. Prevalence of pinguecula and pterygium in a general population in Spain. *Eye (Lond)*. 2011;25(3):350-357.
- Nguena MB, van den Tweel JG, Makupa W, et al. Diagnosing ocular surface squamous neoplasia in East Africa: case-control study of clinical and in vivo confocal microscopy assessment. *Ophthalmology*. 2014;121(2):484-491.
- Kao AA, Galor A, Karp CL, Abdelaziz A, Feuer WJ, Dubovy SR. Clinicopathologic correlation of ocular surface squamous neoplasms at Bascom Palmer Eye Institute: 2001 to 2010. *Ophthalmology*. 2012;119(9):1773-1776.
- Makupa II, Swai B, Makupa WU, White VA, Lewallen S. Clinical factors associated with malignancy and HIV status in patients with ocular surface squamous neoplasia at Kilimanjaro Christian

Medical Centre, Tanzania. *Br J Ophthalmol*. 2012;96(4):482-484.

17. American Joint Committee on Cancer. Carcinoma of the conjunctiva. In: Edge SB, Byrd DR, Compton CC, Fritz AG, Greene FL, Trotti A, eds. *Cancer Staging Handbook*. 7th ed. New York, NY: Springer; 2010:600-602.

18. Landis JR, Koch GG. The measurement of observer agreement for categorical data. *Biometrics*. 1977;33(1):159-174.

19. National AIDS/STI Control Program (NAS COP), Ministry of Health, Kenya. Guidelines on use of antiretroviral drugs for treating and preventing HIV infection: a rapid advice. http://healthservices.uonbi.ac.ke/sites/default/files/centraladmin/healthservices/Rapid%20Advice%20Booklet%202014%2024%20June%2012%20noon_O.pdf. Published 2014. Accessed February 10, 2015.

20. Tiong T, Borooh S, Msosa J, et al. Clinicopathological review of ocular surface squamous neoplasia in Malawi. *Br J Ophthalmol*. 2013;97(8):961-964.

21. Kim BH, Kim MK, Wee WR, Oh JY. Clinical and pathological characteristics of ocular surface squamous neoplasia in an Asian population. *Graefes Arch Clin Exp Ophthalmol*. 2013;251(11):2569-2573.

22. Tunc M, Char DH, Crawford B, Miller T. Intraepithelial and invasive squamous cell carcinoma of the conjunctiva: analysis of 60 cases. *Br J Ophthalmol*. 1999;83(1):98-103.

23. Coroneo M. Ultraviolet radiation and the anterior eye. *Eye Contact Lens*. 2011;37(4):214-224.

24. Liu T, Liu Y, Xie L, He X, Bai J. Progress in the pathogenesis of pterygium. *Curr Eye Res*. 2013;38(12):1191-1197.

25. Chalkia AK, Spandidos DA, Detorakis ET. Viral involvement in the pathogenesis and clinical features of ophthalmic pterygium (review). *Int J Mol Med*. 2013;32(3):539-543.

26. Di Girolamo N. Association of human papilloma virus with pterygia and ocular-surface squamous neoplasia. *Eye (Lond)*. 2012;26(2):202-211.

27. Dushku N, Hatcher SL, Albert DM, Reid TW. p53 expression and relation to human papillomavirus infection in pingueculae, pterygia, and limbal tumors. *Arch Ophthalmol*. 1999;117(12):1593-1599.

28. Hirst LW, Axelsen RA, Schwab I. Pterygium and associated ocular surface squamous neoplasia. *Arch Ophthalmol*. 2009;127(1):31-32.

29. Oellers P, Karp CL, Sheth A, et al. Prevalence, treatment, and outcomes of coexistent ocular surface squamous neoplasia and pterygium. *Ophthalmology*. 2013;120(3):445-450.