

Clinical Profile and Outcome of Chronic Pancreatitis in Children

Dr. Dilip Kumar Singh

M.S. (General Surgery), Assistant Professor, Lord Buddha Koshi Medical College and Hospital, Saharsa, Bihar.

Research Article

Article Info:

Received on: 16/05/2016
Published on: 27/06/2016



QR Code for mobile

Literati



ABSTRACT :

Chronic pancreatitis (CP) is characterised by pancreatic inflammation and fibrosis the end-point of which is destruction of pancreatic parenchyma with eventual loss of exocrine and endocrine function. Yet the syndrome is well considered in adults, there is incomplete data in children and adolescents; and most of the described series include small number of subjects. Hence study was conducted to evaluate the etiology, clinical presentation of chronic pancreatitis in children.

The age group of the patients are upto 18 years. The patients astroenterology department of hospital in North India were considered in the study. All the patient's clinical history were collected. Also the complete physical examination was done.

Idiopathic chronic pancreatitis is the principal type of chronic pancreatitis in children and adolescents. It can present with or without calcification. The calcific variety is an aggressive disease characterized by early morphological and functional damage to the pancreas

Keywords: Chronic pancreatitis, clinical profile, children , Idiopathic chronic pancreatitis

INTRODUCTION:

Chronic pancreatitis is inflammation of the pancreas that does not heal or improve—it gets worse with time and leads to permanent damage. Chronic pancreatitis eventually impairs a patient's ability to digest food and make pancreatic hormones. Industrialized countries have estimated an annual incidence rate of 5-12/100,000 people who will develop chronic pancreatitis. The prevalence of chronic pancreatitis is 50/100,000 people. Chronic pancreatitis often develops in patients between the ages of 30 and 40, and is more common in men than women.

Whereas there are causes of chronic pancreatitis that are unknown; several factors have been identified to cause chronic pancreatitis:

- Heavy alcohol use
- Autoimmune conditions (when the body's immune system attacks its own body)
- Genetic mutations due to cystic fibrosis
- Blocked pancreatic duct or common bile duct
- Familial pancreatitis (runs in the family—with 2 or more immediate family members with a history of pancreatitis)

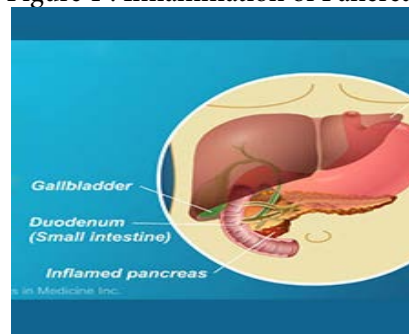
Most individuals with chronic pancreatitis experience upper abdominal pain, although some have no pain at all. The pain may spread to the back, become worse with eating or drinking, and become constant and disabling. In some cases, the abdominal pain goes away as the condition worsens, but this is fairly uncommon. Other symptoms include the following:

- Nausea
- Vomiting
- Weight loss

- Diarrhea
- Oily or fatty stools
- Clay-colored or pale stools

Individuals with chronic pancreatitis frequently lose weight, even when their appetite and eating habits are normal. The weight loss occurs because the body does not secrete enough pancreatic enzymes to digest food, so nutrients are not absorbed normally, leading to malnutrition. Patients who have chronic pancreatitis may have a decreased quality of life due to pain and often require admission to the hospital for treatment of symptoms.

Figure 1 : Inflammation of Pancreas



Chronic pancreatitis is best diagnosed with tests that can evaluate the structure of the pancreas via radiography (x-ray exams)—blood tests are generally not helpful for making the diagnosis of chronic pancreatitis. As with acute pancreatitis, a doctor will conduct a thorough medical history and physical examination. Physicians have a variety of diagnostic tests to choose from:

Transabdominal ultrasound

Sound waves are sent toward the pancreas via a handheld device that a technician glides over the abdomen. The

Conflict of interest: Authors reported none

*Corresponding author:

Dr. Dilip Kumar Singh

Assistant Professor, Lord Buddha Koshi Medical College and Hospital, Saharsa, Bihar.

submit your manuscript | www.jbiopharm.com



sound waves bounce off the pancreas, gallbladder, liver, and other organs, and their echoes generate electrical impulses that create an image—called a sonogram—on a video monitor. If gallstones are causing inflammation, the sound waves will also bounce off of them, showing their location.

Endoscopic ultrasound

After spraying a solution to numb the patient's throat, the doctor inserts an endoscope—a thin, flexible, lighted tube—down the throat, through the stomach, and into the small intestine. They then turn on an ultrasound attachment to the endoscope, which produces sound waves to create visual images of the pancreas and bile ducts. To read more about endoscopic ultrasounds, please click here.

Magnetic resonance cholangiopancreatography (MRCP)

MRCP uses magnetic resonance imaging (MRI), a non-invasive procedure that produces cross-section images of parts of the body. After being lightly sedated, the patient lies in a cylinder-like tube. The technician injects dye into the patient's veins, which helps show the pancreas, gallbladder, and pancreatic and bile ducts.

Computerized tomography (CT)

A CT scan is a noninvasive radiograph (x-ray) that produces 3-dimensional images of parts of the body. The patient lies on a table that slides into a donut-shaped machine. The test can show gallstones and the extent of damage to the pancreas.

Occasionally, blood tests, such as a test for IgG4 to assess for autoimmune pancreatitis, can be used to help diagnose the cause of chronic pancreatitis. However, blood tests are not typically used to make the diagnosis of chronic pancreatitis.

Significant pain associated with chronic pancreatitis can seriously reduce a patient's quality of life. It is important to treat chronic pancreatitis as soon as it is diagnosed because repeated episodes of inflammation can cause irreversible damage, and pain relief becomes much less effective. Pain relief can be achieved with medication, often using the World Health Organization's 3-step ladder approach to pain relief:

- Pain medication begins with nonopioids (like acetaminophen, ibuprofen, or both).
- If nonopioids do not relieve pain, mild opioids (like codeine) are given.
- If mild opioids do not relieve pain, strong opioids (like morphine) are given.

Many patients with chronic pancreatitis receive antioxidants with their pain medicine, which has been shown to help with pain relief.³⁻⁵ There are other options for pain relief, such as a celiac plexus block, which may provide another option for significant pain relief. The celiac plexus block is achieved via injection and prevents the nerves that travel from the pancreas from reporting pain signals back to the brain.

If there is a narrowing of the pancreatic duct, placement of a plastic tube called a stent into the duct can be helpful in alleviating pain symptoms.

Yet the syndrome is well considered in adults, there is in-

complete data in children and adolescents; and most of the described series include small number of subjects. Hence study was conducted to evaluate the etiology, clinical presentation of chronic pancreatitis in children.

Materials & Methodology:

The age group of the patients are upto 18 years. The patients gastroenterology department of hospital in North India were considered in the study. All the patient's clinical history were collected. Also the complete physical examination was done. All the patients are informed consents. The 40 patients were enrolled in to the study.

Chronic pancreatitis was diagnosed on the basis of clinical features (abdominal pain, steatorrhea or diabetes mellitus) and the identification of pancreatic ductal and/ or parenchymal changes (calcification, atrophy, ductal dilatation) on imaging [2]. Clinical information, complications and laboratory data were collected by a standardized review of medical charts and the data recorded in data forms. Nutritional status was assessed using WHO growth charts for height for age and body mass index (BMI) for age [3].

Pancreatic exocrine insufficiency was assessed by estimation of 72-hour stool fat using van de Kamer method [4]. Steatorrhea was diagnosed if the stool fat was >18 g in a 72-hour stool collection [5]. Blood sugar was checked in all the children. A fasting plasma glucose of ≥ 126 mg/dL, 2 hr post-prandial plasma glucose >200 mg/dL or HbA1C >6.5% was used to diagnose diabetes mellitus [6]. Morphological changes in the pancreas were identified by imaging studies of abdomen viz. ultrasound abdomen, contrast enhanced computed tomography (CECT), MRI with magnetic resonance cholangio-pancreatography (MRCP), endoscopic retrograde cholangio-pancreatography (ERCP) and / or endoscopic ultrasound (EUS). Main pancreatic duct was considered to be dilated if the duct diameter was more than 3 mm in the head and 2 mm in the body or tail of the pancreas [7].

Results & Discussion:

The total number of 80 children's were studied who had admitted to Gastroenterology department who had been diagnosed with the chronic pancreatitis. As the definite cause of the condition is not found hence all this patients were categorized as idiopathic chronic pancreatitis.

The 3 patients showed the history of the abdominal trauma before the starting of symptoms of pancreatitis. IN the study group 7 patients were observed with the Pancreas divisum. Out of this 7 patients 4 patients showed the history of chronic pancreatitis.

The average age of the patients in the study is 15 years. All the patients complaining about the pain were hospitalized for 2-3 times due to severe pain. There is also the sugar imbalance in the children. 5 cases were given the insulin to control the blood sugar levels.

Increased level of the stool fats was observed in 50% of the children's. Few of children's were reported the symptomatic steatorrhea while majority of them had subclinical steatorrhea.

Table 1 showed the Pancreatic morphological abnormali-

ties observed in imaging diagnosis.

Table 1 : Pancreatic morphological abnormalities

Morphological Changes	No. of Patients Observed
Pancreatic calcification, duct dilatation and parenchymal atrophy	38
Pancreatic calcification and duct dilatation	12
Duct dilatation and parenchymal atrophy	17
Pancreatic calcification and parenchymal atrophy	6
Pancreatic calcification	2
Duct dilatation	5
Total	80

Pancreatic calcification, duct dilatation and parenchymal atrophy was seen in 38 patients. Pancreatic calcification and duct dilatation was observed in 12 cases. 17 patients showed the Duct dilatation and parenchymal atrophy. The Pancreatic calcification and parenchymal atrophy was seen in 6 patients. Pancreatic calcification was noted in 2 patients while Duct dilatation in 5 patients.

The leading cause of chronic pancreatitis in the present study is noted as Idiopathic chronic pancreatitis. The literature from China have also described Idiopathic chronic pancreatitis as the major cause of chronic pancreatitis between children [8]. Data on occurrence of exocrine and endocrine insufficiency between children with chronic pancreatitis are limited [9].

The prevalence of symptomatic steatorrhea was lower (2.02% vs. 9.5%) and diabetes mellitus higher (9.1% vs. 0%) in the present study as compared to the study by Wang, et al. [8].

Conclusion:

The present study has several limitations: a retrospective study in which assessment of pain was subjective and evaluation and management were not protocol based; data on growth parameters and steatorrhea were not available for all patients; and genetic mutation analysis was not performed for etiology evaluation.

References:

1. <https://www.pancreasfoundation.org/patient-information/chronic-pancreatitis/>
2. Tandon RK. Tropical pancreatitis. *J Gastroenterol* 2007;42:141-7.
3. WHO | BMI-for-age (5-19 years) [Internet]. [cited 2012 Jan 22]. Available from: http://www.who.int/growthref/who2007_bmi_for_age/en/index.html
4. Van de Kramer JH, Ten Bokkel Huinink H, Weyers HA. Rapid method for the determination of fat in feces. *J Biol Chem.* 1949;177:347-55.
5. Dutta AK, Balekuduru A, Chacko A. Spectrum of mal-absorption in India—tropical sprue is still the leader. *J Assoc Physicians India.* 2011;59:420-2
6. Diagnosis and classification of diabetes mellitus. *Diabetes Care.* 2010;33:S62-69.
7. Edge M-D, Hoteit M, Patel A-P, Wang X, Baumgarten DA, Cai Q. Clinical significance of main pancreatic duct dilation on computed tomography: single and double duct dilation. *World J Gastroenterol.* 2007;13:1701-5.
8. Wang W, Liao Z, Li Z-S, Shi X-G, Wang L-W, Liu F, *et al.* Chronic pancreatitis in Chinese children: etiology, clinical presentation and imaging diagnosis. *J Gastroenterol Hepatol.* 2009;24:1862-8.
9. Nydegger A, Couper RTL, Oliver MR. Childhood pancreatitis. *J Gastroenterol Hepatol.* 2006;21:499-509.