

Circulation

JOURNAL OF THE AMERICAN HEART ASSOCIATION



Clinical Significance of Abnormal Electrocardiographic Patterns in Trained Athletes

Antonio Pelliccia, Barry J. Maron, Franco Culasso, Fernando M. Di Paolo, Antonio Spataro, Alessandro Biffi, Giovanni Caselli and Paola Piovano

Circulation 2000;102;278-284

Circulation is published by the American Heart Association, 7272 Greenville Avenue, Dallas, TX 75214

Copyright © 2000 American Heart Association. All rights reserved. Print ISSN: 0009-7322. Online ISSN: 1524-4539

The online version of this article, along with updated information and services, is located on the World Wide Web at:

<http://circ.ahajournals.org/cgi/content/full/102/3/278>

Subscriptions: Information about subscribing to *Circulation* is online at
<http://circ.ahajournals.org/subscriptions/>

Permissions: Permissions & Rights Desk, Lippincott Williams & Wilkins, a division of Wolters Kluwer Health, 351 West Camden Street, Baltimore, MD 21202-2436. Phone: 410-528-4050. Fax: 410-528-8550. E-mail:
journalpermissions@lww.com

Reprints: Information about reprints can be found online at
<http://www.lww.com/reprints>

Clinical Significance of Abnormal Electrocardiographic Patterns in Trained Athletes

Antonio Pelliccia, MD; Barry J. Maron, MD; Franco Culasso, PhD; Fernando M. Di Paolo, MD; Antonio Spataro, MD; Alessandro Biffi, MD; Giovanni Caselli, MD; Paola Piovano, MD

Background—The prevalence, clinical significance, and determinants of abnormal ECG patterns in trained athletes remain largely unresolved.

Methods and Results—We compared ECG patterns with cardiac morphology (as assessed by echocardiography) in 1005 consecutive athletes (aged 24 ± 6 years; 75% male) who were participating in 38 sporting disciplines. ECG patterns were distinctly abnormal in 145 athletes (14%), mildly abnormal in 257 (26%), and normal or with minor alterations in 603 (60%). Structural cardiovascular abnormalities were identified in only 53 athletes (5%). Larger cardiac dimensions were associated with abnormal ECG patterns: left ventricular end-diastolic cavity dimensions were 56.0 ± 5.6 , 55.4 ± 5.7 , and 53.7 ± 5.7 mm ($P < 0.001$) and maximum wall thicknesses were 10.1 ± 1.4 , 9.8 ± 1.3 , and 9.3 ± 1.4 mm ($P < 0.001$) in distinctly abnormal, mildly abnormal, and normal ECGs, respectively. Abnormal ECGs were also most associated with male sex, younger age (< 20 years), and endurance sports (cycling, rowing/canoeing, and cross-country skiing). A subset of athletes (5% of the 1005) showed particularly abnormal or bizarre ECG patterns, but no evidence of structural cardiovascular abnormalities or an increase in cardiac dimensions.

Conclusions—Most athletes (60%) in this large cohort had ECGs that were completely normal or showed only minor alterations. A variety of abnormal ECG patterns occurred in 40%; this was usually indicative of physiological cardiac remodeling. A small but important subgroup of athletes without cardiac morphological changes showed striking ECG abnormalities that suggested cardiovascular disease; however, these changes were likely an innocent consequence of long-term, intense athletic training and, therefore, another component of athlete heart syndrome. Such false-positive ECGs represent a potential limitation to routine ECG testing as part of preparticipation screening. (*Circulation*. 2000;102:278-284.)

Key Words: athlete's heart ■ 12-lead ECG ■ echocardiography ■ screening for cardiovascular diseases

The 12-lead ECG shows a broad range of abnormal patterns in trained athletes, particularly increased QRS voltages, which are suggestive of left ventricular (LV) hypertrophy, and repolarization abnormalities.¹⁻¹² These alterations have been attributed to the physiological cardiac adaptations that occur as a consequence of systematic physical training.⁹ Moreover, ECG patterns in trained athletes may mimic those observed in patients with structural heart diseases such as hypertrophic cardiomyopathy (HCM) or arrhythmogenic right ventricular cardiomyopathy (ARVC), which can be responsible for sudden death during physical exertion.^{13,14}

There has also been substantial interest in implementing preparticipation cardiovascular screening in athletic populations, and cost-effective strategies for identifying potentially lethal cardiac diseases are still debated.¹⁵⁻¹⁷ The 12-lead ECG has been proposed as a simple test that may enhance the detection of cardiovascular abnormalities^{17,18} and, indeed, it

is relied on extensively in the systematic evaluation program of competitive athletes operating in Italy.¹⁹

Despite several observational surveys describing ECG abnormalities among trained athletes,^{2,4,7,9,11} the determinants and clinical significance of these ECG patterns remain largely unresolved. Therefore, the present study was designed to provide a measure of clarification regarding abnormal ECGs in athletes by comparing ECG patterns with cardiac morphology (as assessed by echocardiography) in the same individuals. We examined a large population of trained athletes who were engaged in a variety of sporting disciplines.

Methods

Study Population

The Institute of Sports Science is a medical division of the Italian National Olympic Committee where all national team members undergo an annual medical evaluation. This evaluation consists of a

Received September 1, 1999; revision received February 11, 2000; accepted February 14, 2000.

From the Institute of Sports Science, Department of Medicine, Italian National Olympic Committee, Rome, Italy (A.P., F.M.D.P., A.S., A.B., G.C., P.P.); the Minneapolis Heart Institute Foundation, Minneapolis, Minnesota (B.J.M.); and the Department of Experimental Medicine, University La Sapienza, Rome, Italy (F.C.).

Correspondence to Antonio Pelliccia, MD, Institute of Sports Science, Department of Medicine, Via dei Campi Sportivi 46, 00197 Rome, Italy. E-Mail ISS_Medicina@coni.it

© 2000 American Heart Association, Inc.

Circulation is available at <http://www.circulationaha.org>

medical history, physical examination, 12-lead and exercise ECG, chest x-ray and, since 1985, echocardiography.¹⁹

Thus, 1050 athletes were consecutively evaluated from 1993 to 1995. Of these, 45 subjects were excluded due to technically unsatisfactory ECG or echocardiographic recordings; the final study group was composed of 1005 athletes. Their median age was 23 years, and their age ranged from 9 to 55 years (only 16 athletes were either <12 or >40 years); 745 of the athletes (74%) were male. Body surface area was 1.9 ± 0.3 m² (range, 1.0 to 2.7 m²). All but 2 athletes were white; these 2 were African. Of the 1005 athletes, 785 (78%) were examined routinely as a part of our systematic medical program, and 220 (22%) were referred to our institution for the evaluation of suspected cardiovascular abnormalities. Athletes were engaged in 38 different sporting disciplines and had participated in vigorous training programs for periods of 2 to 30 years (median, 7 years); 440 of the athletes (44%) had achieved international recognition in Olympic Games and World Championships, and 565 (56%) competed at the national level. Selected data from 332 athletes have been included in previous analyses.^{20,21}

Electrocardiography

Standard 12-lead ECGs were performed with the subject in the supine position during quiet respiration and were recorded at 25 mm/s. ECG tracings were obtained a few minutes before the echocardiographic investigation and ≥ 24 hours after the last athletic activity. ECGs were interpreted without knowledge of the clinical history and echocardiographic findings of the athlete.

All ECG patterns were evaluated according to commonly adopted clinical criteria.²²⁻²⁴ We arbitrarily classified ECGs into 3 subgroups on the basis of the presence of ≥ 1 of the listed criteria. The subgroups were as follows.

Distinctly Abnormal ECG

Distinctly abnormal ECGs were those that were strongly suggestive of cardiovascular disease. The criteria for such a designation included the following: (1) striking increase in R or S wave voltage (≥ 35 mm) in any lead, (2) Q waves ≥ 4 mm in depth and present in ≥ 2 leads, (3) repolarization pattern with inverted T wave > 2 mm in ≥ 2 leads, (4) left bundle branch block, (5) marked left ($\leq -30^\circ$) or right ($\geq 110^\circ$) QRS axis deviation, and (6) Wolff-Parkinson-White pattern.

Mildly Abnormal ECG

Mildly abnormal ECGs were those that were compatible with the presence of cardiovascular disease. The criteria for such a designation included the following: (1) increased R or S wave voltage (30 to 34 mm) in any lead; (2) Q waves 2 to 3 mm in depth and present in ≥ 2 leads; (3) repolarization patterns with either flat, minimally inverted, or particularly tall (ie, ≥ 15 mm) T waves in ≥ 2 leads; (4) abnormal R wave progression in the anterior precordial leads; (5) right bundle branch block (RSR¹ pattern ≥ 0.12 s in V₁ and V₂); (6) right atrial enlargement (peaked P waves ≥ 2.5 mm in leads II, III, or V₁); (7) left atrial enlargement (prolonged positive P wave in lead II and/or deep, prolonged negative P wave in V₁); and (8) short PR interval (≤ 0.12 s).

Normal ECG or ECG With Minor Alterations

This subgroup consisted of ECGs that were completely normal and those with the minor alterations that have been consistently reported in trained athletes and that are regarded as part of athlete's heart syndrome.⁹ These minor alterations included the following: (1) increased PR interval duration (> 0.20 s), (2) mild increase in R or S wave voltage (25 to 29 mm), (3) early repolarization (ST elevation ≥ 2 mm in > 2 leads), (4) incomplete right bundle branch block (RSR¹ pattern in V₁ and V₂ of < 0.12 s in duration), and (5) sinus bradycardia < 60 bpm.

Echocardiography

Two-dimensional, M-mode, and Doppler echocardiographic studies were performed using a Hewlett-Packard Sonos 2500 with a 3.5 MHz transducer. Images were obtained in multiple cross-sectional

planes using standard transducer positions. End-diastolic and end-systolic LV cavity dimensions and anterior ventricular septal and posterior free wall thicknesses were obtained from the M-mode echocardiogram.²⁵ Ventricular septal thickness measurements obtained from M-mode echocardiograms were verified using the 2D images. LV mass was calculated using the formula of Devereux et al.²⁶ The ostia and most proximal portion of the left and right coronary arteries were routinely visualized.²⁷ Parameters of LV filling were obtained with pulsed Doppler echocardiography.²⁸ Cardiac dimensions were judged to exceed normal limits when they were $> 95\%$ of the prediction limits derived from populations of similar ages, heights, and body surface areas.^{29,30} Echocardiograms were interpreted without knowledge of the clinical history or ECG pattern.

Statistical Analysis

Data were expressed as mean and SD. Differences between means were assessed with unpaired or paired Student's *t*-tests. Differences between proportions were tested with the χ^2 test. A 2-tailed $P < 0.05$ was considered statistically significant. Differences between the 3 ECG subgroups were assessed by ANOVA and multiple Bonferroni tests.³¹ Relation between LV dimensions and ECG voltage scores were tested by linear regression analysis. Stepwise logistic regression analysis was used to determine those variables that were most closely associated with abnormal ECG patterns.³¹

Results

ECG Patterns and Cardiovascular Abnormalities

Abnormal ECGs were identified in 402 athletes (40%); these included 145 with distinctly abnormal and 257 with mildly abnormal patterns. Of the other 603 athletes (60%), ECGs were completely normal in 188 and showed only minor alterations (considered typical of athlete's heart) in 415. The prevalence of various abnormalities in the 3 ECG subgroups is summarized in Table 1.

A cardiovascular abnormality was identified clinically and/or by echocardiography in 53 athletes (5%); these included 20 of the 785 elite athletes examined as a part of our routine medical evaluations and 33 of the 220 athletes referred to our institution for a suspected cardiac abnormality. The most frequent abnormalities were mitral valve prolapse with mild regurgitation (n=19) and a bicuspid aortic valve with regurgitation (n=10); less common defects were an atrial or ventricular septal defect (n=6), dilated cardiomyopathy (n=4), mild pulmonary artery stenosis (n=2), and myocarditis (n=2); HCM, aortic prosthesis for valvular stenosis, pericarditis, and coronary artery disease were present in 1 athlete each. In addition, Wolff-Parkinson-White syndrome and systemic hypertension were each identified in 3 athletes.

Cardiac abnormalities were present in each ECG subgroup, but they were significantly more common in those athletes with distinctly abnormal ECGs (10%) compared with athletes with mildly abnormal ECGs (5%; $P < 0.001$) or normal ECGs (4%; $P < 0.001$). Specifically, of the 785 athletes examined as a part of our unselected medical program, 40% had abnormal ECGs (of which $\approx 3\%$ had cardiovascular abnormalities); of the 220 athletes specifically referred for suspected cardiac disease, 38% had abnormal ECGs (15% with cardiovascular abnormalities).

Of the 53 athletes with cardiovascular abnormalities, 27 had abnormal ECGs and 26 had normal ECGs (false-negatives). Of the 952 athletes without evidence of cardiac

TABLE 1. Distribution of ECG Abnormalities in 1005 Trained Athletes

Distinctly Abnormal ECG (n=145)		Mildly Abnormal ECG (n=257)		ECG Normal or With Minor Alterations (n=603)	
Parameter	n (%)	Parameter	n (%)	Parameter	n (%)
R or S wave ≥35 mm	92 (63)	R or S wave 30–34 mm	141 (55)	R or S wave 25–29 mm	170 (28)
Negative T wave	27 (19)	Flat/tall T wave	59 (23)	J-junction elevation	144 (24)
Q wave ≥4 mm	17 (12)	Q wave 2–3 mm	69 (27)	Incomplete RBBB	122 (20)
LAD	11 (8)	LAE	9 (4)	PR interval >0.20 s	75 (12)
RAD	8 (6)	RAE	2 (0.8)	Sinus bradycardia <60 bpm	369 (61)
WPW	3 (2)	Incomplete R wave progression V ₁ to V ₃	40 (16)		
LBBB	2 (1)	PR interval ≤0.12 s	9 (4)		
		RBBB	2 (0.8)		

J-junction indicates early repolarization pattern; LAD, left axis deviation ($\leq -30^\circ$); LBBB, left bundle branch block; LAE, left atrial enlargement; Incomplete R wave progression V₁ to V₃, abnormal pattern of R wave progression in the anterior precordial leads V₁ to V₃; RAD, right axis deviation ($\geq 110^\circ$); RAE, right atrial enlargement; RBBB, right bundle branch block; and WPW, Wolff-Parkinson-White pattern.

disease, 577 had normal ECGs and 375 had either distinctly or mildly abnormal ECGs (false-positives). The combined power of the distinctly and mildly abnormal ECGs for identifying cardiovascular abnormalities was as follows: sensitivity, 51%; specificity, 61%; positive predictive accuracy, 7%; and negative predictive accuracy, 96%.

Relation of ECG Patterns to Cardiac Dimensions

Echocardiographic analysis showed that cardiac dimensions differed significantly between athletes in the 3 ECG categories (Table 2). LV end-diastolic cavity dimension, maximum wall thickness, mass index, and the left atrial dimension were each greater in athletes with distinctly abnormal ECGs than in those with normal ECGs. Athletes with mildly abnormal ECGs showed cardiac dimensions that were intermediate and significantly greater than those in athletes with normal ECGs.

Among the 1005 athletes, the maximum R or S wave voltage showed a statistically significant but modest linear correlation with LV end-diastolic cavity dimension ($r=0.30$; $P<0.001$), maximum wall thickness ($r=0.35$; $P<0.001$), and mass ($r=0.36$; $P<0.001$).

ECG Patterns in Relation to Sex and Age

ECG patterns differed greatly with respect to sex (Figure 1). A significantly larger proportion of male athletes had either distinctly (17% versus 8%; $P<0.001$) or mildly abnormal (28% versus 14%; $P<0.001$) ECGs compared with female athletes. Conversely, the vast majority of female athletes showed normal ECGs (78%) compared with male athletes (55%; $P<0.001$). Logistic regression analysis confirmed that a greater probability for an abnormal ECG pattern was associated with male sex (odds ratio [OR], 3.79; 95% confidence interval [CI], 2.50 to 5.75) and younger age (<20 years; OR, 1.05; 95% CI, 1.02 to 1.09). Male athletes had greater maximum R or S wave voltages (24.8 ± 7.8 versus 17.5 ± 5.6 mV in female athletes; $P<0.001$) and more frequently abnormal Q waves (14% versus 6% in female athletes; $P<0.005$).

ECG Patterns in Relation to Sporting Disciplines

ECG patterns also differed with respect to the type of sporting discipline (Figure 2). Distinctly abnormal ECGs were observed in athletes participating in a variety of sports, but they

TABLE 2. Relation of Cardiac Dimensions to the 12-lead ECG Pattern in 1005 Highly Trained Athletes

	A: Distinctly Abnormal	P (A vs B)	B: Mildly Abnormal	P (B vs C)	C: Normal or Minor Alterations	P (A vs C)
No. of athletes	145		257		603	
LVDD, mm	56.0 ± 5.6	NS	55.4 ± 5.7	<0.001	53.7 ± 5.7	<0.001
Max LV WT, mm	10.1 ± 1.4	<0.03	9.8 ± 1.3	<0.001	9.3 ± 1.4	<0.001
Mass index, g/m ²	115 ± 23	<0.01	109 ± 24	<0.001	99 ± 23	<0.001
LA, mm	37.2 ± 4.6	<0.06	36.3 ± 4.7	<0.005	35.3 ± 4.7	<0.001
FS, %	34.5 ± 4.0	NS	35.2 ± 4.4	NS	34.9 ± 4.1	NS
E/A ratio	2.3 ± 0.7	NS	2.4 ± 0.7	NS	2.3 ± 0.7	NS
EF slope	458 ± 135	NS	469 ± 144	NS	473 ± 125	NS

E/A ratio indicates ratio of the early-to-late diastolic peaks of flow velocity; EF slope, descent of the early diastolic transmitral peak flow velocity; FS, fractional shortening; LA, left atrium; LV, left ventricular; LVDD, left ventricular end-diastolic dimension; Max, maximum; NS, not significant; and WT, wall thickness.

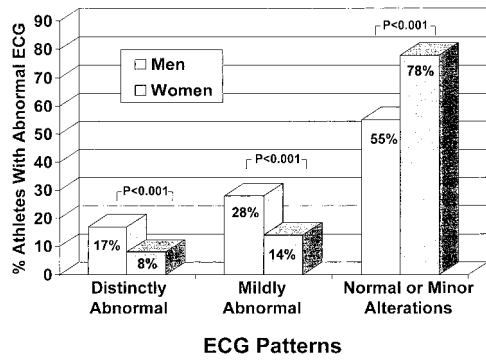


Figure 1. Distribution of 3 ECG categories with respect to sex among 1005 competitive athletes. Numbers in bars indicate proportion of male and female athletes in each ECG category.

were most frequently encountered in endurance disciplines such as cycling, cross-country skiing, and rowing/canoeing (35%, 30%, and 20% of the athletes in each group, respectively). Logistic regression analysis showed that a greater probability for an abnormal ECG pattern was associated with training in cycling (OR, 6.01; 95% CI, 1.22 to 29.7), cross-country skiing (OR, 8.58; 95% CI, 1.30 to 56.5), and rowing/canoeing (OR, 6.60; 95% CI, 1.39 to 31.2). Distinctly abnormal ECGs were absent in athletes participating in technical disciplines, such as equestrian, alpine skiing, or judo, and normal ECGs predominated.

Profile of Athletes With Distinctly Abnormal ECGs

Of the 1005 athletes, 145 (14%) had distinctly abnormal ECGs (Figure 3); these athletes were aged 15 to 36 years and

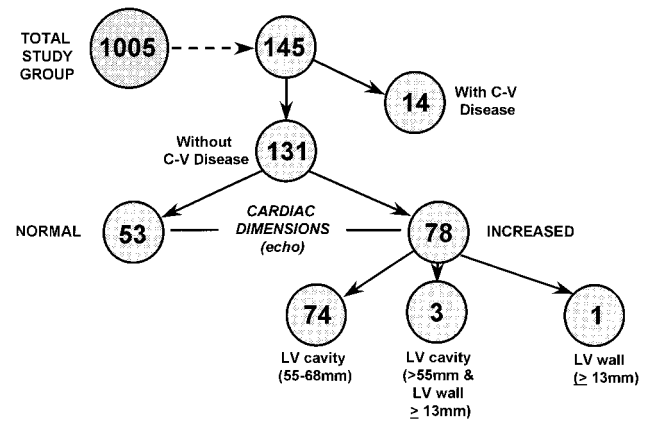


Figure 3. Flow diagram showing results of echocardiographic studies in the subgroup of 145 athletes with distinctly abnormal ECGs that were highly suggestive of cardiovascular (C-V) disease.

were mostly male (n=125). Only a minority of these athletes (n=14; 10%) showed evidence of structural cardiac abnormalities that could be responsible for the altered ECG patterns. Of the remaining 131 athletes, 78 showed an absolute increase in cardiac dimensions; LV end-diastolic cavity dimension (≥ 55 mm, up to 68 mm) increased in 74, wall thickness (≥ 13 mm) increased in 1 athlete, and both cavity and wall thickness increased in 3 athletes. These 78 athletes were predominantly male (n=75) and largely participated (n=48) in endurance disciplines such as rowing, cycling, cross-country skiing, and long-distance running.

Of note, the remaining 53 athletes (5% of the 1005) showed neither structural abnormalities nor a significant

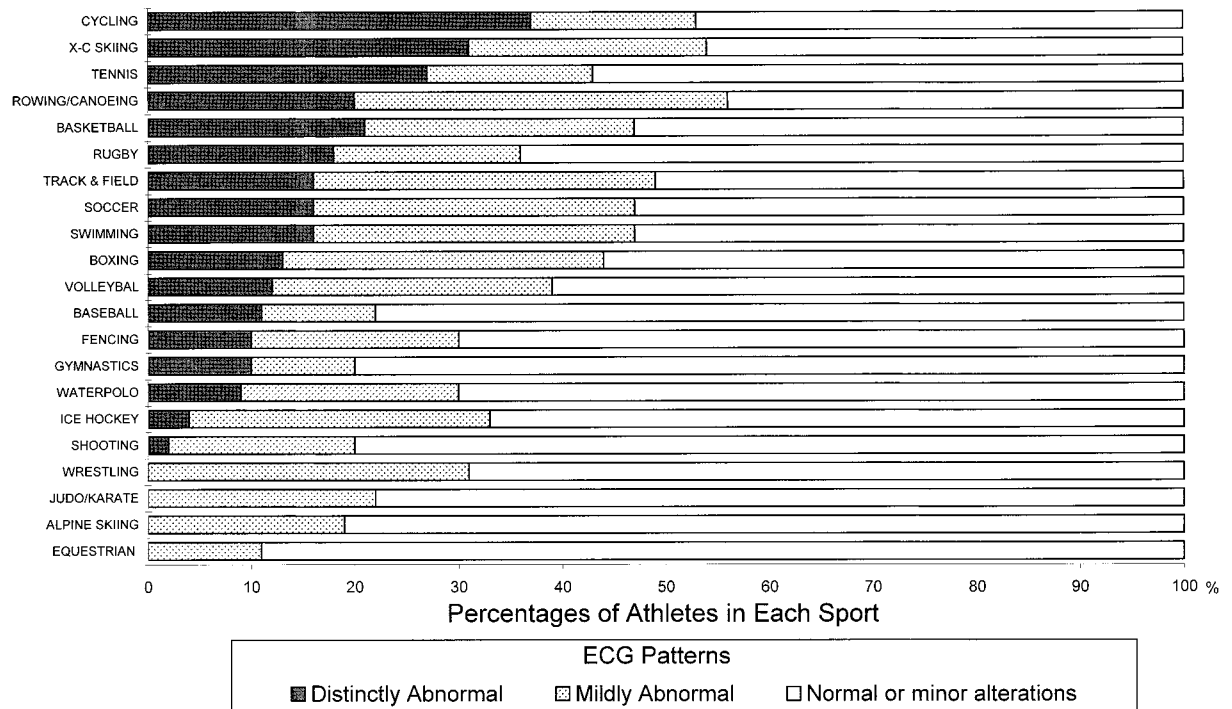


Figure 2. Distribution of 3 ECG categories with respect to sporting disciplines among 1005 athletes. ECGs that were distinctly abnormal (black bars), mildly abnormal (gray bars), and normal or with minor alterations (white bars) are depicted as proportions of all the athletes participating in each sporting discipline. Only sports with ≥ 12 participants are shown. X-C indicates cross-country.

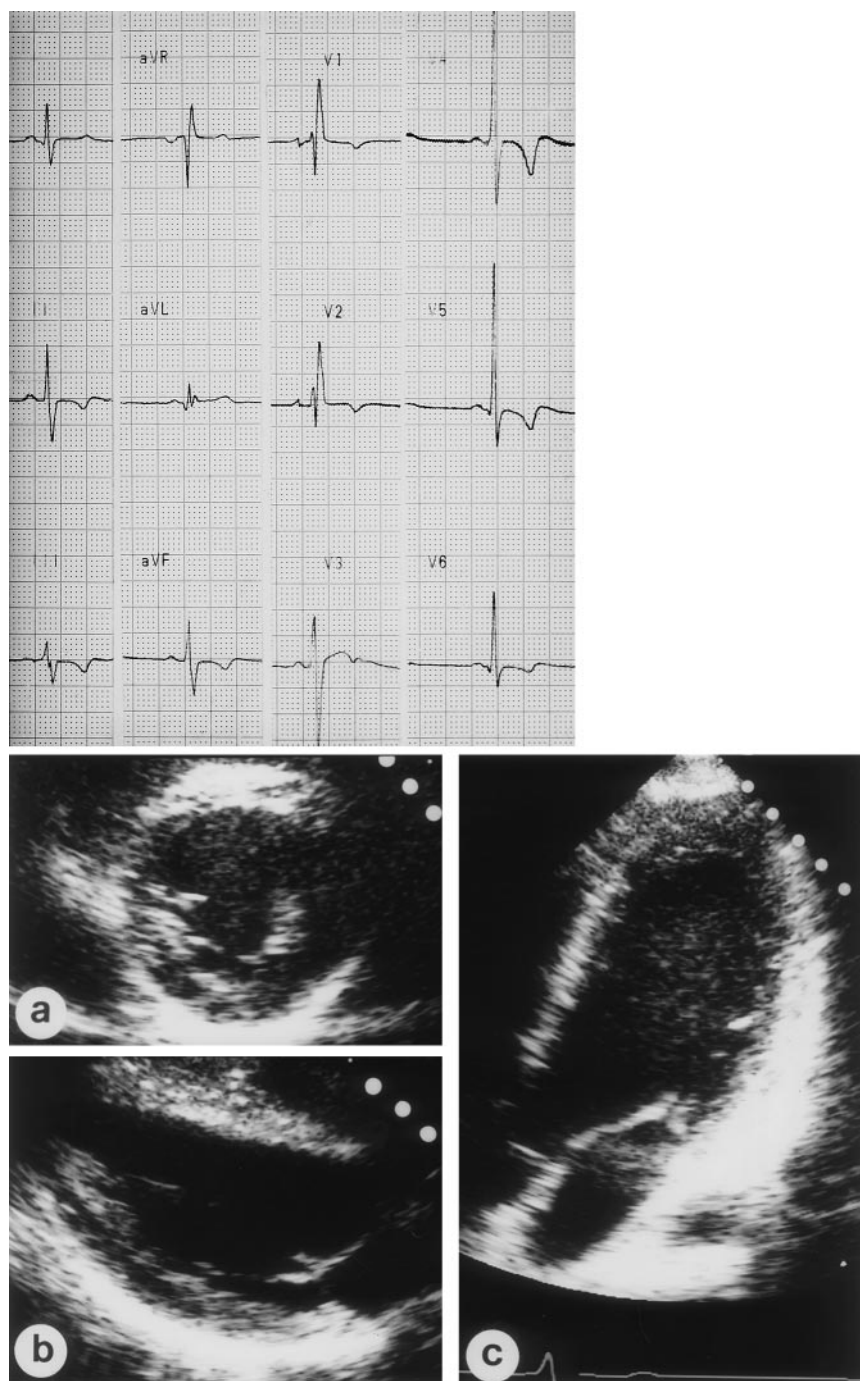


Figure 4. Top panel, Distinctly abnormal 12-lead ECG from a 19-year-old male soccer player that was highly suggestive of cardiac disease and showed marked and diffuse T wave inversion (up to 7 mm in depth) in lateral precordial (V_4 to V_6) and inferior leads (II, III, and aVF), increased R wave voltage >30 mm (V_4 , V_5), and incomplete right bundle branch block. Bottom panel, Parasternal short and long-axis (a, b) and apical long-axis (c) views in this athlete show no evidence of a structural cardiac abnormality or physiological adaptation to training (LV end-diastolic cavity dimension, 50 mm; ventricular septal thickness, 11 mm; posterior free wall thickness, 10 mm).

increase in cardiac dimensions as a consequence of athletic conditioning (Figure 4). These athletes were predominantly male ($n=37$) but showed no obvious predilection for particular sporting disciplines, level of training, or achievement.

In 27 of the 145 athletes, ECG patterns raised particular clinical suspicion because of marked repolarization abnormalities; 11 of these 27 athletes showed diffuse, symmetric, and marked T wave inversion associated with greatly increased precordial R or S wave voltages and/or deep Q waves, which is strongly suggestive of HCM.²⁴ However, only one of these athletes, a 24-year-old basketball player, had clinical and echocardiographic evidence of this disease. The other 16 athletes (aged ≥ 15 years) showed T wave inversion in the right prec-

ordial leads V_1 to V_3 (or V_4) associated with incomplete right bundle branch block that raised suspicion of ARVC.³² However, none of these individuals had clinical features, familial occurrence, or imaging studies supporting this diagnosis.

Of the 145 athletes with distinctly abnormal ECGs, 126 had clinical and echocardiographic follow-up studies for 1 to 11 years (mean, 3.4 years) after the initial identification of the abnormal ECG pattern. Only the single subject with HCM (who was disqualified from competition) developed cardiac symptoms associated with atrial fibrillation; all other athletes remained free of symptoms and without clinical and echocardiographic evidence of structural cardiac disease while they continued intensive training and competition.

Discussion

Several reports over the past 30 years have described a variety of ECG alterations in trained athletes that have been attributed to cardiac adaptations to systematic athletic conditioning.^{1–12} The present study offers new insights into the determinants and clinical significance of the wide range of ECG patterns that may be found in trained athletes because it directly compares ECG patterns with echocardiographic assessments of cardiac morphology. We took advantage of the cardiovascular program implemented at the Institute of Sports Science in Italy, in which both ECGs and echocardiograms have been assembled prospectively in a large population of elite athletes.¹⁹ We made several observations that are useful in clarifying the clinical issues surrounding ECG changes in trained athletes.

Structural cardiovascular diseases were rarely responsible for the abnormal ECG patterns in trained athletes. Only 5% of our population had cardiac abnormalities that could have influenced the ECG pattern identified clinically or with echocardiography. Indeed, a potentially lethal condition (ie, dilated cardiomyopathy or HCM) was detected in only 5 athletes. The low prevalence of cardiac disease in our cohort was not completely unexpected given that the majority of the athletes examined in our medical program had previously undergone a screening evaluation and would have been disqualified from competitions had cardiovascular abnormalities been identified.¹⁹

In the absence of pathological conditions, the major determinant of altered ECG patterns was the morphological cardiac remodeling induced by physical training. Indeed, those athletes with the most marked ECG abnormalities showed the greatest increase in LV cavity size, wall thickness, and mass, as well as left atrial dimension. Conversely, athletes with normal or virtually normal ECGs had the smallest and most normal cardiac dimensions. This relationship between cardiac dimensions and ECG abnormalities was substantiated by statistically significant linear correlations.

Other determinants of abnormal ECG patterns identified by logistic regression analysis were participation in certain endurance sports, male sex, and younger age. Athletes engaged in cycling, rowing/canoeing, and cross-country skiing showed the largest LV dimensions, and these athletes most often had abnormal ECG patterns. Conversely, athletes participating in technical disciplines (ie, equestrian, alpine skiing, and judo) had no evidence of significant LV remodeling and very rarely showed ECG abnormalities. Male athletes most commonly showed abnormal ECG patterns, whereas female athletes usually had normal or virtually normal ECGs. The predominance of normal ECG patterns in female athletes is likely due to several factors, including the mild morphological LV changes induced by training in women²⁰ and their lower participation rates in certain disciplines (such as rowing/canoeing) that have a substantial impact on ECG pattern. Finally, the higher prevalence of abnormal ECGs in athletes <20 years of age suggests that intensive training is more likely to alter the ECG pattern when associated with body growth and maturation during adolescence.

Of particular interest was the subgroup of 145 athletes with markedly abnormal and sometimes bizarre ECG patterns that

suggested the presence of underlying cardiac disease. Only a minority of these athletes had clinical or echocardiographic evidence of structural disease that could account for their abnormal ECGs. Most had increased LV dimensions that could explain the abnormal ECG patterns. However, 53 of the 145 athletes with markedly abnormal ECGs (5% of the 1005) showed neither structural abnormalities or training-induced increases in cardiac dimensions. Therefore, it is reasonable to infer that long-term, intensive athletic conditioning preferentially and substantially alters the ECG in some athletes by as-yet undefined mechanisms and that such bizarre ECG patterns may be part of athlete's heart syndrome.

Of note, several of the distinctly abnormal ECGs we encountered could be regarded as typical of patients with HCM or ARVC, which are well established as potentially lethal cardiac diseases in young people and athletes.^{24,32} However, we found no familial, clinical, or echocardiographic evidence of these diseases to explain the ECG abnormalities. Also, we believe that it is very unlikely that extremely rare lesions, such as congenital coronary artery anomalies of wrong aortic sinus origin, were responsible for the abnormal ECGs because we routinely visualized the coronary ostia with echocardiography,²⁷ and ECGs indicative of myocardial ischemia are uncommonly associated with these anomalies.

Our findings have certain important implications for preparticipation cardiovascular screening in large populations of athletes. The 12-lead ECG has been suggested as a relatively simple and inexpensive test to strengthen the limited diagnostic efficacy of the medical history and physical examination¹⁷ and, indeed, this has been routine practice for the last 2 decades in Italy, in which a systematic screening program for participants in competitive sports was implemented by national law.¹⁹ Recently, Corrado et al¹⁸ suggested that preparticipation screening with ECG was effective in detecting HCM in young Italian athletes. The present study, however, defines certain limitations of the ECG in identifying cardiovascular disease in highly trained athletes. In an important subset of our population without cardiac morphological alterations, striking ECG abnormalities highly suggestive of cardiac disease were likely an innocent consequence of athletic training and part of athlete's heart syndrome. Such false-positive ECGs represent a potential limitation to routine ECG testing as part of preparticipation cardiovascular screening in athletic populations. However, normal ECGs were highly predictive of an absence of cardiovascular abnormalities, probably because of the low prevalence of cardiovascular disease in our healthy study population.

In sharp contrast to the high prevalence of abnormal ECG patterns reported in previous surveys,^{4,9,11} our data showed that most athletes (60%) had ECGs that were either normal or had only minor alterations, and did not raise clinical suspicion of cardiovascular disease. This apparent discrepancy may be the consequence of our definition of normality; we considered ECGs as virtually normal even if they showed a prolonged PR interval, incomplete right bundle branch block, or early repolarization, which are regarded as part of athlete's heart syndrome.⁹ In addition, our large number of normal ECGs may also be due to the inclusion of many athletes participating in sports with little or no impact on cardiac

dimensions,^{21,33} as well as the relatively large proportion of females athletes, who show less cardiac remodeling with training.²⁰

References

- Smith WG, Cullen KJ, Thorburn IO. Electrocardiograms of marathon runners in 1962 Commonwealth Games. *Br Heart J*. 1964;26:469–476.
- Venerando A, Rulli V. Frequency, morphology and meaning of the electrocardiographic anomalies found in Olympic marathon runners. *J Sports Med*. 1964;3:135–141.
- Hanne-Paparo N, Wendkos MH, Brunner DT. T wave abnormalities in the electrocardiograms of top-ranking athletes without demonstrable organic heart disease. *Am Heart J*. 1971;81:743–747.
- Lichtman J, O'Rourke RA, Klein A, et al. Electrocardiogram of the athlete: alterations simulating those of organic heart disease. *Arch Intern Med*. 1973;132:763–770.
- Roeske WR, O'Rourke RA, Klein A, et al. Noninvasive evaluation of ventricular hypertrophy in professional athletes. *Circulation*. 1976;53:286–292.
- Zeppilli P, Pirrami MM, Sassara M, et al. T wave abnormalities in top ranking athletes: effects of isoproterenol, atropine, and physical exercise. *Am Heart J*. 1980;100:213–222.
- Oakley DG, Oakley CM. Significance of abnormal electrocardiograms in highly trained athletes. *Am J Cardiol*. 1982;50:985–989.
- Balady GJ, Cadigan JB, Ryan TJ. Electrocardiogram of the athlete: an analysis of 289 professional football players. *Am J Cardiol*. 1984;53:1339–1343.
- Huston P, Puffer JC, MacMillan RW. The athletic heart syndrome. *N Engl J Med*. 1985;315:24–32.
- Douglas PS, O'Toole ML, Hiller WDB, et al. Electrocardiographic diagnosis of exercise-induced left ventricular hypertrophy. *Am Heart J*. 1988;116:784–790.
- Zehender M, Meinertz T, Keul J, et al. ECG variants and cardiac arrhythmias in athletes: clinical relevance and prognostic importance. *Am Heart J*. 1990;119:1378–1391.
- Björnstad H, Smith G, Storstein L, et al. Electrocardiographic and echocardiographic findings in top athletes, athletic students and sedentary controls. *Cardiology*. 1993;82:66–74.
- Maron BJ, Shirani J, Poliac LC, et al. Sudden death in young competitive athletes. *JAMA*. 1996;276:199–204.
- Thiene G, Nava A, Corrado D, et al. Right ventricular cardiomyopathy and sudden death in young people. *N Engl J Med*. 1988;318:129–133.
- Maron BJ, Pelliccia A, Spirito P. Cardiac disease in young trained athletes: insights into methods for distinguishing athlete's heart from structural heart disease, with particular emphasis on hypertrophic cardiomyopathy. *Circulation*. 1995;91:1596–1601.
- Maron BJ, Thompson PD, Puffer JC, et al. Cardiovascular preparticipation screening of competitive athletes. *Circulation*. 1996;94:850–856.
- Fuller CM, McNulty CM, Spring DA, et al. Prospective screening of 5615 high school athletes for risk of sudden cardiac death. *Med Sci Sports Exerc*. 1997;29:1131–1138.
- Corrado D, Basso C, Schiavon M, et al. Screening for hypertrophic cardiomyopathy in young athletes. *N Engl J Med*. 1998;339:364–369.
- Pelliccia A, Maron BJ. Preparticipation cardiovascular evaluation of the competitive athlete: perspectives from the 30-year Italian experience. *Am J Cardiol*. 1995;75:827–829.
- Pelliccia A, Maron BJ, Culasso F, et al. Athlete's heart in women: echocardiographic characterization of highly trained elite female athletes. *JAMA*. 1996;276:211–215.
- Pelliccia A, Culasso F, Di Paolo FM, et al. Physiologic left ventricular cavity dilatation in elite athletes. *Ann Intern Med*. 1999;130:23–31.
- Friedman HH. *Diagnostic Electrocardiography and Vectorcardiography*. New York: McGraw-Hill; 1971.
- Sokolow M, Lyon TO. The ventricular complex in left ventricular hypertrophy as obtained by unipolar precordial and limb leads. *Am Heart J*. 1949;37:161–186.
- Maron BJ, Wolfson JK, Ciró E, et al. Relation of electrocardiographic abnormalities and patterns of left ventricular hypertrophy identified by 2-dimensional echocardiography in patients with hypertrophic cardiomyopathy. *Am J Cardiol*. 1983;51:189–194.
- Sahn DJ, DeMaria A, Kisslo J, et al. Recommendations regarding quantitation in M-mode echocardiography: results of a survey of echocardiographic measurements. *Circulation*. 1978;58:1072–1083.
- Devereux RB. Detection of left ventricular hypertrophy by M-mode echocardiography: anatomic validation, standardization, and comparison to other methods. *Hypertension*. 1987;9(suppl II):II-19–II-26.
- Pelliccia A, Spataro A, Maron BJ. Prospective echocardiographic screening for coronary artery anomalies in 1360 elite competitive athletes. *Am J Cardiol*. 1993;72:978–979.
- Maron BJ, Spirito P, Green KJ, et al. Noninvasive assessment of left ventricular diastolic function by pulsed Doppler echocardiography in patients with hypertrophic cardiomyopathy. *J Am Coll Cardiol*. 1987;10:733–742.
- Henry WL, Gardin JM, Ware JH. Echocardiographic measurements in normal subjects from infancy to old age. *Circulation*. 1980;62:1054–1061.
- Lauer MS, Martin GL, Levy D. Gender-specific reference M-mode values in adults: population-derived values with consideration of the impact of height. *J Am Coll Cardiol*. 1995;26:1039–1046.
- Armitage P, Berry G. *Statistical Methods in Medical Research*. Oxford, England: McGraw-Hill; 1994:277.
- McKenna WJ, Thiene G, Nava A, et al. Diagnosis of arrhythmogenic right ventricular dysplasia/cardiomyopathy. *Br Heart J*. 1994;71:215–218.
- Pelliccia A, Maron BJ, Spataro A, et al. The upper limit of physiologic cardiac hypertrophy in highly trained elite athletes. *N Engl J Med*. 1991;324:295–301.