

Clinical trial of video-assisted thoracoscopic segmentectomy using infrared thoracoscopy with indocyanine green

Shintaro Tarumi*, Noriyuki Misaki, Yoshitaka Kasai, Sung Soo Chang, Tetsuhiko Go and Hiroyasu Yokomise

Department of General Thoracic Surgery, Breast and Endocrinological Surgery, Faculty of Medicine, Kagawa University, Kagawa, Japan

* Corresponding author. 1750-1 Ikenobe, Miki-cho, Kita-gun, Kagawa 761-0793, Japan. Tel: +81-87-8912191; fax: +81-87-8912192; e-mail: starumi@med.kagawa-u.ac.jp (S. Tarumi).

Received 29 July 2013; received in revised form 17 October 2013; accepted 28 October 2013

Abstract

OBJECTIVES: The maintenance of a good surgical view is mandatory in video-assisted thoracoscopic surgery (VATS). For routine segmentectomy, it is necessary to re-inflate the lung in order to identify the intersegmental line. However, such re-inflation can occasionally obstruct the surgical view. Infrared thoracoscopy (IRT) with indocyanine green (ICG) can reveal the intersegmental line based on blood flow differences, without the need for lung re-inflation. The purpose of this study was to confirm the usefulness of IRT with ICG for VATS.

METHODS: Between October 2008 and September 2011, 44 consecutive patients underwent segmentectomy at our institution. In 13 patients, VATS segmentectomy using IRT with ICG was employed. Informed consent was obtained from all patients. Computed tomography was performed to identify the dominant pulmonary artery supplying the target segment. The operations were performed using two ports and one mini-thoracotomy (3–6 cm). The dominant arteries were interrupted, and the intersegmental line was identified using IRT with ICG.

RESULTS: Identification of the intersegmental line was possible in 11 (84.6%) of the 13 patients. The average age was 70 years, and 6 of the patients were male. The mean operation time was 191 min, and the mean bleeding volume was 64 ml. The operation time and bleeding volume were similar to the values in the other 31 patients who underwent thoracotomy (167 min/115 ml, $P = 0.212/0.361$, respectively). No complications attributable to IRT with ICG were observed.

CONCLUSIONS: VATS segmentectomy using IRT with ICG allows the maintenance of a clear surgical view and identification of the intersegmental line in a high proportion of cases. Therefore, we consider this method to be useful for minimally invasive thoracic surgery.

Keywords: Video-assisted thoracoscopic surgery • Indocyanine green • Infrared thoracoscopy • Segmentectomy

INTRODUCTION

The development of instruments, especially in the field of endoscopy, has increased the success rate of video-assisted thoracoscopic surgery (VATS). Compared with thoracotomy, VATS is minimally invasive and this is a major advantage [1, 2]. Okada *et al.* [3] described radical hybrid VATS segmentectomy to treat lung cancer and reported a complication rate of 9.8% and a cancer-free 5-year survival rate of 84.7%. Other studies have reported the usefulness of segmentectomy to define margins in patients with early-stage lung cancer [4, 5]. Segmentectomy has been found to be better than lobectomy for residual lung function [6]. VATS segmentectomy affords a shorter length of stay and lower morbidity compared with open approaches [7]. These previous reports indicate that VATS segmentectomy is a reasonable method for some types of early-stage lung cancer, but VATS only allows a limited monitor view, and segmentectomy requires a multilateral view, especially when a segmental fissure is created. For VATS segmentectomy, a clear surgical view is important. We have reported a method of identifying the segmental fissure using infrared thoracoscopy (IRT) with indocyanine green (ICG) [8, 9]. This method can

delineate the segmental fissure according to the degree of blood flow without re-inflating the lung. The lung is kept in a deflated state, which is safer for the patient and facilitates the segmentectomy. The purpose of this study was to confirm the usefulness of IRT with ICG for VATS.

MATERIALS AND METHODS

The institutional review board of the University of Kagawa approved the present study. Informed consent was obtained from all patients after the risks and benefits of the proposed surgery had been explained by their surgeons.

Infrared thoracoscopy system

We have described the principles of IRT in a previous report [9]. In brief, IRT (Olympus Co., Ltd, Tokyo, Japan) is a system that uses ICG (Daiichi Sankyo Co., Ltd, Tokyo, Japan) to identify blood flow. The main peak of the absorption spectrum of ICG is 805 nm, and

the emission spectrum of ICG peaks at 830 nm in plasma [10]. The infrared light is directed to the surface of the lung from the light source through a special filter, and the reflected light is detected by a CCD camera. The signals form images according to the set-up transducer on the monitor. If there is no ICG in the blood

flowing to the lung, then the tissue remains unchanged on the monitor (Fig. 1B). ICG is injected into the blood via a peripheral vein. If the tissue receives cardiac output, the appearance of the tissue is affected by ICG. Absorption appears as a blue colour on the monitor (Fig. 1C), whereas emitted light appears as increased luminance. In this way, it is possible to use IRT with ICG to observe blood flow to the lung.

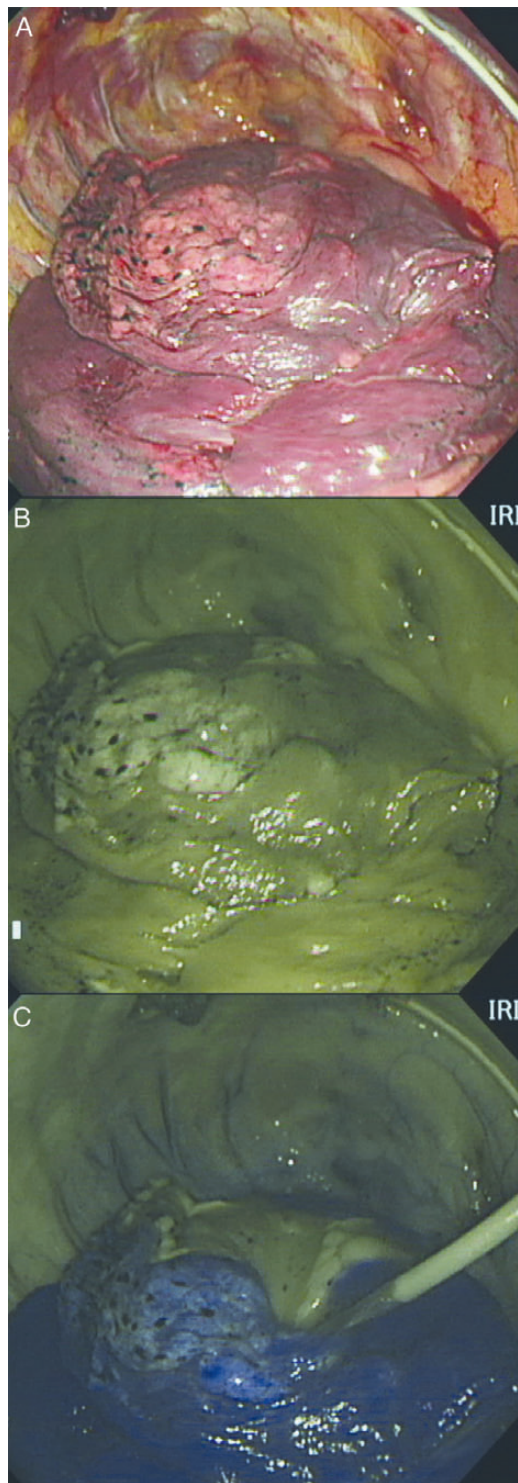


Figure 1: (A) The image was obtained under normal light. (B) The pale colour indicates the absence of ICG in the tissue under IRT. (C) The blue colour indicates the flow of blood containing ICG. The colour boundary shows the segmental fissure.

Patients

A single-institution, non-randomized, retrospective study was conducted in 45 consecutive cases of planned anatomical segmentectomy between October 2008 and September 2011. One patient who was converted to lobectomy because of the margin was excluded. Thirteen patients who were treated after January 2010 underwent VATS segmentectomy using IRT with ICG. These patients reported no iodine or ICG allergies. The other 31 cases had anterolateral thoracotomy. One case was converted from VATS to thoracotomy because of a technical problem. Our general criteria for removal of the chest tube were the absence of an air leak and pale bloody drainage of <200 ml/day and the criterion for discharge was a clinically stable condition the day after chest tube removal. Mortality and morbidity were defined based on events occurring within the first 30 postoperative days. Complications were counted as Grade 2 or more according to the National Cancer Institute Common Terminology Criteria for Events (NCI-CTCAE), version 4.0 [11]. These data were collected in January 2012 from medical records along with laboratory and radiographic findings.

Surgical procedure

All patients underwent a preoperative work-up by computed tomography (CT; Aquilion64, Toshiba Medical Systems Co., Tochigi, Japan) scanning. CT images were three-dimensionally (3D) reconstructed to obtain the detailed anatomy of the pulmonary vessels. We obtained tactile images of the relationship between the target segments and the dominant pulmonary vessels and tumour. We decided to apply segmentectomy in the preoperative staff meeting based on the consensus of a number of surgeons. In the operating room, the surgeon could check the anatomical structures on a dedicated monitor. The patients were placed in the decubitus position under intubation with a double-lumen tube. The 10-mm camera port was placed in the seventh intercostal space in the middle axillary line. The second 10-mm port was placed in the sixth intercostal space near the scapula. The 3- to 4-cm access port was placed in the fourth intercostal space in the anterior axillary line. The main port applied a lap protector (Hakko Co., Ltd, Nagano, Japan) without rib spreading. The thoracotomy cases were performed by anterolateral incision, preserving the latissimus dorsi, splitting the anterior serratus muscle and cutting the fourth or fifth intercostal muscle with a rib spreader. The dominant pulmonary arteries were identified during preoperative evaluation, and the surgeon judged the blood supply of the target segment to be divided. The patients had ICG 3.0 mg/kg injected into a peripheral vein for observation of the lungs under infrared light after the dominant pulmonary arteries were ligated. Two patients had ICG 0.5 mg/kg injected as a trial dose to reduce the amount of ICG. On the monitor, the appearance of the lung gradually changed in the areas with normal blood flow, whereas

areas that did not have blood flow remained pale. The boundary line between the two colour areas was then marked on the visceral pleura with an electrocautery. The dominant bronchi were divided, and the veins were divided as needed. We used a stapling technique with parenchyma division during the segmentectomy.

Statistical analysis

All statistical analyses were performed using Statistical Package for the Social Sciences for Windows, version 20.0.0 (IBM SPSS, Chicago, IL, USA). A Mann-Whitney *U*-test was used to compare differences in continuous variables between the two groups. Fisher's exact test was used to compare differences in dichotomous variables between the two groups. Two-tailed values of $P < 0.05$ were considered significant.

RESULTS

The patients and tumour characteristics are described in Table 1. VATS segmentectomy was completed in 6 male and 7 female patients; their mean age was 70 (range, 56–83) years. Twelve cases were primary lung cancer, and 1 was infectious disease. The average tumour size during VATS was 1.4 (range, 0.5–4.5) cm, which was smaller than the value of 2.4 (range, 0.7–8.5 cm; $P = 0.016$) recorded in the thoracotomy group. There were no significant differences in age, sex or primary disease between the two groups. Identification of the segmental fissure was possible in 11 (84.6%) of the 13 patients using IRT with ICG in VATS. The thoracotomy group included 18 patients in whom IRT with ICG was used, and the segmental fissure could be identified in 17 (94.4%) of these 18 patients. The 13 remaining patients underwent conventional segmentectomy using the re-inflation method for identifying the intersegmental border. The mean operation time was 191 (range, 120–339) min, and the mean bleeding volume was 64 (range, 0–208) ml. The mean duration of drainage was 2.8 (range, 1–6) days. The mean hospital stay was 8.5 (range, 4–16) days. There were no significant differences in operation time, bleeding volume or duration of drainage between the two groups (Table 2). Complications occurred in 2 (15%) of the 13 patients.

Two patients in the VATS group had a case of pulmonary fistula that required pleurodesis (Grade 2). In the thoracotomy group, 5 (16%) of 31 patients had complications. Three patients had pulmonary fistula that required pleurodesis (Grade 2), and 2 had hypoxia (Grade 2). There was no significant difference in morbidity between the two groups. No patients died during the hospital stay. There were no complications resulting from IRT with ICG.

DISCUSSION

The maintenance of a good surgical view is mandatory in VATS. For routine segmentectomy, it is necessary to re-inflate the lung to identify the segmental fissure for anatomical resection in order to avoid perioperative complications, such as bleeding, haematoma and small bronchial fistula. However, such re-inflation can occasionally obstruct the surgical view, particularly in VATS. Furthermore, it is impossible to prepare the lung for re-inflation with the fingers and blunt dissection in VATS [12]. Our goal was to identify the segmental fissure without obstruction of the surgical view.

We previously performed thoracotomy in both animal and clinical studies and demonstrated that the anatomical intersegmental border could be identified by IRT with ICG without re-inflation [8, 9]. In this study, we verified that VATS segmentectomy using IRT with ICG to precisely identify segmental fissures can be satisfactorily performed, compared with conventional segmentectomy. There were no differences in perioperative factors or mortality and morbidity between the two groups. Furthermore, we found that VATS segmentectomy produced the same outcome as thoracotomy. We achieved accurate identification of the segmental fissure in 84.6% of the patients in the VATS group. Although both cases in which the segmental fissure could not be identified were VATS patients, the problem may not be related to VATS. IRT with ICG has a few problems that need to be resolved, including the limitation that the ICG doses are large and emphysematous lung tissue tends to stain less than normal lung [8, 9, 13]. However, we tried to reduce the ICG dose by investigating the minimal amount needed to detect the segmental fissure. The reduced dose may have been a factor in the difficulty in observing the segmental

Table 1: Patient and tumour characteristics

Variable	VATS	Thoracotomy	<i>P</i> -value
Number of patients	13	31	
Gender (M/F)	6/7	24/7	0.074
Age, mean (95% CI) (years)	70.2 (65.0–75.5)	72.2 (68.2–76.2)	0.227
Tumour size, mean (95% CI) (cm)	1.4 (0.8–2.0)	2.4 (1.8–2.9)	0.016
Primary disease			
Primary lung cancer	12 (92.3%)	23 (74.2%)	0.164
Metastatic lung cancer	0 (0%)	7 (22.6%)	
Infectious disease	1 (7.7%)	1 (3.2%)	
Tumour locations			
Upper lobe	9 (69.2%)	16 (51.6%)	
Lower lobe	4 (30.8%)	15 (48.4%)	

VATS: video-assisted thoracoscopic surgery; CI: confidence interval.

Table 2: Surgical results

	VATS	Thoracotomy	<i>P</i> -value
Number of patients	13	31	
Operation time, mean (95% CI) (min)	191.1 (162.6–219.6)	167.3 (148.5–186.1)	0.212
Bleeding volume, mean (95% CI) (ml)	63.8 (8.6–119.0)	115.0 (68.7–161.3)	0.361
Chest tube duration, mean (95% CI) (days)	2.8 (1.7–3.9)	3.2 (2.5–3.9)	0.487
Hospital stay, mean (95% CI) (days)	8.5 (5.8–11.2)	12.7 (10.3–15.1)	0.020
Complications			
Pulmonary fistula	2 (15.4%)	3 (9.7%)	
Hypoxia	0 (0%)	2 (6.4%)	
Morbidity (%)	15.4	16.1	0.999
Mortality (%)	0	0	

VATS: video-assisted thoracoscopic surgery; CI: confidence intervals.

fissure in 2 cases who underwent VATS. Furthermore, another case whose segmental fissure could not be observed by IRT thoracotomy had severe emphysema. More cases are required to verify the true success rate of this method for use in VATS. We are also investigating another method of observing segmental fissure using IRT with ICG in order to try to reduce the dose of ICG [14].

Many authors have reported on techniques to perform segmentectomy with VATS [3, 4, 7, 15]. There are restrictions on the use of VATS because of the limited 2D monitoring view, and segmentectomy is occasionally more technically demanding than lobectomy. We identified the dominant artery to the target segment based on 3D reconstruction of CT images prior to the operation [9]. Other authors have also reported the usefulness of 3D CT in segmentectomy [16–18]. For segmentectomy, it is essential to perform adequate preoperative evaluation. The goal is to maintain a clear surgical view and to locate the actual segmental fissure.

The limitations of this study include its retrospective design and small sample size. It was a single-centre study, and IRT with ICG requires a special system for the delivery of infrared light. If the system becomes widely used, we plan to conduct a multicentre study in the future. The amount of ICG given and the IRT system were not fixed, as it was important to empirically search for the optimal dose and system parameters. ICG is stable in the serum and confined to the intravascular compartment, because it has a high molecular weight and is highly bound to serum proteins. Furthermore, ICG is cleared by rapid hepatobiliary extraction within 24 h [10]. In the past several years, there are some reports of the use of ICG doses of up to 5 mg/kg [19, 20]. However, there is a report of 3 cases with anaphylactoid reactions to ICG, which may have been due to a dose-dependent pseudoallergic mechanism [21]. We tried to reduce the dose of ICG to improve the safety and to decrease the cost of the procedure. The plasma clearance of the ICG is biphasic. There is a rapid initial phase with a half-life of 3–4 min and a secondary phase with a half-life of >1 h at low concentrations [10]. Although the observation duration varied from 3 to 5 min, this was enough time to observe and mark the visceral pleura. If we can discriminate lung blood flow in the secondary phase, we will be able to extend the duration.

There is some concern for the clinical application of our new method. Regarding the instruments, we did not have to use any new devices except for the IRT system, and we could perform the operation with the usual equipment. The manipulation of the IRT system was not different from that of the conventional thoracoscope. Regarding the operation time, we were able to observe the boundary line within 13 (range, 8–18) s of injection of ICG, and the mean observation duration was 3 min 30 s [14]. Our new method does not require more time compared with the conventional re-inflation method.

In conclusion, VATS segmentectomy is a complicated technique due to its limited view, but IRT with ICG can provide a clear surgical field by maintaining the deflated state of the lung and achieve a high rate of identification of the segmental fissure. The method should improve patient safety and allow more precise VATS segmentectomy.

Conflict of interest: none declared.

REFERENCES

- [1] Whitson BA, Andrade RS, Boettcher A, Bardales R, Kratzke RA, Dahlberg PS *et al.* Video-assisted thoracoscopic surgery is more favorable than thoracotomy for resection of clinical stage I non-small cell lung cancer. *Ann Thorac Surg* 2007;83:1965–70.
- [2] Flores RM, Park BJ, Dycoco J, Aronova A, Hirth Y, Rizk NP *et al.* Lobectomy by video-assisted thoracic surgery (VATS) versus thoracotomy for lung cancer. *J Thorac Cardiovasc Surg* 2009;138:11–8.
- [3] Okada M, Tsutani Y, Ikeda T, Misumi K, Matsumoto K, Yoshimura M *et al.* Radical hybrid video-assisted thoracic segmentectomy: long-term results of minimally invasive anatomical sublobar resection for treating lung cancer. *Interact Cardiovasc Thorac Surg* 2012;14:5–11.
- [4] Shapiro M, Weiser TS, Wisnivesky JP, Chin C, Arustamyan M, Swanson SJ. Thoracoscopic segmentectomy compares favorably with thoracoscopic lobectomy for patients with small stage I lung cancer. *J Thorac Cardiovasc Surg* 2009;137:1388–93.
- [5] Schuchert MJ, Pettiford BL, Keeley S, D'Amato TA, Kilic A, Close J *et al.* Anatomic segmentectomy in the treatment of stage I non-small cell lung cancer. *Ann Thorac Surg* 2007;84:926–32; discussion 32–3.
- [6] Keenan RJ, Landreneau RJ, Maley RH Jr, Singh D, Macherey R, Bartley S *et al.* Segmental resection spares pulmonary function in patients with stage I lung cancer. *Ann Thorac Surg* 2004;78:228–33; discussion 28–33.
- [7] Schuchert MJ, Pettiford BL, Pennathur A, Abbas G, Awais O, Close J *et al.* Anatomic segmentectomy for stage I non-small-cell lung cancer: comparison of video-assisted thoracic surgery versus open approach. *J Thorac Cardiovasc Surg* 2009;138:1318–25 e1.
- [8] Misaki N, Chang SS, Gotoh M, Yamamoto Y, Satoh K, Yokomise H. A novel method for determining adjacent lung segments with infrared thoracoscopy. *J Thorac Cardiovasc Surg* 2009;138:613–8.
- [9] Misaki N, Chang SS, Igai H, Tarumi S, Gotoh M, Yokomise H. New clinically applicable method for visualizing adjacent lung segments using an infrared thoracoscopy system. *J Thorac Cardiovasc Surg* 2010;140:752–6.
- [10] Desmetre T, Devoisselle JM, Mordon S. Fluorescence properties and metabolic features of indocyanine green (ICG) as related to angiography. *Survey Ophthalmol* 2000;45:15–27.
- [11] Common Terminology Criteria for Adverse Events (CTCAE) v4.03. <http://evs.nci.nih.gov/ftp1/CTCAE/About.html> (20 August 2012, date last accessed).
- [12] Siemel W, Dango S, Kirschbaum A, Cucuruz B, Horth W, Stremmel C *et al.* Sublobar resections in stage IA non-small cell lung cancer: segmentectomies result in significantly better cancer-related survival than wedge resections. *Eur J Cardiothorac Surg* 2008;33:728–34.
- [13] Gotoh M, Yamamoto Y, Igai H, Chang S, Huang C, Yokomise H. Clinical application of infrared thoracoscopy to detect bullous or emphysematous lesions of the lung. *J Thorac Cardiovasc Surg* 2007;134:1498–501.
- [14] Kasai Y, Tarumi S, Chang SS, Misaki N, Gotoh M, Go T *et al.* Clinical trial of new methods for identifying lung intersegmental borders using infrared thoracoscopy with indocyanine green: comparative analysis of 2- and 1-wavelength methods. *Eur J Cardiothorac Surg* 2013;44:1103–7.
- [15] Swanson SJ. Segmentectomy for lung cancer. *Semin Thorac Cardiovasc Surg* 2010;22:244–9.
- [16] Iwano S, Usami N, Yokoi K, Naganawa S. Segmentectomy simulation using a virtual three-dimensional safety margin. *Ann Thorac Surg* 2012;93:e37–9.
- [17] Nakamoto K, Omori K, Nezu K. Lung Cancer Project Group of West-Seto Inland Sea J. Superselective segmentectomy for deep and small pulmonary nodules under the guidance of three-dimensional reconstructed computed tomographic angiography. *Ann Thorac Surg* 2010;89:877–83.
- [18] Oizumi H, Kanauchi N, Kato H, Endoh M, Suzuki J, Fukaya K *et al.* Anatomic thoracoscopic pulmonary segmentectomy under 3-dimensional multidetector computed tomography simulation: a report of 52 consecutive cases. *J Thorac Cardiovasc Surg* 2011;141:678–82.
- [19] Fox IJ, Wood EH. Indocyanine green: physical and physiologic properties. *Mayo Clin Proc* 1960;35:732–44.
- [20] Moody FG, Rikkers LF, Aldrete JS. Estimation of the functional reserve of human liver. *Ann Surg* 1974;180:592–8.
- [21] Speich R, Saesseli B, Hoffmann U, Neftel KA, Reichen J. Anaphylactoid reactions after indocyanine-green administration. *Ann Int Med* 1988;109:345–6.