

Clinical usefulness of dopamine transporter SPECT imaging with ^{123}I -FP-CIT in patients with possible dementia with Lewy bodies: randomised study

Zuzana Walker, Emilio Moreno, Alan Thomas, Fraser Inglis, Naji Tabet, Michael Rainer, Gilberto Pizzolato* and Alessandro Padovani, on behalf of the DaTSCAN DLB Phase 4 Study Group

Background

Dementia with Lewy bodies (DLB) is underrecognised in clinical settings.

Aims

To investigate whether performing a ^{123}I -ioflupane injection (^{123}I -FP-CIT also called DaTSCANTM) single photon emission computed tomography (SPECT) scan in patients with possible DLB would lead to a more certain diagnosis (probable DLB or non-DLB dementia).

Method

We randomised 187 patients with possible DLB 2:1 to have a scan or not (control group). The outcome measure was a change in diagnosis to probable DLB or non-DLB.

Results

There were 56 controls and 114 scanned patients, of whom 43% had an abnormal scan. More patients in the imaging group had a change in diagnosis compared with controls at 8 and 24 weeks (61% ($n=70$) *v.* 4% ($n=2$) and 71% ($n=77$) *v.* 16% ($n=9$); both $P<0.0001$). Clinicians were more likely to

change the diagnosis if the scan was abnormal (82%) than if it was normal (46%).

Conclusions

Imaging significantly contributed to a more certain diagnosis, proving to be a useful adjunct in the work-up of patients with possible DLB.

Declaration of interest

Z.W. has received funding for travel, consultancy and speaker fees and research support from GE Healthcare (GEHC), consultancy fees from Bayer Healthcare and Novartis and research support from Lundbeck. N.T. has received speaker fees from Eli Lilly and Pfizer and consultancy fees from GEHC. E.M. is a full time employee of GEHC. F.I. has received speaker fees as a consultant to Pfizer and funding for research work conducted with Abbott Laboratories Ltd, Eli Lilly, GEHC, Genentech, Medivation Inc, Noscira, Pfizer and Roche. A.T. has received research support for an investigator-led study from GEHC.

The clinical diagnosis of dementia with Lewy bodies (DLB) is based on a set of criteria proposed by the DLB consortium¹ that establish different levels of certainty (possible DLB and probable DLB). Apart from dementia as a central feature, the criteria specify core features (marked fluctuations in attention and alertness, spontaneous Parkinsonian features, and recurrent vivid visual hallucinations) and suggestive features (antipsychotic sensitivity, rapid eye movement sleep behaviour disorder and low dopamine transporter uptake in basal ganglia). Patients can be diagnosed as having possible or probable DLB based on the number of core and suggestive features. Patients who fulfil possible DLB criteria have a very uncertain diagnosis as they have only one core or one or more suggestive features. In a 1-year follow-up study of patients with possible DLB, 40% of individuals continued to be in the possible DLB diagnostic category. All patients that received a diagnosis of non-DLB at follow-up had negative ^{123}I -ioflupane injection (^{123}I -FP-CIT) scans and 63% of patients with a probable diagnosis of DLB at follow-up had an abnormal scan.²

Several studies have demonstrated that the clinical diagnosis of DLB has fairly high specificity but low sensitivity.^{3,4} ^{123}I -FP-CIT is used with single photon emission computed tomography (SPECT) imaging for assessment of dopamine transporter and therefore the integrity of the nigrostriatal pathway. Loss of dopamine transporter has been shown at autopsy to be a feature of both DLB and Parkinsonian disorders.⁵ Low dopamine transporter uptake in the basal ganglia is a suggestive feature of DLB. Long-term follow-up of a series of patients with dementia who had ^{123}I -FP-CIT SPECT scans and who subsequently had

neuropathological examinations showed that the sensitivity of an ^{123}I -FP-CIT SPECT scan for diagnosing DLB was 100%, and the specificity was 92%.^{6,7} In a large European study, using a consensus panel clinical diagnosis, an ^{123}I -FP-CIT SPECT scan had 78% sensitivity and 90% specificity for DLB *v.* non-DLB dementia.⁸

Prognosis, the course of the disease and the clinical management of DLB differ in some important aspects from other dementias such as Alzheimer's disease. The management of Parkinsonian symptoms, sleep disorders and autonomic dysfunction needs specific consideration.⁹ Patients with DLB are more likely to develop complications when they receive antipsychotics¹⁰ and they may respond better to cholinesterase inhibitors although no prospective study has demonstrated this definitively.¹¹ There is also some evidence that patients with DLB could benefit from memantine.¹² Patients with DLB have more pronounced neuropsychiatric symptoms and increased caregiver distress.¹³ Overall, DLB evolves more rapidly than Alzheimer's disease, resulting in earlier long-term nursing care and higher cost of treatment.^{14,15} As a result of the different prognostic implications of a diagnosis of probable DLB compared with other diagnoses, an improvement in the confidence of diagnosis has clinical relevance. An accurate and early diagnosis may provide a better explanation of the features, lead to changes in the clinical management of patients, and help families, relatives and carers to make informed decisions and future plans. This should translate into better management of the patient with reduced carer burden and better clinical outcome. In uncertain dementia, diagnostic confidence tends to increase during the follow-up of patients as the clinical features evolve over time. The present study tested the hypothesis that imaging with

*Deceased.

^{123}I -FP-CIT SPECT would lead to an earlier change to a more certain diagnosis (probable DLB or non-DLB dementia) compared with patients without imaging during follow-up.

Method

Study design and participants

In this multicentre, randomised, open-label trial we enrolled participants from 21 centres in 6 European countries with experience in the diagnosis of DLB (EudraCT NUMBER: 2010-021474-11). Approximately 70% of the 21 centres were general hospitals whereas the rest were academic centres (60% of the clinicians were neurologists and 40% old age psychiatrists). The study period was 14 January 2011 to 8 October 2012. Patients had to be 55 years of age or older and have a Mini-Mental-State-Examination (MMSE)¹⁶ score between 10 and 28. Patients with possible DLB were diagnosed by local clinicians according to the consensus criteria¹ as having dementia plus one core feature or one or more suggestive features (excluding prior dopamine transporter imaging). All patients had a reliable informant who was willing to participate in the study. Exclusion criteria included having an established clinical diagnosis of probable DLB or non-DLB dementia; Parkinsonian features present for more than 1 year prior to onset of dementia; severe extrapyramidal features (a score greater than 30 on the Unified Parkinson's Disease Rating Scale-III; UPDRS-III¹⁷); known or suspected significant vascular pathology according to brain magnetic resonance imaging (MRI)/computed tomography (CT); the presence of any severe mental or physical illness that could account for dementia; life expectancy of less than 1 year; medication known to influence uptake of ^{123}I -FP-CIT (these included amphetamine, benztropine, bupropion, cocaine, mazindol, methylphenidate, phentermine and sertraline); or a history or current misuse of illicit drugs or alcohol. Informed consent was obtained from each patient and their caregiver. This study was conducted in full accordance with the Declaration of Helsinki, the Good Clinical Practice: Consolidated Guideline approved by the International Conference on Harmonisation and all applicable national and local laws and regulations.

Randomisation

Randomisation was performed centrally using the labelling system ClinPro/LBL at GE Healthcare in Oslo in December 2010. The randomisation was performed using a block size of 6, imaging group:control group (4:2). Randomisation cards were printed with the treatment group names and these names were covered by black scratch off labels to be used by the local research staff.

Procedures

Patients without an MRI scan available prior to baseline underwent a standard MRI scan during the course of the study unless this was contraindicated. In that case, cerebral CT imaging within 6 months prior to baseline or during the study was also acceptable.

All patients had a baseline visit, at which the following procedures/schedules were performed and the results recorded: collection of demographic data, use of any concomitant medication, medical/surgical history, physical examination with emphasis on neurological examination, UPDRS-III score (if on anti-Parkinsonian medication, there was no requirement to stop treatment), Addenbrooke's Cognitive Examination-Revised (ACE-R),¹⁸ Neuropsychiatric Inventory (NPI),¹⁹ Clinician Assessment of Fluctuation Scale,²⁰ and Geriatric Depression Scale (GDS).²¹ Onsite clinicians recorded DLB features listed in the

Consensus criteria¹ taking into account the results of the above scales as well as patients' dementia diagnostic category. Clinicians also rated their confidence of diagnosis using a visual analogue scale (VAS) scored from 0 to 100 mm. Clinicians were instructed, 'Please indicate how certain you are that your diagnosis is correct (i.e. how certain you are that you can exclude or confirm DLB) by placing a mark on the VAS scale'. The 0 mm end of the scale represented 'Not confident at all' whereas the 100 mm end of the scale represented 'Extremely confident'.

Following baseline assessment, patients were randomly assigned to have a ^{123}I -FP-CIT SPECT scan or no scan (2:1). Both study personnel and patients were aware of participants' group assignment. If the patient was randomised to the imaging group, the study centre scheduled the imaging visit 2 to 6 weeks after baseline assessment.

SPECT imaging

Each patient in the imaging group was given oral medication for thyroid blockade prior to the administration of ^{123}I -FP-CIT. The patient then received a single intravenous injection of ^{123}I -FP-CIT in a maximum volume of 2.5 ml and a radioactivity range of 111–185 MBq. Monitoring for adverse events began as soon as the injection started. Within 3–6 h of their injection, the patient underwent a SPECT scan to assess the functional integrity of the nigrostriatal dopaminergic neuron terminals in the striatum. Post administrative thyroid blocking was also performed. All patients remained under constant medical supervision during the imaging phase of the study. Any adverse event reported by the patient was recorded.

All centres had sufficient experience with ^{123}I -FP-CIT SPECT imaging. Therefore, there was no need for prestudy striatal phantom studies. Images were acquired using a gamma camera fitted with a low-energy high-resolution or fan beam collimator and calibrated using the 159 keV photopeak and a $\pm 10\%$ energy window. Angular sampling was not less than 120 views in a circular orbit (3° steps over 360° rotation). The radius of rotation was set as small as possible. Matrix size was 128×128 , and zoom factor was selected to give a pixel size of 3.5–4.5 mm. A minimum of 500 k counts was collected for optimal images. A headrest was used for all acquisitions.

After the imaging procedure, images were visually rated by local nuclear medicine physicians and classified as normal (normal uptake in all regions); abnormal type 1 (asymmetric activity with one putamen showing reduced uptake), type 2 (absent activity in the putamen of both hemispheres), type 3 (absent activity in the putamen of both hemispheres and greatly reduced in one or both caudate nuclei; see Fig. 1 for examples of normal and abnormal images types 1–3), or type 4 (other abnormal pattern). The rating of other abnormal pattern was made when no clear pattern could be determined but the scan was clearly abnormal. An example would be balanced loss with high background signal, maintaining the normal comma shape but the uptake is uniformly reduced as compared with background activity; another example would be intense localised reduction in uptake in one striatum (or part of the striatum) but preserved full uptake in the rest of the striatum indicating a striatal infarct. The readers were masked to all clinical and psychometric evaluations. The images, and the physician's rating, were provided to the patient's clinician within 1 week.

All patients were invited to return to the study centre to attend a second visit 8 weeks (± 1 week) after baseline. For patients in the imaging group, the physician reviewed the result of the SPECT scan and discussed this with the patient. The following procedures were performed with all returning patients and the results

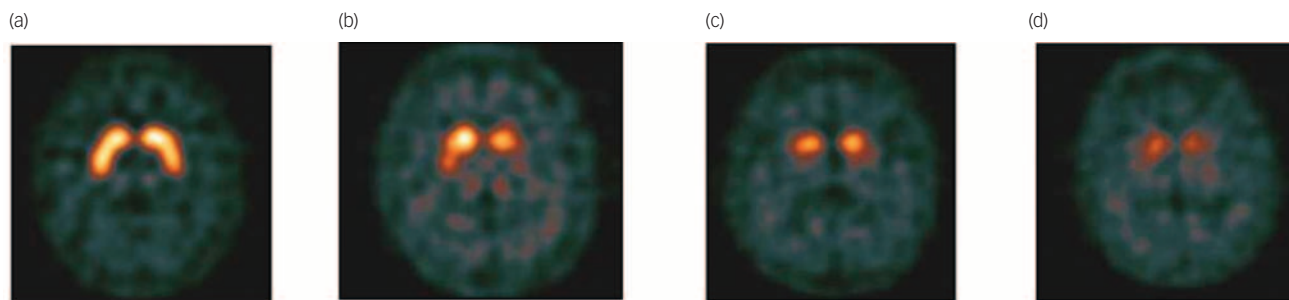


Fig. 1 Example of visual scan rating categories.

(a) Normal, (b) abnormal type 1, (c) abnormal type 2, (d) abnormal type 3.

recorded: physical examination with neurological examination, UPDRS-III score, dementia diagnostic category, DLB features and clinician's confidence of diagnosis.

Patients were reassessed 24 weeks (± 2 weeks) weeks after baseline. The same schedules used at baseline were repeated. At the end of the study, participants in the control group were scheduled for ^{123}I -FP-CIT SPECT imaging if considered clinically appropriate but the results of these scans were not part of the study.

Outcomes

The primary outcome measure was the proportion of patients with a change in clinical diagnosis (to probable DLB or non-DLB) at 8 weeks. Secondary outcome measures were change in clinical diagnosis at 24 weeks and change in clinicians' confidence of diagnosis at 8 and 24 weeks.

Statistical analysis

The proportion of patients with a change in clinical diagnostic category at 8 and 24 weeks compared with baseline was compared using Fisher's exact test for both groups. The mean change in clinicians' confidence of diagnosis between baseline and week 8, baseline and week 24, and weeks 8 and 24 was compared using an analysis of covariance model (ANCOVA) for both groups. The treatment group was the main effect and the baseline confidence of diagnosis was entered as the covariate. The percentage of abnormal ^{123}I -FP-CIT SPECT scans in the imaging group was also reported.

Per-protocol

Both primary and secondary outcomes were analysed per-protocol. The analysis of week 8 outcomes included all control participants who attended both baseline and week 8 visits, and all ^{123}I -FP-CIT participants who attended both baseline and week 8 visits and for whom a ^{123}I -FP-CIT image interpretation was available. The analysis of week 24 outcomes included all participants who attended baseline, week 8 and week 24 visits. All data reported in this paper were analysed per-protocol unless otherwise specified.

Intention-to-treat

Intention-to-treat analyses were performed on the primary outcome and the secondary outcome of diagnostic category at 24 weeks. Analysis of both outcomes included all participants who were randomised regardless of whether they completed

subsequent visits. For the intention-to-treat analyses missing values were regarded as having no change in diagnostic category.

Results

In total, 192 patients gave informed consent and 187 were randomised to one of the two groups. Of these, 127 patients were randomised to the imaging group and 60 patients were randomised to the control group. However, 11 patients who were randomised to the imaging group did not undergo imaging and 4 patients in the control group failed to attend their week 8 visit. Overall, 116 patients had a scan (Fig. 2) although only 114

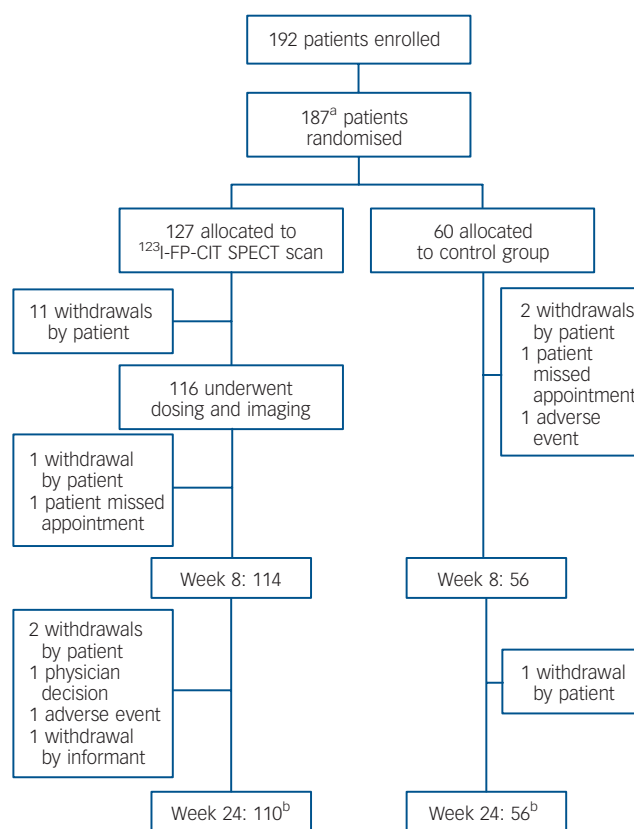


Fig. 2 Trial profile.

a. Five patients declined to participate after the initial screening visit but before randomisation.
b. including one patient who missed the appointment at week 8 in each group. ^{123}I -FP-CIT, ^{123}I -ioflupane injection; SPECT, single photon emission computed tomography.

attended the follow-up visit at 8 weeks. All images were readable and rated as normal or abnormal types 1, 2, 3 or 4.

Demographics

Baseline characteristics are presented in Table 1. The two groups were well-matched for age, geriatric depression scale, fluctuations scale, presence of Parkinsonian features and cognitive testing (Table 1). Of the randomised population at baseline, 30 patients took anti-Parkinson's treatment, 133 took anti-dementia medication and/or antidepressants, 36 took anxiolytics and 23 took antipsychotics, mainly quetiapine ($n=18$). A total of 28% of patients had features of Parkinsonism. The two groups were well-matched for core and suggestive features of DLB (Table 2, all $P>0.05$).

Primary and secondary outcome measures

Following per-protocol analyses, change in diagnostic category at 8 weeks, as compared with baseline, was 61% ($n=70$) in the imaging group and 4% ($n=2$) in the control group. The change in diagnostic category at week 24 compared with baseline was 71% ($n=77$) in the imaging group and 16% ($n=9$) in the control group. The difference between the two groups was statistically significant at both time points (both $P<0.0001$; Fig. 3). Confidence of diagnosis at baseline was similar in both groups but was significantly greater in the imaging group at 8 and 24 weeks (Fig. 4, both $P<0.0001$).

The data were also analysed according to intention-to-treat. Change in diagnostic category at 8 weeks, as compared with baseline, was 55% in the imaging group and 3% in the control group. The change in diagnostic category at week 24 compared with baseline was 61% in the imaging group and 15% in the

control group. The difference between the two groups was statistically significant at both time points (both $P<0.0001$).

Results for imaging group according to visual rating of scan

Injection was administered according to protocol in 86% of the participants with a mean radioactivity of 174 MBq (range 142–209). Three participants received a contraindicated medication (2 took sertraline, 1 took bupropion) at the time of injection. Physician review of ^{123}I -FP-CIT images resulted in 65 (57%) scans being classed as normal and 49 (43%) as abnormal (abnormal type 1 in 8%, type 2 in 21%, type 3 in 4% and type 4 in 10%).

Clinicians were more likely to change a diagnosis when the scan was abnormal than when the scan was normal (Table 3 and Fig. 5). The majority of patients with an abnormal scan (78%, $n=38$) were assigned a diagnosis of probable DLB by the clinicians. None of the patients with a normal scan were classified as probable DLB. Patients with a normal scan were equally distributed between non-DLB and possible DLB diagnostic categories.

Change in VAS scores for confidence of diagnosis showed a similar pattern with a significantly greater increase for patients with abnormal images (Table 4). Changes in diagnostic category for both groups depending on scan result are shown in Table 3. Nine patients with abnormal images had a 24-week diagnosis of either non-DLB ($n=3$) or possible DLB ($n=6$). More detailed descriptions of these nine participants are presented in Table 5.

Safety

In the patients who underwent imaging, 24 of 116 patients (21%) reported 39 treatment-emergent adverse events. Two treatment-emergent adverse events were thought to be at least possibly

Table 1 Baseline characteristics^a

	Imaging group ($n=114$)	Control group ($n=56$)	Total ($n=170$)
Gender, n (%)			
Men	64 (56.1)	29 (51.8)	93 (54.7)
Women	50 (43.9)	27 (48.2)	77 (45.3)
Age, years: mean (s.d.)	75.2 (7.08)	74.6 (7.63)	75.0 (7.25)
Geriatric Depression Scale (0–15) ^b			
Mean (s.d.)	3.3 (2.91)	3.8 (2.43)	3.5 (2.76)
Median (IQR)	3 (1–5)	3 (2–6)	3 (2–5)
Clinical Assessment of Fluctuation Scale (0–16)			
Mean (s.d.)	2.9 (3.76)	1.9 (3.57)	2.5 (3.72)
Median (IQR)	0 (0–6)	0 (0–2.5)	0 (0–6)
Fluctuation Scale >0 , n (%)	51 (45)	16 (29)	67 (39)
Addenbrooke's Cognitive Examination – Revised (0–100)			
Mean (s.d.)	63.8 (17.1)	59.8 (16.6)	62.5 (17.0)
Median (IQR)	63.5 (52–78)	56.0 (50–74)	62.5 (50–77)
Mini-Mental State Examination (0–30)			
Mean (s.d.)	22.2 (4.67)	21.9 (4.69)	22.1 (4.66)
Median (IQR)	23 (20–26)	22 (19–26)	23 (19–26)
Neuropsychiatric Inventory, total (0–144) ^c			
Mean (s.d.)	15.9 (14.66)	13.3 (14.93)	15.0 (14.75)
Median (IQR)	13 (5–23)	10 (4–18)	12 (4–21)
Neuropsychiatric Inventory, caregiver distress (0–60) ^c			
Mean (s.d.)	8.6 (8.17)	7.1 (6.72)	8.1 (7.73)
Median (IQR)	6 (2–13)	7 (2–10)	6 (2–11)
Unified Parkinson's Disease Rating Scale, Part III overall assessment (0–56)			
Mean (s.d.)	9.3 (8.47)	9.2 (7.53)	9.3 (8.15)
Median (IQR)	6.5 (2–15)	8.0 (2–15)	7 (2–15)

a. For all scales the data in parentheses represent theoretical range values for the test.

b. Data available for only 113 participants in the imaging group.

c. Data only available for 55 participants in the control group.

Table 2 Presence of core and suggestive dementia with Lewy bodies (DLB) features at baseline^a

DLB feature type	n (%)	
	Imaging group (n = 114)	Control group (n = 56)
Fluctuating cognition	36 (32)	13 (23)
Visual hallucinations	25 (22)	16 (29)
Features of Parkinsonism	30 (26)	19 (34) ^b
Rapid eye movement sleep behaviour disorders	23 (20) ^b	6 (11) ^c
Severe antipsychotic sensitivity	0	0

a. The results of DLB feature type were classified into two groups, present and other (including not present, unclear).
 b. Percentages were calculated excluding the one participant where information was not available.
 c. Percentages were calculated excluding the five participants where information was not available.

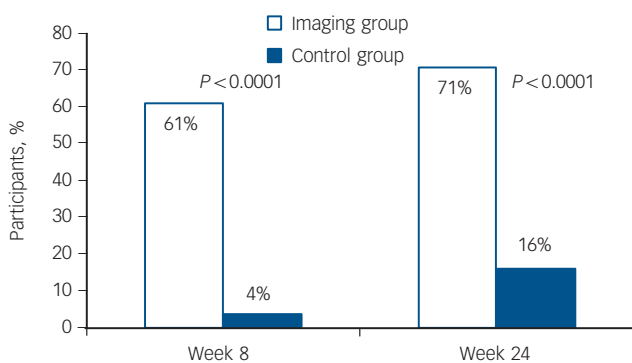


Fig. 3 Per cent change in diagnostic category for the two groups at week 8 and 24.

related to administration of ¹²³I-FP-CIT (these were an anxiety attack and bruising at injection site). Eight patients in the imaging group reported serious adverse events during the study. There were no deaths.

Discussion

This is the largest prospective multicentre study in possible DLB showing that access to dopamine transporter SPECT imaging significantly assisted clinicians to make a clearer diagnosis at 8 and 24 weeks. At baseline mean clinician confidence of diagnosis

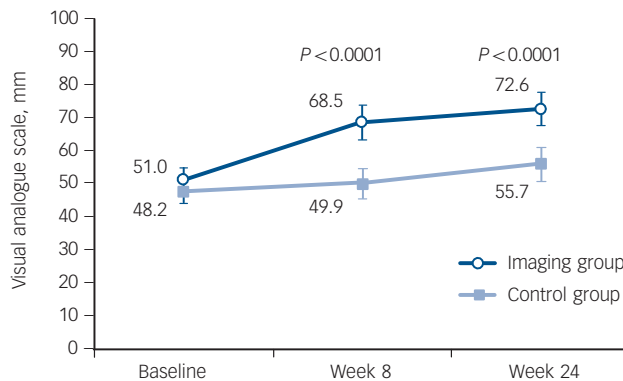


Fig. 4 Mean values of clinician confidence of diagnosis for the two groups measured on a visual analogue scale (mm).
 P-values, point estimates and 95% confidence interval are obtained from ANCOVA model with treatment group as the main effect and baseline value as covariates. Bars represent 95% CI of the mean.

was only 50%, indicating great uncertainty of diagnosis. Imaging also considerably improved the diagnostic confidence of clinicians at 8 and 24 weeks.

Our results highlight that a relatively large proportion of patients with dementia that have only one core feature or just suggestive features of DLB have an abnormal dopamine transporter scan, and therefore increased likelihood of DLB diagnosis. This emphasises the importance of routinely enquiring about core and suggestive features of DLB. In clinical practice, patients with only one feature of DLB are frequently diagnosed as possible Alzheimer’s disease. This could partially explain the low sensitivity of clinical diagnostic criteria for DLB.

In our imaging cohort, only about a quarter of patients had Parkinsonian features and these were mild, with a mean UPDRS-III score of 9. However, 43% of scanned patients had an abnormal ¹²³I-FP-CIT scan. This reaffirms that a ¹²³I-FP-CIT scan can detect dopaminergic deficits before the emergence of clinical Parkinsonism²² and that dopaminergic imaging in this group is particularly helpful.

This is the first study to observe that a change in diagnostic category and improvement in clinicians’ confidence of diagnosis are more likely when the result of ¹²³I-FP-CIT SPECT imaging is abnormal. When the scan was abnormal, the majority of clinicians were able to commit to a more certain diagnosis. When the scan was normal, only half of the clinicians made a change in diagnostic category, suggesting that physicians are less likely to

Table 3 Relationship between dementia diagnosis and single photon emission computed tomography (SPECT) image results^a

Diagnostic category at week 8	n	Non-DLB	Diagnostic category at week 24, n		
			Possible DLB	Probable DLB	Missing
<i>Control group (n = 56)</i>					
Non-DLB	2		2		
Possible DLB	54	4	44	5	1
<i>Imaging group (n = 114)</i>					
Normal scan					
Non-DLB	65	25	4		1
Possible DLB	35	11	22		2
Abnormal scan					
Non-DLB	49	2 ^b			
Possible DLB	9	1 ^b	5 ^b	3	
Probable DLB	38		1 ^b	35	2

DLB, dementia with Lewy bodies.
 a. All participants had a diagnosis of possible DLB at baseline.
 b. Mismatches between imaging results and diagnostic category are listed in table 5.

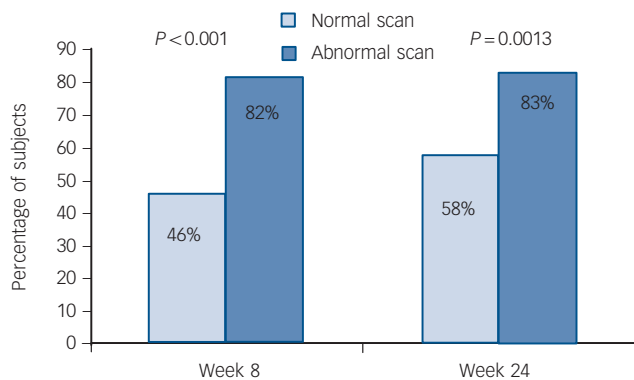


Fig. 5 Per cent change in diagnostic category according to scan results at week 8 and 24.

rule out DLB on the basis of a normal scan. This is in contrast to a retrospective, non-randomised study examining diagnostic changes in patients with suspected DLB following ^{123}I -FP-CIT SPECT.²³ Most patients with abnormal scans had a post-scan diagnosis of DLB, whereas most patients with normal scans had a post-scan diagnosis of non-DLB dementia.

Although ^{123}I -FP-CIT SPECT scans are safe, the additional cost and inconvenience for the patient mean that imaging is

indicated only in difficult to diagnose cases. The main advantage of ^{123}I -FP-CIT scans is that they facilitate early diagnosis and therefore guide appropriate management. The relatively infrequent change in diagnosis even at 6 months follow-up in the non-imaging group suggests that the policy of 'wait and see' frequently used in neurodegenerative disorders is not particularly useful in possible DLB. As in the study by O'Brien *et al.*,² we have found a high proportion of patients continued to have a diagnosis of possible DLB in the absence of dopamine transporter imaging.

Importance of scan result

It is interesting that both improvement in confidence of diagnosis and a change to a more certain diagnosis were more likely to take place when the ^{123}I -FP-CIT SPECT scan was abnormal than normal. Three patients continued to have a non-DLB diagnosis despite an abnormal scan. However, all three imaging reports expressed a level of uncertainty about the result, which is likely to have influenced the clinicians. One of the reports indicated technical difficulties that made it difficult to accurately interpret the scan. One suggested alternative pathology (infarct), and in one case the clinical decision was unclear. Another possibility is that despite the abnormal ^{123}I -FP-CIT SPECT scans, the clinicians felt that an alternative diagnosis of dementia was more likely. Morgan *et al.*²⁴ scanned 12 patients with frontotemporal dementia (many of whom had extrapyramidal signs) using ^{123}I -FP-CIT

Table 4 Change in clinician's confidence of diagnosis by group and scan result^a

	Baseline to week 8		Baseline to week 24	
	<i>n</i>	Mean (s.d.)	<i>n</i>	Mean (s.d.)
Control group	56	1.7 (11.64) ^b	55	7.2 (18.03) ^b
Imaging group	114	17.5 (31.69)	109	21.2 (30.40)
Abnormal scan	49	28.3 (20.90) ^c	47	28.8 (20.48) ^c
Normal scan	65	9.3 (35.88)	62	15.5 (35.25)

a. In both models covariate was baseline value of confidence of dementia diagnosis.
b. Control v. imaging: baseline to week 8 - $F=32.27$ ($P<0.0001$), baseline to week 24 - $F=29.92$ ($P<0.0001$).
c. Abnormal v. normal: baseline to week 8 - $F=42.39$ ($P<0.0001$), baseline to week 24 - $F=31.44$ ($P<0.0001$).

Table 5 Participants with mismatch between ^{123}I -ioflupane injection (^{123}I -FP-CIT) and diagnosis

Participant	Age, gender	DLB core and suggestive features at baseline	Supportive DLB features at baseline	^{123}I -FP-CIT imaging results	Diagnostic category at week 8	Diagnostic category at week 24	Change at week 24 v. baseline
004-0004	70, male	Fluctuations	Depression	Other abnormal pattern: left posterior putamen decrease	Non-DLB	Non-DLB	Change
018-0002	70, male	RBD	MTL	Other abnormal pattern: right basal ganglia normal. Left equivocal? Technical difficulty, but type 1 cannot be discounted. Lateral tilt	Non-DLB	Non-DLB	Change
022-0001	78, female	Fluctuations	None	Other abnormal pattern: near normal uptake on the left but loss of head of caudate uptake on right with a preserved putamen - ? Infarct	Possible DLB	Non-DLB	Change
001-0013	82, male	Fluctuations	Depression	Abnormal type 1	Possible DLB	Possible DLB	No change
013-0008	73, male	RBD	None	Other abnormal pattern: diffuse decrease in striatal uptake	Possible DLB	Possible DLB	No change
018-0009	79, male	Parkinsonism	MTL	Other abnormal pattern: very high background activity + artefact of movement	Probable DLB	Possible DLB	No change
019-0001	81, male	Fluctuations	MTL, falls and syncope	Other abnormal pattern: bilateral small vessel ischaemic change	Possible DLB	Possible DLB	No change
019-0011	82, male	Parkinsonism	None	Other abnormal pattern: crescent shape but not uniform uptake with irregular margins likely to be ischemic in origin	Possible DLB	Possible DLB	No change
019-0012	82, male	Parkinsonism	None	Abnormal type 1	Possible DLB	Possible DLB	No change

DLB, dementia with Lewy bodies; RBD, rapid eye movement sleep behaviour disorder; MTL, relative preservation of the medial temporal lobe.

SPECT and found that four had abnormal scans, showing that an abnormal scan does not exclude the diagnosis of frontotemporal dementia.

In the present study, a large proportion of patients with a normal scan retained a diagnosis of possible DLB. A possible explanation for this is that a few false-negative results have been reported in the literature in cases with autopsy diagnosis.^{6,25} At present, there is only one study that has followed-up patients with a clinical diagnosis of DLB and a negative ¹²³I-FP-CIT scan. It included only three participants and they all continued to have typical features of DLB²⁶ but no autopsies were available. Longitudinal studies including autopsy are needed to clarify the position of patients with normal striatal dopamine transporter ¹²³I-FP-CIT uptake in DLB.

Strengths and limitations

The strengths of this study include: the randomisation of a very large number of patients with possible DLB (the largest previous cohort described was 44 patients in O'Brien *et al*²); a prospective pan-European design involving a number of countries with a range of clinical centres (academic and non-academic); different specialties (psychiatrists and neurologists); a relatively small number of patients with Parkinsonian features in the imaging group (25%); and the exclusion of patients with vascular pathology through the use of MRI.

The main limitations of this study are the lack of neuropathological confirmation of diagnosis, the open-label design and the relatively short 6-month follow-up period. The emergence of new features may take longer than 6 months.² We noted slight differences in baseline measures for control and imaging groups, however, none of these differences were statistically significant. The study protocol stipulated that the consensus criteria for possible DLB had to be met at enrolment into the study. However, at follow-up we did not stipulate any use of criteria, rather we left clinicians to make diagnoses according to their usual clinical practice. Therefore it was permissible for a patient with rapid eye movement sleep behaviour disorder and an abnormal ¹²³I-FP-CIT scan to receive a diagnosis of probable DLB. This does not strictly follow the consensus criteria as two suggestive features are not sufficient for a diagnosis of probable DLB. In this study we did not record if more certain clinical diagnosis and increased physician's confidence led to a change in clinical management and this is something that should be studied in the future. We did not use a consensus clinical panel diagnosis, which would provide a more accurate diagnosis. Although this could be seen as a limitation, it is also a strength, as this reflects real-life practice, where diagnosis is made by one onsite clinician.

The main technical limitation was that different centres used different reconstruction methods for the SPECT images, and centres had varying levels of experience with DLB. Scans were read locally by nuclear medicine physicians with variable expertise. It is possible that centralised reading of the images by masked raters would have carried more weight with clinicians. The raters were masked to MRI so they could not take minor vascular pathology into account when reporting the scans. In a small number of difficult to interpret images, it is possible that a quantitative data analysis of striatal uptake adjusted for age would be more informative.

Implications

¹²³I-FP-CIT SPECT imaging significantly contributed to a change in diagnostic category and improved diagnostic confidence in the diagnostic work-up of patients with an uncertain diagnosis of

DLB. Changes in diagnostic category were less frequent in the control group despite a 6-month prospective follow-up. ¹²³I-FP-CIT was shown to be safe and well tolerated. This study further underlines the recommendation of the UK National Institute for Health and Care Excellence,²⁷ which is to use ¹²³I-FP-CIT SPECT scanning to support a diagnosis of DLB in uncertain cases.

Zuzana Walker, MD, FRCPsych, Division of Psychiatry, University College London, London, and North Essex Partnership University NHS Foundation Trust, Essex, UK; **Emilio Moreno**, MD, PhD, GE Healthcare, Amersham, UK; **Alan Thomas**, PhD, FRCPsych, Biological Research Building, Newcastle University, Newcastle, UK; **Fraser Inglis**, FRCP, Glasgow Memory Clinic, Glasgow, UK; **Naji Tabet**, MD, MRCPsych, Postgraduate Medicine, Brighton and Sussex Medical School, Brighton, UK; **Michael Rainer**, MD, Karl Landsteiner Institut für Gedächtnis- und Alzheimerforschung, Vienna, Austria; **Gilberto Pizzolato** (deceased), MD, previously at Department of Medicine, Surgery and Health Sciences, University of Trieste, Trieste, Italy; **Alessandro Padovani**, MD, PhD, Scienze Cliniche e Sperimentali, University of Brescia, Brescia, Italy

Correspondence: Zuzana Walker, Mental Health Unit, St Margaret's Hospital, The Plain, Epping, Essex, CM16 6TN, UK. Email: z.walker@ucl.ac.uk

First received 21 Mar 2014, final revision 2 Jul 2014, accepted 1 Aug 2014

Funding

Funded by GE Healthcare. The study was designed by the chief investigator (Z.W.) together with GE Healthcare. In addition to providing funding, GE Healthcare was responsible itself or under third-party agreement for monitoring, data collection and statistical analysis under the supervision of the chief investigator. All data were available to the Z.W. and all the other authors.

Acknowledgements

We would like to thank all of the patients and carers for participating in this study. We would like to thank Tim Whitfield (research assistant at North Essex Partnership University NHS Foundation Trust) for support during the preparation of this manuscript. We would also like to thank all the support staff at the local nuclear medicine departments for their help.

The DaTSCAN DLB Phase 4 Study Group were as follows. Michael Rainer, Thomas Leitha – Vienna, Austria. Gerhard Ransmayr, Michael Gabriel – Linz, Austria. Florence Pasquier, Frank Semah – Lille, France. Giovanni Castelnovo, Laurent Collombier – Nîmes, France. Reinhard Ehret, Uwe Stabell – Berlin, Germany. Adrian Daneek, Christian La Fougere – Munich, Germany. Gilberto Pizzolato, Franca Dore – Trieste, Italy. Alessandro Padovani, Barbara Paghera – Brescia, Italy. Ubaldo Bonucelli, Roberto Ceravolo, Duccio Volterrani – Pisa, Italy. Albert Lladó, Francisco Lomeña – Barcelona, Spain. Dolores Martinez Lozano, Daniel Flores – Castellon, Spain. Eulogio Gil Neciga, David Garcia Solis – Sevilla, Spain. Guillermo Amer Ferrer, Jaume Daumal – Palma de Mallorca, Spain. Maria Jose Moreno Carretero, Andres Serena – Vigo, Spain. Jenny McCleery, Gill Oliver – Banbury, UK. Naji Tabet, Lynn Jenkins, Sabina Dizdarevik – East Sussex, UK. Timothy Stevens, Christopher Barber, Zuzana Walker – Essex, UK. Alan Thomas, Kim Howe – Newcastle-upon-Tyne, UK. Fraser Inglis – Glasgow, UK. Derek Brown, Joanne Prosser – Glasgow, UK. Jay Chahal, Emilio Moreno – Amersham, UK. Shamsul Alan – Princeton, USA.

References

- McKeith IG, Dickson DW, Lowe J, Emre M, O'Brien JT, Feldman H, et al. Diagnosis and management of dementia with Lewy bodies – third report of the DLB consortium. *Neurology* 2005; **65**: 1863–72.
- O'Brien JT, McKeith IG, Walker Z, Tatsch K, Booij J, Darcourt J, et al. Diagnostic accuracy of I-123-FP-CIT SPECT in possible dementia with Lewy bodies. *Br J Psychiatry* 2009; **194**: 34–9.
- Litvan I, Bhatia KP, Burn DJ, Goetz CG, Lang AE, McKeith I, et al. SIC Task force appraisal of clinical diagnostic criteria for Parkinsonian disorders. *Mov Disord* 2003; **18**: 467–86.
- Nelson PT, Jicha GA, Kryscio RJ, Abner EL, Schmitt FA, Cooper G, et al. Low sensitivity in clinical diagnoses of dementia with Lewy bodies. *J Neurology* 2010; **257**: 359–66.
- Piggott MA, Marshall EF, Thomas N, Lloyd S, Court JA, Jaros E, et al. Striatal dopaminergic markers in dementia with Lewy bodies, Alzheimer's and Parkinson's diseases: rostrocaudal distribution. *Brain* 1999; **122**: 1449–68.
- Walker RWH, Walker Z. Dopamine transporter single photon emission computerized tomography in the diagnosis of dementia with Lewy bodies. *Mov Disord* 2009; **24**: S754–S759.
- Walker Z, Jaros E, Walker RWH, Lee L, Costa DC, Livingston G, et al. Dementia with Lewy bodies: a comparison of clinical diagnosis, FP-CIT single photon emission computed tomography imaging and autopsy. *J Neurol Neurosurg Psychiatry* 2007; **78**: 1176–81.

- 8 McKeith I, O'Brien J, Walker Z, Tatsch K, Boonij J, Darcourt J, et al. Sensitivity and specificity of dopamine transporter imaging with (123)I-FP-CIT SPECT in dementia with Lewy bodies: a phase III, multicentre study. *Lancet Neurology* 2007; **6**: 305–13.
- 9 Boot BP, McDade EM, McGinnis SM, Boeve BF. Treatment of dementia with Lewy bodies. *Curr Treat Options Neurol* 2013; **15**: 738–64.
- 10 Ballard C, Grace J, McKeith I, Holmes C. Neuroleptic sensitivity in dementia with Lewy bodies and Alzheimer's disease. *Lancet* 1998; **351**: 1032–3.
- 11 Pakrasi S, Mukaetova-Ladinska EB, McKeith IG, O'Brien JT. Clinical predictors of response to acetyl cholinesterase inhibitors: experience from routine clinical use in Newcastle. *Int J Geriatr Psychiatry* 2003; **18**: 879–86.
- 12 Matsunaga S, Kishi T, Iwata N. Memantine for Lewy body disorders: systematic review and meta-analysis. *Am J Geriatr Psychiatry* 2013 Dec 4 (Epub ahead of print).
- 13 Walker Z, McKeith I, Rodda J, Qassem T, Tatsch K, Boonij J, et al. Comparison of cognitive decline between dementia with Lewy bodies and Alzheimer's disease: a cohort study. *BMJ Open* 2012; **2**: e000380.
- 14 Bostrom F, Jonsson L, Minthon L, Londos E. Patients with Lewy body dementia use more resources than those with Alzheimer's disease. *Int J Geriatr Psychiatry* 2007; **22**: 713–9.
- 15 Bostrom F, Jonsson L, Minthon L, Londos E. Patients with dementia with Lewy bodies have more impaired quality of life than patients with Alzheimer disease. *Alzheimer Dis Assoc Disord* 2007; **21**: 150–4.
- 16 Folstein MF, Folstein SE, Mchugh PR. Mini-Mental State - practical method for grading cognitive state of patients for clinician. *J Psychiatric Res* 1975; **12**: 189–98.
- 17 Fahn S. *Unified Parkinson's Disease Rating Scale. Recent Developments in Parkinson's Disease*: 153–63. McMillan, 1987.
- 18 Mioshi E, Dawson K, Mitchell J, Arnold R, Hodges JR. The Addenbrooke's Cognitive Examination Revised (ACE-R): a brief cognitive test battery for dementia screening. *Int J Geriatr Psychiatry* 2006; **21**: 1078–85.
- 19 Cummings JL, Mega M, Gray K, Rosenbergthompson S, Carusi DA, Gornbein J. The Neuropsychiatric Inventory – comprehensive assessment of psychopathology in dementia. *Neurology* 1994; **44**: 2308–14.
- 20 Walker MP, Ayre GA, Cummings JL, Wesnes K, McKeith IG, O'Brien JT, et al. The Clinician Assessment of Fluctuation and the One Day Fluctuation Assessment Scale. Two methods to assess fluctuating confusion in dementia. *Br J Psychiatry* 2000; **177**: 252–6.
- 21 Sheikh JJ, Yesavage JA. *Geriatric Depression Scale (GDS): Recent Evidence and Development of a Shorter Version. Clinical Gerontology: A Guide to Assessment and Intervention*: 165–73. The Haworth Press, 1986.
- 22 Filippi L, Manni C, Pierantozzi M, Brusa L, Danieli R, Stanzione P, et al. 123I-FP-CIT semi-quantitative SPECT detects preclinical bilateral dopaminergic deficit in early Parkinson's disease with unilateral symptoms. *Nucl Med Commun* 2005; **26**: 421–6.
- 23 Kemp PM, Clyde K, Holmes C. Impact of I-123-Fp-Cit (Datscan) Spect on the diagnosis and management of patients with dementia with Lewy bodies: a retrospective study. *Nucl Med Commun* 2011; **32**: 298–302.
- 24 Morgan S, Kemp P, Boonij J, Costa DC, Padayachee S, Lee L, et al. Differentiation of frontotemporal dementia from dementia with Lewy bodies using FP-CIT SPECT. *J Neurol Neurosurg Psychiatry* 2012; **83**: 1063–70.
- 25 Colloby SJ, McParland S, O'Brien JT, Attems J. Neuropathological correlates of dopaminergic imaging in Alzheimer's disease and Lewy body dementias. *Brain* 2012; **135**: 2798–808.
- 26 Siepel FJ, Rongve A, Buter TC, Beyer MK, Ballard CG, Boonij J, et al. (123I)FP-CIT SPECT in suspected dementia with Lewy bodies: a longitudinal case study. *BMJ Open* 2013; **3**: e002642.
- 27 National Institute for Health and Care Excellence. *Supporting People with Dementia and their Carers in Health and Social Care. NICE Clinical Guideline 42*. National Institute for Health and Care Excellence, 2006.

