

## Clinically significant neurovascular variations in the axilla and the arm — a case report

Published online 23 May, 2007 © <http://www.neuroanatomy.org>

Bincy M. GEORGE<sup>(1)</sup> ✦  
 Sathesha NAYAK<sup>(1)</sup>  
 Pramod KUMAR<sup>(2)</sup>

Department of Anatomy, Melaka Manipal Medical College (Manipal Campus)  
 International Centre for Health Sciences (1), Department of Plastic Surgery, Kasturba  
 Medical College, Manipal (2), Madhav Nagar, Manipal, Karnataka State, INDIA.



✦ Bincy M. George,  
 Lecturer,  
 Department of Anatomy, Melaka Manipal Medical  
 College (Manipal Campus), International Centre for  
 Health Sciences, Madhav Nagar, Manipal, Udipi  
 District, Karnataka State, 576104, INDIA.  
 ☎ +91-820 2822641  
 📠 +91-988 6104682  
 ✉ [binicyrajakumary@yahoo.com](mailto:binicyrajakumary@yahoo.com)

Received 12 September 2006; accepted 17 April 2007

### ABSTRACT

Knowledge of neurovascular variations is important for surgeons who remove axillary lymph nodes, to anesthesiologists, and orthopedic surgeons. We found surgically important variations of axillary artery, axillary vein, median, radial and musculocutaneous nerves in the right upper limb of a male cadaver.

The axillary artery gave a large abnormal arterial trunk which in turn divided into a common circumflex humeral-subscapular trunk and profunda brachii artery. The abnormal trunk was sandwiched between the two roots of median nerve at its origin. There was an abnormal communicating branch between medial cord and radial nerve. The axillary vein was duplicated in most of its course and was abnormally large in size. In the arm, the musculocutaneous nerve gave three communicating branches to the median nerve.

The abnormality reported here might result in neurovascular compression symptoms in the upper limb and might cause confusions in anesthesia and surgery. *Neuroanatomy; 2007; 6: 36–38.*

**Key words** [median nerve] [axillary artery] [axillary vein] [axilla] [musculocutaneous nerve]

### Introduction

The axillary artery is the continuation of the subclavian artery beyond the outer border of the first rib. The artery is divided into three parts by the pectoralis minor muscle. The first part of the artery gives superior thoracic artery. The second part of the artery gives lateral thoracic and thoracoacromial branches. The third part gives subscapular, anterior circumflex and posterior circumflex humeral arteries.

The axillary vein is the continuation of the basilic vein at the lower border of the teres major muscle. It continues as the subclavian vein at the outer border of the first rib.

The median nerve is usually formed just lateral to the third part of the axillary artery by the union of its medial and lateral roots coming from medial and lateral cords of the brachial plexus respectively. It then descends down in the front of the arm and crosses the brachial artery from lateral to medial side. It enters the cubital fossa along with the brachial artery.

Radial nerve is the largest branch of the posterior cord of the brachial plexus. It lies posterior to the axillary artery initially, and then runs downwards and laterally to enter the posterior compartment of the arm by passing through the lower triangular space, with the profunda brachii artery. The profunda brachii artery is normally a branch of the brachial artery.

The musculocutaneous nerve is a branch of the lateral cord of the brachial plexus. It pierces the coracobrachialis

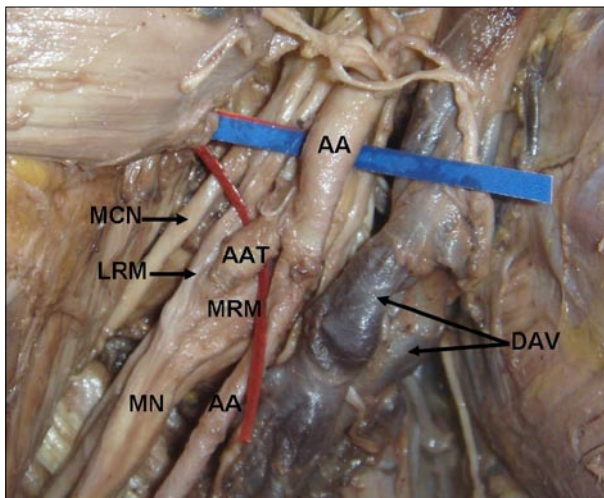
muscle and enters the front of the arm. It supplies the biceps, brachialis and coracobrachialis muscles.

We saw variations of axillary vessels, radial, median and musculocutaneous nerves in the right upper limb.

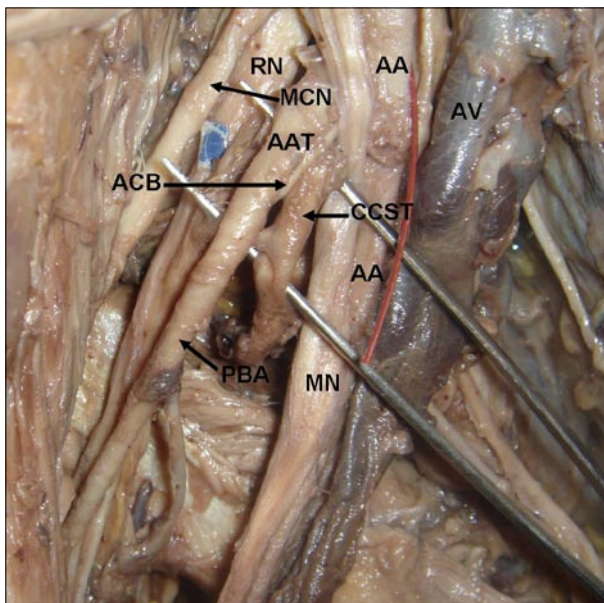
### Case Report

During the routine dissections for medical undergraduates, several variations were found in the anterior compartment of the arm of an approximately 50 year-old male cadaver. The variations found were unilateral. The axillary artery bifurcated into two almost equal sized trunks (Fig. 1). The superficial among the two continued as the brachial artery. The abnormal deep trunk bifurcated into a common circumflex humeral-subscapular trunk and a profunda brachii artery (Fig. 2). The common circumflex humeral-subscapular trunk further divided to give anterior and posterior circumflex humeral arteries and subscapular artery. The abnormal arterial trunk from axillary artery was sandwiched between the medial and lateral roots of the median nerve (Fig. 1). The medial root of median nerve passed laterally, deep to the axillary artery. There was an abnormal communicating branch between medial cord of the brachial plexus and radial nerves in the axilla. This branch arose from medial cord, passed backwards, hooking around the bifurcation of common circumflex humeral-subscapular trunk and joined the radial nerve (Fig. 2).

The axillary vein was abnormally large and was duplicated in major part of its course. However the



**Figure 1.** Dissection of the right axilla, showing the abnormal branching of the axillary artery; abnormal formation of median nerve; and double axillary veins. Color version of figure is available online. (AA: axillary artery; MRM: medial root of median nerve; LRM: lateral root of median nerve; MN: median nerve; DAV: double axillary vein; MCN: musculocutaneous nerve; AAT: abnormal arterial trunk)



**Figure 2.** Dissection of the right axilla showing the abnormal communication between median and radial nerves, and branches of abnormal trunk from axillary artery. The axillary vessels and median nerves have been reflected medially. Color version of figure is available online. (AA: axillary artery; AV: axillary vein; MN: median nerve; RN: radial nerve; AAT: abnormal arterial trunk; MCN: musculocutaneous nerve; ACB: abnormal communicating branch between medial cord and radial nerve; CCST: common circumflex humeral - subscapular trunk; PBA: profunda brachii artery)

two veins joined to form a single axillary vein near its termination (Fig. 1).

In the arm, the musculocutaneous nerve gave three communicating branches to the median nerve, two of which passed anterior to the brachial artery and one

passed posterior to the brachial artery before joining the median nerve (Fig. 3).

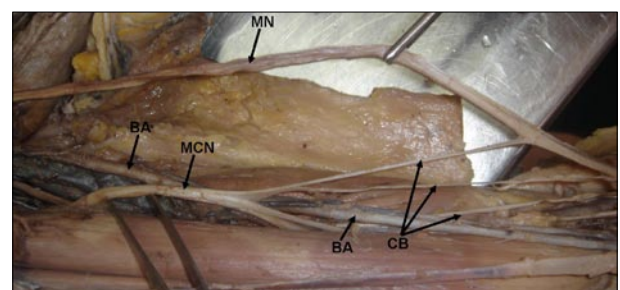
### Discussion

Variations in the branching pattern of the axillary artery are very common. Any of the branches of subclavian or brachial may arise from axillary artery and axillary artery may have variable relations with the branches of brachial plexus. It may give rise to a common trunk from which may arise the subscapular, anterior and posterior circumflex humeral, profunda brachii, and ulnar collateral arteries [1]. The abnormal arterial trunk which we report here has been reported earlier but its relation to the median nerve is quite interesting. In our case, the medial root of the median nerve passed deep to the main continuation of the axillary artery, where it might get compressed leading to nerve compression symptoms. The two roots of median nerve strangulated the abnormal arterial trunk, which in turn might result in lowering of blood flow through the branches of this abnormal trunk. The abnormal branch connecting the medial cord with the radial nerve in the axilla looped around the bifurcation of the abnormal arterial trunk. This is another fact that might result in decreased blood flow in the branches of this trunk.

The variations of axillary vein also have been reported in the past. Penetration of the axillary vein by medial cutaneous nerve of the forearm has been reported by Roy and Sharma [2]. Kutiyanawala et al [3], have reported a double axillary vein and muscular slips crossing axillary vein in the axilla. The knowledge of axillary vein variations may be useful in axillary surgery and brachial plexus anesthesia.

Variations in the formation of the median nerve have been noted. Such variations include formation of median nerve by four roots, one from medial cord and other three from the lateral cord [4]. Variations such as passing through a bony canal [5] and abnormal communications with the musculocutaneous nerve have been recorded [6,7].

The reported variations of the musculocutaneous nerve include its total absence [8] and communications with the median nerve at various levels [6, 7]. The musculocutaneous nerve, not piercing the coracobrachialis is also known [9].



**Figure 3.** Dissection of the arm showing the three communicating branches between median and musculocutaneous nerves. Color version of figure is available online. (BA: brachial artery; MN: median nerve; MCN: musculocutaneous nerve; CB: communicating branches)

The variations we are reporting may be of special interest for the anesthesiologist doing nerve block anesthesia and surgeons clearing the axillary lymph nodes in breast cancer patients. The abnormal formation of the median nerve might compress the large abnormal arterial trunk. This might result in vascular symptoms in the axillary region.

The abnormal communicating branch between medial cord and radial nerve has not been reported hitherto. This communicating branch might compress the artery against which it is looping or the artery might compress this communicating branch. This in turn might lead to

pain or numbness in the area supplied by the nerve fibres or lead to vascular symptoms.

The enlarged axillary vein might put pressure on the axillary artery or the branches of the brachial plexus or even can get damaged during surgery of the axilla.

The three communication branches between musculocutaneous and median, though not unique, it is good to know about them. This knowledge is useful in traumatology and orthopedic procedures. Since one of the communicating branches is passing deep to the brachial artery, that branch might get compressed by brachial artery. This may result in nervous symptoms in the distal part of the limb.

## References

- [1] Bergman RA, Thompson SA, Afifi AK, Saadeh FA. *Compendium of human anatomic variations*. Urban and Schwarzenberg, Baltimore-Munich. 1988; p 70–73.
- [2] Roy TS, Sharma S. Axillary vein perforation by the medial cutaneous nerve of the forearm. *Clin. Anat.* 2004; 17: 300–302.
- [3] Kutyanawala MA, Stotter A, Windle R. Anatomical variants during axillary dissection. *Br. J. Surg.* 1998; 85: 393–394.
- [4] Uzun A, Seelig LL Jr. A variation in the formation of the median nerve: communicating branch between the musculocutaneous and median nerves in man. *Folia Morphol. (Warsz)*. 2001; 60: 99–101.
- [5] Kazuki K, Egi T, Okada M, Takaoka K. Anatomic variation - a bony canal for the median nerve at the distal humerus: a case report. *J. Hand Surg. [Am]*. 2004; 29: 953–956.
- [6] Loukas M, Aqueelah H. Musculocutaneous and median nerve connections within, proximal and distal to the coracobrachialis muscle. *Folia Morphol. (Warsz)*. 2005; 64: 101–108.
- [7] Prasada Rao PV, Chaudhary SC. Communication of the musculocutaneous nerve with the median nerve. *East Afr. Med. J.* 2000; 77: 498–503.
- [8] Gumushurun E, Adiguzel E. A variation of the brachial plexus characterized by the absence of the musculocutaneous nerve: a case report. *Surg. Radiol. Anat.* 2000; 22: 63–65.
- [9] Nakatani T, Mizukami S, Tanaka S. Three cases of the musculocutaneous nerve not perforating the coracobrachialis muscle. *Kaihogaku Zasshi*. 1997; 72: 191–194.