

Clinicopathological study of jaw cysts in southeast region of Turkey

Mehmet Demirkol¹, Bilal Ege¹, Saim Yanik¹, M. Hamdi Aras¹, Sinan Ay²

Correspondence: Dr. Mehmet Demirkol,
Email: drmehmetdemirkol@hotmail.com

¹Department of Oral and Maxillofacial Surgery, Faculty of Dentistry, Gaziantep University, Gaziantep, Turkiye,
²Department of Oral and Maxillofacial Surgery, Faculty of Dentistry, Osmangazi University, Eskisehir, Turkiye

ABSTRACT

Objective: The purpose of this retrospective study was to analyze clinic and radiologic features and the prevalence of jaw cysts in southeast region of Turkey. **Materials and Methods:** This study was carried out in 149 cysts of the jaw diagnosed among 407 individuals who were taken biopsy in our department from October 2008 to December 2012. All cysts were treated by enucleation, marsupialization, or combination, and all cases were histologically examined. **Results:** One-hundred-and-forty-eight cases were classified odontogenic, one was non-odontogenic. There were 89 cysts (59.7%) in men, 60 (40.3%) in women. The mean age was 32.72 years. We found 80 cysts (35 F, 45 M) in the maxillary and 69 (28 F, 41 M) in mandible. It is observed that 94 were radicular cysts (63%), 40 were dentigerous cysts (26.9%), 9 were odontogenic keratocysts (OKC) (6.1%), 5 were residual radicular cysts (3.4%), and 1 was nasopalatine cyst (0.6%). In radicular cysts, 56 of them (59.5%) were located in the anterior region of the jaws; 18 dentigerous cysts and 2 OKCs were found in the posterior region of mandible. Clinically, the chief complaint of patients was expansion and pain. Radiographically, scalloping of the lesion between the teeth was found in 1 case, root resorption was seen in 3 cases, and displacement of the teeth and follicles was observed in 16 cases. **Conclusions:** We found similar prevalence of jaw cysts that reported in the literature, in which most odontogenic cysts (OCs) were inflammatory origin.

Key words: Dentigerous cyst, epidemiology, jaw cysts, radicular cysts

INTRODUCTION

Jaw cysts are unique entities that those described by Kramer^[1] as a pathological cavity that includes fluid, semi-fluid, or gaseous substance. These are characterized by osteolytic lesions that develop odontogenic apparatus and its remnants that may be found within bone or in the gingival tissue covering the maxilla and mandible. It has been thought that cystic and degenerative proliferation in this epithelium have the potential to contribute to the development of odontogenic cyst (OC).^[1-3] According to most recent World Health Organization (WHO) International Classification, the epithelial-lined OCs are divided into two main groups that reflect their pathogenesis: Developmental and inflammatory origin.^[4] Developmental cysts are classified into an

odontogenic group, arising from odontogenic tissue (Malassez epithelial remnants, dental lamina, or enamel organ remnants) and a non-odontogenic group, arising from ectoderm involved in the developmental of the facial tissues. Inflammation process is induced inflammatory cysts, whereas developmental cysts are of unknown origin.^[5,6] Many studies^[4,7-11] in different regions of the world have been conducted on the prevalence of OCs. Some studies^[7,8] shown that mandible was most prevalent site, but other authors^[4,9,10] found that maxilla was most frequent site.

The objective of the study was to assess the prevalence of jaw cysts diagnosed in southeast region of Turkey, Gaziantep, according to age, gender, anatomic area, clinical and radiological features, and to compare results with current data.

How to cite this article: Demirkol M, Ege B, Yanik S, Aras MH, Ay S. Clinicopathological study of jaw cysts in southeast region of Turkey. *Eur J Dent* 2014;8:107-11.

Copyright © 2014 Dental Investigations Society.

DOI: 10.4103/1305-7456.126260

MATERIALS AND METHODS

This retrospective study is comprised the 149 cysts of the jaw diagnosed among 407 individuals who were taken biopsy in department of Oral and Maxillofacial Surgery, Gaziantep University of Dentistry, between October 2008 and December 2012. Histopathological examination was performed at the Department of Pathology. The clinicopathological information obtained from each patient record included age, gender, anatomic site, and clinical findings. Lesions were categorized in accordance with the WHO Histological Classification of Jaw Cysts in 1992.^[12] As defined by this classification, radicular, residual radicular, dentigerous, odontogenic keratocysts (OKC) were identified OCs, and nasopalatine was non-odontogenic (nOC) cyst. Diagnoses of lesions were made with microscopic features of cyst and together with clinic and radiographic findings.

Based on sites of jaw involvement, which had previously been established according to those reported by Sharifian and Khalili,^[13] we modified from this classification. The sites of involvement in mandibular lesions were sub-classified into four main areas as follows: Anterior (from canine to canine), pre-molars, 1st and 2nd molars, and 3rd molar/ramus area. For maxillary, lesions were sub-classified: Anterior (from canine to canine), pre-molars, molars, and molar region/included maxillary sinus. Another sub-category defined as "more than one area" (MOA) was evaluated for cases involving more than one region in each jaw. Data about demographic information (age and sex) were also collected; age was reported as decade of life, from the 1st to 8th decade or older. Clinical and radiographic findings are assessed such as root resorption, tooth displacement, expansion, and pain.

The WHO^[14] report that presents new classification for OC and tumors redefined the OKC as keratocyst odontogenic tumor in 2005. Thus, OKC was preferred to describe as an OC in present retrospective study for comparison with other published reports before this histological classification.^[6,15]

After collection of data, results were analyzed to calculate the prevalence of lesions and their association with the variables under study.

RESULTS

Throughout the study period, 407 biopsies were performed, 148 cases were diagnosed as cysts. Among

149 jaw cysts, 148 cases (99.4%) were diagnosed with OCs and 1 case (0.6%) was nOC. One patient had cyst in both jaw. Overall, jaw cysts were diagnosed more commonly in males 89 (59.7%), the ratio of male to female (M:F) was 1.4:1. The patients' mean age was 32.72 years at the time of diagnosis; ranging in age from 6 to 79 years. Table 1 shows distribution in terms of age and gender of jaw cysts. The maxillary bone was the most commonly affected, comprising 80 lesions (53.7%) of all cysts. Sixty-nine cases (46.3%) were found in the mandible. The case numbers according to diagnosis of jaw cysts were as follows; 94 were radicular cysts (63%), 40 were dentigerous cysts (26.9%), 9 were OKCs (6.1%), 5 were residual radicular cysts (3.4%), and 1 was nasopalatine cyst (0.6%), respectively.

Among 149 cases, 94 radicular cysts were observed with M:F ratio of 1:1.2. Patient age at the time of diagnosis ranged from 6 to 68 years, with an average age of 31.8 years. The lesion was predominantly seen in 3rd decade ($n = 29$). Figure 1 presents distribution of 94 radicular cysts in terms of age and gender in decades. The most frequent primary jaw of occurrence was the maxillary bone with 57 cases (60.6%); the most commonly affected of anterior site of jaws were accounted for 56 cases (59.5%). Prevalence of OC and nOC according to different jaw locations are shown in Table 2.

The second most occurrence lesion was dentigerous cyst with prevalence of 40 cases (26.9%). Age range was 7 to 66 years with a mean of 31.7 years. Most common occurrence was seen in the 3rd and 4th decades of life. Figure 2 shows distribution of 40 dentigerous cysts in terms of age and gender in decades. Mandible was the most affected anatomic site with 29 cases (72.5%); of these, 17 cases (58.6%) were located in the mandibular 3 molar/ramus area. Maxilla was affected in 11 cases (27.5%); the anterior region was the most frequent site, with 7 cases (17.5%). One patient had dentigerous cyst in both jaws.

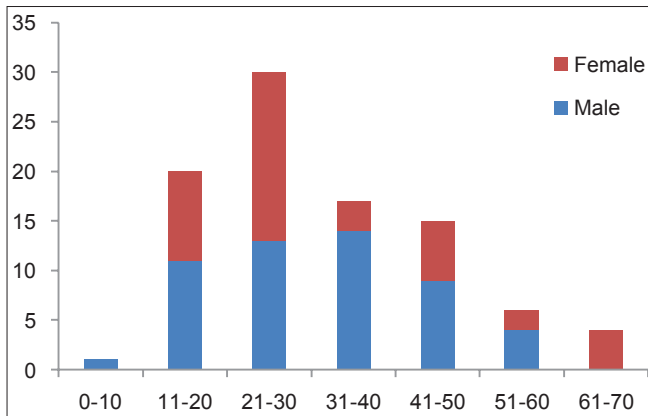
Table 1: Distribution of jaw cysts according to sex and age (n=149)

Type of cyst	Frequency n (%)	Female n (%)	Male n (%)	M/F ratio	Mean age (age-range)
Radicular	94 (63)	41 (27.5)	53 (35.5)	1.2	31.8 (6-68)
Dentigerous	40 (26.9)	15 (10.2)	25 (16.7)	1.6	31.7 (7-66)
Keratocyst	9 (6.1)	3 (2)	6 (4.1)	2	26 (9-52)
Residual radicular	5 (3.4)	1 (0.6)	4 (2.8)	4	60.2 (46-79)
Nasopalatine	1 (0.6)	-	1 (0.6)	-	61 (61)
Total	149 (100)	60 (40.3)	89 (59.7)	1.4	32.7 (6-79)

Table 2: Prevalence of OCs and nOCs according to different jaw locations

Location	Anterior n (%)		Pre-molars n (%)		First/second molars n (%)		Third molar/ramus n (%)		MOA n (%)	
	Mand	Max	Mand	Max	Mand	Max	Mand	Max	Mand	Max
Radicular	13 (8.8)	43 (28.9)	14 (9.6)	2 (1.3)	8 (5.4)	5 (3.4)	-	1 (0.6)	2 (1.3)	7 (4.7)
Dentigerous	1 (0.6)	7 (4.7)	8 (5.4)	-	1 (0.6)	1 (0.6)	17 (11.5)	2 (1.3)	2 (1.3)	1 (0.6)
Keratocyst	1 (0.6)	-	3 (1.9)	-	-	1 (0.6)	2 (1.3)	-	2 (1.3)	-
Residual	-	4 (2.5)	-	1 (0.6)	-	-	-	-	-	-
Nasopalatine	-	1 (0.6)	-	-	-	-	-	-	-	-
Total	15 (10)	54 (36.8)	25 (16.9)	3 (1.9)	9 (6.0)	7 (4.7)	19 (12.8)	3 (1.9)	6 (3.9)	8 (5.4)

Mand: Mandibular, Max: Maxilla, MOA: More than one area, OCs: Odontogenic cysts, nOCs: Non-odontogenic cysts

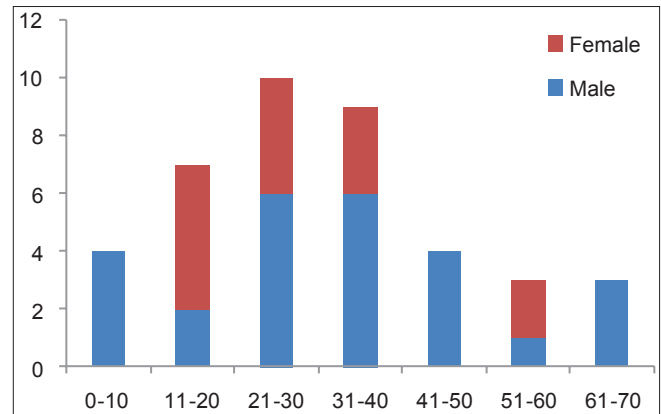
**Figure 1:** Distribution of 94 radicular cysts according to gender and age in decades

The third most common occurrence of lesion type was OKC with nine cases (6.1%); mean age was 26 years at the time of diagnosis (range, 9-52 years). According to age, the peak incidence was in 5th decade of life (three cases). The age and gender distribution of nine OKCs are shown in Figure 3. Three cases were located mandibular pre-molar region.

Five cases (3.4%) of residual radicular cysts were found. Four cases occurred in male, and one in female. All residual radicular cysts occurred in maxilla: One case in pre-molar, and four cases in the anterior region. Only one patient had nasopalatine cyst.

The developmental cysts, such as keratocyst and dentigerous cysts were mostly situated in the molar region of jaws. In addition to this, the upper anterior region was mostly affected by inflammatory cysts.

Most patients clinically presented with varying degree of expansion and pain in the lesion area. Radiographically, scalloping of the lesion between the teeth was found in one case, root resorption was seen in three cases, and displacement of the teeth and follicles was observed in sixteen cases. One-hundred-and-forty-nine lesions presented

**Figure 2:** Distribution of 40 dentigerous cysts according to gender and age in decades

well-defined; of these, two lesions were uni-locular and one-hundred-and-forty-seven were multi-locular.

Treatments of all patients were made by apical resection of non-vital tooth that previously performed endodontic treatment, removed of tooth or impacted tooth involved in the lesion, and all cysts were removed by enucleation or initial marsupialization and following enucleation with primarily closing of the wound.

DISCUSSION

This retrospective study evaluated the prevalence of jaw cysts in patients from the southeastern region of Turkey. From October 2008 to December 2012, among a total of 407 biopsy specimens, 149 jaw cysts were diagnosed, which constitutes 36% of whole sample. This finding of study was not consistent with other studies in different countries such as Brazil,^[12] England,^[2] Mexico,^[11] Italy,^[16] Chile,^[4] India,^[17] and USA,^[18] which found frequencies of 14.7%, 12.8%, 7.8%, 10.4%, 10%, 14.3%, and 19.4%, respectively. The reason why our findings are relatively higher than other current studies may be due to poor oral hygiene of the subjects and delayed treatment of the lesion until symptomatic. Thus, they are more

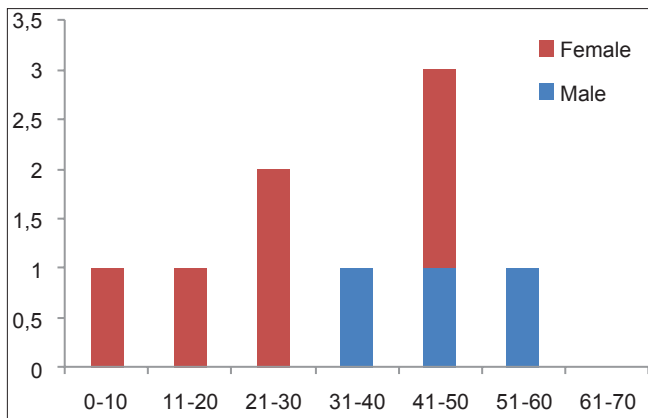


Figure 3: Distribution of nine odontogenic keratocysts according to gender and age in decades

likely to be subject to long-term chronic inflammatory processes, without the adequate resolutive endodontic treatment.^[4] The overall M: F was 1.4:1 in present study. This corresponds to the ratios obtained from studies in Turkey^[15] and Spain.^[16] The higher prevalence of male gender in some studies may be explained by the fact that men usually have poorer oral hygiene habits and are more susceptible to trauma of the maxillary anterior teeth than women.^[8,11] In the present data, the maxilla was the most common site of lesion involvement, in agreement with the report by Ochsenius *et al.*^[4] and by Tortorici *et al.*,^[16] but the mandible was found to be most affected jaw of lesion involvement, in which reported from Meningaud *et al.*^[8] and Koseoglu *et al.*^[7] studies.

The mean age at the time of cyst diagnosis was 32.72 years (range, 6-79 years). Our mean age is lower than those of the studies from France,^[8] Spain,^[5] Turkey,^[15] and Sicily.^[16] Of the 149 cases, 22 cysts (14.7%) were diagnosed in pediatric populations (range, 2-16 years) and 127 cysts (85.3%) were diagnosed in adult populations (range, 16-79 years). This is in contrast to a study done in the U.K.: 553 jaw cysts (7.8%) were diagnosed in children 16 years and under, and 6385 jaw cysts (89.6%) were diagnosed in adults 17 years and older.^[2]

In our study, the most common type of jaw cysts were radicular cysts (63%), dentigerous cysts (26.9%), and as a third OKCs (6.1%). This finding is consistent with Bataineh *et al.*^[10] from Jordan (41.7%, 24.8%, 6.0%), Nakamura *et al.*^[19] from Japan (41.2%, 27%, 7.7%), and Mosqueda-Taylor *et al.*^[3] from Mexico (39.9%, 33%, 21.5%). Overall, our findings suggest that in the southeastern region of Turkey, the population has a high risk of developing inflammatory cysts.

The radicular cyst is the most frequently diagnosed lesion, and they lead pulpal necrosis subsequently pulpitis; therefore, these lesions are considered to be of an inflammatory origin.^[4,20] In our study, its occurrence in the males was slightly greater than in the females among the patients who have radicular cysts, which is consistent with the findings of some studies,^[2,7,8] but differs from other studies that found female predominance.^[4,11] In another study, Duffo *et al.* stated that female predominance can be explained by the results of that the population seeking dental treatment is predominantly female.^[21] In the literature, this male predominance may be explained by the hypothesis that males usually have poorer oral hygiene habits and are more frequently exposed to trauma in the anterior maxilla.^[8] The peak occurrence of radicular cysts was in the 3rd and 4th decades of life, which parallels other studies findings.^[2,4,16] The present study also confirms previous reports that the anterior maxilla is the predominant area than any other jaw's sites.^[2,4,11] Aesthetic concerns in the upper anterior zone and low health awareness are probably cause of the delay in seeking treatment. Another pre-disposal factor is that patients may wish to preserve their anterior teeth even when endodontic treatment is inadequate.^[4] Therefore, long-term chronic inflammatory processes induce cystic degeneration in peri-apical tissues.^[6]

A dentigerous cyst is one that affects the crown of an unerupted tooth by expanding its follicle; this cyst is attached to the tooth's cervical area. Most studies^[2-4,8,11] report that dentigerous cysts are the second most prevalent OCs, which was confirmed in our study (representing 26.9% of the cysts in the sample, or 9.8% of all specimens). The male predominance was lower percentage to those reported in other series,^[4,8,11,16] and M: F ratio 1.66:1 was closely percentage that in the Tortorici *et al.*^[20] study (1.56:1). In this series, 20 patients (50%) were in the 3rd life-decade and 14 (35%) in the 4th decade. This finding seems to be higher in comparison to studies^[4,11,13] reporting a peak in the first two decades of life. Late detection of the dentigerous cysts in patients of the 3rd and 4th decades may be due to the slow asymptomatic growth tendency of the lesion or delayed medical care. The most affected sites of the jaws were 3rd molar/ ramus area (17 cases) in the mandible and anterior area (7 cases) in the maxilla, which is compatible with other findings reported studies.^[2,4,10] As stated in the relevant literature, impacted mandibular third molars and maxillary canine follicles are responsible for the formation of dentigerous cysts.^[12]

In our study, OKCs were the third most frequently diagnosed lesions, accounting for 6.1% of all OCs. It has been known that the residual cysts are occurred followed by insufficiently curettage of the cyst remnants after tooth extraction.^[6] In this present study, they comprised 3.4% of the entire cyst sample. Only one nasopalatine cyst (0.6%) was found in the records we analyzed. We felt the clinical and demographic findings of OKCs, residual radicular cysts, and nasopalatine cysts were not a sufficient enough percentage of the sample to compare with other reporting studies.^[4,13,15] Therefore, it is difficult to ascertain to which degree this percentage of the sample may have contributed to affect the incidence of jaw cysts in present study.

In this study, a first attempt has been made to present demographic data and clinical features of jaw cysts about southeast region of Turkey's population and to compare the results with the other reports. Based on findings, we found similar prevalence of jaw cysts that reported in the literature, in which most OCs were inflammatory origin. There is a need for large number of samples of jaw cysts in Turkish population to establish a detailed data of the characteristic behavior and clinicopathological features of these lesions.

REFERENCES

- Kramer IR. Changing views on oral disease. *Proc R Soc Med* 1974;67:271-6.
- Jones AV, Craig GT, Franklin CD. Range and demographics of odontogenic cysts diagnosed in a UK population over a 30-year period. *J Oral Pathol Med* 2006;35:500-7.
- Mosqueda-Taylor A, Irigoyen-Camacho ME, Diaz-Franco MA, Torres-Tejero MA. Odontogenic cysts. Analysis of 856 cases. *Med Oral* 2002;7:89-96.
- Ochsenius G, Escobar E, Godoy L, Penafiel C. Odontogenic cysts: Analysis of 2,944 cases in Chile. *Med Oral Patol Oral Cir Bucal* 2007;12:E85-91.
- Núñez-Urrutia S, Figueiredo R, Gay-Escoda C. Retrospective clinicopathological study of 418 odontogenic cysts. *Med Oral Patol Oral Cir Bucal* 2010;15:e767-73.
- Prockt AP, Schebela CR, Maito FD, Sant'Ana-Filho M, Rados PV. Odontogenic cysts: Analysis of 680 cases in Brazil. *Head Neck Pathol* 2008;2:150-6.
- Koseoglu BG, Atalay B, Erdem MA. Odontogenic cysts: A clinical study of 90 cases. *J Oral Sci* 2004;46:253-7.
- Meningaud JP, Oprean N, Pitak-Arnop P, Bertrand JC. Odontogenic cysts: A clinical study of 695 cases. *J Oral Sci* 2006;48:59-62.
- Varinauskas V, Gervickas A, Kavoliūniene O. Analysis of odontogenic cysts of the jaws. *Medicina (Kaunas)* 2006;42:201-7.
- Bataineh AB, Rawashdeh MA, Al Qudah MA. The prevalence of inflammatory and developmental odontogenic cysts in a Jordanian population: A clinicopathologic study. *Quintessence Int* 2004;35:815-9.
- Ledesma-Montes C, Hernández-Guerrero JC, Garcés-Ortiz M. Clinico-pathologic study of odontogenic cysts in a Mexican sample population. *Arch Med Res* 2000;31:373-6.
- Kramer IR, Pindborg JJ, Shear M. *Histological Typing of Odontogenic Tumors*. 2nd ed. Geneva, Switzerland: World Health Organization; 1992.
- Sharifian MJ, Khalili M. Odontogenic cysts: A retrospective study of 1227 cases in an Iranian population from 1987 to 2007. *J Oral Sci* 2011;53:361-7.
- Philipsen HP. Keratocystic odontogenic tumour. In: Barnes L, Eveson JW, Reichart P, Sidransky D, editors. *World Health Organization Classification of Tumours. Pathology and Genetics of Head and Neck Tumours*. Lyon, France: IARC Press; 2005. p. 306-7.
- Tekkesin MS, Olgac V, Aksakalli N, Alatlı C. Odontogenic and nonodontogenic cysts in İstanbul: Analysis of 5088 cases. *Head Neck* 2012;34:852-5.
- Das SN, Brave VR, Shetty RP. A survey of 4478 biopsy specimens of oral lesions. *J Pierre Fauchard Acad* 1994;8:143-7.
- Bhaskar SN. Oral pathology in the dental office: Survey of 20,575 biopsy specimens. *J Am Dent Assoc* 1968;76:761-6.
- Grossmann SM, Machado VC, Xavier GM, Moura MD, Gomez RS, Aguiar MC *et al.* Demographic profile of odontogenic and selected nonodontogenic cysts in a Brazilian population. *Oral Surg Oral Med Oral Pathol Oral Radiol Endod* 2007;104:e35-41.
- Nakamura T, Ishida J, Nakano Y, Ishii T, Fukumoto M, Izumi H, *et al.* A study of cysts in the oral region. Cysts of the jaw. *J Nihon Univ Sch Dent* 1995;37:33-40.
- Tortorici S, Amodio E, Massenti MF, Buzzanca ML, Burruano F, Vitale F. Prevalence and distribution of odontogenic cysts in Sicily: 1986-2005. *J Oral Sci* 2008;50:15-8.
- Dufoo S, Maupome G, Diez-de-Bonilla J, Hernandez-Guerrero JC. Caries experience in a selected patient population in Mexico City. *Community Dent Oral Epidemiol* 1996;24:298-9.

Access this article online

Quick Response Code:



Website:
www.eurjdent.com

Source of Support: Nil.
Conflict of Interest: None declared