

UCLA

UCLA Previously Published Works

Title

Clinicopathological Study of Patients With C9ORF72-Associated Frontotemporal Dementia Presenting With Delusions.

Permalink

<https://escholarship.org/uc/item/36c45706>

Journal

Journal of geriatric psychiatry and neurology, 28(2)

ISSN

0891-9887

Authors

Shinagawa, Shunichiro
Naasan, Georges
Karydas, Anna M
[et al.](#)

Publication Date

2015-06-01

DOI

10.1177/0891988714554710

Peer reviewed

Journal of Geriatric Psychiatry and Neurology

Clinico-pathological study of patients with C9ORF72 associated frontotemporal dementia presenting with delusions

Journal:	<i>Journal of Geriatric Psychiatry and Neurology</i>
Manuscript ID:	JGPN-14-0039.R1
Manuscript Type:	Research Investigations
Date Submitted by the Author:	30-May-2014
Complete List of Authors:	Shinagawa, Shunichiro; Jikei University School of Medicine, Psychiatry; University of California, San Francisco, Memory and Aging Center, Department of Neurology Naasan, Georges; University of California, San Francisco, Memory and Aging Center, Department of Neurology Karydas, Anna; University of California, San Francisco, Memory and Aging Center, Department of Neurology Coppola, Giovanni Coppola; University of California, Los Angeles, Department of Pathology Pribadi, Mochtar; University of California, Los Angeles, Department of Pathology Seeley, William; University of California, San Francisco, Department of Pathology; University of California, San Francisco, Memory and Aging Center, Department of Neurology Trajanowski, John; University of Pennsylvania Perelman School of Medicine, Center for Neurodegenerative Disease Research Miller, Bruce; University of California, San Francisco, Memory and Aging Center, Department of Neurology Girenberg, Lea; University of California, San Francisco, Memory and Aging Center, Department of Neurology; University of California, San Francisco, Department of Pathology
Keywords:	Delusions, neurodegeneration, Neuroimaging, Neuropathology, Frontotemporal dementia, C9ORF72

SCHOLARONE™
Manuscripts

Clinico-pathological study of patients with *C9ORF72* associated
frontotemporal dementia presenting with delusions

Shunichiro Shinagawa MD 1)2)

Georges Naasan MD 1)

Anna M. Karydas PhD 1)

Giovanni Coppola MD 3)

Mochtar Pribadi PhD 3)

William W. Seeley MD 1)4)

John Q. Trojanowski, MD, PhD 5)

Bruce L. Miller MD 1)

Lea T. Grinberg MD, PhD 1)4)

- 1) Memory and Aging Center, Department of Neurology, University of California, San Francisco, California, USA
- 2) Department of Psychiatry, The Jikei University School of Medicine, Tokyo, Japan
- 3) Departments of Psychiatry and Neurology, University of California, Los Angeles, California, USA
- 4) Department of Pathology, University of California, San Francisco, USA
- 5) Center for Neurodegenerative Disease Research, University of Pennsylvania Perelman School of Medicine, Pennsylvania, USA

1
2
3
4
5
6
7 Word count (main body): 4690
8

9 Number of references: 61
10

11 Tables: 1
12

13 Figures: 1
14

15 Word count (abstract): 181
16

17 Correspondence: Lea T Grinberg
18

19 Memory and Aging Center, UCSF Department of Neurology
20

21 675 Nelson Rising Lane, Suite 190, San Francisco, CA 94158
22

23 Phone: 415-502-7229
24

25 Fax: 415-476-7963
26

27 Email: lea.grinberg@ucsf.edu
28
29
30
31
32
33
34
35
36
37
38
39
40
41
42
43
44
45
46
47
48
49
50
51
52
53
54
55
56
57
58
59
60

Abstract

Background: Several clinical studies point to a high prevalence of psychotic symptoms in frontotemporal dementia (FTD) associated with *C9ORF72* mutations, but clinico-pathological studies addressing the association between *C9ORF72* mutations and delusions are lacking.

Method: Seventeen pathologically proven frontotemporal lobar degeneration subjects associated with *C9ORF72* mutations were identified from Neurodegenerative Disease Brain Bank. Four of 17 *C9ORF72* mutation cases exhibited well-defined delusions. The clinical history, neurological examination, neuropsychological testing, neuroimaging analysis, and postmortem assessment of the patients with delusions were evaluated and compared with the other cases.

Result: The content of the delusions was mixed including persecution, infidelity, and grandiosity. All cases showed Parkinsonism, voxel-based morphometry analysis showed greater precuneus atrophy in patients with delusions than those without delusions. All four had unclassifiable FTLD-TDP, with characteristics of both type A and type B. Three cases had additional tau pathology and another had α -synuclein pathology.

Conclusion: *C9ORF72* carriers with well-defined delusions likely associated with additional pathologies and parietal atrophy in neuroimaging. Patients presenting with middle age onset of delusions should be screened for *C9ORF72* mutations, especially if family history and Parkinsonism are present.

Keywords:

C9ORF72; neurodegeneration; frontotemporal dementia; delusion;
neuropathology; neuroimaging

Running Head:

Delusions in *C9ORF72* associated FTD

For Peer Review

1 Background

2 Frontotemporal dementia (FTD) is the second most common cause of early
3 onset dementia and is characterized by changes in personality, behavior or
4 language ^{1,2}. FTD is associated with neurodegeneration of the frontal and
5 temporal lobes and occurs in both sporadic and genetic forms. A hexanucleotide
6 repeat expansion in chromosome 9 open reading frame 72 (*C9ORF72*) was
7 recently reported as the most frequent genetic cause of behavioral variant FTD
8 (bvFTD), FTD with motor neuron disease (FTD-MND) and amyotrophic lateral
9 sclerosis (ALS) ^{3,4}. Several clinical studies on *C9ORF72* patients highlight a
10 high prevalence of psychotic features (delusions and hallucinations) associated
11 with this mutation ⁵⁻⁸.

12 Delusional symptoms are frequently linked to schizophrenic psychoses but
13 are also observed in neurodegenerative diseases ⁹. It has been suggested that
14 the dysfunction of dopaminergic neurons projecting to the striatum contributes
15 to delusion formation in patients with schizophrenia ¹⁰, however other
16 hypotheses also have been proposed for the neurobiological basis of delusions
17 with schizophrenia. Delusions also have been linked to frontal cortex
18 dysfunction causing deficits in cognitive control or executive functions. This
19 may result in premature probabilistic reasoning bias and/or lack of top-down
20 control leading to release of other brain areas and manifesting as delusions ^{11,12}.

21 Although patients with FTD show severe frontal, temporal and basal
22 ganglia dysfunction, delusions have been considered a relatively rare feature of
23 FTD ¹³⁻¹⁵, and the presence of delusions in FTD has ranged from 2.3% to 12.7%
24 in clinical cohorts ^{15,16}. However, delusions appear to be more common in
25 patients with *C9ORF72* mutations; 50% in 32 cases ⁵ and 42% in 14 cases ⁶. The

1 anatomical underpinnings of delusions in FTD remain unclear, and *C9ORF72*
2 cases may contribute to an understanding of the neurobiological basis of
3 delusions.

4 Here, we report the clinical, neuropsychological, neuroimaging, and
5 neuropathological findings of patients with FTD and delusions who, at autopsy,
6 showed frontotemporal lobar degeneration with TAR DNA-binding protein
7 inclusions (FTLD-TDP) associated with the *C9ORF72* mutation, who had
8 delusions along the clinical course of their disease.

9 10 **Method**

11 All 17 patients belonging the University of California, San Francisco
12 (UCSF) Neurodegenerative Disease Brain Bank, with a neuropathological
13 diagnosis of FTLD-TDP due to *C9ORF72* expansion were included. Diagnosis of
14 *C9ORF72* expansion was made by genetic testing and confirmed by the finding
15 of p62 positive /TDP-43 negative intraneuronal inclusions in cerebellum and
16 hippocampus¹⁷. All subjects and their informants signed an institutional
17 review board-approved research consent form to participate in the study.
18 Patients were seen at the Memory and Aging Center at the UCSF between 2004
19 and 2010 and had undergone at least one neurological evaluation, including
20 extensive neuropsychological assessment and neuroimaging. Medical history
21 including psychiatric history is confirmed independently by neurologist and
22 research nurse through caregiver interviews using structured questionnaires.
23 Out of the 17 patients identified as *C9ORF72* expansion positive, four of them
24 presented with well-defined delusions during the disease evolution. Delusion
25 was defined according to the Diagnostic and Statistical Manual of Mental

1 Disorders, Fourth Edition (DSM-IV) as “a false belief based upon an incorrect
2 inference about external reality that is firmly sustained despite what almost
3 everyone else believes and despite what constitutes incontrovertible and
4 obvious proof or evidence to the contrary, the belief is not one ordinarily
5 accepted by other members of the person's culture or subculture”¹⁸. Clinical
6 data collected included the time of onset of delusions in relation to other
7 symptoms, previous psychiatric history, the presence of associated
8 hallucinations, and the phenomenological content of the delusions. Subjects’
9 demographic characteristics are summarized in Table 1.

11 Neuropsychological data

12 The patients underwent a detailed neuropsychological battery during their
13 visits. General intellectual function was assessed using the UCSF screening
14 battery described elsewhere¹⁹.

16 Genotyping

17 The presence of expanded GGGGCC hexanucleotide repeats in C9orf72 was
18 detected using the repeat-primed PCR reaction as described elsewhere³. PCR
19 products were run on an ABI3730 DNA Analyzer and analyzed using the Peak
20 Scanner Software.

22 Neuroimaging

23 Each patient was scanned with a structural Magnetic Resonance Imaging
24 (MRI) on a 1.5T or 3T scanner within one year of the first UCSF visit.
25 Structural T1-weighted images were preprocessed for voxel-based morphometry

1 (VBM) using Diffeomorphic Anatomical Registration Through Exponentiated
2 Lie (DARTEL) running in Statistical Parametric Mapping (SPM) 8 with Matlab.
3 Group comparison of VBM gray matter images were conducted between 4
4 pathologically proven FTLD-TDP subjects with *C9ORF72* mutation who had
5 delusions and remaining 13 subjects who did not.

6 7 Neuropathology

8 All patients were subjected to an extensive dementia-oriented postmortem
9 assessment at UCSF or at the University of Pennsylvania, following a standard
10 protocol described previously^{20,21}. The brains were procured within 18 hours
11 post-mortem. The majority of the brains was cut into 8–10 mm-thick coronal
12 slabs and alternately fixed, in 10% neutral buffered formalin for 72h, or rapidly
13 frozen; the remaining were hemi-sectioned sagittally with one hemisphere fixed
14 in 10% neutral buffered formalin and the other rapidly frozen. Tissue blocks
15 covering dementia-related regions of interest were dissected from the fixed
16 slabs and basic and immunohistochemical stains were applied following
17 standard diagnostic procedures developed for patients with dementia²¹. All
18 immunohistochemical runs included positive control sections to exclude
19 technical factors as a cause of absent immunoreactivity. FTLD-TDP subtyping
20 followed the current “harmonized” nomenclature²². All cases were also screened
21 for p62 positive /TDP-43 negative intraneuronal inclusions, pathognomonic
22 markers of *C9ORF72* expansion in amygdala^{10,23}, a brain area involved in
23 different kind of delusions. Finally, the presences of additional overlapping
24 neurodegenerative disorders were compared between the two groups.

1
2
3
4
5 **1 Results**

6
7 **2 Case presentation**

8
9 **3 Case 1**

10
11 Mr. A, a right-handed man, presented first symptoms at the age of 56.

12
13 Previously psychiatrically healthy, he became fixated on specific topics,
14 developed paranoia about his neighbors and became frightened by them when
15 they performed yard work. As the disease progressed he also became suspicious
16 of close friends. At the age of 58, he vocalized that he felt his life was threatened
17 and that his wife had been replaced by a demon. He did not have any
18 self-awareness that these thoughts were irrational and false. He was seen by a
19 psychiatrist and a neurologist at the age of 60, after he made obscene gestures
20 to a woman and propositioned his neighbor's wife. He was started with
21 Quetiapine first at 25 mg, increasing to a maximum of 150 mg. It reduced his
22 fears, especially about his wife; however, he progressively became more fearful
23 of others around him.

24
25 At the age of 61, he became quieter, mellower, and progressively slower.
26 Fluoxetine started at that time reduced his inappropriate behaviors in public.
27 He habitually strolled around the house and exhibited motor restlessness. He
28 developed increased interest in chocolate. His personal grooming declined. At
29 the age of 62 years, he went out alone and returned after 8 hours sunburned
30 and dehydrated; he reported that he had been looking for his friend who was
31 actually living in another state.

32
33 Mr. A was evaluated at the UCSF Memory and Aging Center at the age of
34 62. He demonstrated utilization behavior and perseverations and was impulsive
35 and easily distracted. On neurological exam, he had mild cogwheeling in the
36
37
38
39
40
41
42
43
44
45
46
47
48
49
50
51
52
53
54
55
56
57
58
59
60

1 arms, mild to moderate hypomimia, and mild bradykinesia. Cognitive testing
2 revealed deficits in all domains except for copying tasks and language. His
3 working memory and executive function were most severely impaired (see Table
4 1). Past medical history was unremarkable for psychiatric symptoms. His
5 family history was negative for dementia. His medications included Fluoxetine
6 (30 mg) and Quetiapine (150 mg). MRI revealed bilateral frontal atrophy. He
7 died suddenly by choking at the age of 64, eight years after the onset of his
8 symptoms.

9 Neuropathological exam demonstrated brain atrophy (weight: 1170 grams),
10 with most severe degenerative changes involving the dorsal and opercular
11 frontal cortices, as well as the dorsal striatum. Microscopic examination
12 revealed hippocampal sclerosis. Immunohistochemical analysis showed
13 unequivocal evidence of FTLD-TDP, featuring TDP-43 immunoreactive
14 inclusions in many cortical regions examined, especially the dorsal and
15 opercular frontal regions. TDP-43 pathology were consistent with FTLD-TDP,
16 with features of type A and type B ²². Argrophilic grain disease, a 4-repeat
17 tauopathy was noted in limbic areas and orbital frontal cortex.

18 19 Case 2

20 Mr. B, a left-handed man started to believe that his wife was cheating on
21 him around the age of 40. This delusion spontaneously remitted after several
22 years, however, it reemerged at age of 62. The couple underwent marriage
23 counseling, but the delusion did not remit again. Concomitantly, he developed
24 difficulty in completing his usual tasks, such as fixing light sockets or cars.
25 Subsequently, he had difficulty in understanding directions and conversation.

1 Other language problems included poor repetition, and reduction in speech. He
2 became apathetic, but showed increase in appetite. He had no awareness of his
3 cognitive deficits.

4 Mr. B was evaluated at the UCSF at the age of 65 years. On neurological
5 examination, language was abnormal with evidence of paraphasic errors and
6 some difficulty with reading. He exhibited Parkinsonism with masked faces and
7 reduced blink frequency, however, there was no increased tone at rest, no
8 tremor, and he walked without difficulty. Verbal and visual memories were
9 moderately impaired, but visuospatial abilities remained normal.

10 Neuropsychological tests confirmed the language deficits and showed moderate
11 executive dysfunction (for details see Table 1). Past medical history was
12 unremarkable. His medications were Donepezil and Fexofenadine (60mg).
13 Family history was unknown because he was adopted. Structural imaging
14 showed generalized atrophy, with frontal predominance.

15 The Parkinsonism, executive loss and memory dysfunction all progressed,
16 followed by the appearance of progressive apathy. At age 68, he had difficulty
17 swallowing, increased tone in all extremities, upper limb fasciculations, and a
18 prominent jaw jerk. He died from pneumonia at the age of 70, seven years after
19 the onset of symptoms.

20 Fresh brain weight was 1066 grams. Neuropathology showed atrophy with
21 most severe degenerative changes in the frontal lobes, in particular, the
22 anterior orbital and inferior frontal gyri and the anterior cingulate cortex.
23 Immunohistochemical analysis showed FTLD-TDP with features of type A and
24 type B, consistent with unclassifiable FTLD-TDP. Co-occurring 4-repeat tau
25 pathology was seen and characterized by deposition of neurofibrillary tangles

1 and astrocytic inclusions mostly in limbic areas, inferior temporal gyrus and in
2 precentral gyrus. This tauopathy did not fit into existing criteria for a specific
3 entity and was classified as an atypical tauopathy.

4 5 Case 3

6 Mr. C, a right-handed man, presented with problems in his management
7 skills and an increased number of business-related judgment errors at age 46.
8 Three years later, he had uncharacteristic loss of empathy for his wife who was
9 hospitalized at that time. At the age of 51, he closed his business and found a
10 job for a local manager of a discount store, but he soon started to have trouble at
11 work. He had the grandiose delusion that "they were saving a large store for
12 him." He became socially withdrawn and spent more time watching television.
13 He was fired at the age of 53 years due to his inability to keep the store in good
14 condition, but his delusion continued.

15 Also around that time, he became emotionally and physically more distant
16 from his wife, refused to do jobs around the house, showed increasing apathy.
17 He exhibited other strange behaviors such as sneaking into the home and
18 peeking around the corner at his wife. He maintained the grandiose delusion
19 that someone was saving highly paid jobs for him. He became more rigid and
20 inflexible about his schedule at home, showing anxiety if meals were not served
21 on time. He became irritable and developed environmental dependence playing
22 with items placed in front of him and mimicking other people's actions. Also, he
23 developed compulsive symptoms such as repetitive checking of the temperature.
24 Later on, he inappropriately greeted strangers and developed a preference for
25 sweets.

1 Mr. C was evaluated at UCSF at the age of 54 years. On neurological
2 examination, he had a fine resting and action tremor in the left hand. Tone was
3 increased in the arm with evidence of paratonia on the left greater than right.
4 Gait changes were notable for a decreased arm swing on the left. He had no
5 awareness of his deficits or delusion. He performed poorly on
6 neuropsychological assessment of frontal and executive function with relatively
7 intact language and visuospatial function (for details see Table 1). Past medical
8 history was significant for hypercholesterolemia, borderline hypertension and a
9 loss of hearing after a motor accident. Family history was significant for a
10 strong history of autosomal dominant dementia with Parkinsonism in many
11 relatives. His mother died at age 60 with similar symptoms of dementia and
12 Parkinsonism, but she did not have an autopsy. The patient's MRI showed mild
13 frontal lobe and striatal atrophy.

14 He died by pneumonia at the age of 59, thirteen years after the onset of his
15 symptoms. Neuropathological examination showed general atrophy and marked
16 ventricular dilatation. The fresh brain weighed 1050 grams. TDP-43
17 immunopositive neuropil threads were found in multiple regions of the central
18 nervous system and features were consistent with unclassifiable FTLTDP. In
19 addition, he showed argyrophilic grain disease restricted to limbic area.

20 21 Case 4

22 Mr. D, a right-handed man, started to exhibit social withdrawal and
23 executive dysfunction in his late 30s. He became reluctant to join in
24 conversations, completed tasks more slowly and had difficulty concentrating
25 and multi-tasking. In his 40s, he became careless and failed to finish tasks at

1 work. By his late 40s, he became even slower, and less talkative. At the age of
2 54, he developed auditory hallucinations and delusions, believing that various
3 “friends” were talking to him and to each other through TV. Also, he thought
4 that people were watching him through the bathroom mirrors. He believed he
5 was a “sex god” and that various neighbors dated him. He also believed that an
6 imposter replaced his physician. He occasionally accused his wife of infidelity.
7 He exhibited less emotion but inappropriately laughed at serious TV shows. At
8 the age of 56, his speech output declined and his response time became delayed,
9 he walked more slowly. He accompanied his family to work but did little work
10 by himself. Table manners deteriorated and he ate enormous quantities of food
11 voraciously in a messy fashion, including eating food off the floor. He also
12 became apathetic.

13 Mr. D was evaluated at the UCSF Memory and Aging Center at the age of
14 57. His affect was flat, his speech was effortful, and he was perseverative,
15 stimulus-bound and demonstrated poor insight. His neurological examination
16 showed jerky ocular pursuit, increased arm tone with cogwheeling in the left
17 greater than right, slowed finger taps, fasciculations throughout the arms and
18 legs, a fine postural tremor of the outstretched hands, and a slow stooped gait.
19 His exam was also notable for delayed response times, marked utilization
20 behavior, and inability to perform tasks. Neuropsychological testing showed
21 moderate impairments in episodic memory encoding and consolidation,
22 impaired language comprehension, verbal agility, and repetition, marked
23 executive impairment, and impaired abstract reasoning, with relatively spared
24 visuospatial skills (see Table 1).

25 His past medical history includes hypertension, ankylosing spondylitis, and

1 prostate resection. Regarding family history, his mother was diagnosed with
2 Parkinson's disease dementia and had a brain autopsy showing neuronal loss in
3 the substantia nigra without Lewy bodies. His medications included Donepezil
4 (10mg), Quetiapine (800mg), divalproex sodium (500mg), and Trazodone
5 (300mg). His MRI showed moderate bilateral lateral parietal atrophy as well as
6 bifrontal atrophy, vermian atrophy, and bilateral caudate atrophy.

7 He died at 58 years of age. The fresh brain weighed 1340 grams.

8 Neuropathological exam showed atrophy with most severe degenerative
9 changes involving the prefrontal and peri-rolandic cortices, substantia nigra
10 and lower motor neurons of the brainstem and spinal cord.

11 Immunohistochemical analysis showed an unclassifiable FTLD-TDP with
12 frequent granular or compact neuronal cytoplasmic inclusions, in superficial
13 and deep layers of affected cortices, subcortical and brainstem and spinal cord
14 structures. Although primary motor cortex showed TDP-43 pathology, no
15 corticospinal tract demyelination was observed, making motor neuron disease a
16 more appropriate pathological characterization than ALS. In addition, Lewy
17 body pathology was observed in the dorsal motor nucleus of the vagus,
18 corresponding a very early Parkinson's disease Braak stage I²⁴.

19
20 All the 17 cases fulfilled the most recent bvFTD clinical consensus criteria².

21 Among the remaining 13 cases lacking well-defined delusions, one case showed
22 confabulation that disappeared within 2 years from its appearance. The other
23 cases did not show any other psychotic symptoms. Seven cases had motor
24 neuron symptoms to variable extend, and one case had family history of ALS.
25 Two cases have Parkinsonism. Mean age at disease onset is 60.4 years old,

1 mean age at death is 68.2 years old. Neuropathologically, in addition to TDP-43
2 pathology, three non-delusional cases had additional non-AD tau pathology.

3 4 **Neuroimaging Results**

5 VBM analysis showed greater atrophy in left parietal precuneus area at the
6 level of uncorrected $p < 0.005$ in the four cases with delusions compared with
7 other 13 cases without delusions (Figure 1). In the small volume correction
8 analysis for left parietal precuneus area, the atrophy was also significant at a
9 Family Wise Error (FWE)-corrected p level of < 0.05 .

10 11 **Neuropathological analyses**

12 p62 positive/TDP-43 negative characteristic inclusions in the amygdala
13 were seen in most of the 17 cases and no notable difference was found between
14 the two groups. Among the 13 patients without delusions, three showed
15 overlapping argyrophilic grain disease restricted to limbic areas and one
16 showed an atypical tauopathy.

17 18 **Discussion**

19 We report the clinical, neuropsychological, neuroimaging, and
20 neuropathological findings in four FTLD-TDP cases with delusions associated
21 with *C9ORF72* mutations. *C9ORF72* mutation cases account for 12% of familial
22 and 3% of sporadic FTD cases^{3,6}. Pathologically, *C9ORF72* mutations are
23 associated with FTLD-TDP, type B²⁵, as well as type A⁵, or a unclassifiable
24 type that features both type A and type B characteristics. Additionally,
25 depositions of ubiquitin or p62-positive/TDP-negative characteristic inclusions

1 are found in cerebellum, hippocampus and thalamus. These inclusions contain
2 dipeptide-repeat proteins translated in an ATG-independent fashion from the
3 hexanucleotide repeats and are pathognomonic of *C9ORF72* expansion. On
4 structural imaging, in addition to atrophy in frontal, insular, and anterior
5 temporal areas commonly affected in bvFTD, patients with *C9ORF72*
6 mutations show atrophy in parietal, occipital, cerebellar, and thalamus ^{6-8,26}.

7 Psychotic features (particularly delusions) are seen in up to 50% of
8 *C9ORF72* mutation carriers ^{5,6}, a much larger frequency than in other FTLD
9 types ¹⁵. Therefore, the distinctive anatomical and neurochemical features of
10 *C9ORF72* may reveal insights into the neurobiological basis of psychosis ^{5-8,27}.

11 Before the discovery of *C9ORF72* mutation, delusions were thought to be a
12 relatively rare symptom in FTD patients. Some of these reports show patients
13 with young-onset FTD who were diagnosed with psychotic disorders before the
14 dementia-onset ^{28,29}. Paranoid delusions were the most frequent symptoms in
15 these series. Other case reports showed complex delusions ³⁰, grandiose
16 delusions ³¹, and Cotard delusions ³². Snowden et al. reported that most of the
17 delusions with their *C9ORF72* mutation cases were somatic delusions such as
18 alterations in temperature perception, preoccupation with bowel movements,
19 and leg pain ⁵, which was different from our series showing various delusions.

20 Compared to FTD, delusions are a relatively common symptom in
21 Alzheimer's disease (AD) and Dementia with Lewy bodies (DLB). A review
22 article reported a median prevalence of 36% (9.3–63%) for delusions in AD, most
23 involving delusion of theft, which can be included in the persecutory delusion
24 category ^{10,33}. Studies focusing on the underlying biological background of
25 delusions in AD have suggested that persecutory delusions occur early in the

1 disease course and are associated with neurochemical and neuropathological
2 changes in frontostriatal and temporal-limbic circuits ³⁴. On the other hand,
3 delusional misidentification in AD is associated with greater global cognitive
4 deficits and advanced limbic pathology ³⁴. In patients with DLB, hallucinations
5 are the most frequent psychotic symptoms, with a prevalence from 63 to 78%,
6 followed by misidentifications (56%) and paranoid delusions (25 to 28%) ^{35,36}.
7 Paranoid or persecutory delusions in DLB subjects were hypothesized to be
8 associated with dysfunction in the frontal cortex in addition to occipital cortex
9 dysfunction ³⁵.

10 Several studies on schizophrenia suggest that development of delusion is
11 associated with a dysfunction of dopamine regulation in the ventral striatum,
12 which leads to aberrant assignment of salience to stimuli ^{11,37}. Also, dysfunction
13 in brain areas associated with executive behavioral control such as the
14 prefrontal cortex (PFC) may lead to alterations in affective state, disinhibition,
15 and ways of thinking that might increase the risk of delusion formation ³⁸. PFC
16 was found to be implicated in prediction-error processing ^{39,40}, and reality
17 monitoring tasks ⁴¹, structural volume loss in the PFC correlates with
18 symptoms of delusion ⁴². Thalamic dysfunction may also result in reduced
19 ability to adjust sensory responsiveness to ongoing behaviors in patients with
20 schizophrenia ⁴³. Psychosis in schizophrenia is associated with
21 source-monitoring deficits whereby self-initiated behaviors become attributed to
22 outside sources, and one of the functions of the thalamus is to adjust sensory
23 responsiveness in accordance with the behavioral contextual cues. Lower
24 numbers of cerebellar Purkinje neurons also seen in association with psychosis
25 in patients with schizophrenia and bipolar disorder ⁴⁴. The decreased synthesis

1 and release of reelin from cerebellar granule cells could be associated with the
2 pathophysiologies that regulate GABAergic neuron dysfunction in the
3 cerebellum of these patients.

4 There are a variety of neurological disorders strongly associated with
5 psychosis. Often, psychosis occurs in association with temporal lobe dysfunction
6 and is seen in patients with temporal lobe epilepsy, herpes simplex encephalitis,
7 and autoimmune encephalitis that target the temporal lobes⁴⁵⁻⁴⁷. Disorders of
8 the basal ganglia and brain stem have a higher than expected prevalence of
9 delusions and psychosis as is seen with Huntington's disease, Fahr's syndrome,
10 and Wilson's disease⁴⁸⁻⁵⁰. These results suggest that variety neurobiological
11 substrates may predispose to delusions.

12
13 Why, then did the four FTD cases with *C9ORF72* mutations presented here
14 exhibit delusions? Mahoney et al. hypothesize that dysfunction of thalamic and
15 cerebellar projections could be related to the neuropsychiatric features
16 associated with this *C9ORF72* mutations cases, including hallucinations and
17 delusions⁷. This thalamic and cerebellar pathology is relatively unique to
18 *C9ORF72* mutation FTD cases. Although this hypothesis remains appealing, it
19 is important to note that the other 13 cases in our series without delusions also
20 showed changes in thalamus and cerebellar structures.

21 Thus, based on above-mentioned knowledge of delusions in other
22 neurodegenerative disorders and schizophrenia, we hypothesized that in
23 addition to PFC dysfunction that is common in patients with FTD, other regions
24 might have contributed to development of delusions in our series of patients²³.
25 VBM analysis showed more atrophy in left parietal precuneus area in

1 delusional patients compared to the non-delusional patients. Although the
2 result is significant even after correction, our sample is small and the time gap
3 latency between delusion onset and MRI acquisition should be taken into
4 consideration. This parietal involvement has also been reported in other
5 *C9ORF72* mutation series^{3,6}. Precuneus is involved in discriminating
6 self-relevant information from self-irrelevant information and in retrieving
7 source memories⁵⁴. Therefore, in addition to executive dysfunction, failing to
8 discriminate between self-relevant and self-irrelevant information and to
9 retrieve the information source must make the patients hypersensitive to all
10 information. Although the precuneus is very vulnerable to AD and to associate
11 with delusions in patients with AD⁵¹⁻⁵³, such delusions are typically delusions of
12 theft, rather than bizarre delusions as observed in our C9orf72 mutation series.
13 Thus, we speculate that degree of frontal involvement may contribute to the
14 variety of delusions in our cases.

15 Downey et al. suggested a distributed anatomical correlate in
16 thalamo-cerebello-cortical circuitry including parietal cortex as a key terminus
17 to explain altered body schema processing in C9orf72 related FTD patients⁵⁵.
18 Our findings corroborate their observations. In fact, their results provide a
19 useful framework for interpreting our findings, in particular the candidate
20 mechanism of self / non-self regulation. However, as they point out, the
21 spectrum of neuropsychiatric phenomena attributable to altered body schema
22 processing is potentially much wider than delusions and hallucinations. Thus,
23 our results have to be interpreted causally. Although precuneus changes may be
24 neuroanatomical basis underlying delusions in C9orf72 related FTD patients, it
25 is not possible to rule out a broader change in network vulnerable to this

1
2
3
4
5 1 disease.
6
7 2

8
9 3 Neuropathological information revealed that 3 out of 4 delusional patients
10 4 presented an overlapping tauopathy (2 AGD and 1 atypical tauopathy). This
11 5 75% frequency is significantly higher than frequency of tauopathies in
12 6 non-delusional cases 23% (3/13) and may indicate an association. Patients with
13 7 AGD are prone to present persecutory delusions ^{56,57}. Thus, the mixture of tau
14 8 pathology and FTLD-TDP pathology especially in frontal cortex and ventral
15 9 striatum, may have contributed to the clinical picture of delusions. In case 4,
16 10 there was an additional Lewy body pathology. Lewy body pathology is
17 11 associated with visual hallucinations, which were present in this patient, but
18 12 the link is weakened because Lewy body pathology was restricted to the dorsal
19 13 motor nucleus of the vagus nerve. None of the previous three subjects showed
20 14 hallucinations in any modality. This may indicate a difference in pathological
21 15 background between delusions and hallucinations. However, Snowden et al.
22 16 reported that among 4 pathological confirmed cases with psychosis, 1 had tau
23 17 pathology without TDP-43 pathology and the others had TDP-43 pathology
24 18 without accompanying pathology ⁵. Synergistic effects of FTLD-TDP and certain
25 19 tauopathies in causing delusions deserve investigation in a larger cohort, once it
26 20 becomes available.

27
28
29
30
31
32
33
34
35
36
37
38
39
40
41
42
43
44
45
46 21 Although postmortem examination can potentially identify the underlying
47 22 basis of neuropsychiatric symptoms, its power is limited by the long lag between
48 23 the onset of delusions and expiration. It is possible that the advance stage of the
49 24 disease by the time of passing precludes identification of more subtle differences
50 25 between patients with specific symptoms. It might explain why we could not
51
52
53
54
55
56
57
58
59
60

1 find any distinctive pathological findings in parietal and precuneus in the
2 delusional group. This also supports the hypothesis that precuneus can be a
3 component of a network that may show differential vulnerability.
4

5 Interestingly, all of our four delusional cases had Parkinsonism, compared
6 to 2/13 non-delusional cases. However, iatrogenic Parkinsonism cannot be
7 discarded as two delusional cases (case 1 and case 4) and one non-delusional
8 subject were treated with atypical antipsychotics. This may indicate higher
9 sensibility of delusional subjects to dopamine dysfunction, both associated to
10 delusions and to Parkinsonism. Association between delusions and
11 Parkinsonism in *C9ORF72* mutation cases suggests an overlapping
12 vulnerability of certain brain areas to both Lewy body disease and *C9ORF72*
13 mutation-related pathology, even though both have different abnormal protein
14 deposition signatures. One clinico-pathological study with 68 patients shows a
15 greater loss of dopaminergic neurons in the substantia nigra of patients with
16 *C9ORF72* mutations than those without⁵⁸. Parkinson disease itself is not
17 associated with *C9ORF72* mutations⁵⁹.

18
19 Finally, delusions in our series often preceded the behavioral and cognitive
20 disabilities. This observation may increase the likelihood of misdiagnosis and
21 delayed appropriate treatment. FTD cases are often diagnosed as having
22 atypical psychosis such as late-onset schizophrenia or late-life depression with
23 psychotic features⁶⁰. Indeed, patients with FTD receive a prior psychiatric
24 diagnosis significantly more often than patients with AD (FTD, 50.7% vs. AD,
25 23.1%)⁶¹. Clinicians need to consider the possibility of this mutation and assess

1 the family history when a patient presents with middle age onset delusions.

2

3 **Conclusion**

4 All of our FTD series with the *C9ORF72* mutation presenting delusions had
5 some additional pathology and Parkinsonism, which suggests a common
6 anatomy or neurochemistry underlying these delusions. VBM analysis suggests
7 relationship between precuneus and appearance of delusions, although the
8 number of cases is small to draw conclusions. Further work with larger cohorts
9 will be required to investigate the biological correlates of delusions in this
10 genetic FTD group. Their presentations of this mutation carrier are
11 heterogeneous and may be at higher risk of being misdiagnosed with primary
12 psychosis. Clinicians need to consider the possibility of this mutation and assess
13 the family history when a patient presents with middle age onset delusions.

14

15 **Acknowledgments**

16 We thank patients and their families for the time and effort they dedicated
17 to our research.

18

19 **Declaration of Conflicting Interests**

20 The authors declared no potential conflicts of interest with respect to the
21 research, authorship, and publication of this article.

22

23 **Funding**

24 Financial support for this research and any potential conflicts are as
25 followings: Dr. Shinagwa has received a fellowship grant from Mitsukoshi

26

27

28

29

30

1 Health and Welfare Foundation. Dr. Grinberg receives institutional support
2 from these NIH grants P50AG023501, P01AG019724. Dr. Seeley receives
3 institutional support from these NIH grants: P50AG023501, P01AG019724.
4 Dr. Miller receives institutional support from these NIH grants: P50AG023501,
5 P01AG019724, and P50AG1657303. Other authors have no financial or other
6 relationship relevant to the subject of this manuscript.
7

8 REFERENCES

- 9
- 10 1. Ratnavalli E, Brayne C, Dawson K, Hodges JR. The prevalence of
11 frontotemporal dementia. *Neurology*. 2002 Jun 11;58(11):1615–1621.
- 12 2. Rascovsky K, Hodges JR, Knopman DS, et al. Sensitivity of revised
13 diagnostic criteria for the behavioural variant of frontotemporal dementia.
14 *Brain*. 2011 Sep 1;134(Pt 9):2456–2477.
- 15 3. DeJesus-Hernandez M, Mackenzie IR, Boeve BF, et al. Expanded
16 GGGGCC hexanucleotide repeat in noncoding region of C9ORF72 causes
17 chromosome 9p-linked FTD and ALS. *Neuron*. 2011 Oct 20;72(2):245–256.
- 18 4. Renton A, Majounie E, Waite A, et al. A hexanucleotide repeat expansion
19 in C9ORF72 is the cause of chromosome 9p21-linked ALS-FTD. *Neuron*.
20 2011 Oct 20;72(2):257–268.
- 21 5. Snowden J, Rollinson S, Thompson JC, et al. Distinct clinical and
22 pathological characteristics of frontotemporal dementia associated with
23 C9ORF72 mutations. *Brain*. 2012 Feb 24;135(3):693–708. Available from:
- 24 6. Sha SJ, Takada LT, Rankin KP, et al. Frontotemporal dementia due to
25 C9ORF72 mutations: clinical and imaging features. *Neurology*. 2012 Sep
26 4;79(10):1002–1011.
- 27 7. Mahoney CJ, Beck J, Rohrer JD, et al. Frontotemporal dementia with the
28 C9ORF72 hexanucleotide repeat expansion: clinical, neuroanatomical and
29 neuropathological features. *Brain*. 2012 Mar;135(Pt 3):736–750.

- 1
2
3
4
5 1 8. Boeve BF, Boylan KB, Graff-Radford NR, et al. Characterization of
6 2 frontotemporal dementia and/or amyotrophic lateral sclerosis associated
7 3 with the GGGGCC repeat expansion in C9ORF72. *Brain*. 2012
8 4 Mar;135(Pt 3):765–783.
- 9
10 5 9. Bhat R, Rockwood K. Psychiatric complications of dementia. *Can J*
11 6 *Psychiatry*. 2011 Jul;56(7):398–407.
- 12
13
14 7 10. Pankow A, Knobel A, Voss M, Heinz A. Neurobiological correlates of
15 8 delusion: beyond the salience attribution hypothesis. *Neuropsychobiology*.
16 9 2012;66(1):33–43.
- 17
18
19 10 11. Heinz A, Schlagenhauf F. Dopaminergic Dysfunction in Schizophrenia:
20 11 Salience Attribution Revisited. *Schizophrenia Bulletin*. 2010 May
21 12 1;36(3):472–485.
- 22
23
24 13 12. Lakhan SE, Vieira KF. Schizophrenia pathophysiology: are we any closer
25 14 to a complete model? *Ann Gen Psychiatry*. 2009;8(1):12.
- 26
27
28 15 13. Bathgate D, Snowden J, Varma A, Blackshaw A, Neary D. Behaviour in
29 16 frontotemporal dementia, Alzheimer's disease and vascular dementia.
30 17 *Acta Neurol Scand*. 2001 Jun 1;103(6):367–378.
- 31
32 18 14. Mendez MF, Lauterbach ECE, Sampson SMS. An evidence-based review
33 19 of the psychopathology of frontotemporal dementia: a report of the ANPA
34 20 Committee on Research. *J Neuropsychiatry Clin Neurosci*. 2008 Jan
35 21 1;20(2):130–149.
- 36
37
38 22 15. Mendez MF, Shapira J, Woods RJ, Licht EA, Saul RE. Psychotic
39 23 symptoms in frontotemporal dementia: prevalence and review. *Dement*
40 24 *Geriatr Cogn Disord*. 2008;25(3):206–211.
- 41
42
43 25 16. Mourik JC, Rosso SM, Niermeijer MF, Duivenvoorden HJ, van Swieten
44 26 JC, Tibben A. Frontotemporal Dementia: Behavioral Symptoms and
45 27 Caregiver Distress. *Dement Geriatr Cogn Disord*. 2004;18(3-4):299–306.
- 46
47
48 28 17. Mori K, Lammich S, Mackenzie IR, et al. hnRNP A3 binds to GGGGCC
49 29 repeats and is a constituent of p62-positive/TDP43-negative inclusions in
50 30 the hippocampus of patients with C9orf72 mutations. *Acta Neuropathol*.
51 31 2013 Mar;125(3):413–423.
- 52
53 32 18. American Psychiatric Association. *Diagnostic and Statistical Manual of*
54 33 *Mental Disorders, Fourth Edition*. American Psychiatric Pub; 2000.

- 1
2
3
4
5 1 19. Kramer JH, Jurik JJ, Sha SJ, et al. Distinctive neuropsychological
6 2 patterns in frontotemporal dementia, semantic dementia, and Alzheimer
7 3 disease. *Cogn Behav Neurol*. 2003 Dec 1;16(4):211–218.
8
9 4 20. Forman MS, Farmer J, Johnson JK, et al. Frontotemporal dementia:
10 5 clinicopathological correlations. *Ann Neurol*. 2006 Jun 1;59(6):952–962.
11
12 6 21. Mirra SS, Heyman A, McKeel D, et al. The Consortium to Establish a
13 7 Registry for Alzheimer’s Disease (CERAD). Part II. Standardization of
14 8 the neuropathologic assessment of Alzheimer’s disease. *Neurology*. 1991
15 9 Apr 1;41(4):479–486.
16
17 10 22. Mackenzie IR, Neumann M, Baborie A, et al. A harmonized classification
18 11 system for FTLD-TDP pathology. *Acta Neuropathol*. 2011 Jul
19 12 1;122(1):111–113.
20
21 13 23. Holt AEM, Albert ML. Cognitive neuroscience of delusions in aging. *NDT*.
22 14 Dove Press; 2006;2(2):181–189.
23
24 15 24. Braak H, Del Tredici K, Rüb U, de Vos RAI, Jansen Steur ENH, Braak E.
25 16 Staging of brain pathology related to sporadic Parkinson's disease.
26 17 *Neurobiology of Aging*. 2003 Mar;24(2):197–211.
27
28 18 25. Dobson-Stone C, Hallupp M, Bartley L, et al. C9ORF72 repeat expansion
29 19 in clinical and neuropathologic frontotemporal dementia cohorts.
30 20 *Neurology*. 2012 Sep 3;79(10):995–1001.
31
32 21 26. Whitwell JL, Weigand SD, Boeve BF, et al. Neuroimaging signatures of
33 22 frontotemporal dementia genetics: C9ORF72, tau, progranulin and
34 23 sporadics. *Brain*. 2012 Feb 24;135(3):794–806.
35
36 24 27. Takada LT, Sha SJ. Neuropsychiatric features of C9orf72-associated
37 25 behavioral variant frontotemporal dementia and frontotemporal dementia
38 26 with motor neuron disease. *Alzheimer's Research & Therapy*. 2012 Oct
39 27 3;4(5):38–38.
40
41 28 28. Velakoulis D, Walterfang M, Mocellin R, Pantelis C, McLean C.
42 29 Frontotemporal dementia presenting as schizophrenia-like psychosis in
43 30 young people: clinicopathological series and review of cases. *The British*
44 31 *Journal of Psychiatry*. 2009 Mar 31;194(4):298–305.
45
46 32 29. Omar R, Sampson EL, Loy CT, et al. Delusions in frontotemporal lobar
47 33 degeneration. *J Neurol*. 2009 Apr 1;256(4):600–607.
48
49
50
51
52
53
54
55
56
57
58
59
60

- 1
2
3
4
5 1 30. Loy CT, Kril J, Trollor JN, et al. The case of a 48 year-old woman with
6 2 bizarre and complex delusions. *Nature Reviews Neurology*. 2010
7 3 Mar;6(3):175–179.
- 8
9 4 31. Duggal HS, Singh I. Frontotemporal dementia presenting with psychotic
10 5 symptoms. *J Neuropsychiatry Clin Neurosci*. 2009;21(1):103–104.
- 11
12 6 32. Mendez MF, Ramírez-Bermúdez J. Cotard syndrome in semantic
13 7 dementia. *Psychosomatics*. 2011 Nov;52(6):571–574.
- 14
15
16 8 33. Ropacki SA, Jeste DV. Epidemiology of and risk factors for psychosis of
17 9 Alzheimer's disease: a review of 55 studies published from 1990 to 2003.
18 10 *Am J Psychiatry*. 2005 Nov 1;162(11):2022–2030.
- 19
20
21 11 34. Reeves SJ, Gould RL, Powell JF, Howard RJ. Origins of delusions in
22 12 Alzheimer's disease. *Neuroscience & Biobehavioral Reviews*. 2012 Nov
23 13 1;36(10):2274–2287.
- 24
25
26 14 35. Casanova MF, Starkstein SE, Jellinger KA. Clinicopathological correlates
27 15 of behavioral and psychological symptoms of dementia. *Acta*
28 16 *Neuropathologica* [Internet]. 2011 Aug 1;122(2):117–135. Available from:
29 17 <http://link.springer.com/10.1007/s00401-011-0821-3>
- 30
31 18 36. Nagahama Y, Okina T, Suzuki N, Matsuda M. Neural correlates of
32 19 psychotic symptoms in dementia with Lewy bodies. *Brain*. 2010
33 20 Feb;133(Pt 2):557–567.
- 34
35
36 21 37. Guillin O, Abi-Dargham A, Laruelle M. Neurobiology of Dopamine in
37 22 Schizophrenia. *Int Rev Neurobiol*. 2007 Jan 1;78:39–39.
- 38
39
40 23 38. Kapur S, Agid O, Mizrahi R, Li M. How antipsychotics work-from
41 24 receptors to reality. *NeuroRx*. 2006 Jan 1;3(1):10–21.
- 42
43
44 25 39. Corlett PR, Aitken MRF, Dickinson A, et al. Prediction error during
45 26 retrospective revaluation of causal associations in humans: fMRI evidence
46 27 in favor of an associative model of learning. *Neuron*. 2004 Dec
47 28 2;44(5):877–888.
- 48
49 29 40. Turner DC, Aitken MRF, Shanks DR, et al. The role of the lateral frontal
50 30 cortex in causal associative learning: exploring preventative and
51 31 super-learning. *Cerebral Cortex*. 2004 Aug 1;14(8):872–880.

- 1
2
3
4
5 1 41. Lagioia A, Eliez S, Schneider M, Simons JS, Van der Linden M, Debbané
6 2 M. Neural correlates of reality monitoring during adolescence.
7 3 NeuroImage. 2011 Apr 1;55(3):8–8.
8
9
10 4 42. Buchy L, Ad-Dab'bagh Y, Lepage C, et al. Symptom Attribution in first
11 5 episode psychosis: A cortical thickness study. Psychiatry Res. 2012 Jul
12 6 30;203(1):6–13.
13
14 7 43. Vukadinovic Z, Rosenzweig I. Abnormalities in thalamic neurophysiology
15 8 in schizophrenia: could psychosis be a result of potassium channel
16 9 dysfunction? Neuroscience and Biobehavioral Reviews. 2012
17 10 Feb;36(2):960–968.
18
19
20 11 44. Maloku E, Covelo IR, Hanbauer I, et al. Lower number of cerebellar
21 12 Purkinje neurons in psychosis is associated with reduced reelin
22 13 expression. Proc Natl Acad Sci USA. 2010 Mar 2;107(9):4407–4411.
23
24
25 14 45. Elliott B, Joyce E, Shorvon S. Delusions, illusions and hallucinations in
26 15 epilepsy: 2. Complex phenomena and psychosis. Epilepsy Research. 2009
27 16 Aug;85(2-3):172–186.
28
29
30 17 46. Nadkarni S, Arnedo V, Devinsky O. Psychosis in epilepsy patients.
31 18 Epilepsia. 2007 Nov 29;48:17–19.
32
33 19 47. Mocellin RR, Walterfang M, Velakoulis D. Hashimoto's encephalopathy :
34 20 epidemiology, pathogenesis and management. CNS Drugs. 2007 Jan
35 21 1;21(10):799–811.
36
37
38 22 48. Jellinger KA. Cerebral correlates of psychotic syndromes in
39 23 neurodegenerative diseases. J Cell Mol Med. 2012 Apr 26;16(5):995–1012.
40
41 24 49. Rosenblatt A, Leroi I. Neuropsychiatry of Huntington's Disease and Other
42 25 Basal Ganglia Disorders. PSYM. 2000 Feb 1;41(1):24–30.
43
44
45 26 50. Lauterbach EC, Cummings JL, Duffy JR, et al. Neuropsychiatric
46 27 correlates and treatment of lenticulostratial diseases: a review of the
47 28 literature and overview of research opportunities in Huntington's,
48 29 Wilson's, and Fahr's diseases. A report of the ANPA Committee on
49 30 Research. American Neuropsychiatric Association. J Neuropsychiatry
50 31 Clin Neurosci. 1998 Jan 1;10(3):249–266.
51
52
53
54
55
56
57
58
59
60

- 1
2
3
4
5 1 51. Fukuhara R, Ikeda M, Nebu AA, et al. Alteration of rCBF in Alzheimer's
6 2 disease patients with delusions of theft. *Neuroreport*. 2001 Aug
7 3 8:12(11):2473–2476.
8
9 4 52. Nomura KK, Kazui H, Wada TT, et al. Classification of delusions in
10 5 Alzheimer's disease and their neural correlates. *Psychogeriatrics*. 2012
11 6 Sep 1;12(3):200–210.
12
13 7 53. Jedidi H, Daury N, Capa R, et al. Brain Metabolic Dysfunction in Capgras
14 8 Delusion During Alzheimer's Disease: A Positron Emission Tomography
15 9 Study. *Am J Alzheimers Dis Other Demen*. 2013 Jun 30.
16
17 10 54. Lundstrom BN, Ingvar M, Petersson KM. The role of precuneus and left
18 11 inferior frontal cortex during source memory episodic retrieval.
19 12 *NeuroImage*. 2005 Oct 1;27(4):824–834.
20
21 13 55. Downey LE, Fletcher PD, Golden HL, et al. Altered body schema
22 14 processing in frontotemporal dementia with C9ORF72 mutations. *Journal*
23 15 *of Neurology, Neurosurgery & Psychiatry*. 2014 Feb 12.
24
25 16 56. Asaoka T, Tsuchiya K, Fujishiro H, et al. Argyrophilic grain disease with
26 17 delusions and hallucinations: a pathological study. *Psychogeriatrics*. 2010
27 18 Jun 1;10(2):69–76.
28
29 19 57. Togo T, Isojima D, Akatsu H, et al. Clinical features of argyrophilic grain
30 20 disease: a retrospective survey of cases with neuropsychiatric symptoms.
31 21 *Am J Geriatr Psychiatry*. 2005 Dec;13(12):1083–1091.
32
33 22 58. Cooper-Knock J, Frolov A, Highley JR, et al. C9ORF72 expansions,
34 23 parkinsonism, and Parkinson disease: A clinicopathologic study.
35 24 *Neurology*. 2013 Aug 27;81(9):808–811.
36
37 25 59. Harms MB, Neumann D, Benitez BA, et al. Parkinson disease is not
38 26 associated with C9ORF72 repeat expansions. *Neurobiology of Aging*. 2013
39 27 May;34(5):1519.e1–e2.
40
41 28 60. Passant U, Elfgren C, Englund E, Gustafson L. Psychiatric symptoms and
42 29 their psychosocial consequences in frontotemporal dementia. *Alzheimer*
43 30 *Dis Assoc Disord*. 2005 Oct;19 Suppl 1:S15–S18.
44
45 31 61. Woolley JD, Khan BK, Murthy NK, Miller BL, Rankin KP. The Diagnostic
46 32 Challenge of Psychiatric Symptoms in Neurodegenerative Disease. *J Clin*
47 33 *Psychiatry*. 2011 Feb 15;72(02):126–133.
48
49 34
50
51
52
53
54
55
56
57
58
59
60

Table 1

Clinical, neuropsychological, and brain imaging features of 4 cases

	Right handed Male	Right handed Male	Right handed Male	Right handed Male
Clinical diagnosis	bvFTD	bvFTD	bvFTD	bvFTD
Disease onset	56	62	46	late 30s
Initial symptom	perseveration	executive dysfunction	executive dysfunction	apathy
Delusion onset	58	40s	54	54
Delusion content	paranoia about neighbors / Capgras	infidelity	grandiose	paranoia / grandiose / Capgras
Prognosis of delusion	progressive	continued	continued	slight improve with medication
Medication for delusion	Quetiapine	None	None	Quetiapine
Behavioral symptoms	sexually inappropriate roaming stereotypy loss of personal hygiene preference for sweets	reduction in motivation increase in appetite	apathy / lack of interest rigid inflexible in schedule irritable environmental dependent preference for sweets	hyperorality apathy utilization behavior loss of personal hygiene
family history	negative	unknown (adaption)	mother/ maternal family	mother
neuropsychological examination				
Mini Mental State Exam	17/30	20/30	28/30	19/30
CVLT Short Form*	2-3-3-2-0-0	5-4-5-6-4-3	6-6-6-6-6-7	2-3-4-4-3-2
Benson Figure Copy and Recall	14/17 and 6/17	16/17 and 8/17	16/17 and 9/17	16/17 and 8/17
Digit span Forward/Backward	5/2	7/2	7/2	6/3
Stroop inhibition	unable	9 with 19 uncorrected errors	21 with 5 uncorrected errors	6 with 11 uncorrected errors
Modified Trails (sec)	unable	62sec	unable	unable
Boston Naming Test	11/15	11/15	13/15	15/15
Phonemic and Category	3 and 5	2 and 6	6 and 13	2 and 2

1
2
3
4
5
6
7
8
9
10
11
12
13
14
15
16
17
18
19
20
21
22
23
24
25
26
27
28
29
30
31
32
33
34
35
36
37
38
39
40
41
42
43
44
45
46
47
48
49

fluency				
Geriatric Depression Scale	12	4	0	15
Neuropsychiatric Inventory	45	8	20	52
(delusion scale)	8	2	2	12
Unified Parkinson's Disease Rating Scale	9	10	-	6
MRI imaging**				
dorsolateral frontal atrophy	++	+	+	+
medial frontal atrophy	++	+	-	++
orbitofrontal atrophy	++	-	+	+
striatum atrophy	+	+	+	+
<u>parietal atrophy</u>	++	+	+	++
cerebellum atrophy	+	-	-	-
age at death	64	69	60	58
main pathological changes	FTLD-TDP, unclassifiable argyrophilic grain disease	FTLD-TDP, unclassifiable atypical tauopathy	FTLD-TDP, unclassifiable argyrophilic grain disease	FTLD-TDP, unclassifiable Lewy body pathology

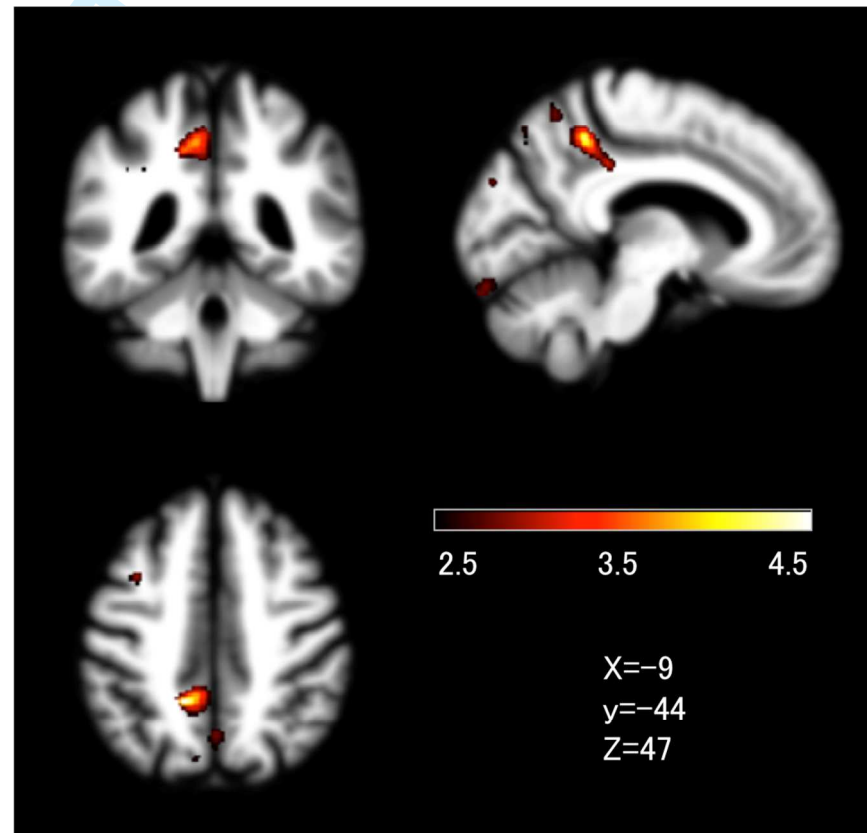
* California Verbal Learning Test, 4 time registration, 30 second recall, and 10 minutes recall of 9 words

**(+) means mild atrophy and (++) means severe atrophy, based on expert neurologist who is blind to patients' clinical information

FTLD-TDP: frontotemporal lobar degeneration with TAR DNA-binding protein inclusions

Figure 1

T-score map showing regions greater atrophy in 4 C9ORF72 mutation carriers with delusions compared to 13 patients without delusions



(2.50 < T < 4.50)