

## CASE REPORT

## Coexistent digital gouty and infective flexor tenosynovitis

Qasim Akram,<sup>1</sup> Michael Hughes,<sup>2</sup> Lindsay Muir<sup>2</sup><sup>1</sup>Blackpool Teaching Hospitals NHS Foundation Trust, Blackpool, UK<sup>2</sup>Salford Royal Foundation Trust, Salford, Manchester, UK**Correspondence to**

Dr Qasim Akram, qasim.akram.qa@gmail.com

Accepted 13 June 2016

**SUMMARY**

Flexor tenosynovitis of the hand is often caused by trauma or infection. Gouty tenosynovitis is an uncommon presentation of the condition and is usually misdiagnosed as infection with the patient undergoing surgery. The coexistence of infection and gout causing flexor tenosynovitis has never been described before in the literature; we report the first ever case and emphasise the importance of its awareness for optimal treatment. A 54-year-old man was initially diagnosed and treated as having infective flexor tenosynovitis and, later, due to a lack of improvement in his symptoms, was discovered to also have gout. We review the literature and suggest management strategy for use in daily clinical practice, including an algorithm, for this presentation.

**BACKGROUND**

Flexor tendon tenosynovitis (FTS) of the hand is often due to trauma, or infection caused by bacteria or TB, but other causes may include inflammatory diseases such as gout or inflammatory arthritis.<sup>1–8</sup> We report the first case report, to the best of our knowledge, of the coexistence of infection and gout of the flexor tendon.

FTS is an uncommon presentation of gout and can rarely be the first manifestation of the condition. A number of case reports and series have been published in the literature describing gouty tenosynovitis affecting the flexor tendons; usually initially diagnosed as infection, with the true gouty aetiology only being discovered at the time of surgery.<sup>1–6</sup>

An awareness of the possibility of gouty FTS with concomitant infection, as a clinical entity, is of extreme importance and could potentially prevent the need for surgery. We review the literature and provide a suggested clinical assessment and management strategy for such a presentation for use in daily practice.

**CASE PRESENTATION**

A 54-year-old man presented acutely to the orthopaedic department, with a 1-week history of a swollen left index finger. He had suffered a laceration to this finger while putting out his refuse and since then had been experiencing worsening pain, swelling and erythema. He denied symptoms of fever and was systemically well. His medical history consisted of asthma and hypertension.

On examination, there was gross swelling to his left index finger, maximal over his proximal phalanx with moderate erythema and reduced

flexion in left index finger proximal interphalangeal (PIP) and metacarpophalangeal (MCP) joints. He was able to fully flex his distal interphalangeal joint. There was moderate tenderness in the flexor tendon sheath distribution.

A flexor tendon sheath infection was suspected and he was started on intravenous antibiotic therapy. The following morning, due to a lack of improvement of the finger, he underwent exploratory surgery and a washout of the flexor tendon sheath via a Bruner incision. *Staphylococcus aureus* was isolated and he was started on oral antibiotic therapy—ciprofloxacin and rifampicin—due to penicillin allergy, and on the advice of the local microbiology team, for a planned duration of 6 weeks.

Fifteen days later, postoperation, the patient's finger remained swollen and erythematous with minimal discharge. He therefore underwent a further debridement and washout. Owing to a further lack of improvement, he had a further three washouts over the next few weeks. His latest synovial fluid analysis revealed the presence of gouty crystals as well as *S. aureus* bacterium. Rheumatology advice was sought and the patient started on a week-long course of 500 µg colchicine orally.

A week later, 1 month after his initial presentation, he was seen in the rheumatology clinic. He reported an overall improvement in his symptoms on colchicine, but on direct questioning he disclosed a year long history of intermittent joint pain and swelling affecting his hands, wrists, elbows and shoulders, consistent with recurrent gouty-type attacks. He denied any relevant family history, but admitted to drinking more than 10 units of alcohol on a daily basis. He was found to have evidence of, swollen and tender joints, including the right and left index finger MCP and PIP joints, and the flexor tendons. There was also swelling and tenderness over wrists and elbows, and evidence of gouty tophi over his elbows.

**INVESTIGATIONS**

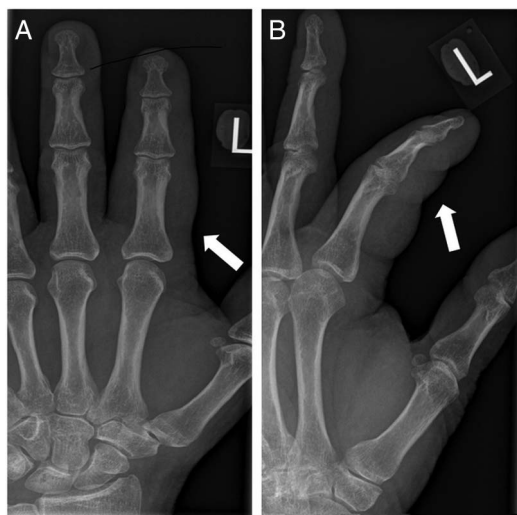Laboratory data revealed a normal white cell count and C reactive protein (CRP) of 8.5 mg/L; renal function was normal. A radiograph of the finger revealed diffuse soft tissue swelling of the digit (figure 1).

Serum urate (447 µmol/L (normal range ≤360 µmol/L)), CRP (80 mg/L) and erythrocyte sedimentation rate (67 mm/hours) were all elevated. Rheumatoid factor and anticyclic citrullinated antibodies (highly sensitive and specific for rheumatoid arthritis), were both negative.



CrossMark

**To cite:** Akram Q, Hughes M, Muir L. *BMJ Case Rep* Published online: [please include Day Month Year] doi:10.1136/bcr-2015-213601



**Figure 1** Left hand radiograph: (A) posterior-anterior and (B) oblique views. White arrows indicate significant digital soft tissue swelling of the left index finger. Note there is no evidence of erosive disease or features of osteomyelitis.

## TREATMENT

The patient was advised to reduce his alcohol intake (to within nationally recommended limits), and prescribed a further course of colchicine and naproxen. On further review, he had made good progress with an overall improvement in joint pain and swelling including of his index fingers. He had also completed a 6-week course of antibiotic therapy. Once the acute flare of his gouty disease had settled, he was started on long-term allopurinol treatment (note it is imperative that gout is quiescent before starting allopurinol therapy, to prevent the precipitation of a further gouty attack). He was started on 100 mg allopurinol and this dose was titrated in 100 mg increments up to a maintenance dose of 300 mg over 2 months.

## OUTCOME AND FOLLOW-UP

On further follow-up, the patient was on a maintenance dose of 300 mg allopurinol, which had resulted in achieving the target serum urate (below 360), an improvement of his tophi and no further relapses of gout.

## DISCUSSION

This case highlights the diagnostic challenge and clinical importance of the recognition of infection and acute gouty disease at the level of the flexor tendon. We provide a suggested assessment and management strategy (including an algorithm) of FTS for use in routine clinical practice (figure 2).

There are a limited number of case reports and series in the published literature describing gouty FTS of the digits.<sup>1–6</sup> Common clinical characteristics of these patients, although not exclusive, include a known personal or family history of gout, male sex, excess alcohol intake and a severe acutely painful digit mimicking infection, often with an associated feverish illness. However, Aslam *et al*<sup>6</sup> have reported the development of an atypical acute gouty FTS occurring in a young woman without a preceding history of known gout. Surgical intervention (with diagnostic and therapeutic implications), for example, exploration and tenosynovectomy, is usually inevitable, but with good reported outcomes, including significantly improved hand function and the absence of associated pain.<sup>3 5 6</sup>

Gout is a common (affecting 1–2% of the population)<sup>9</sup> and curable disease caused by an excess of monosodium urate crystals, which are deposited in the joints and soft tissues. The flexor (and also the extensor) tendons may also be affected by gout. The metabolic pathway of urate metabolism implicated in gout is well understood and, therefore, pleasingly to clinicians, amenable to intervention.<sup>9 10</sup> Serum urate may be elevated either due to increased production (eg, increased cell turnover) or decreased excretion (eg, renal failure), or due to a combination of both.<sup>9 10</sup> It is important to appreciate that ‘gout’ is a spectrum of diseases, from asymptomatic hyperuricemia to acute gouty attacks and chronic tophaceous gout.

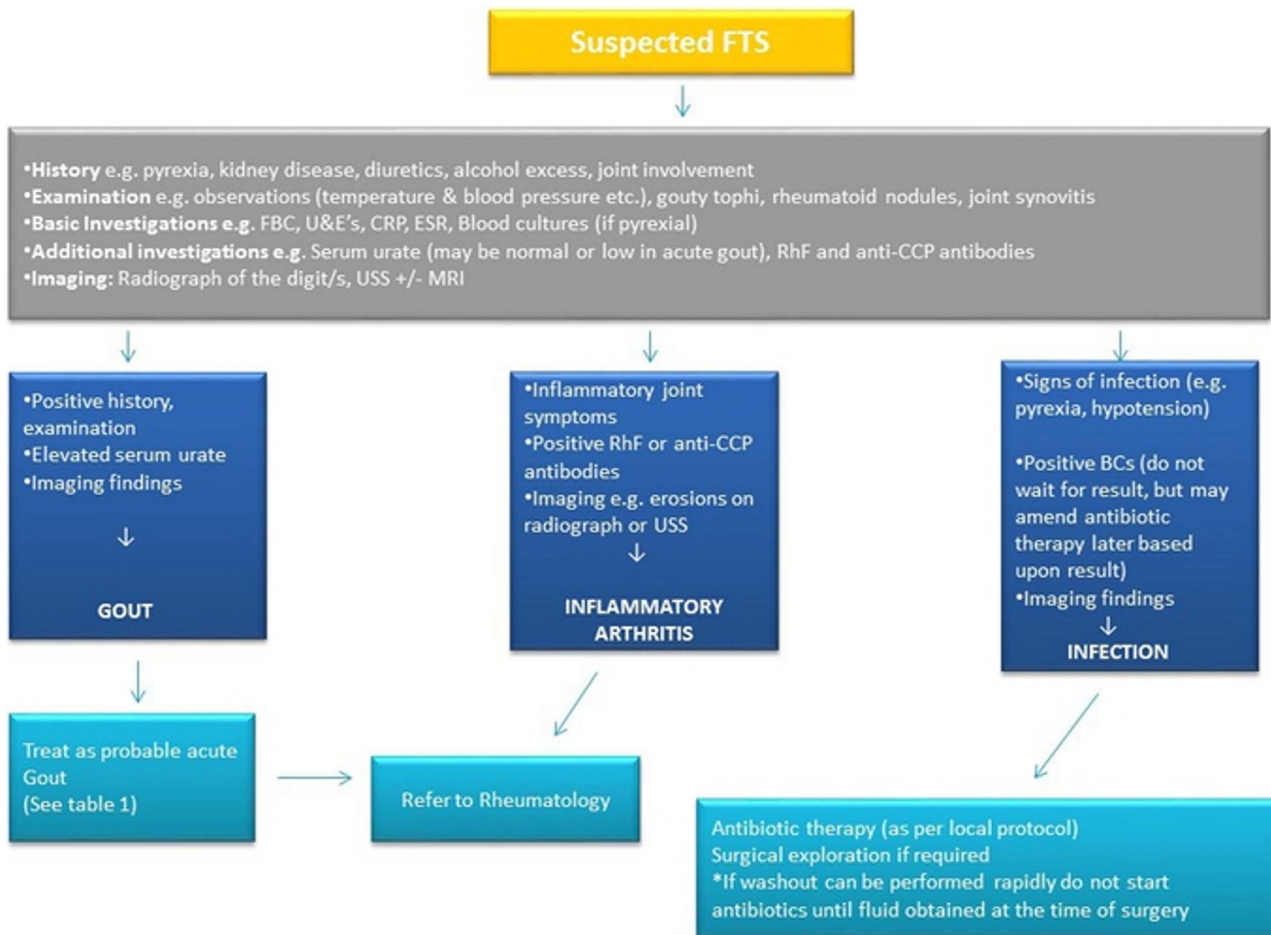
Acute gout may be exceptionally painful and is not uncommonly associated with a systemic feverish illness (eg, fever and significantly raised CRP). Gout is part of the ‘metabolic syndrome’ (eg, occurring concomitantly with hypertension, diabetes mellitus and hyperlipidaemia), and is also associated independently with cardiovascular risk. Treatment of acute gout includes colchicine, non-steroidal anti-inflammatories (NSAIDs) and steroid therapy.<sup>9–14</sup>

Steroids should be reserved for patients who are intolerant or have contraindications to colchicine or NSAIDs. Longer term treatment may be indicated for recurrent attacks and progressive joint destruction with urate-lowering therapy, for example, allopurinol and febuxostat in cases of severe renal impairment, poor compliance or intolerability to allopurinol.<sup>9–14</sup> Febuxostat may also improve the triglyceride/cholesterol profile in the metabolic syndrome.<sup>15</sup>

An absolutely key point, as highlighted by our case, is that when faced with the acutely inflamed flexor tendon an infective process must be suspected and treated first (ie, with appropriate intravenous antibiotic therapy and with a low threshold for surgical intervention). However, clinicians should also consider other possible differential diagnoses and the possibility of the coexistence of dual pathologies, including gout, trauma or inflammatory arthritis including spondyloarthritis.<sup>7 8</sup>

The absolute ‘gold standard’ method to diagnose gout is by the positive microscopic identification of urate (negatively birefringent) crystals from a relevant sample (eg, synovial fluid and/or tissue). Diagnostic imaging in this acute setting, in particular, high-frequency ultrasound (HFUS) to aid interventional procedures (eg, aspiration), is an exciting area that requires future research.<sup>16</sup> Gouty deposits have been demonstrated on ultrasound (eg, the ‘double contour sign’) and MRI.<sup>5</sup> In addition, Aslam *et al*<sup>6</sup> have reported the successful application of HFUS to obtain peritendinous fluid, which demonstrated urate crystals (thereby avoiding the need for surgical intervention). Of caution, serum urate may be normal or low during an acute attack.

We report the first case in the literature, to the best of our knowledge, of infection and gout both coexisting at the level of the digital flexor tendon in the same patient. As mentioned above, infection was initially suspected, and investigated and treated appropriately. Owing to the persistent and progressive nature of this patient’s symptoms, he underwent further debridement and washout, leading to the positive identification of urate crystals (and the presence of *S. aureus*). It could be argued that his infective process triggered an episode of acute gout, which acted as a focus for the persistence of his inflammatory symptoms, requiring further washouts, leading to colleagues suspecting presentation due to infection alone. The patient’s care benefited greatly from the input from colleagues in rheumatology in regard to the treatment of his acute gouty attack (and probable reason for the progressive worsening of his symptoms initially) and in regard to longer term treatment.



**Figure 2** Suggested management algorithm of flexor tenosynovitis of the hand. anti-CCP, anti-cyclic citrullinated peptide antibody; BCs, blood cultures; CRP, C reactive protein; ESR, erythrocyte sedimentation rate; RhF, rheumatoid factor; U&E's, urea and electrolytes.

In addition, other causes of acute tenosynovitis were considered (eg, inflammatory arthritis). The patient's risk factors for gout were explored (including excess alcohol intake) on focused questioning.

In conclusion, our case highlights the need for all clinicians to maintain a high index of suspicion when presented with acute FTS of the hand, for the coexistence of an infective and gouty process, and other differential diagnosis. A thorough clinical history is imperative. Although infection must be first considered, investigated and treated appropriately, a gouty process should be considered, in particular, in those patients with a history of known gout (including those receiving urate lowering therapy). Successful identification of gouty FTS could potentially avoid the need for the patient to undergo surgical intervention.

### Learning points

- ▶ Infection and gout can coexist in flexor tendon tenosynovitis (FTS).
- ▶ Accurate and prompt recognition of the conditions may prevent the need for surgery.
- ▶ Other aetiologies (in particular gout) should be considered if the patient fails to respond to treatment (and/or deterioration) of infected FTS.
- ▶ This case highlights the need for a coordinated multidisciplinary approach to the management of complex FTS.

**Competing interests** None declared.

**Patient consent** Obtained.

**Provenance and peer review** Not commissioned; externally peer reviewed.

### REFERENCES

- 1 Primm DD Jr, Allen JR. Gouty involvement of a flexor tendon in the hand. *J Hand Surg Am* 1983;8:863–5.
- 2 Moore JR, Weiland AJ. Gouty tenosynovitis in the hand. *J Hand Surg* 1985;10:291–5.
- 3 Abrahamsson SO. Gouty tenosynovitis simulating an infection. A case report. *Acta Orthop Scand* 1987;58:282–3.
- 4 Weinzeig J, Fletcher JW, Linburg RM. Flexor tendinitis and median nerve compression caused by gout in a patient with rheumatoid arthritis. *Plast Reconstr Surg* 2000;106:1570–2.
- 5 Weniger FG, Davison SP, Risin M, et al. Gouty flexor tenosynovitis of the digits: report of three cases. *J Hand Surg Am* 2003;28:669–72.
- 6 Aslam N, Lo S, McNab I. Gouty flexor tenosynovitis of the digits: report of three cases. *J Hand Surg Am* 2004;29:526.
- 7 Hmamouchi I, Bahiri R, Srfi N, et al. A comparison of ultrasound and clinical examination in the detection of flexor tenosynovitis in early arthritis. *BMC Musculoskelet Disord* 2011;12:91.
- 8 Pang HN, Teoh LC, Yam AK, et al. Factors affecting the prognosis of pyogenic flexor tenosynovitis. *J Bone Joint Surg Am* 2007;89:1742–8.
- 9 Roddy E, Mallen CD, Doherty M. Gout. *BMJ* 2013;347:f5648.
- 10 Rees F, Hui M, Doherty M. Optimizing current treatment of gout. *Nat Rev Rheumatol* 2014;10:271–83.
- 11 Zhang W, Doherty M, Bardin T, et al. EULAR evidence based recommendations for gout. Part II: Management. Report of a task force of the EULAR Standing Committee for International Clinical Studies Including Therapeutics (ESCSIT). *Ann Rheum Dis* 2006;65:1312–24.
- 12 Jordan KM, Cameron JS, Snaith M, et al. British Society for Rheumatology and British Health Professionals in Rheumatology guideline for the management of gout. *Rheumatology (Oxford)* 2007;46:1372–4.

- 13 Khanna D, Fitzgerald JD, Khanna PP, *et al.* 2012 American College of Rheumatology guidelines for management of gout. Part 1: systematic nonpharmacologic and pharmacologic therapeutic approaches to hyperuricemia. *Arthritis Care Res (Hoboken)* 2012;64:1431–46.
- 14 Khanna D, Khanna PP, Fitzgerald JD, *et al.* 2012 American College of Rheumatology guidelines for management of gout. Part 2: therapy and antiinflammatory prophylaxis of acute gouty arthritis. *Arthritis Care Res (Hoboken)* 2012;64:1447–61.
- 15 Saviola G, Benucci M, Abdi-Ali L, *et al.* Can febuxostat reduce triglyceride and cholesterol serum levels in gouty patients? *J Clin Rheumatol* 2014;20:394–5.
- 16 Ho CF, Chiou HJ, Chou YH, *et al.* Peritendinous lesions: the role of high-resolution ultrasonography. *Clin Imaging* 2003;27:239–50.

Copyright 2016 BMJ Publishing Group. All rights reserved. For permission to reuse any of this content visit <http://group.bmj.com/group/rights-licensing/permissions>.

BMJ Case Report Fellows may re-use this article for personal use and teaching without any further permission.

Become a Fellow of BMJ Case Reports today and you can:

- ▶ Submit as many cases as you like
- ▶ Enjoy fast sympathetic peer review and rapid publication of accepted articles
- ▶ Access all the published articles
- ▶ Re-use any of the published material for personal use and teaching without further permission

For information on Institutional Fellowships contact [consortiasales@bmjgroup.com](mailto:consortiasales@bmjgroup.com)

Visit [casereports.bmj.com](http://casereports.bmj.com) for more articles like this and to become a Fellow