

Color vision deficiency among medical students: an unnoticed problem

T Pramanik, MT Sherpa and R Shrestha

Department of Physiology, Nepal Medical College, Jorpati, Kathmandu, Nepal

Corresponding author: Dr. Tapas Pramanik, Associate Professor, Department of Physiology, Nepal Medical College, Jorpati, Kathmandu, Nepal; e-mail: drpramanik@hotmail.com

ABSTRACT

Color vision deficiency, most of the time remains an unnoticed problem; although it is not very rare. The faculty of appreciation of color is essential for our smooth daily activities. Unfortunately, even many doctors do not know the severity of their color vision deficiency and tend to assume it as slight, and a few, as in the general population, do not know about their disability. Some common difficulties reported by medical practitioners and medical students were in recognizing- widespread body color changes (pallor, cyanosis, jaundice, rashes, erythema of skin), colorful charts, slides, test-strips for blood and urine, body products: blood or bile in urine, faeces, sputum, vomit, microscopy, mouth and throat conditions, impressions presented in the Ishihara chart, titration end-points, tissue identification (surgery) etc. The present study was undertaken to evaluate the presence of congenital color vision deficiencies among the medical students. The study was carried out among the 1st and 2nd year medical students of Nepal Medical College and Teaching Hospital (n = 120) with the help of Ishihara chart, that was shown to all participants. They were asked to read the impressions in the color chart. The impression perceived by a person with normal color vision was different from the impression perceived by a person with color vision deficiency. It was noted that, among the study population (n = 120) 5.83% of the volunteers were color weak. Amongst the color-deficient volunteers, 57.0% were protanopic while 43.0% were deuteranopic. Medical students must be made aware of their congenital color vision deficiency and its effects on their work. Screening will enable the student and later the doctor to become aware of limitations in their powers of observation and devise ways of overcoming them; the patient will be protected from harm and litigation may be avoided when doctors have adapted their practice to their deficiency. Medical students and physicians must be screened for color vision deficiency and advised about it so they can take special care in clinical practice.

Keywords: Color blindness, Medical Students.

INTRODUCTION

Nature blessed us with a world rich in colors. The lush green wide fields, the brilliant colors of the fall foliage, the gorgeous blue of the sea, the majestic colorful horizon during sunrise and sunset gives immense pleasure to our eyes. The faculty of appreciation of color is essential for our smooth daily activities. Especially medical students and medical practitioners who lack this faculty partially or totally, experience a wide range of difficulty in their practice of medicine with a potentiality of errors. It is very difficult for them to appreciate and evaluate the presence and extent of colored clinical signs eg, fresh blood in vomit or stool, position of bacilli in sputum stained by Ziehl- Neelsen method or biopsy sample stained by H-E stain. The medical students must be making aware of their deficiencies and know their severity so that they can take special care in clinical practice. The present study was undertaken to evaluate the presence of congenital color vision deficiencies among the medical students – the future medical practitioners to make them cautious about their color

vision deficiencies so that they can be more alert during evaluation of colored clinical signs, as the effects of color vision deficiency on decision-making in general practice and some specialties are more than essential.

SUBJECTS AND METHODS

The study was carried out among the 1st and 2nd year medical students of Nepal Medical College and Teaching Hospital (n = 120) with the help of Ishihara chart. This chart consists of polychromatic plates containing printed figures made up of colored spots on a background of similarly shaped colored spots. The figures are intentionally made up of colors that are liable to look the same as the background, to an individual who is color-deficient.

Ishihara Chart was shown to all participants and they were asked to read the impressions in the color chart. The impression perceived by a person with normal color vision was different from the impression perceived by a person with color vision deficiency.

RESULTS

After careful screening it was noted that, among the study population (n = 120) 5.8% of the volunteers (n = 7) were color weak (Fig. 1). Amongst the color-deficient volunteers, 57.0% were protanopic (n = 4) while 43.0% were deuteranopic (n = 3) as represented in Fig. 2.

DISCUSSIONS

Color blindness is one of the common genetic disorders observed in all human populations. It is a sex linked recessive trait. The genes are located on the X chromosome within Xq28 band. It was reported that among the Jordanians 8.7% of the males and 0.3% of the females are color blind/weak.¹ Among the British male physicians 8.0% were reported as color deficient.²

The difficulties faced by the color deficient medical students and doctors in their work was documented where they expressed their own experiences,³⁻⁶ and a few studies reported the inconveniences of color-deficient professionals in clinical and laboratory skills.⁷⁻¹²

Some common difficulties reported in medical practice and as students were in recognizing- widespread body color changes (pallor, cyanosis, jaundice, rashes, erythema of skin), colorful charts, slides, test-strips for blood and urine, body products: blood or bile in urine, faeces, sputum, vomit, microscopy, mouth and throat conditions, impressions presented in the Ishihara chart, titration end-points, tissue identification (surgery).¹³

Studies among the British general practitioners revealed, person having mild color deficiency have fewer difficulties and having more color deficiency faced more difficulties. The works of Spandling revealed a wide range of difficulties experienced by color vision deficient person in their practice of medicine with a potentiality of errors.¹³ Study of Campbell *et al* revealed the physicians with color vision deficiencies could not identify and out line properly the clinical sign in 10 photographs of which 8 were vomit or stool (of which 6 showed fresh blood), one skin rash and for 1 to mark the position of bacilli in sputum stained by Ziehl-Neelson method, whereas physicians with normal color

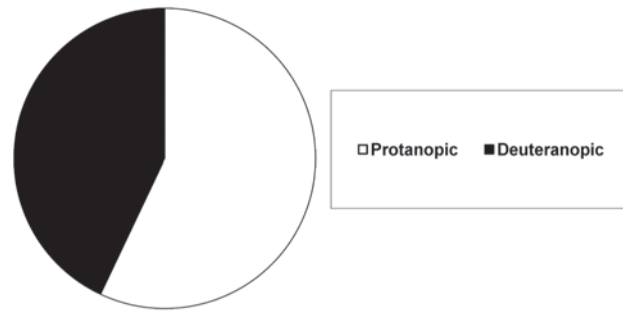


Fig. 2. Distribution of protanopia and deuteranopia among the color weak persons

vision did it easily.¹⁴ Examination of histologic and histopathologic microscopic sections relies upon differential colors provided by staining techniques, such as hematoxylin and eosin, to delineate normal tissue components and to identify pathologic alterations in test components. Given the prevalence of color deficiency (commonly called ‘color blindness’) in the general population, it is likely that this reliance upon color differentiation poses a significant obstacle for several medical students beginning a course of study that includes examination of histological slides. In the past, first-year medical students at Michigan State University who identified themselves as color deficient were encouraged to use color transparency overlays or tinted contact lenses to filter out problematic color. Recently, however, they had been offered a computer monitor adjusted to grayscale for in-lab work, as well as grayscale copies of color photomicrographs for examination purposes, grayscale images emphasize the texture of tissues and the contrasts between tissues as the students learn histological architecture, using this approach, color-deficient students have quickly learned to compensate for their deficiency by focusing on cell and tissue structure rather than on color variation. According to Rubin *et al*, besides the color-deficient students, gray scale photomicrographs might also prove instructional for students with normal (trichromatic) color vision, by encouraging them to consider structural characteristics of cells and tissues that might otherwise be overshadowed by stain colors.¹⁵

With increasing experience doctors tend to make more use of intuition when making decisions, while medical students are more likely to use analysis.¹⁶ Students are therefore at a stage when they would be relatively open to advice about their congenital color vision deficiency and its effects on their work. Screening enables the student and later the doctor to become aware of limitations in their powers of observation and devise ways of overcoming them; as a result confidence may be gained and anxiety avoided; an informed choice of career can be made; the patient is protected from harm

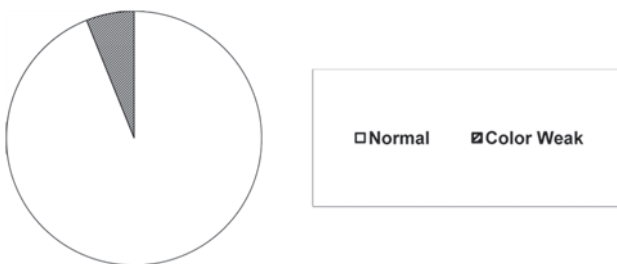

Fig. 1. Distribution of color weak persons among the population

and litigation may be avoided when doctors have adapted their practice to their deficiency.¹⁷ Many doctors do not know the severity of their condition and tend to assume it is slight, and a few, as in the general population, do not know they have any disability,^{18,19} and the problem needs attention. Thus it can be suggested that medical students and physicians should be screened for color vision deficiency and advised about it so they can take special care in clinical practice.

ACKNOWLEDGEMENTS

Authors are thankful to Prof. P. Roychowdhury, HOD, Physiology, NMC and Dr. S.B.Rizyal Principal, Nepal Medical College for their help and support.

REFERENCES

1. Al-Aqtum MT, Al Qawasmeh MH. Prevalence of color blindness in young Jordanians. *Ophthalmologica* 2001; 215: 39-42.
2. Spalding JA. Color vision deficiency in medical profession. *Brit J Med Pract* 1999; 49: 469-75.
3. Ahlenstiel H. Red-green blindness as a personal experience. Kodak Research Library, 1951.
4. Logan JS. The disability in so-called red-green blindness. An account based on many years of self-observation. *Ulster Med J* 1977; 46: 41-5.
5. Spalding JAB. The doctor with an inherited defect of colour vision: the effect on clinical skills. *J Roy Coll Gen Pract* 1993; 43: 32-3.
6. Currier JD. A two-and-a-half colour rainbow. *Arch Neurol* 1994; 51: 1090-92.
7. Tocantins LM, Jones JW. Defective colour vision and its handicaps in medicine. *Amer J Sci* 1993; 293: 243-9.
8. Little WS. Experience of a red-blind physician with the ophthalmoscope. Practical advantage of colour-blindness with a case. *Arch Ophthalm* 1881; 10: 20-22.
9. Olson IA. The use of colour filters by students with congenital color defects in the learning of histology. *Med Biol Illus* 1971; 21: 52-3.
10. Voke J. Colour Vision Testing in Specific Industries and Professions. London, UK: Keller 1980: 13-5.
11. Smith VC, Burns SA, Pokorny J. Colorimetric evaluation of urine-sugar tests by diabetic patients. In: Verriest G, ed. Colour Vision Deficiency. VI. Proceedings of the International Research Group on Colour Vision Deficiency; 1981. Dordrecht, Netherlands: Kluwer Academic Publishers 1982: 345-54.
12. Poole CJM, Hill DJ, Christie JL, Birch J. Deficient colour vision and interpretation of histopathology slides: cross sectional study. *Brit Med J* 1997; 315: 1279-81.
13. Spalding JA. Medical students and congenital color vision deficiency; unnoticed problems and the case for screening. *Occup Med (London)* 1999; 49: 247-52.
14. Campbell JL, Griffin L, Spalding JA, Mir FA. The effect of abnormal color vision on the ability to identify and outline colored clinical signs and to count stained bacilli in sputum. *Clin Exp Optom* 2005; 88: 376-81.
15. Rubin LR, Lakey WL, Kennedy FA, Stephenson RB. Using color and grey scale images to teach histology to color-deficient medical students. *Anat Sci Edu* 2009; 2: 84-8.
16. Bradley GW. Disease diagnosis and decision. Chichester, UK: John Wiley and Sons, 1986: 49-69.
17. Iinuma T, Handa Y. A consideration of the racial incidence of congenital dyschromats in males and females. *Med Probl Ophthal* 1976; 17: 151-7.
18. Spalding JAB. Doctors with inherited colour vision deficiency: their difficulties in clinical work. In: Cavonius CR, ed. Colour Vision Deficiencies XII. Proceedings of the International Research Group for Colour Vision Deficiency; 1995. Dordrecht, Netherlands: Kluwer Academic Publishers, 1997: 483-9.
19. Jacobs GH. Comparative Colour Vision. New York, NY (USA): Academic Press 1981: 159-97.