

Colour vision deficiencies in Alzheimer's disease

MONA PACHE¹, CLAUDIA H. W. SMEETS², PAOLA FONTANA GASIO², EGEMEN SAVASKAN², JOSEF FLAMMER¹, ANNA WIRZ-JUSTICE², HEDWIG J. KAISER¹

¹University Eye Clinic, Basel, Switzerland

²Centre for Chronobiology, Psychiatric University Clinic, Basel, Switzerland

Address correspondence to: H. J. Kaiser, University Eye Clinic Basel, Mittlere Str. 91, PO Box, CH-4012 Basel, Switzerland. Fax: (+41) 61 265 8652. Email: Hedwig-J.Kaiser@unibas.ch

Abstract

Objective: visual disorders are among the earliest symptoms of Alzheimer's disease. It is, however, still controversial as to whether Alzheimer's disease impairs colour vision. In this study, colour vision of Alzheimer's disease patients was tested using the Ishihara test and the PV-16 choice test. The latter test, primarily designed for children, was chosen in order to avoid problems due to cognitive decline.

Methods: 26 patients with mild to severe Alzheimer's disease (M:F=5:21; mean age: 80 ± 9 years, range: 53–95 years) and 25 controls (M:F=5:20; mean age 80 ± 10 years, range: 56–100 years) were rated after undergoing complete neuro-ophthalmologic examination.

Results: the Alzheimer's disease patients made significantly more unspecific errors in the Ishihara test ($P=0.02$) and in the PV-16 choice test ($P=0.0008$) than the controls. No relation between test performance and severity of Alzheimer's disease was found.

Conclusions: Alzheimer's disease patients have an unspecific colour vision deficiency independent of the severity of the disease.

Keywords: Alzheimer's disease, colour vision, Ishihara, PV-16

Introduction

Alzheimer's disease (AD) is a progressive neurodegenerative disease associated with deficits in visual function including stereopsis, contrast sensitivity, and motion detection [1]. The question as to whether AD also impairs colour vision is, however, still controversial. While some studies did not find a significant difference in colour vision between AD patients and controls [2–4], others have described various colour vision deficiencies in AD [5–7].

In general, three colour axes exist: the deutan (green), the protan (red) and the tritan (blue) axis. Light is perceived by photoreceptors specifically sensitive to one of the three axes. Some researchers came to the conclusion that AD patients make more tritan errors than controls [5, 6], while others found colour distortions in the deutan axis only [7]. Since the testing methods vary from study to study, direct comparisons are difficult. Another problem is that some of the applied colour vision tests might have been too complicated for patients with AD, leading to unreliable results. As recent studies indicate that problems in naming of colours may result from cognitive decline in AD [7], conventional colour tests should

probably not be applied in AD patients. Therefore, in this study colour vision of AD patients and controls was tested with the PV-16 choice test, a test specially designed for children. The main difference between this test and those for adults is that it has less intellectual demand and does not take long to perform, thereby reducing problems due to cognitive decline. The PV-16 test is specialised for detection of acquired colour vision deficits in the protan, deutan and tritan axis. In addition, the more commonly used Ishihara test was employed in a modified form. If a patient was unable to name numbers on pseudo-isochromatic plates, he or she was encouraged to follow the number with a finger. With the Ishihara test, protan and deutan deficiencies can be detected; however, deficits in the tritan axis are not recognised.

Methods

Study design

This study was planned as an observational retrospective cross-sectional study. In order to estimate the necessary

number of patients we performed a power calculation based on the following assumptions.

- i. Because subjects with known colour vision deficiency would be excluded from the study, we estimated a proportion of 1% colour vision deficiency in the control group.
- ii. In AD patients we estimated a proportion of 30% colour vision deficiency.
- iii. The power was set to 85% and the level of significance was set to 0.05.
- iv. The number of necessary subjects calculated according to Altman [8] was 50.

Subjects

Twenty-six institutionalised AD patients (M:F=5:21; mean age: 80 ± 9 years, range: 53–95 years) in the Psychiatric University Clinic Basel, Switzerland were consecutively recruited by one examiner (E.S.). All patients fulfilled clinical diagnostic criteria for AD according to ICD-10. If the diagnosis of AD was uncertain or dementia of different aetiology such as vascular dementia was apparent in magnetic resonance imaging (MRI), patients were excluded. According to the results of the Mini Mental Status Examination (MMSE) [9], subjects were divided into three groups: mild AD with MMSE score 30–20 ($n=10$); moderate AD with MMSE score 19–11 ($n=15$); and severe AD with MMSE score 10–0 ($n=1$). The mean MMSE score was 18 ± 5 , range 9–25.

Twenty-five controls (M:F=5:20; mean age 80 ± 10 years, range: 56–100 years) were consecutively recruited by one examiner (H.K.) from patients of the University Eye Clinic, Basel, Switzerland using minimisation [8] for absence/prevalence of cataract [8] to ensure balance between the groups. Controls presented with minor eye disease not affecting colour vision or for routine examination. Controls had no history nor symptoms of AD or any other form of dementia.

Mean MMSE score of the controls was 27 ± 2 , range 25–30. As visual acuity of at least 20/200 is required to perform colour vision tests [10], only subjects who fulfilled this criterion were included in the study. Subjects and patients with a history of colour blindness, diseases with known impact on colour vision (e.g. glaucoma, progressive cone dystrophy, hereditary dominant optic atrophy, multiple sclerosis) except cataract and age-related macular degeneration (AMD), or medication with known influence on colour vision (e.g. ibuprofen, indomethacin) were excluded from the study.

In general elderly people suffer more frequently from cataract and AMD, diseases with potential influence on colour vision [11–13]. Therefore these diseases were not considered as exclusion criteria; however, we tried to adjust the number of cataracts in AD patients ($n=15$) and controls ($n=14$) by minimisation. It is known that subjects with advanced AMD show an increased risk for

AD [14]. Therefore we refrained from adjustment for AMD in order to reflect normal conditions in an aged population. Mild to moderate AMD was present in 5 AD patients and in 2 controls.

Neuro-ophthalmologic examination

All patients underwent a neuro-ophthalmologic examination including best corrected visual acuity, pupillary reaction, random dot test for stereoscopic vision (Lang I test), motility, saccades, confrontation visual field, slit-lamp biomicroscopy, and Goldmann applanation tonometry. In order to avoid problems due to cognitive decline, visual acuity was tested using the Lea Hyvärinen (LH) test, a symbolic chart test specially designed for children. All examinations were performed by one experienced ophthalmologist (M.P.). Colour vision testing (Ishihara test, PV-16 choice test, see below) was performed by a different experienced examiner (C.S.).

Colour vision tests

Ishihara test

The Ishihara test, widely used for screening of deficits in the protan and deutan axes, consists of 38 pseudo-isochromatic plates, each with a circle of dots and a number inside the circle. Test plates are composed in such a way that subjects with normal vision can recognise the number in the circle, whereas subjects with colour vision deficits cannot differentiate between number and background.

When naming of the numbers in the Ishihara test was too difficult for AD patients, they were allowed to follow the number with their finger. Results were scored as pathological when three or more mistakes were made.

PV-16 choice test

The PV-16 choice test is especially suitable for detection of acquired colour vision deficits in the protan, deutan and tritan axes. It represents a children's version of the Farnsworth-Munsell-100-Hue test. The PV-16 choice test is unique with respect to other colour vision tests in that it uses large cap sizes, which give more information about colour vision function and also improves the ability of low vision individuals to perform this test. The test exists in a saturated and desaturated form. The saturated form is used when strong deficiencies are expected, while the desaturated form is used when the deficits are expected to be only small. In order to minimise the influence of cataract, which *per se* affects mainly the tritan axis, we chose the saturated form of the PV-16 choice test.

In the PV-16 choice test the ability to arrange colour caps in a smooth uninterrupted hue sequence, progressing

from the starting hue, is tested. Errors in the PV-16 test are plotted on a circular diagram, which is arranged so that correct ordering of caps results in a standard hue circle. Major translocation errors in the sequencing of the caps produce lines that cross the diagram from one side to the other. Protan, deutan, and tritan-type deficits are reflected by lines parallel to the respective three reference lines shown (see Figure 1). Two or more switches in the colour order were considered pathological.

Statistical analysis

Statistical analysis was performed using the statistical package StatView 4.5 (Abacus Concepts, Berkeley, CA). Comparisons of significance of difference for independent groups were performed using unpaired *t*-test. The chi-square statistic (2×2 table, contingency table) was used for frequency comparisons (nominal categorised variables). Significance was calculated using Fisher's exact test. Data were expressed as mean ± standard error of the mean and statistical significance was set to *P* < 0.05. Multiple regression and analysis of covariation was performed.

Results

Neuro-ophthalmologic examination

Visual acuity. Mean visual acuity was 20/50 ± 20/200 in AD patients and 20/32 ± 20/100 in controls. The lower visual acuity in the AD group appeared to be related

primarily to diminished ability to cooperate. To perform colour vision tests, a visual acuity of at least 20/200 is required, which was the criterion for inclusion in the study.

Pupillary reaction. Pupillary reaction was intact in all AD patients and controls.

Stereopsis. Stereopsis was intact in 56% of the AD patients and in 80% of the controls. The difference between the groups, however, was not statistically significant.

Motility. Hypometric saccades were present in 2 AD patients. In all other subjects, saccadic pursuit was normal.

Confrontation visual field. No gross visual field defects were detected in either the AD or the control group.

Biomicroscopy. Mild to moderate cataract was present in 15 AD patients and in 14 controls. In both the AD and the control group, 7 subjects were pseudophakic in both eyes. One AD patient presented with a tilted disc. Mild to moderate AMD was present in 5 AD patients and in 2 controls.

Intraocular pressure. Mean intraocular pressure was significantly lower in AD patients (12.2 ± 1.7) when compared to controls (15.3 ± 3.3) (*P* < 0.04).

Colour vision tests

Ishihara test

All subjects could recognise the non-pseudo-isochromatic control plate, thus showing that cognitive impairment did not influence the results. AD patients made significantly more errors than controls ($\chi^2 = 5.8$; *df* = 1; *P* = 0.02).

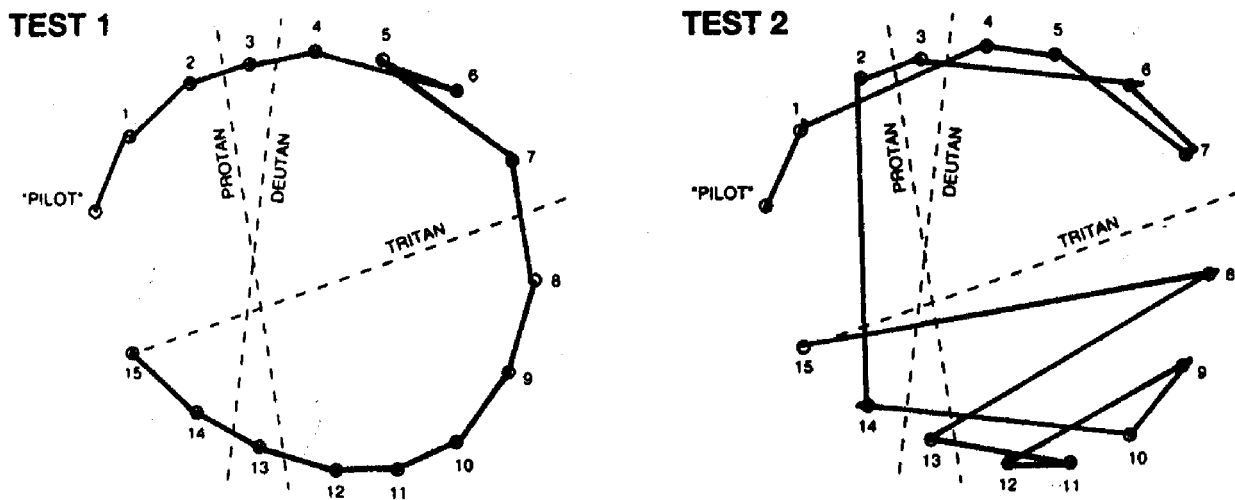


Figure 1. PV-16 test results are plotted on a circular diagram, which is arranged so that correct ordering of caps results in a standard hue circle, with the blue end of the spectrum at cap No. 1 and the violet end at cap No. 15. Major translocational errors result in lines that cross the circle from one side to another. Protan, deutan, and tritan-type deficits are reflected by lines parallel to the respective three reference lines shown. Left side: Normal performance of a control. Minor transpositions of adjacent caps, as seen here, were not scored as discrimination errors. Right side: Performance of an AD patient showing unspecific colour-vision deficiency.

The errors did not occur in a particular axis but remained unspecific. Only 62% of all AD patients completed the test without errors, in contrast with 88% of the controls. Considering each test plate separately, AD patients had more difficulties with recognising plates No. 5, 9, and 10–15 (see Table 1). No relation between performance in the Ishihara test and severity of AD was found.

PV-16 choice test

Forty-six per cent of AD patients and all controls could complete the PV-16 test in a reliable way. When problems in AD patients appeared to be more related to the understanding of the task itself than to problems in colour vision, results were not included in the analysis. Those who completed the test ($n=12$, 46%) made significantly more errors than controls ($\chi^2=13.0$; $df=1$; $P=0.0008$). Whereas 96% of the controls were able to perform this test without errors, only 42% ($n=5$) of the AD patients who completed the test did so without errors. The errors did not occur in specific axes but rather were unspecific (see Figure 1). No relation between performance in the PV-16 choice test and severity of AD was found.

Discussion

Our results demonstrate that AD patients suffer significantly more often from colour vision deficiencies than controls. Unlike previous studies, which found either no significant difference between AD patients and controls [2–4], or else disturbances along specific colour axes [5–7], the deficiencies found in this study were unspecific. Different testing methods may account at least in part for the heterogeneous outcome of the studies listed above. In the present study, colour vision of AD patients and controls was tested with a modified version of the Ishihara test and the PV-16 choice test, a test specially designed for children and people with poor vision. No relation between performance of both the Ishihara and the PV-16 choice tests and the severity of AD was found, which is in agreement with previous studies [7, 15]. By contrast, McCleary *et al.* [16] reported a correlation between errors in the Ishihara test and MMSE scores. The latter study suggests that the Ishihara test might be less suitable for determining whether colour vision deficiencies exist in AD patients. However, in our study

the Ishihara test was used in such a way that patients who had difficulties naming the numbers on the pseudo-isochromatic were encouraged to identify the number non-verbally. The fact that all patients recognised the non-isochromatic control plate either by naming or by following with their finger indicates that performance of the Ishihara test is not beyond the cognitive abilities of AD patients. However, while all subjects could complete the Ishihara test, only 12 of the 26 AD patients were able to complete the PV-16 test in a reliable way. Even though the PV-16 choice test was carried out with patience from the observer side, many AD patients appeared to have difficulties performing the test. They were unable to reproduce earlier findings, did not understand the task at all, or lost interest in the test before it was finished. In such cases, the test was rated as not assessable rather than pathological. For further analysis, data were analysed after correcting for missing values, thus possibly explaining the different outcome of the present study and previous studies with a similar design. This low rate of completion constrains the PV-16 test to AD patients capable of participating and is therefore not a good screening tool. But if the patient is able to perform the task, the PV-16 can detect colour vision deficiencies in all three axes.

Surprisingly, we also found a difference in visual acuity. This might be also due to the fact that the assessment of visual acuity seemed to take longer in patients than in controls. This might have also led to mental exhaustion of the AD patients before their final acuity was assessed. The difference in eye pressure is of no clinical relevance as data of both groups are within the normal range.

Several lines of evidence suggest that visual dysfunction in AD patients is related more to neuropathology of the visual cortex than to changes in the retina, optic nerve, or retina-calcarine pathways [1]. The striate cortex shows senile plaques, neurofibrillary tangles and astrocytic gliosis [17]. Furthermore, a large amount of neurofibrillary tangles was found in the peristriate cortex and infratemporal cortex of AD autopsy tissue [18–20]. However, a degeneration of large numbers of optic nerve axons and loss of retinal ganglion cells in AD patients has been described in several studies [21–24]. A decreased immunostaining for melatonin-1A (MT1) receptors in the highly degenerated photoreceptor cell layer of AD patients has also recently been demonstrated [25]. Since melatonin is a highly potent antioxidative substance, our results indicate that in AD patients a lack of melatonin might be responsible, at least in part, for the observed degeneration of photoreceptor cells [26]. As the degeneration was not restricted to one specific cone type this could possibly explain why the acquired colour vision deficiencies of AD patients observed in the present study were unspecific and not restricted to a specific colour axis.

Our study also has limitations that deserve comment. We assumed that the colour vision tests were appropriate

Table 1. AD patients had significantly more difficulties with recognising the Ishihara plates No. 5, 9, 10–15 than controls

Ishihara plate No.	5	9	10	11	12	13	14	15
χ^2 (df=1)	5.4	8.4	12.5	12.5	12.5	9.4	6.8	6.8
P-value	0.05	0.01	0.0006	0.0006	0.0006	0.005	0.02	0.02

for ruling out problems due to cognitive decline. Yet the PV-26 test could only be performed by less than half of the AD patients, suggesting that even this carefully chosen test has limitations in application. In spite of good age matching, the control group differed from the AD group in visual acuity. Recruiting and testing was not optimal with regard to duration of test and observer bias. Nevertheless, we have quite reasonable evidence that AD patients suffer from an unspecific colour vision deficiency. Further functional and neuroanatomic studies are underway to follow up this possibility.

Acknowledgements

The authors thank Birgit Förster, Dorothee Siefert, and Christian Prünke for their kind help in recruiting the controls.

Funding

This study was supported by the Velux Foundation. CS received grants from the Hersenstichting Nederland, Stichting Fonds Dr. Christine Buisman, Faculteit der Natuurwetenschappen, Wiskunde en Informatica of the Universiteit van Amsterdam, and a STUNT-grant for her summer studentship in Basel.

References

1. Holroyd S, Shepherd ML. Alzheimer's disease: a review for the ophthalmologist. *Surv Ophthalmol* 2001; 45: 516–24.
2. Bassi CJ, Solomon K, Young D. Vision in aging and dementia. *Optom Vis Sci* 1993; 70: 809–13.
3. Kiyosawa M, Bosley TM, Chawluk J *et al.* Alzheimer's disease with prominent visual symptoms. Clinical and metabolic evaluation. *Ophthalmology* 1989; 96: 1077–85; discussion 1085–6.
4. Wijk H, Sivik L. Some aspects of colour perception among patients with Alzheimer's disease. *Scand J Caring Sci* 1995; 9: 3–9.
5. Cronin-Golomb A, Sugiura R, Corkin S, Growdon JH. Incomplete achromatopsia in Alzheimer's disease. *Neurobiol Aging* 1993; 14: 471–7.
6. Kurylo DD, Corkin S, Dolan RP, Rizzo JF 3rd, Parker SW, Growdon JH. Broad-band visual capacities are not selectively impaired in Alzheimer's disease. *Neurobiol Aging* 1994; 15: 305–11.
7. Wijk H, Berg S, Sivik L, Steen B. Colour discrimination, colour naming and colour preferences among individuals with Alzheimer's disease. *Int J Geriatr Psychiatry* 1999; 14: 1000–5.
8. Altman DG. *Practical Statistics for Medical Research*. London: Chapman & Hall, 1991.
9. Folstein MF, Folstein SE, McHugh PR. "Mini-mental state". A practical method for grading the cognitive state of patients for the clinician. *J Psychiatr Res* 1975; 12: 189–98.
10. Schneider T. Einführung in die Farbsinnprüfung, Teil 1: Einflussgrößen, pseudoisochromatische Tafeln, Farbflecktests. *Z prakt Augenheilkd* 1989; 10: 29–35.
11. Frennesson C, Nilsson UL, Nilsson SE. Colour contrast sensitivity in patients with soft drusen, an early stage of ARM. *Doc Ophthalmol* 1995; 90: 377–86.
12. Fristrom B, Lundh BL. Colour contrast sensitivity in cataract and pseudophakia. *Acta Ophthalmol Scand* 2000; 78: 506–11.
13. Holz FG, Gross-Jendroska M, Eckstein A, Hogg CR, Arden GB, Bird AC. Colour contrast sensitivity in patients with age-related Bruch's membrane changes. *Ger J Ophthalmol* 1995; 4: 336–41.
14. Klaver CC, Ott A, Hofman A, Assink JJ, Breteler MM, de Jong PT. Is age-related maculopathy associated with Alzheimer's Disease? The Rotterdam Study. *Am J Epidemiol* 1999; 150: 963–8.
15. Cronin-Golomb A, Corkin S, Rizzo JF, Cohen J, Growdon JH, Banks KS. Visual dysfunction in Alzheimer's disease: relation to normal aging. *Ann Neurol* 1991; 29: 41–52.
16. McCleary R, Shankle WR, Mulnard RA, Dick MB, Ishihara test performance and dementia. *J Neurol Sci* 1996; 142: 93–8.
17. Beach TG, McGeer EG. Lamina-specific arrangement of astrocytic gliosis and senile plaques in Alzheimer's disease visual cortex. *Brain Res* 1988; 463: 357–61.
18. Arnold SE, Hyman BT, Flory J, Damasio AR, Van Hoesen GW. The topographical and neuroanatomical distribution of neurofibrillary tangles and neuritic plaques in the cerebral cortex of patients with Alzheimer's disease. *Cereb Cortex* 1991; 1: 103–16.
19. Braak H, Braak E, Kalus P. Alzheimer's disease: areal and laminar pathology in the occipital isocortex. *Acta Neuropathol (Berl)* 1989; 77: 494–506.
20. Lewis DA, Campbell MJ, Terry RD, Morrison JH. Laminar and regional distributions of neurofibrillary tangles and neuritic plaques in Alzheimer's disease: a quantitative study of visual and auditory cortices. *J Neurosci* 1987; 7: 1799–808.
21. Blanks JC, Hinton DR, Sadun AA, Miller CA. Retinal ganglion cell degeneration in Alzheimer's disease. *Brain Res* 1989; 501: 364–72.
22. Blanks JC, Torigoe Y, Hinton DR, Blanks RH. Retinal degeneration in the macula of patients with Alzheimer's disease. *Ann N Y Acad Sci* 1991; 640: 44–6.
23. Hinton DR, Sadun AA, Blanks JC, Miller CA. Optic-nerve degeneration in Alzheimer's disease. *N Engl J Med* 1986; 315: 485–7.
24. Sadun AA, Bassi CJ. Optic nerve damage in Alzheimer's disease. *Ophthalmology* 1990; 97: 9–17.
25. Savaskan E, Wirz-Justice A, Olivieri G *et al.* Distribution of melatonin MT1 receptor immunoreactivity in human retina. *J Histochem Cytochem* 2002; 50: 519–26.
26. Marchiafava PL, Longoni B. Melatonin as an antioxidant in retinal photoreceptors. *J Pineal Res* 1999; 26: 184–9.

Received 25 June 2002; accepted in revised form 10 February 2003