

# UC Irvine

## UC Irvine Previously Published Works

### Title

Combined photodynamic and photothermal induced injury enhances damage to in vivo model blood vessels.

### Permalink

<https://escholarship.org/uc/item/2w72d325>

### Journal

Lasers in surgery and medicine, 34(5)

### ISSN

0196-8092

### Authors

Kelly, Kristen M  
Kimel, Sol  
Smith, Tia  
[et al.](#)

### Publication Date

2004

### DOI

10.1002/lsm.20041

### Copyright Information

This work is made available under the terms of a Creative Commons Attribution License, available at <https://creativecommons.org/licenses/by/4.0/>

Peer reviewed

# Combined Photodynamic and Photothermal Induced Injury Enhances Damage to In Vivo Model Blood Vessels

Kristen M. Kelly, MD,<sup>1\*</sup> Sol Kimel, PhD,<sup>1,2</sup> Tia Smith, BS,<sup>1</sup> Amy Stacy, BS,<sup>1,3</sup> Marie J. Hammer-Wilson, MS,<sup>1</sup> Lars O. Svaasand, PhD,<sup>1,4</sup> and J. Stuart Nelson, MD, PhD<sup>1</sup>

<sup>1</sup>Beckman Laser Institute, University of California, Irvine, California 92612

<sup>2</sup>Department of Chemistry, Technion-Israel Institute of Technology, Haifa 32000, Israel

<sup>3</sup>Department of Bioengineering, University of California, San Diego, California, 92093

<sup>4</sup>Norwegian University of Science and Technology, Trondheim N-7491, Norway

**Background and Objectives:** The degree of port wine stain (PWS) blanching following pulsed dye laser (PDL) therapy remains variable and unpredictable. Because of the limitations of current PDL therapy, alternative treatment approaches should be explored. The objective was to evaluate a novel methodology for selective vascular damage, combined photodynamic (PDT) and photothermal (PDL) treatment, using the in vivo chick chorioallantoic membrane (CAM) model.

**Study Design/Materials and Methods:** Thirty microliters of benzoporphyrin derivative monoacid ring A (BPD) solution was administered intraperitoneally into chick embryos at day 12 of development. Study groups were: (1) control (no BPD, no light); (2) BPD alone; (3) continuous wave irradiation (CW) alone (576 nm, 60 mW/cm<sup>2</sup>, 125 seconds); (4) CW+PDL; (5) BPD+PDL; (6) PDT (BPD+CW); (7) PDL alone (585 nm, 4 J/cm<sup>2</sup>); and (8) PDT+PDL (BPD + CW followed immediately by PDL). Vessels were videotaped prior to, and at 1 hour post-intervention and then assessed for damage based on the following scale: 0, no damage; 1, coagulation; 1.5, vasoconstriction; 2.0, coagulation+vasoconstriction; 2.5, angiostasis; 3.0, hemorrhage. Damage scores were weighted by vessel "order."

**Results:** PDT+PDL resulted in significantly ( $P < 0.01$ ) more severe vascular damage than was observed in any other study group: 127% more than PDT, 47% more than PDL alone.

**Conclusions:** PDT+PDL is a novel and promising approach for selective vascular damage and may offer a more effective method for treatment of PWS and other vascular skin lesions. *Lasers Surg. Med.* 34:407–413, 2004. © 2004 Wiley-Liss, Inc.

**Key words:** chick chorioallantoic membrane; blood vessels; photodynamic therapy; pulsed dye laser; port wine stain

## INTRODUCTION

Pulsed dye laser (PDL) treatment of port wine stain (PWS) produces reasonably good results in some patients because of its ability to destroy selectively dermal blood vessels. Yellow light emitted by a PDL (pulse duration

~1 millisecond) is preferentially absorbed by hemoglobin in PWS blood vessels and, after being converted to heat, causes thermal damage to the vessel wall and thrombosis [1–3]. The degree of PWS blanching following PDL therapy is variable and unpredictable and less than 20% of patients achieve complete blanching [4,5], even after multiple treatments (5–30 or more). One factor limiting therapeutic efficacy is the inability of PDL to destroy microvessels (diameter (D) < 20 μm) [6], which contribute significantly to the clinical appearance of PWS lesions. Because of the limited patient response to current PDL therapy, alternative treatment approaches should be explored.

Photodynamic therapy (PDT) has been evaluated for the clinical management of an array of human tumors [7]. Briefly, a photosensitizing drug is administered to the patient and, after a pre-selected time interval, the tissue-localized photosensitizer is exposed to light at a wavelength absorbed by the photosensitizer. Excited photosensitizer molecules subsequently react with substrates to generate short-lived highly reactive species, including singlet molecular oxygen, which cause irreversible damage to biologically important intracellular structures.

Despite the demonstrated propensity of PDT to destroy the tumor vascular compartment [8–10], PDT has been applied only rarely for treatment of PWS [11–13]. While reasonable success was achieved in terms of PWS blanching, skin necrosis resulted when blue light was used which might be attributed to the high light intensity used [11]. Skin necrosis similarly resulted with the use of red light, presumably because of the deep penetration of wavelengths greater than 600 nm [12]. Further, the photosensitizers utilized in these earlier studies resulted in 15–30 days of light sensitivity.

Contract grant sponsor: National Institutes of Health (to JSN); Contract grant numbers: GM-62177, EB002495, AR-47551; Contract grant sponsor: Air Force Office of Scientific Research; Contract grant sponsor: Beckman Laser Institute Endowment; Contract grant sponsor: Dermatology Foundation (to KMK); Contract grant sponsor: National Science Foundation (to TS and AS).

\*Correspondence to: Kristen M. Kelly, MD, 1002 Health Sciences Road East, Irvine, CA 92612. E-mail: KMKelly@uci.edu  
Accepted 20 February 2004  
Published online in Wiley InterScience  
(www.interscience.wiley.com).  
DOI 10.1002/lsm.20041

By careful selection of photosensitizer and wavelength for laser irradiation, PDT injury can be localized to vessels at a desired depth, allowing effective treatment of vascular lesions without injury to the overlying skin. In the present study, we investigate the suitability of benzoporphyrin derivative monoacid ring A (BPD), a second-generation, vascular-specific photosensitizer [14–18]. BPD is expected to be an excellent photosensitizer for PWS treatment based on the following characteristics: (1) vascular compartmentalization [14–17]; (2) proven safety and efficacy in humans [19,20]; (3) photosensitivity of relatively short duration (1–5 days depending on dose administered) [20]; and (4) presence of an absorption peak in the desired yellow wavelength range. BPD has a strong absorption band at  $\lambda = 576$  nm (molar extinction coefficient  $\epsilon = 15,000 \text{ M}^{-1} \text{ cm}^{-1}$ ), in addition to its main absorption peak at  $\lambda = 690$  nm ( $\epsilon = 30,000 \text{ M}^{-1} \text{ cm}^{-1}$ ) [14]. Hemoglobin, the targeted chromophore in PWS treatment, also has an absorption peak in the yellow spectral region. Further, yellow light has a penetration depth of  $<1,000 \mu\text{m}$ , which will confine therapeutic effects to the upper dermis and targeted PWS vessels.

While either PDT or PDL therapy alone can be used for treatment of vascular lesions, each has its limitations. By combining PDT-induced photochemical and PDL-induced photothermal injuries, an enhanced effect might be achieved leading to optimized selective vascular injury and, ultimately, improved PWS blanching [21]. The combination of PDT and PDL is a novel use of these modalities and offers exciting therapeutic potential. Sub-therapeutic PDT, using yellow light absorbed by BPD ( $\lambda = 576$  nm), should make PWS blood vessels more vulnerable to subsequent PDL irradiation by heating the pre-treated vessels compromised by PDT [22]. Use of yellow light for both PDT and PDL confines therapeutic effects to the upper 1,000  $\mu\text{m}$  of the dermis, containing ectatic PWS venules, while reducing risk of possible skin infarction, which could result from destruction of the deeper vascular plexus.

We report enhanced vascular injury achieved by combining PDT with PDL using the *in vivo* chick chorioallantoic membrane (CAM) model, as previously used for studying vascular effects of BPD-PDT [23–25] or PDL [26–28] alone.

## MATERIALS AND METHODS

### CAM Model

The CAM is an established *in vivo* system for studying laser induced microvascular effects [23–28]. The CAM consists of a thin, three-dimensional vascular network located in the chick mesoderm, a transparent matrix that does not significantly absorb or scatter incident visible radiation. It allows direct observation of blood flow, with real-time inspection and video documentation, enabling identification of pre-capillary arterioles (A), and post-capillary venules (V) [29,30].

The extensive CAM microvascular network (Fig. 1) is characterized according to the following branching pattern [29]. Capillaries ( $D < 20 \mu\text{m}$ ) are barely observable at the magnification used ( $70\times$ ); they are defined as order-0

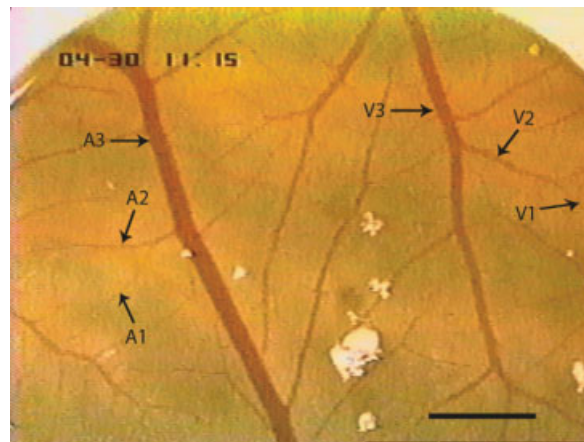


Fig. 1. Demonstration of characteristic branching pattern of chorioallantoic membrane (CAM) microvascular network. The scale bar equals 500  $\mu\text{m}$ . Original magnification =  $70\times$ . [Figure can be viewed in color online via [www.interscience.wiley.com](http://www.interscience.wiley.com).]

vessels. A1 and V1 designate, respectively, arterioles and venules of order-1, with  $D = 20\text{--}50 \mu\text{m}$ . The convergence of two order-1 vessels is assigned as an order-2 vessel, A2 or V2, with  $D = 60\text{--}90 \mu\text{m}$ . Similarly, two order-2 vessels form an order-3 vessel, A3 or V3, with  $D > 100 \mu\text{m}$ . Arterial (An) and venous (Vn) trees inside a selected area to be irradiated were considered independent observables.

### CAM Preparation

Fertilized white Leghorn chicken eggs were placed in a hatching incubator with hourly tilting, set at  $38^\circ\text{C}$  and 60% humidity. At day 4 of embryonic age (EA 4), 4 ml of albumin were aspirated with a 20-G needle, through a hole drilled at the narrow apex, to create a false air sac. At EA 7, a 20 mm diameter opening was cut into the shell and covered with a sterile Petri dish; incubation was continued in a static incubator adjusted to  $38^\circ\text{C}$  and 70% humidity. At EA 12, when CAM vasculature was fully developed, a Teflon O-ring (6 mm inner diameter, 1.4 mm annular width) was placed aseptically on a well-vascularized site of the CAM, situated above the yolk sac for improved visibility. The Teflon O-ring covered an area of 30  $\text{mm}^2$  that typically contained some 100 vessels of various diameters [23,26,27] and provided a baseline on the video record.

### BPD Administration

BPD (Verteporfin<sup>®</sup>, QLT, Vancouver, BC, Canada) liposomal powder was reconstituted in water, 2 mg/ml. A working solution of 0.125 mg/ml was prepared by diluting the stock preparation with 5% dextrose [23,24], protected from light and used within 4 hours of preparation.

BPD (30  $\mu\text{l}$  containing  $\sim 4 \mu\text{g}/\text{CAM}$ , i.e., 1 mg/kg wet weight of the embryo) was administered intraperitoneally (IP) into the chick embryo using a Hamilton syringe with a 30-G needle [24]. Sterile blackened Petri dishes were placed over the eggshell openings and further manipulations performed in subdued light.

### CW Laser Irradiation

A diffused beam, CW argon pumped-dye laser (Lumenis, Santa Clara, CA) tuned to 576 nm irradiated the area inside the Teflon O-ring, using a power density of 60 mW/cm<sup>2</sup> for 125 seconds, yielding a total radiant exposure of 7.5 J/cm<sup>2</sup>. This value is higher than used in previous experiments, 5 J/cm<sup>2</sup> [24], because the absorption coefficient of BPD at 576 nm (15,000 M<sup>-1</sup> cm<sup>-1</sup>) is lower than that at 690 nm (30,000 M<sup>-1</sup> cm<sup>-1</sup>) [14]. The radiant exposure used in the present study is, however, significantly lower than that reported for 440 nm irradiation [25] after normalizing for BPD absorption.

### PDL Irradiation

A 585 nm PDL (ScleroPlus™, Candela, Wayland, MA) with a 1.5 milliseconds pulse duration, with which photo-thermal effects on the CAM vasculature have been determined previously [26–28], irradiated the area inside the Teflon O-ring at 4 J/cm<sup>2</sup>, using a 7 mm diameter spot.

### Photodynamic Therapy

Ten minutes after BPD administration ( $\Delta t_1$ ), CW irradiation was performed as described above using a power density of 60 mW/cm<sup>2</sup> for 125 seconds, yielding a total radiant exposure of 7.5 J/cm<sup>2</sup>.

### Study Groups

The following intervention groups were studied (Table 1): (1) control; (2) BPD alone; (3) CW alone; (4) CW + PDL ( $\Delta t_2 < 1$  minute); (5) BPD+PDL ( $\Delta t_1 = 10$  minutes); (6) PDT ( $\Delta t_1 = 10$  minutes); (7) PDL alone; (8) PDT + PDL ( $\Delta t_1 = 10$  minutes;  $\Delta t_2 < 1$  minute). Here,  $\Delta t_1$  denotes the interval between drug administration and light initiation (either CW or PDL), chosen to optimize vascular occlusion efficacy time, and  $\Delta t_2$  the time interval between CW and PDL irradiation. Three complete experiments (evaluating all study groups) were performed.

### Video Microscopic Documentation

Immediately prior to BPD administration, the CAM area was videotaped with a CCD color camera (Sony, model DXC-101) mounted on a stereomicroscope (Olympus, model SZH), using oblique illumination provided by a cold white fiberoptic light guide (Fiber-Lite, Dolan-Jenner, Lawrence, MA). This enabled identification of vessel topology.

Vessel type (A or V) was identified by direction of blood flow. At 1 hour post-irradiation, the CAM area inside the O-ring was videotaped again. Videotapes were analyzed off-line for quantification of vascular damage. Total magnification on the color monitor (Sony, model KV-1393R) was 70 $\times$ .

### Damage Assessment

Vessels were assessed for damage score based on the following scale [23,24]: 0, no damage; 1, coagulation; 1.5, vasoconstriction; 2.0, coagulation + vasoconstriction; 2.5, angiostasis; 3.0, hemorrhage. These scores were multiplied by the vessel “order” [29] as follows: order-1 (D = 20–50  $\mu$ m), order-2 (D = 60–90  $\mu$ m), or order-3 (D > 100  $\mu$ m) yielding weighted scores of 0–3, 0–6, or 0–9, respectively.

Each egg was given one weighted score for each vessel type (whether A or V) based on the highest damage observed. A composite vessel damage score was determined for each egg by selecting the highest damage score (A or V). The mean damage scores  $\pm$  standard errors of the mean (SEM) were evaluated for each vessel type (A, V, or composite), in each study group.

### RESULTS

Table 2 provides the mean weighted damage scores  $\pm$  SEM for the first five study groups after observation of venules, arterioles, and both vessel types (composite). It should be noted that no vascular damage was observed for the control and BPD only groups. Intermediate levels of vascular damage were observed in the CW alone, CW + PDL and BPD + PDL groups. These study groups provide a source of comparison for the PDT, PDL alone and PDT + PDL study groups whose results are described below.

Table 3 provides the mean weighted damage scores  $\pm$  SEM for the PDT, PDL alone, and PDT + PDL study groups. PDT + PDL resulted in significantly more severe vascular damage than any other study group: 127% more than PDT ( $P < 0.01$ ), 47% more than PDL alone ( $P < 0.01$ ). Analysis of variance (ANOVA) confirmed statistically significant differences between the groups ( $P < 0.01$ ).

Figure 2 displays characteristic CAM images before, and 1 hour post-intervention. The CAM that received PDT developed vasoconstriction of arterioles and venules as demonstrated by comparing Figure 2A (pre-intervention) with Figure 2D (1 hour post-intervention). The CAM that received PDL alone developed coagulation and vasocon-

**TABLE 1. Legend of Text Label and Light Parameters for Study Groups**

Study group	Label in text	Light parameters
No BPD, no light	Control	NA
BPD only	BPD alone	NA
CW irradiation only	CW alone	60 mW/cm <sup>2</sup> , 125 seconds
CW + PDL irradiation	CW + PDL	60 mW/cm <sup>2</sup> , 125 seconds; 7 mm, 4 J/cm <sup>2</sup>
BPD + PDL irradiation	BPD + PDL	7 mm, 4 J/cm <sup>2</sup>
BPD + CW irradiation	PDT	60 mW/cm <sup>2</sup> , 125 seconds
PDL irradiation only	PDL alone	7 mm, 4 J/cm <sup>2</sup>
BPD + CW + PDL irradiation	PDT + PDL	60 mW/cm <sup>2</sup> , 125 seconds; 7 mm, 4 J/cm <sup>2</sup>

**TABLE 2. Mean Weighted Damage Scores and Standard Errors of the Mean (SEM) by Chorioallantoic Membrane (CAM) Vessel Type for the First Five Study Groups**

Study group (n)	Venule weighted damage $\pm$ SEM	Arteriole weighted damage $\pm$ SEM	Composite vessel damage $\pm$ SEM
Control (3)	0 $\pm$ 0	0 $\pm$ 0	0 $\pm$ 0
BPD (3)	0 $\pm$ 0	0 $\pm$ 0	0 $\pm$ 0
CW alone (12)	3.3 $\pm$ 0.8	2.8 $\pm$ 0.6	3.8 $\pm$ 0.7
CW + PDL (14)	3.5 $\pm$ 0.7	3.5 $\pm$ 0.6	3.9 $\pm$ 0.7
BPD + PDL (14)	2.6 $\pm$ 0.6	2.4 $\pm$ 0.6	2.8 $\pm$ 0.6

n, number of CAM in each study group; BPD, benzoporphyrin derivative monoacid ring A; PDL, pulsed dye laser; CW, continuous wave irradiation.

striction in arterioles and most venules as observed by comparing Figure 2B (pre-intervention) with Figure 2E (post-intervention). The final pictured CAM received combined PDT + PDL (Fig. 2C pre-intervention and Fig. 2F post-intervention) resulting in angiostasis of all arterioles and venules, only clot formation is visible. By comparing the various images, the enhanced vascular injury potential of combined PDT + PDL is clearly demonstrated.

## DISCUSSION

In our study, the advantages of PDT + PDL over either modality alone were demonstrated convincingly as combined therapies resulted in 127% more vascular injury than PDT ( $P < 0.01$ ) and 47% more than PDL alone ( $P < 0.01$ ). As such, the PDT + PDL approach achieved synergism in this study.

Interestingly, the CW alone group was noted to produce vascular injury. We would have expected low level CW irradiation alone to have a minimal effect on the vasculature. This prediction appeared supported by the fact the damage scores of the CW + PDL group were fairly similar to those of the PDL alone group. However, in light of the injury observed in the CW alone group, the effects of CW irradiation require further study.

It is very unlikely that the observed CW effects are due to thermal effects alone. Exposing the CAM vasculature to yellow light for  $\Delta t = 125$  seconds results in thermal diffusion over a distance  $L$ , given approximately by  $L = \sqrt{\chi \Delta t}$  where the thermal diffusivity is  $\chi = 1.2 \times 10^{-7} \text{ m}^2/\text{second}$  [27,28]. Heat will thus diffuse to a distance

of about  $L = 3.9$  mm from the vessel during exposure. The corresponding heating of a single superficial vessel of diameter larger than the optical penetration depth in blood, is approximately  $\Delta T : 2S\Delta tD/\rho C\pi L^2$ . The temperature rise  $\Delta T$  in a vessel of diameter  $D = 100 \mu\text{m}$  resulting from an irradiation  $S = 60 \text{ W/cm}^2$  for 125 seconds exposure, and specific heat per unit volume  $\rho C = 4.2 \text{ J/cm}^3 \text{ }^\circ\text{C}$ , will thus be in the range of  $0.01^\circ\text{C}$ . In the extreme case where the vessels cover the entire CAM surface in the area defined by the ring, the corresponding temperature rise will be about  $\Delta T = S\Delta t/\rho CL$ , i.e.,  $0.4^\circ\text{C}$ . It may be concluded that the temperature rise is well below  $1^\circ\text{C}$  and therefore, negligible.

Further evidence that the damage observed in the CW alone group is not due to thermal effects alone, is that the CW + PDL group demonstrated approximately the same level of damage as the PDL alone group and significantly less than that observed for PDT + PDL.

Histologically, PWS consist of dilated engorged capillaries with a single layer of endothelial cells [31]. Optical Doppler tomography (ODT) evaluation of vasculature during BPD-mediated sub-threshold PDT demonstrated transient changes, including vessel wall thrombus formation [22]. Because PWS vessels have been demonstrated to have venous characteristics, sub-threshold PDT induced thrombi are not likely to be subsequently dislodged by the low venous blood pressure present in PWS. It is also important to note that PDT, unlike PDL, affects all vessels including capillaries.

Yellow light emitted by the PDL is preferentially absorbed by hemoglobin in PWS allowing relatively selective

**TABLE 3. Mean Weighted Damage Scores and SEM by CAM Vessel Type for the PDT, PDL Alone, and PDT + PDL Study Groups**

Study group (n)	Venule weighted damage $\pm$ SEM	Arteriole weighted damage $\pm$ SEM	Composite vessel damage $\pm$ SEM
PDT (14)	2.1 $\pm$ 0.6	1.9 $\pm$ 0.6	2.6 $\pm$ 0.6
PDL alone (16)	3.6 $\pm$ 0.4	3.7 $\pm$ 0.5	4.0 $\pm$ 0.4
PDT + PDL (15)	5.3 $\pm$ 0.6	4.9 $\pm$ 0.4	5.9 $\pm$ 0.4*

PDT, photodynamic therapy.

\*Denotes statistically significant difference as compared to PDT or PDL alone ( $P < 0.01$ ).

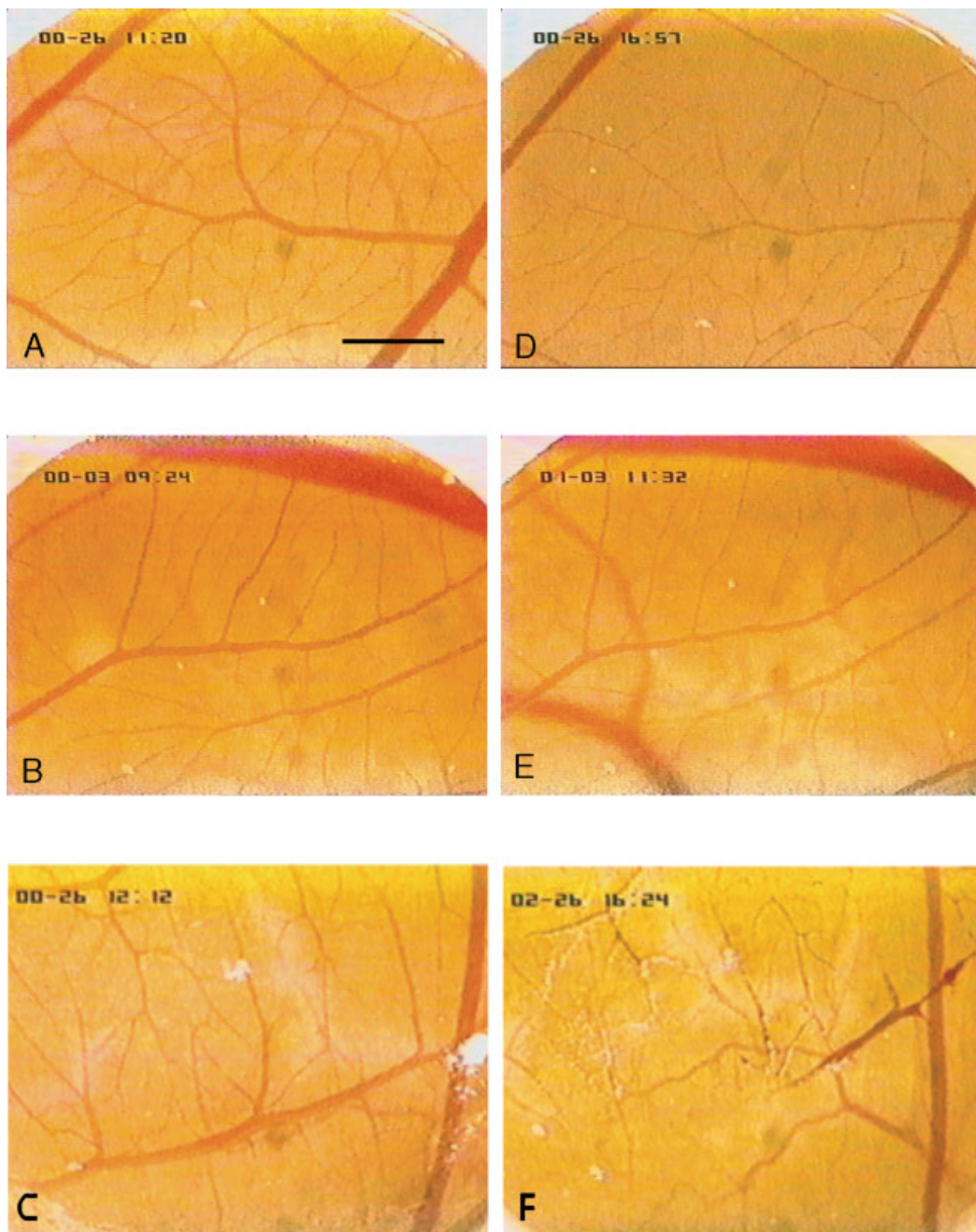


Fig. 2. Characteristic CAM images before (**A**, **B**, **C**) and 1 hour-post (**D**) PDT; (**E**) PDL alone; and (**F**) PDT + PDL. Scale bar in **Panel A** equals 500  $\mu\text{m}$  and applies to all figures. Original magnification = 70 $\times$ . [Figure can be viewed in color online via [www.interscience.wiley.com](http://www.interscience.wiley.com).]

destruction of ectatic capillaries in the superficial dermis [32]. Heat induced by light absorption results in an intravascular coagulum [33] and endothelial cell damage [34] followed by hemorrhage and vasculitis [35]. One month after PDL treatment, abnormally dilated vessels are eliminated leaving small vessels with thickened endothelial walls [34]. These residual small vessels may, in some cases, contribute to incomplete PWS blanching.

By combining PDT-induced photochemical and PDL-induced photothermal injury, an enhanced effect can be achieved resulting in improved, yet still selective vascular injury and ultimately, we believe, optimized PWS blanching. Our technique uses a sub-therapeutic PDT exposure to create an initial vascular injury in blood vessel walls [22], especially smaller vessels (potentially not affected by PDL alone). PDL irradiation immediately, or after a short

interval following PDT, then heats selectively the pre-treated vessels compromised by PDT. Use of yellow light for both PDT and PDL confines therapeutic effects to the upper 1,000  $\mu\text{m}$  of the dermis, containing ectatic PWS venules, while reducing the risk of possible skin infarction which could result from destruction of the lower vascular plexus [36].

We have initiated studies to evaluate the therapeutic efficacy of the PDT + PDL approach for treatment of vascular lesions such as PWS in humans. Prior to clinical use for PWS, the complex nature of the response of human skin to photoactivated BPD must be elucidated with further studies devoted to structural changes produced in skin [14–18]. ODT can image blood flow in human skin with high (10  $\mu\text{m}$ ) spatial resolution [37] and will be used to monitor the response to sub-threshold PDT and PDL irradiation in-situ and in real time [37,38]. This will enable optimization of PWS light exposure and allow determination of the treatment end point on an individual patient basis. Prospective, clinical studies are required so that the role of combined PDT + PDL treatment in the clinical management of PWS patients can be fully defined.

## ACKNOWLEDGMENTS

A verteporfin sample was generously provided by QLT (Vancouver, BC, Canada).

## REFERENCES

- Ashinoff R, Geronemus RG. Flashlamp-pumped pulsed dye laser for port wine stains in infancy: Earlier versus later treatment. *J Am Acad Dermatol* 1991;24:467–472.
- Geronemus RG, Quintana AT, Lou WW, Kauvar AN. High-fluence modified pulsed dye laser photocoagulation with dynamic cooling of port-wine stains in infancy. *Arch Dermatol* 2000;136:942–943.
- Kelly KM, Nanda VS, Nelson JS. Treatment of port wine stain birthmarks using the 1500  $\mu\text{s}$  pulsed dye laser at high fluences in conjunction with cryogen spray cooling. *Dermatol Surg* 2002;28:309–313.
- Van der Horst CMAM, Koster PHL, deBorgie CAJM, Bossuyt PMM, van Gemert MJC. Effect of timing of treatment of port-wine stains with the flash-lamp-pumped pulsed dye laser. *N Engl J Med* 1998;338:1028–1033.
- Lanigan SW. Port-wine stains unresponsive to pulsed dye laser: Explanations and solutions. *Br J Dermatol* 1998;139:173–177.
- Edstrom DW, Hedblad M-A, Ros A-M. Flashlamp pulsed dye laser and argon-pumped dye laser in the treatment of port-wine stains: A clinical and histological comparison. *Br J Derm* 2002;146:285–289.
- Nelson JS, McCullough JL, Berns MW. Principles and applications of photodynamic therapy in dermatology. In: Arndt KA, Dover JE, Olbricht SA, editors. *Lasers in cutaneous and aesthetic surgery*. Philadelphia, PA: Lippincott-Raven; 1997. pp 349–382.
- Orenstein A, Nelson JS, Liaw LH, Kaplan R, Kimel S, Berns MW. Photochemotherapy of hypervascular dermal lesions: A possible alternative to photothermal therapy? *Lasers Surg Med* 1990;10:334–343.
- Nelson JS, Liaw LH, Orenstein A, Roberts WG, Berns MW. The mechanism of tumor destruction following photodynamic therapy with hematoporphyrin derivative, chlorin and phthalocyanine. *J Natl Cancer Inst* 1988;80:1599–1605.
- Star WM, Marijnissen HPA, van den Berg-Blok AE, Versteeg JAC, Franken KAP, Reinhold HS. Destruction of rat mammary tumor and normal tissue microcirculation by hematoporphyrin derivative photoradiation as observed in vivo in sandwich observation chambers. *Cancer Res* 1986;46:2532–2540.
- Gu Y, Jun-heng L. The clinical study of argon laser PDT for port wine stain. 40 case reports. *Chin J Laser Med* 1992;1:1–4.
- Jiang L, Gu Y, Li X, Zhao X, Li J, Wang K, Liang J, Pan Y, Zhang Y. Changes of skin perfusion after photodynamic therapy for port wine stain. *Chin Med J* 1998;111:136–138.
- Lin XX, Wang W, Wu SF, Yang C, Chang TS. Treatment of capillary vascular malformation (port-wine stains) with photochemotherapy. *Plast Reconstr Surg* 1997;99:1826–1830.
- Tsoukas MM, Lin GC, Lee MS, Anderson RR, Kollias N. Predictive dosimetry for threshold phototoxicity in photodynamic therapy on normal skin: Red wavelengths produce more extensive damage than blue at equal threshold doses. *J Invest Dermatol* 1997;108:501–505.
- Lin GC, Tsoukas ML, Lee MS, Gonzalez S, Vibhagool C, Anderson RR, Kollias N. Skin necrosis due to photodynamic action of benzoporphyrin depends on circulating rather than tissue drug levels: Implications for control of photodynamic therapy. *Photochem Photobiol* 1998;68:575–583.
- Tsoukas MM, Gonzalez S, Flotte TJ, Anderson RR, Sherwood ME, Kollias N. Wavelength and fluence effect on vascular damage with photodynamic therapy on skin. *J Invest Dermatol* 2000;114:303–308.
- Fingar VH, Kik PK, Haydon PS, Cerrito PB, Tseng M, Abang E, Wieman TJ. Analysis of acute vascular damage after photodynamic therapy using benzoporphyrin derivative (BPD). *Br J Cancer* 1999;79:1702–1708.
- Middelkamp-Hup MA, Sanchez-Carpintero I, Kossodo S, Waterman P, Gonzalez S, Mihm MC, Anderson RR. Photodynamic therapy for cutaneous proliferative vascular tumors in a mouse model. *J Invest Dermatol* 2003;121:634–639.
- Sickenberg M, Schmidt-Erfurth U, Miller JW, Pournaras CJ, Zografos L, Piguat B, Donati G, Laque H, Barbazetto I, Gragoudas ES, Lane A-M, Birngruber R, van den Bergh H, Strong A, Manjuri U, Gray T, Fsadni M, Bressler NM. A preliminary study of photodynamic therapy using verteporfin for choroidal neovascularization in pathologic myopia, ocular histoplasmosis syndrome, angioid streaks, and idiopathic causes. *Arch Ophthalmol* 2003;118:327–339.
- Houle J-M, Strong A. Duration of skin photosensitivity and incidence of photosensitivity reactions after administration of verteporfin. *Retina* 2002;22:691–697.
- Kimel S, Svaasand LO, Kelly KM, Nelson JS. Synergistic photodynamic and photothermal treatment of port wine stain? *Lasers Surg Med* 2004;34:80–82.
- Major AL, Kimel S, Mee S, Milner TE, Smithies DJ, Srinivas SM, Chen Z, Nelson JS. Microvascular photodynamic effects determined in vivo using optical Doppler tomography. *IEEE J Sel Topics Quant Elect* 1999;5:1168–1175.
- Hammer-Wilson MJ, Akian L, Espinoza J, Kimel S, Berns MW. Photodynamic parameters in the chick chorioallantoic membrane (CAM) bioassay for topically applied photosensitizers. *J Photochem Photobiol B* 1999;53:44–52.
- Hammer-Wilson MJ, Cao D, Kimel S, Berns MW. Photodynamic parameters in the chick chorioallantoic membrane (CAM) bioassay for photosensitizers administered intraperitoneally (IP) into the chick embryo. *Photochem Photobiol Sci* 2002;1:721–728.
- Lange N, Ballini J-P, Wagnieres G, van den Bergh H. A new drug-screening procedure for photosensitizing agents used in photodynamic therapy for CNV. *Invest Ophthalmol Vis Sci* 2001;42:38–46.
- Kimel S, Svaasand LO, Hammer-Wilson MJ, Schell MJ, Milner TE, Nelson JS, Berns MW. Differential vascular response to laser photothermolysis. *J Invest Dermatol* 1994;103:693–700.
- Kimel S, Svaasand LO, Cao D, Hammer-Wilson MJ, Nelson JS. Vascular response to laser photothermolysis as a function of pulse duration, vessel type, and diameter: Implications for port wine stain laser therapy. *Lasers Surg Med* 2002;30:160–169.

28. Kimel S, Svaasand LO, Hammer-Wilson MJ, Nelson JS. Influence of wavelength on response to laser photothermolysis of blood vessels: Implications for port wine stain laser therapy. *Lasers Surg Med* 2003;33:288–295.
29. DeFouw DO, Rizzo VJ, Steinfeld R, Feinberg RN. Mapping of the microcirculation in the chick chorioallantoic membrane during normal angiogenesis. *Microvasc Res* 1989;38:136–147.
30. Djonov VG, Galli AB, Burri PH. Intussusceptive arborization contributes to vascular tree formation in the chick chorioallantoic membrane. *Anat Embryol (Berlin)* 2000;202:347–357.
31. Lever WF, Schaumburg-Lever G. *Histopathology of the skin*. Philadelphia, PA: J.B. Lippincott Company; 1990. p 690.
32. Hohenleutner U, Hilbert M, Wlotzke U, Landthaler M. Epidermal damage and limited coagulation depth with the flashlamp-pumped pulsed dye laser: A histochemical study. *J Invest Dermatol* 1995;104:798–802.
33. Garden JM, Tan OT, Kershmann R. Effect of dye laser pulse duration on selective cutaneous vascular injury. *J Invest Dermatol* 1986;87:653–657.
34. Tan OT, Carnd JM, Margolis R, Seki Y, Boll J, Eng M, Anderson RR, Parrish JA. Histologic responses of port-wine stains treated by argon, carbon dioxide, and tunable dye lasers. *Arch Dermatol* 1986;122:1016–1022.
35. Anderson RR. Laser–tissue interaction. In: Goldman MP, Fitzpatrick RE, editors. *Cutaneous laser surgery: The art and science of selective photothermolysis*. St. Louis, MO: Mosby-Year Book, Inc.; 1994. pp 1–18.
36. Svaasand LO, Norvang LT, Fiskerstrand EJ, Stopps EKS, Berns MW, Nelson JS. Tissue parameters determining the visual appearance of normal skin and port-wine stains. *Lasers Med Science* 1995;10:55–65.
37. Nelson JS, Kelly KM, Zhao Y, Chen Z. Imaging blood flow in human port wine stain in-situ and in real-time using optical Doppler tomography. *Arch Dermatol* 2001;137:741–744.
38. Wang I, Andersson-Engels S, Nilsson GE, Wardell K, Svanberg K. Superficial blood flow following photodynamic therapy of malignant non-melanoma skin tumours measured by laser Doppler perfusion imaging. *Br J Dermatol* 1997;136:184–189.