

SCIENTIFIC REPORTS



OPEN

Common surgical procedures in pilonidal sinus disease: A meta-analysis, merged data analysis, and comprehensive study on recurrence

V. K. Stauffer¹, M. M. Luedi², P. Kauf³, M. Schmid³, M. Diekmann⁴, K. Wieferich⁴, B. Schnüriger⁵ & D. Doll⁴

We systematically searched available databases. We reviewed 6,143 studies published from 1833 to 2017. Reports in English, French, German, Italian, and Spanish were considered, as were publications in other languages if definitive treatment and recurrence at specific follow-up times were described in an English abstract. We assessed data in the manner of a meta-analysis of RCTs; further we assessed non-RCTs in the manner of a merged data analysis. In the RCT analysis including 11,730 patients, Limberg & Dufourmentel operations were associated with low recurrence of 0.6% (95%CI 0.3–0.9%) 12 months and 1.8% (95%CI 1.1–2.4%) respectively 24 months postoperatively. Analysing 89,583 patients from RCTs and non-RCTs, the Karydakis & Bascom approaches were associated with recurrence of only 0.2% (95%CI 0.1–0.3%) 12 months and 0.6% (95%CI 0.5–0.8%) 24 months postoperatively. Primary midline closure exhibited long-term recurrence up to 67.9% (95%CI 53.3–82.4%) 240 months post-surgery. For most procedures, only a few RCTs without long term follow up data exist, but substitute data from numerous non-RCTs are available. Recurrence in PSD is highly dependent on surgical procedure and by follow-up time; both must be considered when drawing conclusions regarding the efficacy of a procedure.

For unknown reasons, the incidence of pilonidal sinus disease (PSD) has risen continuously during the past 50 years, particularly in European and North American young men^{1,2}. In a German military cohort for example, the number of affected patients increased from 29/100,000 in 2000 to 48/100,000 in 2012, and the total number of PSD-related in-patient surgeries exceeded the number of inguinal hernia-related interventions in 20 to 40-year-old patients³. Recurrent disease may probably affect patients' long-term satisfaction following PSD surgery⁴. Recurrence between 0 percent⁵ and 100 percent⁶ has been reported for PSD, and wide recurrence range can be seen even within the different surgical approach techniques as open treatment, primary midline closure or flap techniques and others. Some evidence suggests that recurrence is associated with surgical procedure and correlated with length of follow-up as well^{4,7}. However, the data are conflicting, and applied follow-up times often appear to have been randomly chosen, which brings into question the validity of reported recurrence associated with different surgical procedures. The purpose of this meta-analysis and merged data analysis was therefore to obtain a comprehensive assessment of recurrence and to ascertain determinants of recurrence of PSD with respect to specific surgical procedures and follow-up time. We considered both randomised controlled trials (RCTs) and non-RCTs.

We thus assembled a database with sources from the first description of PSD in 1833 on, that included reported recurrence, year of publication, timeframes of follow-up, type of study, and patient- and procedure-specific factors. We grouped therapeutic procedures for cumulative statistical analyses (Table 1). Using this dataset, we assessed the efficacy of common surgical procedures employed in treating PSD as a function of recurrence. We

¹Lindenhofspital, Lindenhofgruppe, 3010, Bern, (VS), Switzerland. ²Department of Anaesthesiology, Bern University Hospital Inselspital, University of Bern, 3010, Bern, (MML), Switzerland. ³Biomedical Statistics PROGNOSIX AG, 8001, Zurich, (PK, MS), Switzerland. ⁴Department of Procto-Surgery, St. Marien-Krankenhaus Vechta, Teaching Hospital of the Hannover University, 49377, Vechta, (KW, DD), Germany. ⁵Department of Visceral Surgery and Medicine, Bern University Hospital Inselspital, University of Bern, 3010, Bern, (BS), Switzerland. Correspondence and requests for materials should be addressed to D.D. (email: ddoll@gmx.de)

<i>Primary open</i>	Excision, “exhairese”, vacuum assisted closure (VAC), sinusectomy/excision, atypical excision and any other primary open approaches including supplemental measures such as laser, phenol, cryotherapy, local or systemic antibiotics, and platelet rich plasma in wound
<i>Primary median closure</i>	Any primary midline closure approach including supplemental measures such as laser, phenol, cryotherapy, local antibiotics, drainage, wound closure over antibiotics (“all put in closed wound”), systemic antibiotics, platelet rich plasma in wound but not using advancement or rotation flap techniques
<i>Primary asym. closure</i>	S-shape closure, D-shape closure, D-flap, oblique crossing, Casten and modified Casten approach
<i>Karydakis/Bascom*</i>	Bascom cleft lift*, and modified Bascom cleft lift* approach, Karydakis and modified Karydakis approach, cleft lift procedure, including supplemental measures such as laser, phenol, cryotherapy, local antibiotics, drainage, wound closure over antibiotics (“all put in closed wound”), systemic antibiotics, platelet rich plasma in wound
<i>Limberg/Dufourmental</i>	Limberg and Dufourmental approach as well as their modifications, rhomboid flap, teardrop flap and z-plasty including supplemental measures such as local or systemic antibiotics
<i>Flaps</i>	Classical advancement flap, gluteus flap, VY-advancement flap, lateral advancement flap, local fasciocutaneous, infragluteal, and bilateral gluteus muscle advancement flap, “lembo di lator”, pope musculofascial advancement flap, “Kopp gluteo-fascial plasty”, Rotation flap, Schrudde-Olivari and other flaps including combinations and supplemental measures such as local or systemic antibiotics
<i>Marsupialisation</i>	Marsupialisation as described by Obeid, McFee, Mutschmann, DePrizio, Colp and Buie
<i>Limited excision</i>	Lay open, curettage, drainage, sinotomy, sinotomy and cauterisation, “cystostomie”, minor excision, curettage, deroofting and curettage, cauterisation, and flush as described by Dorton
<i>Pit picking*</i>	Bascom pit picking with a lateral incision *, Trepines, pit picking, pit excision, pit excision and phenol, brushing, Farrell drills, Lord-Millar, primary open approach with subcutaneous excision of collateral tracts, tract coagulation
<i>Partial closure</i>	Partial closure techniques including supplemental measures such as local or systemic antibiotics
<i>Incision and drainage</i>	Incision, incision and curettage, and aspiration including supplemental measures such as, local or systemic antibiotics
<i>Phenol treatment</i>	Classic phenol treatment and supplemental measures such as laser, cryotherapy, and local or systemic antibiotics
<i>Laser treatment</i>	Primary laser techniques
<i>Other treatments additionally included in the overall analysis</i>	Plug and Seton technique, as well as endoscopic approaches, cryotherapy, histoacryl glue injection, aspiration and antibiotics, and conservative approaches such as Ayurveda therapy

Table 1. Grouping of therapeutic strategies for analysis of recurrence rates in pilonidal sinus disease. *Bascom described and used two different procedures: “Cleft closure/cleft lift” (merged with Karydakis group) and “Pit picking” (merged with Pit picking group).

found that the recurrence in PSD varied depending on the surgical procedure and on the length of follow-up. While naturally, an increase of recurrence could be observed with longer follow-up, the rate of this increase was varying among the different procedures. This indicates that a thorough evaluation of a procedure in view of recurrence has to include the specific relation of recurrence to follow-up time and cannot just be based on comparisons at one single follow-up time. The strength of our conclusions is substantially buttressed by the extensive analysis of a large database pertaining to particular therapeutic procedures.

Results

Our search criteria retrieved 5,840 studies and 303 book chapters across all databases. After excluding duplicates, 5,768 studies were screened. Reports on PSD in other than the classical presacral intergluteal location, studies in embryonic development, in carcinomas, etc. were excluded. Following exclusion, 1,148 articles on PSD at classical anatomical location with specific surgical treatment remained for analysis. Of these, 408 lacked detailed data on recurrence or follow-up time or both. Finally, 740 studies published from 1833 to 2017 were analysed. A flow chart describing the selection of literature sources, based on the *Preferred reporting items for systematic reviews and meta-analysis (PRISMA)*⁸, is illustrated in Fig. 1.

Results reported in the final set of publications were stratified according to the specific surgical technique employed to avoid bias across studies. This approach led to 14 groups for analysis. Additionally, we included an overall analysis. For each of the specific therapeutic approaches, the data included the number of patients, the reported follow-up time, and the recurrence.

Heterogeneity analysis. Considering prospective/randomized control trials only, the heterogeneity analysis showed $I^2 < 5\%$, $p > 0.2$ (Cochrane’s Q-test) except for the Bascom/Karydakis (0–12 months, $p < 0.001$, $I^2 = 80.36\%$, $df = 4$), marsupialisation (0–12 months; $p < 0.001$, $I^2 = 97.84\%$, $df = 3$), and other flap techniques (0–12 months, $p = 0.062$, $I^2 = 64\%$, $df = 2$). Considering all studies, the heterogeneity analysis showed $I^2 < 5\%$, $p > 0.2$ (Cochrane’s Q-test) except for the primary asymmetric closure (0–12 months, $p = 0.023$, $I^2 = 61.54\%$, $df = 5$), marsupialisation (0–12 months, $p < 0.001$, $I^2 = 64.43\%$, $df = 18$), and pit picking (0–12 months, $p < 0.001$, $I^2 = 98.31\%$, $df = 6$).

The above described analysis ascertains that there is no statistical evidence of heterogeneity in our study group, except for primary asymmetric closure, marsupialisation and pit picking.

Follow-up time and recurrence over all surgical therapies. Data on recurrence and follow-up times in all surgical PSD treatments together pertaining to 11,700 patients were extracted from 102 RCTs^{2,5,9–110}. A recurrence of 1.5% (95% CI 1.3–1.8%) was observed in patients at 12 months, 4.3% (95% CI 3.8–4.8%) at 24 months, and 20.3% (95% CI 17.8–22.9%) at 60 months.

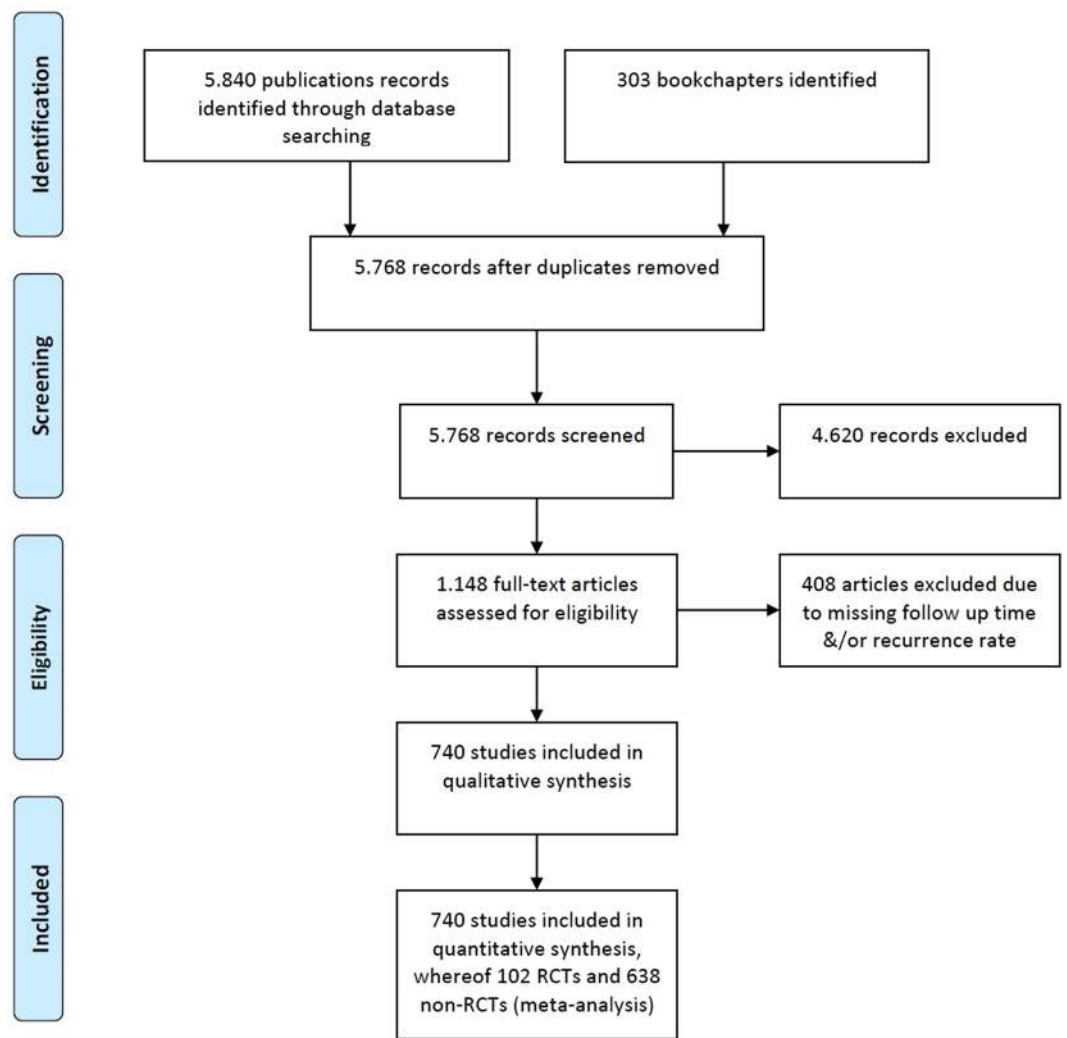


Figure 1. Flow diagram based on *Preferred reporting items for systematic reviews and meta-analysis (PRISMA)*⁸ illustrating the systematic search for evidence regarding recurrence and long term follow-up data associated with common surgical procedures in PSD.

Further, data on recurrence and follow-up times in all surgical PSD treatments together pertaining to primary open PSD treatment pertaining to a total of 89,583 patients were extracted from 638 additional non-RCTs^{4,62,111–746}. Among these patients, a recurrence of 2.0% (95% CI 1.9–2.1%) was observed in patients at 12 months, 4.4% (95% CI 4.3–4.6%) at 24 months, 10.8% (95% CI 10.5–11.3%) at 60 months, 16.9% (95% CI 16.3–17.5%) at 120 months, and 60.4% (95% CI 47.1–37.8%) at 240 months (Fig. 4).

To enable an entire picture, this overall analysis included data on recurrence and follow-up times pertaining to 184 patients treated for PSD by other methods (Table 1) extracted from 3 RCTs. Among these patients, a recurrence of 3.8% (95% CI 0.9–6.7%) was observed in patients at 12 months and 7.8% (95% CI 0.4–15.1%) at 24 months and follow-up times pertaining to 2,916 patients treated for PSD by other methods extracted from 40 additional non-RCTs. Among these patients, a recurrence of 2.9% (95% CI 2.2–3.7%) was observed in patients at 12 months, 6.7% (95% CI 5.4–8.0%) at 24 months, and 26.0% (95% CI 22.6–29.4%) at 60 months.

To provide a rational basis for selecting treatment approaches, we assessed possible associations between recurrence of PSD and specific therapeutic procedures in the manner of a classical meta-analysis of RCTs, and found that recurrence in common surgical procedures for PSD were dependent on follow-up time (Figure 2); additional data from non-RCTs were included and processed in the manner of a merged data analysis (Figure 3).

Recurrence in primary open PSD treatment. Data on recurrence and follow-up times in primary open PSD treatment pertaining to 1,713 patients were extracted from 32 RCTs^{9–38,747,748}. Among these patients, a recurrence of 1.0% (95% CI 0.5–1.6%) was observed in patients at 12 months, 3.2% (95% CI 2.2–4.2%) at 24 months, and 16.5% (95% CI 11.9–21.2%) at 60 months.

Further, data on recurrence and follow-up times in primary open PSD treatment pertaining to 10,166 patients were extracted from 128 additional non-RCTs^{4,39,40,111–234}. Among these patients, a recurrence of 1.5% (95% CI

Procedure / Follow up time [months]	Patients included	12	24	60	120	240
Overall	11,730	1.5	4.3	20.3	NA	NA
Primary open	1,713	1.0	3.2	16.5	NA	NA
Primary midline closure	4,626	2.1	7.0	21.9	NA	NA
Primary asymmetric closure	119	7.3	NA	NA	NA	NA
Karydakis/Bascom**	1,457	1.5	2.4	10.2	NA	NA
Limberg / Dufourmental	2,380	0.6	1.8	NA	NA	NA
Other flap techniques	283	0.4	7.5	NA	NA	NA
Marsupialisation	343	1.0	14.3	NA	NA	NA
Limited excision	384	1.3	1.7	NA	NA	NA
Pit picking***	98	4.3	8.3	NA	NA	NA
Partial closure	73	NA	NA	NA	NA	NA
Incision and drainage	0	NA	NA	NA	NA	NA
Phenol treatment	70	NA	NA	NA	NA	NA
Laser treatment	0	NA	NA	NA	NA	NA

* Data of homogeneous recurrence rates ($I^2 < 5\%$, $p > 0.2$) are printed in bold, heterogeneous data in italic numbers; **includes Bascom cleft lift; ***includes Bascom Pit Picking

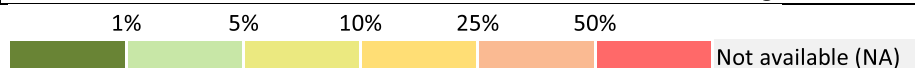


Figure 2. Procedure specific recurrence rates in PSD [%]* derived from RCTs. *Data of homogeneous recurrence rates ($I^2 < 5\%$, $p > 0.2$) are printed in bold, heterogeneous data in italic numbers; **includes Bascom cleft lift; ***includes Bascom Pit Picking.

Procedure / Follow up time [months]	Patients included	12	24	60	120	240
Overall	89,583	2.0	4.4	10.8	16.9	60.4
Primary open	10,166	1.5	4.2	13.1	19.9	NA
Primary midline closure	21,583	3.4	7.0	16.8	32.0	67.9
Primary asymmetric closure	3,121	<i>1.0</i>	<i>1.6</i>	<i>3.2</i>	<i>6.7</i>	NA
Karydakis/Bascom**	16,349	0.2	0.6	1.9	2.7	NA
Limberg / Dufourmental	12,384	0.4	1.6	5.2	11.4	NA
Other flap techniques	4,257	1.1	1.9	7.9	NA	NA
Marsupialisation	3,207	<i>1.8</i>	5.6	9.4	16.3	NA
Limited excision	6,366	5.0	6.8	16.2	34.0	NA
Pit picking***	6,272	<i>2.7</i>	6.5	15.6	NA	NA
Partial closure	530	2.8	5.1	19.0	NA	NA
Incision and drainage	360	10.4	25.9	40.2	NA	NA
Phenol treatment	1,947	1.9	14.1	40.4	NA	NA
Laser treatment	125	1.9	5.1	36.6	NA	NA

* Data of homogeneous recurrence rates ($I^2 < 5\%$, $p > 0.2$) are printed in bold, heterogeneous data in italic numbers; **includes Bascom cleft lift, ***includes Bascom Pit Picking

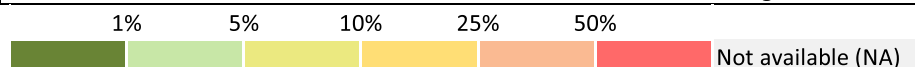


Figure 3. Procedure specific recurrence rates in PSD [%]* overall derived from RCTs and non-RCTs. *Data of homogeneous recurrence rates ($I^2 < 5\%$, $p > 0.2$) are printed in bold, heterogeneous data in italic numbers; **includes Bascom cleft lift, ***includes Bascom Pit Picking.

1.2–1.7%) was observed in patients at 12 months, 4.2% (95% CI 3.7–4.7%) at 24 months, 13.1% (95% CI 11.9–14.4%) at 60 months, and 19.9% (95% CI 17.9–21.9%) at 120 months (Fig. 5).

Recurrence in primary midline closures. Data on recurrence and follow-up times in primary midline closures (not using advancement or rotation flap techniques) pertaining to 4,626 PSD patients which were

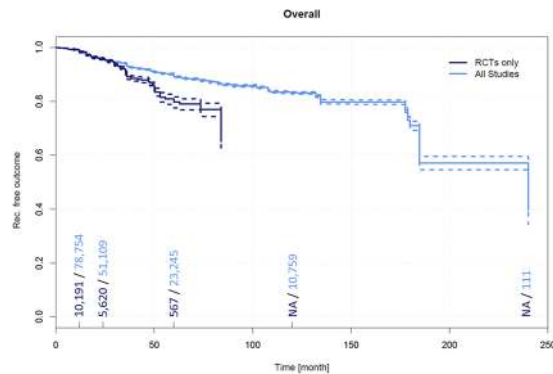


Figure 4. Recurrence free outcome as a function of follow-up time irrespective of specific therapeutic procedure. Data presented are for RCTs only and for all available studies. Numbers of patients included in the analysis are indicated at 12, 24, 60, and 120 months. Dashed lines indicate 95% confidence intervals.

extracted from 51 RCTs^{5,9,10,19,20,22,25–29,31,32,35,37,41–73,235,236,748}. Among these patients, a recurrence of 2.1% (95% CI 1.7–2.6%) was observed in patients at 12 months, 7.0% (95% CI 6.0–8.0%) at 24 months, and 21.9% (95% CI 18.5–25.3%) at 60 months.

Data on recurrence and follow-up times in primary open PSD treatment pertaining to 21,583 patients were extracted from 205 additional non-RCTs^{4,60,74,75,111,112,114,115,117,118,121–126,128–134,136,137,141,143,149,153–156,160,161,163,167–171,174,175,177,181,182,188–192,194,196,197,199–201,203,206,208,215,216,218,220,221,223,224,230,233,237–373}. Among these patients, a recurrence of 3.4% (95% CI 3.1–3.6%) was observed in patients at 12 months, 7.0% (95% CI 6.5–7.4%) at 24 months, 16.8% (95% CI 15.8–17.8%) at 60 months, 32.0% (95% CI 29.6–34.4%) at 120 months, and 67.9% (95% CI 53.3–82.4%) at 240 months (Fig. 6).

Recurrence in primary asymmetric closure. Data on recurrence and follow-up times in primary asymmetric closure PSD treatment pertaining to 119 patients were extracted from 2 RCTs^{34,374}. Among these patients, a recurrence of 7.3% (95% CI 0.0–19.9%) was observed in patients at 12 months.

Further, data on recurrence and follow-up times pertaining to 3,121 patients receiving primary open PSD treatment were extracted from 28 additional non-RCTs^{4,76,130,133,139,157,221,228,320,348,357,375–391}. Among these patients, a recurrence of 1.0% (95% CI 0.6–1.4%) was observed in patients at 12 months, 1.6% (95% CI 1.1–2.1%) at 24 months, 3.2% (95% CI 2.3–4.0%) at 60 months, and 6.7% (95% CI 5.2–8.2%) at 120 months (Fig. 7).

Recurrence in Karydakis and Bascom cleft lift techniques. Data on recurrence and follow-up times pertaining to 1,457 patients treated for PSD by a Karydakis or Bascom cleft lift technique were extracted from 21 RCTs^{24,33,59,62,63,77–90,392,393}. Among these patients, a recurrence of 1.5% (95% CI 0.8–2.2%) was observed in patients at 12 months, 2.4% (95% CI 1.4–3.3%) at 24 months, and 10.2% (95% CI 5.4–15.0%) at 60 months.

Data on recurrence and follow-up times pertaining to 16,349 patients treated for PSD by a Karydakis and Bascom cleft lift technique were extracted from 66 additional non-RCTs^{91,92,136,146,161,163,184,198,206,254,263,313,335,346,348,361,379,391,394–441}. Among these patients, a recurrence of 0.2% (95% CI 0.1–0.3%) was observed in patients at 12 months, 0.6% (95% CI 0.5–0.8%) at 24 months, 1.9% (95% CI 1.6–2.2%) at 60 months, and 2.7% (95% CI 2.4–3.1%) at 120 months (Fig. 8). Along with the Limberg/Dufourmental approaches and other flap techniques, the Karydakis and Bascom cleft lift procedures resulted in the lowest recurrence at any follow-up time in our analysis (Tables 2 and 3).

Recurrence in Limberg and Dufourmental flaps. Data on recurrence and follow-up times pertaining to 2,380 patients treated for PSD by Limberg and Dufourmental flap techniques were extracted from 36 RCTs^{5,14,21,23,43,44,46,49,53,54,56,61,64,65,73,77,78,80,82,83,90,93–102,236,392,393,442,443}. Among these patients, a recurrence of 0.6% (95% CI 0.3–0.9%) was observed in patients at 12 months and 1.8% (95% CI 1.1–2.4%) at 24 months.

Data on recurrence and follow-up times pertaining to 12,384 patients treated for PSD by Limberg and Dufourmental flaps were extracted from 139 additional non-RCTs^{4,60,103,104,115,126–128,133,156,157,196,199,201,208,221,224,242,261,262,267,289,302,303,313,318,321,322,334–336,348,372,399,407,410,415,417,426,433,438,439,444–541}. Among these patients, a recurrence of 0.4% (95% CI 0.3–0.5%) was observed in patients at 12 months, 1.6% (95% CI 1.3–1.9%) at 24 months, 5.2% (95% CI 4.5–5.8%) at 60 months, and 11.4% (95% CI 9.2–13.7%) at 120 months (Fig. 9).

Recurrence in other flap techniques. Data on recurrence and follow-up times pertaining to 283 patients treated for PSD by other flap techniques were extracted from 6 RCTs^{45,55,98,105,542,543}. Among these patients, a recurrence of 0.4% (95% CI 0.0–1.1%) was observed in patients at 12 months and 7.5% (95% CI 2.4–12.5%) at 24 months.

Data on recurrence and follow-up times pertaining to 4,258 patients treated for PSD by other flap techniques were extracted from 89 additional non-RCTs^{106,107,111,126,137,160,167,182,192,208,221,224,233,245,259,283,312,321,339,354,368,410,433,449,492,511,512,525,532,538,544–602}. Among these patients, a recurrence of 1.1% (95% CI 0.8–1.4%) was observed in patients at 12 months, 1.9% (95% CI 1.4–2.4%) at 24 months, and 7.9% (95% CI 6.4–9.4%) at 60 months (Fig. 10).

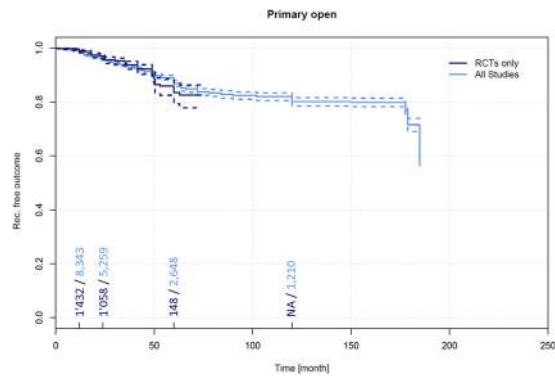


Figure 5. Recurrence free outcome as a function of follow-up time of patients receiving primary open treatment. Data presented are for RCTs only and for all available studies. Numbers of patients included in the analysis are indicated at 12, 24, 60, and 120 months. Dashed lines indicate 95% confidence intervals.

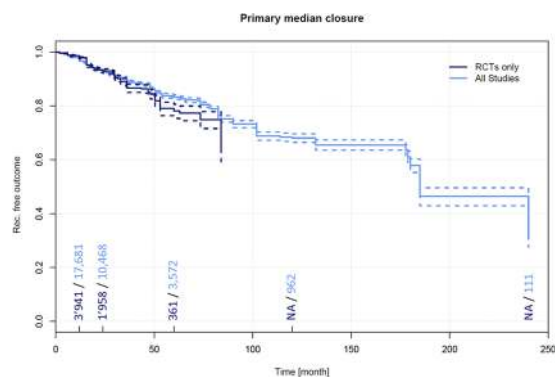


Figure 6. Recurrence free outcome as a function of follow-up time of patients treated with primary midline closure (not using advancement or rotation flap techniques). Data presented are for RCTs only and for all available studies. Numbers of patients included in the analysis are indicated at 12, 24, 60, and 120 months. Dashed lines indicate 95% confidence intervals.

Recurrence in marsupialisation. Data on recurrence and follow-up times pertaining to 343 patients treated for PSD by marsupialisation were extracted from 8 RCTs^{17,18,30,47,96,101,603,604}. Among these patients, a recurrence of 1.0% (95% CI 0.0–2.3%) was observed in patients at 12 months and 14.3% (95% CI 0.0–30.3%) at 24 months.

Data on recurrence and follow-up times pertaining to 3,207 patients treated for PSD by other flap techniques were extracted from 55 additional non-RCTs^{4,108,109,115,129,132,133,137,143,163,170,171,177,188,190,193,200,204,215,218,224,230,245,272,279,294,303,313,315,317,318,336,352,358,363,369,593,605–622}. Among these patients, a recurrence of 1.8% (95% CI 1.2–2.3%) was observed in patients at 12 months, 5.6% (95% CI 4.5–6.7%) at 24 months, 9.4% (95% CI 7.6–11.1%) at 60 months, and 16.3% (95% CI 11.8–20.9%) at 120 months (Supplementary Fig. 1).

Recurrence in limited excision. Data on recurrence and follow-up times pertaining to 384 patients treated for PSD by limited excision were extracted from 5 RCTs^{29,50,105,604,623}. Among these patients, a recurrence of 1.3% (95% CI 0.0–2.9%) was observed in patients at 12 months and 1.7% (95% CI 0.0–3.5%) at 24 months.

Data on recurrence and follow-up times pertaining to 6,366 patients treated for PSD by limited excision PSD treatment were extracted from 71 additional non-RCTs^{52,61,69,72,73,75,81,83,88,94,106,114,119,121,124,125,131,140,142,144,149,160,208,221,226,248,249,261,285,293,295,319,321,322,400,410,416,536,609,625–656}. Among these patients, a recurrence of 5.0% (95% CI 4.3–5.6%) was observed in patients at 12 months, 6.8% (95% CI 6.0–7.7%) at 24 months, 16.2% (95% CI 14.3–18.2%) at 60 months, and 34.0% (95% CI 26.3–41.6%) at 120 months (Supplementary Fig. 2).

Recurrence in pit picking. Data on recurrence and follow-up times pertaining to 98 patients treated for PSD by pit picking were extracted from 2 RCTs^{85,86}. Among these patients, a recurrence of 4.3% (95% CI 0.0–8.7%) was observed in patients at 12 months and 8.3% (95% CI 0.0–17.0%) at 24 months.

Data on recurrence and follow-up times pertaining to 6,272 patients treated for PSD by pit picking were extracted from 32 additional non-RCTs^{179,329,354,410,412,483,655–680}. Among these patients, a recurrence of 2.7% (95% CI 2.2–3.1%) was observed in patients at 12 months, 6.5% (95% CI 5.7–7.3%) at 24 months, and 15.6% (95% CI 13.8–17.4%) at 60 months (Supplementary Fig. 3).

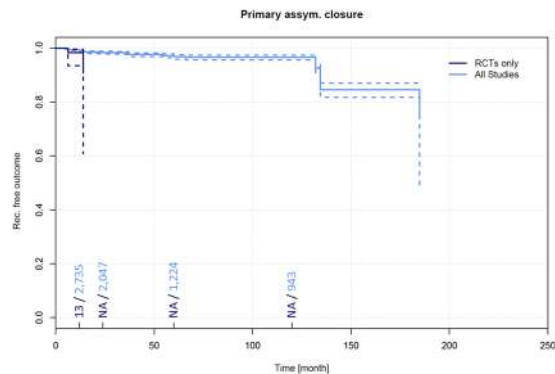


Figure 7. Recurrence free outcome as a function of follow-up time of patients treated with primary asymmetric closure. Data presented are for RCTs only and for all available studies. Numbers of patients included in the analysis are indicated at 12, 24, 60, and 120 months. Dashed lines indicate 95% confidence intervals.

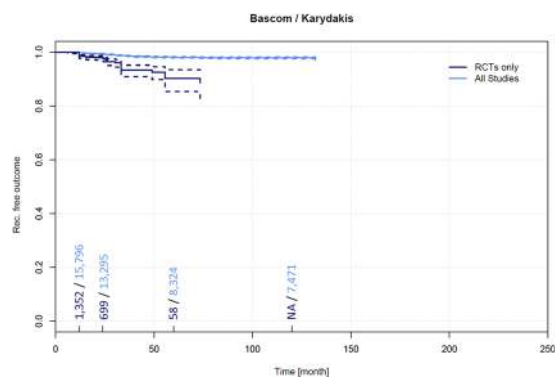


Figure 8. Recurrence free outcome as a function of follow-up time of patients treated with Bascom and Karydakis techniques. Data presented are for RCTs only and for all available studies. Numbers of patients included in the analysis are indicated at 12, 24, 60, and 120 months. Dashed lines indicate 95% confidence intervals.

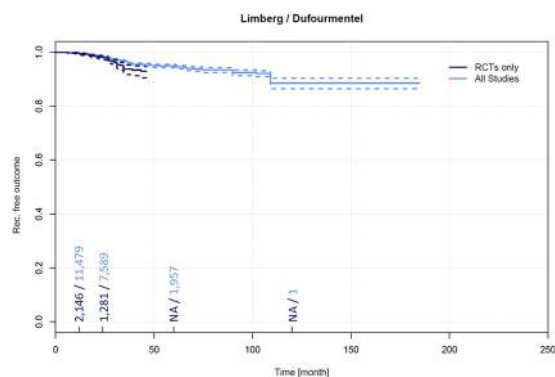


Figure 9. Recurrence free outcome as a function of follow-up time of patients treated with Limberg and Dufourmental flap technique. Data presented are for RCTs only and for all available studies. Numbers of patients included in the analysis are indicated at 12, 24, 60, and 120 months. Dashed lines indicate 95% confidence intervals.

Recurrence in partial closure. Data on recurrence and follow-up times pertaining to 73 patients treated for PSD by partial closure were extracted from 1 RCT⁴⁸. Due to the single observation, meta-analysis based on RCTs was not possible.

Data on recurrence and follow-up times pertaining to 530 patients treated for PSD by partial closure were extracted from 11 additional non-RCTs^{118,124,125,155,167,168,182,315,681–683}. Among these patients, a recurrence of 2.8% (95% CI 1.2–4.4%) was observed in patients at 12 months, 5.1% (95% CI 2.8–7.3%) at 24 months, and 19.0% (95% CI 12.7–25.4%) at 60 months (Supplementary Fig. 4).

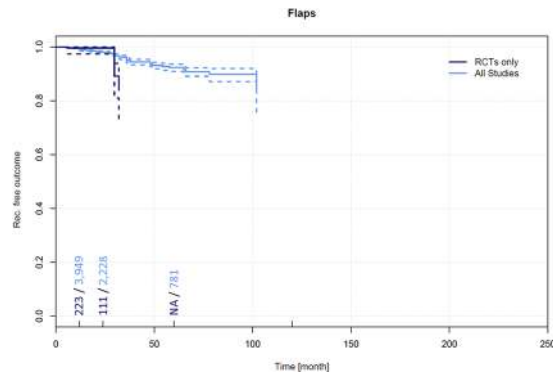


Figure 10. Recurrence free outcome as a function of follow-up time of patients treated with other flap techniques. Data presented are for RCTs only and for all available studies. Numbers of patients included in the analysis are indicated at 12, 24, 60, and 120 months. Dashed lines indicate 95% confidence intervals.

Recurrence in incision and drainage. No RCTs are available that report recurrence and follow-up times for incision and drainage.

Data on recurrence and follow-up times pertaining to 360 patients treated for PSD by incision and drainage were extracted from 13 non-RCTs^{118,162,177,179,197,199,206,254,264,378,684–686}. Among these patients, a recurrence of 10.4% (95% CI 6.6–14.3%) was observed in patients at 12 months, 25.9% (95% CI 19.1–32.8%) at 24 months, and 40.2% (95% CI 29.4–50.9%) at 60 months (Supplementary Fig. 5).

Recurrence in phenol treatment alone. Data on recurrence and follow-up times pertaining to 70 patients treated for PSD by phenol alone were extracted from 1 RCT¹². Due to the single observation, meta-analysis was not possible.

Data on recurrence and follow-up times pertaining to 1,947 patients treated for PSD by phenol alone were extracted from 26 additional non-RCTs^{194,219,338,355,445,457,687–706}. Among these patients, a recurrence of 1.9% (95% CI 1.1–2.6%) was observed in patients at 12 months, 14.1% (95% CI 11.8–16.5%) at 24 months, and 40.4% (95% CI 27.8–52.9%) at 60 months (Supplementary Fig. 6).

Recurrence in laser alone. No RCTs are available that report recurrence and follow-up times for PSD treatment by laser alone.

Data on recurrence and follow-up times pertaining to 125 patients treated for PSD by incision and drainage were extracted 14 non-RCTs^{175,707–719}. Among these patients, a recurrence of 1.9% (95% CI 0.0–4.7%) was observed in patients at 12 months, 5.1% (95% CI 0.4–9.8%) at 24 months, and 36.6% (95% CI 3.8–69.4%) at 60 months (Supplementary Fig. 7).

Comparing recurrence at 60 month following surgery amongst the RCT studies (11,730 patients, Figure 2, column “60”), range was 10.2%–21.9%; separated by a factor of 2.1. In all studies (Figure 3), range was from 1.9% to 40.4% at 60 months, giving a factor of $40.4/1.9 = 21$. Thus, recurrence results differ by a factor of 2.1 in RCTs and by a factor of 21 in all studies through selection of a surgical therapy (when a given 5 year follow up is applied).

On the other hand, recurrence varies with time since surgery. In RCT primary open results (as shown in Figure 2), line primary open treatment, recurrence is 1.0% at 12 months and increases to 16.5% at 60 months. Recurrence varies by a factor of 16.5/1 through time in this primary open group, while this is lower in the Karydakis & Bascom group (10,2/1,5; 6,8).

In the 89,583 patients group combining RCT and non-RCT data, the quotient between longest and shortest recurrence result can be found in the Limberg & Dufourmentel group, with 0.4% at 12 months and 11.4% at 120 months following surgery (factor 28,5). Thus, recurrence results may differ by a factor of 6, 8 and more for a given surgical therapy if follow up time is not properly defined (or defined at all). This indicates that a thorough evaluation of a procedure in view of recurrence has to include the specific relation of recurrence to follow-up time.

Discussion

We have reviewed all pilonidal sinus treatment data from all available cases from the first published description of pilonidal sinus in 1833 to the present day. We have analysed data from more than 80,000 patients surgically treated for a single disease over the past 180 years, and have systematically assessed the relationship between recurrence, follow-up times, and surgical procedure. Our meta-analysis of the data identified a relationship between recurrence of PSD and follow-up times for each different therapeutic approach. The mean recurrence for all cases measured at the one-year time point differed from the five-year recurrence by a factor of 5; whereas, for the individual therapeutic procedures, one and five-year recurrence differed by a factor of 3 to 20 (Tables 2 and 3).

Recurrence varies between surgical procedures by a factor of 2,1 at 60 months in RCTs and 21 in all studies. On the other hand, recurrence varies by a factor of 19 to 29 within a given surgical therapy if comparing 12 months and longest follow up results (Tables 2 and 3). Thus, any report of a given surgical procedure without specified follow up may contain a 10 fold higher or lower true recurrence as the postulated one.

Our study has several limitations that we identify as follows: The systematic review and meta-analysis was limited to reports in English, French, German, Italian, and Spanish. Publications in other languages were included where definitive treatment and recurrence at specific follow-up times were described in an English abstract. Consequently, Japanese and Chinese literature is not fully included. On the other hand, pilonidal sinus is exceptionally rare in the Asian population⁷⁴⁵, therefore, we do not anticipate an emergence of Asian data that would significantly skew the current results. Further, our strategy of including all available evidence since January 1st, 1833 ensured a broad picture. Although additional older literature may be found and studied, such literature is unlikely to add significantly to the findings reported here, as regular follow-up was not commonplace in early times; surgeons relied more on “return on recurrence” follow-up^{746,749}. Furthermore, the older literature includes more primary open treatment methods with follow-up exceeding 120 months^{166,750}, which are well-represented in the analysis. Therefore, the inclusion of additional new primary open patients is unlikely to change our findings. Given the design, the scope of this study is relatively narrow and specific. Yet, including more variables such as e.g. length of hospital stay, length of post-op course, and cost of post-op course would be a very extensive beyond the scope of a single study. Another source of bias may be our strategy for grouping therapeutic procedures. We had to condense multiple, sometimes minute, variants of mainstream surgical therapies into cohorts large enough for thorough analysis. While some therapies are gone, and will not return, others, such as marsupialisation, seem to be enjoying a resurgence, and new strategies such as endoscopic approaches are currently being investigated. Additionally, studies were picked regardless of their inclusion of primary or recurrent PSD cases what may affect the surgical technique of choice and the outcome in many ways. Statistical limitations are built into the design of this study. While detailed information about a single patient is commonly not available, it was necessary to simulate single patients from pools of patients reported in each single study. Therefore, no sub-analysis of links between recurrence and follow-up time for gender or age groups, etc., could be applied. Since the analysed studies reported follow-up times with various statistical measures (mean, median, and range), there could be a potential bias within the details in the survival curve structures. Abrupt drops, for example, are often due to studies in which large numbers of patients experienced recurrence at a specific (mean/median/centre of range) follow-up time. Therefore, the specific drops in the survival curves should be interpreted cautiously. For the purpose of this study, the goal was to acquire an understanding of general links between follow-up times and recurrence among therapeutic procedures. Although we cannot necessarily determine, by extrapolation from our results, a particular follow-up time at which recurrence increases, the trend over time is meaningful, and thanks to the very high case numbers, is reliably estimated.

The highest incidence of recurrence identified in our data, 67.9%, occurred 240 months after primary midline closures; so, this method should be abandoned straight away, while other traditional approaches such as primary open treatment can be justified, also when considering the development of more complicated surgeries involving flap techniques. Correctly, this leads to a call for more off-midline closure education for surgeons⁷⁵¹. From our analysis of data from more than 80,000 patients over 18 decades, we found that the Karydakakis and the Bascom cleft lift procedures show the lowest recurrence at any time of follow-up, followed by rhomboid flaps and other flaps. However, current RCT evidence only provides follow-up data for 10 years postoperatively for Karydakakis/Bascom, and a longer-term study would be of interest. Nevertheless, non-RCT data point into the direction of a continued low recurrence with these advancement and rotational flap methods. Because of the high recurrence as early as 2 years (25.9%, rising to 40.2 after 5 years), incision and drainage cannot be recommended as definite therapy. The simple manoeuvre easily relieves a patient from pain in an acute situation, but must be followed by a definite technique with lower recurrence. Similarly, phenol treatment is associated with high recurrence, 14.1% at 24 months and 40.4% at 60 months; longer term follow-up data are unavailable. A Turkish group has reported on the phenol technique recently⁴⁵⁷. They praise its minimal invasiveness and concomitant short duration of stay in hospital. However, given the high recurrence, these might be misleading arguments. The data on laser treatment still remain weak; long term follow-up data and extensive cohorts have not yet been published.

Our results presented here suggest that the variances in recurrence are understandable once the follow-up time is taken into account. We found that recurrence is a function of follow-up time for every major surgical and non-surgical method analysed. Our endeavours here have established a respective benchmark, potentially increasing the comparability as also proposed, e.g., for a staging system⁴¹⁰.

In conclusion, physicians must keep in mind that recurrence of surgical procedures in PSD impressively depend on follow-up time. This dependence, i.e. the steepness of increase of recurrence with longer follow-up times, is specific to a surgical procedure. Applying a recurrence without knowing the time since surgery may be open to a bias factor of up to 18 and above. The choice of surgical therapy influences recurrence by a factor of up to 21. As we are now able to understand recurrence in PSD in a more standardised way. Primary midline closure is dead, while older therapies (such as marsupialisation) may be reconsidered, while advancement flap (Karydakakis & Bascom) and rotational flap procedures (Limberg/Dufourmentel) are undoubtedly primary league with asymmetrical procedures, as proven by RCT and combined RCT/non-RCT analysis in 89,583 patients available from 1833 to 2017. Follow-up of PSD patients should always be planned long term, i.e., five or ten years if reliable conclusions are to be drawn regarding the efficacy of a new procedure or on the efficacy of your own results using an already known technique.

Methods

Ethical approval and informed consent. The systematic review with meta-analysis and merged data analysis included no experiment carried out on live vertebrates (or higher invertebrates), humans or human samples. Thus, formal ethics approval was not required.

Search strategy and study selection criteria. To assemble a comprehensive database pertaining to PSD, we systematically searched for the NCBI Medical Subject Heading (MeSH) term, “pilonid*“, as well as “dermoid” AND “cyst” in MEDLINE, PubMed, PubMed Central, Scopus, Ovid, Embase, and Cochrane Central Register of Controlled Trials (CENTRAL). We additionally searched these terms in Google, Google Scholar, ResearchGate, and references listed in national and international guidelines such as the S3 guidelines of the Association of the Scientific Medical Societies in Germany on the treatment of PSD. We also assessed the references listed in the literature cited of all documents retrieved by the searches. Documents retrieved included randomised, non-randomised, prospective, retrospective, and observational studies such as cohort, case-control, cross-sectional studies, and case reports published between 1833 to 2017. Four authors (VS, MML, MD, and DD) reviewed the retrieved documents for compliance with the inclusion criteria: specification of the definitive treatment, recurrence, and length of follow-up. Reports in English, French, German, Italian, and Spanish were considered, as were publications in other languages if definitive treatment and recurrence at specific follow-up times were described in an English abstract, or if the authors contacted via email or Research Gate provided an English translation of their surgical approach, recurrence, and follow-up time. Exclusion criteria were: PSD in other than presacral location, neoplasia involvement, double publication of data by an author. Further, studies lacking any component of the minimal data set which comprised of: definitive treatment strategy/recurrence/follow-up time were excluded. Prior meta-analysis reports and review articles were excluded, as well, although their reference lists were screened for potential additions to the evidence. Also, previously unpublished data presented in review articles were taken into account. Studies in which recurrence were deduced from patients returning with recurrent disease (“return on recurrence”), but which did not actively investigate the majority of non-returners, were excluded.

The review protocol is registered in the National Health Service (NHS) international prospective register of systematic reviews PROSPERO (42016051588).

Data collection, extraction and quality assessment. All studies were analysed and documented on paper. The transcript data were collected into a Microsoft Excel (Version 2016, Microsoft Corp., Redmond, WA) spreadsheet, and correct transfer was controlled. Every specific therapeutic strategy reported in a paper was assigned to a line. Columns included citation details, number of patients included, therapeutic procedures, reported follow-up times, study details and recurrence.

The statistical measures applied for reporting of follow-up times are not standardised, and thus, were not identical among different studies. However, given the relative clustering of the disease incidence in young adults, mean and median reports were treated as equivalent. For data that included a range of follow-up times, the centre of the given range was used in our analysis. For data in which minimum follow-up times were reported, the values were integrated as is.

Individual studies were assessed for consistency in described methods and reported results to minimize potential risk of bias in a thorough data synthesis. A subgroup of prospective randomized control trials was analysed separately in addition to check for consistency with the complete set of studies. The reported recurrence in each study were then linked to the study’s follow-up time. Follow-up time was defined as mean, median, centre of range, or minimum. To compare information across all studies, single patients were statistically simulated. I.e., for each study participant, a data sample was extracted containing recurrence, follow-up time, and therapeutic procedure. If, for example, a study included 500 patients and a recurrence of 20% for a particular therapeutic procedure, then 100 single samples would be defined as recurrent disease, whereas, the remaining 400 samples would be defined as recurrence-free. In this simulation, some information, such as gender ratios, could not be included since this information was only available cumulatively in the majority of studies.

In cases where an article addressed more than one therapeutic strategy, the data pertaining to each treatment strategy were considered separately in our analysis.

Grouping of therapeutic procedures and statistical analyses. Therapeutic procedures were analysed cumulatively (“overall”) and stratified as subgroups (Table 1). The overall analysis also included some other different techniques not specifically analysed as subgroup. For statistical analysis and visualizations, the statistical software package R (version 3.1.0) in the R-studio framework (version 0.98.982) was used. Statistical significance was assumed if $p < 0.05$. All tests were considered in a two-tailed set-up. For the analysis of recurrence free outcome over time, survival analysis according to Kaplan-Meier including pointwise 95% confidence intervals (CI) was used as implemented in the R-package ‘survival’ (version 2.40-1). These analyses were performed for each defined therapeutic procedure. Results were plotted as percent of recurrence-free outcomes with their 95% CI. In order to comprehend the data leading to the Kaplan-Meier curves, the numbers of patients included in the intervals of 0-12, 12-24, 24-60, 60-120, and > 120 months are included on the horizontal axes of the plots. If no specific data were available for an interval, linear interpolation of recurrence free outcome according to the two nearest observed follow-up times was used. To provide a comprehensive study on recurrence and a rational basis for selecting treatment procedures, we assessed data in the manner of a classical meta-analysis of RCTs, and further employed an analysis that included non-RCTs in the manner of a merged data analysis. Because the Kaplan-Meier curves were calculated as stepwise functions, small discrepancies between the plotted and the tabled values may occur.

Potential heterogeneity of the study outcomes was assessed through Cochrane analysis and I^2 calculation as described previously^{752,753}. Therefore, the articles were grouped according to procedures and follow-up time-intervals as applied for plotting the Kaplan-Meier curves. A separate analysis was conducted for studies based on randomized controlled trials (RCTs) and for the complete set of studies considered (RCTs and non-RCTs). The data used for computing Cochrane’s Qs were computed with the recurrence as reported in the

corresponding studies, weighted with the respective numbers of study participants. For assessing significance of heterogeneity, a Chi² test was employed. I² was computed to complete the results of the Chi² test.

Data Availability Statement. All data and calculations are available to readers upon request to the corresponding author.

Ethics. This article does not contain any studies with human participants, human samples or live vertebrates. Therefore, no informed consent had to be obtained prior to preparation of current manuscript.

References

- Allen-Mersh, T. G. Pilonidal sinus: finding the right track for treatment. *Br J Surg* **77**, 123–132 (1990).
- Evers, T. *et al.* Trends in incidence and long-term recurrence rate of pilonidal sinus disease and analysis of associated influencing factors. *Zhonghua Wai Ke Za Zhi* **49**, 799–803 (2011).
- Luedi, M. M., Kauf, P., Evers, T., Sievert, H. & Doll, D. Impact of spinal versus general anesthesia on postoperative pain and long term recurrence after surgery for pilonidal disease. *Journal of clinical anesthesia* **33**, 236–242, <https://doi.org/10.1016/j.jclinane.2016.03.061> (2016).
- Doll, D., Luedi, M. M., Evers, T., Kauf, P. & Matevossian, E. Recurrence-free survival, but not surgical therapy per se, determines 583 patients' long-term satisfaction following primary pilonidal sinus surgery. *Int J Colorectal Dis* **30**, 605–611, <https://doi.org/10.1007/s00384-015-2130-0> (2015).
- Akca, T., Colak, T., Ustunsoy, B., Kanik, A. & Aydin, S. Randomized clinical trial comparing primary closure with the Limberg flap in the treatment of primary sacrococcygeal pilonidal disease. *Br J Surg* **92**, 1081–1084, <https://doi.org/10.1002/bjs.5074> (2005).
- Clothier, P. R. & Haywood, I. R. The natural history of the post anal (pilonidal) sinus. *Ann R Coll Surg Engl* **66**, 201–203 (1984).
- Sievert, H. *et al.* The influence of lifestyle (smoking and body mass index) on wound healing and long-term recurrence rate in 534 primary pilonidal sinus patients. *Int J Colorectal Dis* **28**, 1555–1562, <https://doi.org/10.1007/s00384-013-1731-8> (2013).
- Moher, D., Liberati, A., Tetzlaff, J. & Altman, D. G. Preferred reporting items for systematic reviews and meta-analyses: the PRISMA statement. *PLoS medicine* **6**, e1000097, <https://doi.org/10.1371/journal.pmed.1000097> (2009).
- Al-Hassan, H. K. F. & Neglén, I. M. P. Primary closure or secondary granulation after excision of pilonidal sinus. *Acta Chir Scand* **156**, 695–699 (1990).
- Al-Salamah, S. M., Hussain, M. I. & Mirza, S. M. Excision with or without primary closure for pilonidal sinus disease. *J Pak Med Assoc* **57**, 388–391 (2007).
- Biter, L. U. *et al.* The use of negative-pressure wound therapy in pilonidal sinus disease: a randomized controlled trial comparing negative-pressure wound therapy versus standard open wound care after surgical excision. *Dis Colon Rectum* **57**, 1406–1411, <https://doi.org/10.1097/DCR.0000000000000240> (2014).
- Calikoglu, I. *et al.* Phenol Injection Versus Excision With Open Healing in Pilonidal Disease: A Prospective Randomized Trial. *Dis Colon Rectum* **60**, 161–169, <https://doi.org/10.1097/DCR.0000000000000717> (2017).
- Duxbury, M. S., Blake, S. M., Dashfield, A. & Lambert, A. W. A randomised trial of knife versus diathermy in pilonidal disease. *Ann R Coll Surg Engl* **85**, 405–407, <https://doi.org/10.1308/00358840322520799> (2003).
- Fazeli, M. S., Adel, M. G. & Lebaschi, A. H. Comparison of outcomes in Z-plasty and delayed healing by secondary intention of the wound after excision of the sacral pilonidal sinus: results of a randomized, clinical trial. *Dis Colon Rectum* **49**, 1831–1836, <https://doi.org/10.1007/s10350-006-0726-8> (2006).
- Ghnnam, W. M. & Hafez, D. M. Laser hair removal as adjunct to surgery for pilonidal sinus: our initial experience. *J Cutan Aesthet Surg* **4**, 192–195, <https://doi.org/10.4103/0974-2077.91251> (2011).
- Gupta, P. J. Comparative study between radiofrequency sinus excision and open excision in sacro-coccygeal pilonidal sinus disease. *Dig Surg* **22**, 459–463, <https://doi.org/10.1159/000092034> (2005).
- Gupta, P. J. Radiofrequency sinus excision: better alternative to marsupialization technique in sacrococcygeal pilonidal sinus disease. *J Natl Med Assoc* **97**, 998–1002 (2005).
- Gupta, P. A comparison of two operations for pilonidal sinus disease. *Nig J Surg Res* **6**, 41–45 (2004).
- Holzer, B. *et al.* Efficacy and tolerance of a new gentamicin collagen fleece (Septocoll) after surgical treatment of a pilonidal sinus. *Colorectal Dis* **5**, 222–227 (2003).
- Hosseini, S. V. *et al.* The comparison between drainage, delayed excision and primary closure with excision and secondary healing in management of pilonidal abscess. *Int J Surg* **4**, 228–231, <https://doi.org/10.1016/j.ijsu.2005.12.005> (2006).
- Jamal, A., Shamim, M., Hashmi, F. & Qureshi, M. I. Open excision with secondary healing versus rhomboid excision with Limberg transposition flap in the management of sacrococcygeal pilonidal disease. *J Pak Med Assoc* **59**, 157–160 (2009).
- Kareem, T. S. Surgical treatment of chronic sacrococcygeal pilonidal sinus. *Open method versus primary closure. Saudi Med J* **27**, 1534–1537 (2006).
- Kaser, S. A., Zengaffinen, R., Uhlmann, M., Glaser, C. & Maurer, C. A. Primary wound closure with a Limberg flap vs. secondary wound healing after excision of a pilonidal sinus: a multicentre randomised controlled study. *Int J Colorectal Dis* **30**, 97–103, <https://doi.org/10.1007/s00384-014-2057-x> (2015).
- Keshvari, A. *et al.* Karydakias flap versus excision-only technique in pilonidal disease. *J Surg Res* **198**, 260–266, <https://doi.org/10.1016/j.jss.2015.05.039> (2015).
- Khatoon, S. *et al.* Pilonidal sinus: Excision with primary midline closure versus open method. *J Liaquat Univ. Med. Health Sci.* **9**, 9–11 (2010).
- Khawaja, H. T., Bryan, S. & Weaver, P. C. Treatment of natal cleft sinus: a prospective clinical and economic evaluation. *BMJ (Clinical research ed.)* **304**, 1282–1283 (1992).
- Kronborg, O., Christensen, K. & Zimmermann-Nielsen, C. Chronic pilonidal disease: a randomized trial with a complete 3-year follow-up. *Br J Surg* **72**, 303–304 (1985).
- Lundhus, E. & Gottrup, F. Outcome at three to five years of primary closure of perianal and pilonidal abscess. A randomised, double-blind clinical trial with a complete three-year followup of one compared with four days' treatment with ampicillin and metronidazole. *Eur J Surg* **159**, 555–558 (1993).
- Mohamed, H. A., Kadry, I. & Adly, S. Comparison between three therapeutic modalities for non-complicated pilonidal sinus disease. *Surgeon* **3**, 73–77 (2005).
- Ortiz Hurtado, H., Marti Rague, J. & Sitges Creus, A. Pilonidal sinus. Comparison of 3 surgical techniques. *Cir. Esp.* **31**, 413–418 (1977).
- Rao, M. M., Zawislak, W., Kennedy, R. & Gilliland, R. A prospective randomised study comparing two treatment modalities for chronic pilonidal sinus with a 5-year follow-up. *Int J Colorectal Dis* **25**, 395–400, <https://doi.org/10.1007/s00384-009-0804-1> (2010).
- Shah, S. T. A., Tahir, M., Nasir, M., Paracha, S. A. & Wahab, K. Outcome of open versus closed surgical technique for treatment of chronic pilonidal sinus: a randomized controlled trial. *Khyber Med Univ J* **5**, 146–151 (2013).

33. Shah, A., Waheed, A. & Malik, A. Recurrence rates in pilonidal sinus surgery: Comparison of two techniques (Karydakus Versus Conventional Open Excision). *Pak. J. Med. Health Sci.* **3**, 91–95 (2009).
34. Sheikh, M. R., Malik, K. A. & Rehmann, S. Outcome of surgery for pilonidal sinus: Karydakus versus open procedure. *Pak J Surg* **23** (2007).
35. Sondena, K., Nesvik, I., Andersen, E. & Soreide, J. A. Recurrent pilonidal sinus after excision with closed or open treatment: final result of a randomised trial. *Eur. J Surg* **162**, 237–240 (1996).
36. Spyridakis, M., Christodoulidis, G., Chatzitheofilou, C., Symeonidis, D. & Tepetes, K. The role of the platelet-rich plasma in accelerating the wound-healing process and recovery in patients being operated for pilonidal sinus disease: preliminary results. *World J Surg* **33**, 1764–1769, <https://doi.org/10.1007/s00268-009-0046-y> (2009).
37. Testini, M. *et al.* Treatment of chronic pilonidal sinus with local anaesthesia: a randomized trial of closed compared with open technique. *Colorectal Dis.* **3**, 427–430 (2001).
38. Viciano, V. *et al.* Effect of hydrocolloid dressings on healing by second intention after excision of pilonidal sinus. *Eur. J Surg* **166**, 229–232 (2000).
39. Argov, S., Golz, A. & Barzilai, A. Single stage operation for pilonidal sinus. *HAREFUAH* **99**, 420–421 (1980).
40. Arnous, J., Denis, J. & Dubois, N. Treatment of pilonidal sinus by “en bloc excision”. *Gastroenterol Clin Biol* **1**, 945–949 (1977).
41. Andersson, R. E., Lukas, G., Skullman, S. & Hugander, A. Local administration of antibiotics by gentamicin-collagen sponge does not improve wound healing or reduce recurrence rate after pilonidal excision with primary suture: a prospective randomized controlled trial. *World J Surg* **34**, 3042–3048, <https://doi.org/10.1007/s00268-010-0763-2> (2010).
42. Aysan, E., Basak, F., Kinaci, E. & Sevinc, M. Efficacy of local adrenalin injection during sacrococcygeal pilonidal sinus excision. *Eur Surg Res* **36**, 256–258, <https://doi.org/10.1159/00078861> (2004).
43. Dass, T. A., Zaz, M., Rather, A. & Bari, S. Elliptical excision with midline primary closure versus rhomboid excision with limberg flap reconstruction in sacrococcygeal pilonidal disease: a prospective, randomized study. *Indian J Surg* **74**, 305–308, <https://doi.org/10.1007/s12262-011-0400-9> (2012).
44. Galal Elshazly, W. & Said, K. Clinical trial comparing excision and primary closure with modified Limberg flap in the treatment of uncomplicated sacrococcygeal pilonidal disease. *Alexandria Journal of Medicine* **48**, 13–18, <https://doi.org/10.1016/j.ajme.2011.10.002> (2012).
45. Enshaei, A. & Motearefi, S. Comparison of two surgical methods, primary closure and rotational flap, in patients with chronic pilonidal sinus. *Glob J Health Sci* **6**, 18–22, <https://doi.org/10.5539/gjhs.v6n7p18> (2014).
46. Ertan, T. *et al.* Does technique alter quality of life after pilonidal sinus surgery? *Am J Surg* **190**, 388–392, <https://doi.org/10.1016/j.amjsurg.2004.08.068> (2005).
47. Fuzun, M. *et al.* Which technique for treatment of pilonidal sinus—open or closed? *Dis Colon Rectum* **37**, 1148–1150 (1994).
48. Gencosmanoglu, R. & Inceoglu, R. Modified lay-open (incision, curettage, partial lateral wall excision and marsupialization) versus total excision with primary closure in the treatment of chronic sacrococcygeal pilonidal sinus: a prospective, randomized clinical trial with a complete two-year follow-up. *Int J Colorectal Dis* **20**, 415–422, <https://doi.org/10.1007/s00384-004-0710-5> (2005).
49. Khan, P. S., Hayat, H. & Hayat, G. Limberg flap versus primary closure in the treatment of primary sacrococcygeal pilonidal disease; a randomized clinical trial. *Indian J Surg* **75**, 192–194, <https://doi.org/10.1007/s12262-012-0430-y> (2013).
50. Lorant, T., Ribbe, I., Mahteme, H., Gustafsson, U. M. & Graf, W. Sinus excision and primary closure versus laying open in pilonidal disease: a prospective randomized trial. *Dis Colon Rectum* **54**, 300–305, <https://doi.org/10.1007/DCR.0b013e31820246bf> (2011).
51. Milone, M., Musella, M., Salvatore, G., Leongito, M. & Milone, F. Effectiveness of a drain in surgical treatment of sacrococcygeal pilonidal disease. Results of a randomized and controlled clinical trial on 803 consecutive patients. *Int J Colorectal Dis* **26**, 1601–1607, <https://doi.org/10.1007/s00384-011-1242-4> (2011).
52. Milone, M. *et al.* Intradermal absorbable sutures to close pilonidal sinus wounds: a safe closure method? *Surg Today* **44**, 1638–1642, <https://doi.org/10.1007/s00595-013-0741-z> (2014).
53. Morrison, P. D. Is Z-plasty closure reasonable in pilonidal disease? *Ir J Med Sci* **154**, 110–112 (1985).
54. Muzi, M. G. *et al.* Randomized comparison of Limberg flap versus modified primary closure for the treatment of pilonidal disease. *Am J Surg* **200**, 9–14, <https://doi.org/10.1016/j.amjsurg.2009.05.036> (2010).
55. Nursal, T. Z. *et al.* Prospective randomized controlled trial comparing V-Y advancement flap with primary suture methods in pilonidal disease. *Am J Surg* **199**, 170–177, <https://doi.org/10.1016/j.amjsurg.2008.12.030> (2010).
56. Okus, A., Sevinc, B., Karahan, O. & Eryilmaz, M. A. Comparison of Limberg flap and tension-free primary closure during pilonidal sinus surgery. *World J Surg* **36**, 431–435, <https://doi.org/10.1007/s00268-011-1333-y> (2012).
57. Othman, I. Skin glue improves outcome after excision and primary closure of sacrococcygeal pilonidal disease. *Indian J Surg* **72**, 470–474, <https://doi.org/10.1007/s12262-010-0170-9> (2010).
58. Perepelitsa, G. F. & Dulinov, A. I. Use of lasers in the surgical treatment of suppurative pilonidal cysts. *Klin Khir*, 68 (1990).
59. Polat, N., Albayrak, D., Ibiş, A. C. & Altan, A. Comparison between karydakus flap repair and primary closure for surgical treatment of sacrococcygeal pilonidal sinus. *Trakya Universitesi Tip Fakultesi Derg.* **25**, 87–94 (2008).
60. Pomazkin, V. I. & Mansurov, I. V. Choice of operation for treatment of patients with pilonidal sinus. *Vestn Khir Im I I Grek* **167**, 85–87 (2008).
61. Roshdy, H., Ali, Y., Askar, W., Awad, I. & Farid, M. Rhomboid flap versus primary closure after excision of sacrococcygeal pilonidal sinus (a prospective randomized study). *Egypt J Surg* **29**, 146–152 (2010).
62. Sakr, M. F. & Moussa, M. A. Prospective controlled randomized trial comparing Karydakus technique and midline closure in patients with recurrent chronic pilonidal sinus. *Surg. Chronicles* **16**, 84–90 (2011).
63. Sakr, M., Habib, M. & Shaheed, A. A. Assessment of Karydakus technique as compared with midline closure for the management of chronic pilonidal sinus. *J. Pelvic Med. Surg.* **12**, 201–206, <https://doi.org/10.1097/01.spv.0000217399.78641.43> (2006).
64. Sevinc, B. *et al.* Randomized prospective comparison of midline and off-midline closure techniques in pilonidal sinus surgery. *Surgery* **159**, 749–754, <https://doi.org/10.1016/j.surg.2015.09.024> (2016).
65. Shabbir, F. *et al.* Modified Limberg’s flap versus primary closure for treatment of pilonidal sinus disease: a comparative study. *J Pak Med Assoc* **64**, 1270–1273 (2014).
66. Sondena, K. *et al.* The role of cefoxitin prophylaxis in chronic pilonidal sinus treated with excision and primary suture. *J Am Coll Surg* **180**, 157–160 (1995).
67. Sondena, K. *et al.* Influence of failure of primary wound healing on subsequent recurrence of pilonidal sinus. combined prospective study and randomised controlled trial. *Eur. J Surg* **168**, 614–618 (2002).
68. Sondena, K., Andersen, E. & Soreide, J. A. Morbidity and short term results in a randomised trial of open compared with closed treatment of chronic pilonidal sinus. *Eur. J Surg* **158**, 351–355 (1992).
69. Sondena, K., Nesvik, I., Andersen, E., Natas, O. & Soreide, J. A. Bacteriology and complications of chronic pilonidal sinus treated with excision and primary suture. *Int J Colorectal Dis* **10**, 161–166 (1995).
70. Terzi, C., Canda, A. E., Unek, T., Dalgic, E. & Fuzun, M. What is the role of mechanical bowel preparation in patients with pilonidal sinus undergoing surgery? Prospective, randomized, surgeon-blinded trial. *World J Surg* **29**, 1465–1471, <https://doi.org/10.1007/s00268-005-0007-z> (2005).
71. Vogel, P. & Lenz, J. Treatment of pilonidal sinus with excision and primary suture using a local, resorbable antibiotic carrier. *Results of a prospective randomized study.* *Chirurg* **63**, 748–753 (1992).

72. Yetim, I., Ozkan, O. V., Dervisoglu, A., Erzurumlu, K. & Canbolant, E. Effect of gentamicin-absorbed collagen in wound healing in pilonidal sinus surgery: a prospective randomized study. *J Int Med Res* **38**, 1029–1033 (2010).
73. Youssef, T. E.-A. S. & Farid, M. Tension-free primary closure compared with modified Limberg flap for pilonidal sinus disease: a prospective balanced randomized study. *RR unglaublich niedrig bei 100% FUP* **34**, 85–89 (2015).
74. Aaser, P. & Gruner, O. P. Pilonidal cysts. *Excision and intracutaneous absorbable primary suture. Tidsskr Nor Laegeforen* **112**, 206–207 (1992).
75. Abou-Zikry, A. S., Guindi, A. & Hashem, M. Pilonidal sinus and cysts (sacro-coccygeal sinus); report of 22 cases treated by excision and primary suture. *J Egypt Med Assoc.* **37**, 696–705 (1954).
76. Bruscianno, L. *et al.* D-shape asymmetric excision of sacrococcygeal pilonidal sinus with primary closure, suction drain, and subcuticular skin closure: an analysis of risks factors for long-term recurrence. *Surg Innov* **22**, 143–148, <https://doi.org/10.1177/1553350614535856> (2015).
77. Bali, I. *et al.* Effectiveness of Limberg and Karydakís flap in recurrent pilonidal sinus disease. *Clinics (Sao Paulo)* **70**, 350–355, [https://doi.org/10.6061/clinics/2015\(05\)08](https://doi.org/10.6061/clinics/2015(05)08) (2015).
78. Bessa, S. S. Comparison of short-term results between the modified Karydakís flap and the modified Limberg flap in the management of pilonidal sinus disease: a randomized controlled study. *Dis Colon Rectum* **56**, 491–498, <https://doi.org/10.1097/DCR.0b013e31828006f7> (2013).
79. Boereboom, C. L., Watson, N. F. A., Liptrot, S. A. & Lund, J. N. A randomised trial of fibrin glue vs surgery for pilonidal sinus disease: results and long term follow up. *Iq bassam diss* **12**, 1280–1283, <https://doi.org/10.1111/j.1463-1318.2010.02336.x> (2010).
80. Can, M. F., Sevinc, M. M., Hancerliogullari, O., Yilmaz, M. & Yagci, G. Multicenter prospective randomized trial comparing modified Limberg flap transposition and Karydakís flap reconstruction in patients with sacrococcygeal pilonidal disease. *Am J Surg* **200**, 318–327, <https://doi.org/10.1016/j.amjsurg.2009.08.042> (2010).
81. Demircan, F. *et al.* The effect of laser epilation on recurrence and satisfaction in patients with sacrococcygeal pilonidal disease: a prospective randomized controlled trial. *Int J Clin Exp Med* **8**, 2929–2933 (2015).
82. Ersoy, E. *et al.* Comparison of the short-term results after Limberg and Karydakís procedures for pilonidal disease: randomized prospective analysis of 100 patients. *Colorectal Dis* **11**, 705–710, <https://doi.org/10.1111/j.1463-1318.2008.01646.x> (2009).
83. Guner, A. *et al.* Limberg flap versus Bascom cleft lift techniques for sacrococcygeal pilonidal sinus: prospective, randomized trial. *World J Surg* **37**, 2074–2080, <https://doi.org/10.1007/s00268-013-2111-9> (2013).
84. Gurer, A. *et al.* Is routine cavity drainage necessary in Karydakís flap operation? A prospective, randomized trial. *Dis Colon Rectum* **48**, 1797–1799, <https://doi.org/10.1007/s10350-005-0108-7> (2005).
85. Milone, M., Fernandez, L. M., Musella, M. & Milone, F. Safety and Efficacy of Minimally Invasive Video-Assisted Ablation of Pilonidal Sinus: A Randomized Clinical Trial. *JAMA Surg* **151**, 547–553, <https://doi.org/10.1001/jamasurg.2015.5233> (2016).
86. Nordon, I. M., Senapati, A. & Cripps, N. P. A prospective randomized controlled trial of simple Bascom's technique versus Bascom's cleft closure for the treatment of chronic pilonidal disease. *Am J Surg* **197**, 189–192, <https://doi.org/10.1016/j.amjsurg.2008.01.020> (2009).
87. Sahin, A., Olcucuoglu, E., Seker, D. & Kulacoglu, H. The effect of using methylene blue in surgical treatments of pilonidal disease: a prospective randomized study. *European Surgery* **46**, 148–154, <https://doi.org/10.1007/s10353-014-0276-6> (2014).
88. Sevinc, B. *et al.* Randomized prospective comparison of midline and off-midline closure techniques in pilonidal sinus surgery. *Surgery*, <https://doi.org/10.1016/j.surg.2015.09.024> (2015).
89. Sozen, S., Emir, S., Guzel, K. & Ozdemir, C. S. Are postoperative drains necessary with the Karydakís flap for treatment of pilonidal sinus? (Can fibrin glue be replaced to drains?) A prospective randomized trial. *Ir J Med Sci* **180**, 479–482, <https://doi.org/10.1007/s11845-010-0549-4> (2011).
90. Tokac, M., Dumlu, E. G., Aydin, M. S., Yalcin, A. & Kilic, M. Comparison of modified limberg flap and karydakís flap operations in pilonidal sinus surgery: prospective randomized study. *Int Surg* **100**, 870–877, <https://doi.org/10.9738/INTSURG-D-14-00213.1> (2015).
91. Abdelrazeq, A. S., Rahman, M., Botterill, I. D. & Alexander, D. J. Short-term and long-term outcomes of the cleft lift procedure in the management of nonacute pilonidal disorders. *Dis Colon Rectum* **51**, 1100–1106, <https://doi.org/10.1007/s10350-008-9262-z> (2008).
92. Abdul-Ghani, A. K., Abdul-Ghani, A. N. & Ingham Clark, C. L. Day-care surgery for pilonidal sinus. *Ann R Coll Surg Engl* **88**, 656–658, <https://doi.org/10.1308/003588406X149255> (2006).
93. Colak, T., Turkmenoglu, O., Dag, A., Akca, T. & Aydin, S. A randomized clinical study evaluating the need for drainage after Limberg flap for pilonidal sinus. *J Surg Res* **158**, 127–131, <https://doi.org/10.1016/j.jss.2008.11.005> (2010).
94. Das, K. *et al.* Diathermy versus scalpel in Limberg flap in pilonidal sinus surgery. A prospective randomized trial. *Ann Ital Chir* **85**, 148–152 (2014).
95. Erdem, E., Sungurtekin, U. & Nessar, M. Are postoperative drains necessary with the Limberg flap for treatment of pilonidal sinus? *Dis Colon Rectum* **41**, 1427–1431 (1998).
96. Karakayali, F. *et al.* Unroofing and marsupialization vs. rhomboid excision and Limberg flap in pilonidal disease: a prospective, randomized, clinical trial. *Dis Colon Rectum* **52**, 496–502, <https://doi.org/10.1007/DCR.0b013e31819a3ec0> (2009).
97. Kirkil, C. *et al.* The effects of drainage on the rates of early wound complications and recurrences after Limberg flap reconstruction in patients with pilonidal disease. *Tech Coloproctol* **15**, 425–429, <https://doi.org/10.1007/s10151-011-0782-5> (2011).
98. Saydam, M. *et al.* Comparison of modified Limberg flap transposition and lateral advancement flap transposition with Burow's triangle in the treatment of pilonidal sinus disease. *Am J Surg* **210**, 772–777, <https://doi.org/10.1016/j.amjsurg.2015.03.031> (2015).
99. Sungurtekin, H., Sungurtekin, U. & Erdem, E. Local anesthesia and midazolam versus spinal anesthesia in ambulatory pilonidal surgery. *J Clin Anesth* **15**, 201–205 (2003).
100. Yabanoglu, H., Karagulle, E., Belli, S. & Turk, E. Results of modified Dufourmentel rhomboid flap in patients with extensive Sacrococcygeal pilonidal disease. *Acta Chir Belg* **114**, 52–57 (2014).
101. Yetişir, F., Kaya, O. & Baran, I. The comparison of marsupialization and Limberg flap in the treatment of pilonidal disease. *Turk. J. Surg.* **21**, 184–190 (2005).
102. Zorlu, M. *et al.* Early results with the Mutaf technique: a novel off-midline approach in pilonidal sinus surgery. *!!writing* **90**, 265–271, <https://doi.org/10.4174/ast.2016.90.5.265> (2016).
103. Abu Galala, K. H., Salam, I. M. A., El Ashaal, Y. I., Chandran, V. P. & Sim, A. J. W. Excision of pilonidal sinus and primary closure by a rhomboid flap transposition. *Asian Journal of Surgery* **19**, 305–308 (1996).
104. Afsarlar, C. E. *et al.* Treatment of adolescent pilonidal disease with a new modification to the Limberg flap: symmetrically rotated rhomboid excision and lateralization of the Limberg flap technique. *J Pediatr Surg* **48**, 1744–1749, <https://doi.org/10.1016/j.jpedsurg.2013.01.029> (2013).
105. Malik, G. A., Choudary, T. H. & Wahab, A. Pilonidal Sinus; Prevalence and comparison of excision and primary closure with lay open procedure. *Professional Med J* **16**, 297–298 (2009).
106. Acarturk, T. O., Parsak, C. K., Sakman, G. & Demircan, O. Superior gluteal artery perforator flap in the reconstruction of pilonidal sinus. *J Plast Reconstr Aesthet Surg* **63**, 133–139, <https://doi.org/10.1016/j.bjps.2008.07.017> (2010).
107. Awad, M. M. & Saad, K. M. Does closure of chronic pilonidal sinus still remain a matter of debate after bilateral rotation flap? (N-shaped closure technique). *daten nachtragen* **39**, 157–162 (2006).

108. Abramson, D. J. A simple marsupialization technic for treatment of pilonidal sinus: long-term follow up. *Ann Surg* **151**, 261–267 (1960).
109. Abramson, D. J. An open, semiprimary closure operation for pilonidal sinuses, using local anesthesia. *Dis Colon Rectum* **13**, 215–219 (1970).
110. Al-Naami, M. Y. Outpatient pilonidal sinotomy complemented with good wound and surrounding skin care. *Saudi Med J* **26**, 285–288 (2005).
111. Awad, M. M. *et al.* A scoring system as a method to evaluate pilonidal sinus disease to make an easy decision for its management. *Daten nachtragen* **42**, 43–48, <https://doi.org/10.4103/0970-0358.53011> (2009).
112. Baier, P. K., Baumgartner, U., Furtwangler, A., Holzinger, F. & Schoffel, U. Therapy of the pilonidal sinus—Primary wound closure or open wound after excision. *Zentralbl Chir* **127**, 310–314, <https://doi.org/10.1055/s-2002-31557> (2002).
113. Baldelli, C. M. *et al.* A short course of granulocyte-colony-stimulating factor to accelerate wound repair in patients undergoing surgery for sacrococcygeal pilonidal cyst: proof of concept. *Cytotherapy* **14**, 1101–1109, <https://doi.org/10.3109/14653249.2012.697147> (2012).
114. Bianco, V., Basile, C. & Tortorella, M. Sacrococcygeal pilonidal sinus disease. Treatment by “open” and “closed” technique: personal experience. *G Chir* **24**, 145–147 (2003).
115. Blake P. *et al.* Tratamiento quirurgico del quiste pilonidal. *Revista chilena de cirugía* (1997).
116. Blanco, G., Giordano, M. & Torelli, I. Surgical treatment of pilonidal sinus with open surgical technique. *Minerva Chir* **58**, 181–187 (2003).
117. Bracho Bracho, J. & Lira Soto, N. M. Enfermedad pilonidal: tecnica cerrada Vs. tecnica abierta con anestesia local. *Boletin médico de postgrado* (1996).
118. Breidenbach, L. & Wilson, H. L. P. Cysts and Sinuses. *Ann Surg* **102**, 455–463 (1935).
119. Brust, J. C. & Sarner, J. B. Pilonidal cyst. *N Y State J Med* **48**, 2138–2144 (1948).
120. Butter, A., Hanson, M., VanHouwelingen, L., Merritt, N. & Seabrook, J. Hair epilation versus surgical excision as primary management of pilonidal disease in the pediatric population. *Can J Surg* **58**, 209–211 (2015).
121. Carstensen, E. & Keichel, F. Etiology and therapy of pilonidal sinus. *Chirurg* **34**, 303–308 (1963).
122. Castronovo, G., Ciulla, A., Urso, G., Tomasello, G. & Damiani, S. Pilonidal sinus: an retrospective analysis of 205 cases. *Ann Ital Chir* **74**, 559–563 (2003).
123. Chiedozi, L. C., Al-Rayyes, F. A., Salem, M. M., Al-Haddi, F. H. & Al-Bidewi, A. A. Management of pilonidal sinus. *Saudi Med J* **23**, 786–788 (2002).
124. Cimarelli, S. & Magnano, G. Treatment of pilonidal sinus. *Our experience. Minerva Chir* **44**, 1131–1134 (1989).
125. Close, A. S. Pilonidal cysts: an analysis of surgical failures. *Ann Surg* **141**, 523–526 (1955).
126. Coda, A. & Ferri, F. Sinus pilonidalis: Removal and primary suture with aspirative draining. *Chirurgia* **3**, 433–437 (1990).
127. Dahmann, S., Lebo, P. B. & Meyer-Marcotty, M. V. Comparison of Treatments for an Infected Pilonidal Sinus: Differences in Scar Quality and Outcome Between Secondary Wound Healing and Limberg Flap in a Prospective Study. *Handchir Mikrochir Plast Chir* **48**, 111–119, <https://doi.org/10.1055/s-0041-111322> (2016).
128. Falco, M. *et al.* Surgical treatment of sinus pilonidalis by Dufourmentel’s flap technique. *Il Giornale di chirurgia* **28**, 93–97 (2007).
129. DeRosario, J. L. & Khare, U. Pilonidal disease—a surgical enigma. *Can Med Assoc J* **93**, 1262–1267 (1965).
130. Destito, C., Romagnoli, A., Pucello, D., Mercuri, M. & Marin, A. W. Pilonidal sinus: long term results of excision and closure technic. *Review of the literature. G Chir* **18**, 441–446 (1997).
131. Doll, D. *et al.* Methylene Blue halves the long-term recurrence rate in acute pilonidal sinus disease. *Int J Colorectal Dis* **23**, 181–187, <https://doi.org/10.1007/s00384-007-0393-9> (2008).
132. Doll, D. *et al.* Timeline of recurrence after primary and secondary pilonidal sinus surgery. *Dis Colon Rectum* **50**, 1928–1934, <https://doi.org/10.1007/s10350-007-9031-4> (2007).
133. Doll, D., Matevossian, E., Hoenemann, C. & Hoffmann, S. Incision and drainage preceding definite surgery achieves lower 20-year long-term recurrence rate in 583 primary pilonidal sinus surgery patients. *patienten info* **11**, 60–64, <https://doi.org/10.1111/j.1610-0387.2012.08007.x> (2013).
134. Donati, A. *et al.* Heterologous lyophilized collagen in the secondary healing of pilonidal fistulae. *Minerva Chir* **48**, 141–145 (1993).
135. Dorman, R. M. & Bass, K. D. Novel use of porcine urinary bladder matrix for pediatric pilonidal wound care: preliminary experience. *Pediatr Surg Int* **32**, 997–1002, <https://doi.org/10.1007/s00383-016-3915-0> (2016).
136. Dudink, R., Veldkamp, J., Nienhuijs, S. & Heemskerk, J. Secondary healing versus midline closure and modified Bascom natal cleft lift for pilonidal sinus disease. *Scand J Surg* **100**, 110–113 (2011).
137. Dwight, R. W. & Maloy, J. K. Pilonidal sinus; experience with 449 cases. *N Engl J Med* **249**, 926–930, <https://doi.org/10.1056/NEJM195312032492303> (1953).
138. Eftaiha, M. & Abcarian, H. The dilemma of pilonidal disease: surgical treatment. *Dis Colon Rectum* **20**, 279–286 (1977).
139. Eichfuss, H. P., Schontag, H. & Pfeiffer, M. A new surgical procedure for treating sacrococcygeal fistulas and cysts. *Aktuel Chir* **17**, 138–140 (1982).
140. Elbanna, H. G. *et al.* Novel Approach of Treatment of Pilonidal Sinus Disease With Thrombin Gelatin Matrix as a Sealant. *Dis Colon Rectum* **59**, 775–780, <https://doi.org/10.1097/DCR.0000000000000604> (2016).
141. Fahrni, G. T. *et al.* Five-year Follow-up and Recurrence Rates Following Surgery for Acute and Chronic Pilonidal Disease: A Survey of 421 Cases. *Wounds* **28**, 20–26 (2016).
142. Feigenbaum, H. A. Excision of acute pilonidal cyst abscess; a preliminary report. *Am J Surg* **94**, 636–637 (1957).
143. Fitzpatrick, E. B. *et al.* Pilonidal disease in a military population: how far have we really come? *Am J Surg* **207**, 907–914, <https://doi.org/10.1016/j.amjsurg.2013.07.038> (2014).
144. Fox, P. F. Pilonidal Cysts and Sinuses in Identical Twins. *Journal of the American Medical Association (JAMA)* **125**, 120 (1944).
145. Garcia, J. C. & Dupuis, F. Surgical treatment of pilonidal disease. A new simplified technic. *J Chir (Paris)* **120**, 347–350 (1983).
146. Gendy, A. S. *et al.* A comparison of the cleft lift procedure vs wide excision and packing for the treatment of pilonidal disease in adolescents. *J Pediatr Surg* **46**, 1256–1259, <https://doi.org/10.1016/j.jpedsurg.2011.03.062> (2011).
147. Gerhard, H. On the understanding and treating coccygeal fistulae. *Z Aertzl Fortbildg (Jena)* **57**, 841–843 (1963).
148. Golz, A., Argov, S. & Barzilai, A. Pilonidal sinus disease: comparison among various methods of treatment and a survey of 160 patients. *Curr Surg* **37**, 77–85 (1980).
149. Goodall, P. The aetiology and treatment of pilonidal sinus. A review of 163 patients. *Br J Surg* **49**, 212–218 (1961).
150. Grandjean, J. P. & Al Nashawati, G. Pilonidal disease treated by wide excision and controlled cicatrization. A report on 73 patients. *Lyon Chir* **92**, 292–295 (1996).
151. Gupta, P. J. Radio surgery in pilonidal sinus: a new approach for the old problem. *Acta Chir Belg* **105**, 183–186 (2005).
152. Guyuron, B., Dinner, M. I. & Dowden, R. V. Excision and grafting in treatment of recurrent pilonidal sinus disease. *Surg Gynecol Obstet* **156**, 201–204 (1983).
153. Hell, E., Zimmermann, G. & Boeckl, O. Pilonidal disorder (pilonidal cyst) and its treatment. *Med Welt* **6**, 230–232 (1971).
154. Hemati, H. R., Ghorbani, R. & Nayeri Tarshizi, E. Recurrence rate in the pilonidal sinus after excision with or without primary closure. *Koomesh* **15**, 78–82 (2013).
155. Hoffert, P. W. & Healy, M. J. Jr. Pilonidal sinus and cyst: an analysis of the results of surgical therapy in 229 consecutive cases. *Bull N Y Acad Med* **28**, 612 (1952).

156. Holmebakk, T. & Nesbakken, A. Surgery for pilonidal disease. *Scand J Surg* **94**, 43–46 (2005).
157. Hosseini, M., Heidari, A. & Jafarnejad, B. Comparison of Three Surgical Methods in Treatment of Patients with Pilonidal Sinus: Modified Excision and Repair/Wide Excision/Wide Excision and Flap in RASOUL, OMID and SADR Hospitals (2004–2007). *Indian J Surg* **75**, 395–400, <https://doi.org/10.1007/s12262-012-0713-3> (2013).
158. Houston, H. E. One-stage cure of infected pilonidal cysts. *Am Surg* **43**, 517–519 (1977).
159. Hughes, L. E. & Harding, K. G. Radical surgery for pilonidal sinus. *Annals of the Royal College of Surgeons of England* **65**, 64–65 (1983).
160. Iesalnieks, I., Furst, A., Rentsch, M. & Jauch, K. W. Primary midline closure after excision of a pilonidal sinus is associated with a high recurrence rate. *Chirurg* **74**, 461–468, <https://doi.org/10.1007/s00104-003-0616-8> (2003).
161. Iesalnieks, I., Deimel, S. & Schlitt, H. J. Karydakís flap for recurrent pilonidal disease. *World J Surg* **37**, 1115–1120, <https://doi.org/10.1007/s00268-013-1950-8> (2013).
162. Jordan, M. H. & Meinecke, H. M. Ambulatory surgery for pilonidal disease. *Am Surg* **45**, 360–363 (1979).
163. Kasim, K., Abdhamid, N. M., Badwan, B. R. & Allowbany, A. Is There a Relation Between Natal Cleft Depth and Post-Operative Morbidity After Different Methods of Excision of Sacro-Coccygeal Pilonidal Sinus? *Indian J Surg* **77**, 201–205, <https://doi.org/10.1007/s12262-012-0762-7> (2015).
164. Kement, M., Oncel, M., Kurt, N. & Kaptanoglu, L. Sinus excision for the treatment of limited chronic pilonidal disease: results after a medium-term follow-up. *Dis Colon Rectum* **49**, 1758–1762, <https://doi.org/10.1007/s10350-006-0676-1> (2006).
165. Khodakaram, K., Stark, J., Hoglund, I. & Andersson, R. E. Minimal Excision and Primary Suture is a Cost-Efficient Definitive Treatment for Pilonidal Disease with Low Morbidity: A Population-Based Interventional and a Cross-Sectional Cohort Study. *World J Surg*. <https://doi.org/10.1007/s00268-016-3828-z> (2016).
166. Kleckner, M. S. Pilonidal Sinus: Its surgical management. *Trans Am Proctol Soc* **36**, 166 (1936).
167. Kleiman, A. Pilonidal cyst; follow-up studies on 481 patients. *US Armed Forces Med J* **3**, 575–580 (1952).
168. Kooistra, H. P. Pilonidal sinuses. Review of the literature and report of three hundred fifty cases. *Am J Surg* **LV** 1, 3–17 (1942).
169. Lamke, L. O., Larsson, J. & Nylen, B. Results of different types of operation for pilonidal sinus. *Acta Chir Scand* **140**, 321–324 (1974).
170. Larsen, B. B. Comparative results-in operations for pilonidal cysts. *Arch Surg* **56**, 516–521 (1948).
171. Lawrence, K. B. & Baker, W. J. The marsupialization operation for pilonidal sinus; a comparison with other surgical methods in 359 cases. *N Engl J Med* **245**, 134–139, <https://doi.org/10.1056/NEJM195107262450403> (1951).
172. Leak, K., Widgerow, A. & Johnson, S. Pilonidal sinus (Jeep's disease): An improved model of care. *Wounds UK* **7**, 72–77 (2011).
173. Thompson, J. P. S. & Lee, J. Radical surgery for pilonidal sinus. *Annals of the Royal College of Surgeons of England* **65**, 64–65 (1983).
174. Leoni, G. *et al.* Sinus pilonidalis. Critical review of our experience. *Chirurgia* **11**, 93–96 (1998).
175. Lukish, J. R., Kindelan, T., Marmon, L. M., Pennington, M. & Norwood, C. Laser epilation is a safe and effective therapy for teenagers with pilonidal disease. *J Pediatr Surg* **44**, 282–285, <https://doi.org/10.1016/j.jpedsurg.2008.10.057> (2009).
176. Lynch, J. B., Laing, A. J. & Regan, P. J. Vacuum-assisted closure therapy: a new treatment option for recurrent pilonidal sinus disease. *Report of three cases. Dis Colon Rectum* **47**, 929–932, <https://doi.org/10.1007/s10350-004-0522-2> (2004).
177. Macfee, W. F. Pilonidal Cysts and Sinuses: A Method of Wound Closure: Review of 230 Cases. *Ann Surg* **116**, 687–699 (1942).
178. Mathesheimer, J. L. An ambulant method for the treatment of pilonidal disease. *Am J Surg* **69**, 230–231 (1945).
179. Matter, I., Kunin, J., Schein, M. & Eldar, S. Total excision versus non-resectional methods in the treatment of acute and chronic pilonidal disease. *Br J Surg* **82**, 752–753 (1995).
180. McGuinness, J. G., Winter, D. C. & O'Connell, P. R. Vacuum-assisted closure of a complex pilonidal sinus. *Dis Colon Rectum* **46**, 274–276, <https://doi.org/10.1097/01.DCR.0000049220.07412.0B> (2003).
181. McKirdie, M. Pilonidal Sinus. *Ann Surg* **107**, 389–399 (1938).
182. Meier, H. P. Recurrence in sacral dermoid (sinusitis pilonidalis sacralis). *Helv Chir Acta* **49**, 645–649 (1983).
183. Menzel, T., Dorner, A. & Cramer, J. Excision and open wound treatment of pilonidal sinus. Rate of recurrence and duration of work incapacity. *Dtsch Med Wochenschr* **122**, 1447–1451, <https://doi.org/10.1055/s-2008-1047784> (1997).
184. Morden, P., Drongowski, R. A., Geiger, J. D., Hirschl, R. B. & Teitelbaum, D. H. Comparison of Karydakís versus midline excision for treatment of pilonidal sinus disease. *Pediatr Surg Int* **21**, 793–796, <https://doi.org/10.1007/s00383-005-1543-1> (2005).
185. Mueller, X., Rothenbuehler, J. M. & Frede, K. E. Sacrococcygeal cysts. Is Lord Millar's procedure an alternative to exeresis? *J Chir* **128**, 487–490 (1991).
186. Mustafi, N. & Engels, P. Post-surgical wound management of pilonidal cysts with a haemoglobin spray: a case series. *J Wound Care* **25**, 191–198, <https://doi.org/10.12968/jowc.2016.25.4.191> (2016).
187. Nahas, S. C. *et al.* Results of the surgical treatment of non-complicated pilonidal disease. *Rev Hosp Clin Fac Med Sao Paulo* **52**, 287–290 (1997).
188. Nasr, A. & Ein, S. H. A pediatric surgeon's 35-year experience with pilonidal disease in a Canadian children's hospital. *Can J Surg* **54**, 39–42 (2011).
189. Notaras, M. J. A review of three popular methods of treatment of postanal (pilonidal) sinus disease. *Br J Surg* **57**, 886–890 (1970).
190. Obedman, M. & Vaticon, D. Pilonidal sinus: a high-incidence disease among adolescents. *etiology, hair, recurrence, incidence* **6**, 21–36, <https://doi.org/10.1515/IJAMH.1993.6.1.21> (1993).
191. Ommer, A. *et al.* Pilonidal Sinus—Primary Closure also in Case of Abscess? *Zentralbl Chir* **129**, 216–219, <https://doi.org/10.1055/s-2004-822742> (2004).
192. Oram, Y., Kahraman, F., Karıncaoglu, Y. & Koyuncu, E. Evaluation of 60 patients with pilonidal sinus treated with laser epilation after surgery. *Dermatol Surg* **36**, 88–91, <https://doi.org/10.1111/j.1524-4725.2009.01387.x> (2010).
193. Ortiz, H. H., Marti, J. & Sitges, A. Pilonidal sinus: a claim for simple track incision. *Dis Colon Rectum* **20**, 325–328 (1977).
194. Oueidat, D., Dirani, R. A., Assi, M., Shams, T. B. & Jurjus, A. A. 25 years' experience in the management of pilonidal sinus disease. *Open Journal of Gastroenterology* **4**, 5 (2014).
195. Patti, R. *et al.* Use of fibrin glue in the treatment of pilonidal sinus disease: a pilot study. *G Chir* **27**, 331–334 (2006).
196. Pazdirek, F., Kouda, M., Jech, Z., Frajer, L. & J., J. H. *Pilonidal sinus - diagnosis at the intersection of general and plastic surgery*. **93**, 545–548 (2014).
197. Perruchoud, C., Vuilleumier, H. & Givel, J. C. Pilonidal sinus: how to choose between excision and open granulation versus excision and primary closure? Study of a series of 141 patients operated on from 1991 to 1995. *Swiss Surg* **8**, 255–258 (2002).
198. Petersen, S. *et al.* Short-term results of Karydakís flap for pilonidal sinus disease. *Tech. Coloproctol.* **11**, 235–240 (2007).
199. Rabie, M. E. *et al.* Sacrococcygeal pilonidal disease: sinotomy versus excisional surgery, a retrospective study. *ANZ J Surg* **77**, 177–180, <https://doi.org/10.1111/j.1445-2197.2006.04002.x> (2007).
200. Riedler, L., Weimann, S. & Steiner, E. Operative therapy of the pilonidal sinus; 115 controlled patients. *Zentralbl Chir* **103**, 1410–1415 (1978).
201. Roberton, H. R. Pilonidal surgery. *Med J Aust* **1**, 375–376 (1981).
202. Rogers, H. & Dwight, R. W. Pilonidal Sinus: Observations on One Hundred Forty Cases Treated by Cautery Excision. *Ann Surg* **107**, 400–418 (1938).
203. Rosato, L., Fornero, G., Luc, A. R. & Clerico, G. The radical treatment of sacrococcygeal pilonidal cysts. *Minerva Chir* **52**, 1277–1279 (1997).

204. Rouch, J. D. *et al.* Short- and Long-term Results of Unroofing and Marsupialization for Adolescent Pilonidal Disease. *JAMA Surg* **151**, 877–879, <https://doi.org/10.1001/jamasurg.2016.0850> (2016).
205. Ruf, G. Pilonidal sinus. *Coloproctology* **28**, 315–321, <https://doi.org/10.1007/s00053-006-6024-z> (2006).
206. Sakr, M. F., Hamed, H. H., Ramadan, M. A., Kantoush, H. E. & Al-Torky, H. M. Pilonidal sinus in Kuwait: Analysis of 801 consecutive patients. (2012).
207. Sasse, K. C., Brandt, J., Lim, D. C. & Ackerman, E. Accelerated healing of complex open pilonidal wounds using MatriStem extracellular matrix xenograft: nine cases. *J Surg Case Rep* **2013**, <https://doi.org/10.1093/jscr/rjr025> (2013).
208. Schmitt, J. C. *et al.* Pilonidal cysts. 161 operated cases. *Ann Chir* **31**, 973–979 (1977).
209. Seleem, M. I. & Al-Hashemy, A. M. Management of pilonidal sinus using fibrin glue: a new concept and preliminary experience. *Colorectal Dis* **7**, 319–322, <https://doi.org/10.1111/j.1463-1318.2005.00808.x> (2005).
210. Shafik, A. Electrocauterization in the treatment of pilonidal sinus. *Int Surg* **81**, 83–84 (1996).
211. Shinde, P. & Toshikhane, H. Pilonidal sinus (Nadi vrana): A case study. *Int J Ayurveda Res* **1**, 181–182, <https://doi.org/10.4103/0974-7788.72492> (2010).
212. Shpitz, B., Kaufman, Z., Kantarovsky, A., Reina, A. & Dinbar, A. Definitive management of acute pilonidal abscess by loop diathermy excision. *Dis Colon Rectum* **33**, 441–442 (1990).
213. Soll, C., Hahnloser, D., Dindo, D., Clavien, P. A. & Hetzer, F. A novel approach for treatment of sacrococcygeal pilonidal sinus: less is more. *Int J Colorectal Dis* **23**, 177–180, <https://doi.org/10.1007/s00384-007-0377-9> (2008).
214. Soll, C. *et al.* Sinusectomy for primary pilonidal sinus: less is more. *Surgery* **150**, 996–1001, <https://doi.org/10.1016/j.surg.2011.06.019> (2011).
215. Solla, J. A. & Rothenberger, D. A. Chronic pilonidal disease. An assessment of 150 cases. *Dis Colon Rectum* **33**, 758–761 (1990).
216. Sondena, K., Nesvik, I., Andersen, E., Pollard, M. L. & Soreide, J. A. Recurrent pilonidal sinus: Etiology and treatment. *Dig. Surg.* **12**, 117–120, <https://doi.org/10.1159/000172329> (1995).
217. Speter, C., Zmora, O., Nadler, R., Shinhar, D. & Bilik, R. Minimal incision as a promising technique for resection of pilonidal sinus in children. *J Pediatr Surg.* <https://doi.org/10.1016/j.jpedsurg.2017.03.040> (2017).
218. Spivak, H., Brooks, V. L., Nussbaum, M. & Friedman, I. Treatment of chronic pilonidal disease. *Dis Colon Rectum* **39**, 1136–1139 (1996).
219. Stansby, G. & Greatorex, R. Phenol treatment of pilonidal sinuses of the natal cleft. *Br J Surg* **76**, 729–730 (1989).
220. Stelzmueller, I. *et al.* Group Milleri Streptococci in perianal infections. *Colorectal disease: the official journal of the Association of Coloproctology of Great Britain and Ireland* **12**, e121–127 (2010).
221. Sturniolo, G., Carditello, A., Bonavita, G., Bartolotta, M. & Saitta, E. Evaluation of the results of different types of surgical intervention for pilonidal fistula. *Minerva Chir* **39**, 1161–1164 (1984).
222. Swenson, S. A. H. H. N. & Groesbeck, H. P. Pilonidal Sinus - Clinical Experiences with the Rogers Operation in thirty-five consecutive cases. *Am J Surg* **66**, 49–57 (1944).
223. Tetrick, J. E. Limited excision of pilonidal cyst and sinus. *Ohio State Med J* **67**, 135–138 (1971).
224. Thomas, D. Pilonidal sinus: a review of the literature and a report of 100 cases. *Med J Aust* **2**, 184–188 (1968).
225. Thomason, T. H. Cysts and sinuses of sacrococcygeal region. *Ann Surg* **32**, 80 (1934).
226. Val-Bernal, J. F., González-Vela, M. C., Hermana, S., Garijo, M. F. & González-López, M. A. Pilonidal sinus associated with cellular blue nevus. A previously unrecognized association. *J. Cutaneous Pathol.* **34**, 942–945, <https://doi.org/10.1111/j.1600-0560.2007.00753.x> (2007).
227. Vaughn, C. J. & Lalikos, J. F. The use of acellular dermal regeneration template for recalcitrant pilonidal disease. *J Wound Care* **20**, 275–277, <https://doi.org/10.12968/jowc.2011.20.6.275> (2011).
228. Walfisch, S., Mnitentag, H., Baruchin, A. M. & Sagi, A. Nd: YAG and CO 2 Lasers for the Treatment of Pilonidal Sinuses: Advantages over Traditional Techniques. *Medical Laser Application* **19**, 155–159 (2004).
229. Wang, C., Yao, Y. & Cao, Y. The integrative method “suture dragging and simplified vacuum assisted therapy” for complex pilonidal sinus disease. *Case Rep Surg* **2014**, 425497, <https://doi.org/10.1155/2014/425497> (2014).
230. Weckner, W. & Zorner, M. Treatment of pilonidal sinus. *Z Aerztl Fortbildg (Jena)* **75**, 903–906 (1981).
231. Williams, A. C. Skin grafting in the treatment of extensive pilonidal disease and anal fistula. *Am Surg* **17**, 1137–1144 (1951).
232. Yamashita, Y., Nagae, H. & Hashimoto, I. Ambulatory Surgery for Pilonidal Sinus: Tract Excision and Open Treatment Followed by At-Home Irrigation. *J Med Invest* **63**, 216–218, <https://doi.org/10.2152/jmi.63.216> (2016).
233. Zagory, J. A., Golden, J., Holoyda, K., Demeter, N. & Nguyen, N. X. Excision and Primary Closure May Be the Better Option in the Surgical Management of Pilonidal Disease in the Pediatric Population. *Am Surg* **82**, 964–967 (2016).
234. Zieger, K. Complications after surgery for pilonidal cyst. An introduction to a new debate on a “costly” disease. *Ugeskr Laeger* **161**, 6056–6058 (1999).
235. Abbasi, H. R. H., Hosseini, S. V., Yarmohammadi, H. & Bolandparvaz, S. Comparison between two methods of excision and primary closure of pilonidal sinus. *Electrocautery increases recurrence* **9**, 143–146 (2007).
236. Abu Galala, K. H. *et al.* Treatment of pilonidal sinus by primary closure with a transposed rhomboid flap compared with deep suturing: a prospective randomised clinical trial. *Eur J Surg* **165**, 468–472 (1999).
237. Akinci, O. F., Coskun, A., Ozgonul, A. & Terzi, A. Surgical treatment of complicated pilonidal disease: limited separate elliptical excision with primary closure. *Colorectal Dis* **8**, 704–709, <https://doi.org/10.1111/j.1463-1318.2006.01022.x> (2006).
238. Albahadili, M. A. & Awazli, L. G. Pilonidal Sinus Excision Using Carbon Dioxide Laser 10600 nm. *Iraqi J Laser* **14**, 33–40 (2015).
239. Aldean, I., Shankar, P. J., Mathew, J., Safarani, N. & Haboubi, N. Y. Simple excision and primary closure of pilonidal sinus: a simple modification of conventional technique with excellent results. *Colorectal Dis* **7**, 81–85, <https://doi.org/10.1111/j.1463-1318.2004.00736.x> (2005).
240. Al-Jaberi, T. M. Excision and simple primary closure of chronic pilonidal sinus. *Eur J Surg* **167**, 133–135 (2001).
241. Almajid, F. M., Alabdralnabi, A. A. & Almulhim, K. A. The risk of recurrence of Pilonidal disease after surgical management. *Saudi Med J* **38**, 70–74, <https://doi.org/10.15537/smj.2017.1.15892> (2017).
242. Alptekin, H. *et al.* Specimen index may be a predictive factor for recurrence after primary closure of pilonidal disease. *J Korean Surg Soc* **83**, 367–373, <https://doi.org/10.4174/jkss.2012.83.6.367> (2012).
243. Angermann, P. & Beiter, E. C. Pilonidal cyst. A sequence treated with excision and primary suture. *Ugeskr Laeger* **146**, 24–26 (1984).
244. Arda, I. S., Guney, L. H., Sevmis, S. & Hicsonmez, A. High body mass index as a possible risk factor for pilonidal sinus disease in adolescents. *World J Surg* **29**, 469–471, <https://doi.org/10.1007/s00268-004-7533-y> (2005).
245. Aydede, H., Erhan, Y., Sakarya, A. & Kumkumoglu, Y. Comparison of three methods in surgical treatment of pilonidal disease. *ANZ J Surg* **71**, 362–364 (2001).
246. Badawy, E. A. & Kanawati, M. N. Effect of hair removal by Nd:YAG laser on the recurrence of pilonidal sinus. *J Eur Acad Dermatol Venereol* **23**, 883–886, <https://doi.org/10.1111/j.1468-3083.2009.03147.x> (2009).
247. Bear, N. E. & Woldman, V. F. Treatment of pilonidal cysts. *Wis Med J* **44**, 1166–1169 (1945).
248. Beardsley, J. M. Treatment of pilonidal cyst and sinus. *AMA Arch Surg* **68**, 608–611 (1954).
249. Bellis, C. J. Pilonidal cyst; treatment by a uniformly successful method. *dressung verband!! rö xrt* **13**, 334–337 (1950).
250. Benfatto, G. *et al.* Drainage useful in the excision and closure “per primam” of pilonidal sinus: technical notes. *Chir Ital* **55**, 621–624 (2003).

251. Bentivegna, S. S. & Procaro, P. Primary closure of pilonidal cystectomy. *Am Surg* **43**, 214–216 (1977).
252. Bhushan, T. V. Surgical treatment of chronic sacrococcygeal pilonidal sinus. *Open method versus primary closure. Saudi Med J* **28**, 815 (2007).
253. Biffoni, M. *et al.* Pilonidal sinus. Outpatient treatment with local anesthesia. *G Chir* **30**, 173–176 (2009).
254. Bissett, L. P. & Isbister, W. H. The management of patients with pilonidal disease—a comparative study. *Aust N Z J Surg* **57**, 939–942 (1987).
255. Bouq, Y. A., Fazili, F. M., Fawzi, H. A. G. & Parvez, T. Surgical management of pilonidal disease: Our experience. *JK Pract.* **11**, 21–26 (2004).
256. Bowers, W. F. & Williamson, W. S. Pilonidal sinus; preliminary report on a fresh approach. *AMA Arch Surg* **73**, 931–935 (1956).
257. Braungart, S., Powis, M., Sutcliffe, J. R. & Sugarman, I. D. Improving outcomes in pilonidal sinus disease. *J Pediatr Surg* **51**, 282–284, <https://doi.org/10.1016/j.jpedsurg.2015.10.076> (2016).
258. Brearley, R. Treatment of pilonidal sinus. *Br Med J* **2**, 1256 (1959).
259. Britton, D. C., Marks, C. G., Ritchie, J. K. & Thompson, H. R. The treatment of pilonidal sinus at St Mark's Hospital. *Proc R Soc Med* **70**, 478–480 (1977).
260. Bunke, H. J., Schultheis, A., Meyer, G. & Dusel, W. Surgical revision of the pilonidal sinus with single shot antibiotics. *Chirurg* **66**, 220–223 (1995).
261. Çağlayan, K. *et al.* The effect of different surgical methods on complications and on the quality of life in pilonidal sinus disease. *Turk. J. Surg.* **27**, 94–97, <https://doi.org/10.5097/1300-0705.UCD.950-11.03> (2011).
262. Çağlayan, K. *et al.* Investigation of Patient Dependent Factors Effecting Complications and Recurrence in Pilonidal Sinus Disease. *Kolon Rektum Hast Derg* **21**, 103–108 (2011).
263. Can, M. F., Sevinc, M. M. & Yilmaz, M. Comparison of Karydakís flap reconstruction versus primary midline closure in sacrococcygeal pilonidal disease: results of 200 military service members. *Surg Today* **39**, 580–586, <https://doi.org/10.1007/s00595-008-3926-0> (2009).
264. Christensen, K., Kronborg, O., Zimmermann-Nielsen, C. & Olsen, H. Incision or primary suture in acute pilonidal abscesses. A prospective randomized study. *Ugeskr Laeger* **147**, 3479–3481 (1985).
265. Cianci, F. & Marinaccio, F. Treatment of pilonidal sinus by radical excision and primary closure. *Our experience. Minerva Chir* **39**, 1111–1115 (1984).
266. Ciccolo, A. *et al.* Treatment of pilonidal disease in short-stay surgery: personal method. *Ann Ital Chir* **75**, 603–605 (2004).
267. Cihan, A. *et al.* Modified Limberg flap reconstruction compares favourably with primary repair for pilonidal sinus surgery. *ANZ J Surg* **74**, 238–242, <https://doi.org/10.1111/j.1445-2197.2004.02951.x> (2004).
268. Comarr, A. E. Pilonidal cysts and/or sinuses: primary closure with the wirebution retention technic. *Am J Surg* **97**, 328–330 (1959).
269. Corsi, P. R., Corsi, R. D. C. C., Moura, L. F. R. A. D., Guerreiro, T. D. T. & Vasconcelos, L. P. D. Tratamento cirurgico do cisto pilonidal através de ressecao e fechamento primario com retalhos cutaneos. *Revista brasileira de colo-proctologia* (2004).
270. Cortese, M., Benedetti Valentini, G. & Giacomini, S. Personal experience in the treatment of pilonidal sinus. *Minerva Chir* **40**, 1137–1139 (1985).
271. Courtney, S. P. & Merlin, M. J. The use of fusidic acid gel in pilonidal abscess treatment: cure, recurrence and failure rates. *Ann R Coll Surg Engl* **68**, 170–171 (1986).
272. Cruz, J. & Ram, M. D. Sacrococcygeal pilonidal sinus. *Dis Colon Rectum* **14**, 356–359 (1971).
273. Dalenback, J., Magnusson, O., Wedel, N. & Rimback, G. Prospective follow-up after ambulatory plain midline excision of pilonidal sinus and primary suture under local anaesthesia—efficient, sufficient, and persistent. *Colorectal Dis* **6**, 488–493, <https://doi.org/10.1111/j.1463-1318.2004.00693.x> (2004).
274. de Quinta Frutosa, R. *et al.* Enfermedad pilonidal. Tratamiento por exéresis en bloque con cierre primario. *Cir Esp* **68**, 570–572 (2000).
275. Del Papa, M., Mobili, M., Attardo, S., Paolucci, G. & Braccioni, U. Radical excision and primary suture of pilonidal sinus: our experience. *Ann Ital Chir* **63**, 507–509, discussion 509–510 (1992).
276. Denkers, D. & Girona, J. Der abszedierte Sinus pilonidalis der Steißbeinregion - Möglichkeiten der chirurgischen Versorgung. *coloproctology* **18**, 257–259 (1996).
277. Diana, G., Muscarella, F., Pepe, D. & Speciale, A. Primary closure in the treatment of pilonidal sinus. Evaluation of immediate and remote results. *MINERVA CHIR.* **41**, 765–767 (1986).
278. Doll, D. *et al.* Does gentamycin affect long term recurrence rate in pilonidal sinus surgery? *European Surgery* **43**, 236–243, <https://doi.org/10.1007/s10353-011-0615-9> (2011).
279. Duchateau, J., De Mol, J., Bostoen, H. & Allegaert, W. Pilonidal sinus. Excision—marsupialization—phenolization? *Acta Chir Belg* **85**, 325–328 (1985).
280. El-Shaer, W. M. The modified gluteal sliding plication closure in the treatment of chronic pilonidal sinus. *Int J Colorectal Dis* **25**, 887–894, <https://doi.org/10.1007/s00384-010-0911-z> (2010).
281. Emir, S., Topuz, O., Kanat, B. H. & Bali, I. Sinotomy technique versus surgical excision with primary closure technique in pilonidal sinus disease. *Bosn J Basic Med Sci* **14**, 263–267, <https://doi.org/10.17305/bjbm.2014.4.139> (2014).
282. Evangelou, G. & Tiniakos, G. Treatment of pilonidal sinus disease based on pathological observations. *Int Surg* **59**, 493–496 (1974).
283. Favre, R. & Delacroix, P. Apropos of 1,110 Cases of Pilonidal Disease of Coccy-Perineal Localization. *Mem Acad Chir (Paris)* **90**, 669–676 (1964).
284. Ferguson, L. K. Pilonidal Cysts: Treatment by Excision and Primary Suture in Ambulatory Patients. *Ann Surg* **101**, 469–477 (1935).
285. Ferguson, L. K. M. P. M. Pilonidal Cysts: Excision and primary suture in ambulatory patients. *Am J Surg* **36**, 270–277 (1937).
286. Filingeri, V. & Gravante, G. Radiofrequency sinus excision. *Dig. Surg.* **23**, 125, <https://doi.org/10.1159/000094136> (2006).
287. Finestone, E. O. Technic of excision and primary closure of pilonidal sinus. *N Y State J Med* **52**, 1291–1294 (1952).
288. Frostad, H. Sacral dermoidcysts. Especially with a view to their treatment. *Acta chir scand* **93**, 23 (1946).
289. Galati, G., Sterpetti, A. V. & Tartaglia, E. Therapeutic approaches to patients with pilonidal sinus based on specific clinical characteristic. *Eur J Plast Surg* **35**, 595–598 (2012).
290. Ghnnam, W., Ghazy, H., Saed, B. & Farid, M. Limited excision and primary closure for pilonidal sinus. *Egypt J Surg* **28**, 43–47 (2009).
291. Gilani, S. N. *et al.* Excision and primary closure of pilonidal sinus disease: worthwhile option with an acceptable recurrence rate. *Ir J Med Sci.* **180**, 173–176, <https://doi.org/10.1007/s11845-010-0532-0> (2011).
292. Gipponi, M., Reboa, G., Testa, T., Giannini, G. & Strada, P. Tension-free primary closure with autologous platelet gel versus Vivostat- for the definitive treatment of chronic sacrococcygeal pilonidal disease. *In Vivo* **24**, 583–589 (2010).
293. Goldman, B. *Combined therapy for pilonidal (sacrocoxygeal) cyst and sinus; roentgen epililation of operative field prior to surgical excision with primary closure* **18**, 903–909 (1952).
294. Goswitz, J. T. Sacrococcygeal Pilonidal Sinus Disease. Treatment and Long-Term Follow-up in a Military Hospital Serving Combat-Ready Units. *Arch Surg* **90**, 890–892 (1965).
295. Grubnik, V. V. & Bakhar, G. A. The use of a laser in the surgical treatment of an epithelial coccygeal cyst. *Klin.Khir.* 23–25 (1993).
296. Hamilton, J. E. & Cattanach, L. M. Comparative study of chemotherapies in the surgery of pilonidal sinus. *Am J Surg* **74**, 449–454 (1947).
297. Hamilton, J. E., Stephens, G. & Claugus, C. E. Pilonidal Sinus: Excision and Primary Closure. *Surgery* **54**, 597–603 (1963).

298. Heifetz, C. J. Pilonidal disease; a study of fifty consecutive cases treated successfully by excision and primary closure. *Am J Surg* **96**, 405–410 (1958).
299. Holm, J. & Hulthen, L. Simple primary closure for pilonidal disease. *Acta Chir Scand* **136**, 537–540 (1970).
300. Hurwitt, E. S. Subphrenic abscess following primary closure for pilonidal sinus; report of a case. *N Engl J Med* **237**, 398, <https://doi.org/10.1056/NEJM194709112371104> (1947).
301. Inan, A., Surgit, O., Sen, M., Bozer, M. & Dener, C. One day surgery for pilonidal disease. *Bratisl Lek Listy* **112**, 572–574 (2011).
302. Jandik, J. *Sinus pilonidalis - possibilities of surgical treatment*. **93**, 496–501 (2014).
303. Jarufe, C. *et al.* Enfermedad pilonidal cronica sacrococigea. *Revista chilena de cirugia* **51**, 66–71 (1999).
304. Kam, B. H. A simple surgical method of treating pilonidal sinus. *Arch Chir Neerl* **28**, 43–53 (1976).
305. Karaman, K. *et al.* S-shaped wide excision with primary closure for extensive chronic pilonidal sinus disease. *Case Rep Surg* **2014**, 451869, <https://doi.org/10.1155/2014/451869> (2014).
306. Karimi, E. Surgical treatment of pilonidal sinus. *Ann Chir* **34**, 507–510 (1980).
307. Kathel, P., Gupta, A., Gupta, A. & Shiju, K. S. A Case Report of Pilonidal Sinus Managed By Primary Closure and Review of Literature. *Sch J Med Case Rep* **2**, 532–535 (2014).
308. Kaya, B., Uctum, Y., Simsek, A. & Kutanis, R. Primary closure in the treatment of pilonidal disease. An easy and effective method. *Kolon Rektum Hast Derg* **20**, 59–65 (2010).
309. Khaira, H. S. & Brown, J. H. Excision and primary suture of pilonidal sinus. *Ann R Coll Surg Engl* **77**, 242–244 (1995).
310. Khanzada, T. W. & Samad, A. Recurrence after excision and primary closure of pilonidal sinus. *Pak. J. Med. Sci.* **23**, 375–379 (2007).
311. Klug, W., Knoch, H. G. & Holland-Moritz, A. Sinus pilonidalis. *Zeitschrift für ärztliche Fortbildung* **78**, 711–714 (1984).
312. Kopp, J. A. Primary Closure of Pilonidal Sinus, Using a Muscle Fascia Graft. *Arch Chir Neerl* **16**, 151–160 (1964).
313. Küçükkartallar, T. T., Küçükkartallar, A. & Vatansev, C. *et al.* The comparison of the results of different operation techniques for pilonidal sinus disease. *Genel Tip Derg* **17**, 95–97 (2007).
314. Laforet, E. G. Pilonidal sinus; a method of treatment by primary closure. *Am J Surg* **93**, 873–875 (1957).
315. Larkin, L. C. Pilonidal cyst; analysis of 100 consecutive cases, emphasizing treatment by radical excision, primary closure and penicillin therapy. *Surg Gynecol Obstet* **82**, 694–704 (1946).
316. Larsen, B. B. Pilonidal cysts and sinuses; a technic for excision and primary closure. *Ann Surg* **123**, 1090–1100 (1946).
317. Lee, S. L., Tejirian, T. & Abbas, M. A. Current management of adolescent pilonidal disease. *J Pediatr Surg* **43**, 1124–1127, <https://doi.org/10.1016/j.jpedsurg.2008.02.042> (2008).
318. Lee, H. C., Ho, Y. H., Seow, C. F., Eu, K. W. & Nyam, D. Pilonidal disease in Singapore: clinical features and management. *Aust N Z J Surg* **70**, 196–198 (2000).
319. Liboni, N. S. & Fregnani, C. H. T. G. Preliminary results from 28 cases of pilonidal cyst treated by excision and primary closure of the wound, reinforced with support suturing. *Einstein* **5**, 148–152 (2007).
320. Limongelli, P. *et al.* D-shape asymmetric and symmetric excision with primary closure in the treatment of sacrococcygeal pilonidal disease. *Am J Surg* **207**, 882–889, <https://doi.org/10.1016/j.amjsurg.2013.06.013> (2014).
321. Mahdy, T. Surgical treatment of the pilonidal disease: primary closure or flap reconstruction after excision. *Dis Colon Rectum* **51**, 1816–1822, <https://doi.org/10.1007/s10350-008-9436-8> (2008).
322. Maniscalco, L., Speranza, G. & Maniscalco, A. The pilonidal sinus: Which management? *Chirurgia* **14**, 81–83 (2001).
323. Mecchia, P., Tonizzo, C. A. & Flamia, M. Pilonidal cysts and fistulas: radical excision “en bloc” and closure “per primam”. *Minerva Chir* **50**, 553–556 (1995).
324. Mentes, O. *et al.* Management of pilonidal sinus disease with oblique excision and primary closure: results of 493 patients. *Dis Colon Rectum* **49**, 104–108, <https://doi.org/10.1007/s10350-005-0226-2> (2006).
325. Michotey, G., Brandone, H. & Helaine, R. Apropos of a Series of 20 Cases of So-Called Pilonidal Sacrococcygeal Cysts. *Mars Chir* **15**, 383–389 (1963).
326. Miller, J. M., Ginsberg, M., Lipin, R. J. & Long, P. H. Streptokinase and streptodornase in the treatment of pilonidal cysts. *US Armed Forces Med J* **2**, 1423–1429 (1951).
327. Milone, M. *et al.* Pilonidal sinus surgery: could we predict postoperative complications? part 2, <https://doi.org/10.1111/ijw.12310> (2014).
328. Miocinovic, M., Horzic, M. & Bunoza, D. The treatment of pilonidal disease of the sacrococcygeal region by the method of limited excision and open wound healing. *Acta Med Croatica* **54**, 27–31 (2000).
329. Muller, X. M., Rothenbuhler, J. M. & Frede, K. E. Sacro-coccygeal cyst: surgical techniques and results. *Helv. Chir Acta* **58**, 889–892 (1992).
330. Muzi, M. G., Milito, G., Nigro, C., Cadeddu, F. & Farinon, A. M. A modification of primary closure for the treatment of pilonidal disease in day-care setting. *Colorectal Dis* **11**, 84–88, <https://doi.org/10.1111/j.1463-1318.2008.01534.x> (2009).
331. Muzi, M. G. *et al.* Long-term results of pilonidal sinus disease with modified primary closure: new technique on 450 patients. *Am Surg* **80**, 484–488 (2014).
332. Novotny, G. M. E. and Primary Closure of Pilonidal Sinus. A Critical Review of Forty-Five Cases. *Med Serv J Can* **20**, 352–354 (1964).
333. Obeid, S. A. A new technique for treatment of pilonidal sinus. *Dis Colon Rectum* **31**, 879–885 (1988).
334. Onder, A. *et al.* Pilonidal sinus disease: risk factors for postoperative complications and recurrence. *Int Surg* **97**, 224–229, <https://doi.org/10.9738/CC86.1> (2012).
335. Örhalmi, J., Sotona, O., Dusek, T. & Ferko, A. *Pilonidal sinus - possibilities surgical treatment*. **93**, 491–495 (2014).
336. Osmanoglu, G. & Yetisir, F. Limberg flap is better for the surgical treatment of pilonidal sinus. Results of a 767 patients series with an at least five years follow-up period. *Chirurgia (Bucur)* **106**, 491–494 (2011).
337. Palmieri, B., Gozzi, G. & Rossi, A. Pilonidal cysts: the state of the art and the authors’ personal experiences. *Minerva Chir* **49**, 377–382 (1994).
338. Pezzangora, V., Averno, V. & Barina, R. Treatment of fistulized pilonidal sinuses by phenol injection. *Chir Ital* **32**, 848–854 (1980).
339. Powell, B. C., Webb, C. B., Ewing, J. A. & Smith, D. E. Gluteal Fascial Advancement for Pilonidal Cyst Disease: A 10-year Review. *Am Surg* **82**, 622–625 (2016).
340. Pozzi, C. & Tritapepe, R. Healing of the operative wound after radical removal of the Sinus pilonidalis. *MINERVA CHIR.* **44**, 2329–2332 (1989).
341. Qadir, H., Nazir, A., Aslam, M. & Rasool, I. Primary repair without drain after limited excision of pilonidal sinus. *Pak. J. Med. Health Sci.* **3**, 242 (2009).
342. Rainsbury, R. M. & Southam, J. A. Radical surgery for pilonidal sinus. *Ann R Coll Surg Engl* **64**, 339–341 (1982).
343. Rossi, P. *et al.* The pilonidal sinus: its surgical treatment, our experience and a review of the literature. *G Chir* **14**, 120–123 (1993).
344. Ross, R. L. Recurrent pilonidal cyst and sinus; a plan of preoperative preparation, operation and postoperative care. *Calif Med* **85**, 183–186 (1956).
345. Russell, J. L. A method of excision and primary closure of pilonidal cysts and sinuses. *Can Med Assoc J* **60**, 267–270 (1949).
346. Sakr, M. F. E., Sakr, M. E. & Hamed, H. M. *et al.* Management of 634 Consecutive Patients with Chronic Pilonidal Sinus: A Nine-Year Experience of a Single Institute. *mehr RR im Text* **3**, 145–154 (2012).
347. Sarles, J. C., Sastre, B. & Delecourt, P. Treatment of pilonidal cyst with radical excision and primary closure. *Gastroenterol Clin Biol* **1**, 929–932 (1977).

348. Saylam, B., Balli, D. N., Duzgun, A. P., Ozer, M. V. & Coskun, F. Which surgical procedure offers the best treatment for pilonidal disease? *Langenbecks Arch Surg* **396**, 651–658, <https://doi.org/10.1007/s00423-011-0768-9> (2011).
349. Schonk, J. W. Some aspects of the treatment of the pilonidal sinus. *Arch Chir Neerl* **23**, 297–302 (1971).
350. Serour, F., Somekh, E., Krutman, B. & Gorenstein, A. Excision with primary closure and suction drainage for pilonidal sinus in adolescent patients. *Pediatr Surg Int* **18**, 159–161, <https://doi.org/10.1007/s003830100683> (2002).
351. Shons, A. R. & Mountjoy, J. R. Pilonidal disease: the case for excision with primary closure. *Dis Colon Rectum* **14**, 353–355 (1971).
352. Sias, F., Licheri, S., Secci, L., Loi, R. & Daniele, G. M. Ambulatory treatment of pilonidal sinus. *Chirurgia* **7**, 639–642 (1994).
353. Siddiqui, S. S. & Khan, M. A. Pilonidal sinus: Following the Aristotelian middle! *Pak. J. Med. Sci.* **24**, 845–848 (2008).
354. Smith, C. M., Jones, A., Dass, D., Murthi, G. & Lindley, R. Early experience of the use of fibrin sealant in the management of children with pilonidal sinus disease. *J Pediatr Surg* **50**, 320–322, <https://doi.org/10.1016/j.jpedsurg.2014.11.022> (2015).
355. Stewart, T. J. & Bell, M. The treatment of pilonidal sinus by phenol injection. *Ulster Med J* **38**, 167–171 (1969).
356. Sutalo, N. *et al.* The influence of drainage in the treatment of chronic pilonidal sinus disease using midline closure. *Psychiatr Danub* **27**, 593–595 (2015).
357. Talu, M. Y., Talu, O. & User, Y. *et al.* Oblique excision with primary closure for the treatment of pilonidal sinus. *Eur J Plast Surg* **19**, 200–203 (1996).
358. Tejirian, T., Lee, J. J. & Abbas, M. A. Is wide local excision for pilonidal disease still justified? *Am Surg* **73**, 1075–1078 (2007).
359. Toccaceli, S., Persico Stella, L., Diana, M., Dandolo, R. & Negro, P. Treatment of pilonidal sinus with primary closure. A twenty-year experience. *Chir Ital* **60**, 433–438 (2008).
360. Tocchi, A. *et al.* Ambulatory closed surgery for the treatment of pilonidal sinus. *G Chir* **22**, 303–307 (2001).
361. Toydemir, T., Peşluk, O., Ermeç, E. D. & Turhan, A. N. Comparison of the clinical outcomes of karydakias flap versus primary closure procedures in the surgical treatment of sacrococcygeal pilonidal sinus disease. *Med. J. Bakirkoy* **8**, 78–81, <https://doi.org/10.5350/BTDMJB201208206> (2012).
362. Tritapepe, R. & Di Padova, C. Excision and primary closure of pilonidal sinus using a drain for antiseptic wound flushing. *Am J Surg* **183**, 209–211 (2002).
363. Turner, F. P. & O'Neil, J. W. Treatment of pilonidal sinus by primary closure; a seven-year study. *AMA Arch Surg* **78**, 398–405 (1959).
364. Verbeek, H. O. & Bender, J. Results of treatment of pilonidal sinus by block excision and primary suture. *Arch Chir Neerl* **26**, 311–318 (1974).
365. Virgillo, G., Mendicino, F. & Costanzo, A. Sinus pilonidalis. *Brief review of literature and contribution to surgical therapy* **27**, 1–40 (1975).
366. Vitale, A., Barberis, G., Maida, P. & Salzano, A. Use of biological glue in the surgical treatment of sacrococcygeal fistulas. *G. Chir* **13**, 271–272 (1992).
367. Wani, M., Shah, M., Wani, K. & Malik, A. Excision and primary closure of sacrococcygeal pilonidal sinus using suction drain. *International Surgery Journal*, 837–840, <https://doi.org/10.18203/2349-2902.isj20161158> (2016).
368. Washer, J. D., Smith, D. E., Carman, M. E. & Blackhurst, D. W. Gluteal fascial advancement: an innovative, effective method for treating pilonidal disease. *Am Surg* **76**, 154–156 (2010).
369. Watters, N. & Macdonald, I. B. Marsupialization of pilonidal sinus and abscess: a report of 50 cases. *Can Med Assoc J* **79**, 236–240 (1958).
370. Weeder, S. D. Pilonidal Cyst, its etiology and treatment. *Ann Surg* **98**, 385–393 (1933).
371. Williams, R. S. A simple technique for successful primary closure after excision of pilonidal sinus disease. *Ann R Coll Surg Engl* **72**, 313–314, discussion 314–315 (1990).
372. Yildiz, T., Ilce, Z. & Kucuk, A. Modified Limberg flap technique in the treatment of pilonidal sinus disease in teenagers. *J Pediatr Surg* **49**, 1610–1613, <https://doi.org/10.1016/j.jpedsurg.2014.06.011> (2014).
373. Ziegler, H. R., Murphey, D. R. Jr. & MEEK, E. M. Pilonidal cyst and sinus; a new method of excision with primary closure. *Surgery* **20**, 690–703 (1946).
374. Karip, A. B. *et al.* Effect of Triclosan-Coated Suture and Antibiotic Prophylaxis on Infection and Recurrence after Karydakias Flap Repair for Pilonidal Disease: A Randomized Parallel-Arm Double-Blinded Clinical Trial. *Surg Infect (Larchmt)* **17**, 583–588, <https://doi.org/10.1089/sur.2015.207> (2016).
375. Brezin, D. L., Brezin, C. & Lawrence, J. Pilonidal cyst. *Am J Surg* **60**, 264–266 (1943).
376. Bulus, H. & Coskun, A. Is Asymmetric excision primary closure at treatment of pylonidal sinus disease an appropriate choice? *J. Clin. Anal. Med.* **2**, 79–81, <https://doi.org/10.4328/jcam.279> (2011).
377. Casten, D. F., Tan, B. Y. & Ayuyao, A. A technique of radical excision of pilonidal disease with primary closure. *Surgery* **73**, 109–114 (1973).
378. Ciftci, F., Abdurrahman, I., Tosun, M. & Bas, G. A new approach: oblique excision and primary closure in the management of acute pilonidal disease. *Int J Clin Exp Med* **7**, 5706–5710 (2014).
379. De Nardi, P., Gazzetta, P. G., Fiorentini, G. & Guarneri, G. The cleft lift procedure for complex pilonidal disease. *European Surgery* **48**, 250–257, <https://doi.org/10.1007/s10353-016-0428-y> (2016).
380. Docimo, L. *et al.* Primary closure of decentered wounds in surgical treatment of pilonidal sinus. *Chirurgia* **11**, 239–244 (1998).
381. Eichfuss, H. P., Eichen, R., Koch, G. & Eckert, P. Primary closure of the sinus pilonidalis. *Chirurg* **49**, 124–126 (1978).
382. Greenberg, R., Kashtan, H., Skornik, Y. & Werbin, N. Treatment of pilonidal sinus disease using fibrin glue as a sealant. *Tech Coloproctol* **8**, 95–98, <https://doi.org/10.1007/s10151-004-0063-7> (2004).
383. Ibrahim, A. M. R. R. Oblique excision and primary closure of pilonidal sinus (sacrococcygeal). *Trends Med. Res.* **7**, 62–69, <https://doi.org/10.3923/tmr.2012.62.69> (2012).
384. Kim, J. K., Jeong, J. C., Lee, J. B., Jung, K. H. & Bae, B. K. S-plasty for pilonidal disease: modified primary closure reducing tension. *J Korean Surg Soc* **82**, 63–69, <https://doi.org/10.4174/jkss.2012.82.2.63> (2012).
385. Kitchen, P. R. Pilonidal sinus: experience with the Karydakias flap. *Br J Surg* **83**, 1452–1455 (1996).
386. Maghsoudi, H., Nezami, N. & Ghamari, A. A. Ambulatory treatment of chronic pilonidal sinuses with lateral incision and primary suture. *Can J Surg* **54**, 78–82, <https://doi.org/10.1503/cjs.026309> (2011).
387. Marzouk, D. M., Abou-Zeid, A. A., Antoniou, A., Haji, A. & Benziger, H. Sinus excision, release of coccytaneous attachments and dermal-subcuticular closure (XRD procedure): a novel technique in flattening the natal cleft in pilonidal sinus treatment. *Ann R Coll Surg Engl* **90**, 371–376, <https://doi.org/10.1308/003588408X285955> (2008).
388. Saber, A. Modified off-midline closure of pilonidal sinus disease. *N Am J Med Sci* **6**, 210–214, <https://doi.org/10.4103/1947-2714.132936> (2014).
389. Senapati, A., Cripps, N. P., Flashman, K. & Thompson, M. R. Cleft closure for the treatment of pilonidal sinus disease. *Colorectal Dis* **13**, 333–336, <https://doi.org/10.1111/j.1463-1318.2009.02148.x> (2011).
390. Zimmerman, C. E. Outpatient excision and primary closure of pilonidal cysts and sinuses. *Am J Surg* **136**, 640–642 (1978).
391. Yildiz, M. K. *et al.* Karydakias flap procedure in patients with sacrococcygeal pilonidal sinus disease: experience of a single centre in Istanbul. *ScientificWorldJournal* **2013**, 807027, <https://doi.org/10.1155/2013/807027> (2013).
392. Arslan, K. *et al.* Which flap method should be preferred for the treatment of pilonidal sinus? A prospective randomized study. *Tech Coloproctol* **18**, 29–37, <https://doi.org/10.1007/s10151-013-0982-2> (2014).

393. Ates, M., Dirican, A., Sarac, M., Aslan, A. & Colak, C. Short and long-term results of the Karydakís flap versus the Limberg flap for treating pilonidal sinus disease: a prospective randomized study. *Am J Surg* **202**, 568–573, <https://doi.org/10.1016/j.amjsurg.2010.10.021> (2011).
394. Akinci, O. F., Coskun, A. & Uzunkoy, A. Simple and effective surgical treatment of pilonidal sinus: asymmetric excision and primary closure using suction drain and subcuticular skin closure. *Dis Colon Rectum* **43**, 701–706, discussion 706–707 (2000).
395. Al-Khayat, H. *et al.* Risk factors for wound complication in pilonidal sinus procedures. *J Am Coll Surg* **205**, 439–444, <https://doi.org/10.1016/j.jamcollsurg.2007.04.034> (2007).
396. Anderson, J. H., Yip, C. O., Nagabhushan, J. S. & Connelly, S. J. Day-case Karydakís flap for pilonidal sinus. *Dis Colon Rectum* **51**, 134–138, <https://doi.org/10.1007/s10350-007-9150-y> (2008).
397. Anyanwu, A. C., Hossain, S., Williams, A. & Montgomery, A. C. Karydakís operation for sacrococcygeal pilonidal sinus disease: experience in a district general hospital. *Ann R Coll Surg Engl* **80**, 197–199 (1998).
398. Bannura, C. *et al.* Ambulatory karydakís procedure for sacrococcygeal pilonidal disease. *Revista Chilena de Cirugia* **61**, 256–260 (2009).
399. Guillermo Bannura, C. Sacrococcygeal pilonidal disease. risks factors and surgical options. *Revista Chilena de Cirugia* **63**, 527–533 (2011).
400. Bascom, J. & Bascom, T. Failed pilonidal surgery: new paradigm and new operation leading to cures. *Arch Surg* **137**, 1146–1150; discussion 1151 (2002).
401. Bascom, J. & Bascom, T. Utility of the cleft lift procedure in refractory pilonidal disease. *Am J Surg* **193**, 606–609; discussion 609, <https://doi.org/10.1016/j.amjsurg.2007.01.008> (2007).
402. Bascom, J. U. Repeat pilonidal operations. *Am J Surg* **154**, 118–122 (1987).
403. Bertelsen, C. A. Cleft-lift operation for pilonidal sinuses under tumescent local anesthesia: a prospective cohort study of peri- and postoperative pain. *Dis Colon Rectum* **54**, 895–900, <https://doi.org/10.1007/DCR.0b013e31820ee852> (2011).
404. Bertelsen, C. A. & Jorgensen, L. N. Bascom's operation for pilonidal fistula. *Ugeskr Laeger* **170**, 2313–2317 (2008).
405. Bessa, S. S. Results of the lateral advancing flap operation (modified Karydakís procedure) for the management of pilonidal sinus disease. *Dis Colon Rectum* **50**, 1935–1940, <https://doi.org/10.1007/s10350-007-9049-7> (2007).
406. Bannura, G. Karydakís operation for sacrococcygeal pilonidal sinus disease. *Rev Chil Cir* **57**, 340–344 (2005).
407. Bostanoglu, S., Sakcak, I., Avsar, F. M., Cosgun, E. & Hamamci, E. O. Comparison of Karydakís technique with Limberg Flap Procedure in Pilonidal Sinus Disease: Advantages of Karydakís technique. *Pak. J. Med. Sci.* **26**, 773–777 (2010).
408. Buczacki, S., Drage, M., Wells, A. & Guy, R. Sacrococcygeal pilonidal sinus disease. *Colorectal Dis* **11**, 657, <https://doi.org/10.1111/j.1463-1318.2009.01818.x> (2009).
409. Cripps, N., Evans, J., Nordon, I. & Senapati, A. Sacrococcygeal pilonidal sinus disease. *Colorectal Dis* **11**, 105–106 (2008).
410. Guner, A., Cekic, A. B., Boz, A., Turkyilmaz, S. & Kucuktulu, U. A proposed staging system for chronic symptomatic pilonidal sinus disease and results in patients treated with stage-based approach. *BMC Surg* **16**, 18, <https://doi.org/10.1186/s12893-016-0134-5> (2016).
411. Guner, A., Ozkan, O. F., Kece, C., Kesici, S. & Kucuktulu, U. Modification of the Bascom cleft lift procedure for chronic pilonidal sinus: results in 141 patients. *Colorectal Dis* **15**, e402–406, <https://doi.org/10.1111/codi.12243> (2013).
412. Iesalnieks, I., Deimel, S., Zulke, C. & Schlitt, H. J. Smoking increases the risk of pre- and postoperative complications in patients with pilonidal disease. *patienten info* **11**, 1001–1005, <https://doi.org/10.1111/ddg.12140> (2013).
413. Immerman, S. C. Treatment of pilonidal disease using the Bascom 'Cleft-Lift' procedure. *Am Surg* **80**, E49–50 (2014).
414. Khan, M. I., Jawed, M., Bhura, S., Shaikh, U. & Arif, A. To evaluate the outcome of sacrococcygeal pilonidal sinus excision using karydakís technique. *Med. Forum Monthly* **25**, 57–59 (2014).
415. Iribarren, B. *et al.* Comparison between Limberg and Karydakís flap for wound closure after pilonidal cyst resection. *Revista Chilena de Cirugia* **67**, 399–406, <https://doi.org/10.4067/S0718-40262015000400009> (2015).
416. Kanat, B. H. *et al.* Comparison of early surgery (unroofing-curettage) and elective surgery (Karydakís flap technique) in pilonidal sinus abscess cases. *Ulus Travma Acil Cerrahi Derg* **20**, 366–370, <https://doi.org/10.5505/tjtes.2014.62547> (2014).
417. Karaca, T. *et al.* Comparison of short-term results of modified Karydakís flap and modified Limberg flap for pilonidal sinus surgery. *Int J Surg* **10**, 601–606, <https://doi.org/10.1016/j.ijsu.2012.10.001> (2012).
418. Karydakís, G. E. New approach to the problem of pilonidal sinus. *Lancet* **2**, 1414–1415 (1973).
419. Karydakís, G. E. Easy and successful treatment of pilonidal sinus after explanation of its causative process. *Aust N Z J Surg* **62**, 385–389 (1992).
420. Keshava, A., Young, C. J., Rickard, M. J. & Sinclair, G. Karydakís flap repair for sacrococcygeal pilonidal sinus disease: how important is technique? *ANZ J Surg* **77**, 181–183, <https://doi.org/10.1111/j.1445-2197.2006.04003.x> (2007).
421. Keshvari, A., Fazeli, M. S., Kazemini, A., Meisami, A. & Nouri-Taromloo, M. K. Prospective evaluation of outcome of karydakís flap for sacrococcygeal pilonidal disease. *Tehran Uni. Med. J.* **72**, 823–830 (2015).
422. Keshvari, A., Keramati, M. R., Fazeli, M. S., Kazemini, A. & Nouritaromloo, M. K. Risk factors for complications and recurrence after the Karydakís flap. *J Surg Res* **204**, 55–60, <https://doi.org/10.1016/j.jss.2016.04.035> (2016).
423. Kitchen, P. R. B. Pilonidal sinus: Excision and primary closure with a lateralised wound - the Karydakís operation. *AUST. NEW ZEALAND J. SURG.* **52**, 302–305 (1982).
424. Kulacoglu, H., Dener, C., Tumer, H. & Aktimur, R. Total subcutaneous fistulectomy combined with Karydakís flap for sacrococcygeal pilonidal disease with secondary perianal opening. *Colorectal Dis* **8**, 120–123, <https://doi.org/10.1111/j.1463-1318.2005.00872.x> (2006).
425. Kumar, N. A. & Sutradhar, P. Karydakís procedure for sacrococcygeal pilonidal sinus disease: Our experience. *daten nachtragen* **47**, 402–406, <https://doi.org/10.4103/0970-0358.146615> (2014).
426. Larsson, J. C., Aliaga, F. D., Granero, L. & Cornet, M. Tratamiento de la Enfermedad Pilonidal Crónica. Comparación de 3 Técnicas Quirúrgicas. *Rev Argent Coloproct* **25**, 64–70 (2014).
427. Martinez Sanz, N., Pena Ros, E., Sanchez Cifuentes, A., Benavides Buleje, J. A. & Albarracin Marin-Blazquez, A. Modified Karydakís procedure for giant pilonidal sinus. *Cir Esp* **94**, 609–611, <https://doi.org/10.1016/j.ciresp.2016.05.001> (2016).
428. Melkonian, T. *et al.* Short-and long-term results with Karydakís technique for sacrococcygeal pilonidal disease. *Revista Chilena de Cirugia* **65**, 25–29 (2013).
429. Mohamed, S. J., Kristensen, B. B., Lindgaard, L. & Bisgaard, T. Acceptable effect of multimodal analgesic treatment after a Bascom cleft lift operation. *Dan Med J* **62**, A4985 (2015).
430. Moran, D. C., Kavanagh, D. O., Adhmed, I. & Regan, M. C. Excision and primary closure using the Karydakís flap for the treatment of pilonidal disease: outcomes from a single institution. *World J Surg* **35**, 1803–1808, <https://doi.org/10.1007/s00268-011-1138-z> (2011).
431. Ortega, P. M. *et al.* Is the cleft lift procedure for non-acute sacrococcygeal pilonidal disease a definitive treatment? Long-term outcomes in 74 patients. *Surg Today* **44**, 2318–2323, <https://doi.org/10.1007/s00595-014-0923-3> (2014).
432. Patel, H., Lee, M., Bloom, I. & Allen-Mersh, T. G. Prolonged delay in healing after surgical treatment of pilonidal sinus is avoidable. *Colorectal Dis* **1**, 107–110, <https://doi.org/10.1046/j.1463-1318.1999.00030.x> (1999).
433. Piskin, T. *et al.* Orifice location guided excision and flap procedures for treatment of sacrococcygeal pilonidal disease. *Adv. Clin. Exp. Med.* **20**, 481–488 (2011).

434. Ramzan, D. M., Khalid Mirza, D. M. & Arif Ali, D. M. Pilonidal Sinus; Experience with Modified Karydak's Procedure Using Subcuticular Skin Closure. *The Professional Medical Journal* **23**, 1499–1504, <https://doi.org/10.17957/tpmj/16.3602> (2016).
435. Ruschfeldt, C., Bernstein, A., Norderval, S. & Revhaug, A. Introducing an asymmetric cleft lift technique as a uniform procedure for pilonidal sinus surgery. *Scand J Surg* **97**, 77–81 (2008).
436. Sakr, M., El-Hammadi, H., Moussa, M., Arafa, S. & Rasheed, M. The effect of obesity on the results of Karydak's technique for the management of chronic pilonidal sinus. *Int J Colorectal Dis* **18**, 36–39, <https://doi.org/10.1007/s00384-002-0407-6> (2003).
437. Senapati, A., Cripps, N. P., Flashman, K. & Thompson, M. R. Cleft Closure for the Treatment of Pilonidal Sinus Disease. *Colorectal Dis.* (2009).
438. Sit, M., Aktas, G. & Yilmaz, E. E. Comparison of the three surgical flap techniques in pilonidal sinus surgery. *Am Surg* **79**, 1263–1268 (2013).
439. Sözen, S. *et al.* Comparison between Karydak's flap repair and Limberg flap for surgical treatment of sacrococcygeal pilonidal sinus (short term results). *Turk. J. Surg.* **26**, 153–156, <https://doi.org/10.5097/1300-0705.UCD.609-10.01> (2010).
440. Tezel, E., Bostanci, H., Anadol, A. Z. & Kurukahvecioglu, O. Cleft lift procedure for sacrococcygeal pilonidal disease. *Dis Colon Rectum* **52**, 135–139, <https://doi.org/10.1007/DCR.0b013e31819734f8> (2009).
441. Theodoropoulos, G. E., Vlahos, K., Lazaris, A. C., Tahteris, E. & Panoussopoulos, D. Modified Bascom's asymmetric midgluteal cleft closure technique for recurrent pilonidal disease: early experience in a military hospital. *Dis Colon Rectum* **46**, 1286–1291, <https://doi.org/10.1097/01.DCR.0000084409.63183.5B> (2003).
442. Altinli, E., Koksall, N., Onur, E., Celik, A. & Sumer, A. Impact of fibrin sealant on Limberg flap technique: results of a randomized controlled trial. *Tech Coloproctol* **11**, 22–25, <https://doi.org/10.1007/s10151-007-0320-7> (2007).
443. Cihan, A. *et al.* Superiority of asymmetric modified Limberg flap for surgical treatment of pilonidal disease. *Dis Colon Rectum* **49**, 244–249, <https://doi.org/10.1007/s10350-005-0253-z> (2006).
444. Aithal, S. K., Rajan, C. S. & Reddy, N. Limberg flap for sacrococcygeal pilonidal sinus a safe and sound procedure. *Indian J Surg* **75**, 298–301, <https://doi.org/10.1007/s12262-012-0489-5> (2013).
445. Akan, K. *et al.* Comparison of surgical Limberg flap technique and crystallized phenol application in the treatment of pilonidal sinus disease: a retrospective study. *Ulus Cerrahi Derg* **29**, 162–166, <https://doi.org/10.5152/UCD.2013.2457> (2013).
446. Akin, M. *et al.* Rhomboid excision and Limberg flap for managing pilonidal sinus: long-term results in 411 patients. *Colorectal Dis* **10**, 945–948, <https://doi.org/10.1111/j.1463-1318.2008.01563.x> (2008).
447. Akin, M. *et al.* Comparison of the classic Limberg flap and modified Limberg flap in the treatment of pilonidal sinus disease: a retrospective analysis of 416 patients. *Surg Today* **40**, 757–762, <https://doi.org/10.1007/s00595-008-4098-7> (2010).
448. Al-Haifi, M. B. *et al.* Rhomboid flap - A primary cure for pilonidal sinus. *Kuwait Med. J.* **42**, 282–285 (2010).
449. Altintoprak, F. *et al.* Comparison of the Limberg flap with the V-Y flap technique in the treatment of pilonidal disease. *J Korean Surg Soc* **85**, 63–67, <https://doi.org/10.4174/jkss.2013.85.2.63> (2013).
450. Altintoprak, F. *et al.* Retrospective review of pilonidal sinus patients with early discharge after Limberg flap procedure. *Int Surg* **99**, 28–34, <https://doi.org/10.9738/INTSURG-D-13-00150.1> (2014).
451. Ardelet, M. *et al.* Sequential intervention with primary excision and Limberg plastic surgery procedure for treatment of sacrococcygeal pilonidal sinus: Results of a pilot study. *Chirurg* **86**, 771–775, <https://doi.org/10.1007/s00104-014-2963-z> (2015).
452. Azab, A. S., Kamal, M. S., Saad, R. A., Abou al Atta, K. A. & Ali, N. A. Radical cure of pilonidal sinus by a transposition rhomboid flap. *Br J Surg* **71**, 154–155 (1984).
453. Azab, A. S., Kamal, M. S. & el Bassyoni, F. The rationale of using the rhomboid fasciocutaneous transposition flap for the radical cure of pilonidal sinus. *J Dermatol Surg Oncol* **12**, 1295–1299 (1986).
454. Arumugam, P. J., Chandrasekaran, T. V., Morgan, A. R., Beynon, J. & Carr, N. D. The rhomboid flap for pilonidal disease. *Colorectal Dis* **5**, 218–221 (2003).
455. Aslam, M. N., Shoaib, S. & Choudhry, A. M. Use of Limberg flap for pilonidal sinus—a viable option. *J Ayub Med Coll Abbottabad* **21**, 31–33 (2009).
456. Azizi, R., Alemrajabi, M., Naderan, M. & Shoar, S. Efficacy of modified Limberg flap in surgical treatment of infected pilonidal abscess: a case-control study. *European Surgery* **46**, 144–147, <https://doi.org/10.1007/s10353-014-0273-9> (2014).
457. Bayhan, Z. *et al.* Crystallized phenol application and modified Limberg flap procedure in treatment of pilonidal sinus disease: A comparative retrospective study. *Asian J Surg* **39**, 172–177, <https://doi.org/10.1016/j.asjsur.2015.12.007> (2016).
458. Behdad, A. & Hosseinpoor, M. Z-plasty for the treatment of residual cavity after pilonidal sinus excision. *Medical Journal of the Islamic Republic of Iran* **14**, 317–319 (2001).
459. Bose, B. & Candy, J. Radical cure of pilonidal sinus by Z-plasty. *Am J Surg* **120**, 783–786 (1970).
460. Bozkurt, M. K. & Tezel, E. Management of pilonidal sinus with the Limberg flap. *Dis Colon Rectum* **41**, 775–777 (1998).
461. Casula, G., Uccheddu, A. & Figus, M. Long term results of the Z-plasty method in the treatment of pilonidal sinus. *Minerva Chir* **38**, 617–620 (1983).
462. Cervelli, V. *et al.* Plastic surgery by the Limberg-Dufourmentel method in the treatment of a pilonidal sinus. The anatomical considerations and an emblematic case. *Minerva Chir* **52**, 659–662 (1997).
463. Cubukcu, A. *et al.* The role of obesity on the recurrence of pilonidal sinus disease in patients, who were treated by excision and Limberg flap transposition. *Int J Colorectal Dis* **15**, 173–175 (2000).
464. Daphan, C., Tekelioglu, M. H. & Sayilgan, C. Limberg flap repair for pilonidal sinus disease. *Dis Colon Rectum* **47**, 233–237 (2004).
465. Darwish, A. M. & Hassanin, A. Reconstruction following excision of sacrococcygeal pilonidal sinus with a perforator-based fasciocutaneous Limberg flap. *J Plast Reconstr Aesthet Surg* **63**, 1176–1180, <https://doi.org/10.1016/j.bjps.2009.05.051> (2010).
466. Do Amaral Braga, J. Jr. & Haertel Gomes, N. Intergluteal dermoid cyst. *REV. BRAS. MED.* **30**, 543–545 (1973).
467. Dogra, S. & Rao, P. P. Z-Plasty a Rational and Effective Technique for Pilonidal Sinus. *Hellenic Journal of Surgery* **86**, 208–211 (2014).
468. El-Khadrawy, O., Hashish, M., Ismail, K. & Shalaby, H. Outcome of the rhomboid flap for recurrent pilonidal disease. *World J Surg* **33**, 1064–1068, <https://doi.org/10.1007/s00268-009-9920-x> (2009).
469. El-Tawil, S. & Carapeti, E. Use of a double rhomboid transposition flap in the treatment of extensive complex pilonidal sinus disease. *Colorectal Dis* **11**, 313–317, <https://doi.org/10.1111/j.1463-1318.2008.01596.x> (2009).
470. Eryilmaz, R., Sahin, M., Alimoglu, O. & Dasiran, F. Surgical treatment of sacrococcygeal pilonidal sinus with the Limberg transposition flap. *Surgery* **134**, 745–749, [https://doi.org/10.1016/s0039-6060\(03\)00163-6](https://doi.org/10.1016/s0039-6060(03)00163-6) (2003).
471. Fahim, M. *et al.* Limberg FLAP Reconstruction for Pilonidal Sinus Disease: An Experience. *Ann. Pak. Inst. Med. Sci.* **9**, 215–218 (2013).
472. Faux, W., Pillai, S. C. & Gold, D. M. Limberg flap for pilonidal disease: the “no-protractor” approach, 3 steps to success. *Tech Coloproctol* **9**, 153–155, <https://doi.org/10.1007/s10151-005-0216-3> (2005).
473. Ferreira Montero, V., Garcia Fabian, A. P., Martinez Laganga, A. & Perez Ruiz, L. Rhombic plastia in the form of an ‘L’ for treating pilonidal cysts. *Cir. Esp.* **31**, 153–158 (1977).
474. Friedl, P. G., Rappold, E. M. & Jager, C. Effective and minimally painful surgery of pilonidal sinus - asymmetric transposition flap according to Dufourmentel. *patienten info* **9**, 333–335, <https://doi.org/10.1111/j.1610-0387.2011.07662.x> (2011).
475. Gwynn, B. R. Use of the rhomboid flap in pilonidal sinus. *Ann R Coll Surg Engl* **68**, 40–41 (1986).
476. Hasse, F. M., Rademacher, C., Bingham, K. & Lohlein, D. The Dufourmentel flap-plasty for treatment of chronic pilonidal sinus. *Chirurg* **69**, 663–666 (1998).

477. Hegele, A., Strombach, F. J. & Schonbach, F. Reconstructive surgical therapy of infected pilonidal sinus. *Chirurg* **74**, 749–752, <https://doi.org/10.1007/s00104-003-0657-z> (2003).
478. Jäschke, C. W., Mahrlein, R. & Mangold, G. Results of the Limberg transposition flap in the treatment of pilonidal sinus. *Zentralbl Chir* **127**, 712–715, <https://doi.org/10.1055/s-2002-33579> (2002).
479. Jimenez Romero, C., Alcalde, M., Martin, F., Pulido, A. & Rico, P. Treatment of pilonidal sinus by excision and rhomboid flap. *Int J Colorectal Dis* **5**, 200–202 (1990).
480. Johnson, H. A. On treatment of pilonidal sinus and cysts by conservative excision and W-plasty closure. *Plast Reconstr Surg* **62**, 107–108 (1978).
481. Jonas, J., Blaich, S. & Bahr, R. Surgery of pilonidal sinus using the Limberg flap. *Zentralbl Chir* **125**, 976–981, <https://doi.org/10.1055/s-2000-10076> (2000).
482. Kapan, M., Kapan, S., Pekmezci, S. & Durgun, V. Sacrococcygeal pilonidal sinus disease with Limberg flap repair. *Tech Coloproctol* **6**, 27–32, <https://doi.org/10.1007/s101510200005> (2002).
483. Kapp, T., Zadnikar, M., Hahnloser, D., Soll, C. & Hetzer, F. H. New concept in the treatment of the pilonidal sinus. *Praxis (Bern 1994)* **96**, 1171–1176, <https://doi.org/10.1024/1661-8157.96.31.1171> (2007).
484. Karaca, A. S., Ali, R., Capar, M. & Karaca, S. Comparison of Limberg flap and excision and primary closure of pilonidal sinus disease, in terms of quality of life and complications. *J Korean Surg Soc* **85**, 236–239, <https://doi.org/10.4174/jkss.2013.85.5.236> (2013).
485. Karakas, B. R. *et al.* Is the lateralization distance important in terms in patients undergoing the modified Limberg flap procedure for treatment of pilonidal sinus? *Tech. Coloproctol.* (2014).
486. Karakas, B. R. Comparison of Z-plasty, limberg flap, and asymmetric modified Limberg flap techniques for the pilonidal sinus treatment: review of literature. *Acta Chir Iugosl* **60**, 31–37 (2013).
487. Katsoulis, I. E., Hibberts, F. & Carapeti, E. A. Outcome of treatment of primary and recurrent pilonidal sinuses with the Limberg flap. *Surgeon* **4**(7–10), 62 (2006).
488. Kaya, B. *et al.* Modified Limberg transposition flap in the treatment of pilonidal sinus disease. *Tech Coloproctol* **16**, 55–59, <https://doi.org/10.1007/s10151-011-0799-9> (2012).
489. Kicka, M., Toporcer, T. & Radonak, J. *Pilonidal sinus—a classical plastic procedure according to Limberg (Limberg flap procedure) or its modified version?* **90**, 482–487 (2011).
490. Kushwaha, R., El-Tawil, S., Hibberts, F., Katsoulis, I. E. & Carapeti, E. Treatment of complex primary and recurrent pilonidal sinus with a Rhomboid Transposition Flap. *Br J Surg* **93**, 1–104 (2006).
491. Lahooti, M., Taheri, P. A., Nezami, B. G. & Assa, S. Sacrococcygeal pilonidal sinus treated by a new fascio-cutaneous flap. *Dis Colon Rectum* **51**, 588–592, <https://doi.org/10.1007/s10350-008-9211-x> (2008).
492. Lamke, L. O., Larsson, J. & Nylen, B. Treatment of pilonidal sinus by radical excision and reconstruction by rotation flap surgery of Z-plasty technique. *Scand J Plast Reconstr Surg* **13**, 351–353 (1979).
493. Lauterbach, H. H. & Konrad, U. Zweiphasenkonzept zur Therapie des infizierten Sinus pilonidalis. *Chir Praxis* **55**, 623–628 (1999).
494. Lieto, E. *et al.* Dufourmental rhomboid flap in the radical treatment of primary and recurrent sacrococcygeal pilonidal disease. *Dis Colon Rectum* **53**, 1061–1068, <https://doi.org/10.1007/DCR.0b013e3181defd25> (2010).
495. Lodha, S. C. Treatment of pilonidal sinus by 'Z' plasty. *J Indian Med Assoc* **62**, 307–309 (1974).
496. Madbouly, K. M. Day-case Limberg flap for recurrent pilonidal sinus: does obesity complicate the issue? *Am Surg* **76**, 995–999 (2010).
497. Mansoor, A. & Dickson, D. Z-plasty for treatment of disease of the pilonidal sinus. *Surg Gynecol Obstet* **155**, 409–411 (1982).
498. Manterola, C., Barroso, M., Araya, J. C. & Fonseca, L. Pilonidal disease: 25 cases treated by the Dufourmental technique. *Dis Colon Rectum* **34**, 649–652 (1991).
499. McDermott, F. T. Pilonidal sinus treated by Z-plasty. *Aust N Z J Surg* **37**, 64–69 (1967).
500. Menten, O., Bagci, M., Bilgin, T., Ozgul, O. & Ozdemir, M. Limberg flap procedure for pilonidal sinus disease: results of 353 patients. *Langenbecks Arch Surg* **393**, 185–189, <https://doi.org/10.1007/s00423-007-0227-9> (2008).
501. Menten, B. B. *et al.* Modified Limberg transposition flap for sacrococcygeal pilonidal sinus. *Surg Today* **34**, 419–423, <https://doi.org/10.1007/s00595-003-2725-x> (2004).
502. Middleton, M. D. Treatment of pilonidal sinus by Z-plasty. *Br J Surg* **55**, 516–518 (1968).
503. Milito, G., Cortese, F. & Casciani, C. U. Rhomboid flap procedure for pilonidal sinus: results from 67 cases. *Int J Colorectal Dis* **13**, 113–115 (1998).
504. Milito, G. *et al.* Modified Limberg's transposition flap for pilonidal sinus. Long term follow up of 216 cases. *Ann Ital Chir* **78**, 227–231 (2007).
505. Misiakos, E. P. *et al.* Limberg flap reconstruction for the treatment of pilonidal sinus disease. *Chirurgia (Bucur)* **101**, 513–517 (2006).
506. Monro, R. S. & McDermott, F. T. The Elimination of Causal Factors in Pilonidal Sinus Treated by Z-Plasty. *Br J Surg* **52**, 177–181 (1965).
507. Moosavi, S. R., Kharazm, P. & Vaghardoost, R. Surgical treatment of pilonidal sinus with a fasciocutaneous rotation flap based on an inferior pedicle. *Scand J Plast Reconstr Surg Hand Surg* **40**, 281–283, <https://doi.org/10.1080/02844310600869811> (2006).
508. Müller, K. *et al.* Prospective analysis of cosmesis, morbidity, and patient satisfaction following Limberg flap for the treatment of sacrococcygeal pilonidal sinus. *Dis Colon Rectum* **54**, 487–494 (2011).
509. Mutaf, M., Temel, M. & Koc, M. N. A New Surgical Technique for Closure of Pilonidal Sinus Defects: Triangular Closure Technique. *Med Sci Monit* **23**, 1033–1042 (2017).
510. Naveen, N., Kumar, M. K., Babu, K. R. & Dhanraj, P. Tandem rhomboid flap repair: a new technique in treatment of extensive pilonidal disease of the natal cleft. *J Clin Diagn Res* **8**, ND03-04, <https://doi.org/10.7860/JCDR/2014/9283.4824> (2014).
511. Omer, Y., Hayrettin, D., Murat, C., Mustafa, Y. & Evren, D. Comparison of modified limberg flap and modified elliptical rotation flap for pilonidal sinus surgery: a retrospective cohort study. *Int J Surg* **16**, 74–77, <https://doi.org/10.1016/j.ijss.2015.02.024> (2015).
512. Öz, B. *et al.* A comparison of surgical outcome of fasciocutaneous V-Y advancement flap and Limberg transposition flap for recurrent sacrococcygeal pilonidal sinus disease. *Asian J Surg*, **6**, <https://doi.org/10.1016/j.asjsur.2015.10.002> (2015).
513. Ozgul, T. *et al.* Therapy of pilonidal sinus with the Limberg transposition flap. *Chirurg* **66**, 192–195 (1995).
514. Rabbani, S. *et al.* Rhomboid excision with limberg transposition flap in the management of sacrococcygeal pilonidal sinus - a reliable surgical technique. *Pakistan J of Medical and Health Sci* **8** (2014).
515. Rao, J., Deora, H. & Mandia, R. A Retrospective Study of 40 Cases of Pilonidal Sinus with Excision of Tract and Z-plasty as Treatment of Choice for Both Primary and Recurrent Cases. *Indian J Surg* **77**, 691–693, <https://doi.org/10.1007/s12262-013-0983-4> (2013).
516. Raza, M. W. *et al.* Limberg flap for pilonidal sinus. *J Rawal Med coll* **16**, 132–134 (2012).
517. Rojas Gorigoytia, G. R. Pilonidal sinuses. Treatment using the L.L.L. plasty. *Cir. Plast. Ibero-Latinoam.* **7**, 245–252 (1981).
518. Romero, C. J., Alcalde, M., Martin, F., Pulido, A. & Rico, P. Treatment of pilonidal sinus by excision and rhomboid flap. *Int J Colorectal Dis* **5**, 200–202, <https://doi.org/10.1007/BF00303275> (1990).
519. Roth, R. F. & Moorman, W. L. Treatment of pilonidal sinus and cyst by conservative excision and W-plasty closure. *Plast Reconstr Surg* **60**, 412–415 (1977).

520. Sabiani, P., Le Treut, Y. P., Bouloudnine, G., Maillet, B. & Bricot, R. Le traitement de la maladie pilonidale par la technique d'exérèse-plastie "LLL". A propos de 27 cas. *Annales de gastroentérologie et d'hépatologie* **21**, 287–290 (1985).
521. Sabuncuoğlu, M. Z. *et al.* Eyedrop-shaped, modified Limberg transposition flap in the treatment of pilonidal sinus disease. *Asian J Surg* **38**, 161–167, <https://doi.org/10.1016/j.asjsur.2015.03.007> (2015).
522. Sellés, R. *et al.* Complete excision and marsupialization of chronic pilonidal sacrococcygeal sinus: The ideal technique? *Cir. Esp.* **72**, 92–94, [https://doi.org/10.1016/S0009-739X\(02\)72016-2](https://doi.org/10.1016/S0009-739X(02)72016-2) (2002).
523. Shabir, F., Khan, B. A. & Mian, M. A. Rhomboid excision with Limberg flap a novel treatment for sacrococcygeal pilonidal sinus. *Pak. J. Med. Health Sci.* **8**, 687–690 (2014).
524. Sharma, P. P. Multiple Z-plasty in pilonidal sinus—a new technique under local anesthesia. *World J Surg* **30**, 2261–2265, <https://doi.org/10.1007/s00268-005-0632-6> (2006).
525. Singh, R. & Pavithran, N. M. Adipo-fascio-cutaneous flaps in the treatment of pilonidal sinus: experience with 50 cases. *Asian J Surg* **28**, 198–201, [https://doi.org/10.1016/S1015-9584\(09\)60343-2](https://doi.org/10.1016/S1015-9584(09)60343-2) (2005).
526. Spychala, A. & Murawa, D. The Limberg flap procedure in the treatment of pilonidal cyst disease of the sacrum - initial report. *Pol Przegł Chir* **86**, 257–262, <https://doi.org/10.2478/pjs-2014-0046> (2014).
527. Tardu, A., Haşlak, A., Özçınar, B. & Başak, F. Comparison of Limberg and Dufourmental flap in surgical treatment of pilonidal sinus disease. *Turk. J. Surg.* **27**, 35–40, <https://doi.org/10.5097/1300-0705.UCD.659-11.04>
528. Tekin, A. Pilonidal sinus: experience with the Limberg flap. *Colorectal Dis* **1**, 29–33, <https://doi.org/10.1046/j.1463-1318.1999.00007.x> (1999).
529. Topgul, K., Ozdemir, E., Kilic, K., Gokbayir, H. & Ferahkose, Z. Long-term results of limberg flap procedure for treatment of pilonidal sinus: a report of 200 cases. *Dis Colon Rectum* **46**, 1545–1548, <https://doi.org/10.1097/01.DCR.0000089114.56612.06> (2003).
530. Toubanakis, G. Treatment of pilonidal sinus disease with the Z-plasty procedure (modified). *Am Surg* **52**, 611–612 (1986).
531. Tschudi, J. & Ris, H. B. Morbidity of Z-plasty in the treatment of pilonidal sinus. *Chirurg* **59**, 486–490 (1988).
532. Unalp, H. R., Derici, H., Kamer, E., Nazli, O. & Onal, M. A. Lower recurrence rate for Limberg vs. V-Y flap for pilonidal sinus. *Dis Colon Rectum* **50**, 1436–1444, <https://doi.org/10.1007/s10350-007-0276-8> (2007).
533. Orhan, M. K., Kucukel, F., Topgul, K., Orzer, I. & Sari, S. Rhomboid excision and Limberg flap for managing pilonidal sinus: results of 102 cases. *Dis Colon Rectum* **45**, 656–659 (2002).
534. Wroński, K., Bocian, R. & Pakuła, D. Surgical treatment of pilonidal sinus by means of Z-plasty - Case report and literature review. *Prz. Dermatol.* **97**, 329–334 (2010).
535. Yamout, S. Z. *et al.* Early experience with the use of rhomboid excision and Limberg flap in 16 adolescents with pilonidal disease. *J Pediatr Surg* **44**, 1586–1590, <https://doi.org/10.1016/j.jpedsurg.2008.11.033> (2009).
536. Yeo, M. S., Shim, T. W., Cheong, W. K., Leong, A. P. & Lee, S. J. Simultaneous laser depilation and perforator-based fasciocutaneous limberg flap for pilonidal sinus reconstruction. *J Plast Reconstr Aesthet Surg* **63**, e798–800, <https://doi.org/10.1016/j.bjps.2010.06.032> (2010).
537. Yildar, M., Cavdar, F. & Yildiz, M. K. The evaluation of a modified Dufourmental flap after S-type excision for pilonidal sinus disease. *ScientificWorldJournal* **2013**, 459147, <https://doi.org/10.1155/2013/459147> (2013).
538. Yildar, M. & Cavdar, F. Comparison of the Limberg flap and bilateral gluteus maximus advancing flap following oblique excision for the treatment of pilonidal sinus disease. *Surg Today* **44**, 1828–1833, <https://doi.org/10.1007/s00595-013-0764-5> (2014).
539. Yilmaz, S., Kirimlioglu, V. & Katz, D. Role of simple V-Y advancement flap in the treatment of complicated pilonidal sinus. *Eur J Surg* **166**, 269 (2000).
540. Yoldas, T. *et al.* Recurrent pilonidal sinus: lay open or flap closure, does it differ? *Int Surg* **98**, 319–323, <https://doi.org/10.9738/INTSURG-D-13-00081.1> (2013).
541. Sood, S. C., Green, J. R. & Parui, R. Results of various operations for sacrococcygeal pilonidal disease. *Plast Reconstr Surg* **56**, 559–566 (1975).
542. Berkem, H. *et al.* V-Y advancement flap closures for complicated pilonidal sinus disease. *Int J Colorectal Dis* **20**, 343–348, <https://doi.org/10.1007/s00384-004-0699-9> (2005).
543. Awad, M. M., Saad, K. M., Tolba, A. M. & Gharib, O. H. A simple novel technique for closure of simple and complex pilonidal sinus with either simple (tongue-shaped) or bilobed rotation flap. *daten nachtragen* **44**, 47–50 (2007).
544. Ay, A., Aytakin, O. & Aytakin, A. Interdigitating Fasciocutaneous Gluteal V-Y Advancement Flaps for Reconstruction of Sacral Defects. *Ann. Plast. Surg.* **50**, 636–638, <https://doi.org/10.1097/01.sap.0000054241.94281.d2> (2003).
545. Basterzi, Y. *et al.* Reconstruction of extensive pilonidal sinus defects with the use of S-GAP flaps. *Ann Plast Surg* **61**, 197–200, <https://doi.org/10.1097/SAP.0b013e3181587a06> (2008).
546. Behan, F. C., Rozen, W. M. & Tan, S. Yin-Yang flaps: the mathematics of two keystone island flaps for reconstructing increasingly large defects. *ANZ J. Surg.* **81**, 574–575 (2011).
547. Boyce, D. E. & Shokrollahi, K. Reconstructive surgery. *BMJ (Clinical research ed.)* **332**, 710–712, <https://doi.org/10.1136/bmj.332.7543.710> (2006).
548. Cherry, J. K. Primary closure of pilonidal sinus. *Surg Gynecol Obstet* **126**, 1263–1269 (1968).
549. Demiryilmaz, I. *et al.* Application of fasciocutaneous V-Y advancement flap in primary and recurrent sacrococcygeal pilonidal sinus disease. *Med Sci Monit* **20**, 1263–1266, <https://doi.org/10.12659/MSM.890752> (2014).
550. Dilek, O. N. & Bekerecioglu, M. Role of simple V-Y advancement flap in the treatment of complicated pilonidal sinus. *eur J Surg* **164**, 961–964 (1998).
551. Dizen, H., Yoldas, O., Yildiz, M., Cilekar, M. & Dilektasli, E. Modified elliptical rotation flap for sacrococcygeal pilonidal sinus disease. *ANZ J Surg* **84**, 769–771, <https://doi.org/10.1111/ans.12818> (2014).
552. Dwright, R. W. Pilonidal sinus; an evaluation of plastic closure using flaps of gluteal muscle. *AMA Arch Surg* **64**, 438–442 (1952).
553. Dylek, O. N. & Bekerecioglu, M. Role of simple V-Y advancement flap in the treatment of complicated pilonidal sinus. *Eur J Surg* **164**, 961–964 (1998).
554. Ekcı, B. & Gokce, O. A new flap technique to treat pilonidal sinus. *Tech Coloproctol* **13**, 205–209, <https://doi.org/10.1007/s10151-009-0500-8> (2009).
555. Elalfy, K., Emile, S., Lotfy, A., Youssef, M. & Elfeki, H. Bilateral gluteal advancement flap for treatment of recurrent sacrococcygeal pilonidal disease: A prospective cohort study. *Int J Surg* **29**, 1–8, <https://doi.org/10.1016/j.ijsu.2016.03.006> (2016).
556. El-Khatib, H. A. & Al-Basti, H. B. A perforator-based bilobed fasciocutaneous flap: an additional tool for primary reconstruction following wide excision of sacrococcygeal pilonidal disease. *J Plast Reconstr Aesthet Surg* **62**, 494–498, <https://doi.org/10.1016/j.bjps.2007.11.043> (2009).
557. Elshahat, A. The versatility of the hatchet flap in soft tissue reconstruction and a proposed new classification. *Eur J Plast Surg* **35**, 351–357, <https://doi.org/10.1007/s00238-011-0615-9> (2012).
558. Ersen, B., Kahveci, R., Aksu, I. & Tunali, O. Multiple perforator preserving SGAP flap for the reconstruction of sacral wounds. *Eur J Plast Surg*. <https://doi.org/10.1007/s00238-015-1157-3> (2015).
559. Eryilmaz, R., Okan, I., Coskun, A., Bas, G. & Sahin, M. Surgical treatment of complicated pilonidal sinus with a fasciocutaneous V-Y advancement flap. *Dis Colon Rectum* **52**, 2036–2040, <https://doi.org/10.1007/DCR.0b013e3181beb537> (2009).
560. Ejermeros, H. Pilonidal cysts; treatment by Holman's operation. *Acta Chir Scand* **113**, 374–379 (1957).
561. Garrido, A., Ali, R., Ramakrishnan, V., Spyrou, G. & Stanley, P. R. Reconstruction of the natal cleft with a perforator-based flap. *Br J Plast Surg* **55**, 671–674 (2002).

562. Geuenich, A. & Hannekum, A. Primary closure of pilonidal sinus through a slide-swing operation. *Chirurg* **52**, 114–117 (1981).
563. Gordon, K. J. & Hunt, T. M. Osteomyelitis as a complication of a pilonidal sinus. *Int J Colorectal Dis* **31**, 155–156, <https://doi.org/10.1007/s00384-015-2184-z> (2016).
564. Ho Quoc, C. *et al.* Reconstruction fessière esthétique fiabilisée par une artère perforante glutéale. *Annales de chirurgie plastique et esthétique* **58**, 347–351, <https://doi.org/10.1016/j.anplas.2012.10.008> (2013).
565. Hobbs, A. F. An operative technique for the treatment of pilonidal sinus. *Aust N Z J Surg* **36**, 337–342 (1967).
566. Josvay, J., Sashegyi, M., Kelemen, P. & Donath, A. Clinical experience with the hatchet-shaped gluteus maximus musculocutaneous flap. *Ann. Plast. Surg* **55**, 179–182 (2005).
567. Kajisa, T., Usami, Y. & Kikuchi, F. Lumbar adipofascial turnover flap for reconstruction of pilonidal sinus; A case report. *Jpn. J. Plast. Surg.* **52**, 1357–1361 (2009).
568. Krand, O., Yalt, T., Berber, I., Kara, V. M. & Tellioglu, G. Management of pilonidal sinus disease with oblique excision and bilateral gluteus maximus fascia advancing flap: result of 278 patients. *Dis Colon Rectum* **52**, 1172–1177, <https://doi.org/10.1007/DCR.0b013e31819ef582> (2009).
569. Kauer, O. *et al.* Utilizacion del colgajo romboidal simple en el tratamiento quirurgico de la enfermedad pilonidal. *Revista chilena de cirugía* **51**, 623–626 (1999).
570. Kayaalp, C., Olmez, A., Aydin, C. & Piskin, T. Tumescant local anesthesia for excision and flap procedures in treatment of pilonidal disease. *Dis Colon Rectum* **52**, 1780–1783, <https://doi.org/10.1007/DCR.0b013e3181b553bb> (2009).
571. Khatri, V. P., Espinosa, M. H. & Amin, A. K. Management of recurrent pilonidal sinus by simple V-Y fasciocutaneous flap. *Dis Colon Rectum* **37**, 1232–1235 (1994).
572. Lasheen, A. E., Saad, K. & Raslan, M. Crossed triangular flaps technique for surgical treatment of chronic pilonidal sinus disease. *Arch Surg* **143**, 503–505, <https://doi.org/10.1001/archsurg.143.5.503> (2008).
573. Lin, C. T., Chen, S. Y., Chen, S. G., Tzeng, Y. S. & Chang, S. C. Parasacral Perforator Flaps for Reconstruction of Sacral Pressure Sores. *Ann. Plast. Surg* **75**, 62–65 (2015).
574. Lodhi, F. B., Ijaz, S. & Shafo, M. Pilonidal sinus: use of Limberg flap in the treatment. *Professional Med J* **13**, 435–439 (2006).
575. Mackowski, A. & Levitt, M. Outcomes of the house advancement flap for pilonidal sinus. *ANZ J Surg*, <https://doi.org/10.1111/ans.13077> (2015).
576. Mathur, B. S., Tan, S. S., Bhat, F. A. & Rozen, W. M. The transverse lumbar perforator flap: An anatomic and clinical study. *J Plast Reconstr Aesthet Surg* **69**, 770–776, <https://doi.org/10.1016/j.bjps.2016.03.023> (2016).
577. Al Najjar, M. J. A.-H. & Al Najjar, S. H. A. Elliptical Rotation Flap for Complicated Pilonidal Sinus. *Iraqi JMS* **13**, 56–63 (2015).
578. Nelson, R. & Lalonde, D. Treatment of the chronic pilonidal sinus wound with a local perforator-assisted transposition flap. *Plast Reconstr Surg* **122**, 47e–49e, <https://doi.org/10.1097/PRS.0b013e31817746c8> (2008).
579. Nessar, G., Kayaalp, C. & Seven, C. Elliptical rotation flap for pilonidal sinus. *Am J Surg* **187**, 300–303, <https://doi.org/10.1016/j.amjsurg.2003.11.012> (2004).
580. Onishi, K. & Maruyama, Y. Sacral adipofascial turn-over flap for the excisional defect of pilonidal sinus. *Plast Reconstr Surg* **108**, 2006–2010 (2001).
581. Ozdemir, H., Unal Ozdemir, Z., Tayfun Sahiner, I. & Senol, M. Whole natal cleft excision and flap: an alternative surgical method in extensive sacrococcygeal pilonidal sinus disease. *Acta Chir Belg* **114**, 266–270 (2014).
582. Özmen, S., Kandal, S., Findikcioglu, F. & Menteş, B. Superior gluteal artery perforator flap: An alternative in the treatment of complicated pilonidal sinus. **1**(17), 176–178 (2006).
583. Perez-Gurri, J. A., Temple, W. J. & Ketcham, A. S. Gluteus maximus myocutaneous flap for the treatment of recalcitrant pilonidal disease. *Dis Colon Rectum* **27**, 262–264 (1984).
584. Polat, C. *et al.* Is oval flap reconstruction a good modification for treating pilonidal sinuses? *Am J Surg* **201**, 192–196, <https://doi.org/10.1016/j.amjsurg.2010.01.025> (2011).
585. Rosen, W. & Davidson, J. S. Gluteus maximus musculocutaneous flap for the treatment of recalcitrant pilonidal disease. *Ann Plast Surg* **37**, 293–297 (1996).
586. Sahasrabudhe, P., Panse, N., Waghmare, C. & Waykole, P. V-y advancement flap technique in resurfacing postexcisional defect in cases with pilonidal sinus disease-study of 25 cases. *Indian J Surg* **74**, 364–370, <https://doi.org/10.1007/s12262-011-0403-6> (2012).
587. Saray, A., Dirlik, M., Caglikulekci, M. & Turkmenoglu, O. Gluteal V-Y advancement fasciocutaneous flap for treatment of chronic pilonidal sinus disease. *Scand J Plast Reconstr Surg Hand Surg* **36**, 80–84 (2002).
588. Schoeller, T., Wechselberger, G., Otto, A. & Papp, C. Definite surgical treatment of complicated recurrent pilonidal disease with a modified fasciocutaneous V-Y advancement flap. *Surgery* **121**, 258–263 (1997).
589. Schoeller, T., Wechselberger, G., Otto, A. & Papp, C. Pilonidal sinus: experience with the Karydakias flap. *Br J Surg* **84**, 890–891 (1997).
590. Schrögendorfer, K. F. *et al.* Prospective evaluation of a single-sided innervated gluteal artery perforator flap for reconstruction for extensive and recurrent pilonidal sinus disease: functional, aesthetic, and patient-reported long-term outcomes. *World J Surg* **36**, 2230–2236 (2012).
591. Stroosma, O. C. Gluteal fascioplasty as a method of primary closure in the treatment of pilonidal sinus. *Arch Chir Neerl* **30**, 61–64 (1978).
592. Sungur, N. *et al.* V-Y rotation advancement fasciocutaneous flap for excisional defects of pilonidal sinus. *Plast Reconstr Surg* **117**, 2448–2454, <https://doi.org/10.1097/01.prs.0000219170.74059.94> (2006).
593. Trooskin, S. Z. Pilonidal cyst: wide excision and primary closure with an advancement flap. *J Med Soc N J* **82**, 367–370 (1985).
594. Tuncbilek, G., Nasir, S., Ozkan, O., Kayikcioglu, A. & Mavili, E. Partially de-epithelialised and buried V-Y advancement flap for reconstruction of sacrococcygeal and ischial defects. *Scand. J Plast. Reconstr. Surg Hand Surg* **38**, 94–99 (2004).
595. Turan, A., Isler, C., Bas, S. C., Genc, B. & Ozsoy, Z. A new flap for reconstruction of pilonidal sinus: lumbar adipofascial turnover flap. *Ann Plast Surg* **58**, 411–415, <https://doi.org/10.1097/01.sap.0000243999.36577.3f> (2007).
596. Turner, F. P. Pilonidal sinus: primary closure with equal musculofascial flaps and removable far-and-near sutures; analysis of fifty-nine consecutive cases. *Ann Surg* **140**, 687–694 (1954).
597. Venus, M. R. & Titley, O. G. The use of the Limberg flap for reconstruction of pilonidal sinus excision wounds. *Surgeon* **5**, 127 (2007). author reply 127.
598. Venus, M. R. & Titley, O. G. Outcomes in the repair of pilonidal sinus disease excision wounds using a parasacral perforator flap. *Ann R Coll Surg Engl* **94**, 12–16, <https://doi.org/10.1308/003588412X13171221499748> (2012).
599. Windhofer, C., Michlits, W., Gruber, S. & Papp, C. Reconstruction in the buttock region using the local fasciocutaneous infragluteal (FCI) flap. *hair syndrome* **63**, 126–132 (2010).
600. Yazar, M. *et al.* Cosmetic closure of pilonidal sinus defects with bilateral transpositional adipofascial flaps. *J Plast Surg Hand Surg* **47**, 292–296, <https://doi.org/10.3109/2000656X.2013.765884> (2013).
601. Yücel, E. T. L. T. & Yilmaz, O. C. “Flag Excision an Flap” Procedure: a Novel Modification for Off-Midline Closure After Pilonidal Sinus Excision. *Indian J Surg* (2015).
602. Yuksel, B. C., Berkem, H., Ozel, H. & Hengirmen, S. A new surgical method of pilonidal sinus treatment: a bilaterally paralel elliptic fascio-cutaneous advancement flap technique. *Bratisl Lek Listy* **113**, 728–731 (2012).
603. Aldemir, M., Kara, I. H., Erten, G. & Tacyildiz, I. Effectiveness of collagenase in the treatment of sacrococcygeal pilonidal sinus disease. *Surg Today* **33**, 106–109, <https://doi.org/10.1007/s005950300022> (2003).

604. Oncel, M. *et al.* Excision and marsupialization versus sinus excision for the treatment of limited chronic pilonidal disease: a prospective, randomized trial. *Tech Coloproctol* **6**, 165–169, <https://doi.org/10.1007/s101510200037> (2002).
605. Abramson, D. J. Excision and delayed closure of pilonidal sinuses. *Surg Gynecol Obstet* **144**, 205–207 (1977).
606. Abramson, D. J. Outpatient management of pilonidal sinuses: excision and semiprimary closure technic. *Mil Med* **143**, 753–757 (1978).
607. Abramson, D. J. & Cox, P. A. The marsupialization operation for pilonidal cysts and sinuses under local anesthesia with lidocaine; an ambulatory method of treatment. *Ann Surg* **139**, 341–349 (1954).
608. Arauz, S., Yamaguchi, N., Schmidt Goffi, F. & Zanoto, A. Surgical treatment of sacrococcygeal pilonidal disease: a comparative study between marsupialization and incision plus curettage techniques. *Rev Col Bras Cir* **29**, 659–662 (2002).
609. Brockbank, M. J. Pilonidal Cyst. *Am J Surg* **68**, 4 (1945).
610. Cavanagh, C. R. & Schnug, G. E. Definitive Treatment of the Pilonidal Abscess. *Northwest Med* **63**, 449–451 (1964).
611. Cavanagh, C. R., Schnug, G. E., Girvin, G. W. & McGonigle, D. J. Definitive marsupialization of the acute pilonidal abscess. *Am Surg* **36**, 650–651 (1970).
612. Gonzalo Inostroza, L. *et al.* Pilonidal cyst abscess: Definitive treatment in a single time during the acute, short-term results. *Revista Chilena de Cirugia* **63**, 54–58 (2011).
613. Licheri, S. *et al.* Radical treatment of acute pilonidal abscess by marsupialization. *G Chir* **25**, 414–416 (2004).
614. Neumeister, C. A. A modification of the marsupialization operation for pilonidal disease. *tract coag max voltage* **56**, 730–732 (1963).
615. Ozbalci, G. S., Tuncal, S., Bayraktar, K., Tasova, V. & Ali Akkus, M. Is gentamicin-impregnated collagen sponge to be recommended in pilonidal sinus patient treated with marsupialization? A prospective randomized study. *Ann Ital Chir* **85**, 576–582 (2014).
616. Perez Oberreuter, G. *et al.* Tecnica de marsupializacion en quiste pilonidal: 7 anos de experiencia. *Revista chilena de cirugia* **50** (1998).
617. Sahsamani, G. *et al.* Semi-closed surgical technique for treatment of pilonidal sinus disease. *Ann Med Surg (Lond)* **15**, 47–51, <https://doi.org/10.1016/j.amsu.2017.02.004> (2017).
618. Struijk, D. G., Krediet, R. T., de Glas-Vos, J. W., Boeschoten, E. W. & Arisz, L. Experiences with acute peritoneal dialysis in adults. *Ned Tijdschr Geneesk* **128**, 751–755 (1984).
619. Van Ess, L. J. Surgical management of pilonidal disease. *Am J Proctol* **16**, 389–393 (1965).
620. Yildirim, D., Sunamak, O., Pergel, A. & Mounla, M. Combined single step definitive treatment in acute pilonidal sinus abscess. *Surg Sci* **1**, 24–26 (2010).
621. Zambouras, D. H. & Karavas, N. Operative Behandlung des Sakraldermoids durch eine neue modifizierte Marsupialisationsmethode. *Chirurg* **7**, 330–331 (1971).
622. Zimmerman, K. unknown. *Am J Surg* **86**, 569 (1953).
623. Vahedian, J., Nabavizadeh, F., Nakhaee, N., Vahedian, M. & Sadeghpour, A. Comparison between drainage and curettage in the treatment of acute pilonidal abscess. *Saudi Med J* **26**, 553–555 (2005).
624. Al Homoud, S. J., Habib, Z. S., Abdul Jabbar, A. S. & Isbister, W. H. Management of sacrococcygeal pilonidal disease. *Saudi. Med. J.* **22**, 762–764 (2001).
625. Arik, M. K. & Borazan, E. Phenol application combined with minimally invasive surgery for pilonidal sinus treatment. *Anatolian J. Clin. Invest.* **5**, 165–168 (2011).
626. Balsamo, F., Borges, A. M. P. & Formiga, G. J. S. Pilonidal sinus: Surgical treatment results with incision and curettage. *Rev. Bras. Coloproctologia* **29**, 325–328 (2009).
627. Biegeleisen, H. I. Sclerotherapy for pilonidal cyst. *Am J Surg* **64**, 622–625 (1939).
628. Boulay, J. & Prudent, J. Continuous drainage by thread applied to treatment of pilonidal disease. *Annales de Gastroenterologie et d'Hepatology* **16**, 317–323 (1980).
629. Crile, G. Jr. A definitive ambulatory treatment for infected pilonidal cysts. *Surgery* **24**, 677–679 (1948).
630. Eley, E. & Lund, J. N. Fibrin glue in the treatment for pilonidal sinus: high patient satisfaction and rapid return to normal activities. *Tech Coloproctol* **17**, 101–104, <https://doi.org/10.1007/s10151-012-0956-9> (2013).
631. Gage, A. A. & Dutta, P. Cryosurgery for pilonidal disease. *Am J Surg* **133**, 249–254 (1977).
632. Garg, P., Garg, M., Gupta, V., Mehta, S. K. & Lakhtaria, P. Laying open (deroofing) and curettage under local anesthesia for pilonidal disease: An outpatient procedure. *World J Gastrointest Surg* **7**, 214–218, <https://doi.org/10.4240/wjgs.v7.i9.214> (2015).
633. Gidwani, A. L., Murugan, K., Nasir, A. & Brown, R. Incise and lay open: an effective procedure for coccygeal pilonidal sinus disease. *Ir J Med Sci* **179**, 207–210, <https://doi.org/10.1007/s11845-009-0450-1> (2010).
634. Gul, V. O. *et al.* Minimally Invasive Surgical Approach to Complicated Recurrent Pilonidal Sinus. *Case Rep Surg* **2015**, 759316, <https://doi.org/10.1155/2015/759316> (2015).
635. Gupta, P. J. Radiofrequency incision and lay open technique of pilonidal sinus (clinical practice paper on modified technique). *Kobe J Med Sci* **49**, 75–82 (2003).
636. Isbister, W. H. & Prasad, J. Pilonidal disease. *Aust N Z J Surg* **65**, 561–563 (1995).
637. Jain, V. & Jain, A. Use of lasers for the management of refractory cases of hidradenitis suppurativa and pilonidal sinus. *J Cutan Aesthet Surg* **5**, 190–192, <https://doi.org/10.4103/0974-2077.101377> (2012).
638. Jensen, S. L. & Harling, H. Prognosis after simple incision and drainage for a first-episode acute pilonidal abscess. *Br J Surg* **75**, 60–61 (1988).
639. Kepenekci, I., Demirkan, A., Celasin, H. & Gecim, I. E. Unroofing and curettage for the treatment of acute and chronic pilonidal disease. *World J Surg* **34**, 153–157, <https://doi.org/10.1007/s00268-009-0245-6> (2010).
640. Klin, B., Heller, O. N. & Kaplan, I. The use of the CO₂ laser in pilonidal sinus disease: preliminary results of an ambulatory prospective study. *J Clin Laser Med Surg* **8**, 31–37 (1990).
641. Korb, J. H. Infected pilonidal cysts; a simplified method of treatment. *Mil Surg* **108**, 29–34 (1951).
642. Lewin, R. A. Pilonidal Sinus in Infancy. *Pediatrics* **35**, 795–797 (1965).
643. Matino, J. J., Banerjee, S., Brown, S. H. & Waldron, J. E. Human dermal tissue allograft use in treating chronic pilonidal sinus. *Conn Med* **74**, 393–398 (2010).
644. Mikkelsen, K. Pilonidal sinus. A follow-up study of out-patients treated by simple incision. *Ugeskr Laeger* **137**, 789–791 (1975).
645. Miller, R. J. Pilonidal disease. A logical approach. *Postgrad Med* **41**, 382–385 (1967).
646. O'Connor, J. J. Surgery plus freezing as a technique for treating pilonidal disease. *Dis Colon Rectum* **22**, 306–307 (1979).
647. Olmez, A., Kayaalp, C. & Aydin, C. Treatment of pilonidal disease by combination of pit excision and phenol application. *Tech Coloproctol* **17**, 201–206, <https://doi.org/10.1007/s10151-012-0903-9> (2013).
648. Qayyum, I., Bai, D. & Tsoraides, S. S. Loop drainage after debridement (LDAD): minimally invasive treatment for pilonidal cyst. *Tech Coloproctol* **20**, 591–594, <https://doi.org/10.1007/s10151-016-1469-8> (2016).
649. Shafiroff, B. G. & Doubilet, H. The conservative treatment of pilonidal cyst. *N Y State J Med* **46**, 891–893 (1946).
650. Shirah, B. & Shirah, H. The Effect of Hydrogen Peroxide on the Healing of the Laid Open Wound in the Treatment of Chronic Sacrococcygeal Pilonidal Sinus: A Retrospective Database Analysis of 500 Patients. *International Journal of Surgery and Medicine* **2**, 17, <https://doi.org/10.5455/ijsm.woundhealing> (2016).
651. Sozen, S. O., Sozen, V. & Das, V. *et al.* Day-Care Surgery for Pilonidal Sinus Using Sinotomy Technique and Fibrin Glue Injection. *Arch Clin Exp Surg* **1**, 138–141 (2012).

652. Thomson, J. P. & Lee, J. Radical Surgery for pilonidal sinus. *Ann R Coll Surg Engl* **65**, 64 (1983).
653. Thorlakson, R. H. An Unusual Type of Pilonidal Sinus: Report of a Case. *Dis Colon Rectum* **6**, 345–351 (1963).
654. Yalcin, S. & Ergul, E. A single-surgeon, single-institute experience of 59 sinotomies for sacrococcygeal pilonidal disease under local anesthesia. *Bratisl Lek Listy* **111**, 284–285 (2010).
655. Bascom, J. Pilonidal disease: long-term results of follicle removal. *Dis Colon Rectum* **26**, 800–807 (1983).
656. Bascom, J. Pilonidal disease: origin from follicles of hairs and results of follicle removal as treatment. *Surgery* **87**, 567–572 (1980).
657. Cherian, T. K. A simple out-patient treatment for pilonidal sinus (Millar-Lord method). *INDIAN J. SURG.* **42**, 119–122 (1980).
658. Colov, E. P. & Bertelsen, C. A. Short convalescence and minimal pain after out-patient Bascom's pit-pick operation. *Danish medical bulletin* **58**, A4348 (2011).
659. Di Castro, A., Guerra, F., Levi Sandri, G. B. & Ettorre, G. M. Minimally invasive surgery for the treatment of pilonidal disease. The Gips procedure on 2347 patients. *Int J Surg* **36**, 201–205, <https://doi.org/10.1016/j.ijsu.2016.10.040> (2016).
660. Edwards, M. H. Pilonidal sinus: a 5-year appraisal of the Millar-Lord treatment. *Br J Surg* **64**, 867–868 (1977).
661. Chen, C. L., Fitzpatrick, L. & Kamel, H. Who uses the emergency department for dermatologic care? A statewide analysis. *Journal of the American Academy of Dermatology* **71**, 308–313, <https://doi.org/10.1016/j.jaad.2014.03.013> (2014).
662. Froidevaux, A. & Marti, M. C. Sacro coccygeal cysts. *Results of a new series of 51 cases. Lyon Chir* **73**, 269–271 (1977).
663. Gips, M., Melki, Y., Salem, L., Weil, R. & Sulkes, J. Minimal surgery for pilonidal disease using trephines: description of a new technique and long-term outcomes in 1,358 patients. *Dis Colon Rectum* **51**, 1656–1662, discussion 1662–1653, <https://doi.org/10.1007/s10350-008-9329-x> (2008).
664. Iesalnieks, I., Deimel, S., Kienle, K., Schlitt, H. J. & Zulke, C. Pit-picking surgery for pilonidal disease. *Chirurg* **82**, 927–931, <https://doi.org/10.1007/s00104-011-2077-9> (2011).
665. Iesalnieks, I., Deimel, S. & Schlitt, H. J. "Pit picking" surgery for patients with pilonidal disease: mid-term results and risk factors. *Chirurg* **86**, 482–485, <https://doi.org/10.1007/s00104-014-2776-0> (2015).
666. Jensen, S. L. & Nielsen, O. V. Lord-Millar brush method in ambulatory treatment of pilonidal cysts. *Ugeskr Laeger* **150**, 98–100 (1988).
667. Khodakaram, K., Stark, J., Hoglund, I. & Andersson, R. E. Minimal Excision and Primary Suture is a Cost-Efficient Definitive Treatment for Pilonidal Disease with Low Morbidity: A Population-Based Interventional and a Cross-Sectional Cohort Study. *World J Surg* **41**, 1295–1302, <https://doi.org/10.1007/s00268-016-3828-z> (2017).
668. Klaiber, C., Staub, A., Ackermann, D. & Akovbiantz, A. The Lord-Millar operation of pilonidal sinus. *HELV. CHIR. ACTA* **49**, 221–222 (1982).
669. Lord, P. H. & Millar, D. M. Pilonidal Sinus: A Simple Treatment. *Br J Surg* **52**, 298–300 (1965).
670. Lund, J. N. & Leveson, S. H. Fibrin glue in the treatment of pilonidal sinus: results of a pilot study. *Dis Colon Rectum* **48**, 1094–1096, <https://doi.org/10.1007/s10350-004-0905-4> (2005).
671. Majeski, J. & Stroud, J. Sacrococcygeal pilonidal disease. *Int Surg* **96**, 144–147 (2011).
672. Millar, D. M. & Lord, P. H. The treatment of acute postanal pilonidal abscess. *Br J Surg* **54**, 598–599 (1967).
673. Mosquera, D. A. & Quayle, J. B. Bascom's operation for pilonidal sinus. *J R Soc Med* **88**, 45P–46P (1995).
674. Neola, B., Capasso, S., Caruso, L., Falato, A. & Ferulano, G. P. Scarless outpatient ablation of pilonidal sinus: a pilot study of a new minimally invasive treatment. part 2, <https://doi.org/10.1111/iwj.12350> (2014).
675. Parvaiz, A. & Kennedy, R. Bascom's procedure in the day-surgical management of symptomatic pilonidal sinus. *Br J Surg* **88**, 155–156 (2001).
676. Petersen, S. Skin preserving pit excision, so-called pit picking. *Pilonidal Sinus Journal* **3**, 7 (2017).
677. Petrovic, J., Dimitrijevic, I. & Krivokapic, Z. Minor vs complete excision of pilonidal sinus—early postoperative period. *Acta Chir Jugosl* **59**, 81–85 (2012).
678. Senapati, A., Cripps, N. P. & Thompson, M. R. Bascom's operation in the day-surgical management of symptomatic pilonidal sinus. *Br J Surg* **87**, 1067–1070, <https://doi.org/10.1046/j.1365-2168.2000.01472.x> (2000).
679. Smart, P. J., Dungerwalla, M. & Heriot, A. G. Bascom's Simple Pilonidal Sinus Surgery: Simpler with Ultrasound Guidance. *Journal of Medical Ultrasound* **21**, 97–99, <https://doi.org/10.1016/j.jmu.2013.04.001> (2013).
680. Zorcolo, L., Capra, F., Scintu, F. & Casula, G. Surgical treatment of pilonidal disease. Results with the Bascom's technique. *Minerva Chir* **59**, 387–395 (2004).
681. Postlethwait, R. W. Extensive Pilonidal Cyst - Case Report. *Am J Surg* **64**, 416–418 (1944).
682. Pyrttek, L. J. & Bartus, S. A. Excision of Pilonidal Cyst with Simplified Partial Wound Closure. *Surg Gynecol Obstet* **118**, 605–608 (1964).
683. Rahoma, A. H. Pilonidal sinus: Why does it recur. *Malays. J. Med. Health Sci.* **5**, 69–77 (2009).
684. Anderson, A. W. Hair extracted from an ulcer. *Boston Med Surg J* **36**, 74 (1847).
685. Javed, M. A. *et al.* Comparison of conventional incision and drainage for pilonidal abscess versus novel endoscopic pilonidal abscess treatment (EPAT). *Tech Coloproctol* **20**, 871–873, <https://doi.org/10.1007/s10151-016-1546-z> (2016).
686. Klass, A. A. The so-called pilo-nidal sinus. *hair clothes breaking shoulder etc* **75**, 737–742 (1956).
687. Aksoy, H. M., Aksoy, B. & Egemen, D. Effectiveness of topical use of natural polyphenols for the treatment of sacrococcygeal pilonidal sinus disease: a retrospective study including 192 patients. *Eur J Dermatol* **20**, 476–481, <https://doi.org/10.1684/ejd.2010.0978> (2010).
688. Aygen, E., Arslan, K., Dogru, O., Basbug, M. & Camci, C. Crystallized phenol in nonoperative treatment of previously operated, recurrent pilonidal disease. *Dis Colon Rectum* **53**, 932–935, <https://doi.org/10.1007/DCR.0b013e3181d8283b> (2010).
689. Dag, A., Colak, T., Turkmenoglu, O., Sozutek, A. & Gundogdu, R. Phenol procedure for pilonidal sinus disease and risk factors for treatment failure. *Surgery* **151**, 113–117, <https://doi.org/10.1016/j.surg.2011.07.015> (2012).
690. Dogru, O., Camci, C., Aygen, E., Girgin, M. & Topuz, O. Pilonidal sinus treated with crystallized phenol: an eight-year experience. *Dis. Colon Rectum* **47**, 1934–1938 (2004).
691. Girgin, M. & Kanat, B. H. The results of a one-time crystallized phenol application for pilonidal sinus disease. *Indian J Surg* **76**, 17–20, <https://doi.org/10.1007/s12262-012-0548-y> (2014).
692. Girgin, M. *et al.* Minimally invasive treatment of pilonidal disease: crystallized phenol and laser depilation. *Int Surg* **97**, 288–292, <https://doi.org/10.9738/CCI30.1> (2012).
693. Gulpinar, K., Pampal, A., Ozis, S. E. & Kuzu, M. A. Non-operative therapy for pilonidal sinus in adolescence: crystallised phenol application, 'report of a case'. *BMJ Case Rep* **2013**, <https://doi.org/10.1136/bcr-2012-008382> (2013).
694. Hegge, H. G., Vos, G. A., Patka, P. & Hoitsma, H. F. Treatment of complicated or infected pilonidal sinus disease by local application of phenol. *Surgery* **102**, 52–54 (1987).
695. Kayaalp, C., Olmez, A., Aydin, C., Piskin, T. & Kahraman, L. Investigation of a one-time phenol application for pilonidal disease. *Med Princ Pract* **19**, 212–215, <https://doi.org/10.1159/000285291> (2010).
696. Kaymakcioglu, N. *et al.* Treatment of pilonidal sinus by phenol application and factors affecting the recurrence. *Tech Coloproctol* **9**, 21–24, <https://doi.org/10.1007/s10151-005-0187-4> (2005).
697. Kelly, S. B. & Graham, W. J. Treatment of pilonidal sinus by phenol injection. *Ulster Med J* **58**, 56–59 (1989).
698. Maurice, B. A. & Greenwood, R. K. A Conservative Treatment of Pilonidal Sinus. *Br J Surg* **51**, 510–512 (1964).
699. Owen Smith, M. S. *Phenol irrigation for pilonidal sinus.* **121**, 79–86 (1975).

700. Rignault, D., Pailler, J. L., Bon, J. C., Chauvet, J. & Emani, A. Clinical aspects of pilonidal sinus: a study of 572 cases. *Gastroenterol Clin Biol* **1**, 925–929 (1977).
701. Rignault, D., Pailler, J. L., Brillac, J., Essioux, H. & Bon, J. C. Nonsurgical treatment of pilonidal fistulas by the curettage-phenolization method. *Gastroenterol Clin Biol* **1**, 941–944 (1977).
702. Sakcak, I., Avsar, F. M. & Cosgun, E. Comparison of the application of low concentration and 80% phenol solution in pilonidal sinus disease. *JRSM.Short Rep.* **1**, 5 (2010).
703. Schneider, I. H., Thaler, K. & Kockerling, F. Treatment of pilonidal sinuses by phenol injections. *Int J Colorectal Dis* **9**, 200–202 (1994).
704. Stephens, F. O. & Sloane, D. R. Management of pilonidal sinus—a modern approach. *Med J Aust* **1**, 395–396 (1968).
705. Vara-Thorbeck, R., Mekinassi, K. & Berchid, S. Phenol treatment of pilonidal sinuses. *Zentralbl Chir* **115**, 777–780 (1990).
706. Yilmaz, M. E., Yilmaz, O. & Uyar, M. E. *et al.* Crystalline Phenol Practices and Clinical Results in our Patients with Pilonidal Sinus. *J Universal Surg* **3**, 1–4 (2015).
707. Benedetto, A. V. & Lewis, A. T. Pilonidal sinus disease treated by depilation using an 800 nm diode laser and review of the literature. *Dermatol Surg* **31**, 587–591 (2005).
708. Downs, A. M. & Palmer, J. Laser hair removal for recurrent pilonidal sinus disease. *J Cosmet Laser Ther* **4**, 91 (2002).
709. Kandamany, N. & Mahaffey, P. J. The importance of hair control and personal hygiene in preventing recurrent pilonidal sinus disease. *J Plast Reconstr Aesthet Surg* **61**, 986–987, <https://doi.org/10.1016/j.bjps.2007.11.065> (2008).
710. Koch, D., Pratsou, P., Szczecinska, W., Lanigan, S. & Abdullah, A. The diverse application of laser hair removal therapy: a tertiary laser unit's experience with less common indications and a literature overview. *tabs!!* **30**, 453–467, <https://doi.org/10.1007/s10103-013-1464-5> (2015).
711. Landa, N., Aller, O., Landa-Gundin, N., Torrontegui, J. & Azpiazu, J. L. Successful treatment of recurrent pilonidal sinus with laser epilation. *Dermatol Surg* **31**, 726–728 (2005).
712. Lavelle, M., Jafri, Z. & Town, G. Recurrent pilonidal sinus treated with epilation using a ruby laser. *J Cosmet Laser Ther* **4**, 45–47, <https://doi.org/10.1080/147641702320602564> (2002).
713. Lindholt, C. S., Lindholt, J. S. & Lindholt, J. Nd-YAG laser treatment in a patient with complicated pilonidal cysts. *BMJ Case Rep* **2009**, <https://doi.org/10.1136/bcr.07.2008.0552> (2009).
714. Lindholt-Jensen, C. S., Lindholt, J. S. & Beyer, M. Nd-YAG laser treatment of primary and recurrent pilonidal sinus. *Lasers Med Sci* **27**, 505–508 (2012).
715. Odili, J. & Gault, D. Laser depilation of the natal cleft—an aid to healing the pilonidal sinus. *Ann R Coll Surg Engl* **84**, 29–32 (2002).
716. Piccolo, D. *et al.* Unconventional use of intense pulsed light. *Biomed.Res.Int.* **2014**, 618206 (2014).
717. Sadick, N. S. & Yee-Levin, J. Laser and light treatments for pilonidal cysts. *Cutis* **78**, 125–128 (2006).
718. Saraceno, R., Teoli, M., Casciello, C. & Chimenti, S. Methyl aminolaevulinate photodynamic therapy for the treatment of hidradenitis suppurativa and pilonidal cysts. *Photodermatol Photoimmunol Photomed* **25**, 164–165, <https://doi.org/10.1111/j.1600-0781.2009.00428.x> (2009).
719. Shafiqh, Y., Beheshti, A., Charkhchian, M. & Rad, F. S. Successful treatment of pilonidal disease by intense pulsed light device. *Adv Clin Exp Med* **23**, 277–282 (2014).
720. Armstrong, J. H. & Barcia, P. J. Pilonidal sinus disease. The conservative approach. *Arch Surg* **129**, 914–917, discussion 917–919 (1994).
721. Berger, H. The medical treatment of pilonidal disease. *N Y State J Med* **49**, 1313 (1949).
722. Borde, C. M. & Bruck, H. G. The indications for split thickness skin grafting in recurrent pilonidal sinus. *Wiener Klinische Wochenschrift* **85**, 624–628 (1973).
723. Chia, C. L., Tay, V. W. & Mantoo, S. K. Endoscopic pilonidal sinus treatment in the Asian population. *Surg Laparosc Endosc Percutan Tech* **25**, e95–97, <https://doi.org/10.1097/SLE.0000000000000131> (2015).
724. Conroy, F. J., Kandamany, N. & Mahaffey, P. J. Laser depilation and hygiene: preventing recurrent pilonidal sinus disease. *J Plast Reconstr Aesthet Surg* **61**, 1069–1072, <https://doi.org/10.1016/j.bjps.2007.06.022> (2008).
725. Dwivedi, A. P. Management of pilonidal sinus by Kshar Sutra, a minimally invasive treatment. *Int J Ayurveda Res* **1**, 122–123, <https://doi.org/10.4103/0974-7788.64408> (2010).
726. Encabo, B. *et al.* Pilonidal sinus: clinical and ultrasonographic response to topical resorcinol 15. *Br J Dermatol* **175**, 1103–1104, <https://doi.org/10.1111/bjd.14872> (2016).
727. Feit, H. L. The use of thorium X in treatment of pilonidal cyst: a preliminary report. *Dis Colon Rectum* **3**, 61–64 (1960).
728. Flannery, B. P. & Kidd, H. A. A review of pilonidal sinus lesions and a method of treatment. *Postgrad Med J* **43**, 353–358 (1967).
729. Hemanta, P., Kumar, R. R. & Rao, M. M. Ksharasutra therapy - a minimal invasive parasurgical method in the treatment of sacrococcygeal pilonidal sinus (Nadi vrana): Result of a pilot study. *Intern. J. Res. Ayurveda Pharm.* **3**, 668–670, <https://doi.org/10.7897/2277-4343.03518> (2012).
730. Hirshowitz, B., Mahler, D. & Kaufmann-Friedmann, K. Treatment of pilonidal sinus. *Surg Gynecol Obstet* **131**, 119–122 (1970).
731. Hussain, Z. I., Aghahoseini, A. & Alexander, D. Converting emergency pilonidal abscess into an elective procedure. *Dis Colon Rectum* **55**, 640–645, <https://doi.org/10.1097/DCR.0b013e31824b9527> (2012).
732. Isik, A. *et al.* The use of fibrin glue without surgery in the treatment of pilonidal sinus disease. *Int J Clin Exp Med* **7**, 1047–1051 (2014).
733. Jain, Y. *et al.* Endoscopic pilonidal abscess treatment: a novel approach for the treatment of pilonidal abscess. *Ann R Coll Surg Engl*, 1–3, <https://doi.org/10.1308/rcsann.2016.0260> (2016).
734. Lewis, A. T. & Benedetto, A. V. Lasers in dermatology: Unapproved treatments. *Clin. Dermatol.* **20**, 700–714, [https://doi.org/10.1016/S0738-081X\(02\)00292-4](https://doi.org/10.1016/S0738-081X(02)00292-4) (2002).
735. Lu, J. G., Wang, C., Cao, Y. Q. & Yao, Y. B. Thread-dragging and pad pressure therapy in traditional Chinese medicine for treatment of pilonidal sinus: a case report. *Zhong Xi Yi Jie He Xue Bao* **9**, 36–37 (2011).
736. Meinero, P. *et al.* Endoscopic pilonidal sinus treatment (EPSiT): a prospective multicentre trial. *Colorectal Dis*, <https://doi.org/10.1111/codi.13322> (2016).
737. Meinero, P., Mori, L. & Gasoli, G. Endoscopic pilonidal sinus treatment (E.P.Si.T.). *Tech Coloproctol* **18**, 389–392, <https://doi.org/10.1007/s10151-013-1016-9> (2014).
738. Mendes, C. R. S., Ferreira, L. S. D., Sapucaia, R. A. & Lima, M. A. Endoscopic pilonidal sinus treatment (E.P.Si.T.): a minimally invasive approach. *Journal of Coloproctology* **35**, 72–75, <https://doi.org/10.1016/j.jcol.2015.01.007> (2015).
739. Milone, M. *et al.* Video-assisted ablation of pilonidal sinus: a new minimally invasive treatment—a pilot study. *Surgery* **155**, 562–566, <https://doi.org/10.1016/j.surg.2013.08.021> (2014).
740. Milone, M., Bianco, P., Musella, M. & Milone, F. A technical modification of video-assisted ablation for recurrent pilonidal sinus. *Colorectal Dis* **16**, O404–406, <https://doi.org/10.1111/codi.12770> (2014).
741. Rao, A. C. Cutting seton for pilonidal disease: a new approach. *Tech Coloproctol* **10**, 242–244, <https://doi.org/10.1007/s10151-006-0287-9> (2006).
742. Sangamesh, H., Chandrakanth, H. & Vijaykumar, B. A case discussion on pilonidal sinus: Case report. *Intern. J. Res. Ayurveda Pharm.* **3**, 746–747, <https://doi.org/10.7897/2277-4343.03535> (2012).
743. Williams, D. W. Free graft repair in pilonidal sinus. *Postgrad Med J* **30**, 430–433 (1954).

744. Ypsilantis, E., Carapeti, E. & Chan, S. The use of topical 10% metronidazole in the treatment of non-healing pilonidal sinus wounds after surgery. *Int J Colorectal Dis.* <https://doi.org/10.1007/s00384-015-2269-8> (2015).
745. Ishida, H. Five cases of pilonidal sinus (Japanese). *J. Clin. Surg.* **28**, 1597–1599 (1973).
746. Rains, A. J. Treatment of pilonidal sinus by excision and primary closure. *Br Med J* **2**, 171–173 (1959).
747. Agren, M. S. *et al.* A randomized, double-blind, placebo-controlled multicenter trial evaluating topical zinc oxide for acute open wounds following pilonidal disease excision. *Wound Repair Regen* **14**, 526–535, <https://doi.org/10.1111/j.1743-6109.2006.00159.x> (2006).
748. Aldaqal, S. M., Kensarah, A. A., Alhabboubi, M. & Ashy, A. A. A new technique in management of pilonidal sinus, a university teaching hospital experience. *Int Surg* **98**, 304–306, <https://doi.org/10.9738/INTSURG-D-13-00064.1> (2013).
749. Weeks, R. B. Y. & Weeks, G. G. Sacrococcygeal Cysts - Report of 200 cases in an army hospital. *Am J Surg* **60**, 260–263 (1943).
750. Hopping, R. A. Pilonidal disease; review of the literature with comments on the etiology, differential diagnosis and treatment of the disease. *Am J Surg* **88**, 780–788 (1954).
751. Doll, D. Pilonidal Disease Surgery Needs More Off-Midline Closure Education. *World J Surg*, <https://doi.org/10.1007/s00268-016-3809-2> (2016).
752. Higgins, J. & Thompson, S. G. Quantifying heterogeneity in a meta-analysis. *Statistics in medicine* **21**, 1539–1558 (2002).
753. Higgins, J. P., Thompson, S. G., Deeks, J. J. & Altman, D. G. Measuring inconsistency in meta-analyses. *Bmj* **327**, 557–560, <https://doi.org/10.1136/bmj.327.7414.557> (2003).

Acknowledgements

The authors thank Dr. Eric Milner (Biomedical Science Writers, LLC www.biomedicalsciencewriters.com) for language editing the manuscript.

Author Contributions

V.S., M.M.L., M.D., K.W., D.D. acquired the data. V.S., M.M.L., P.K., M.S., D.D. performed statistical analysis and calculations. V.S., M.M.L., P.K., M.S., M.D., K.W., B.S., D.D. interpreted the data and edited the manuscript. V.S., M.M.L., P.K., B.S., D.D. wrote the manuscript. V.S., M.M.L., P.K., M.S., D.D. designed the graphics.

Additional Information

Supplementary information accompanies this paper at <https://doi.org/10.1038/s41598-018-20143-4>.

Competing Interests: The authors declare no competing interests.

Publisher's note: Springer Nature remains neutral with regard to jurisdictional claims in published maps and institutional affiliations.



Open Access This article is licensed under a Creative Commons Attribution 4.0 International License, which permits use, sharing, adaptation, distribution and reproduction in any medium or format, as long as you give appropriate credit to the original author(s) and the source, provide a link to the Creative Commons license, and indicate if changes were made. The images or other third party material in this article are included in the article's Creative Commons license, unless indicated otherwise in a credit line to the material. If material is not included in the article's Creative Commons license and your intended use is not permitted by statutory regulation or exceeds the permitted use, you will need to obtain permission directly from the copyright holder. To view a copy of this license, visit <http://creativecommons.org/licenses/by/4.0/>.

© The Author(s) 2018