

Comparative Study of Imprint Cytology and Frozen Section in the Intraoperative Diagnosis of Thyroid Lesions

Sukumar Shaha¹, AJE Nahar Rahman²

Abstract

Imprint cytology can provide a useful adjunct to the frozen section diagnosis and may be used safely in the intraoperative diagnosis of thyroid nodules, especially in the centres where frozen section facilities are not available. This study was conducted to compare imprint cytology and frozen section in terms of diagnostic accuracy, sensitivity, specificity, positive predictive value and to assess the value of imprint cytology in the intraoperative diagnosis of thyroid lesions. A total of 57 consecutive patients were enrolled in the study. All of the patients underwent frozen section in the department of pathology, BSMMU, Dhaka. Imprints were taken from the fresh specimen sent for frozen section from departments of otolaryngology and surgery of BSMMU. Imprint slides were stained with rapid H & E staining method. Then the tissues were submitted for frozen section by standard method. In this study, diagnostic accuracy, sensitivity, specificity, positive predictive value and negative predictive value of imprint cytology were 81.25%, 66.66%, 82.59%, 87.12% respectively. Frozen section revealed the diagnostic accuracy, sensitivity, specificity, positive predictive value and negative predictive as 88.46%, 72.72%, 100%, 100%, 83.33% respectively. Imprint cytology was found to be comparable with frozen section in diagnostic accuracy and sensitivity. Since imprint cytology is a simple and cost-effective procedure it can be used as an alternative to frozen section in hospitals where frozen section facilities are not available.

Key Words: Imprint cytology, frozen section, intraoperative diagnosis of thyroid lesions

Introduction

The thyroid gland is the largest endocrine gland of the body. Pathologic lesions of varied morphology affect the thyroid. These lesions may cause diffuse or nodular enlargement of the thyroid. Diffuse thyroid enlargement are mostly associated with non-neoplastic lesions. Nodular enlargement is produced in non-neoplastic as well as benign and malignant lesions¹. Thyroid diseases can be divided into three groups: inflammatory (thyroiditis), hyperlastic (nodular goiters and Grave's disease), and neoplastic diseases. A thyroid nodule is a palpable swelling in a thyroid gland with an otherwise normal appearance. Thyroid nodules are common and may be caused by a variety of thyroid disorders. While most are benign, about 5 percent of all palpable nodules are malignant². It is crucial to reduce the number of unnecessary operations for thyroid disease. But to achieve this, an accurate diagnosis must be made⁴. Although thyroid function tests, scintigraphy and ultrasonography are used routinely for diagnostic purposes in cases of thyroid nodules, the discrimination between benign and malignant nodules cannot be made correctly with these tests. FNAC has been found to be insufficient for thyroid

nodules in the discrimination between benign and malignant follicular lesions because by this technique it is not able to demonstrate vascular and capsular invasion, which is the hallmark of follicular carcinoma. Although we can take pride in success of FNAC of most thyroid lesions imprint cytology can provide a useful adjunct to the frozen section diagnosis and may be used safely in the diagnosis of thyroid nodules, especially in the cases when frozen section cannot be performed. Examination of frozen section has been the standard method of rapid diagnosis for thyroid lesions for many years. The advent of refrigerated microtome is now giving high diagnostic accuracy, albeit, there are some pitfalls of this method. However, facilities for frozen sections are not always available in most of the hospitals in our country and in these circumstances a surgeon may have to proceed to thyroidectomy relying on the clinical findings and FNAC results⁵. Mutaharra et al (2001) studied the role of imprint cytology and frozen section for rapid intraoperative diagnosis of thyroid swellings by comparing the two procedures. The overall accuracy they obtained in both the techniques was 96% with one false negative result in imprint cytology and one false

1. Dr. Sukumar Saha Department of pathology, Khulna Medical College, Khulna.

2. Prof. AJE Nahar Rahman, Chairman, Department of Pathology, BSMMU, Dhaka.

Bangladesh J Pathol 24 (1) : 2009

Sukumar Saha, AJE Nahar Rahman

Bangladesh J Pathol 24 (1) : 13

positive result for malignancy in case of frozen section. It is observed that the study of imprints can significantly improve rapid intraoperative diagnosis and can replace more expensive method of frozen section⁵.

Methods and materials

It was a prospective type of study conducted during January, 2004 to June, 2006 in the department of pathology, BSMMU, Dhaka, with the consecutive patients who underwent frozen section. A total of 57 patients were included in the study who consented to participate in the study. Imprint slides were prepared from the fresh specimen with thyroid lesions prior to submitting the tissue for frozen section preparation. Three to four imprint slides were made by gently pressing clean glass slides over the lesional areas of the submitted thyroid tissue. Immediately the slides were submerged in 95% ethanol in a koplun jar. The slides were stained with rapid H & E staining method. It took only 5 to 8 minutes to complete staining. In the meantime, frozen section slides were prepared using refrigerated microtome (Minotome plus, Triangle Bio-Medical Sciences, USA) and kept in Carnoy's fixative. These slides were also stained with rapid H & E staining method. Imprint cytology reports were obtained earlier to frozen sections reports were written in other forms. Both reports were made without knowing the results of each other to avoid the bias. Remnant tissue was processed in routine histological technique and H & E stained slides were made. Considering routine histological slides as "Gold standard" both the results of imprint cytology and frozen section were compared with routine histology results of imprint cytology and frozen section were compared with routine histopathology results. Diagnostic accuracy, sensitivity, specificity, positive predictive value and negative predictive value of both imprint cytology and frozen section were determined by comparing with final histological diagnosis using appropriate formulae. Indeterminate diagnosis of both imprint and frozen section and unsatisfactory imprints were excluded from the calculation.

Results

The ages of the patients were between 8 years and 70 years with a mean of 32.96 (SD ±3.27). Among 57 cases, imprint cytology diagnosed 16 (9.12%) cases as positive for malignancy, 14 cases of these were histologically confirmed as malignant. So, in imprint cytology 14 (87.50%) cases were true positive and 2 (12.5%) cases were false positive. Imprint cytology revealed 32 (18.24%) cases as

negative for malignancy, 25 cases of these were histologically confirmed as benign lesion. Hence, 25 (78.12%) cases were true negative and 7 (21.87%) cases were false negative. Of the remaining 9 cases 7 (12.28%) cases were indeterminate and 2 (3.50%) cases were unsatisfactory for evaluation (Table 1).

Table - 1

Imprint and frozen section diagnosis confirmed by routine histological diagnosis to find out true positive, true negative, false positive and false negative diagnosis of both imprint cytology and frozen section.

Confirmed	Historically True		False	
	Positive	Negative	Positive	Negative
Imprint cytology (n=16)	14	14	2	0
Frozen section (n=16)	16	16	0	0
Imprint cytology (n=32)	25	25	7	0
Frozen section (n=36)	30	30	6	0

Frozen section diagnosed 16 (9.12%) case as positive for malignancy and all the cases were histologically confirmed as malignant. So, in frozen section 16 (100%) case were true positive with no false positive diagnosis. Frozen section revealed 36 (20.52%) cases as negative for malignancy, among these 30 (83.33%) cases were confirmed histologically as benign lesion. So, 30 (83.33%) cases were true negative and 6 (16.66%) cases false negative diagnosis (Table 1).

Diagnostic accuracy, sensitivity, specificity, positive predictive value and negative predictive value of imprint were 81.25%, 66.66%, 92.59%, 87.50% and 78.12% respectively. Diagnostic accuracy, sensitivity, positive predictive value and negative predictive value of frozen section were determined as 88.46%, 72.72%, 100%, 100% and 83.33%.

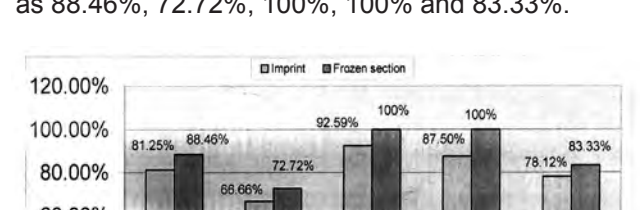


Figure 1: Bar diagram showing diagnostic accuracy, sensitivity, specificity, positive and negative predictive values of imprint and frozen section in the intraoperative diagnosis and thyroid lesions.

Bangladesh J Pathol 24 (1) : 2009

Sukumar Saha, AJE Nahar Rahman

Bangladesh J Pathol 24 (1) : 14

Discussion

Thyroid nodule is a common disorder, and most of them are benign. As thyroid nodules rarely prove to be fatal, it is necessary to reduce the number of operation performed. For this purpose, an accurate diagnosis must be made³. Although thyroid function test, scintigraphy and ultrasonography are routinely used for diagnosis and purposes in thyroid nodules, the discrimination between benign and malignant nodule cannot be made exactly with these tests. At present, preoperative FNA, intraoperative imprint cytology and frozen section are used for the diagnosis and management of thyroid nodules. Taneri et al (2001) have evaluated the role of imprint cytology as a rapid intraoperative diagnostic procedure as an alternative to frozen section. They have observed promising implications and suggested this procedure for the small hospitals where frozen section facilities are not available⁴.

Present study was undertaken to demonstrate the value of imprint cytology in the intraoperative diagnosis of thyroid lesions and to compare diagnostic accuracy, sensitivity, specificity, positive predictive value and negative predictive value between imprint cytology and frozen section.

A total of 57 cases were included in this study. All of the cases were sent for frozen section from the departments of Surgery and Otolaryngology, BSMMU to the department of pathology, BSMMU. In all cases imprint cytology examination and frozen section examination were performed separately. Results of these examinations were compare with those of final histological diagnosis of lesions area of remaining tissue.

In the present study, it was found that 75.43% patients with thyroid lesions were between the ages of 21 to 50 years and peak incidence was in the third decade. The median age of the patients of the study population was 32.96 (13 27) years and male-female ratio was 1:5.33. The study of Francis and Das (1999) showed that the mean age of their study population was 37 years with a male-female ratio of 1:10.25. Our study showed nearly similar mean age and male-female ratio.

In this study, diagnostic accuracy, sensitivity, specificity, positive predictive value and negative predictive value between imprint cytology and frozen section were determined comparing with final histological diagnosis. Diagnostic accuracy, sensitivity and specificity of imprint cytology 81.25%, 66.66% and 92.59% respectively. Positive predictive value and negative predictive value of imprint

cytology were determined as 87.50% and 78.12% respectively. Diagnostic accuracy, sensitivity, specificity, positive predictive value and negative predictive value between imprint cytology and frozen section were 88.46%, 72.72%, 100%, 100% and 83.33% respectively. It is evident from these results that diagnostic accuracy of imprint cytology is close to that of frozen section our study. Both imprint cytology and frozen section revealed high specificity of 92.59% and 100% respectively. So, specificity of imprint cytology and frozen section in the study is also comparable. However, sensitivity of both imprint and frozen section was relatively low in our study. Presumable the causes of lower sensitivity diagnosis in both procedures in the present study. Indeterminate diagnoses of both imprint cytology and frozen section were excluded from calculation of diagnostic accuracy, sensitivity, specificity, positive predictive value and negative predictive value. Present study showed lower positive predictive value of imprint cytology than frozen section (87.50% vs 100%) but negative predictive value of imprint cytology was close to that of frozen section. Several recent studies also have shown high diagnostic accuracy, sensitivity and specificity of imprint cytology.

Table - 2

Diagnostic accuracy, sensitivity, specificity and specificity of imprint cytology in different studies.

Study	Diagnostic Accuracy		Sensitivity		Specificity	
	Accuracy	Sensitivity	Specificity	Accuracy	Sensitivity	Specificity
Taneri F et al (2001) ⁵	96%	83.3%	97.7%	96%	84.0%	93.07%
Mutaharra et al (2001) ¹	96%	83.3%	97.7%	96%	84.0%	93.07%
Tworek et al (1998) ⁷	82.55%	94.11%	71%	82.55%	94.11%	71%
Francis and Das (1999) ⁸	71.15%	85.0%	100%	71.15%	85.0%	100%

Our study revealed diagnostic accuracy of imprint cytology as 81.25%, which was lower than that found in the studies of Taneri F et al (2001) and Mutaharra et al (2001). But diagnostic accuracy of the present study is higher than that of Francis and Das (1999) and close to that of Tworek et al (1998)⁶. Sensitivity of imprint cytology (66.66%) is low in present study. Sensitivity of imprint cytology in the studies of Tworek et al (1998) and Taneri F et al (2001) were 82.55% and 96% respectively. The specificity of imprint cytology in the present study is 92.59%, which is very close to that of the studies of Taneri F et al (2001), Mutaharra et al (2001) and Francis and Das (1999). But specificity of imprint cytology is much higher than that of the study to Tworek et al (1998). Positive predictive value and negative predictive values of imprint cytology of current study are 87.50% and 78.12% respectively.

Bangladesh J Pathol 24 (1) : 2009

Sukumar Saha, AJE Nahar Rahman

Bangladesh J Pathol 24 (1) : 15

Taneri F et al ((2001) found positive and negative values as 83.3% and 97.7% respectively. So, positive predictive value in our study is little higher than that of Taneri et al (2001), but negative predictive value is lower in our study.

Diagnostic accuracy, sensitivity and specificity of frozen section in our study were 88.46%, 72.72% and 100%. It is evident that diagnostic accuracy of frozen section of present study is close to those of Brooks et al (2001)⁸ and Francis and Das (1999)⁷.

But Cetin B (2004) showed higher diagnostic accuracy of 97.8% than that of our study⁹. But sensitivity of frozen section in our study was little lower than that found in the studies of Brooks et al (2001) and Cetin B (2004). In our study, frozen section showed very high specificity and positive predictive value of 100% and 100% respectively. Brooks et al (2001) found positive predictive value as 95% and negative predictive as 88%.

Imprint cytology showed quite high diagnostic accuracy rate but sensitivity was relatively low⁹. However, specificity was high. It showed good positive and negative predictive value. Frozen section showed high diagnostic accuracy rate but sensitivity was relatively lower. It pointed out very high specificity and positive predictive value, although, negative predictive value was little lower. Therefore, in our study, imprint cytology was found to be comparable with frozen section in diagnostic accuracy and sensitivity. Imprint cytology, although, has not been proved to be superior to frozen section in the intraoperative diagnosis of thyroid lesions. For the correct diagnosis of pathological nature of the thyroid lesions frozen section requires more intraoperative time and is more expensive than imprint cytology. This technique is simple and cost effective and requires few equipments and chemicals. Thus in the light of the study we suggest that imprint cytology can provide a useful adjunct to frozen section. This procedure can be an acceptable alternative to frozen section in hospitals where frozen section facilities are not available.

References

- Livolsi V., Montone T., Scck M., 1999. "Thyroid disease" in Diagnostic surgical pathology, 3rd edition, Sternberg S., Antonioli, D., Carter D., Erdman H (eds). Lippincott Williams & Wilkins, Philadelphia. Vol-1. pp: 529-563.
- Welker M., Orlov D., 2003. Thyroid nodules. American Family Physician. 67 (3): 120-125.
- Ogawa Y., Kato Y., Lkeda K., Aya M., Ogisawa K., Kitani K., Onoda N., Ishikawa T., Haba T., Wakasa K., Hirakawa K., et al, 2001. The value of ultrasound-guided fine-needle aspiration cytology for thyroid nodules: an assessment of its potentials and pitfalls. Surg Today. 31 (2): 97-101.
- Taneri F., Poyraz A., Salman B., Tekin E., Onuk E., 2001. 'Using imprint and frozen section in determining strategies for thyroid pathologies.' Endocrine regulations. 35:71-75.
- Mutaharra H.A., Deva W., Wani K.A., Wani N.A., Shah A., Malik A.A., 2001. Imprint cytology versus frozen section in the intraoperative diagnosis of thyroid swellings, JK practitioner. 8 (1): 27-29.
- Tworek J.A., Giordano T.J., Michael C.W., 1998. Comparison of Intraoperative Cytology With Frozen Section in the Diagnosis of Thyroid lesions. Am J Clin Pathol. 110:456-461.
- Francis I., Das D., 1990. Role of Fine needle Aspiration, Intraoperative imprint cytology and Frozen section in the diagnosis of breast and thyroid lesions. Med Principles Pract. 8:173-182.]
- Brooks A.D., Shaha A.R., Dumornay W., Huvos A. G., Zakowski M., Brennan M.F., Shah J., 2001. Role of Fine -Needle Aspiration Cytology and Frozen Section in the Surgical Management of Thyroid Tumours. Annals of Surgical Otolaryngology. 8(2):92-100.
- Cetin B., Asian S., Hatiboglu C., Babacan B., Onder A., Celik A., Cetin A., 2001. Frozen Section in Thyroid Surgery: Is it a necessity?. Can J Surg. 47 (1) 29-33.

Bangladesh J Pathol 24 (1) : 2009