



**University of Dundee**

## **Complete or ultraconservative removal of decayed tissue in unfilled teeth**

Ricketts, David; Kidd, Edwina; Innes, Nicola P. T.; Clarkson, Jan E.

*Published in:*  
Cochrane Database of Systematic Reviews

*DOI:*  
[10.1002/14651858.CD003808.pub2](https://doi.org/10.1002/14651858.CD003808.pub2)

*Publication date:*  
2008

*Document Version*  
Publisher's PDF, also known as Version of record

[Link to publication in Discovery Research Portal](#)

*Citation for published version (APA):*  
Ricketts, D., Kidd, E., Innes, N. P. T., & Clarkson, J. E. (2008). Complete or ultraconservative removal of decayed tissue in unfilled teeth. *Cochrane Database of Systematic Reviews*, (4).  
<https://doi.org/10.1002/14651858.CD003808.pub2>

### **General rights**

Copyright and moral rights for the publications made accessible in Discovery Research Portal are retained by the authors and/or other copyright owners and it is a condition of accessing publications that users recognise and abide by the legal requirements associated with these rights.

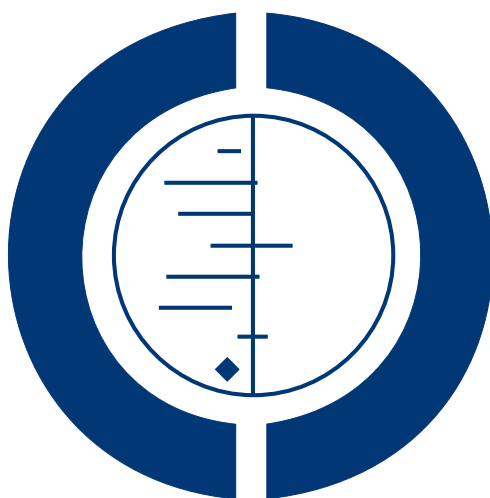- Users may download and print one copy of any publication from Discovery Research Portal for the purpose of private study or research.
- You may not further distribute the material or use it for any profit-making activity or commercial gain.
- You may freely distribute the URL identifying the publication in the public portal.

### **Take down policy**

If you believe that this document breaches copyright please contact us providing details, and we will remove access to the work immediately and investigate your claim.

# Complete or ultraconservative removal of decayed tissue in unfilled teeth (Review)

Ricketts D, Kidd E, Innes NPT, Clarkson JE



**THE COCHRANE  
COLLABORATION®**

This is a reprint of a Cochrane review, prepared and maintained by The Cochrane Collaboration and published in *The Cochrane Library* 2008, Issue 4

<http://www.thecochranelibrary.com>



---

Complete or ultraconservative removal of decayed tissue in unfilled teeth (Review)  
Copyright © 2008 The Cochrane Collaboration. Published by John Wiley & Sons, Ltd.

## TABLE OF CONTENTS

HEADER . . . . .	1
ABSTRACT . . . . .	1
PLAIN LANGUAGE SUMMARY . . . . .	2
BACKGROUND . . . . .	2
OBJECTIVES . . . . .	2
METHODS . . . . .	3
RESULTS . . . . .	4
DISCUSSION . . . . .	5
AUTHORS' CONCLUSIONS . . . . .	6
ACKNOWLEDGEMENTS . . . . .	7
REFERENCES . . . . .	7
CHARACTERISTICS OF STUDIES . . . . .	9
DATA AND ANALYSES . . . . .	15
Analysis 1.1. Comparison 1 Partial decay removal versus complete removal, Outcome 1 Pulpal exposure. . . . .	15
Analysis 1.2. Comparison 1 Partial decay removal versus complete removal, Outcome 2 Signs and symptoms of pulpal pathology at 1 year follow up. . . . .	16
APPENDICES . . . . .	16
WHAT'S NEW . . . . .	17
HISTORY . . . . .	17
CONTRIBUTIONS OF AUTHORS . . . . .	17
DECLARATIONS OF INTEREST . . . . .	18
SOURCES OF SUPPORT . . . . .	18
INDEX TERMS . . . . .	18

[Intervention Review]

## Complete or ultraconservative removal of decayed tissue in unfilled teeth

David Ricketts<sup>1</sup>, Edwina Kidd<sup>2</sup>, Nicola P T Innes<sup>3</sup>, Jan E Clarkson<sup>4</sup>

<sup>1</sup>Restorative Dentistry, Dundee Dental Hospital and School, Dundee, UK. <sup>2</sup>Department of Conservative Dentistry, King's College London, Surbiton, UK. <sup>3</sup>Unit of Dental and Oral Health, Dundee Dental Hospital and School, Dundee, UK. <sup>4</sup>Dental Health Services Research Unit, University of Dundee, Dundee, UK

Contact address: David Ricketts, Restorative Dentistry, Dundee Dental Hospital and School, Park Place, Dundee, Tayside, DD1 4HN, UK. [d.n.j.ricketts@dundee.ac.uk](mailto:d.n.j.ricketts@dundee.ac.uk).

**Editorial group:** Cochrane Oral Health Group.

**Publication status and date:** Edited (no change to conclusions), published in Issue 4, 2008.

**Review content assessed as up-to-date:** 22 May 2006.

**Citation:** Ricketts D, Kidd E, Innes NPT, Clarkson JE. Complete or ultraconservative removal of decayed tissue in unfilled teeth. *Cochrane Database of Systematic Reviews* 2006, Issue 3. Art. No.: CD003808. DOI: 10.1002/14651858.CD003808.pub2.

Copyright © 2008 The Cochrane Collaboration. Published by John Wiley & Sons, Ltd.

### ABSTRACT

#### Background

The treatment of deep dental decay has traditionally involved removal of all the soft demineralised dentine before a filling is placed. However this has been challenged in three groups of studies which involve sealing soft caries into the tooth. The three main groups either remove no caries and seal the decay into the tooth, remove minimal (ultraconservative) caries at the entrance to a cavity and seal the remaining caries in, or remove caries in stages over two visits some months apart to allow the pulp time to lay down reparative dentine (the stepwise excavation technique).

#### Objectives

To test the null hypothesis of no difference in the incidence of damage or disease of the nerve of the tooth (pulp), progression of decay and longevity of restorations irrespective of whether the removal of decay had been minimal (ultraconservative) or complete.

#### Search methods

The Cochrane Oral Health Group Trials Register, Cochrane Central Register of Controlled Trials (CENTRAL), MEDLINE, PubMed and EMBASE databases were searched. The reference lists in relevant papers were checked.

#### Selection criteria

Randomised controlled trials and controlled clinical trials comparing minimal (ultraconservative) caries removal with complete caries removal in unrestored permanent and deciduous teeth.

#### Data collection and analysis

Outcome measures recorded were exposure of the nerve of the tooth (pulp) during caries removal, patient experience of symptoms of pulpal inflammation or necrosis, progression of caries under the filling, time until the filling was lost or replaced. Due to the heterogeneity of the included studies the overall estimate of effect was calculated using a random-effects model.

## Main results

Four studies met the inclusion criteria; two stepwise excavation studies and two ultraconservative caries removal studies. Partial caries removal in symptomless, primary or permanent teeth reduces the risk of pulp exposure. We found no detriment to the patient in terms of pulpal symptoms in this procedure and no reported premature loss or deterioration of the restoration.

## Authors' conclusions

The results of this systematic review reject the null hypothesis of no difference in the incidence of damage or disease of the nerve of the tooth (pulp) irrespective of whether the removal of decay had been minimal (ultraconservative) or complete and accepts the null hypothesis of no difference in the progression of decay and longevity of restorations. However, the number of included studies is small and differ considerably.

Partial caries removal is therefore preferable to complete caries removal in the deep lesion, in order to reduce the risk of carious exposure. However, there is insufficient evidence to know whether it is necessary to re-enter and excavate further but studies that have not re-entered do not report adverse consequences.

## PLAIN LANGUAGE SUMMARY

### Complete or ultraconservative removal of decayed tissue in unfilled teeth

A systematic review of the literature revealed four studies comparing complete and minimal (ultraconservative) caries removal. It was found that partial caries removal in symptomless, primary or permanent teeth reduces the risk of pulp exposure. We found no detriment to the patient in terms of pulpal symptoms in this procedure. Therefore, partial caries removal is preferable to complete caries removal in the deep lesion, in order to reduce the risk of carious exposure. However, there is insufficient evidence to know whether it is necessary to re-enter and excavate further but studies that have not re-entered do not report adverse consequences.

## BACKGROUND

Dental decay (caries) is the most commonly occurring dental disease and its treatment has high cost implications. The treatment of dental decay classically involves removal of soft demineralised dentine before placing a filling (restoration). This tissue is heavily infected with bacteria and is removed using a drill or sharp spoon like instruments (excavators), in order to stop the decay (cariou) process (Kidd 1998). There is uncertainty whether this is necessary.

This type of treatment has been accepted and practiced for generations by dentists but this has recently been challenged by three groups of experiments (Kidd 2000). In these experiments the removal of caries was either minimal or non-existent and it appeared there were no adverse clinical consequences. The changes from the conventional type of treatment were as follows:

(1) Decay (soft infected dentine) was covered by a filling material that sealed it into the tooth (Handelman 1991)

(2) Minimal (ultraconservative) decay was removed and a permanent filling placed (Mertz-Fairhurst 1998)

(3) Minimal (ultraconservative) caries removal and placement of a filling out of a temporary restorative material. After a few weeks the temporary filling was removed, all the remaining decay removed, and a permanent filling placed (Bjørndal 1997).

The literature has concentrated on evidence of caries lesion progression and levels of infection of the decayed dentine. However, health of the nerve of the tooth (dental pulp) and the life span of the restoration is also an important issue. At the present time there is considerable variation in clinical practice and teaching. Therefore there is a need to systematically review the literature on complete and ultraconservative caries removal.

## OBJECTIVES

To test the null hypothesis that there is no difference between minimal (ultraconservative) or complete caries removal for the following: damage or disease of the nerve (pulp); progression of decay; or longevity of restorations.

## METHODS

### Criteria for considering studies for this review

#### Types of studies

Randomised controlled trials (RCTs), and controlled clinical trials (CCTs) including quasi-randomised, that compare minimal (ultraconservative) with complete caries removal prior to restoration.

#### Types of participants

Any patient with untreated primary decay that required a filling. Permanent and deciduous teeth were considered separately. Only teeth with no existing fillings were considered, in order that the dental pulps were not compromised by previous treatment.

#### Types of interventions

Minimal (ultraconservative), compared with complete caries removal prior to restoration.

#### Types of outcome measures

Primary outcomes:

- Exposure of the nerve of the tooth (pulp) during caries removal
- Patient experience of symptoms of pulpal inflammation or necrosis
- Progression of caries under the filling
- Time until the filling is lost or replaced.

#### Search methods for identification of studies

For the identification of studies included or considered for this review, detailed search strategies were developed for each database searched. This was based on the search strategy developed for MEDLINE but revised appropriately for each database. The search strategy combined the subject search with phases 1 and 2 of the Cochrane Sensitive Search Strategy for Randomised Controlled Trials (RCTs) (as published in Appendix 5b.2 in the *Cochrane Handbook for Systematic Reviews of Interventions* 4.2.5). The subject search used a combination of controlled vocabulary and free text terms based on the search strategy for searching MEDLINE (Appendix 1).

The following databases were searched (up to May 2006):

Cochrane Oral Health Group Trials Register

Cochrane Central Register of Controlled Trials (CENTRAL) (*The Cochrane Library* 2006, Issue 2)

MEDLINE (from 1966)

PubMed (from 1966)

EMBASE (from 1980).

The need for further searching of key dental journals was determined by estimating the probable yield of handsearching from the results of the electronic searching. Further handsearching was not considered necessary. The search was not limited by language and any non-English published trials considered to be relevant were translated.

First authors of included studies were not contacted as one was deceased and there was sufficient information in the other three papers for this review.

The references quoted in the included studies were screened for any further trials.

#### Data collection and analysis

The three review authors independently identified eligible papers and extracted data from them. The included studies results were compared and disagreements resolved with discussion. Data extraction was carried out on specially designed forms and review author were not blinded to the journal title or authors.

The date that the study was conducted, the country, the year of publication, treatments, outcomes, sample size and age of subjects were recorded. The number recruited and details of withdrawals by study group were also recorded.

The outcome measures were: exposure of the nerve of the tooth (pulp) during caries removal; the patients' experience of symptoms due to irreversible pulpal inflammation or necrosis; the progression of caries from clinical or radiographic examination; time until the restoration was lost or replaced. These outcomes were recorded for all time points mentioned in the study report.

Favourable outcome measures were considered to be.

(1) Immediate. No pulpal exposure during treatment.

(2) Short term (0 to 4 months). No symptoms of irreversible pulpitis such as spontaneous pain, hypersensitivity to hot and cold lasting longer than 1 minute or tenderness to pressure or both.

(3) Medium term (4 to 12 months). As for short term but additionally, signs of pulpal necrosis such as abscess formation and radiographic evidence of periradicular bone loss and retention of restoration.

(4) Long term (> 12 months). As for medium term.

For outcomes which were reported for time periods greater than 1 year, appropriate subsequent time points were determined for analyses. Other reported outcomes were recorded for descriptive purposes.

The number of studies eligible for inclusion were recorded. The results of the randomised controlled trials (RCTs) and controlled clinical trials (CCTs) were analysed using RevMan and reported according to Cochrane Collaboration criteria.

#### Quality assessment

The quality assessment of included trials was undertaken independently in duplicate by two review authors as part of the data extraction process and in accordance with the guidelines in the *Cochrane Handbook for Systematic Reviews of Interventions* 4.2.5. Any disagreements were resolved by discussion.

The following were included in the quality assessment:

Randomisation procedure and allocation concealment was recorded as (A) adequate, (B) unclear, (C) inadequate, or (D) not used (as described in the *Cochrane Handbook for Systematic Reviews of Interventions*). Further quality assessment was carried out to assess blinding of outcome assessment, completeness of follow up (clear explanations for withdrawals, drop outs, and protocol deviations in intervention and control groups), and intention-to-treat analysis. Definition of inclusion/exclusion criteria and comparability of intervention and control groups at entry also formed part of the quality assessment. The quality assessment criteria were pilot tested using several articles.

After taking into account any additional information provided by the authors of the trials, studies were grouped into the following categories:

(A) Low risk of bias (plausible bias unlikely to seriously affect the results) if all criteria were met.

(B) Moderate risk of bias (plausible bias which raises some doubt about the validity of the results) if one or more of the criteria were partly met (for instance, if authors respond that some attempt had been made to conceal the allocation of patients, to blind assessors, or to give explanations for withdrawals but these attempts were not judged to be ideal, these criteria were categorised as 'partly met').

(C) High risk of bias (plausible bias which seriously weakens confidence in the results) if one or more criteria were not met.

## Data synthesis

### Heterogeneity

The significance of discrepancies in the estimates of the treatment effects from the different trials was assessed by means of Cochran's test for heterogeneity ( $P < 0.1$ ). The overall estimate of effect was calculated using a random-effects model.

### Choice of summary statistic and estimate of overall effect

The Cochrane Collaboration statistical guidelines were followed and risk ratios calculated along with 95% confidence intervals.

## RESULTS

### Description of studies

See: [Characteristics of included studies](#); [Characteristics of excluded studies](#).

From the search strategy, only four papers were suitable for inclusion (Leksell 1996; Magnusson 1977; Mertz-Fairhurst 1987; Ribeiro 1999). All of these, were randomised controlled clinical trials. One study was carried out in America (Mertz-Fairhurst 1987), one in Brazil (Ribeiro 1999) and two in Sweden (Leksell 1996; Magnusson 1977). The trials were published in four reports between 1977 and 1999 and were all single centre studies. One study was government funded (Mertz-Fairhurst 1987) and funding for the remaining studies was unclear. The percentage of teeth lost to follow up ranged from 0% to 19%. Two studies reported no drop outs.

### Characteristics of the participants

Two of the trials were on deciduous teeth (Magnusson 1977; Ribeiro 1999) where participants' ages ranged from 5 to 10 and 7 to 11 respectively. The remaining two trials were carried out on permanent teeth (Leksell 1996; Mertz-Fairhurst 1987). The ages of the subjects were 6 to 16 and 8 to 52 years respectively. Three of the studies were parallel group studies (Leksell 1996; Magnusson 1977; Ribeiro 1999) and one was of split-mouth design (Mertz-Fairhurst 1987). The method and level of randomisation varied. For instance in the study by Magnusson 1977, randomisation was at the patient level and many of the patients had more than one tooth entered into the study. This study was not truly randomised but can be regarded as quasi-allocation as the patients date of birth (odd/even day within the month) was used for allocation to test or control group. In contrast, in Leksell 1996, randomisation was at the level of the tooth and again some patients had more than one tooth treated.

### Characteristics of the intervention

Each trial involved control and treatment groups, with complete caries removal in control groups and partial caries removal in treatment groups. However, what constituted 'partial caries removal' varied greatly from trial to trial. Leksell 1996 stepwise excavation study removed most of the carious dentine in the treatment group, applied calcium hydroxide and restored with zinc oxide-eugenol and planned re-entry within 8 to 24 weeks. Magnusson 1977 also carried out a stepwise excavation study but here, caries removal in the treatment group was described as "partial". The restorative materials were again calcium hydroxide then zinc oxide-eugenol, with planned re-entry 4 to 6 weeks later. The Ribeiro 1999 study removed much less carious tissue, restored teeth with composite and did not re-enter. Mertz-Fairhurst 1987 removed very little caries in the treatment group, not even clearing the enamel-dentine junction. Teeth in the treatment group were restored with composite and the teeth in the control (complete caries removal groups) restored with amalgam. Data from the last three studies

were extracted at 1 year. Whilst the study by [Mertz-Fairhurst 1987](#) only investigated occlusal (Class I) lesions, [Ribeiro 1999](#) looked at equal numbers of occlusal and occlusal-approximal (Class II) lesions. The illustrations, examples and descriptions presented by [Magnusson 1977](#) and [Leksell 1996](#) would suggest only occlusal lesions were investigated, however, this is not confirmed from the text.

### Characteristics of the outcome measures

Two studies used pulp exposure during caries removal as an outcome measure ([Leksell 1996](#); [Magnusson 1977](#)). Three studies also noted signs and symptoms of pulpal pathology ([Magnusson 1977](#); [Mertz-Fairhurst 1987](#); [Ribeiro 1999](#)). The major thrust of two studies ([Mertz-Fairhurst 1987](#); [Ribeiro 1999](#)) was the longevity of the restorations.

### Risk of bias in included studies

The concealment of allocation was unclear for all of the included trials. The outcome assessor could not be blinded as to whether an exposure was present in the two stepwise excavation studies ([Leksell 1996](#); [Magnusson 1977](#)) as the assessor would also be the operator. Similarly, in the [Ribeiro 1999](#) study, it was unlikely that the assessor was blinded, although assessment was at a later time, as this was the same operator who had carried out the procedure and assessment. In the [Mertz-Fairhurst 1987](#) study, outcome assessor could not be blinded because treatment and control groups were restored with different materials. The numbers of withdrawals were adequately reported in all trials although the reasons for withdrawal were not given.

### Effects of interventions

The electronic searches identified 529 titles and abstracts and from this, we obtained 49 full reports. Four trials were considered eligible according to the defined criteria for trial design, participants, interventions and outcomes. Forty-five trials were excluded for the following reasons: no control, the ART technique compared to conventional caries removal where we judged the ART technique to constitute complete caries removal and trials where the fissure sealant was placed over caries without any tooth preparation by comparison to conventional caries removal.

Of the four trials included in the review, 339 patients (604 teeth) were recruited into the trials and, of these, 538 teeth were available for analysis at the end of the studies.

The outcome measures where results could be obtained were: exposure of the nerve of the tooth during caries removal; patient experience regarding pulpal inflammation or necrosis; time until the filling was lost or replaced.

### Exposure of nerve of the tooth during caries removal (Comparison 1; Outcome 1.1)

This could be judged in the two stepwise excavation studies ([Leksell 1996](#); [Magnusson 1977](#)). The incidence of pulpal exposure during complete caries removal in [Leksell 1996](#) was 28 out of 70 teeth (40%) but none were exposed during initial excavation in the treatment group. On re-entry to the treatment group, 10 out of 57 teeth (17.5%) suffered pulpal exposure. In the [Magnusson 1977](#) study, the incidence of pulpal exposure during complete caries removal was 29 out of 55 teeth (53%). In the treatment group none were exposed during the initial excavation but on re-entry 8 out of 55 teeth (15%) were exposed. Both of these studies were parallel group studies with one or more teeth chosen per patient, as such clustering is a potential problem which was not taken into account in either study. However, in the former study ([Leksell 1996](#)) 116 patients were recruited with 127 teeth and as such there will be little clustering of data and is unlikely to change the 95% confidence interval (CI) significantly. In the latter study ([Magnusson 1977](#)) there were 62 children recruited with 110 teeth included, again whilst clustering was not taken into account, it is unlikely to be of major importance, simply making the 95% CI larger than it is. From these two studies the meta-analysis shows that the risk ratios of pulpal exposure for partial caries removal after the first excavation is 0.02, a 98% reduction in risk compared with complete caries removal (95% CI 0.00 to 0.13). Similarly, after the second excavation the risk ratio of pulpal exposure is 0.35, a 65% reduction in risk compared with complete caries removal (95% CI 0.22 to 0.56).

### Patient experience regarding pulpal inflammation or necrosis (Comparison 1; Outcome 1.2)

In the [Leksell 1996](#) study, symptoms of pulpal inflammation or necrosis were only reported in those teeth with no pulpal exposure and cannot be included in any analysis, however, there were no symptoms at 1 year for both the control and the treatment groups. In the [Magnusson 1977](#) study, 2 out of 55 teeth (4%) with partial caries removal gave symptoms of pulpitis. Pulpal necrosis was reported in three control and one treatment tooth. In the [Mertz-Fairhurst 1987](#) study, there was no incidence of pulpal inflammation or necrosis in either the control or the treatment groups. In the [Ribeiro 1999](#) study, one control tooth was reported with pulpal necrosis.

### Time until the filling is lost or replaced

Only the [Mertz-Fairhurst 1987](#) study investigated this. No restorations were lost or replaced in the first 2 years of the study.

## DISCUSSION



In theory, sealing in caries and associated bacteria into a cavity with a restoration that provides a good peripheral seal, deprives the organisms of sugar substrate from the oral cavity. As such, the bacteria reduce in numbers (Handelman 1976) and become less metabolically and the decay arrests. This allows time for the pulp dentine complex to lay down reparative dentine reducing the risk of pulpal exposure when re-entered at a second visit to allow the remaining decay to be removed.

We found evidence for the value of stepwise excavation as opposed to complete caries removal in the management of deep carious lesions in order to reduce the chance of pulpal exposure of both deciduous and permanent teeth during treatment. Although in the protocol we intended to separate the results from deciduous and permanent teeth, we decided not to do this as it was not relevant to the outcome. We found no evidence that partial caries removal is deleterious in terms of signs and symptoms of pulpitis or necrosis in the immediate to long term. Only one of the four studies investigated the failure of restorations if caries was left. There were no failures in either the complete caries removal or the ultraconservative caries removal groups. It should be noted that papers investigating the long-term outcome of partial caries removal have used composite resin as the restorative material.

Only four randomised controlled clinical trials were available for inclusion in this review. One further trial (Fitzgerald 1991) concerned partial and complete caries removal and was randomised as to the medicament used prior to tooth restoration. Unfortunately, this study was not randomised at baseline allocation into complete or partial caries removal. The partial caries removal group was selected on the basis of a radiographic finding that the tooth was likely to be exposed if fully excavated. Despite not being able to include this study, it is of interest that none of the teeth with incomplete caries removal was exposed but 38 out of 101 (38%) teeth with complete caries removal (where no exposure was anticipated) were, in fact, exposed.

Of the included studies, the method of randomisation was unclear in three (Leksell 1996; Mertz-Fairhurst 1987; Ribeiro 1999) and quasi-randomised in one (Magnusson 1977) which used even and odd dates of birth for allocation.

The lesions in the Mertz-Fairhurst 1987 study were only 1/2 way through dentine on radiograph whereas the lesions on all the other studies were all deep enough to be judged clinically to result in pulpal exposure during caries removal. Each study was noted that teeth included had no clinical or radiographic signs of pulpal or periradicular pathology. The medicaments used in the studies varied and there were insufficient data to draw conclusions about the respective benefits of calcium hydroxide, zinc oxide-eugenol or bonded composite.

Ideally in a clinical trial the patient, the operator and the assessor should all be blind as to any treatment/intervention. However, this conventional blinding was not possible in these studies. The

operator knew whether caries removal was partial or complete and certainly knew whether an exposure was present. The operator was often the assessor and it must be assumed that this also precluded conventional blinding. However, a main outcome measure was symptoms of pulpitis or pulp necrosis and it seems unlikely that this would be affected by a lack of assessor blinding. In the Mertz-Fairhurst 1987 study, amalgam was used in control cavities and composite in the treatment group thus once again, blinding was not possible.

It was noticeable that the amount of caries removed in incomplete caries removal varied. It appeared that in the two stepwise caries excavation studies (Leksell 1996; Magnusson 1977) most of the soft dentine was removed. In contrast, in the Ribeiro 1999 study, the enamel-dentine junction was made caries-free but soft, wet dentine was left on the pulpal surface. The Mertz-Fairhurst 1987 study was unique in that the caries removal was indeed ultraconservative. A bevel was placed in sound occlusal enamel but soft, wet dentine was left both at the enamel-dentine junction and on the pulpal surface. The implication of these differences is that we do not know whether the amount of caries removal is relevant in terms of symptoms.

Studies of this nature are prone to patients failing to attend recall appointments - so called drop outs. This inevitably calls into question the validity of the results because it is not known whether these drop outs suffered symptoms, went to other dentists and were, in fact, failures. It appears that drop outs may have had a minimal effect on this review because there were none in two studies (Magnusson 1977; Ribeiro 1999), only 5% in Leksell 1996 and 19% in Mertz-Fairhurst 1987. In this latter study, a split-mouth study design was used, therefore no bias was introduced by drop outs. We selected 1-year data from this study in order to give some comparability with the studies by Leksell 1996 and Ribeiro 1999. However, Mertz-Fairhurst 1987 has reported the results of this work up to 10 years (Mertz-Fairhurst 1998), however, the outcomes presented focus on restoration integrity rather than clinically relevant outcomes.

## AUTHORS' CONCLUSIONS

### Implications for practice

Partial caries removal in symptomless, primary or permanent teeth reduces the risk of pulp exposure. We found no detriment to the patient in terms of pulpal symptoms in this procedure. Therefore, partial caries removal would appear to be preferable to complete caries removal in the deep lesion, in order to reduce the risk of carious exposure. Whilst there is insufficient evidence to know whether it is necessary to re-enter and excavate further in the stepwise excavation technique, the studies that did not re-enter, reported no adverse consequences (Mertz-Fairhurst 1987; Ribeiro 1999). This treatment decision may be influenced by whether the

lesion was a Class I, with all cavity margins in a low risk plaque stagnation areas or a Class II, where some margins will be in high risk plaque stagnation areas. However, with only four included studies with a high risk of bias, and differences in lesion severity, firm conclusions cannot be drawn and there is need for continued research in this field.

### Implications for research

There is a need for further randomised controlled clinical investigation of the need to remove demineralised tissue prior to restoring the tooth. This review found no evidence that incomplete caries removal is deleterious. In fact, the reverse is true as complete caries removal is more likely to result in carious exposure of the pulp. However, although a stepwise approach should be advocated in young patients that have teeth with large pulps, the need to re-enter the cavity must be questioned. This could be investigated by clinical studies involving long-term follow up of symptoms of pulpitis and pulp necrosis, radiographic evidence of caries progression, microbiological evidence of caries progression or arrest and longevity of restorations. It should be noted that the only long-term clinical trial (Mertz-Fairhurst 1987) concerned occlusal caries where caries had only extended to 1/2 way through den-

tine. There is a need to apply the methodology to deeper lesions, lesions affecting multiple tooth surfaces, lesions in compromised teeth that have had a history of restoration and re-restoration and to permanent as well as primary teeth. A major difficulty in this work will be finding stable populations.

There is scope for investigation of bonding of materials to soft, wet and infected dentine. In addition, very little histological work has been carried out although the obvious difficulty here is that the dentist and patients are unlikely to agree to its extraction. Perhaps primary teeth, which are naturally exfoliated are a solution to this problem.

### ACKNOWLEDGEMENTS

We wish to thank Sylvia Bickley (Cochrane Oral Health Group) for her assistance with literature searching, and Emma Tavender and Luisa Fernandez Mauleffinch (Cochrane Oral Health Group) for their help with the preparation of this review. A special thank you to the referees and Cochrane editors for their valuable comments.

### REFERENCES

#### References to studies included in this review

##### Leksell 1996 *{published data only}*

Leksell E, Ridell K, Cvek M, Mejare I. Pulp exposure after stepwise versus direct complete excavation of deep carious lesions in young posterior permanent teeth. *Endodontic Dental Traumatology* 1996;**12**:192–6.

##### Magnusson 1977 *{published data only}*

Magnusson BO, Sundell SO. Stepwise excavation of deep carious lesions in primary molars. *Journal of the Association of Dentistry for Children* 1977;**8**(2):36–40.

##### Mertz-Fairhurst 1987 *{published data only}*

Mertz-Fairhurst EJ, Call-Smith KM, Shuster GS, Williams JE, Davis QB, Smith CD, et al. Clinical performance of sealed composite restorations placed over caries compared with sealed and unsealed amalgam restorations. *Journal of the American Dental Association* 1987;**115**:689–94.

##### Ribeiro 1999 *{published data only}*

Ribeiro CCC, Baratieri LN, Perdigo J, Baratieri NMM, Ritter AV. A clinical, radiographic, and scanning electron microscopic evaluation of adhesive restorations on carious dentin in primary teeth. *Quintessence International* 1999;**30**:591–9.

#### References to studies excluded from this review

##### Allan 1969 *{published data only}*

Allan DN. The durability of conservative restorations. *British Dental Journal* 1969:172–7.

##### Anusavice 1987 *{published data only}*

Anusavice KJ, Kincheloe JE. Comparison of pain associated with mechanical and chemomechanical removal of caries. *Journal of Dental Research* 1987;**66**(11):1680–3.

##### Artaud 1989 *{published data only}*

Artaud C, Berdal A, Cuisinier-Gleizes P, Mattieu H. In vivo investigation of a cariostatic filling material (cermets) used in pediatric dentistry. *Caries Research* 1989;**23**:98–9 (Abs 26).

##### Azhdari 1979 *{published data only}*

Azhdari S, Sveen OB, Buonocore MG. Evaluation of a restorative preventive technique for localised occlusal caries. *Journal of Dental Research* 1979;**58**(Special Issue A):330 (Abs 952).

##### Bjorndal 1998 *{published data only}*

Bjorndal L, Thylstrup A. A practice-based study on stepwise excavation of deep carious lesions in permanent teeth: a 1-year follow-up study. *Community Dentistry and Oral Epidemiology* 1988;**26**:122–8.

##### Bjorndal 1999 *{published data only}*

Bjorndal L. A long-term follow-up study on stepwise excavation of deep carious lesions in permanent teeth. *Caries Research* 1999;**33**:314 (Abstract 98).

##### Chu 2002 *{published data only}*

Chu CH, Lo ECM, Lin HC. Effectiveness of silver diamine fluoride and sodium fluoride varnish in arresting dentin

- caries in Chinese pre-school children. *Journal of Dental Research* 2002;**81**(11):767–70.
- Feng 2002** *{published data only}*  
Feng XP, Cao HZ, Lo ECM. The cost-effectiveness of ART and resin sealing for caries prevention. *Journal of Dental Research* 2002;**81**(Special Issue (B)):B/221 (Abs 41).
- Fitzgerald 1991** *{published data only}*  
Fitzgerald M, Heys RJ. A clinical and histological evaluation of conservative pulpal therapy in human teeth. *Operative Dentistry* 1991;**16**:101–12.
- Florio 2001** *{published data only}*  
Florio FM, Periera AC, Meneghim MC, Ramacciato JC. Evaluation of non-invasive treatment applied to occlusal surfaces. *Journal of Dentistry for Children* 2001;**68**:326–31.
- Foley 2003** *{published data only}*  
Foley J, Blackwell A. In vivo cariostatic effect of black copper cement on carious dentine. *Caries Research* 2003;**37**:254–60.
- Gibson 1980** *{published data only}*  
Gibson GB, Richardson AS. Sticky fissure management. 30-month report. *Journal of Canadian Dental Association* 1980;**4**:255–8.
- Going 1976** *{published data only}*  
Going RE, Conti AJ, Haugh LD, Grainger DA. Two-year clinical evaluation of a pit and fissure sealant. Part II: caries initiation and progression. *Journal of the American Dental Association* 1976;**92**:578–85.
- Going 1978** *{published data only}*  
Going RE, Loesche WJ, Grainger DA, Syed SA. The viability of microorganisms in carious lesions five years after covering with a fissure sealant. *Journal of the American Dental Association* 1978;**97**:455–62.
- Hamilton 2002** *{published data only}*  
Hamilton JC, Dennison JB, Stoffers KW, Gregory WA, Welch KB. Early treatment of incipient carious lesions. A two-year clinical evaluation. *Journal of the American Dental Association* 2002;**133**(12):1643–51.
- Handelman 1976** *{published data only}*  
Handelman SL, Washburn F, Wopperer P. Two-year report of sealant effect on bacteria in dental caries. *Journal of the American Dental Association* 1976;**93**:967–70.
- Handelman 1981** *{published data only}*  
Handelman SL, Leverett DH, Solomon EC, Brenner CM. Use of adhesive sealants over occlusal carious lesions: radiographic evaluation. *Community Dentistry and Oral Epidemiology* 1981;**9**:256–9.
- Handelman 1987** *{published data only}*  
Handelman SL, Leverett DH, Espeland M, Curzon J. Retention of sealants over carious and sound tooth surfaces. *Community Dentistry and Oral Epidemiology* 1987;**15**:1–5.
- Handelman 1991** *{published data only}*  
Handelman SL. Therapeutic use of sealants for incipient or early carious lesions in children and young adults. *Proceedings of the Finnish Dental Society* 1991;**87**:463–75.
- Heinrich 1988** *{published data only}*  
Heinrich R, Kneist S. Microbiological-histological controlled treatment study for evaluation of efficacy of one step and stepwise excavation of deep caries lesions [Mikrobiologisch-histologisch kontrollierte therapiestudie zur effektivitätsbewertung der einzeitigen und schrittweisen caries-profunda-therapie]. *Stomatologie DDR* 1988;**38**(10):693–98.
- Jensen 1980** *{published data only}*  
Jensen OE, Handelman SL. Effect of an autopolymerising sealant on viability of microflora in occlusal dental caries. *Scandinavian Journal of Dental Research* 1980;**88**:382–8.
- Kreulen 1997** *{published data only}*  
Kreulen CM, de Soet JJ, Weerheijm KL, van Amerongen WE. In vivo cariostatic effect of resin modified glass ionomer cement and amalgam on dentine. *Caries Research* 1997;**31**:384–9.
- Leverett 1983** *{published data only}*  
Leverett DH, Handelman SL, Brenner CM, Iker HP. Use of sealants in the prevention and early treatment of carious lesions: cost analysis. *Journal of the American Dental Association* 1983;**106**:39–42.
- Louw 2002** *{published data only}*  
Louw AJ, Sarvan I, Chikte UME, Honkala E. One-year evaluation of atraumatic restorative treatment and minimum intervention techniques on primary teeth. *South African Dental Journal* 2002;**57**(9):366–71.
- Mandari 2001** *{published data only}*  
Mandari GJ, Truin GJ, van't Hof MA, Frencken JE. Effectiveness of three minimal intervention approaches for managing dental caries: survival of restorations after two years. *Caries Research* 2001;**35**:90–4.
- Mandari 2003** *{published data only}*  
Mandari GJ, Frencken JE, van't Hof MA. Six-year success rates of occlusal amalgam and glass-ionomer restorations placed using three minimal intervention approaches. *Caries Research* 2003;**37**:246–53.
- McDonald 1994** *{published data only}*  
Mc Donald SP, Sheiham A. A clinical comparison of non-traumatic methods of treating dental caries. *International Dental Journal* 1994;**44**:465–70.
- Mertz-Fairhurst 1979** *{published data only}*  
Mertz-Fairhurst EJ, Schuster GS, Williams JE, Fairhurst CW. Clinical progress of sealed and unsealed caries. Part 1: Depth changes and bacterial counts. *Journal of Prosthetic Dentistry* 1979;**42**(5):521–6.
- Mertz-Fairhurst 1986** *{published data only}*  
Mertz-Fairhurst EJ, Schuster GS, Fairhurst CW. Arresting caries by sealants: results of a clinical study. *Journal of the American Dental Association* 1986;**112**:194–7.
- Mertz-Fairhurst 1991** *{published data only}*  
Mertz-Fairhurst EJ, Williams JE, Pierce KL, Smith CD, Schuster GS, Mackert JR Jr, et al. Sealed restorations: 4-year results. *American Journal of Dentistry* 1991;**4**(1):43–9.

**Mertz-Fairhurst 1995** {published data only}

Mertz-Fairhurst E, Adair SM, Sams DR, Curtis JW Jr, Ergle JW, Hawkins KI, et al. Cariostatic and ultraconservative sealed restorations: nine-year results among children and adults. *Journal of Dentistry for Children* 1995;**62**:97–107.

**Mertz-Fairhurst 1998** {published data only}

Mertz-Fairhurst EJ, Curtis JR, Ergle JW, Rueggeberg FA, Adair S. Ultraconservative and cariostatic sealed restorations: results at year 10. *Journal of the American Dental Association* 1998;**129**:55–66.

**Mertz-Fairhurst 92a** {published data only}

Mertz-Fairhurst EJ, Smith CD, Williams JE, Sherrer JD, Mackert JR Jr, Richards EE, et al. Cariostatic and ultraconservative sealed restorations: six-year results. *Quintessence International* 1992;**23**(12):827–38.

**Mertz-Fairhurst 92b** {published data only}

Mertz-Fairhurst EJ, Richards EE, Williams JE, Smith CD, Mackert JR, Schuster GS, et al. Sealed restorations: 5-year results. *American Journal of Dentistry* 1992;**5**(1):5–10.

**Mertz-Fairhurst abst** {published data only}

Mertz-Fairhurst EJ, Newcomer AP, Call-Smith KM. Caries arrestment and prevention by sealed conservative filled resin restorations. *Journal of Dental Research* 1983;**62**(AADR abstracts):222 (Abs 478).

**Peters 2001** {published data only}

Peters MC, McLean ME, Briskie DM. Minimally invasive restorative treatments in a caries-prone population. *Journal of Dental Research* 2001;**80**(AADR abstracts):200 (Abs 1316).

**Qvist 1997** {published data only}

Qvist V, Laurberg L, Poulsen A, Teglers PT. Longevity and cariostatic effects of everyday conventional glass-ionomer and amalgam restorations in primary teeth: Three-year results. *Journal of Dental Research* 1997;**76**(7):1387–96.

**Rahimtoola 2000** {published data only}

Rahimtoola S, van Amerongen E, Maher R, Groen H. Pain related to different ways of minimal intervention in the treatment of small caries lesions. *Journal of Dentistry for Children* 2000;**67**:123–7.

**Rahimtoola 2002** {published data only}

Rahimtoola S, van Amerongen E. Comparison of two tooth-saving preparation techniques for one-surface cavities. *Journal of Dentistry for Children* 2002;**69**:16–26.

**Sveen 1978** {published data only}

Sveen OB, Buonocore MG, Azhdari S. Evaluation of a new restorative-preventive technique for localised occlusal caries. *Journal of Dental Research* 1978;**57**(Special Issue A):83 (Abs 33).

**Walls 1988** {published data only}

Walls AWG, Murray JJ, McCabe JF. The management of occlusal caries in permanent molars. A clinical trial

comparing a minimal composite restoration with an occlusal amalgam restoration. *British Dental Journal* 1988;**164**:288–92.

**Weerheijm 1992** {published data only}

Weerheijm KL, de Soet JJ, van Amerongen WE, de Graaff J. Sealing of occlusal hidden caries lesions: an alternative for curative treatment?. *Journal of Dentistry for Children* 1992;**59**(4):263–8.

**Weerheijm 1999** {published data only}

Weerheijm KL, Kreulen CM, de Soet JJ, Groen HJ, van Amerongen WE. Bacterial counts in carious dentine under restorations: 2-year in vivo effects. *Caries Research* 1999;**33**:130–4.

**Welbury 1990** {published data only}

Welbury RR, Walls AWG, Murray JJ, McCabe JF. The management of occlusal caries in permanent molars. A 5-year clinical trial comparing composite with an amalgam restoration. *British Dental Journal* 1990;**169**:361–6.

**Zanata 2000** {published data only}

Zanata RL, Navarro MF de L, Barbosa SH. Stepwise excavation using Fuji IX glass-ionomer in caries-active patients: 15 months evaluation. *Journal of Dental Research* 2000;**79**(5):1042 (Abs 304).

## Additional references

**Bjørndal 1997**

Bjørndal L, Larsen T, Thylstrup A. A clinical and microbiological study of deep carious lesions during stepwise excavation using long treatment intervals. *Caries Research* 1997;**31**:411–7.

**Handelman 1991**

Handelman S. Therapeutic use of sealants for incipient or early carious lesions in children and young adults. *Proceedings of the Finnish Dental Society* 1991;**87**:463–75.

**Kidd 1998**

Kidd EAM, Smith BGN, Pickard HM. *Pickard's Manual of Operative Dentistry*. 7th Edition. Oxford: Oxford University Press, 1998.

**Kidd 2000**

Kidd EAM. Caries removal and the pulpo-dentinal complex. *Dental Update* 2000;**27**(10):476–82.

**Kidd 2004**

Kidd EAM. How “clean” must a cavity be before restoration? . *Caries Research* 2004;**38**:305–13.

**Mertz-Fairhurst 1998**

Mertz-Fairhurst EJ, Curtis JW, Engle JW, Rueggeberg FA, Adair SM. Ultraconservative and cariostatic sealed restorations: results at year 10. *Journal of the American Dental Association* 1998;**129**:55–66.

\* Indicates the major publication for the study

## CHARACTERISTICS OF STUDIES

### Characteristics of included studies [ordered by study ID]

#### Leksell 1996

Methods	Randomised, parallel group study conducted in Sweden. Unclear whether patient blind. Provider and assessor not blind. Unclear information on reasons for withdrawal. Drop outs 5% of teeth
Participants	Young adults; permanent teeth. 116 eligible patients with 134 teeth; 127 teeth remained at the end of the study
Interventions	2 groups: complete caries removal versus stepwise excavation. Calcium hydroxide placed as base. Re-entry in stepwise group in 11 to 24 weeks. Duration 1 year
Outcomes	Pulp exposure. Symptoms of pulpal inflammation or pulp necrosis
Notes	High risk of bias (C).

#### *Risk of bias*

Item	Authors' judgement	Description
Allocation concealment?	Unclear	B - Unclear

#### Magnusson 1977

Methods	Randomised, parallel group study conducted in Sweden. Patient, provider and assessor not blind. Drop outs 0%
Participants	62 children aged 5 to 10 years with 110 deciduous molars or completed
Interventions	2 groups: complete caries removal versus stepwise excavation. Re-entry in stepwise group in 4 to 6 weeks. Duration 10 weeks
Outcomes	Pulp exposure. Symptoms of pulp inflammation or necrosis. Other outcomes: histology 3 teeth
Notes	Moderate risk of bias (B).

#### *Risk of bias*

Item	Authors' judgement	Description
Allocation concealment?	Unclear	B - Unclear

**Mertz-Fairhurst 1987**

Methods	Randomised, split-mouth study, conducted in USA. Patient, provider and assessor not blind. Unclear information on reason for withdrawal. Drop outs 19%
Participants	Adults with occlusal caries half way to pulp on radiograph. 753 patients screened to give 123 eligible patients with 312 teeth. 253 teeth available for follow up
Interventions	2 groups: complete caries removal versus untraconservative removal. Complete caries removal restored amalgam or sealed amalgam. Ultraconservative caries removal restored compisite. Duration 1 year
Outcomes	Loss/deterioration of filling. Other outcomes reported: integrity of sealant
Notes	Symptoms not reported. We assume no symptoms. Duration of 1 year chosen for consistency with other studies. 2-year data available. Further publications available giving data up to 10 years. High risk of bias (C)

***Risk of bias***

Item	Authors' judgement	Description
Allocation concealment?	Unclear	B - Unclear

**Ribeiro 1999**

Methods	Randomised, parallel study conducted in Brazil. Unclear whether patient blind. Operator and assessor not blind. Drop outs 0%
Participants	Child patients aged 7 to 11 years. 38 eligible patients with 48 carious deciduous molars. All available for follow up
Interventions	2 groups : complete caries removal versus ultraconservative removal. Teeth restored with composite. Duration 1 year
Outcomes	Retention of restoration. Pulpal necrosis. Other outcomes reported: marginal integrity; radiographs of residual caries; histology of adhesive bond
Notes	High risk of bias (C).

***Risk of bias***

Item	Authors' judgement	Description
Allocation concealment?	Unclear	B - Unclear

### Characteristics of excluded studies *[ordered by study ID]*

Study	Reason for exclusion
Allan 1969	Restoration failure study.
Anusavice 1987	Compares chemo-mechanical and mechanical caries removal - both complete caries removal
Artaud 1989	Caries-free teeth.
Azhdari 1979	Both techniques complete caries removal.
Bjorndal 1998	No comparison made with complete caries removal.
Bjorndal 1999	No comparison made with complete caries removal.
Chu 2002	No restorative materials used. Study investigated application of fluoride to carious dentine
Feng 2002	No ultraconservative caries removal group.
Fitzgerald 1991	Not a randomised controlled trial.
Florio 2001	Enamel caries only. Compared fissure sealants with fluoride application, no caries removal/control
Foley 2003	Not comparing two-methods of caries removal. All minimal preparation
Gibson 1980	Compares sealant with no treatment. No radiography to confirm occlusal dentine caries present
Going 1976	No complete caries removal group.
Going 1978	No complete caries removal group.
Hamilton 2002	Compares early treatment of enamel lesions with air abrasion to monitoring
Handelman 1976	Does not compare ultraconservative caries removal with complete
Handelman 1981	No ultraconservative caries removal group.
Handelman 1987	Compares fissure sealant on caries-free teeth with fissure sealant over frank caries. Looks at retention only
Handelman 1991	No comparison between complete and ultraconservative caries removal
Heinrich 1988	Paper translated from German. Unable to extract meaningful and relevant data
Jensen 1980	Not randomised controlled trial.
Kreulen 1997	Does not compare complete caries removal with ultraconservative

(Continued)

Leverett 1983	No ultraconservative caries removal in fissure sealant group
Louw 2002	Both groups complete caries removal.
Mandari 2001	Investigates ART. Aimed at complete caries removal.
Mandari 2003	Caries removal considered complete in all study groups (ART). Comparisons made between restorative materials and clinical settings
McDonald 1994	No complete caries removal group.
Mertz-Fairhurst 1979	Compares sealed caries with open cavities, no complete caries removal group
Mertz-Fairhurst 1986	2-year report data in included studies/analysis.
Mertz-Fairhurst 1991	2-year report data in included studies/analysis.
Mertz-Fairhurst 1995	2- year report data in included studies/analysis.
Mertz-Fairhurst 1998	2-year report data in included studies/analysis.
Mertz-Fairhurst 92a	2-year report data in included studies/analysis.
Mertz-Fairhurst 92b	2-year report data in included studies/analysis.
Mertz-Fairhurst abst	Feasibility study of sealed composite restorations over caries. No results presented
Peters 2001	Complete caries removal using air abrasion. Different materials used to restore
Qvist 1997	Does not compare ultraconservative to complete caries removal
Rahimtoola 2000	Compares ART with conventional preparation. Both complete caries removal
Rahimtoola 2002	Compares ART with conventional preparation. Both complete caries removal
Sveen 1978	Clinical study on preventive resin restoration technique.
Walls 1988	Conventional caries removal in both groups.
Weerheijm 1992	No comparison of complete versus ultraconservative caries removal
Weerheijm 1999	Does not compare complete with ultraconservative caries removal. Investigates effect of resin-modified glass ionomer cement and amalgam on bacteria
Welbury 1990	Conventional caries removal in both groups.



*(Continued)*

---

Zanata 2000	Does not compare complete versus ultraconservative caries removal
-------------	---

---

## DATA AND ANALYSES

### Comparison 1. Partial decay removal versus complete removal

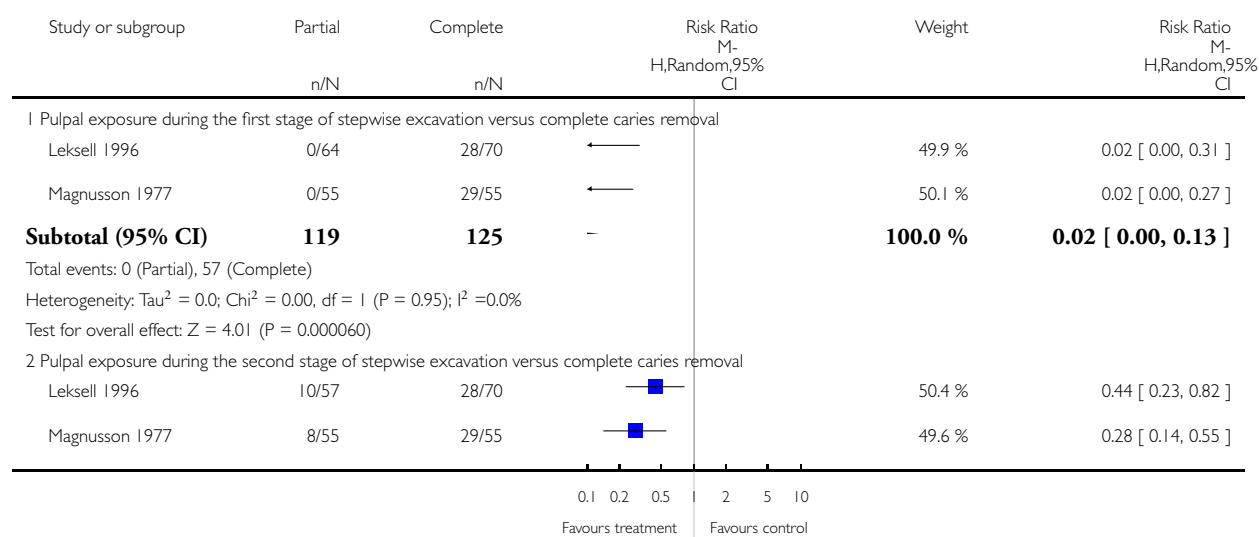
Outcome or subgroup title	No. of studies	No. of participants	Statistical method	Effect size
1 Pulpal exposure	2		Risk Ratio (M-H, Random, 95% CI)	Subtotals only
1.1 Pulpal exposure during the first stage of stepwise excavation versus complete caries removal	2	244	Risk Ratio (M-H, Random, 95% CI)	0.02 [0.00, 0.13]
1.2 Pulpal exposure during the second stage of stepwise excavation versus complete caries removal	2	237	Risk Ratio (M-H, Random, 95% CI)	0.35 [0.22, 0.56]
2 Signs and symptoms of pulpal pathology at 1 year follow up	3	410	Risk Ratio (M-H, Random, 95% CI)	0.81 [0.20, 3.25]
2.1 Signs and symptoms of pulpal pathology	3	410	Risk Ratio (M-H, Random, 95% CI)	0.81 [0.20, 3.25]

#### Analysis 1.1. Comparison 1 Partial decay removal versus complete removal, Outcome 1 Pulpal exposure.

Review: Complete or ultraconservative removal of decayed tissue in unfilled teeth

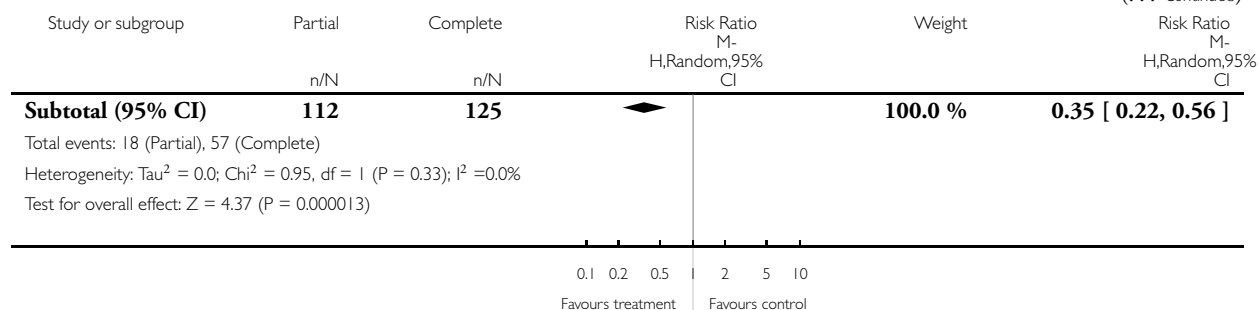
Comparison: 1 Partial decay removal versus complete removal

Outcome: 1 Pulpal exposure



(Continued ...)

(... Continued)

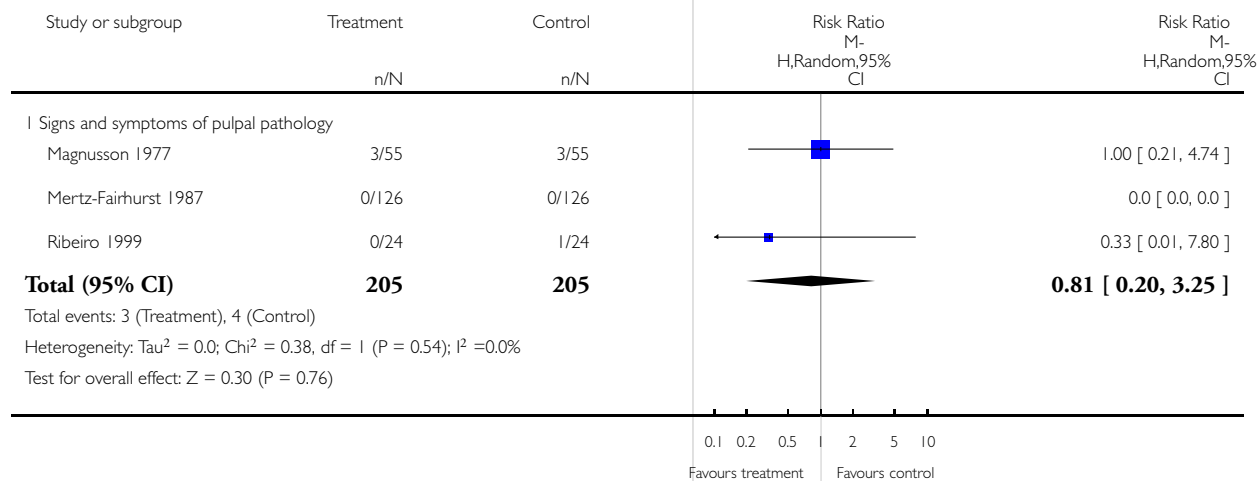


**Analysis 1.2. Comparison 1 Partial decay removal versus complete removal, Outcome 2 Signs and symptoms of pulpal pathology at 1 year follow up.**

Review: Complete or ultraconservative removal of decayed tissue in unfilled teeth

Comparison: 1 Partial decay removal versus complete removal

Outcome: 2 Signs and symptoms of pulpal pathology at 1 year follow up



## APPENDICES

### Appendix I. MEDLINE search strategy

#1 DENTAL-CARIES\$:ME  
#2 ((teeth OR tooth OR dental\$) AND (caries OR carious OR decay\$ OR lesion\$))  
#3 DENTAL-RESTORATION-PERMANENT:ME  
#4 DENTAL-RESTORATION-TEMPORARY:ME  
#5 restor\$  
#6 filling\$  
#7 "Stepwise excavation"  
#8 atraumatic ADJ restor\$  
#9 ART  
#10 PIT-AND-FISSURE-SEALANTS:ME  
#11 fissure ADJ6 seal\$  
#12 GLASS-IONOMER-CEMENTS\$:ME  
#13 RESIN-CEMENTS:ME  
#14 (resin ADJ3 (cement\$ OR seal\$))  
#15 glass ADJ ionomer\$  
#16 #1 OR #2  
#17 ((#12 OR #13 OR #14 OR #15) AND ((dental OR fissure\$) ADJ6 seal\$))  
#18 #10 OR #11 OR #17)  
#19 #3 OR #4 OR #5 OR #6 OR #7 OR #8 OR #9 OR #18  
#20 #16 AND #19

## WHAT'S NEW

Last assessed as up-to-date: 22 May 2006.

Date	Event	Description
6 August 2008	Amended	Converted to new review format.

## HISTORY

Protocol first published: Issue 3, 2002

Review first published: Issue 3, 2006

## **CONTRIBUTIONS OF AUTHORS**

Development of protocol: David Ricketts (DR), Edwina Kidd (EK) and Nicola Innes (NI)

Identification of studies: DR, EK and NI

Data extraction: DR, EK and NI

Analysis and interpretation of data: DR, EK, NI and Jan Clarkson (JC)

Methodological support: JC

Writing the review: DR, EK, NI and JC

## **DECLARATIONS OF INTEREST**

None known.

## **SOURCES OF SUPPORT**

### **Internal sources**

- University of Dundee Dental School, UK.
- Guy's, King's and St Thomas Dental School, UK.

### **External sources**

- No sources of support supplied

## **INDEX TERMS**

### **Medical Subject Headings (MeSH)**

\*Dental Pulp; Cariostatic Agents [\*therapeutic use]; Dental Caries [drug therapy; \*therapy]; Dental Enamel [drug effects; surgery]; Dental Restoration, Permanent [methods]; Pit and Fissure Sealants [\*therapeutic use]; Randomized Controlled Trials as Topic

### **MeSH check words**

Humans