

# Complete rupture of the hamstring origin from a water skiing injury

RALPH B. BLASIER,\*† MD, AND LAWRENCE G. MORAWA,‡ MD

*From the \* Section of Orthopaedic Surgery, University Hospitals, Ann Arbor, Michigan, and the ‡ Orthopaedic Department, Wayne State University, Detroit, Michigan*

Complete rupture of apparently normal hamstring musculature is a rare injury. We report a case of complete rupture of the hamstring muscles at the ischial origin sustained as a result of a water skiing accident in a patient with no recognizable predisposing factors.

## CASE REPORT

The patient, aged 31 years at the time of injury, was a recreational water skier. He was athletic, but not to any professional or competitive level. The patient was water skiing on two skis, about 30 to 35 mph, in a slight crouch with knees and hips somewhat flexed. While in this position, his ski tips engaged a wavelet, submerged, and suddenly decelerated. The bulk of his body maintained its course and speed and forcibly extended the knees while flexing the hips, resulting in a face-first dive into the water (Fig. 1).

The patient recalled immediate agonizing pain of the right posterior thigh that could only be moderated by calm immobility. He was unable to walk. Any effort to move the thigh, especially any attempt to straighten the knee or flex the hip, increased the pain. The patient sought local medical help for relief of the pain and arranged to be returned from his remote vacation site to his home town where he presented to us 48 hours after the injury. There was no history of prior local symptoms, acute or chronic systemic illness, or steroid use.

On physical examination the patient maintained a supine, flexed-knee position. There was marked ecchymosis of the proximal posterior thigh (Fig. 2). The site was tender, but no defect was palpable. Sensation and circulation were normal, as was motor examination distal to the knee. The patient refused motor testing proximal to the knee. The slightest effort to passively extend the knee or flex the hip elicited pain. Although the examination was hampered by the patient's pain, there was no detectable contracture of

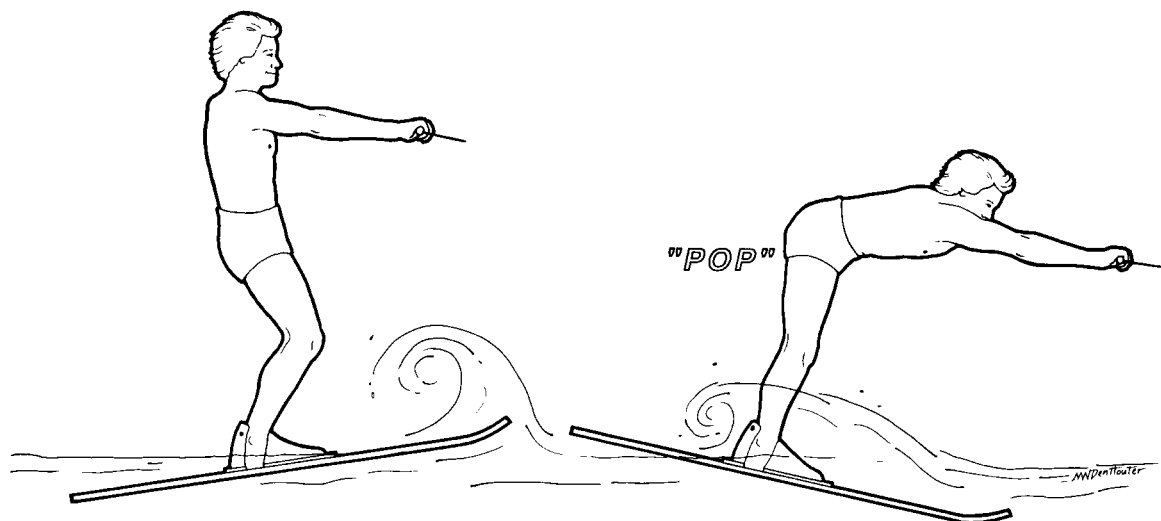the contralateral hamstring. The remainder of the physical examination was normal. Roentgenograms showed no fracture; specifically, there was no ischial avulsion. Computerized tomography was discussed, but was considered unnecessary. Magnetic resonance imaging was not available.

The diagnosis of hamstring avulsion was made, and surgical exploration was carried out. A serpentine incision was made on the proximal posterior aspect of the thigh. We did not incise the gluteus maximus, but rather lifted it proximally to reveal the hamstring origin. We found all of the hamstring muscles to be detached at their bony origin. The ischial head of the biceps femoris and the semitendinosus were avulsed together and were more lateral. The semimembranosus was avulsed alone and was more medial (Fig. 3). No biopsy was taken, but the tendons appeared and felt entirely normal. There was no "explosion" of the fibers as has been described in similar injuries to the quadriceps tendon.<sup>4</sup> There was no apparent cartilage metaplasia as has been described in a similar avulsion of the adductor longus origin.<sup>14</sup> No other injury was evident in the area of exploration. The femoral origin of the biceps femoris was uninjured.

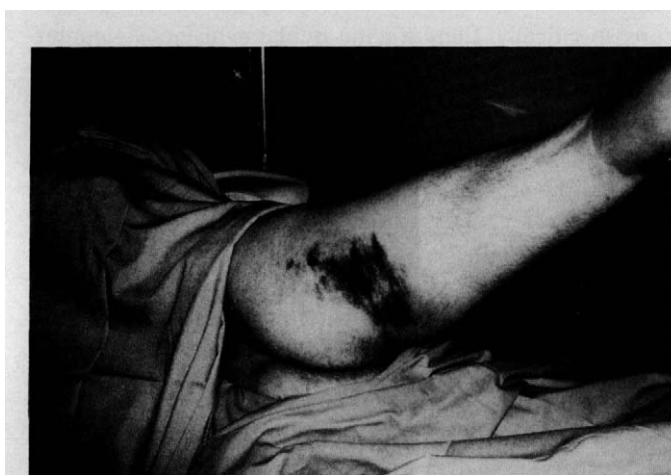Heavy, nonabsorbable sutures were used to attach the hamstring origins to drill holes in the ischium. A hip spica cast was used for 6 weeks of postoperative immobilization with considerable knee flexion and slight hip flexion.

Six weeks after surgery, physical therapy was begun, first to regain motion above and below the injury, and later to regain strength. Four months after surgery, the patient returned to recreational sports. Three years after injury, the patient was asked to return to the office for Biodex isokinetic testing (Biodex Corp., Shirley, NY). He had full range of motion in his hip, and his knee motion was 0° to 130°. Knee flexion strength on his injured side was 8% less than the normal side. There was no measurable difference in endurance of the hamstring groups. Seven years after injury, the patient was again tested. His ranges of motion remained full. He had a 9% deficit in strength in the affected hamstring.

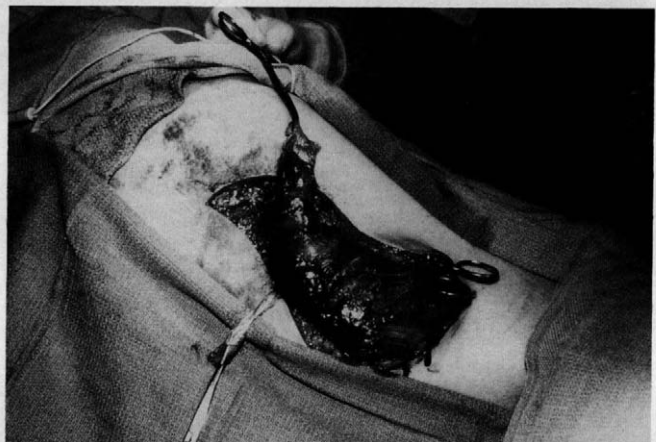
† Address correspondence and reprint requests to: Ralph B. Blasier, MD, Section of Orthopaedic Surgery, University Hospitals (TC 2912), 1500 E. Medical Center Drive, Ann Arbor, MI 48109-0328.



**Figure 1.** Sudden knee extension and increase in hip flexion avulses the hamstring origin.



**Figure 2.** Ecchymosis at hamstring origin. No defect was palpable.



**Figure 3.** At surgery the hamstring origin is avulsed, the tendinous origin of the semimembranosus is separate, and the biceps and semitendinosus are joined.

## DISCUSSION

Water skiing can be a dangerous pastime. Hummel et al.<sup>13</sup> reported 26 severe injuries (4 fatal) sustained in water skiing accidents. Romano et al.<sup>19</sup> discussed many water skiing injuries of somewhat lesser severity, and estimated that water skiing injuries occurred in greater numbers than snow skiing injuries, although no risk rate could be reported because of lack of information on exposure. His report mentioned the possibility of "torn hamstring muscles," but did not elaborate. As part of his paper on athletic injuries to the musculotendinous unit, Brewer<sup>4</sup> mentioned an avulsion of the semitendinosus origin sustained while water skiing and included a photograph of the resulting local tumor mass of the posterior thigh. There was no further description of mechanism, surgical findings (if any), or result of treatment.

Hamstring injuries are not rare and have been discussed many times in the literature.<sup>1, 6, 7, 12, 17, 18, 20</sup> Complete hamstring ruptures caused by indirect trauma are quite uncommon, however. In their compilation of 1014 musculotendinous injuries seen at the Mayo Clinic, Anzel et al.<sup>2</sup> found 871 complete disruptions. Most were due to lacerations or direct blows. Only 25% were caused by indirect stress, and most of these involved the upper limbs. Of the 52 complete indirect stress injuries of the lower limb, only 2 involved the hamstring muscles. Gilcreest<sup>10</sup> found one semitendinosus rupture in his 1933 series, but it was the result of direct trauma and not an overstress injury. Haldeman et al.,<sup>11</sup> in their series of 100 closed muscle and tendon injuries, failed to find any hamstring injury. Wallace<sup>21</sup> has described a traumatic rupture of the biceps femoris, surgically treated, in a dairy cow.

There have been many investigations and speculations about the mechanisms of, and factors predisposing to, hamstring muscle injuries. Frequently mentioned factors predisposing to hamstring injury include: muscle weakness, muscle imbalance, and inflexibility.<sup>1, 3, 6, 7, 12, 15, 20</sup> However, these probably do not apply in this case. Many have noted that musculotendinous ruptures are much more likely if there is some intrinsic pathologic abnormality.<sup>4, 5</sup> Ippolito et al.<sup>14</sup> reported a case of rupture of the adductor longus origin in which the disruption occurred in a 25 mm long segment of cartilaginous metaplasia. This contrasts with the normal thickness of the cartilaginous portion of the healthy tendon insertion that Ippolito states is less than 4 mm and Cooper et al.<sup>8</sup> find to be 250 to 700 microns. McMaster<sup>16</sup> studied experimental ruptures in rabbit musculotendinous units which were normal, crushed, lacerated, or ligated to damage their blood supply. He found that "disease processes" predispose to injury. He also found that healthy musculotendinous units will not rupture through the tendon, but at the musculotendinous junction, the belly of the muscle, or (as in our case) at the bone tendon junction. The literature contains many reports of ruptures of various muscles in association with systemic disease or steroid use.

Garrett et al.<sup>9</sup> studied human cadaver hamstring muscles and found them to have "a relatively high proportion of Type II fibers." They relate the rapid force production of Type II fibers, and the susceptibility of these two-joint muscles to large extrinsic forces, to the occurrence of hamstring injuries. Brewer<sup>5</sup> has also shown that two-joint muscles are susceptible to indirect injury. He further states that the hamstring muscles belong to a group of "muscles of short action" characterized by fibers thought to be short compared to the range of motion of the joints they move. This short extensibility would predispose to indirect injury as in the present case. Two papers emphasized that further restriction in extensibility of the biceps femoris by tethering its femoral origin would predispose to injury this member of the hamstrings.<sup>6, 18</sup> This did not occur in the case presented here.

## CONCLUSIONS

We present a case of complete rupture of the hamstring muscle origin caused by indirect trauma sustained while falling from water skis. This injury was explored and repaired primarily. At followup, 3 years after and again 7 years

after injury, the patient was asymptomatic and had long resumed recreational sports. He had completely regained his motion and endurance. At 3 year followup, he lacked 8% of his hamstring strength compared to the uninjured side. At 7 year followup, he lacked 9% in hamstring strength.

## REFERENCES

1. Agre JC: Hamstring injuries. Proposed aetiological factors, prevention and treatment. *Sports Med* 2: 21-33, 1985
2. Anzel SH, Covey KW, Weiner AD, et al: Disruption of muscles and tendons. An analysis of 1014 cases. *Surgery* 45: 406-414, 1959
3. Baker BE: Current concepts in the diagnosis and treatment of musculotendinous injuries. *Med Sci Sports Exerc* 16: 323-327, 1984
4. Brewer BJ: Athletic injuries: Musculotendinous unit. *Clin Orthop* 23: 30-38, 1962
5. Brewer BJ: Mechanism of injury to the musculotendinous unit. *Instr Course Lect* 17: 354-358, 1960
6. Burkett LN: Investigation into hamstring strains: The case of the hybrid muscle. *J Sports Med* 3: 228-231, 1975
7. Burkett LN: Causitive factors in hamstring strains. *Med Sci Sports* 2: 39-42, 1970
8. Cooper RR, Misol S: Tendon and ligament insertion: A light and electron microscope study. *J Bone Joint Surg* 52A: 1-20, 1970
9. Garrett WE Jr, Califf JC, Bassett FH III: Histochemical correlates of hamstring injuries. *Am J Sports Med* 12: 98-103, 1984
10. Gilcreest EL: Ruptures and tears of muscles and tendons of the lower extremity: Report of fifteen cases. *JAMA* 100: 153-160, 1933
11. Haldeman KO, Soto-Hall R: Injuries to muscles and tendons. *JAMA* 104: 2319-2324, 1935
12. Heiser TM, Weber J, Sullivan G, et al: Prophylaxis and management of hamstring muscle injuries in intercollegiate football players. *Am J Sports Med* 12: 368-370, 1984
13. Hummel G, Gainor BJ: Waterskiing-related injuries. *Am J Sports Med* 10: 215-218, 1982
14. Ippolito E, Postacchini F: Rupture and disinsertion of the proximal attachment of the adductor longus tendon. Case report with histochemical and ultrastructural study. *Ital J Orthop Traum* 7: 79-85, 1981
15. Liemohn W: Factors related to hamstring strains. *J Sports Med Phys Fitness* 18: 71-76, 1978
16. McMaster PE: Tendon and muscle ruptures. Clinical and experimental studies on the causes and location of subcutaneous ruptures. *J Bone Joint Surg* 15: 705-722, 1933
17. Muckle DS: Associated factors in recurrent groin and hamstring injuries. *Br J Sports Med* 16: 37-39, 1982
18. Oakes BW: Hamstring muscle injuries. *Aust Fam Physician* 13: 587-591, 1984
19. Romano RL, Burgess EM, Andrews CB: Medical implications of water-skiing. *Clin Orthop* 23: 140-145, 1962
20. Sutton G: Hamstring by hamstring strains: A review of the literature. *J Orthop Sports Phys Ther* 5: 184-195, 1984
21. Wallace CE: Rupture of the biceps femoris muscle in a dairy cow. *Vet Med Small Anim Clin* 69: 1299-1302, 1974