

Complications from the use of intrawound vancomycin in lumbar spinal surgery: a systematic review

George M. Ghobrial, MD,¹ David W. Cadotte, MD, PhD,² Kim Williams Jr., MD,¹
Michael G. Fehlings, MD, PhD,² and James S. Harrop, MD¹

¹Department of Neurological Surgery, Thomas Jefferson University Hospital, Philadelphia, Pennsylvania; and ²Department of Neurological Surgery, University of Toronto, Ontario, Canada

OBJECT The use of intrawound vancomycin is rapidly being adopted for the prevention of surgical site infection (SSI) in spinal surgery. At operative closure, the placement of vancomycin powder in the wound bed—in addition to standard infection prophylaxis—can provide high concentrations of antibiotics with minimal systemic absorption. However, despite its popularity, to date the majority of studies on intrawound vancomycin are retrospective, and there are no prior reports highlighting the risks of routine treatment.

METHODS A MEDLINE search for pertinent literature was conducted for studies published between 1966 and May 2015 using the following MeSH search terms: “intrawound vancomycin,” “operative lumbar spine complications,” and “nonoperative lumbar spine complications.” This was supplemented with references and known literature on the topic.

RESULTS An advanced MEDLINE search conducted on May 6, 2015, using the search string “intrawound vancomycin” found 22 results. After a review of all abstracts for relevance to intrawound vancomycin use in spinal surgery, 10 studies were reviewed in detail. Three meta-analyses were evaluated from the initial search, and 2 clinical studies were identified. After an analysis of all of the identified manuscripts, 3 additional studies were included for a total of 16 studies. Fourteen retrospective studies and 2 prospective studies were identified, resulting in a total of 9721 patients. A total of 6701 (68.9%) patients underwent treatment with intrawound vancomycin. The mean SSI rate among the control and vancomycin-treated patients was 7.47% and 1.36%, respectively. There were a total of 23 adverse events: nephropathy (1 patient), ototoxicity resulting in transient hearing loss (2 patients), systemic absorption resulting in supratherapeutic vancomycin exposure (1 patient), and culture-negative seroma formation (19 patients). The overall adverse event rate for the total number of treated patients was 0.3%.

CONCLUSIONS Intrawound vancomycin use appears to be safe and effective for reducing postoperative SSIs with a low rate of morbidity. Study disparities and limitations in size, patient populations, designs, and outcomes measures contribute significant bias that could not be fully rectified by this systematic review. Moreover, care should be exercised in the use of intrawound vancomycin due to the lack of well-designed, prospective studies that evaluate the efficacy of vancomycin and include the appropriate systems to capture drug-related complications.

<http://thejns.org/doi/abs/10.3171/2015.7.FOCUS15258>

KEY WORDS lumbar spine; vancomycin; wound infection; complications; thoracolumbar

COST containment is becoming increasingly important in health care, and this also pertains to lumbar spinal surgery. One specific area of focused improvement has been efforts to lower readmission rates. Despite many initiatives, one persistent obstacle to achieving this goal has been the occurrence of postoperative surgical site infection (SSI). Despite attempts to reduce SSI, large studies on posterior lumbosacral spine instrumentation infection report ranges between 3% to 4% across all indications.^{13,19} Moreover, depending on the comorbidities and

surgical complexity, individual risks can approach as high as 15%.^{2,21}

Surgeons are more amenable than ever to incorporate strategies to lower SSI. One potential promise has been the use of vancomycin, a broad-spectrum glycopeptide antibiotic that provides coverage for many gram-positive organisms, including skin flora. Vancomycin was first isolated from *Actinobacteria* species in 1953 by Edmund Kornfeld and later introduced after FDA approval as an intravenous formulation in 1958.¹² Decades later, surgery has seen the

ABBREVIATIONS MIC = minimal inhibitory concentration; SSI = surgical site infection.

SUBMITTED May 28, 2015. **ACCEPTED** July 24, 2015.

INCLUDE WHEN CITING DOI: 10.3171/2015.7.FOCUS15258.

increased use of intrawound vancomycin, which was first administered to cardiothoracic surgery patients with positive results as an unreconstituted powder intended for use in intravenous preparations.¹²

These successful results led to vancomycin's experimental use in spinal surgery patients. In the spine literature, the use of vancomycin powder has appeared to significantly lower the incidence of postoperative SSIs in a number of retrospective studies, from a mean incidence of 4.1% to 1.3%.^{12,13} One aspect under further study is the ideal population for its use, as its use appears to be relatively more beneficial in higher risk populations in some studies.¹³ Most importantly, due to the lack of a well-designed, prospective study, the FDA has not currently approved vancomycin as an intrawound application. However, vancomycin use has been associated with a decreased infection rate, resulting in a cost savings of \$244,402 per 100 thoracolumbar deformity procedures due to decreased re-admission, reoperation, and medical management.²⁵

The benefits of using intrawound vancomycin are the ability to achieve a significantly higher minimal inhibitory concentration (MIC) in the wound bed, while minimizing the serum concentration of the drug and therefore lowering systemic absorption. Clinical studies show that serum vancomycin levels remain at normal therapeutic levels (15–20 µg/ml)¹ or subtherapeutic to undetectable levels,⁷ while local wound concentrations exceed the MIC needed to treat most covered microbes.¹ An elevated serum concentration of vancomycin can be associated with all of the complications reported with the intravenous use of vancomycin hydrochloride, the most concerning of which is nephrotoxicity which can occur at a rate of 6%.²⁰

Again, despite the limited availability of high-quality evidence in the literature, intrawound vancomycin has seen considerable use among spine surgeons, even more so in spine surgeries involving instrumentation such as revision procedures, trauma, and deformity.¹⁶ At the present time, very limited reports are available on the potential complications of intrawound vancomycin use. One theoretical concern with vancomycin that has been highlighted in the spine literature is that broad-spectrum gram-positive coverage could routinely result in the selection of gram-negative and anaerobic bacterial SSIs.⁸

We performed a systematic review of the literature with the aim of summarizing potential vancomycin-related adverse effects.

Methods

An advanced MEDLINE search of English-language papers was conducted on May 6, 2015, using the search string “intrawound vancomycin” in accordance with PRISMA (Preferred Reporting Items for Systematic Reviews and Meta-Analyses) guidelines.¹⁵ Papers were reviewed in their entirety when considered for inclusion. The identified reviews and meta-analyses were reviewed for additional studies. All references identified in each paper were analyzed, and potentially relevant abstracts were reviewed for further inclusion.

Inclusion Criteria

The included articles were already published or pub-

lished prior to print, written in the English language, and involved only human subjects. Prospective clinical trials and retrospective case series with and without comparative cohorts were eligible for inclusion. All included articles were analyzed, and infection rates were recorded with and without intrawound vancomycin use as well as the dosage. All studies must have included data regarding perioperative procedural complications. In particular, the collected secondary variables included adverse events that are potentially attributed to intrawound vancomycin use, which includes the SSI rates, cultured microbial organisms, mortality, nephropathy, ototoxicity, drug-related skin manifestations, and pseudoarthrosis. All included studies were reviewed in detail by 2 authors (K.W. and G.M.G.) to confirm eligibility and limit bias across studies.

Exclusion Criteria

Excluded papers were laboratory or animal research studies, non-English-language publications, case studies, and commentaries. Descriptive studies, surgical technique studies, and articles deemed irrelevant to the topics of interest, as reviewed by 2 authors (G.M.G. and K.W.), were also excluded to limit bias. Meta-analyses and systematic reviews were not included. Relevant studies that appeared in both searches were included in both groups for analysis if they were comparative studies.

Results

The advanced MEDLINE search, which was conducted on May 6, 2015, using the search string “intrawound vancomycin,” found 22 results. After reviewing all abstracts for relevance to intrawound vancomycin use in spinal surgery, 10 studies were reviewed in detail. Three meta-analyses were evaluated from the initial search, and 2 clinical studies were identified. After reviewing all manuscripts, 4 additional studies were identified and a total of 16 studies were selected (Fig. 1).

Adverse Events

Fourteen retrospective studies and 2 prospective studies were identified with a total of 9721 patients. A total of 6701 (68.9%) patients underwent treatment with intrawound vancomycin. The mean SSIs rate among the control and vancomycin-treated patients were 7.47% and 1.36%, respectively. There were a total of 23 adverse events: nephropathy (1 patient), ototoxicity resulting in transient hearing loss (2 patients), systemic absorption resulting in suprathreshold vancomycin exposure (1 patient), and culture-negative seroma formation (19 patients) (Table 1). The overall adverse event rate of the total number of treated patients was 0.3%.

Discussion

The incidence of adverse events pertaining to intrawound vancomycin use is noticeably low across the majority of studies, with only an added morbidity of 0.3%. However, when interpreting vancomycin studies, it has to be taken into consideration that the majority of the conclusions derived are from retrospectively obtained clinical

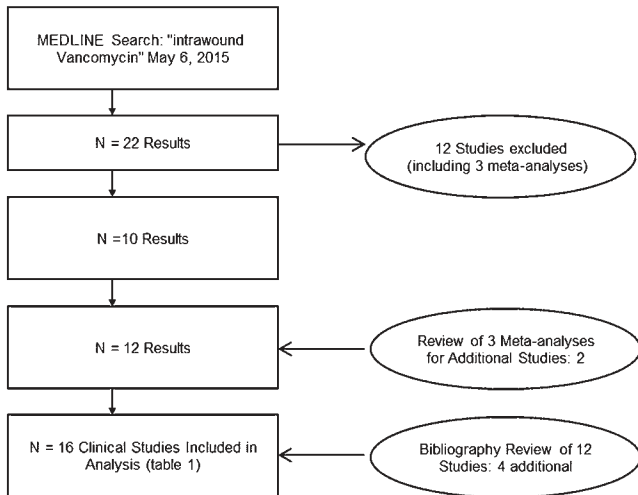


FIG. 1. Study selection.

data and not well-designed prospective studies. The usual limitations to analysis apply, such as the low complication rate due to recall bias.³ Still, in just 4 years, intrawound vancomycin use has been reported with an extremely low rate of adverse events in 6701 patients. This is even more impressive considering that all of these postoperative seromas were treated with wound revisions without any further events, and all manifestations of systemic toxicity such as nephropathy and ototoxicity were rare and transient.

Molinari et al.¹⁷ reported the largest case series to date of intrawound vancomycin use in 1512 surgeries. They found 1 case of transient renal failure. While all patients received 1 g vancomycin, the time course of renal failure, the changes in creatinine over time, and the serum concentrations of vancomycin remain unclear. Prior studies show that serum vancomycin rarely increases to supratherapeutic levels after intrawound administration and is nearly undetectable after 24 hours.¹⁷ Armaghani et al. do note in their retrospective study on vancomycin use that there was one outlier in which supratherapeutic vancomycin levels were noted without any systemic toxicity.¹ Furthermore, Gans et al. evaluated both serum vancomycin and creatinine levels and found no significant rise in either laboratory value across 87 pediatric patients undergoing spinal deformity surgery.⁷

Selective Pressures Concerns on Gram-Negative SSIs and Vancomycin Resistance

Postoperative SSIs are predominantly gram-positive and usually methicillin-sensitive *Staphylococcus aureus*.² Ghobrial et al. highlighted the use of intrawound vancomycin in spinal surgery patients from higher risk populations, such as patients undergoing lumbar revision and deformity procedures, and included a total of 981 patients.⁸ Eighty percent (n = 786) of all described surgeries involved the lumbar spine, and a 5.2% infection rate was noted as well as an approximately 1.5% (n = 15) rate of culture-negative seroma.⁸ Fifteen of the cultured infections were polymicrobial, as well as 2 fungal cultures, and a wide range of

gram-negative infections of the spine were noted, with the most common pathogenic cultured organisms including *Corynebacteria*, *Escherichia coli*, *Proteus*, and *Pseudomonas* (Fig. 2). Tomov et al. reviewed the use of intrawound vancomycin in spinal surgery in their retrospective series of 2325 patients, which included a historical comparative cohort.²⁶ An overall decline in the infection rate was noted, particularly in gram-positive organisms and methicillin-resistant *S. aureus*, with a respective 27% and 23% decrease of each.²⁶ The proportion of gram-negative and polymicrobial infections also decreased after the use of vancomycin, which can only be explained by significant differences in patient populations and operative durations with the use of historical controls.

One additional consideration with the widespread use of vancomycin powder in spinal surgery is the theoretical concern of promoting the development of vancomycin-resistant organisms. None of the reported studies to date describe postoperative spinal infections caused by vancomycin-resistant pathogens in patients with the prior use of intrawound vancomycin. While the development of vancomycin-resistant *S. aureus* has not been published in the spinal surgery literature, vancomycin-resistant *S. aureus* development has been found to be a concern when the MIC of vancomycin is below 4 µg/ml.²⁴ However, previously published studies have demonstrated that vancomycin can reach high concentrations well beyond the MIC needed to treat gram-positive organisms without systemic effects.¹

Dosage Effect on Complications

Currently, there are no human studies designed to determine the optimum concentration of intrawound vancomycin. Eder et al. demonstrated the in vitro, negative, dose-dependent effect of local vancomycin powder on osteoblast activity.⁵ Osteoblast cell cultures were exposed to 0, 3, 6, or 12 mg/cm² of vancomycin powder. At concentrations only above 3 mg/cm², a decline in the pH with a concomitant decrease in osteoblast activity was noted. This was also confirmed with a decrease in alkaline phosphatase activity and calcium deposition. There was detectable osteoblast activity with further dose escalation up to 12 mg/cm². Furthermore, significant cell death due to the acidic pH was noted at 6 mg/cm². Therefore, the biggest theoretical concern is the increased risk of pseudarthrosis, which is particularly concerning as vancomycin is used in revision thoracolumbar spine surgery where a higher risk of SSI has been reported.²¹ In prior retrospective series guiding current use, vancomycin dosing protocols are administered at the standard 1 g^{4,9,17,18,22} or 2 g^{11,16,23,25} and distributed evenly throughout the wound, regardless of wound size. Further in vivo studies are required to determine if safe levels are met, with a particular statistical emphasis on its impact on fusion rates. This clinical question is exceedingly important with protocols that involve the admixture of vancomycin powder within the bone graft.^{7,23} Most clinical studies involving vancomycin are retrospective and do not involve subgroup analyses to evaluate pseudarthrosis between groups. In one of the earliest studies, Strom et al. found no significant difference in the lumbar fusion rates between vancomycin-treated and control groups.²²

TABLE 1. Intrawound vancomycin use in lumbar spine surgery: clinical series and reported adverse effects

Authors & Year	Design	No. of Patients	Vancomycin-Treated		SSIs in Control		SSIs in Vancomycin-Treated		Dose (g)	Adverse Events Reported
			Patients (no.)	Patients (%)	Patients (%)	Patients (%)				
Tomov et al., 2015	Retrospective	2425	1173	2.2	2.2	1.3	1	Increase in gram-negative infections noted; culture-negative seromas (4 patients)		
Heller et al., 2015	Retrospective	683	342	3.8	3.8	1.1	0.5–2.0	None		
Emohare et al., 2014	Retrospective	303	303	3.4	3.4	0	1	None		
Theologis et al., 2014	Retrospective	215	151	10.9	10.9	2.6	2	None		
Martin et al., 2014	Retrospective	306	156	5.3	5.3	5.1	2	None		
Ghobrial et al., 2014	Retrospective	981	981	NA	NA	5.2	Mean 1.13	Culture-negative seromas (15 patients)		
Hill et al., 2014	Retrospective	300	156	4	4	0	1	None		
Armaghani et al., 2014	Retrospective	25	25	NA	NA	0	1	Supratherapeutic serum vancomycin levels from local administration; no clinical adverse events (1 patient)		
Godil et al., 2013	Retrospective	110	56	13	13	0	1	None		
Tubaki et al., 2013	Prospective	907	302	1.68	1.68	1.61	1	None		
Kim et al., 2013	Retrospective	74	34	12.5	12.5	0	1	None		
Strom et al., 2013	Retrospective	253	156	12	12	0	1	None		
Gans et al., 2013	Prospective	87	87	NA	NA	3.4	0.5	None		
Molinari et al., 2012	Retrospective	1512	1512	NA	NA	1.20	1	Transient renal failure (1 patient; 0.07%); transient hearing loss (2 patients; 0.13%)		
Sweet et al., 2011	Retrospective	1732	156	2.6	2.6	0.2	2	None		
O'Neill et al., 2011	Retrospective	110	25	13	13	0	1	None		

NA = not applicable.

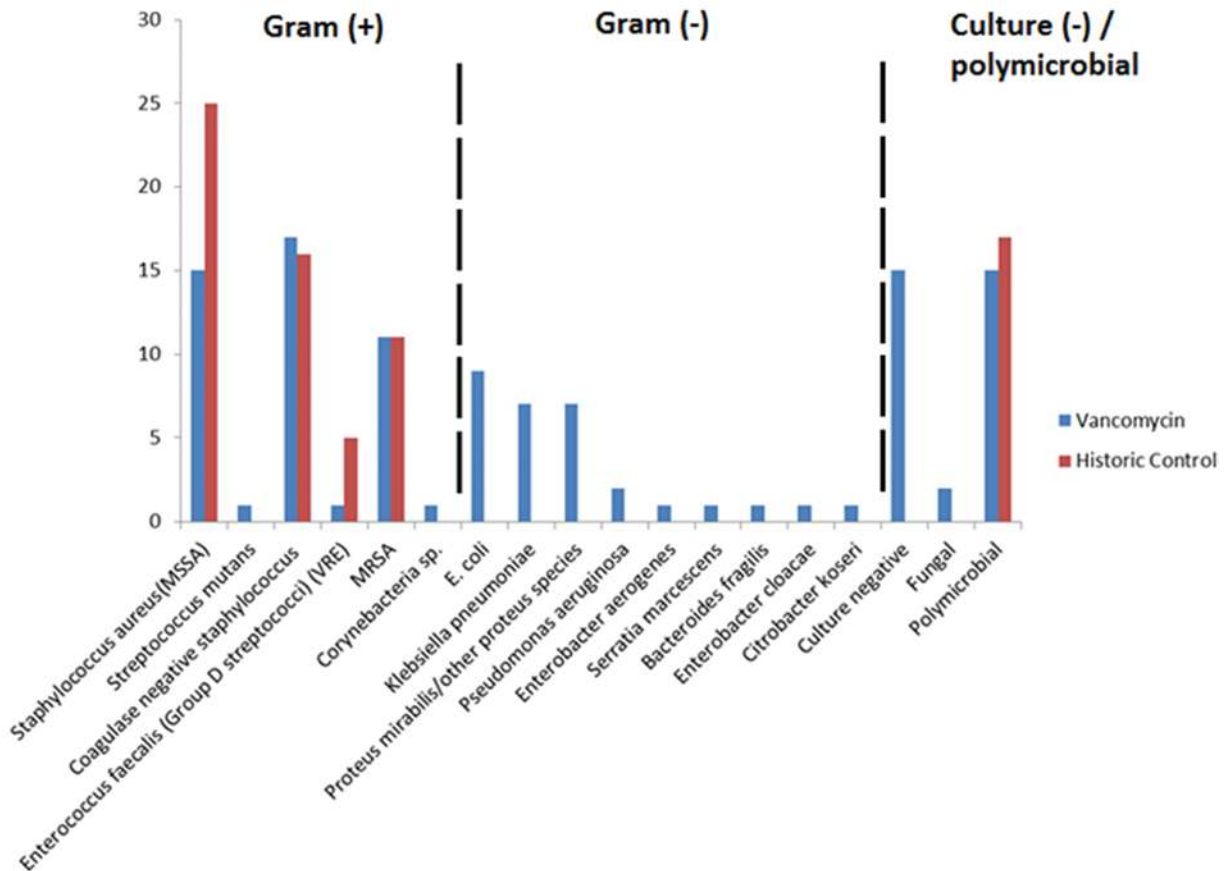


FIG. 2. SSIs in patients previously treated using intrawound vancomycin compared with historical controls at a single institution. The *black dotted lines* separate the types of infection. MRSA = methicillin-resistant *Staphylococcus aureus*; MSSA = methicillin-susceptible *Staphylococcus aureus*; sp. = species; VRE = vancomycin-resistant *Enterococcus*.

Limitations of the Clinical Studies on Intrawound Vancomycin

Many studies lack sufficient numbers to more clearly examine the relationship between increased gram-negative and polymicrobial infections and intrawound vancomycin. Postoperative cultures by organism were not available for every study, which would have allowed a more detailed analysis. Culture-negative seromas are uncommon and have been reported in increased numbers in 2 retrospective studies.^{8,26} The cause-effect relationship has not been established between vancomycin and culture-negative seromas because high doses of intrawound vancomycin could theoretically sterilize the culture samples. Alternatively, further studies are needed to determine the causative relationship between vancomycin powder and related seromas.

Conclusions

Intrawound vancomycin use appears to be safe and effective for reducing postoperative SSIs with a low rate of morbidity. Study disparities and limitations in size, patient populations, designs, and outcome measures contribute significant bias that could not be fully rectified by this systematic review. Moreover, care should be exercised in the use of intrawound vancomycin due to the lack of well-

designed, prospective studies that evaluate the efficacy of vancomycin and include the appropriate systems to capture drug-related complications.

References

1. Armaghani SJ, Menge TJ, Lovejoy SA, Mencia GA, Martus JE: Safety of topical vancomycin for pediatric spinal deformity: nontoxic serum levels with supratherapeutic drain levels. *Spine (Phila Pa 1976)* **39**:1683–1687, 2014
2. Beiner JM, Grauer J, Kwon BK, Vaccaro AR: Postoperative wound infections of the spine. *Neurosurg Focus* **15(3)**:E14, 2003
3. Campbell PG, Yadla S, Malone J, Maltenfort MG, Harrop JS, Sharan AD, et al: Complications related to instrumentation in spine surgery: a prospective analysis. *Neurosurg Focus* **31(4)**:E10, 2011
4. Caroom C, Tullar JM, Benton EG Jr, Jones JR, Chaput CD: Intrawound vancomycin powder reduces surgical site infections in posterior cervical fusion. *Spine (Phila Pa 1976)* **38**:1183–1187, 2013
5. Eder C, Schenk S, Trifinopoulos J, Külekci B, Kienzl M, Schildböck S, et al: Does intrawound application of vancomycin influence bone healing in spinal surgery? *Eur Spine J* [epub ahead of print], 2015
6. Emohare O, Ledonio CG, Hill BW, Davis RA, Polly DW Jr, Kang MM: Cost savings analysis of intrawound vancomycin

- powder in posterior spinal surgery. **Spine J** 14:2710–2715, 2014
7. Gans I, Dormans JP, Spiegel DA, Flynn JM, Sankar WN, Campbell RM, et al: Adjunctive vancomycin powder in pediatric spine surgery is safe. **Spine (Phila Pa 1976)** 38:1703–1707, 2013
 8. Ghobrial GM, Thakkar V, Andrews E, Lang M, Chitale A, Oppenlander ME, et al: Intraoperative vancomycin use in spinal surgery: single institution experience and microbial trends. **Spine (Phila Pa 1976)** 39:550–555, 2014
 9. Godil SS, Parker SL, O'Neill KR, Devin CJ, McGirt MJ: Comparative effectiveness and cost-benefit analysis of local application of vancomycin powder in posterior spinal fusion for spine trauma: clinical article. **J Neurosurg Spine** 19:331–335, 2013
 10. Heller A, McIff T, Lai SM, Burton DC: Intrawound vancomycin powder decreases staphylococcal surgical site infections following posterior instrumented spinal arthrodesis. **J Spinal Disord Tech** [epub ahead of print], 2015
 11. Hill BW, Emohare O, Song B, Davis R, Kang MM: The use of vancomycin powder reduces surgical reoperation in posterior instrumented and noninstrumented spinal surgery. **Acta Neurochir (Wien)** 156:749–754, 2014
 12. Kang DG, Holekamp TF, Wagner SC, Lehman RA Jr: Intra-site vancomycin powder for the prevention of surgical site infection in spine surgery: a systematic literature review. **Spine J** 15:762–770, 2015
 13. Khan NR, Thompson CJ, DeCuyper M, Angotti JM, Kalobwe E, Muhlbauer MS, et al: A meta-analysis of spinal surgical site infection and vancomycin powder. **J Neurosurg Spine** 21:974–983, 2014
 14. Kim HS, Lee SG, Kim WK, Park CW, Son S: Prophylactic intrawound application of vancomycin powder in instrumented spinal fusion surgery. **Korean J Spine** 10:121–125, 2013
 15. Liberati A, Altman DG, Tetzlaff J, Mulrow C, Gøtzsche PC, Ioannidis JP, et al: The PRISMA statement for reporting systematic reviews and meta-analyses of studies that evaluate health care interventions: explanation and elaboration. **J Clin Epidemiol** 62:e1–e34, 2009
 16. Martin JR, Adogwa O, Brown CR, Bagley CA, Richardson WJ, Lad SP, et al: Experience with intrawound vancomycin powder for spinal deformity surgery. **Spine (Phila Pa 1976)** 39:177–184, 2014
 17. Molinari RW, Khera OA, Molinari WJ III: Prophylactic intraoperative powdered vancomycin and postoperative deep spinal wound infection: 1,512 consecutive surgical cases over a 6-year period. **Eur Spine J** 21 (Suppl 4):S476–S482, 2012
 18. O'Neill KR, Smith JG, Abtahi AM, Archer KR, Spengler DM, McGirt MJ, et al: Reduced surgical site infections in patients undergoing posterior spinal stabilization of traumatic injuries using vancomycin powder. **Spine J** 11:641–646, 2011
 19. Picada R, Winter RB, Lonstein JE, Denis F, Pinto MR, Smith MD, et al: Postoperative deep wound infection in adults after posterior lumbosacral spine fusion with instrumentation: incidence and management. **J Spinal Disord** 13:42–45, 2000
 20. Rostas SE, Kubiak DW, Calderwood MS: High-dose intravenous vancomycin therapy and the risk of nephrotoxicity. **Clin Ther** 36:1098–1101, 2014
 21. Schuster JM, Rehtine G, Norvell DC, Dettori JR: The influence of perioperative risk factors and therapeutic interventions on infection rates after spine surgery: a systematic review. **Spine (Phila Pa 1976)** 35 (9 Suppl):S125–S137, 2010
 22. Strom RG, Pacione D, Kalhorn SP, Frempong-Boadu AK: Lumbar laminectomy and fusion with routine local application of vancomycin powder: decreased infection rate in instrumented and non-instrumented cases. **Clin Neurol Neurosurg** 115:1766–1769, 2013
 23. Sweet FA, Roh M, Sliva C: Intrawound application of vancomycin for prophylaxis in instrumented thoracolumbar fusions: efficacy, drug levels, and patient outcomes. **Spine (Phila Pa 1976)** 36:2084–2088, 2011
 24. Tarai B, Das P, Kumar D: Recurrent challenges for clinicians: emergence of methicillin-resistant *Staphylococcus aureus*, vancomycin resistance, and current treatment options. **J Lab Physicians** 5:71–78, 2013
 25. Theologis AA, Demirkiran G, Callahan M, Pekmezci M, Ames C, Deviren V: Local intrawound vancomycin powder decreases the risk of surgical site infections in complex adult deformity reconstruction: a cost analysis. **Spine (Phila Pa 1976)** 39:1875–1880, 2014
 26. Tomov M, Mitsunaga L, Durbin-Johnson B, Nallur D, Roberto R: Reducing surgical site infection in spinal surgery with betadine irrigation and intrawound vancomycin powder. **Spine (Phila Pa 1976)** 40:491–499, 2015
 27. Tubaki VR1, Rajasekaran S, Shetty AP: Effects of using intravenous antibiotic only versus local intrawound vancomycin antibiotic powder application in addition to intravenous antibiotics on postoperative infection in spine surgery in 907 patients. **Spine (Phila Pa 1976)** 38:2149–2155, 2013

Disclosure

Dr. Harrop states that he is a consultant for DePuy Spine and has financial relationships with Asterias, Bioventus, and Teijin.

Author Contributions

Conception and design: Ghobrial. Acquisition of data: Harrop, Ghobrial, Williams, Fehlings. Analysis and interpretation of data: Harrop, Ghobrial, Williams, Fehlings. Drafting the article: Harrop, Ghobrial. Critically revising the article: Ghobrial, Cadotte.

Correspondence

James S. Harrop, Department of Neurological Surgery, Thomas Jefferson University Hospital, 909 Walnut St., 3rd Fl., Philadelphia, PA 19107. email: james.harrop@jefferson.edu.