

Research Articles

Complications of the Laparoscopic Roux-en-Y Gastric Bypass: 1,040 Patients - What Have We Learned?

Kelvin D. Higa, MD; Keith B. Boone, MD; Tienchin Ho, MD

Bariatric Surgery Center, Fresno, CA, USA

Background: The Roux-en-Y gastric bypass (RYGBP) is one of the most common operations for morbid obesity. Laparoscopic techniques have been reported, but suffer from small numbers of patients, longer operative times and seemingly higher initial complication rates as compared to the traditional "open" procedure. The minimally invasive approach continues to be a challenge even to the most experienced laparoscopic surgeons. The purpose of this study is to describe our experience and complications of the laparoscopic Roux-en-Y gastric bypass with a totally hand-sewn gastrojejunostomy.

Methods: 1,040 consecutive laparoscopic procedures were evaluated prospectively. Only patients who had a previous open gastric procedure were excluded initially. Eventually, even patients with failed "open" bariatric procedures and other gastric procedures were revised laparoscopically to the RYGBP. All patients met NIH criteria for consideration for weight reductive surgery.

Results: There were no anastomotic leaks from the hand-sewn gastrojejunostomy. Early complications and open conversions were related to sub-optimal exposure and bowel fixation techniques. Several staple failures were attributed to a manufacturer redesign of an instrument. Average hospital stay was 1.9 days for all patients and 1.5 days for patients without complications. Operative times consistently approach 60 minutes. Average excess weight loss was 70% at 12 months. There were 5 deaths: perioperative pulmonary embolism (1), late pulmonary embolism (2), asthma (1), and suicide (1).

Conclusions: The laparoscopic Roux-en-Y gastric bypass for morbid obesity with a totally hand-sewn

gastrojejunostomy can be safely performed by the bariatric surgeon with advanced laparoscopic skills in the community setting. Fixation and closure of all potential hernia sites with non-absorbable sutures is essential. Stenosis of the hand-sewn gastrojejunal anastomosis is amenable to endoscopic balloon dilation. Meticulous attention must be paid to the operative and perioperative care of the patient.

Key words: Morbid obesity, bariatric surgery, laparoscopy, gastric bypass

Introduction

The gastric bypass is one of the most common procedures performed in the United States for control of morbid obesity. Complications related to the incision, cosmetic considerations and patient preferences have sparked interest in the laparoscopic approach. Concurrent development in less technically demanding procedures such as the vertical banded gastroplasty and adjustable lap-band has taken place in the quest for a comparable minimally invasive solution. Although some authors have achieved excellent results with the lap-band,^{1,2} outcomes data would favor the Roux-en-Y gastric bypass (RYGBP) over these purely restrictive procedures.^{3,4}

We have performed over 1,000 laparoscopic RYGBP procedures since February 1998. Our initial experience with 400 patients has been previously reported.⁵ This paper will discuss complica-

Presented at the 5th Congress of the International Federation for the Surgery of Obesity, Genoa, Italy, September 22, 2000.

Reprint requests to: Kelvin D. Higa, MD, FACS, 7202 N. Millbrook Avenue, Suite 105, Fresno, CA 93720, USA. Fax: (559) 449-3903; e-mail: higanoid@hotmail.com

tions that we have encountered during the development and potential solutions to these problems.

Methods

Patient selection

Patients were selected based on National Institutes of Health criteria.⁶ It was our intention to develop techniques of retraction and visualization applicable to *all* qualified patients; therefore, there were no exclusions based on absolute weight, BMI or the presence of previous operations except for patients who had a previous bariatric or gastric procedure. Later in the series, one of the authors (KH) began performing laparoscopic conversion of previous failed bariatric procedures.

Anatomic construct

The mechanism of weight loss after RYGBP is not completely understood; therefore, we felt it important to emulate our “open” procedure as much as possible to obtain similar outcomes. The principals are as follows (Figure. 1)

1. Small (20-30 ml) proximal, lesser curve based, vertically oriented gastric pouch with exclusion of the gastric fundus.

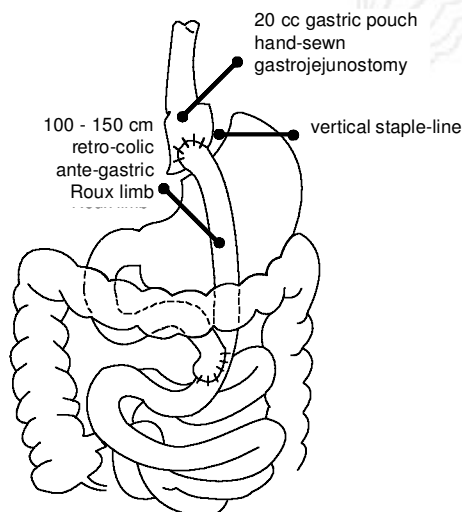


Figure 1. Technique of RYGBP used.

2. Roux limb 100-150 cm length with division of the small bowel close to the ligament of Treitz.
3. Hand-sewn gastrojejunostomy sized at 32 Fr.

Patient positioning and port placement

As a model, the laparoscopic Nissen fundoplication allows excellent access to the stomach, but not to the small intestine. In addition, the obese patient does not require as extreme a distance between ports to prevent the “sword-fighting” one encounters with thinner individuals. Therefore, the ports are centrally located and configured to allow access to both the small bowel and stomach (Figure 2).

Liver retraction

Because the liver can vary both in size and consistency, various forms of liver retraction were evaluated. The most consistent method is that of a single 5 mm or 10 mm rod placed in the sub-xiphoid position.

Formation of the gastric pouch

Dissection at the hiatus is often difficult in the super-obese and male patients. Sub-optimal visualization and inadequate retraction led to incomplete partitioning of the stomach in a few early patients.

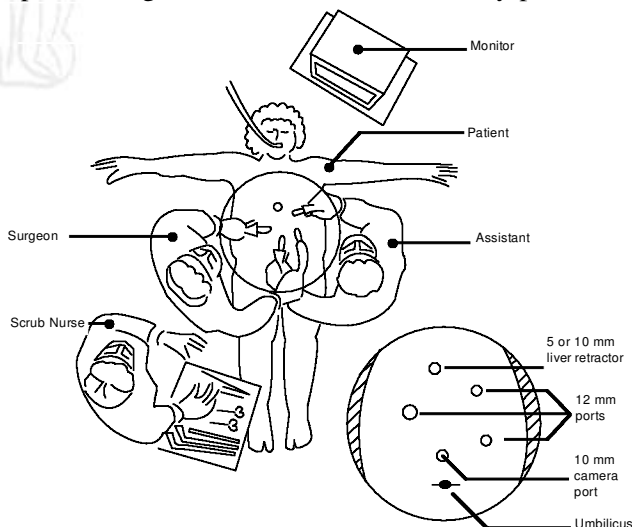


Figure 2. Positioning and port placement.

With the use of an articulating esophageal retractor (Pilling/Weck #381801) for retraction and dissection, consistent exposure is achieved.

Creation of the Roux-limb

Consistent exposure of the small bowel can be achieved by cephalad displacement of the omentum. However, many of our patients have had previous pelvic procedures or extensive adhesions. Rather than attempt mobilization of the adhesions, direct access to the ligament of Treitz can be obtained through the gastro-colic ligament and transverse mesocolon.

Gastrojejunostomy

Passed retro-colic, the Roux limb easily reaches the gastric pouch. In the first few patients, we performed a retro-gastric anastomosis, but we have found it easier to bring the limb anterior to the stomach. A standard two-layer anastomosis, either running or interrupted with absorbable sutures, has proven to be quite durable and serviceable.

Results

This study included 1,040 patients from February 1988 to August 2000 (Table 1). All procedures were performed by the authors KH, KB and TH, and the data were obtained prospectively. Patients were predominately female. Ages ranged from 13 years to 72 years. Average body mass index (BMI) was 47.8 kg/m², range 35 kg/m² to 78 kg/m². Of the patients, 276 were super-obese (BMI > 50 kg/m²).

Table 1. Pre-operative data

BMI	Patients (n)	Female	Male
35-40	154	138	16
40-50	610	509	101
50-60	223	174	49
60-70	46	31	15
70+	7	7	0
Total	1,040	859 (82.6%)	181 (17.4%)

Average excess weight loss at 1 year was 70% (Figure 3).

There was only one operative death, due to pulmonary embolism. There were two late deaths which occurred 5 to 6 months after surgery due to pulmonary embolism and two late deaths due to asthma and suicide, respectively. The suicide was thought to be related to depression after the unexpected death of a family member rather than as a result of the surgery. Complications are shown in Table 2.

Internal hernias occurred with greater frequency in the beginning of the series, when we used absorbable sutures to fix the Roux-limb at the mesocolon as we had done in our "open" experience. Changing to non-absorbable sutures has decreased this complication by approximately 50%.

The majority of patients who developed gallstones did not take ursodiol as prescribed.⁷ The majority of patients who developed marginal ulceration, including two patients who presented with perforation, were associated with NSAID usage despite written and verbal precautions.

Operative times approached 60 minutes as a routine. After the initial learning curve, open conversion was rarely necessary.

Discussion

We consider every bariatric patient to be a candidate for the laparoscopic procedure. We have found that open conversion may be necessary for the following two reasons:

1. Hepatomegaly. A huge liver, as seen with acute weight gain immediately before surgery or with massive obesity, does not allow adequate visualization of the esophageal hiatus and can limit safe dissection.
2. Small abdominal cavity. As in the case of some patients with past abdominoplasty, the inability to establish an adequate pneumoperitoneum prevents safe dissection and visualization.

We have not found the absolute size of the patient or length of instrumentation to be a limiting factor. Thoughtful placement of trocars and the ability to use various suturing techniques are important con-

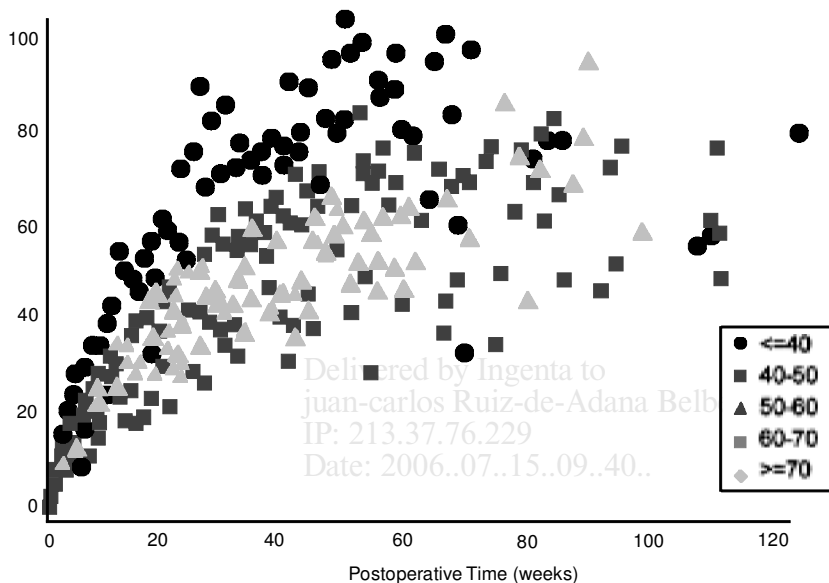


Figure 3. Average percent excess weight loss by BMI group.

siderations. This is especially true in patients who have had previous surgeries and present with the added challenge of intra-abdominal adhesions.

Stenosis at the gastrojejunostomy continues to be a problem. Perhaps due to relative ischemia, this problem is usually corrected with endoscopic balloon dilation. In only one instance, operative revi-

sion was necessary. This was done laparoscopically. The ante-gastric position of the anastomosis allowed for easier access than if it was behind the stomach. Use of aggressive acid reduction perioperatively has not decreased the rate of this complication. Contrarily, stenosis at the mesocolon is not amenable to endoscopic balloon dilation and must

Table 2. Complications

COMPLICATION	No. of Complications	% of all Complications	% of 1,040 Patients
Stenosis at gastrojejunostomy	51	33.3%	4.9%
Internal hernia	26	17.0%	2.5%
Gallstones	15	9.8%	1.4%
Marginal ulcer - NSAIDs induced ⁱ	14	9.2%	1.4%
Staple-line failure	10	6.5%	1.0%
Stenosis at mesocolon	9	5.9%	0.9%
Bleeding requiring transfusion or re-operation	6	3.9%	0.6%
Death	5	3.3%	0.5%
Incomplete division of stomach	4	2.6%	0.4%
Pulmonary embolism	3	2.0%	0.3%
Trocar hernia (bladed 2; non-bladed 1)	3	2.0%	0.3%
Deep venous thrombosis	2	1.3%	0.2%
Perforation ⁱⁱ	2	1.3%	0.2%
Central pontine myelinolysis	1	0.7%	0.1%
Pneumonia	1	0.7%	0.1%
Wound infection	1	0.7%	0.1%
Total	153	100.0%	14.7%

ⁱ Includes two patients presenting with perforation.

ⁱⁱ These represents probable operative injury, either thermal or mechanical.

be surgically corrected; this is easily performed via the laparoscope.

One of the benefits of minimally invasive surgery, that of limiting intra-abdominal adhesions, has led to complications rarely seen with the "open" procedures – that of internal hernias.⁸ Despite fixation of the Roux-limb at the mesocolon with non-absorbable sutures, this complication is important because of its life-long potential and has been reported by others. Easily repaired laparoscopically, this can be a serious problem if the patient presents to physicians who are not familiar with their anatomy and treatment is delayed. We have not seen this complication in the late post-operative period.

As with any mechanical device, staplers may have a definable failure rate. In addition, staplers do not generally account for variances in tissue thickness and friability. Changes in the manufacture specifications of an instrument lead to a "run" of staple failures not experienced with the older design. This complication is rarely seen with current stapling devices. There have been no leaks from the hand-sewn anastomosis.

Despite use of perioperative mini-dose heparin, pneumatic calf compression devices and early ambulation, we had two patients with early deep vein thrombosis. Of equal concern are the two late deaths due to pulmonary emboli 5 and 6 months after the procedure. Both of these patients exhibited no signs of deep venous thrombosis or history of previous thrombotic events.

The presence of previous procedures has not been prohibitive to performing the operation. In fact, laparoscopic mobilization of adhesions has advantages over extending an upper midline incision as is frequently necessary with the traditional approach. We have learned to minimize dissection and to find alternative exposure routes without compromising visualization.

Revision laparoscopic bariatric surgery is quite challenging. However, the improved visualization achieved via the laparoscope allows for more precise and delicate dissection, especially when using the 5-mm curved Harmonic Scalpel®.⁹

RYGBP has been performed laparoscopically by a variety of techniques.¹⁰⁻¹² The basic tenets of the operation remain the same: proper evaluation and education of the patient before surgery, meticulous

attention to operative detail during surgery and close follow-up after surgery. The technical aspect of this operation is within the purview of most bariatric surgeons. The learning experience is arduous, but the potential to benefit this population of deserving patients is immeasurable.

References

1. Miller K, Hell E. Laparoscopic adjustable gastric banding: A prospective 4-year follow-up study. *Obes Surg* 1999; 9: 183-7.
2. Catona A, La Manna L, Forsell P. The Swedish adjustable gastric band: laparoscopic technique and preliminary results. *Obes Surg* 2000 10: 15-21.
3. Doherty C, Maher JW, Heitshusen DS. Prospective investigation of complications, reoperations, and sustained weight loss with an adjustable gastric banding device for treatment of morbid obesity. *J Gastrointest Surg* 1998; 2: 102-8.
4. Sugerman HJ, Starkey JV, Birkenbauer R. A randomized prospective trial of gastric bypass versus vertical banded gastroplasty for morbid obesity and their effects on sweets versus non-sweets eaters. *Ann Surg* 1987 ;205: 613-24.
5. Higa K, Boone K, Ho T. Laparoscopic Roux-en-Y gastric bypass for morbid obesity: technique and preliminary results of our first 400 patients. *Arch Surg* 2000; 135: 1029-34.
6. Gastrointestinal Surgery for Severe Obesity. Consensus Development Conference Panel, National Institutes of Health. *Ann Intern Med* 1991; 115: 956-61.
7. Sugerman HJ, Brewer WH, Shiffman ML et al. A multicenter, placebo-controlled, randomized, double-blind, prospective trial of prophylactic ursodiol for the prevention of gallstone formation following gastric-bypass-induced rapid weight loss. *Am J Surg* 1995; 169: 91-7.
8. Serra C, Baltasar A, Bou R et al Internal hernias and gastric perforation after a laparoscopic gastric bypass. *Obes Surg* 1999; 9: 546-9.
9. Ethicon Endosurgery, 4545 Creek Road, Cincinnati, OH 45242-2839, USA.
10. Wittgrove AC, Clark GW. Laparoscopic gastric bypass, Roux-en-Y – 500 patients: technique and results, with 3-60 month follow-up. *Obes Surg* 2000; 10: 233-9.
11. De la Torre RA, Scott JS. Laparoscopic Roux-en-Y gastric bypass: a totally intra-abdominal approach – technique and preliminary report. *Obes Surg* 1999; 9: 492-8.
12. Schauer PR, Ikaramuddin S, Gourash WF. Laparoscopic Roux-en-Y gastric bypass: a case report at one-year follow-up. *J Laparoendosc Adv Surg Tech A* 1999;9:101-6.

(Received September 25, 2000; accepted November 2, 2000)