



UvA-DARE (Digital Academic Repository)

Treatment of osteochondral defects of the talus

van Bergen, C.J.A.

Publication date
2014

[Link to publication](#)

Citation for published version (APA):

van Bergen, C. J. A. (2014). *Treatment of osteochondral defects of the talus*.

General rights

It is not permitted to download or to forward/distribute the text or part of it without the consent of the author(s) and/or copyright holder(s), other than for strictly personal, individual use, unless the work is under an open content license (like Creative Commons).

Disclaimer/Complaints regulations

If you believe that digital publication of certain material infringes any of your rights or (privacy) interests, please let the Library know, stating your reasons. In case of a legitimate complaint, the Library will make the material inaccessible and/or remove it from the website. Please Ask the Library: <https://uba.uva.nl/en/contact>, or a letter to: Library of the University of Amsterdam, Secretariat, Singel 425, 1012 WP Amsterdam, The Netherlands. You will be contacted as soon as possible.



Chapter 4

Computed tomography of the ankle in full plantar flexion: a reliable method for preoperative planning of arthroscopic access to osteochondral defects of the talus

Christiaan J.A. van Bergen
Gabriëlle J.M. Tuijthof
Leendert Blankevoort
Mario Maas
Gino M.M.J. Kerkhoffs
C. Niek van Dijk

Abstract

Purpose

The purpose of this study was to determine whether preoperative computed tomography (CT) of the ankle joint in full plantar flexion is a reliable and accurate tool to determine the anterior arthroscopic accessibility of talar osteochondral defects (OCDs).

Methods

Twenty consecutive patients were prospectively studied. All patients had an OCD of the talar dome and had a preoperative CT scan of the affected ankle in maximum plantar flexion. Accessibility of the OCD was defined by the distance between the anterior border of the OCD and the anterior distal tibial rim. This distance was measured on sagittal CT reconstructions by two investigators. The reference standard was the distance between the same landmarks measured during anterior ankle arthroscopy by an orthopedic surgeon blinded to the CT scans. Intraobserver and interobserver reliability of CT, as well as the correlation and agreement between CT and arthroscopy, were calculated.

Results

The measured distance between the anterior border of the OCD and the anterior distal tibial rim ranged from -3.1 to 9.1 mm on CT and from -3.0 to 8.5 mm on arthroscopy. The intraobserver and interobserver reliability of the measurements made on CT scans (intraclass correlation coefficients >0.99 , $p < 0.001$), as well as the correlation between CT and arthroscopy, were excellent ($r = 0.98$; $p < 0.001$).

Conclusion

Measurements on CT scans of the ankle in full plantar flexion are a reliable and accurate preoperative method to determine the in situ arthroscopic location of talar OCDs.

Introduction

Osteochondral defects (OCD) of the talus involve the articular cartilage and subchondral bone and are usually located on the central or posterior third of the medial or lateral talar dome.³²² The primary surgical treatment for these lesions is arthroscopic debridement and microfracture.⁴⁵⁸ Arthroscopic access to the talar dome is restricted by the tibial plafond. To gain exposure to the OCD during anterior arthroscopy, the ankle

must be maximally plantarflexed to move the lesion anteriorly.^{424,432} However, some defects located in the posterior part of the talus may not be accessible by anterior arthroscopy.^{296,408} Especially if the OCD is located posteriorly and if there is restricted range of motion of the ankle, determining accessibility of the lesion preoperatively may be difficult. Accurate preoperative planning will assist the surgeon in choosing whether anterior arthroscopy or another surgical approach would be appropriate.

Radiographs can be used for the initial diagnosis, but multislice helical computed tomography (CT) and magnetic resonance imaging (MRI) have higher accuracy in detecting OCDs.⁴⁴⁰ CT scanning is preferred for preoperative planning because it visualizes the exact location, size and extent of the OCD.^{160,408} CT scanning of the ankle is normally performed with the ankle joint in the plantigrade position. This position is different from the plantarflexed ankle on anterior ankle arthroscopy. A CT scan of the ankle in full plantar flexion, simulating the arthroscopic positioning, may better show the intraoperative location of the OCD and could thus be an important tool for preoperative planning.

The purpose of this study is to determine whether a preoperative CT scan of the plantarflexed ankle is able to predict the anterior arthroscopic accessibility of talar OCDs. We hypothesized that the location of the OCD in relation to the anterior distal tibial rim on a CT scan of a fully plantarflexed ankle would correlate with the location as measured during anterior ankle arthroscopy.

Methods

Study design

A prospective study was undertaken according to a study protocol approved by the local medical ethics committee. Patients aged 18 years or older presenting to our outpatient department with a suspected or diagnosed OCD of the talus starting in May 2008 were eligible for the study. After informed consent was obtained, CT scans of the affected ankle in both the plantigrade and fully plantarflexed positions were obtained (Figure 1). The surgeon (blinded to the CT scan of the plantarflexed ankle) made the decision for treatment, based on the CT scan of the plantigrade ankle and the clinical assessment of the ankle range of

motion and joint laxity. The first 20 patients with an OCD who were scheduled for treatment by anterior ankle arthroscopy (June 2008 to March 2009) were included in the study. A sample size of 19 was able to detect a reliability of 0.9 and a minimally acceptable reliability of 0.7, with $\alpha = 0.05$ and $\beta = 0.20$.⁴⁴³ During the study period, we excluded 10 patients who were scheduled for treatment by methods other than anterior ankle arthroscopy: two were treated by posterior arthroscopy⁴²⁷ – the first for a far posterolateral OCD and the second for a posteromedial OCD combined with a loose body in the posterior ankle compartment – and eight were treated with a focal resurfacing implant⁴¹² through a medial malleolar osteotomy for a large OCD of the medial talar dome that failed previous surgical treatment.

Accessibility of the OCD was defined by the distance between the anterior border of the OCD and the anterior distal tibial rim. This distance was measured on sagittal CT reconstructions and compared to anterior ankle arthroscopy as the reference standard. The anterior edge of the lesion rather than the middle or posterior portion was chosen as the landmark for accessibility since it is the anterior part of the lesion that has to be identified initially during arthroscopy. The defect is then treated from anteriorly to posteriorly, thus gaining further exposure during treatment. Removal of the anterior part of the defect cartilage will automatically create more space for access to the more posterior defect area. By forcing the ankle into full plantar flexion, the ankle opens up anteriorly, thus providing access to the complete defect. Adding a noninvasive ankle distractor can also be helpful at this point.

Computed tomography

With the patient supine, CT scans of the affected ankles were acquired in the plantigrade (i.e., the foot sole perpendicular to the table) and

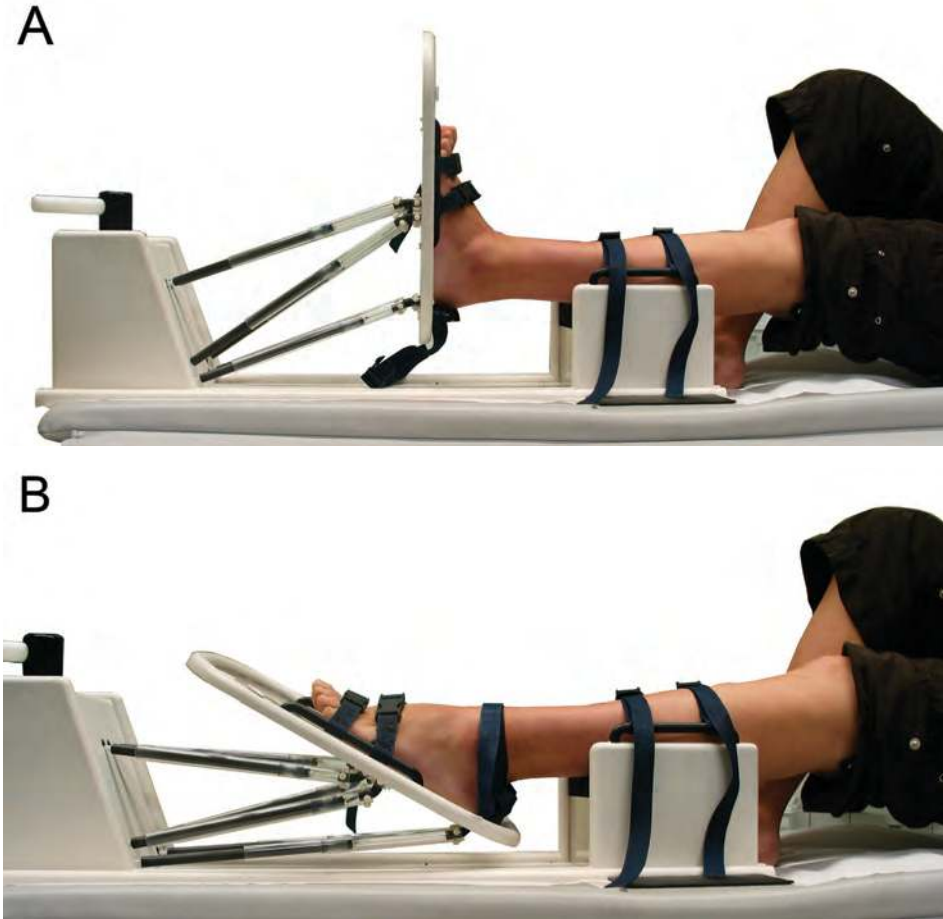


Figure 1. By use of a specially developed 3-dimensional footplate, the affected ankle was fixed and scanned (A) in the neutral (plantigrade) position and (B) in full plantar flexion.

fully plantarflexed ankle positions, using a metal-free 3-dimensional footplate developed in our department (Figure 1). The affected lower leg was placed on a platform positioned 10 cm above the table to allow slight knee flexion and ankle relaxation. The foot was attached to the footplate. The ankle was then manually positioned in maximal plantar flexion, and the footplate was secured in place. Before the scan, we measured the degree of plantar flexion of the affected ankle with a goniometer, using the dorsum of the foot and the anterior side of the lower leg as landmarks in both the neutral and the plantarflexed ankle

positions and then subtracting the neutral from the plantarflexed position.

The CT scan was performed analogous to the protocol described by Beimers et al.⁴⁶ Sagittal 1.0-mm slices were reformatted in two planes, because the lateral and medial talar facets have different anatomic orientations; one set of reconstructions was made parallel to the lateral talar facet and one set parallel to the medial talar facet. These sagittal planes were identified on the original axial scans and reformatted in a standardized fashion. The reconstructed images parallel to the lateral talar facet were used for the

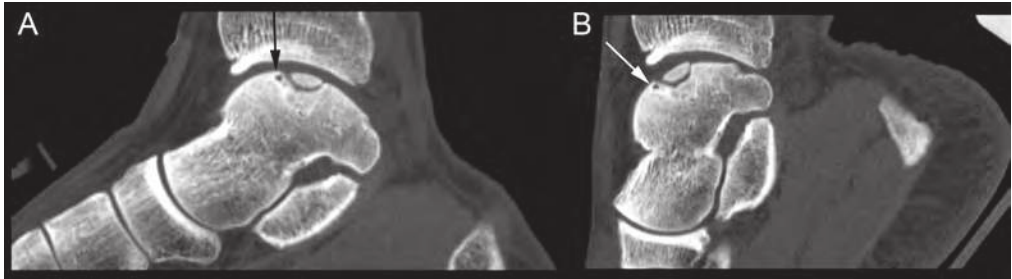


Figure 2. Sagittal reconstructed images of CT scans of an ankle (A) in neutral position and (B) in full plantar flexion. The tube current was 150 mAs for the neutral position and 26 mAs for the plantarflexed position. Although low-dose scans had a lower signal-to-noise ratio, this did not hamper delineation of the defects. The anterior border of the OCD is indicated by the arrows.

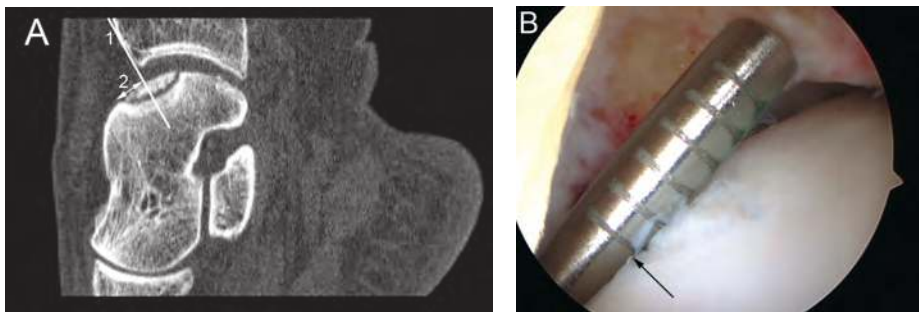


Figure 3. Analysis of a patient with a centromedial OCD. (A) On the CT scan, a tangent line (1) of the anterior distal tibial rim was drawn perpendicularly to the talar dome. The distance (2) from the anterior border of the OCD to this line was measured. (B) During arthroscopy, the distance between the anterior distal tibial rim and anterior border of the defect (arrow) was measured with a specially developed arthroscopic ruler. On this ruler, the first line is 2 mm from the tip and each following line is 1 mm more from the tip, up to 7 mm.

assessment of OCDs located on the lateral talar dome, whereas the images parallel to the medial facet were used for the defects located on the medial talar dome.

For descriptive purposes, the original axial slices of the neutrally positioned ankles were used to divide the location of the OCDs into nine regions according to the anatomic nine-grid scheme described by Raikin et al.³²² For further analysis, the anteromedial, anterocentral, and anterolateral locations were combined into the anterior third of the talar dome; the centromedial, centrocentral, and centrolateral into the central third; and the posteromedial, posterocentral, and posterolateral into the posterior third.

The anterior border of the OCD and the anterior distal tibial rim (i.e., anterior edge of the tibial plafond) were digitally marked on the sagittal reconstructions by the first author in consultation with an orthopaedic surgeon and a musculoskeletal radiologist, using the tools present on the picture archiving and communication system (Impax 5.3.1, Agfa-Gevaert NV, Mortsel, Belgium) of the radiology department. The anterior border of the OCD was defined as the most anterior point of the bony lesion (Figures 2 and 3). Next, two investigators independently measured the distance from the anterior border of the OCD to the anterior distal tibial rim (Figure 3A) as defined by the marks. To analyze intraobserver reliability of the CT measurements, one

investigator (blinded to the first sequence) measured a second time, with a different order of scans.

Arthroscopy

All patients were treated in the supine position under general or spinal anesthesia, with a tourniquet around the upper leg, by a standard arthroscopic technique as previously described.^{424,432} Anteromedial and anterolateral portals were created at the level of the joint line with the ankle initially in dorsiflexion. No additional portals were needed. A 4-mm, 30° arthroscope was routinely used. A local synovectomy around the portal opposite the defect was performed when necessary. With the arthroscopic instruments in the ankle joint, the OCD was brought into view by full plantar flexion of the ankle, which was carried out manually by the assistant. The anterior border of the defect was identified with an arthroscopic hook. The surgeon, blinded to the plantarflexion CT scan, measured the anteroposterior distance between the anterior border of the OCD and the anterior distal tibial rim with the patient's ankle in full plantar flexion, using a specially developed arthroscopic ruler (Figure 3B). After the measurement, in some difficult cases, a small bony rim or osteophyte of the anterior distal tibia was removed with a bonecutter shaver, or noninvasive distraction with a strap around the ankle⁴²⁸ was used to improve exposure. The OCD was treated by debridement from anteriorly to posteriorly and additional microfracturing with a curved microfracture awl. Routine postoperative care and follow-up were arranged.⁴³²

Statistical analysis

The intraobserver and interobserver reliability of the CT measurements were analyzed by computation of intraclass correlation coefficients (ICC)

and systematic differences with 95% confidence intervals (CIs) (paired t-test). According to Fleiss, the reliability is considered good if the ICC is 0.40 to 0.75 and excellent if the ICC is more than 0.75.¹³⁴ The mean of both observers' first series of measurements was used for further analysis, as proposed by Bland and Altman.⁵¹ The correlation of CT and arthroscopic measurements was analyzed by Pearson's correlation coefficient (r). A scatter plot and linear regression analysis were used to analyze the relationship between CT and arthroscopy. Agreement between both measurements was visualized by plotting a Bland and Altman graph.⁵¹ This is a rather strict statistical method for assessing agreement between two methods of clinical measurement and tends to reject rather than falsely accept the new method.⁵¹ A difference between CT and arthroscopic values of less than 2.0 mm was defined as clinically acceptable. This cut off was based on the experience that OCDs within 2 mm of arthroscopic reach can be accessed by shaving off a small rim of the anterior distal tibia. The limits of agreement were calculated (i.e., the mean difference \pm $2 \times$ standard deviation of the mean difference). $P < 0.05$ was considered statistically significant.

Results

The study included 20 consecutive patients (17 men and three women) with a mean age of 33 years (range, 18 – 55 years). In 10 patients the right ankle was affected and in 10 the left. The mean degree of plantar flexion was 42° (standard deviation, 10°). According to the anatomic grid scheme, 10 OCDs were located on the centro-medial talar dome, four posteromedial, three centrolateral, one posterolateral, one anterolateral, and one centrocentral. When combined in thirds from anterior to posterior, the defect was anterior in one patient (5%), central in 14 (70%), and posterior in five (25%) (Figure 4).

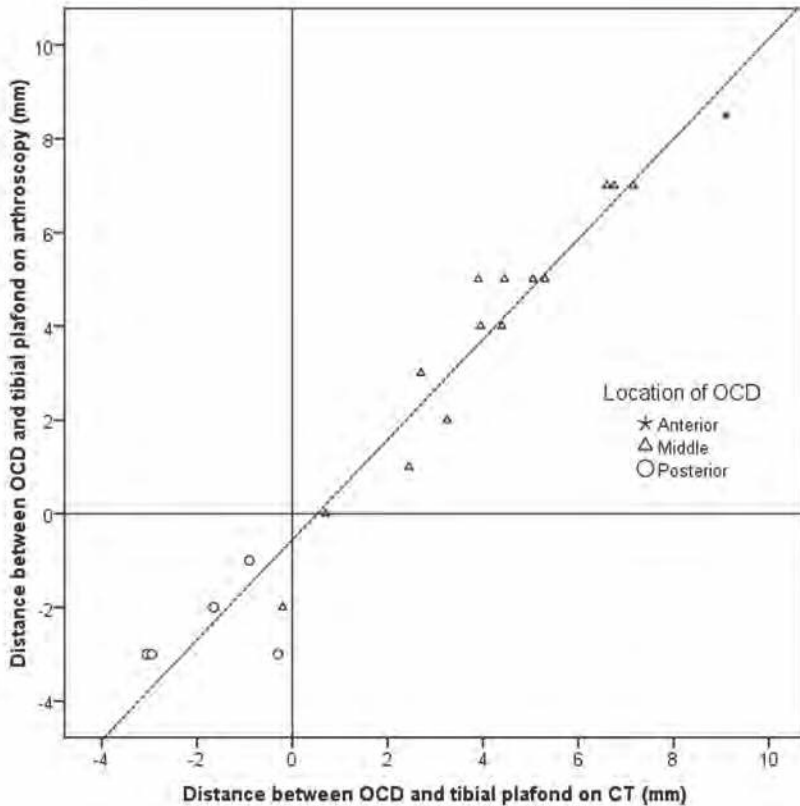


Figure 4. Scatter plot of distance between anterior border of talar osteochondral defect (OCD) and anterior distal tibial rim as measured on CT (x-axis) and anterior ankle arthroscopy (y-axis). The dashed line indicates the relation of these measurements as calculated by linear regression ($y = 1.069x - 0.557$). The distribution of different OCD locations (anterior one-third, middle one-third, and posterior one-third of talar dome) is shown.

On CT, the measured distances between the anterior distal tibial rim and the anterior border of the OCD were as follows. The first observer's first sequence ranged from -2.9 to 9.3 mm (mean, 3.0 mm); the second sequence ranged from -2.8 to 9.2 mm (mean, 3.0 mm). The second observer's measurements ranged from -3.3 to 8.9 mm (mean, 2.7 mm). The mean of both observers' first series of measurements ranged from -3.1 to 9.1 mm (mean, 2.8 mm) (Figure 4). When separated for the anterior, central, and posterior OCDs, the distance measure was 9.1 mm, -0.2 to 7.2 mm (mean, 4.0 mm), and -3.1 to -0.3 mm (mean, -1.8 mm), respectively. Both the intraobserver reliability and

interobserver reliability were excellent (ICC, 0.998 and 0.997, respectively; $p < 0.001$). The intraobserver systematic difference was not statistically significant (mean, 0.051 mm, 95% CI, -0.061 to 0.15 mm), but there was a significant interobserver systematic difference (mean, 0.37 mm; 95% CI, 0.24 to 0.50 mm; $p < 0.001$).

With arthroscopy, the measured distance between the anterior distal tibial rim and the anterior border of the OCD ranged from -3.0 to 8.5 mm (mean, 2.5 mm) (Figure 4). The distance measure was 8.5 mm for the anterior lesion, -2.0 to 7.0 mm (mean, 3.8 mm) for the central lesions, and -3.0 to -1.0 mm (mean, -2.4 mm) for the posterior lesions, respectively.

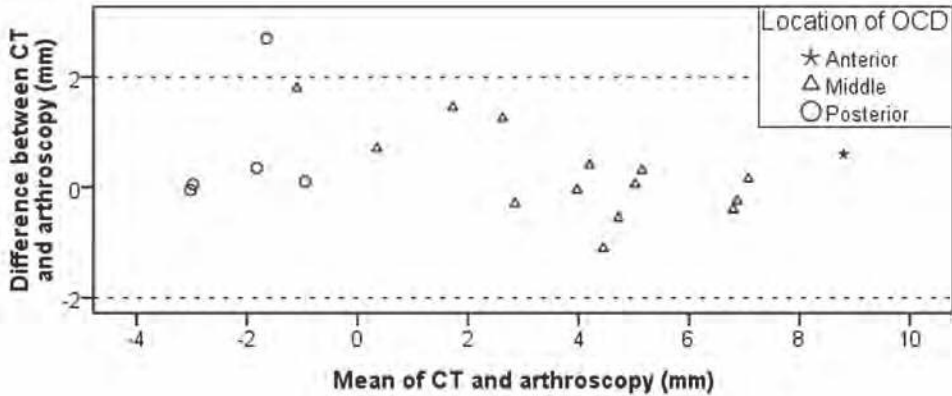


Figure 5. Bland and Altman plot⁵¹ showing difference against mean of distances measured on CT scans and arthroscopy. A difference between CT and arthroscopy of less than 2.0 mm was considered clinically acceptable (dashed lines). The limits of agreement are -1.4 to 2.1 mm.

There was an excellent correlation ($r = 0.975$; $p < 0.001$) between CT and arthroscopy. There was no statistically significant systematic difference (mean, 0.36 mm, 95% CI, -0.051 to 0.77). Linear regression showed that the relation of CT to arthroscopy was expressed by $y = 1.069x - 0.557$ (Figure 4). There was one subject with a difference of more than 2.0 mm (Figure 5). The limits of agreement were -1.4 to 2.1 mm.

Discussion

This study shows that CT of the ankle in full plantar flexion is an accurate and reliable preoperative planning tool to determine the anterior arthroscopic accessibility of a talar OCD. This is evidenced by the agreement (Figure 5) and correlation ($r = 0.975$) of CT and anterior ankle arthroscopy with respect to the distance between the OCD and the anterior distal tibial rim. There was only one patient with a difference between CT and arthroscopy greater than 2.0 mm. Furthermore, the formula expressing the relation of CT to arthroscopy approximates a perfect relation of $y = x$ (Figure 4). This scan is now

incorporated into routine preoperative planning in our orthopaedic service.

From the location of the OCD, it can be postulated how accessible the defect will be (Figure 4). All OCDs that were located in the anterior or central third of the talar dome were in easy arthroscopic reach, whereas all posterior OCDs were more difficult to access because they were located posteriorly to the anterior distal tibial rim. Because the location of the OCD on the plantarflexion scan corresponds well to the arthroscopic location, the CT scan can be used reliably to predict the arthroscopic reach of the OCD: if the anterior border of the defect is located anteriorly to the anterior distal tibial rim on the plantarflexion scan – which was the case in the anterior lesion and in all but one of the central lesions – the OCD will be accessible through anterior arthroscopy. Even when the OCD is located behind the anterior distal tibial rim with maximal plantar flexion of the ankle, it can often still be reached by anterior arthroscopy. Access in these posterior lesions depends on various parameters, such as ankle range of motion, joint laxity, and the presence of osteophytes, as well as surgical methods. Removal of osteophytes and joint opening in case of ligament laxity will

ease the access. Therefore, general recommendations for doubtful cases – especially posterior lesions – cannot be given. The decision for the most appropriate operative approach in posterior lesions thus remains at the discretion of the surgeon. Nevertheless, the CT scan does provide reliable data on the expected arthroscopic location of the OCD, thus facilitating preoperative planning.

To determine exactly if the scan can differentiate between accessible and inaccessible defects, an additional study would have to be performed in which all plantarflexed scans are judged preoperatively by the surgeon, determining whether it is possible to reach the defect with anterior arthroscopy, and then anterior arthroscopy would be performed in all lesions – even when the surgeon finds this approach inappropriate. Because some patients would undergo a surgical procedure without treatment, this study setup seems unethical. Therefore, the indirect study method was applied as outlined in the paper. With this method, it was shown that the location of the OCDs correlates well between the plantarflexed CT and anterior arthroscopy.

Different surgical methods could be used to improve the exposure if necessary. For example, three patients in the study group had anterior tibial osteophytes. Their removal improved the accessibility of the OCD. Because these osteophytes were shown on CT, they did not interfere with the correlation and agreement between CT and arthroscopy, because all measurements were performed before removal of osteophytes. Likewise, access to the defects located posterior to the anterior distal tibial rim could be improved by removing a small part of the rim using a bonecutter shaver (after measuring the distance of OCD to anterior distal tibial rim with an arthroscopic ruler) or using temporary noninvasive distraction. With noninvasive distraction, the force of distraction was not

actually measured in this group, but it was 110 N in OCD patients in a previous study.⁴²⁸

The optimal surgical approach depends on the characteristics of the OCD and the patient, the type of treatment, and the experience of the surgeon.^{296,408} Anterior arthroscopic ankle surgery is the primary treatment of choice and has the advantages of enhanced visualization, outpatients' treatment, less postoperative morbidity than open surgery, and early functional rehabilitation.^{93,348,432} Alternative approaches are posterior arthroscopy or open surgery with or without a malleolar osteotomy.^{296,427,432} Saxena and Eakin treated OCDs arthroscopically when they were located within the anterior 50% of the talar dome.³⁴³ They performed an arthrotomy with or without osteotomy in 13 of the 26 patients who underwent microfracture. Likewise, in a study of 44 patients with 45 OCDs that were initially accessed by anterior ankle arthroscopy, Hankemeier et al. converted to an arthrotomy in 13 and to a medial malleolar osteotomy in 12 because of insufficient access.¹⁷⁹ These patients may have benefitted from more precise preoperative planning.

The intraobserver and interobserver reliability of measurements on CT was excellent. There was no statistically significant intraobserver systematic difference. However, the interobserver systematic difference was 0.37 mm ($p < 0.001$). The source of this difference might have been slight differences in drawing the tangent line of the anterior distal tibial rim, or the level in the ankle joint at which the measurements were made. A level of measurement that is more superior results in a higher distance, because the lines of the anterior OCD and the anterior distal tibial rim cross the talus perpendicularly and are thus divergent (see Figure 3). Though statistically significant, the interobserver difference is so small that it may not be clinically relevant, because 0.37 mm is probably too small to differentiate between an accessible and inaccessible OCD.

Alternatively to CT scans, radiographs might be used to estimate the arthroscopic reach, with the advantages of general availability, less radiation and lower costs. However, talar OCDs are rarely visible on lateral radiographs, and the dimensions are underestimated.¹⁰⁵ Radiographs thus seem to be inappropriate for preoperative planning.

Strengths of this study are the prospective method, the consecutive and representative series of patients, the blinded comparison of arthroscopy and CT, and the clinical relevance. The number of patients, though relatively small, is supported by a power analysis.⁴⁴³ The study group is diverse and representative for a larger population. The distribution of the OCDs' location in the studied population corresponds to a survey of 428 OCDs in 424 patients.³²² In this survey, 6% of the lesions were located in the anterior third, 81% in the middle third, and 14% in the posterior third, compared with 5%, 70%, and 25%, respectively, in the present study.

There are also limitations. There are inherent differences between CT and arthroscopy. The bony defect was assessed on CT, whereas the articular surface (i.e., the cartilage lesion) was assessed with arthroscopy. Furthermore, the degree of plantar flexion may differ between the CT and arthroscopy because of the effects of anesthesia and the lack of pain. The plantarflexion angle was not investigated with patients under anesthesia. Despite these differences, there was excellent agreement and no significant difference of the distances evaluated by CT and

arthroscopy, thus supporting the reliability and usefulness of CT scans.

A disadvantage of the additional CT scan is exposure to radiation. The Committee of Radiation at our hospital has estimated the radiation of the low-dose plantarflexion scan to be 0.02 mSv. This is categorized as a "trivial" risk for average adults by the International Commission on Radiological Protection.¹ The natural background effective dose rate varies considerably from place to place but typically is around 2.4 mSv/yr. The additional radiation of the CT scan can thus be considered acceptable. To reduce the total radiation dose, one may consider acquiring only the plantarflexion CT scan and omitting the plantigrade scan.

Conclusion

Measurements on CT scans of the ankle in full plantar flexion are a reliable and accurate preoperative method to determine the in situ arthroscopic location of talar OCDs.

Acknowledgment

The authors thank I.N. Sierevelt, M.Sc., from the Orthopaedic Research Center Amsterdam, Department of Orthopaedic Surgery, Academic Medical Center, for statistical advice and M. Poulus and M. Schrijnders from the Department of Radiology, Academic Medical Center, for technical support.