

Congenital-Infantile Fibrosarcoma

A Clinicopathologic Study of 10 Cases and Molecular Detection of the *ETV6-NTRK3* Fusion Transcripts Using Paraffin-Embedded Tissues

Wei-Qi Sheng, MD,^{1,2*} Masanori Hisaoka, MD,¹ Sumika Okamoto, MD,¹ Atsuko Tanaka,¹ Jeanne M. Meis-Kindblom, MD,³ Lars-Gunnar Kindblom, MD,³ Tsuyoshi Ishida, MD,⁴ Takayuki Nojima, MD,⁵ and Hiroshi Hashimoto, MD¹

Key Words: Congenital-infantile fibrosarcoma; *ETV6-NTRK3* fusion transcripts; NTRK3; Reverse transcription–polymerase chain reaction; RT-PCR; Immunohistochemistry

Abstract

Congenital-infantile fibrosarcoma (CIFS) is a relatively indolent sarcoma that should be distinguished from more aggressive spindle cell sarcomas of childhood. CIFSs have been found to have a novel recurrent reciprocal translocation t(12;15)(p13;q25) resulting in the gene fusion ETV6-NTRK3 (ETS variant gene 6; neurotrophic tyrosine kinase receptor type 3). We studied immunohistochemical expression of NTRK3, and conducted a reverse transcription–polymerase chain reaction (RT-PCR) assay to detect the ETV6-NTRK3 fusion transcripts using archival formalin-fixed paraffin-embedded tissues from 10 CIFSs. Thirty-eight other spindle cell tumors were included as controls.

The ETV6-NTRK3 fusion transcripts were identified in 7 (70%) of 10 CIFSs. Nucleotide sequence analysis showed that the fusion occurred between ETV6 exon 5 and NTRK3 exon 13. The 38 control tumors were negative for the fusion transcript. Immunohistochemically, CIFSs consistently expressed NTRK3. But the expression of NTRK3 also was observed in 22 of 38 control tumors. These results show the diagnostic usefulness of RT-PCR methods to detect ETV6-NTRK3 fusion transcripts in archival formalin-fixed paraffin-embedded tissue and the important role of NTRK3 in the development of CIFS, despite its being a protein of little importance in differential diagnosis.

Although most fibrosarcomas occur in adults, 25% to 40% occur in children during the first 5 years of life.¹ Despite a similar histologic appearance, congenital-infantile fibrosarcoma (CIFS) is much less aggressive than adult-type fibrosarcoma.^{2,3} Its distinction from infantile fibromatosis may be extremely difficult owing to closely overlapping clinical and histologic features. Why the two should be distinguished has, in fact, been questioned.^{4,5} Moreover, distinction of CIFS from other spindle cell sarcomas of childhood, such as spindle cell rhabdomyosarcoma, hemangiopericytoma, monophasic fibrous synovial sarcoma, malignant peripheral nerve sheath tumor (MPNST), and leiomyosarcoma, is also problematic.

Recently, Knezevich et al⁶ found a novel gene fusion, *ETV6-NTRK3* (ETS variant gene 6; neurotrophic tyrosine kinase receptor type 3), in CIFS resulting from a recurrent chromosomal rearrangement of t(12;15)(p13;q25). By using frozen tissues, the fusion gene was demonstrated in 4 cases of CIFS examined by Knezevich et al,⁶ 5 cases examined by Rubin et al,⁷ and 9 cases examined by Bourgeois et al.⁸ This gene fusion also has been identified in congenital mesoblastic nephroma, which shares some histologic features with CIFS and establishes a histogenetic link between the two lesions.^{7,9,10} The uniqueness of the *ETV6-NTRK3* gene fusion is potentially a useful diagnostic tool, since it has not been detected in other soft tissue spindle cell lesions, including infantile fibromatosis and adult-type fibrosarcoma.^{6,8} *ETV6-NTRK3* has been detected in paraffin-embedded tumor samples of CIFS in only 2 of 3 cases.⁸ Thus, we performed an immunohistochemical study for NTRK3 expression in CIFS and conducted a reverse transcription–polymerase chain reaction (RT-PCR) assay to assess the specificity of *ETV6-NTRK3* fusion transcripts detected in archival formalin-fixed paraffin-embedded tissues of CIFS.

Materials and Methods

Cases of CIFS and other spindle cell lesions were retrieved from the files of the Department of Pathology and Oncology, School of Medicine, University of Occupational and Environmental Health, Kitakyushu, Japan; the Department of Pathology, Sahlgrenska University Hospital, Gothenburg University, Gothenburg, Sweden; the Department of Pathology, Tokyo University Hospital, Tokyo, Japan; and the Department of Pathology, Kanazawa Medical College Hospital, Kanazawa, Japan. The study included CIFS (10 cases), adult-type fibrosarcoma (7 cases), leiomyosarcoma (4 cases), a storiform-pleomorphic variant of malignant fibrous histiocytoma (4 cases), monophasic synovial sarcoma (4 cases), MPNST (3 cases), dermatofibrosarcoma protuberans (4 cases), schwannoma (4 cases), fibromatosis (4 cases), and nodular fasciitis (4 cases). H&E-stained sections of each case were reexamined, and representative paraffin blocks were selected for this analysis. Clinical data were reviewed, and follow-up information was obtained in all instances except 1 recent case.

Immunohistochemical Studies

A standard avidin-biotin complex method was used. Polyclonal rabbit anti-NTRK3 (also referred to as TrkC) immunoglobulin (798), recognizing an epitope corresponding to amino acids 798 to 812 of porcine TrkC p140 (1:100 dilution), was purchased from Santa Cruz Biotechnology (Santa Cruz, CA). Immunostainings were performed using the following panel of antibodies: CD34 (QBEND 10, Immunotech, Marseilles, France), alpha-smooth muscle actin (alpha-SMA) (1A4, Sigma, St Louis, MO), muscle-specific actin (HHF35, Enzo, New York, NY), desmin (D33, DAKO, Glostrup, Denmark), S-100 protein (DAKO), cellular adhesion molecule 5.2 (CAM5.2, Becton Dickinson, San Jose, CA), cytokeratin clone AE1 and AE3 (AE1/AE3, Boehringer Mannheim, Indianapolis, IN), epithelial membrane antigen (DAKO), L26 (DAKO), CD45RO (clone UCHL-1, DAKO), CD3 (DAKO), CD4 (Novocastra, Newcastle upon Tyne, England), and CD8 (DAKO).

For NTRK3 immunostaining, dewaxed tissue sections were subjected to a microwave pretreatment (a 10-mmol/L concentration of sodium citrate buffer, pH 7.0, for 20 minutes at 600 W). Normal brain tissue was used as a positive control, and a negative control was obtained by exclusion of the primary antibody.

RNA Extraction

RNA was extracted from formalin-fixed paraffin-embedded tissues according to previously described methods.^{11,12} Briefly, tissue sections were cut from each representative paraffin block and deparaffinized with 2 changes of

xylene and 3 washes with 100% ethanol. Tissue fragments were homogenized in 200 μ L of lysis buffer (20 mmol/L tris(hydroxymethyl)aminomethane hydrochloride, pH8.0; a 20-mmol/L concentration of EDTA; and 2% sodium dodecyl sulfate). They were then treated with 10 μ L of proteinase K (100 mg/mL) and incubated at 55 C for 48 hours. Total RNA was extracted using Trizol reagent (Gibco BRL, Gaithersburg, MD), according to the manufacturer's protocol and resuspended in 10 to 30 μ L of water free of deoxyribonuclease (DNase) and ribonuclease (RNase). The RNA solution was treated with DNase I (Gibco BRL) for 15 minutes at 37 C.

RT-PCR and DNA Sequencing

Complementary DNA (cDNA) was synthesized using 10 μ L of dissolved RNA, 1 μ L of random primer (Gibco BRL), and 200 U of reverse transcriptase (Superscript II, Gibco BRL). Generated cDNA then was treated with 60 U of RNase H (Takara, Ohtsu, Japan) for 20 minutes at 37 C. To assess the integrity of RNA, parallel PCR for an internal positive control of the porphobilinogen deaminase (*PBGD*) gene was performed with the following primers: *PBGD-S* (5'-TGTCTGGTAACGGCAATGCGGCTGCAAC-3') and *PBGD-A* (5'-TCAATGTTGCCACCACACTGTCCGTCT-3').¹³ These primers amplified a 127-base-pair (bp) fragment of the *PBGD* gene.

To detect the *ETV6-NTRK3* fusion transcripts in formalin-fixed paraffin-embedded tissue samples, we designed a pair of primers that specifically amplify a relatively small 111-bp region flanking the published fusion point of the *ETV6-NTRK3* gene transcript (Oligo Primer Analysis Software, Molecular Biology Insight, Cascade, CO). The *ETV6* forward primer was 5'-GCTTACATGAAC-CACATCATGG-3', and the *NTRK3* reverse primer was 5'-GAAGTCGTGCTACAGAGAGG-3'. PCR was performed under the following conditions: 94 C for 10 minutes followed by 45 cycles at 94 C for 50 seconds, 60 C for 30 seconds, 72 C for 1 minute, and a final extension at 72 C for 10 minutes. In each PCR procedure, a no-reverse transcription control, a no-cDNA template control, and a known fusion transcript-positive case of congenital mesoblastic nephroma (positive control) were included. The positive PCR products were cloned into a pCR2.1 vector using a TA cloning kit (Invitrogen, San Diego, CA) and sequenced by an automated sequencing system (ALFexpress DNA sequencer; Pharmacia Biotech, Uppsala, Sweden).

Results

Clinical Summary

Clinical data for the 10 patients with CIFS are summarized in **Table 1**. There were 7 male and 3 female infants

Table 1
Clinical Data for 10 Cases of Congenital-Infantile Fibrosarcoma

Case No./Sex/Age (mo)	Tumor Location	Tumor Size (cm)	Follow-up
1/F/2	Lower leg (L)	2.5 · 3.5	No evidence of disease, 29 y
2/M/1	Thigh (R)	6 · 3 · 2	No evidence of disease, 28 y
3/F/3	Jaw angle (L)	NA	No evidence of disease, 31 y
4/F/3	Wrist (R)	2 · 2	No evidence of disease, 32 y
5/M/3	Lower leg	NA	No evidence of disease, 22 y
6/M/3	NA	NA	No evidence of disease, 14 y
7/M/1	Lower leg (L)	5.5 · 3.6 · 3.2	Recent case
8/M/4	Lower leg (L)	4 · 2 · 1	No evidence of disease, 22 y
9/M/3	Thigh (L)	10 · 8	No evidence of disease, 28 y
10/M/7	Ankle (L)	2.8 · 1	No evidence of disease, 15 y

NA, not available.

ranging from 1 to 7 months of age at diagnosis. Four tumors occurred in the lower leg, 2 in the thigh, 1 on the head, 1 in the wrist, and 1 in the ankle. The main symptom was a mass or swelling of the soft tissues. All lesions were locally excised with adequate margins. All patients were alive and well without local recurrence or metastasis after a follow-up of 14 to 32 years.

Pathologic Findings

Tumor size (known in 7 cases) ranged from 2 to 10 cm in the greatest dimension. The cut surface was firm, fleshy, and gray-white. Focal cystic change was seen in 1 tumor (case 9); hemorrhage and necrosis were not observed.

Microscopically, most tumors were cellular and composed of uniform oval to spindle-shaped cells with hyperchromatic nuclei separated by variable amounts of collagen. One case, however, had a small number of large, bizarre tumor cells (case 9). All tumors were composed of elongated cells arranged in fascicles. In 3 lesions, a herringbone pattern similar to that of adult-type fibrosarcoma was seen (Image 1). Three tumors displayed a prominent hemangiopericytoma-like vascular pattern (Image 2). In case 2, the tumor was less structured and consisted mainly of more immature, small, round to oval cells with minimal amounts of collagen. Eight of 10 cases had patchy to diffuse chronic inflammatory cell infiltrates composed predominantly of lymphocytes. The number of mitoses per 10 high-power fields ($\times 400$) was 1 to 4 in 6 cases, 5 to 9 in 2 cases, and 10 or more in 2 cases. Diffuse infiltration of neighboring fat or skeletal muscle was observed in all cases. Tumor necrosis or hemorrhage was not observed microscopically in any case.

Immunohistochemical Results

Immunohistochemical staining results are summarized in Table 2. All 10 CIFSs had membranous and cytoplasmic staining for NTRK3 (Image 3). In 8 cases, more than 50% of the tumor cells were positive for NTRK3. NTRK3 also was

found in leiomyosarcoma (4/4), nodular fasciitis (4/4), fibromatosis (4/4), MPNST (3/3), schwannoma (3/4), adult-type fibrosarcoma (2/7), and malignant fibrous histiocytoma (2/4).

Two of 10 CIFSs were positive for CAM5.2; 1 tumor showed patchy (case 4) and 1 showed diffuse staining (case 6). Diffuse S-100 protein immunostaining was seen in 1 tumor (case 7); this case also was focally positive for alpha-SMA and HHF35. Focal reactivity for desmin was seen in 1 case (case 9). None of the CIFSs was positive for CD34, AE1/AE3, or epithelial membrane antigen.

Except for case 9, 7 of 8 CIFSs with chronic inflammatory infiltrates were available for analysis of the immunophenotype of these inflammatory cells. The majority of the cells were T cells (positive for CD45RO and CD3), while a small number of them were B cells (positive for L26). CD8+ T cells were obviously much more in quantity than CD4+ cells. We found no difference in the cellular phenotype among these 7 cases.

RT-PCR and Sequencing

The results of RT-PCR are summarized in Table 3. The *PBGD* gene transcripts were amplified consistently in all 10 CIFSs. By using the *ETV6* forward primer and the *NTRK3* reverse primer, 111-bp fragments were identified in 7 of 10 CIFSs, including the case with a small number of large, bizarre tumor cells, 3 tumors displaying a hemangiopericytoma-like vascular pattern, and 2 of 3 tumors with a herringbone pattern (Image 4). In the 8 tumors with inflammatory cell infiltrates, 1 tumor (case 10) was negative for the fusion transcripts, while the others were positive. Nucleotide sequencing of these PCR products demonstrated that *ETV6* exon 5 was fused consistently to *NTRK3* exon 13 (Figure 1). There was no apparent relationship among *ETV6-NTRK3* fusion transcript detection, the immunohistochemical staining results, and specific microscopic features.

ETV6-NTRK3 fusion transcripts were not detected in any of the 38 control lesions, including 7 adult fibrosarcomas and 4 fibromatoses.

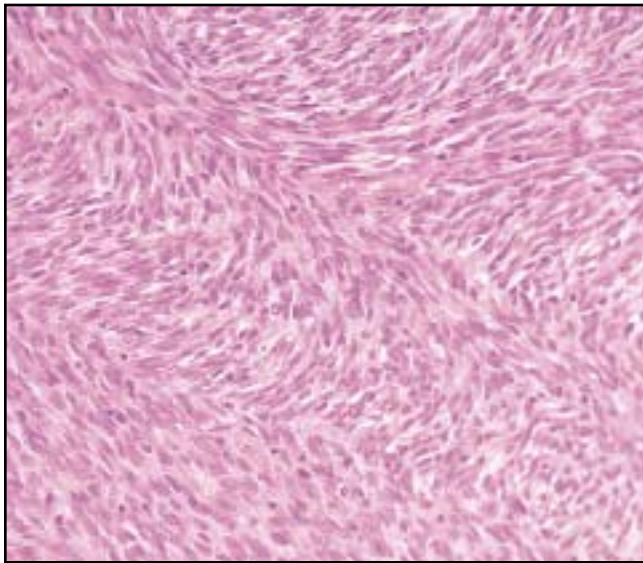


Image 1 (Case 6) Congenital-infantile fibrosarcoma with a prominent herringbone pattern (H&E, ×100).

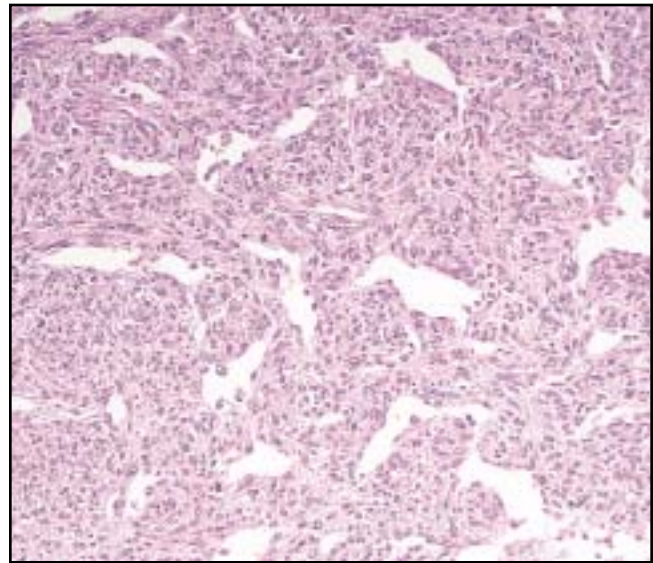


Image 2 (Case 5) Congenital-infantile fibrosarcoma with a hemangiopericytoma-like appearance (H&E, ×100).

Discussion

The clinicopathologic features of our cases are similar to several published series of CIFS.^{1,14-16} However, the reported rates of local recurrence and distant metastasis^{5,14,15} are quite variable; in contrast, there were none in our series.

The differential diagnosis of pediatric soft tissue spindle cell lesions is indeed difficult. Infantile fibromatosis, especially a cellular variant designated *aggressive fibromatosis*, is probably the most difficult one to diagnose. The degree of cellularity, exhibited as alternating cellular and more collagenous areas; foci of residual fat or muscle; and an infiltrative growth pattern are all features of aggressive fibromatosis that overlap with CIFS, making it difficult to distinguish between the lesions.^{17,18} However, the distinction is not so critical owing to their similar biologic behaviors.

Inflammatory myofibroblastic tumor/inflammatory fibrosarcoma (IMT), which also affects infants and young children, may arise in the histologic differential diagnosis if a prominent chronic inflammatory infiltrate is present. However, the clinical features of IMT differ from CIFS.^{19,20} Recent identification of the *TPM-ALK* fusion gene and expression of the *ALK* gene in a subset suggest that IMT has a distinctive genetic background.²¹⁻²³

The CIFSs with considerable vascularity also should be distinguished from infantile hemangiopericytoma and infantile myofibromatosis. Infantile hemangiopericytoma usually is located superficially and has a distinct lobular arrangement with more regularly distributed vessels, whereas infantile myofibromatosis displays a typical zonal appearance with distinct myofibroblastic differentiation.²⁴

Table 2
Immunohistochemical Results for 10 Cases of Congenital-Infantile Fibrosarcomas

Case No.	NTRK3	S-100*	CAM5.2	AE1/AE3	EMA	alpha-SMA	HHF35	Desmin*	CD34*
1	+	-	-	-	-	-	-	-	-
2	++	-	-	-	-	-	-	-	-
3	+	-	-	-	-	-	-	-	-
4	++	-	+	-	-	-	-	-	-
5	++	-	-	-	-	-	-	-	-
6	++	-	++	-	-	-	-	-	-
7	++	++	-	-	-	+	+	-	-
8	++	-	-	-	-	-	-	-	-
9	++	-	-	-	-	-	-	+	-
10	++	-	-	-	-	-	-	-	-

AE1/AE3, cytokeratin clone AE1 and AE3, Boehringer Mannheim, Indianapolis, IN; alpha-SMA, alpha-smooth muscle actin, 1A4, Sigma, St Louis, MO; CAM5.2, cellular adhesion molecule 5.2, Becton Dickinson, San Jose, CA; EMA, epithelial membrane antigen, DAKO, Glostrup, Denmark; HHF35, muscle-specific actin, Enzo, New York, NY; NTRK3, neurotrophic tyrosine kinase receptor type 3, Santa Cruz Biotechnology, Santa Cruz, CA; -, negative; +, less than 50% immunoreactive cells; ++, 50% or more immunoreactive cells. * CD34, QBEND 10, Immunotech, Marseilles, France; desmin, D33, DAKO; S-100, DAKO.

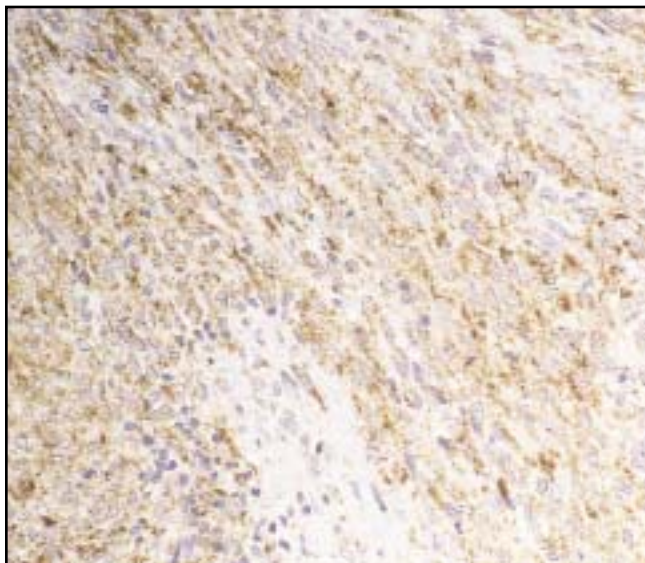


Image 3 Congenital-infantile fibrosarcoma with positive immunostaining for NTRK3 (×200).

Immunohistochemically, 2 of our cases expressed low-molecular-weight cytokeratin (CAM5.2); 1 was positive for S-100 protein, alpha-SMA, and HHF35, and 1 was focally positive for desmin. Coffin et al⁵ identified actin-positive cells in 30% of CIFS cases and desmin in 19%. The actin-positivity seems to represent myofibroblastic differentiation based on corroborating ultrastructural studies.¹⁶

The expression of cytokeratin and S-100 protein in CIFS has been noted in some cases.^{3,25,26} This immunophenotypic diversity may cause problems in differentiating CIFS from MPNST, spindle cell rhabdomyosarcoma, leiomyosarcoma, and synovial sarcoma in infants and young children. However, a serpentine or wavy nuclear contour, nuclear palisading, and distinctly alternating hypercellular and hypocellular zones characteristic of MPNST²⁷ were not

Table 3
Molecular Genetic Findings for 10 Cases of Congenital-Infantile Fibrosarcomas

Case No.	Porphobilinogen Deaminase	<i>ETV6-NTRK3</i>
1	+	-
2	+	-
3	+	+
4	+	+
5	+	+
6	+	+
7	+	+
8	+	+
9	+	+
10	+	-

ETV6, ETS variant gene 6; *NTRK3*, neurotrophic tyrosine kinase receptor type 3.

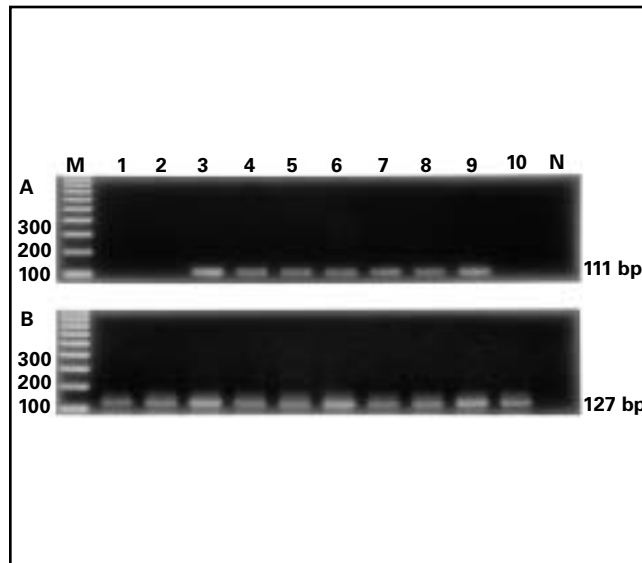


Image 4 Polymerase chain reaction detection of the *ETV6-NTRK3* (A) and porphobilinogen deaminase (B) transcripts in 10 cases of congenital-infantile fibrosarcoma. The lane number represents the case number. M, 100-base-pair (bp) DNA ladder; N, no complementary DNA.

observed in our cases. Spindle cell rhabdomyosarcoma has a predilection for the paratesticular area and demonstrates cross-striations and invariably strong desmin expression.²⁸ Pediatric leiomyosarcomas are extremely rare; most of these are reported as low-grade and display typical smooth muscle features, such as interwoven fascicles of spindle cells with cigar-shaped nuclei and well-delineated eosinophilic, fibrillary cytoplasm.²⁹ Uncommonly, synovial sarcoma may occur in infancy.^{30,31} We found 3 such cases, 2 of which were misdiagnosed previously as CIFS. They had plumper nuclei, focal whorled cell arrangements, and many mast cells. These cases strongly expressed cytokeratin, and the *SYT-SSX* fusion transcript was identified.³²

In our 7 CIFSs with inflammatory cell infiltrates, we found that T lymphocytes were more prominent than B lymphocytes, and most of the T cells were CD8+ cytotoxic or suppressor T cells. We did not find a relationship between RT-PCR results and immunophenotypes of the infiltrating inflammatory cells. But the number of our cases was small, and further studies of a large number of cases are necessary.

In the present study, we identified the fusion transcripts in 7 (70%) of 10 cases of CIFS, all of which were studied by RT-PCR using archival, formalin-fixed, paraffin-embedded tissues. Nucleotide sequence analyses of the positive PCR products revealed that exon 5 of the *ETV6* gene was fused consistently with exon 13 of the *NTRK3* gene, as reported previously.⁶⁻¹⁰ No fusion transcripts were demonstrated in 38 other spindle cell lesions, including 7 adult-type fibrosarcomas and 4 fibromatoses, although the *PBGD*

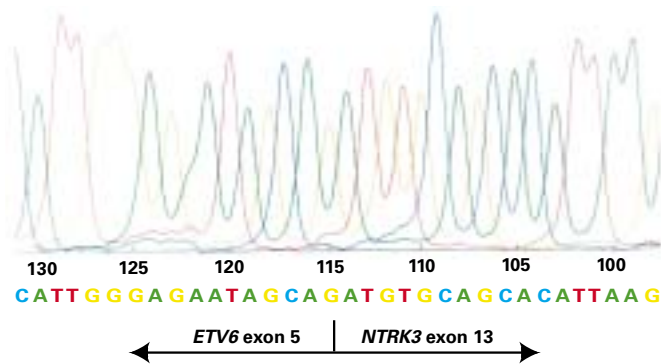


Figure 1 Nucleotide sequence analysis of polymerase chain reaction products showing *ETV6* exon 5 fused to *NTRK3* exon 13.

housekeeping gene was amplified in these cases. The detection of *ETV6-NTRK3* fusion transcripts in most CIFSs indicates that this RT-PCR is a diagnostically useful technique when analyzing formalin-fixed paraffin-embedded tissues. This view is in line with that of a recent study, although only 3 paraffin-embedded CIFSs were examined.⁸

Although 127-bp fragments of the *PBGD* gene were amplified in all 10 CIFSs, 3 were negative for *ETV6-NTRK3* fusion gene transcript. Failure to detect the fusion transcript in these cases probably was not due to the RNA degradation, since the amplified fragment of the fusion transcript (111 bp) is smaller than that of the *PBGD* gene transcript (127 bp). Similar to the findings of Argani et al,¹⁰ our primers recognized only part of the fusion transcript covering the previously described fusion point; they could not amplify variant fusion transcripts containing unknown fusion points.

NTRK3 is a member of the *NTRK* family of receptor protein tyrosine kinase that binds with neurotrophin-3 and mediates nervous system growth and development.^{33,34} Its expression has been found primarily to be restricted to neuronal cells.³⁵ A recent study has shown that *NTRKs* also are expressed in human nonneuronal tissues, including epithelium and smooth muscle of the colon, as well as skeletal muscle, but not normal fibroblasts.³⁶ Chromosome translocations resulting in fusion of *ETV6* (which is expressed in a wide variety of mammalian tissues) and *NTRK3* seem to induce the expression of a fusion protein that contains an intracellular tyrosine kinase domain of *NTRK3*.^{6,37,38} A recent study demonstrated that the *ETV6-NTRK3* chimeric protein is an oncoprotein with potent transforming activity in NIH3T3 cells.³⁷ Dimerization of the chimeric protein (mediated by the helix-loop-helix domain of *ETV6*) has been suggested to cause activation of the protein tyrosine kinase domain in *NTRK3*, thus producing an oncogenic effect by dysregulation of *NTRK3* signal-transduction pathways.³⁷

It is possible that other mechanisms, such as point mutations, also are involved in activation of the *NTRK3* gene and

the development of CIFS. Since the tyrosine kinase receptor gene can be a target for point mutations associated with tumors or other diseases,³⁸ we suspect that the *NTRK3* gene might be activated by point mutations in the fusion gene-negative tumors. However, we could not identify any point mutations in the main portion of the intracellular tyrosine kinase domain (exons 13-18) of *NTRK3*³⁸ using PCR-single-strand conformation polymorphism analysis (unpublished data). Further studies are necessary to elucidate other unknown mechanisms of *NTRK3* overexpression in fusion-negative tumors.

In the present study, we also examined the immunohistochemical expression of *NTRK3* in CIFS to corroborate its oncogenetic function in this tumor. In contrast with the results of Bourgeois et al,⁸ who found only low and inconsistent expression of *NTRK3* in 5 CIFSs, all 10 CIFSs in the present study expressed *NTRK3*, including the 3 fusion transcript-negative cases. The antibody used recognizes a carboxyl terminal portion of *NTRK3*; hence, the *NTRK3*-positive immunohistochemical staining results suggest aberrant expression of *NTRK3* or *NTRK3*-related molecules, most of which seem to be the result of the *ETV6-NTRK3* fusion gene. Thus, unscheduled expression of *NTRK3* or an *NTRK3*-derived protein seems to be important in the development of CIFS. Since the immunohistochemical expression of *NTRK3* also was observed in other spindle cell tumors and tumor-like lesions (mentioned in the “Results” section), we think it is not helpful to the differential diagnosis.

CIFS is a distinctive spindle cell tumor of newborns and infants with a favorable prognosis. It may be difficult to distinguish from other pediatric spindle cell sarcomas and sarcomatous lesions owing to histologic and immunophenotypic variations. The detection of *ETV6-NTRK3* fusion transcripts in most CIFSs using RT-PCR methods with archival, formalin-fixed, paraffin-embedded tissues therefore is a useful diagnostic adjunct. Aberrant expression of *NTRK3* owing to gene rearrangement or unknown genetic alteration seems to be an important oncogenetic factor in CIFS.

*From the Departments of*¹*Pathology and Oncology, University of Occupational and Environmental Health (UOEH), Kitakyushu, Japan;*²*Pathology, Shanghai Cancer Hospital, Shanghai Medical University, Shanghai, People’s Republic of China;*³*Pathology, Sahlgrenska University Hospital, Gothenburg University, Gothenburg, Sweden;*⁴*Pathology, Faculty of Medicine, University of Tokyo Hospital, Tokyo; and*⁵*Pathology, Kanazawa Medical College Hospital, Kanazawa, Japan.*

Supported in part by the Vehicle Racing Commemorative Foundation, Tokyo, Japan; the Swedish Cancer Foundation, Stockholm, Sweden; the Lundberg Foundation, Gothenburg, Sweden; the Johan Jansson Foundation, Gothenburg, Sweden; and project research from the High-Technology Center, Kanazawa Medical University (grant H99-2), Kanazawa, Japan.

Address reprint requests to Dr Hashimoto: Dept of Pathology and Oncology, School of Medicine, University of Occupational and Environmental Health, 1-1 Iseigaoka, Yahatanishi-ku, Kitakyushu 807-8555, Japan.

* Dr Sheng is a research fellow in the Shanghai-UOEH Joint Project on the Cytogenetic Study of Soft Tissue and Bone Tumors.

Acknowledgments: We thank Yasuyuki Sasaguri, MD, and Shohei Shimajiri, MD, Department of Pathology and Cell Biology, School of Medicine, University of Occupational and Environmental Health, for helping us design the primers used in the study. We also are grateful to Kazuyo Bando for technical assistance.

References

- Coffin CM. Fibroblastic-myofibroblastic tumors. In Coffin CM, Dehner LP, O'Shea PA, eds. *Pediatric Soft Tissue Tumors: A Clinical, Pathological, and Therapeutic Approach*. Baltimore, MD: Williams & Wilkins; 1997:133-178.
- Mandahl N, Heim S, Rydholm A, et al. Nonrandom numerical chromosome aberrations 8, 11, 17, 20 in infantile fibrosarcoma. *Cancer Genet Cytogenet*. 1989;40:137-139.
- Schofield DE, Fletcher JA, Grier HE, et al. Fibrosarcoma in infants and children: application of new techniques. *Am J Surg Pathol*. 1994;18:14-24.
- Wilson MB, Stanley W, Sens D, et al. Infantile fibrosarcoma: a misnomer? *Pediatr Pathol*. 1990;10:901-907.
- Coffin CM, Jaszcz W, O'Shea PA, et al. So-called congenital-infantile fibrosarcoma: does it exist and what is it? *Pediatr Pathol*. 1994;14:133-150.
- Knezevich SR, McFadden DE, Wen Tao, et al. A novel ETV6-NTRK3 gene fusion in congenital fibrosarcoma. *Nature Genet*. 1998;18:184-187.
- Rubin BP, Chen CJ, Morgan TW, et al. Congenital mesoblastic nephroma (t(12;15) is associated with ETV6-NTRK3 gene fusion: cytogenetic and molecular relationship to congenital (infantile) fibrosarcoma. *Am J Pathol*. 1998;153:1451-1458.
- Bourgeois JM, Knezevich SR, Mathers JA, et al. Molecular detection of the ETV6-NTRK3 gene fusion differentiates congenital fibrosarcoma from other childhood spindle cell tumors. *Am J Surg Pathol*. 2000;24:937-946.
- Knezevich SR, Garnett MJ, Pysher TJ, et al. ETV6-NTRK3 gene fusion and trisomy 11 establish a histogenetic link between mesoblastic nephroma and congenital fibrosarcoma. *Cancer Res*. 1998;58:5046-5048.
- Argani P, Fritsch M, Kadkol SS, et al. Detection of the ETV6-NTRK3 chimeric RNA of infantile fibrosarcoma/cellular congenital mesoblastic nephroma in paraffin-embedded tissue: application to challenging pediatric renal stromal tumors. *Mod Pathol*. 2000;13:29-36.
- Hisaoka M, Tsuji S, Morimitsu Y, et al. Detection of TLS/FUS-CHOP fusion transcripts in myxoid and round cell liposarcoma by nested reverse transcription-polymerase chain reaction using archival paraffin-embedded tissues. *Diagn Mol Pathol*. 1998;7:96-101.
- Tsuji S, Hisaoka M, Morimitsu Y, et al. Detection of SYT-SSX transcripts in synovial sarcoma by reverse transcription-polymerase chain reaction using archival paraffin-embedded tissues. *Am J Pathol*. 1998;153:1807-1812.
- Finke J, Fritzen R, Ternes P, et al. An improved strategy and a useful housekeeping gene for RNA analysis from formalin-fixed, paraffin-embedded tissues by PCR. *Biotechniques*. 1993;14:448-453.
- Chung EB, Enzinger FM. Infantile fibrosarcoma. *Cancer*. 1976;38:729-739.
- Soule EH, Pritchard DJ. Fibrosarcoma in infants and children: a review of 110 cases. *Cancer*. 1977;40:1711-1721.
- Kodet R, Stejskal J, Pilat D, et al. Congenital-infantile fibrosarcoma: a clinicopathological study of five patients entered on the Prague Children's Tumor Registry. *Pathol Res Pract*. 1996;192:845-853.
- Enzinger FM, Weiss SW. Fibrous tumors of infancy and children. In Enzinger FM, Weiss SW, eds. *Soft Tissue Tumors*. 3rd ed. St Louis, MO: Mosby-Year Book; 1995:231-268.
- Coffin CM, Dehner LP. Fibroblastic-myofibroblastic tumors in children and adolescents: a clinicopathologic study of 108 examples in 103 patients. *Pediatr Pathol*. 1991;11:559-588.
- Meis JM, Enzinger FM. Inflammatory fibrosarcoma of the mesentery and retroperitoneum: a tumor closely simulating inflammatory pseudotumor. *Am J Surg Pathol*. 1991;15:1146-1156.
- Coffin CM, Watterson J, Priest JR, et al. Extrapulmonary inflammatory myofibroblastic tumor (inflammatory pseudotumor): a clinicopathological and immunohistochemical study of 84 cases. *Am J Surg Pathol*. 1995;15:859-872.
- Rubin BP, Lawrence BD, Perez-Atayde A, et al. TPM-ALK fusion genes and ALK expression in inflammatory myofibroblastic tumor [abstract]. *Mod Pathol*. 2000;13:15A.
- Griffin CA, Hawkins AL, Dvorak C, et al. Recurrent involvement of 2p23 in inflammatory myofibroblastic tumors. *Cancer Res*. 1999;59:2776-2780.
- Coffin CM, Hussong J, Perkins S, et al. ALK and p80 expression in inflammatory myofibroblastic tumor [abstract]. *Mod Pathol*. 2000;13:8A.
- Mentzel T, Calonje E, Nascimento AG, et al. Infantile hemangiopericytoma versus infantile myofibromatosis: study of a series suggesting a continuous spectrum of infantile myofibroblastic lesions. *Am J Surg Pathol*. 1994;18:922-930.
- Gorman PA, Malone M, Pritchard J, et al. Deletion of part of the short arm of chromosome 17 in a congenital fibrosarcoma. *Cancer Genet Cytogenet*. 1990;48:193-198.
- Sankary S, Dickman PS, Wiener E, et al. Consistent numerical chromosome aberrations in congenital fibrosarcoma. *Cancer Genet Cytogenet*. 1993;65:152-156.
- Meis JM, Enzinger FM, Martz KL, et al. Malignant peripheral nerve sheath tumors (malignant schwannomas) in children. *Am J Surg Pathol*. 1992;16:694-707.
- Cavazzana AO, Schmidt D, Ninfo V, et al. Spindle cell rhabdomyosarcoma: a prognostically favorable variant of rhabdomyosarcoma. *Am J Surg Pathol*. 1992;16:229-235.
- de Saint Aubain Somerhausen N, Fletcher CDM. Leiomyosarcoma of soft tissue in children: clinicopathologic analysis of 20 cases. *Am J Surg Pathol*. 1999;23:755-763.
- Schmidt D, Thum P, Harms D, et al. Synovial sarcoma in children and adolescents: a report from the Kiel Tumor Registry. *Cancer*. 1991;67:1667-1672.
- Rubin BP, Kozakewich HP, Fletcher JA, et al. Synovial sarcoma in children and adolescents: a clinicopathologic study [abstract]. *Mod Pathol*. 2000;13:205A.
- Okamoto S, Ishida T, Ohnishi H, et al. Synovial sarcomas of three children in the first decade: clinicopathological and molecular findings. *Pathol Int*. 2000;50:818-823.

33. Lamballe F, Klein R, Barbacid M. *trkC*, a new member of the *trk* family of tyrosine protein kinase, is a receptor for neurotrophin-3. *Cell*. 1991;66:967-979.
34. McGregor LM, Baylin SB, Griffin CA, et al. Molecular cloning of the cDNA for human *TrkC* (*NTRK3*), chromosomal assignment, and evidence for a splice variant. *Genomics*. 1994;22:267-272.
35. Shelton DL, Sutherland J, Gripp J, et al. Human *trks*: molecular cloning, tissue distribution, and expression of extracellular domain immunoadhesins. *J Neurosci*. 1995;15:477-491.
36. Shibayama E, Koizumi H. Cellular localization of the *trk* neurotrophin receptor family in human non-neuronal tissues. *Am J Pathol*. 1996;148:1807-1818.
37. Wai DH, Knezevich SR, Lucas T, et al. The *ETV6-NTRK3* gene fusion encodes a chimeric protein tyrosine kinase that transforms NIH3T3 cells. *Oncogene*. 2000;19:906-915.
38. Ichaso N, Rodriguez RE, Martin-Zanca D, et al. Genomic characterization of the human *trkC* gene. *Oncogene*. 1998;17:1871-1875.