



Review Article

Consensus for the Diagnosis, Prognosis and Treatment of Canine Mammary Tumors

Geovanni D. Cassali¹, Gleidice E. Lavallo², Andriago B. De Nardi³, Enio Ferreira⁴, Angélica C. Bertagnolli⁵, Alessandra Estrela-Lima⁶, Antonio C. Alessi⁷, Carlos R. Daleck⁸, Breno S. Salgado⁹, Cristina G. Fernandes¹⁰, Renata A. Sobral¹¹, Renée L. Amorim⁹, Conrado O. Gamba¹, Karine A. Damasceno¹, Patricia A. Auler¹, Georgia M. Magalhães⁷, Juliana O. Silva¹, Josiane B. Raposo¹⁰, Ana M. R. Ferreira¹², Luciana O. Oliveira¹³, Christina Malm¹⁴, Débora A. P. C. Zuccari¹⁵, Neide M. Tanaka¹⁶, Lorena R. Ribeiro⁶, Liliane C. Campos¹, Cristina M. Souza¹, Juliana S. Leite¹², Luciana M. C. Soares⁷, Mariana F. Cavalcanti¹⁷, Zilmara G. C. Fonteles¹⁸, Isabel D. Schuch¹⁹, Juliana Paniago¹⁴, Taismara S. Oliveira²⁰, Erika M. Terra⁸, Thais L. L. Castanheira⁷, Anelize O. C. Felix²¹, Gabriel D. Carvalho²², Thomas N. Guim¹⁰, Tainã N. Guim²³, Eduardo Garrido⁷, Simone C. Fernandes²⁴, Frederico C. L. Maia²⁵, Maria L. Z. Dagli²⁶, Noeme S. Rocha⁹, Heidge Fukumasu²⁷, Fabrizio Grandi⁹, João P. Machado²⁸, Silvana M. M. S. Silva¹⁸, Juliana E. Bezerril⁷, Michele S. Frehse²⁹, Elan C. Paes de Almeida³⁰, Cecilia B. Campos¹

¹Laboratório de Patologia Comparada, Departamento de Patologia Geral, ICB/UFMG, Belo Horizonte – MG, Brazil.

²Hospital Veterinário, Escola de Veterinária, UFMG, Belo Horizonte – MG, Brazil.

³Escola de Medicina Veterinária e Zootecnia, UFT, Araguaína -TO e Hospital Veterinário, UNIFRAN, Franca – SP, Brazil.

⁴Departamento de Medicina Veterinária, UFLA, Lavras – MG, Brazil.

⁵Faculdade de Ciências da Saúde, UNIVALE, Governador Valadares – MG, Brazil.

⁶Departamento de Patologia e Clínicas, Escola de Medicina Veterinária, UFBA, Salvador – BA, Brazil.

⁷Departamento de Patologia Veterinária, Faculdade de Ciências Agrárias e Veterinárias, UNESP, Jaboticabal – SP, Brazil.

⁸Departamento de Clínica e Cirurgia Veterinária, Faculdade de Ciências Agrárias e Veterinárias, UNESP, Jaboticabal - SP, Brazil.

⁹Departamento de Clínica Veterinária, Faculdade de Medicina Veterinária e Zootecnia, UNESP, Botucatu – SP, Brazil.

¹⁰Departamento de Patologia Animal, Faculdade de Veterinária, UFPEL, Pelotas - RS, Brazil.

¹¹Serviço de Oncologia Clínico-Cirúrgica, PROVET - Medicina Veterinária Diagnóstica e de Especialidades, São Paulo - SP, Brazil.

¹²Setor de Anatomia Patológica Veterinária, Departamento de Patologia e Clínica Veterinária, Faculdade de Veterinária, UFF, Niteroi – RJ, Brazil.

¹³Hospital de Clínicas Veterinárias, UFRGS, Porto Alegre – RS, Brazil.

¹⁴Departamento de Clínica e Cirurgia Veterinária, Escola de Veterinária, UFMG, Belo Horizonte - MG, Brazil.

¹⁵Centro de Estudos no Prognóstico do Câncer, Departamento de Biologia Molecular, FAMERP, São José do Rio Preto –SP, Brazil.

¹⁶Curso de Medicina Veterinária, Centro de Ciências Biológicas e da Saúde, Universidade Norte do Paraná, Londrina-PR, Brazil.

¹⁷Oncologia Veterinária, Belo Horizonte – MG, Brazil

¹⁸Departamento de Clínica e Cirurgia Veterinária, UFPI, Teresina – PI, Brazil.

¹⁹Hospital Universitário de Clínicas Veterinária, Faculdade de Veterinária, UFPEL, Pelotas – RS, Brazil.

²⁰Laboratório de Saúde Animal, IMA - Instituto Mineiro de Agropecuária, Belo Horizonte – MG, Brazil.

²¹Departamento de Clínica Veterinária, Faculdade de Veterinária, UFPEL, Pelotas - RS, Brazil.

²²Laboratório de Patologia, IFNMG, Salinas - MG, Brazil.

²³Hospital Universitário Veterinário, UNIPAMPA, Uruguaiana – RS, Brazil.

²⁴Laboratório de Oncologia Experimental, Departamento de Radiologia e Oncologia, Faculdade de Medicina, USP, São Paulo – SP, Brazil.

²⁵Departamento de Medicina Veterinária, UFRPE, Recife – PE, Brazil.

²⁶Departamento de Patologia, Faculdade de Medicina Veterinária e Zootecnia, USP, São Paulo – SP, Brazil.

²⁷Departamento de Ciências Básicas, Faculdade de Zootecnia e Engenharia de Alimentos, USP, Pirassununga – SP, Brazil.

²⁸Patologia Veterinária, UNIVIÇOSA/FACISA, Viçosa – MG, Brazil.

²⁹Departamento de Medicina Veterinária Preventiva, UEL, Londrina - PR, Brazil.

³⁰Departamento de Ciências Básicas, Faculdade de Odontologia, UFF, Nova Friburgo, RJ, Brazil.

Corresponding author: Geovanni D. Cassali, Laboratório de Patologia Comparada, Departamento de Patologia Geral, ICB/UFMG- Av. Antonio Carlos, 6627 CEP 31270-901, Belo Horizonte – MG, Brazil.

E-mail: cassalig@icb.ufmg.br

Submitted May 23rd 2011, Accepted June 20th 2011

Abstract

The purpose of this paper is to establish criteria that could guide the diagnosis, prognosis and treatment of canine mammary neoplasias. It was elaborated during the Mammary Pathology Meeting: Diagnosis, Prognosis and Treatment of the Canine Mammary Neoplasm, held on November 6th and 7th, 2010 in Belo Horizonte – MG, Brazil, sponsored by the Laboratory of Comparative Pathology – UFMG, with the support of the Brazilian Association of Veterinary Pathology (ABPV) and Brazilian Association of Veterinary Oncology (ABROVET). Academics from several regions of Brazil were present and contributed to this work.

Key Words: Mammary neoplasms, animal, dogs, medical oncology.

Introduction

Mammary tumors are the most frequent neoplasm in female dogs and constitute an important problem in veterinary medicine. Several efforts have been made towards the adoption of criteria to standardize the diagnosis, the understanding of tumor behavior and progression, and the evaluation of prognostic factors including morphology, oncogene expression and gene alterations. The knowledge and adoption of these criteria are fundamental for the selection and success of therapies that could prevent tumor recurrence and increase survival (13).

This paper was elaborated during the course of the Mammary Pathology Meeting: Diagnosis, Prognosis and Treatment of the Canine Mammary Neoplasm, held on November 6th and 7th, 2010 in Belo Horizonte – MG, sponsored by the Laboratory of Comparative Pathology – UFMG, with the support of the Brazilian Association of Veterinary Pathology (ABPV) and Brazilian Association of Veterinary Oncology (ABROVET). The objective was to bring teachers and/or researchers, practitioners and graduate students working in the field of anatomical pathology and clinical oncology together to establish criteria that could guide the diagnosis, prognosis and treatment of canine mammary neoplasms.

1. CLINICAL SIGNS

Mammary gland tumors affect middle aged and old female dogs that are sexually intact or spayed (30, 32). The majority of dogs with mammary neoplasms are clinically healthy at the time of diagnosis and the tumors can be identified by the owner or a professional during a routine physical examination (111).

Canine mammary neoplasms are commonly presented as circumscribed nodules with variable size, consistency and mobility to the skin and muscle. They can also be associated with skin ulceration and local inflammatory reactions. Multiple tumors are frequently observed in a single mammary gland or may involve multiple mammary glands simultaneously (multicentric tumors) and can be different histological types (66, 82).

However, the tumor with the worst prognosis will always determine the clinical evolution of the patient (23).

The caudal abdominal and inguinal mammary glands are affected with higher frequency than thoracic glands (13).

2. DIAGNOSIS

Clinical examination

All animals with mammary lesions should be submitted for clinical examination (30). During the examination, the general clinical condition of the animal is evaluated. The professional must collate information concerning medical history, reproductive cycle (regular heat, number of births, castration, use of hormone therapy, abortion and history of pseudo pregnancy), the approximate date when the lesions were first noticed by the owner, and previous tumor lesions. This information should be recorded in a cancer record form (21, 49).

During the clinical examination, the two mammary chains and the lymph nodes should be explored. To determine the precise clinical staging of the cancer, the professional should perform chest radiographs in three views (VD, RL, LL) as this is the standard diagnostic procedure for evaluation of pulmonary metastatic disease. Pulmonary lesions ranging in size from six to eight mm in diameter can be detected using conventional radiography. Early detection of metastatic lesions smaller than 6 mm can be achieved using computed tomography. The lung is the most common site for distant metastasis in dogs with malignant mammary gland tumors, but additional tests such as abdominal ultrasound or radiography should be recommended for investigation of other anatomical sites depending on the specific clinical signs presented by the patient. The observation of distant metastases is associated with an unfavorable prognosis (111).

Excisional biopsy is the recommended diagnosis method for canine mammary tumors. Curing dogs presenting with small malignant well-

differentiated tumors is feasible as long as surgical margins are not compromised.

Inspection of the regional lymph nodes should be included in the routine clinical evaluation of dogs with mammary tumors, as the presence of metastasis impacts on the clinical staging of the cancer and therefore survival and treatment approach.

Cytology is a safe method for inspecting lymph nodes. It has 100% sensitivity and 96% specificity for identification of metastasis. Therefore, fine needle aspiration biopsy (FNAB) of palpable lymph nodes is recommended as the presence of metastasis impacts on the clinical staging of the cancer and the treatment approach. In cases of positive or suspicious results for metastasis, excision of affected lymph nodes should be performed (111). FNAB should be performed on lymph nodes presenting with alterations in volume, shape and consistency upon clinical examination. Cell smears obtained from puncture (3-5 slides) should be air dried or immediately fixed in a solution of 70% ethanol. Excessive contamination with blood, hair and liquefied material should be avoided as this could compromise the quality of the sample (14).

Clinical staging: TNM

Determining the clinical stage enables the definition of the extension of the tumor. As a consequence, this allows a prognosis to be established and treatment to be planned, giving precise indications to the anatomopathologist concerning the material submitted for analysis and for comparing clinical observations from different sources (110).

Clinical staging is determined according to the TNM system established by the World Health Organization (WHO) for canine mammary tumors. Based on this system, the size of the primary lesion (T), the extent of its spread to regional lymph nodes (N) and the presence or absence of distant metastases (M) must be assessed (89) (Tables 1-2).

According to Gilbertson *et al.* (1983) (55) there is a direct relationship between the extent of the tumor at the time of surgery and the risk of recurrence or the appearance of a second primary tumor. Philibert *et al.* (2003) (97) carried out a multivariate study concerning the influence of survival factors in bitches with malignant mammary tumors and demonstrated that dogs presenting with cancer at stage II or higher had significantly decreased survival.

Tumor size is considered an independent prognostic factor for mammary cancer in bitches. Tumors sized 3.0 cm or smaller are significantly correlated with better prognosis compared with larger tumors. This parameter can be easily obtained and should be considered when making decisions concerning complementary therapy (24, 111). During a study concerning canine mammary tumors that included 15 benign and 23 malignant cases, Ferreira *et al.* (2009) (48) observed that most lesions greater than 5.0 cm (T3) were malignant, presenting with a higher proliferation

rate and lower positivity for progesterone receptors (PR) when compared with smaller tumors (T1, T2).

The evaluation of regional lymph nodes has a major impact on the survival of dogs with mammary gland tumors. Animals with regional lymph node metastases exhibit a significant decrease in survival expectancy compared with individuals who tested negative for lymph node metastasis (24, 111). Hellmén *et al.* (1993) (61) performed a study involving 202 female dogs with mammary cancer. They demonstrated that regional lymph node involvement was a statistically significant unfavorable prognostic factor as determined by univariate analysis, but were not significant when multivariate analysis was performed.

The presence of distant metastasis is deleterious for prognosis compared with female dogs that present with spreading to regional lymph nodes only (111).

Inflammatory carcinoma

Inflammatory mammary carcinoma (IMC) is named after the initial clinical appearance of the lesion, which resembles an inflammatory process of the skin or mammary gland. It is an uncommon tumor with a fulminant clinical course and unfavorable prognosis (4, 92, 116). The IMC can affect humans and dogs (4, 62, 116), the latter being the only animal species in which the cancer occurs spontaneously (56). Approximately 50% of mammary tumors are malignant (24, 98), and of these approximately 7.6% are classified as IMC based on clinical examination and histopathological findings (94).

The tumor is microscopically characterized by the presence of an association between any carcinoma subtype and an intense inflammatory reaction, with presence of tumor emboli in lymphatic vessels in the dermis (4, 22, 24). Macroscopically, the lesions grow as continuous, firm and hyperemic plaques without specific demarcation (22). Other symptoms include itching, local temperature rise, intense or moderate pain, swelling and redness of the skin overlying the mammary gland (4, 11, 56, 92). Initially these signals resemble mastitis, mammary abscess or dermatitis (92). IMCs have a high potential for metastasis therefore, it is prudent to carry out additional tests including chest radiographs and abdominal ultrasound to monitor for possible metastatic foci.

Aspiration cytology of the primary tumor

Excisional biopsy is recommended for initial diagnosis of tumors of the mammary gland in the bitch, but the use of aspiration cytology has increased over time and high levels of agreement between cytological and histopathological results have been described (14, 130). The samples must be collected by experienced cytologists, a restraint for the wide use of FNAB in veterinary medicine (14).

Cytological examination may be useful for excluding differential diagnoses such as mastitis, lipomas and mast cell tumors, among others. However,

in clinical evaluations the execution of FNA on the primary tumor does not interfere with the surgical planning for patients as this procedure is selected according to lesion size (T), the affected mammary gland and its lymphatic draining.

Moreover, the final diagnosis should be based on histopathology reports as this allows tumor histomorphology to be assessed meticulously, such as pleomorphism, differentiation degree, mitotic index, presence or absence of necrosis and the precision of excision (30, 82).

Table 1: Clinical staging (TNM) of canine mammary carcinomas (Owen,1980).

Primary Tumor (T)	Regional lymph nodes (N)
T0 No evidence of primary tumor	N0 No regional lymph node metastasis (axillary ou inguinal)
T1 Tumor size < 3cm a : not attached b : attached to the skin c : attached to the muscle	N1 Ipsilateral lymph node involved a : not attached b : attached
T2 Tumor size 3 – 5cm a : not attached b : attached to the skin c : attached to the muscle	N2 Bilateral lymph node involved a : not attached b : attached
T3 Tumor size > 5cm a : not attached b : attached to the skin c : attached to the muscle	Distant metastasis (M)
T4 Tumor of any size (Inflammatory carcinoma)	M0 No distant metastasis M1 Distant metastasis, including distant lymph nodes

Table 2: Grouping by stages of canine mammary tumors (89).

	T	N	M
Stage I	T1a, b or c	N0; N1a or N2a	M0
Stage II	T0 T1a, b or c T2a, b or c	N1 N1 N0 or N1a	M0
Stage III	All T3 All T	All N All Nb	M0
Stage IV	All T	All N	M1

T- Size of primary tumor; N – Lymph node; M – Metastasis

Anatomopathological

Sample harvesting for anatomopathological examination

The histological classification of mammary tumors has become a valuable tool for predicting their biological behavior (6). Therefore, it is essential to conduct an anatomopathological examination of all nodules regardless of their size, as this provides

important additional information that can assist the clinician to define the prognosis and the best treatment plan (125). The main factors affecting sample quality include lack of representation, inadequate fixation and lack of information regarding the sample.

Ideally, specimens should be sent to the pathologist immediately, intact and without fixation. Alternatively, specimens can be fixed in formaldehyde and sent to laboratories within 24 hours for processing. In order to establish an anatomopathological protocol

for the harvesting and shipment of samples, Ferreira and colleagues (2003) (49) proposed that fragments of every affected mammary gland including skin and subcutaneous tissue and regional lymph nodes should be collected separately, and immediately fixed in 10% formalin, neutral and buffered with phosphate. The volume of this solution must be at least 10 times the size of the fragment. It is recommended that the fixation time does not exceed 24 hours so immunohistochemistry is not compromised. After 24 hours fixation in 10% formalin, the fragment should be placed in a solution of 70% alcohol. The vials should be labeled with the name of the animal, organ and lesion location, and accompanied by the clinician request with accurate information concerning the animal's medical history including the macroscopic description of the tumor (see model of anatomopathological protocol published by Ferreira *et al.* (2003)) (49).

For cleavage procedures, the recommendations of Estrela-Lima *et al.* (2010) (44) should be followed and it is proposed that for tumors sized between 3-5 cm and specimens larger than 5 cm, three and five fragments of the tumor mass should be collected, respectively, and each one must measure 1.5x1.5x0.5cm. The margins should be prioritized and the central necrotic areas excluded. The margin evaluation is mandatory, and they can be identified using India ink staining.

In this context, the standardization of harvest and shipment procedures of specimens by surgeons and clinicians, and the material cleavage procedures carried out by the pathologist, is essential to establish criteria for research. Therefore, histopathological diagnosis will be not compromised and the prognosis for patients with mammary neoplasms will be accurate.

Evaluation of surgical resection margins

Whenever there are neoplastic cells in the area stained with Indian ink, the sample should be considered as having "compromised margins". Lateral, deep and superficial margins should be evaluated for the presence of neoplastic cells. If the margins are free, it is recommended to assign a distance in millimeters from the tumor to the smallest margin. If there are compromised margins, these must be identified and the type of imperfection must be assigned (presence of isolated cells or lesion continuity).

Evaluation of metastasis in lymph nodes

During lymph node excision it must be measured and, in case of size augment, cut into longitudinal sections. Histopathological evaluation with hematoxylin-eosin staining allows the assessment of lymph node metastasis by counting the number of cell clusters. Macrometastasis occurs when the cluster size is greater than 2mm, while sizes between 0.2 mm and 2 mm characterize micrometastases. Areas that measure less than 0.2mm are considered isolated cancer cells (2).

It can be difficult to visualize metastasis using routine HE staining. In such cases, it is suggested that immunohistochemistry using specific antibodies against epithelial cell proteins such as cytokeratins are utilized (79).

Histological examination

The safest diagnostic method is histopathological examination of excisional or incisional biopsies. Besides facilitating lesion classification, histopathological examination allows investigators to evaluate infiltration of the skin, soft tissue and surrounding blood vessels, details concerning the histomorphology of the tumor (presence or absence of pleomorphism, degree of differentiation, mitotic index, presence or absence of necrosis) and contributes to a precise excision, as proposed by Ferreira *et al.* (2003) (49).

The assessment of the integrity of the myoepithelial/basal cell layer is an important criterion for the diagnosis of breast carcinoma in women. It aids the differential diagnosis between *in situ* and invasive malignant lesions, being particularly useful for the detection of microinvasion spots (114, 127). In veterinary medicine, myoepithelial markers such as alpha smooth muscle actin, S-100 (33), calponin (43), p63 (53) and maspin (41) have been used predominantly in research directed towards the determination of tumor histogenesis. However, their use as an auxiliary tool in the determination of invasion is limited and few studies have addressed this aspect (5).

Histological grading

Histopathological grading of breast cancer aims to evaluate the architecture of the neoplasm and morphological variations of the core, and the histological grade presents a significant correlation with tumor aggressiveness (39). Currently, in human medicine, the most widely used grading system is the Nottingham modified by Elston and Ellis (1998) (38), which has replaced previous subjective evaluations when the degree of tumor differentiation was estimated by the general appearance of the tumor. The Nottingham method allows the factors to be evaluated systematically using more objective criteria.

According to this system, determination of histological grade is based on the evaluation of the tubule formation index (1 point: more than 75% of the tumor is composed by tubules, two points: between 10% and 75% of tubular formations, and 3 points: the tubules occupy 10% or less of the tumor), nuclear pleomorphism (1 point: small and regular nuclei; 2 points: moderate increase in size and variation of nuclei; 3 points: marked pleomorphism, with large variation in size and shape of nuclei) and mitotic count (1 point: 0-8 mitosis, 2 points: 9-16 mitosis, and 3 points: above 17 mitosis in 40x lens). The histological grade of the tumor is obtained through the sum of the scores which results in a total amount that ranges from 3 to 9. The summary of tumor grades is: 3-5 points:

grade I; 6-7 points: grade II; 8-9 points: Grade III. Anaplasia increases with an increase in grade. The histological grade is considered as an independent prognostic indicator for primary breast cancer in women.

In veterinary medicine, the grading systems for mammary tumors with well-defined criteria are not frequently used (68). Among the most popular ones is the Misdorp *et al.* (1999) (82) and Gilbertson *et al.* (1983) (55) systems, both based on the combination of cellular and nuclear characteristics. Recently, the number of veterinary researchers who have adopted the

criteria for histological grading proposed by Nottingham for evaluating breast carcinomas in dogs has increased (Table 3). These studies reveal a significant correlation between histopathological grading and other prognostic factors such as histological type and survival (23, 36, 37, 44, 63, 64, 80, 87). Therefore, histological grading of tumors determined by the Nottingham system and modified by Elston and Ellis, 1998 (38), represents a sensible tool that can be incorporated into veterinary medicine as is the case with human oncology.

Table 3: Summary of Histological Grades of Breast Cancer according to Elston & Ellis (1998) (38).

Attribute	Score
Tubule Formation	
> 75% of tumor	1
10 to 75% of tumor	2
< 10% of tumor	3
Nuclear Pleomorphism	
Nuclear size similar to a normal cell (2 to 3 times the size of red blood cell)	1
Moderate increase in size and variation	2
Marked variation	3
Mitotic Count (HPF) *	
0 a 8 Mitotic counts / 10 HPF	1
9 a 16 Mitotic counts / 10 HPF	2
17 or greater Mitotic counts / 10 HPF	3

*Adapted according to the microscopy field size used in this study= 0,55 mm.
 HPF = high Power field. Olympus BX-41, 40 X objective lens.

Classification of tumor lesions

Methods of classifying canine mammary tumors vary considerably. There may be disagreement about the most common tumors such as mixed tumors and carcinomas in mixed tumors (13). Several classifications have been proposed, but the most widely

adopted that of Misdorp *et al.* (Table 4) published in 1999 (82) by the AFIP (Armed Forces Institute of Pathology). Below are listed the types adopted by consensus. Microscopic features of some tumors are shown in figures 1-5.

Table 4: Canine Mammary Neoplasms Histological Classification. Modified from Misdorp *et. al.*, 1999 (82).

<p><u>Non-neoplastic epithelial lesion</u></p> <p>Epithelial hyperplasia</p> <ul style="list-style-type: none">Ductal hyperplasiaLobular HyperplasiaAdenosis <p>Columnar cell lesions</p> <ul style="list-style-type: none">Columnar cell alterationColumnar cell hyperplasiaAtypical columnar cell lesions <p><u>Benign tumors</u></p> <ul style="list-style-type: none">AdenomaComplex adenoma or adenomyoepitheliomaBasaloid adenomaFibroadenomaMixed benign tumorDuctal papilloma <p><u>Malignant tumors</u></p> <p>Carcinomas</p> <ul style="list-style-type: none">Carcinomas <i>in situ</i><ul style="list-style-type: none">Ductal Carcinoma <i>in situ</i>Lobular Carcinoma <i>in situ</i>Mixed tumor carcinomaComplex carcinoma or malignant adenomyoepitheliomaPapillar carcinomaTubular carcinomaSolid carcinoma <p>Special type carcinomas</p> <ul style="list-style-type: none">Micropapillar carcinomaInvasive lobular carcinomaPleomorphic lobular carcinomaSecretory carcinomaMucinous carcinomaLipid-rich carcinomaSquamous cell carcinomaSpindle-cell carcinomaAnaplastic carcinomaMammary neoplasms with sebaceous differentiation <p>Sarcomas</p> <ul style="list-style-type: none">FibrosarcomaOsteosarcomaCarcinosarcomaMixed tumor sarcomas <p>Other sarcomas</p> <ul style="list-style-type: none">Pure CondrosarcomaLiposarcomaHemangiosarcoma
--

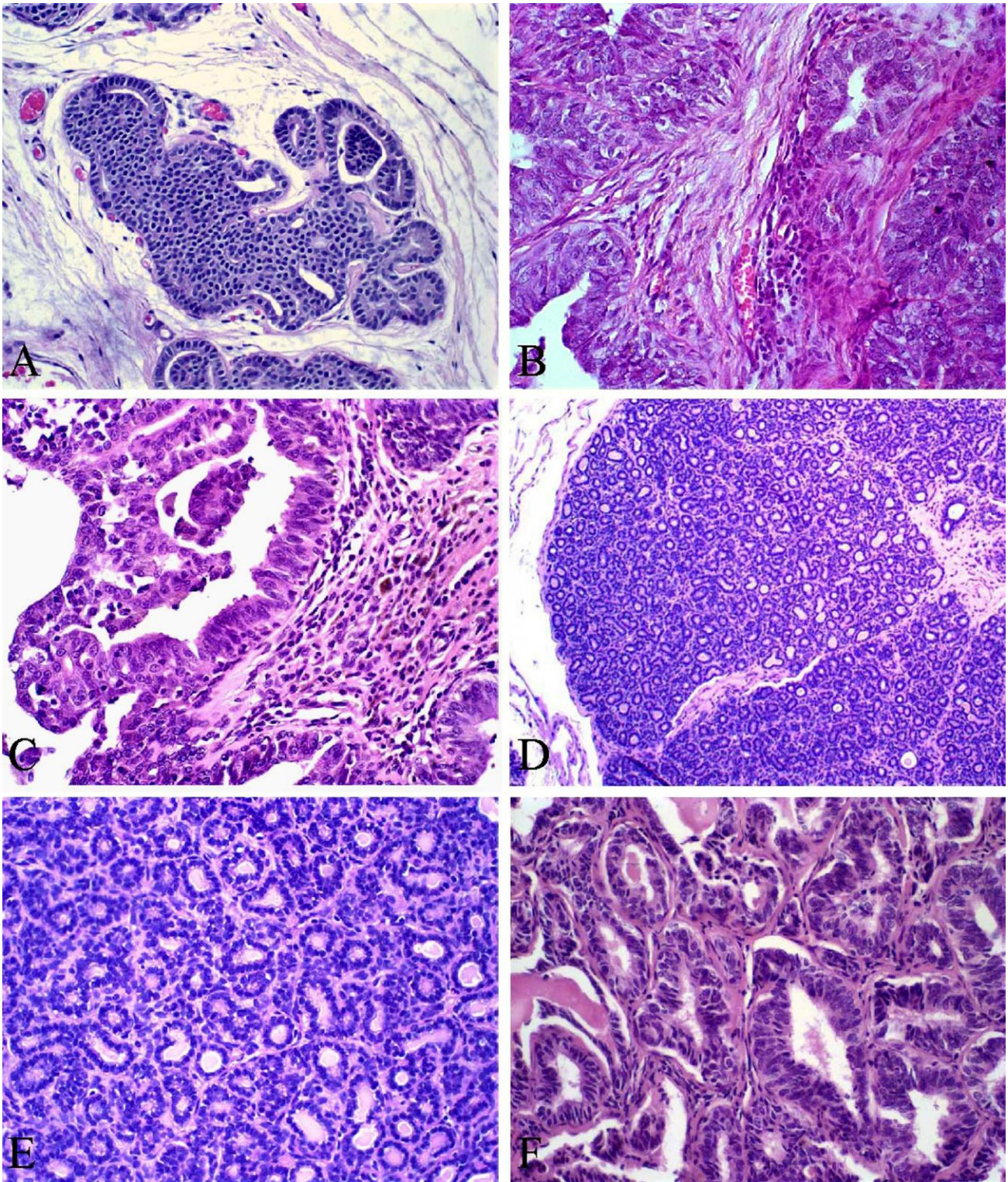


Figure 1

- (A) Atypical ductal hyperplasia. H&E. 40x.
- (B) Ductal carcinoma *in situ*. PAS. 40x.
- (C) Columnar Cell Change with atypia. H&E. 10x.
- (D) Adenose. H&E. 10x.
- (E) Adenose. H&E. 40x
- (F) Columnar Cell Hyperplasia without atypia. H&E. 40x.

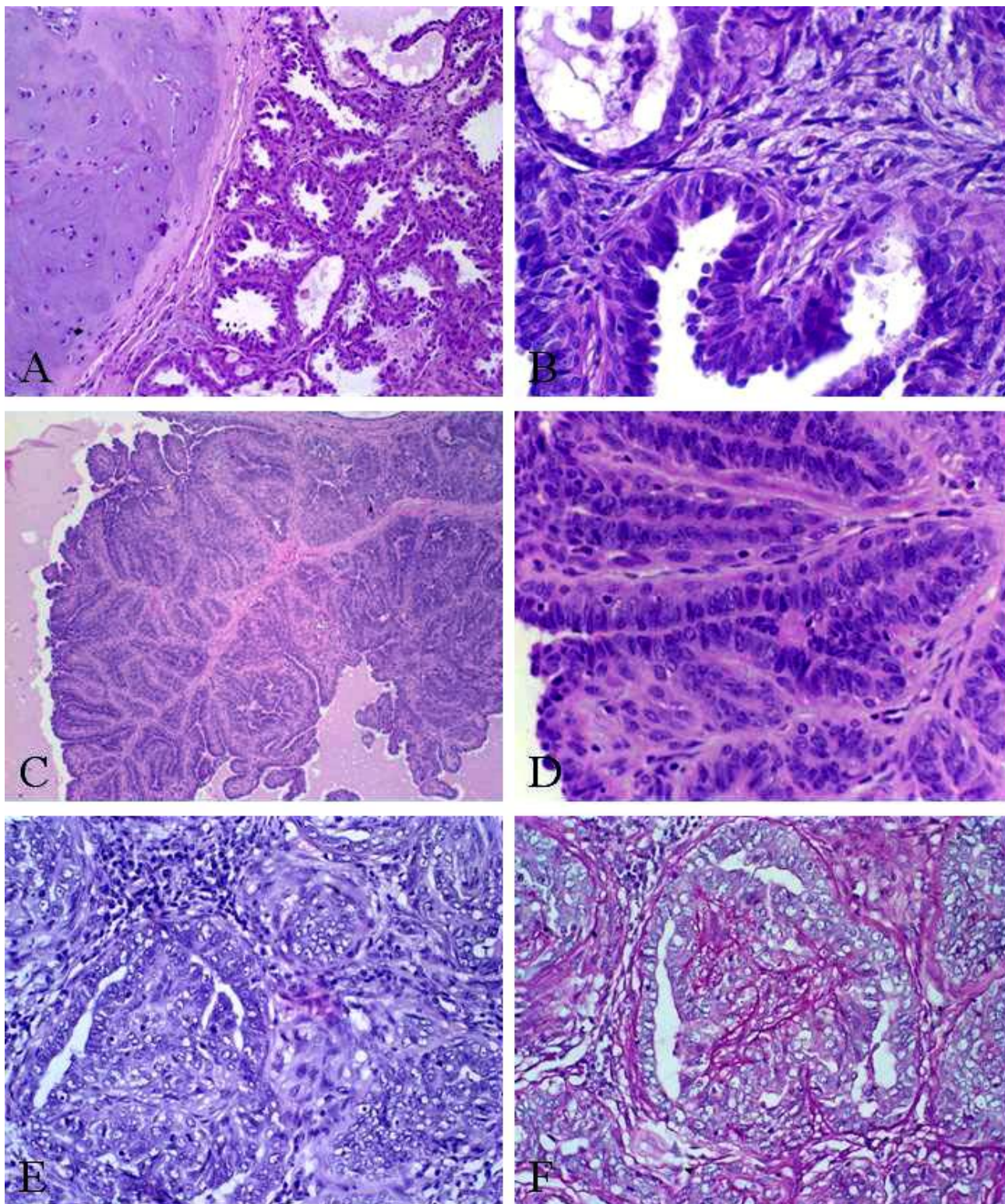


Figure 2
(A and B) Benign mixed tumor. H&E. 20x and 40x.
(C and D) Ductal papilloma. H&E. 10x and 40x.
(E and F) Ductal carcinoma *in situ*. H&E. 40x and PAS 40x.

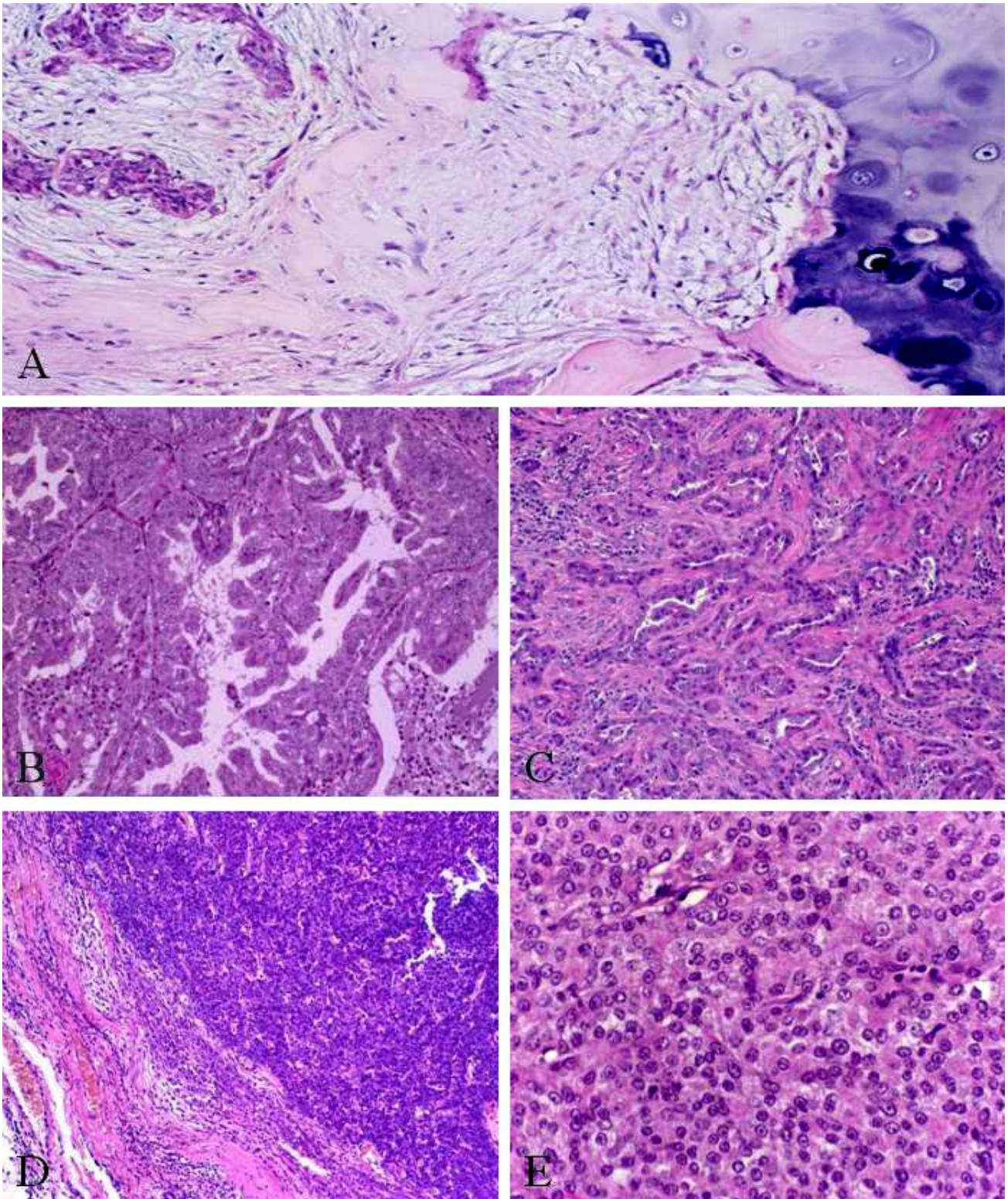


Figure 3
(A) Carcinoma in mixed tumor. H&E. 10x.
(B) Papillary carcinoma. H&E. 10x.
(C) Tubular carcinoma. H&E. 10x.
(D) Solid carcinoma. H&E. 10x.
(E) Solid carcinoma. H&E. 40x.

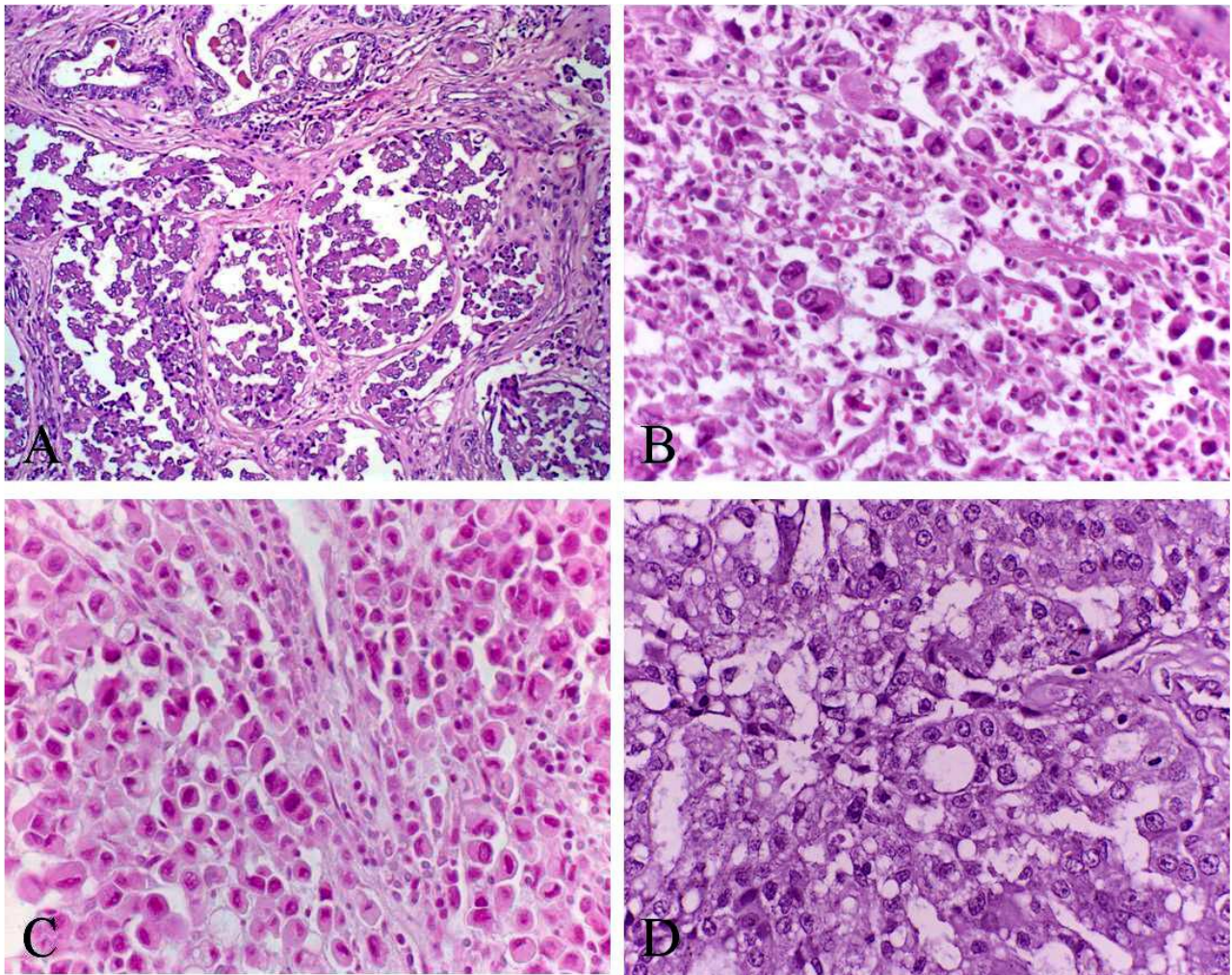


Figure 4
(A) Micropapillary carcinoma. H&E. 10x.
(B) Anaplastic carcinoma. H&E. 40x.
(C) Pleomorphic lobular carcinoma. H&E. 40x.
(D) Secretory carcinoma. H&E. 40x.

Non-neoplastic epithelial lesions

Alterations in the molecular behavior of canine mammary epithelium suggested that intraepithelial or intraductal lesions (ductal and lobular hyperplasia and ductal carcinoma *in situ*) represent evolutionary stages in the process of malignant neoplastic progression (46).

Epithelial hyperplasia

Mammary epithelial hyperplasia is often observed in the final portion of the ductal gland in canine species. These lesions can arise in the extralobular ducts, called ductal hyperplasia, or in the intralobular ducts, called lobular hyperplasia. When these types of hyperplasia are diffuse or multifocal they are referred to as papillomatosis or epitheliosis. In such cases, the lesions affect ductal units and have similar morphological behavior (82).

Current evidence suggests that hyperplastic alterations affecting the ductal intralobular and extra lobular units have similar diagnostic and prognostic significance, as observed in the human mammary gland. It is suggested that other types of cellular alterations,

classified as lobular hyperplasia in human breast, could occur in the canine mammary gland but with a distinct diagnostic significance (3, 85). There are three distinct types of canine hyperplastic alterations:

I) Ductal hyperplasia - refers to proliferations characterized by supernumerary projections of epithelial cells, which are morphologically similar to normal cells of the duct, with mild nuclear pleomorphism. Disorganized or irregular bridges formed by intraductal papillary projections can be observed. They are composed of one or two cells within the terminal ducts or in interlobular ducts. These types of hyperplasia have been previously referred to as papillomatosis or epitheliosis and may appear diffuse or multifocal. Histologically, atypical cellular behaviors are determined by small cells with uniform and monomorphic nuclei. These cells form solid bridges across the ductal lumen with an organized layer of myoepithelial cells that delimit the duct. The discrimination between an atypical hyperplastic lesion (Fig. 1A) and a low degree duct carcinoma *in situ* is

difficult (Fig. 1B). In these situations, the evaluation of the number and size of lesions should be considered as criteria to distinguish them. However, both are potentially malignant. Molecular studies have demonstrated that atypical ductal hyperplasia and low

grade ductal carcinoma *in situ*, apparently, have similar chromosomal alterations and probably share a similar role in the malignant transformation of the mammary gland (46).

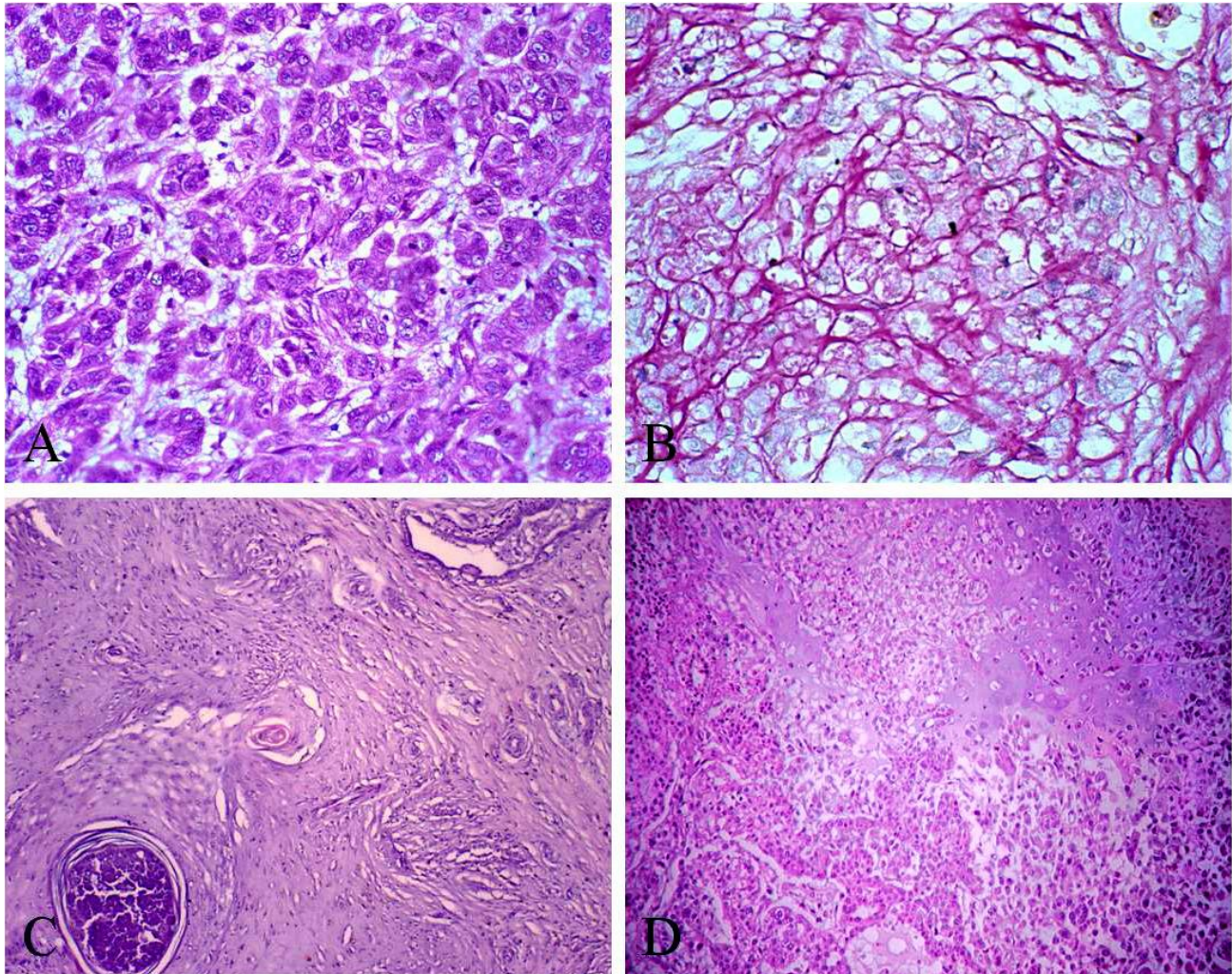


Figure 5
(A) Mucinous carcinoma. H&E. 40x.
(B) Mucinous carcinoma. PAS. 40x.
(C) Squamous cell carcinoma. H&E. 10x.
(D) Carcinosarcoma. H&E. 10x.

II) Lobular hyperplasia - occurs in the terminal lobular units of the mammary gland. In this type of injury, epithelial cells have a distinct morphological behavior. The cell nuclei are small and round, predominantly located in a central position and presenting with low pleomorphism and sometimes a single intracytoplasmic vacuole. This uniform population of cells occupies the acinar units, leading to the growth of such units. No more than four units are compromised in the typical lobular hyperplasia. When five or more acinar units are affected the lesion is classified as an atypical lobular hyperplasia. This is an important distinction for human studies, as it has been demonstrated that atypical lobular lesions have greater potential for malignant transformation than typical lesions (46).

III) Adenosis – An alteration characterized by an increased number of acini and dilation of the intralobular duct, thereby increasing the overall diameter of the lobular units (Fig. 1D, E). Mild alterations in epithelial, myoepithelial and fibrous periductal tissues can occur. This injury is followed by periductal fibrosis (sclerosing adenosis). It is uncommon among dogs and does not appear to be related to neoplastic progression (46).

Columnar cell lesions (CCLs)

CCLs comprise a group of processes characterized by dilatation of the terminal ducts organized in a columnar cell pattern, arranged in one or two cell layers, with or without atypia. These lesions

are associated with intraductal calcifications, atypical intraductal hyperplasia projections, and benign neoplasms, carcinoma *in situ* and invasive carcinoma (47). It is likely that the CCLs represent a step toward the development of several types of low-grade carcinoma *in situ* and invasive carcinoma (27, 99).

These alterations can be classified into three histological types:

I) Columnar Cell Change (CCC), characterized by acini dilations which are delimited by a layer of epithelial cells arranged in a columnar fashion. The cell nuclei are elongated with moderate chromasia. Apical cytoplasm projections are often present as is intraluminal secretion (Fig. 1C, F).

II) Columnar cell hyperplasia (CCH) – columnar lesions similar to CCCs, but a superposition of two or more layers of columnar epithelial cells are observed in the terminal lobular units.

III) Atypical columnar cell lesions – characterized by alterations in columnar cells. The nuclei of these cells are hyperchromatic and ovoid and have a higher ratio of nucleus/cytoplasm, and are not perpendicularly oriented by the basement membrane. Owing to the flattened epithelial surface, this type of alteration is appropriately termed as Flat Epithelial Atypia (FEA). Foci of micropapillary projections and cytoplasmic intraductal tufts can also be observed.

Benign Tumors

Adenoma

Adenoma is a benign neoplasm of well-differentiated epithelial or myoepithelial cells. Tumors composed of well-differentiated epithelial cells are classified as a simple tubular type and should be differentiated from adenosis. Despite the proliferation of tubular structures, adenosis retains their architectural pattern with intralobular ducts. This type of lesion is rare in dogs and the solid nodes composed of fusocellular cells are referred to as myoepitheliomas and may require p63 immunohistochemistry for confirmation (15).

Complex adenomas or adenomyoepithelioma

Adenomyoepithelioma is a benign tumor originating from the proliferation of epithelial and myoepithelial cells, but with no evidence of myxoid matrix formation. Its differentiation from complex well-differentiated carcinomas can be difficult. The presence of a capsule, absence of necrosis and atypia and low mitotic activity is the basis for diagnosis (15).

Basaloid adenoma

Basaloid adenoma is a benign tumor consisting of uniform cords and basaloid monomorphic epithelial cell nests. The peripheral cells assume a palisade arrangement and are orientated against a thin basal lamina. These tumors are usually small (15).

Fibroadenoma

Fibroadenoma is a benign tumor originating from the proliferation of epithelial and stromal elements. There are two types: pericanicular fibroadenoma (epithelium surrounded by stroma) and intracanalicular fibroadenoma (epithelium that is compressed and deformed by the stroma), and fibroadenoma of low or high cellularity (15).

Benign mixed tumor

Benign mixed tumors are characterized by benign proliferation of cells that are morphologically similar to epithelial components (luminal or myoepithelial) and mesenchymal cells that produce cartilage and/or bone and/or adipose tissue, possibly in combination with fibrous tissue (82) (Fig. 2A).

The proliferating myoepithelial cells may appear fusiform or stellate, and are often embedded in abundant extracellular matrix (myxoid matrix). The proliferation of myoepithelial cells in association with the myxoid matrix are the origin of the ectopic cartilage observed in mixed tumors, suggesting that it is a result of (myo) epithelial-mesenchymal transition (40) (Fig. 2B). The cartilage appears in the form of nodules or plaques of variable sizes. The bone tissue consists of osteoclasts that synthesize osteoid and mineralized bone. Bone marrow hematopoietic tissue and fat interposition are eventually observed.

Some degree of pleomorphism and atypia is always present in this kind of tumor, which often make differential diagnosis difficult, particularly in the case of carcinomas in benign tumors.

The histogenesis of these tumors is the subject of several studies. The current consensus is to assume that all elements of cancer including those of a mesenchymal nature, originate from myoepithelial or ductal reserve cells. It is the most common benign tumor in dogs.

Ductal papilloma

This is a benign tumor, ramified or lobed in a distended duct, with organized proliferation of ductal epithelium on a well-defined fibro-vascular axis. The epithelium is distributed as a single layer, has little cellular atypia or nuclear hyperchromasia and minimal mitotic activity. It is placed on a layer of myoepithelial cells (15) (Fig. 2C-D).

Malignant Tumors

Carcinomas

Mammary carcinomas are classified as carcinoma *in situ*, complex carcinoma, simple carcinomas and special carcinomas. Simple carcinomas have three simple histomorphologically distinct variants: the tubulo-papillary carcinoma, solid and anaplastic. Importantly, the tubulo-papillary carcinoma has tubular and papillary variants. Moreover, among the special types of carcinomas are the micropapillary carcinoma, squamous cell carcinoma, mucinous

carcinoma, secretory carcinoma, lipid-rich carcinoma and spindle cell carcinoma.

Carcinomas *in situ*

Different proliferative non-neoplastic mammary lesions are known as mammary cancer precursors in female dogs. However, carcinomas *in situ* are the only alterations recognized as precursor lesions of malignant transformation in the canine mammary gland, similar to human breast (3, 85).

Carcinoma *in situ* is characterized as a proliferation of malignant epithelial cells in the extralobular ductal units (Ductal Carcinoma *in situ*) or terminal lobular units of the mammary gland (lobular carcinoma *in situ*). The abnormal malignant cells occupy the ductal lumen with no discontinuity or absence of the basement membrane (59) (Fig. 2E-F).

Carcinoma *in situ* with microinvasion areas is defined when the continuity of the basement membrane <1 mm is lost, and epithelial cells are present (59).

Ductal carcinoma *in situ* (DCIS)

This is the most common carcinoma *in situ*, often observed in association with invasive canine mammary carcinomas (solid carcinomas, papillary, carcinomas in mixed tumors). DCIS develops in the intra- or extra-lobular ducts. It is characterized by epithelial proliferations affecting more than two ductal units in the same histological section (Fig. 2E-F). Epithelial cell proliferation exhibits an atypical cellular architecture characterized by connecting bridges along the ductal lumen and a layer of polarized epithelial cells associated with a continuous layer of myoepithelial cells. Microcalcifications are sometimes observed within the ductal lumen. DCI can be associated with other types of non-neoplastic (hyperplasia and columnar cell lesions) and benign or malignant neoplasms. There is a direct correlation between the presence of DCIS, atypical columnar cell lesions and invasive mammary carcinomas in dogs.

The architecture of the proliferation of carcinomas *in situ* can be organized according to three different patterns: i) cribriform pattern, ii) papillary, iii) micropapillary, iv) solid, v) solid with central areas of necrosis (comedo), and the latter is predominantly observed in high grade *in situ* lesions.

DCIS grading

DCIS are categorized as low, intermediate and high grade lesions, depending on the cellular atypia level (mainly nuclear) and the loss of luminal polarization.

Low grade DCIS is characterized by a monomorphic cell pattern with no increase in nuclear size or fine and diffuse chromatin, mild prominent nucleoli and lack of mitotic figures. High grade DCIS exhibit a significant level of cellular pleomorphism, nuclear diameters twice the size of normal ductal cells, loose or vesicular chromatin, multiple or prominent nucleoli and numerous mitotic figures (59).

Lobular carcinoma *in situ* (LCIS)

LCIS are termed as lobular lesions as the proliferation of epithelial cells leads to the filling and expansion of terminal lobular units. It affects > 50% of the lobe and a complete loss of the lumen. However, there is no discontinuity or loss of the basement membrane (59).

The cell shape is invariable, the nuclei are small and spherical, and the nucleoli are uniform and discrete. There is a single cytoplasmic vacuole around the nucleus, represented by an invagination of the cytoplasmic membrane.

LCIS is a subtype of pleomorphic lobular carcinoma *in situ*, which is normally differentiated from invasive solid carcinoma. In this subtype, the proliferating cells exhibit pleomorphic nuclei and sometimes evident nucleoli, comedo type central areas of necrosis and microcalcifications. However, unlike the invasive carcinoma, this lesion exhibits no loss of continuity of the basement membrane.

Carcinoma in a mixed tumor

Mixed tumors are frequent mammary gland neoplasias of the bitch. These tumors exhibit a complex histological pattern as they consist of components from epithelial and mesenchymal origin. Some can turn malignant, leading to the development of carcinoma in mixed tumors (82).

Carcinomas in mixed tumors are tumors that contain foci or nodules of epithelial cells with elevated pleomorphism and atypical mitosis, which arise in benign mixed tumors. Carcinoma proliferation can invade or completely replace the pre-existing benign lesion at the time of histopathological examination.

The malignant epithelial cells often exhibit infiltrative growth, which can be identified by the loss of continuity of the basal/myoepithelial layer associated with clusters of tumor cells that penetrate into the stroma (Fig. 3A). The occurrence of non-invasive carcinoma proliferations (*in situ*) can also be observed.

Microinvasion in carcinomas in mixed tumor

Differentiating between *in situ* and invasive carcinomas in mixed tumors is possible by the presence of stromal invasion and microinvasion. The invasion areas are characterized by the presence of clusters of infiltrative tumor epithelial cells in the periductal stroma near the carcinoma components. The microinvasion is identified by the presence of carcinomas *in situ* areas with microscopic peripheral foci (with a diameter less than or equal to 1 mm) of neoplastic cells located beyond the basement membrane. Projections of neoplastic cells in continuity with areas associated with carcinomas *in situ* and disruption of the basement membrane are also considered as microinvasion.

Complex Carcinoma or Malignant Adenomyoepithelioma

This is a malignant tumor that consists of the proliferation of epithelial and myoepithelial cells.

However, there is no evidence of myxoid matrix. Differentiation from well-differentiated complex carcinomas and complex adenomas may be difficult. The absence of a capsule, presence of necrosis and atypia and high mitotic activity, support the diagnosis (15).

Papillary carcinoma

Papillary carcinomas are tumors histologically characterized by papillary arborescent epithelial proliferation with central fibrovascular stroma (Fig. 3B). Papillary lesions are classified as papillomas, carcinoma *in situ* in papillomas, papillary carcinoma *in situ* and non-invasive and invasive papillary carcinoma (105). The differentiation between benign and malignant variants is possible through the presence of myoepithelial cells within the neoplastic papillae located between epithelial cells and the basement membrane, which are not present in malignant tumors (122).

Papillomas with carcinoma *in situ* are characterized by the presence of benign papillary lesions associated with *in situ* carcinomatous areas which exhibit proliferation of uniform cells in solid or cribriform growth patterns. Unlike previously described variants, papillary carcinoma *in situ* is characterized by the presence of multiple layers of columnar and monomorphic epithelial cells and the absence of papilloma areas (90, 122).

Non-invasive papillary carcinomas or encapsulated papillary carcinomas are usually solitary tumors. Well-defined lesions consisting of malignant papillary proliferation within a dilated duct are observed. Importantly, the cells are usually well differentiated with a low to moderate histological grade. The invasive papillary carcinoma is similar to that described above, but in this case areas of stromal invasion with no papillary morphology are usually absent (90, 122).

For immunohistochemical analysis it is recommended that specific antibody labeling is used for myoepithelial neoplasms since papillary malignant neoplasms (papillary carcinoma *in situ* and invasive) exhibit loss of myoepithelial cells, while this does not occur in benign neoplasms (papilloma). The most commonly used antibodies for this purpose are those that are specific for p63 protein and alpha-smooth muscle actin (90, 122).

Tubular carcinoma

This carcinoma is characterized by epithelial proliferation arranged in a predominantly tubular fashion (Fig. 3C). The amount of stroma can vary considerably. Peritumoral lymphocytes are common whether necrosis is present or not. These tumors have a strong tendency to infiltrate into surrounding tissues and vessels (15).

Tumors with tubular and papillary areas are not rare. Using an adaptation of the classification system proposed by Seixas *et al.* (2007) (107) for feline micropapillary carcinomas, when carcinomas exhibit more than 60% tubular areas they are classified as

tubular, if they exhibit more than 60% papillary areas they are considered as papillary carcinomas. The so-called pure carcinomas are those with more than 90% prevalence of morphological characteristics.

Solid carcinoma

Solid carcinoma is a common type of cancer in dogs. It is probably more advanced than the other types, as it is often observed when tumors develop over long time periods without surgical intervention.

Microscopically, there is proliferation of epithelial cells organized in a solid arrangement, with the formation of cords, sheets or clusters (Fig. 3D). The tumor cells are undifferentiated, exhibit small and hyperchromatic nuclei, and the mitotic index is usually high (Fig. 3E). Some solid carcinomas consist of cells that possess a vacuolated cytoplasm, possibly from myoepithelial origin. The amount of stroma can vary from small to moderate. Areas of necrosis are common (15).

Special types of carcinomas

Micropapillary carcinoma

Invasive micropapillary carcinoma of the mammary gland is a rare neoplasm, well described in humans, that is correlated to lymphotropism and an unfavorable prognosis (73). In dogs, this tumor has been reported and exhibits similar behavior to those observed in humans (17, 51).

Microscopically the tumor exhibits cystic spaces similar to lymphatic vessels that are diffusely distributed throughout the breast tissue (Fig. 4A). Inside these spaces there are clusters of epithelial cells that exhibit a micropapillary pattern called "morule like" and also an abundant eosinophilic cytoplasm and a vesicular pleomorphic nucleus with prominent nucleoli.

The mitotic index is variable and metastasis to lymph nodes is commonly observed (17, 19).

In order to characterize the neoplasm the use of immunohistochemistry with a specific antibody for the epithelial membrane antigen (EMA) is recommended. This methodology allows investigators to identify the reversed polarity of the cluster of tumor cells that are in a micropapillary arrangement, through the labeling of the apical plasma membrane. The use of lymphatic endothelial markers such as D2-40 is recommended when it is necessary to differentiate between invasive areas and lymph vessels.

Invasive lobular carcinoma

Invasive lobular carcinoma (ILC) is a neoplasm that represents 5-15% of all invasive breast tumors in women (109). Patients with ILC do not have a better prognosis than those with invasive ductal carcinoma. Histologically, the neoplasm is composed of small cells in a linear arrangement ('indian row') that are uniform in size and do not reveal polarity. It is also characterized by diffuse invasion and a large amount of fibrous stroma. Neoplastic cells sometimes constitute solid foci and occasionally contain mucin with a signet-ring appearance. In addition, the cells might be

disposed in a concentric (targetoid) fashion around benign ducts. In humans, ILC is usually accompanied by *in situ* lobular lesions as in lobular carcinoma *in situ* (119).

ILC has recently been described in three dogs (100) and neoplastic cells in the primary lesions were immunohistochemically positive for the cytokeratin CK34 β E12, but negative for E-cadherin. In two dogs, subcapsular and medullary sinuses of lymph nodes were infiltrated by rounded cells morphologically similar to those of the primary tumor. However, it was difficult to distinguish these from sinusoidal macrophages as described for human patients (119). Pulmonary metastases were evident in two dogs after 63 and 80 days from first diagnosis.

Pleomorphic lobular carcinoma

Pleomorphic lobular carcinoma in humans is recognized as a variant of invasive lobular carcinoma (105, 106). The prognosis is unfavorable owing to their aggressiveness, and affected patients have a short survival time (34). In the dog, this histological type was first described in 2002, by considering the cytomorphological and immunohistochemical similarities with breast lesions in women (16).

Microscopically, tumor epithelial cells are dispersed in the stroma or arranged in a linear pattern exhibiting an irregular cell outline, abundant eosinophilic cytoplasm, pleomorphic and eccentric nuclei (105) (Fig. 4C). Cytoplasmic vacuoles are often present and are easily stained with PAS (16). Using immunohistochemistry they can be characterized by high cellular proliferation (MIB-1), and CAM 5.2 positivity associated with loss of expression of the progesterone receptor, p53 and c-erbB2 (16). The absence of E-cadherin expression at the plasma membrane is an important finding for the characterization of this histological type (124). Positivity in the cytoplasm for this molecule represents an abnormality in its expression pattern (16).

Secretory carcinoma

Secretory carcinoma is a neoplasm that rarely occurs in humans. In dogs the cytological, histological and immunophenotypical findings have been reported.

From fine needle aspiration samples, isolated cells are observed with round to oval shape and associated with numerous clusters of neoplastic epithelial cells. The nuclear chromatin is irregularly distributed with fragmented nucleoli. The cytoplasm is abundant and clear, with large secretory vacuoles that often displace the nucleus to the periphery (20).

Histopathological analysis demonstrates an infiltrative carcinoma composed of cells with clear cytoplasm and prominent vacuoles that displace the nucleus to the periphery, resembling signet ring cells (Fig. 4D). The pattern of proliferation can be solid and/or tubular containing eosinophilic secretion-filled spaces (20, 105). Neoplasms producing extracellular and intracellular content, as the lipid-rich carcinoma, rich in glycogen and mucinous should be considered as a differential diagnosis for secretory carcinoma.

Differentiation between the neoplasms can be made by using Periodic Acid Schiff (PAS) staining associated with treatment with the enzyme diastase. The intracytoplasmic content of secretory carcinoma cells is PAS positive. In contrast, cells that compose in the lipid and glycogen-rich carcinomas are PAS negative. Alpha-lactalbumin is resistant to diastase in a different way from that observed for glycogen. Moreover, immunohistochemistry allows investigators to observe intracytoplasmic alpha lactalbumins that are produced by cells of the secretory carcinoma (105, 117).

Mucinous carcinoma

This tumor is not well described in the veterinary literature and is characterized by the presence of abundant extracellular mucinous material (81). It is known as gelatinous carcinoma, colloid, mucous or mucoid (103). In humans, when the histological pattern is considered pure, patients have a good prognosis as they present a long survival time (103). Studies evaluating the clinical and pathological factors in dogs are scarce (9, 15, 83).

This histological type is characterized by proliferation of epithelial cells that may compose arrangements in solid, tubular or papillary structures with spaces filled with large amounts of eosinophilic mucinous secretion reactive to the PAS-staining in diastase and Alcian Blue (9, 82, 83) (Fig. 5A and B). At least 40% of its growth is composed of the mucinous pattern and accumulation of mucin is located predominantly in the intraductal component (103). However, leakage of mucoid substance can occur from this intraductal structure, characterizing invasive mucinous carcinoma. If carcinoma-cells are present in mucoid medium, the diagnosis of invasive mucinous carcinoma is more appropriate (103).

Lipid-rich carcinoma

The lipid-rich carcinoma is considered a rare variant of invasive ductal carcinoma of human breast cancer and is extremely uncommon in dogs (42, 82).

The histological characteristic of the tumor is neoplastic expansive growth. Tumor cells are arranged in solid nests and cords separated by a moderate amount of stroma, they have vacuolated cytoplasm and a round to flat nucleus. Unique vacuoles that displace the nucleus to the periphery (signet-ring cell) are common. The malignant diagnosis is confirmed when more than 80% of the neoplastic cells are lipid-producing cells. Atypical cellularity ranges from moderate to high and lymphatic invasion can be observed. To differentiate this tumor from other subtypes such as the secretory carcinoma and the glycogen-rich carcinoma, the use of "red oil O" and SUDAM III and IV is advised for staining intracytoplasmic lipid content on frozen sections. Moreover, the neoplastic cells that constitute lipid-rich carcinomas are PAS negative, unlike the case of secretory carcinoma (42, 95).

Immunohistochemical analysis with cytokeratins of various molecular weights and alpha actin yields varied results among affected dogs (42, 95).

Squamous cell carcinoma

This carcinoma is composed of cells in a solid arrangement in the form of sheets or cords with areas of squamous differentiation (Fig. 5C). Basaloid cells are predominant in the periphery of the tumor. The center of more differentiated tumors consists of keratin layers, forming so-called keratin pearls. Many of these tumors are highly infiltrative and lymphatic invasion is common. These should be distinguished from squamous cell carcinomas derived from the skin and appendages. This tumor is not common in dogs (15, 82).

Spindle cell carcinoma

The spindle cell carcinoma is an uncommon carcinoma subtype in dogs (82). Histologically, they are characterized by proliferation of spindle cells arranged in bundles, sometimes featuring a circular pattern. The tumor cells are characterized by an eosinophilic cytoplasm, often vacuolated and with oval vacuolated nuclei with fragmented chromatin. The confirmation of diagnosis requires that at least 80% of the tumor exhibits features of this subtype of carcinoma. The main differential diagnosis is fibrosarcoma. In spindle cell carcinomas multiple clusters of neoplastic cells are observed separated by reticular fibers, in fibrosarcomas the fibers are arranged between individual cells (12, 67, 105).

For confirmation of this neoplasm the use of immunohistochemical techniques and specific antibodies against proteins of mesenchymal (vimentin) and epithelial cells (cytokeratin) is recommended. The positive staining for cytokeratin confirms the epithelial origin of the neoplasm, discarding the occurrence of mesenchymal neoplasms such as fibrosarcoma. Moreover, for histogenetic study of the neoplasm, myoepithelial cell markers (alpha smooth muscle actin, p63 and S100) can be used (12).

Anaplastic carcinoma

This histological type is reported in dogs and is considered to have the worst prognosis because the affected female dogs present early recurrence and metastasis, which confirms its aggressiveness (72, 82).

These tumors are diffusely infiltrative and are characterized by atypical epithelial proliferation, without delineated arrangements, with individual cells invading the reactive, loose and abundant stroma (81, 82) (Fig. 5B). The cells are large, anaplastic, with bizarre nuclei, fragmented chromatin and single or double prominent nucleoli (72). The mitotic index is high, with many atypical figures. Some cells may be multinucleated (72). Areas of invasion by neoplastic cells in blood and lymphatic vascular structures are observed. Intense inflammation is a strong feature of this tumor (81). Its distinction from inflammatory lesions can be difficult; therefore, the use of immunohistochemistry with specific antibodies (keratin to mark cancer cells and specific markers for histiocytes, such as lysozyme and α -1-trypsin) is recommended (82). Anaplastic sarcomas are frequently mistaken for this histological type. Therefore, vimentin

expression and other muscle cell markers such as desmin, are useful for this distinction (82).

Mammary neoplasms with sebaceous differentiation

Mammary neoplasms may present different types of tissue differentiation in humans and dogs including bone, hematopoietic tissue and squamous epithelia (57, 82, 104). However, sebaceous differentiation is rarely reported in mammary tumors in these species and its true importance is currently unknown. In human medicine, the World Health Organization classification for breast tumors has recognized it as a distinct subtype of invasive breast carcinomas (119). However, the presence of sebaceous morphology and other neoplasm components are highly variable among the reported cases, which makes classification criteria of mammary sebaceous carcinoma ambiguous. There is only one documented case in veterinary literature (25) in which two tumors were observed in the left inguinal mammary gland, both grossly presented as whitish to light brown multilobulated and superficially ulcerated masses. Microscopically, cells with abundant foamy cytoplasm resembling sebocytes were located within intraductal papillary-like nests of mammary carcinoma, suggesting sebaceous differentiation. In addition, large areas of a solid invasive sebaceous component were observed surrounding small-sized intraductal papillary neoplastic nests. Prognosis was guarded, since lymphatic spread was detected and the patient died three months after diagnosis.

Histochemically, the sebocyte-like cells are negative for PAS, Alcian Blue and mucicarmine stains; however, Oil Red O provides a positive staining pattern. In addition, immunohistochemical detection of adipophilin could be used in paraffin-embedded tissues to achieve a more accurate diagnosis (86).

Sarcomas

Fibrosarcoma

These are malignant tumors of fibroblast cells with variable amounts of collagen. Such tumors are composed of spindle-shaped cells that produce collagen and are arranged as reticular fibers. The fibers can be arranged in parallel or disorganized. Fibrosarcomas and osteosarcomas are the most frequently encountered mammary sarcomas in the dog (15).

Osteosarcoma

This is a sarcoma characterized by osteoid and/or bone formation by neoplastic cells. These sarcomas are non-combined (pure) or combined. The combined tumors are composed of osseous and cartilaginous malignant tissues. Pleomorphism and mitotic activity are usually prominent. However, the combined sarcomas and their metastases can be highly differentiated. Osteosarcomas occur predominantly in the dog (15).

Carcinosarcoma

These are rare tumors in women and have a poor prognosis compared with other types of carcinomas (121). In the dog, clinical and pathological features resemble those described in humans. The histological characteristics of this type are extremely variable and it was previously described as a malignant mixed tumor of the mammary gland (83). These tumors grow rapidly. Macroscopically they are often well delineated with a firm to bony cut surface (81). They are composed of cells that morphologically resemble epithelial cells (luminal epithelium and/or myoepithelial) and they present with various types of differentiation including adeno-, solid, squamous, mucinous and anaplastic, and sarcomatous areas with fibro-, chondro- and osteomatous differentiation (83) (Fig. 5D). Metastases are of mixed type, sarcomatous or carcinomatous (83).

Sarcoma in mixed tumor

These are tumors with mesenchymal malignant cell foci or distinct nodules in benign mixed tumors. The criteria for malignancy evaluation of the mesenchymal component of mixed tumors are the same as for sarcomas, which take into account cellularity, cytological atypia and mitotic index (45). Unlike carcinomas in mixed tumors, which are very frequent, the sarcomatous transformation in benign mixed tumors is very rare.

Other sarcomas

Pure chondrosarcoma, liposarcomas and hemangiosarcoma are very rare but when present in the mammary gland they have morphological features similar to those observed in other organs (82).

1. PROGNOSIS

Prognostic and predictive markers

Prognostic factors can be defined as one or more specific clinical, pathological and biological characteristics of individuals and their tumors that permit prediction of clinical outcome and survival of patients without subjecting them to additional and adjuvant therapies after initial surgery (23). Otherwise, the evaluation of predictive markers allows the selection of patients for specific and individualized treatments (76).

The study of prognostic factors is of utmost importance, as it enables the behavior and clinical outcome of breast neoplasms to be predicted using individualized therapeutic protocols with appropriate intensity and effectiveness (1, 28, 78, 128, 129). In mammary tumors of female dogs, they are useful for studies concerning comparative pathology, and the search for experimental models for research.

In women's breast cancer, various clinical and pathological factors such as tumor size, lymph node involvement, histological type and grade are traditionally evaluated for clinical staging and prognosis. Currently, veterinary oncologists seek

information concerning the histological variant of the tumor and other prognostic indicators (48). In this respect, the determination of mitotic index, a parameter measured in the histological grading system of Nottingham modified by Elston and Ellis (1998) (38), is an interesting prognostic tool for estimating cell proliferation in canine mammary tumors. The advantages of assessing the mitotic index include the fact that it is cost-effective, applicable to most histological types and can be performed on sections of formalin-fixed tissues, and demonstrates significant association with the MIB-1 label index (36).

Molecular markers have been evaluated as information sources for prognosis and to predict the behavior of various types of cancers in humans and animals. Hormone receptors (estrogen receptor - ER and progesterone receptor - PR), COX-2, a marker of the tumor proliferative index (MIB-1), a marker of angiogenesis (CD31), epidermal growth factor (EGF), adhesion molecules (E-cadherin and β -catenin), Her-2 and p53 are examples of important prognostic markers evaluated in canine mammary tumors using immunohistochemistry (18, 31, 48, 52, 70, 71, 75, 78, 101, 120, 128, 129).

Estrogen, progesterone and epidermal growth factor receptors have been identified in female canine mammary tumors and there is coexistence of these receptors in the same neoplasm (81). It is believed that there is an inverse relationship between the number of hormonal receptors and the proliferative capacity of the neoplastic cells (18, 26, 54).

The analysis of hormone receptors, COX-2 and MIB-1 expression should be incorporated into the routine as it is associated with the indication of specific therapeutic protocols. Therefore, these markers are considered predictive factors (77).

In dogs, similar results to those described in women were observed in terms of increased expression of MIB-1 (immunohistochemical marker of cell proliferation) in malignant mammary tumors, particularly in less differentiated cancers, and by the inverse correlation with immunostaining for progesterone receptor (18).

Cyclooxygenase-2 (COX-2) is a potential marker for mammary cancer in women and dogs as its expression is higher in tumors with poor prognosis. It is inversely correlated with the overall survival rate, which changes the prognosis (71, 102). Some studies correlate the high expression of COX-2 to malignancy, increased proliferative capacity of neoplastic cells, decreased apoptotic rate and neovascularization, factors that increase the metastatic potential of the tumor cells (35).

High levels of angiogenic factors and histological evidence of increased tumor neovascularization detected by measuring the density of microvessels has been described as being of important prognostic value in human medicine for various solid tumors (111). Other factors such as reduction or loss of E-cadherin and β -catenin expression are associated with lower tumor cell differentiation, invasiveness and

metastasis to regional lymph nodes (8), directly influencing prognosis (52).

Several studies demonstrate that HER-2 protein over-expression correlates with shorter survival, shorter disease-free periods and poor prognosis in humans (96, 112). Furthermore, mutations in the p53 gene are frequent in malignant mammary tumors of the dog and are associated with tumor progression (123).

The identification of tumor markers is a valuable method for predicting the behavior of the neoplasm and to determine the prognosis of the disease. However, an accurate prognosis of a canine patient with mammary tumor can be difficult, since the biological behavior of these tumors varies considerably. Therefore, in veterinary medicine the increasing incidence and complexity of the clinical outcome of mammary tumors in female dogs have attracted special interest in the study of prognostic markers and their standardization so that they can be used as independent prognostic factors.

Evaluation of markers

The evaluation of immunostaining is variable and dependent on the antibody. It can be quantitative, qualitative or semi-quantitative.

The most commonly used antibodies for immunohistochemical evaluation of mammary tumors are the markers for hormone receptors (ER and PR) that allow assessment of the degree of differentiation of the neoplasm, and markers of cell proliferation (MIB/ki67) that determine the rate of cell proliferation and specific antibodies that are important for assessing the expression of growth factor receptors (HER-2 and EGFR). Lower survival was recently demonstrated for patients whose tumors had a higher density of microvessels and increased expression of Cox-2 (71).

For immunostaining of ER and PR, semi-quantitative analysis adapted by the American Society of Clinical Oncology / American College of Pathology (ASCO / ACP) is used (58). The analysis includes evaluation of the proportion of positive neoplastic cells for the marker (0, none; 1, <1/100; 2, 1/100 to 1/10; 3, 1/10 to 1/3; 4, 1/3 to 2/3 and 5, > 2/3) and intensity of staining (0, unmarked; 1, low; 2, intermediate and 3, strong). By calculating the sum of the scores for each feature a total score ranging from 0-8 can be obtained and positivity is determined with a total score ≥ 2 when more than 1% of tumor cells are stained.

Evaluation of Ki67 staining (clone MIB-1) should be considered using a high magnification field (40X) and ranked as a high proliferative index (tumors with more than 25% labeled nuclei), intermediate proliferative index (tumor with 10% to 25% of labeled nuclei) or low proliferative index (tumors with less than 10% labeled nuclei) (65).

Cox-2 label analysis is semi-quantitative and the distribution score is estimated by the percentage of positive cells in five fields of high magnification (40x). For all tumors, a value of distribution between 0 and 4 is obtained, where 0 means 0%, 1 means less than 10% of cells labeled, 2 for 10 to 30%, 3% for 31 to 60 and 4 over 61% of labeled cells. Values for the intensity of

staining are given from 0-3, where 0 means no labeling (-), 1 is equivalent to weak labeling (+), 2 for moderate labeling (+ +) and 3 for strong intensity (+ + +). The final score ranges from 0 to 12 and is obtained by multiplying the intensity and distribution values (35, 60).

For HER-2 and EGFR, the semi-quantitative method proposed by the American Society of Clinical Oncology/American College of Pathology (ASCO/ACP) (126) is used. The sample is considered negative with scores of 0 to 1+, indeterminate with a 2+ score and positive for 3+ score. The score 0 is characterized by absence of labeling of the cytoplasmic membrane; 1+ when membrane labeling is weak and incomplete in any proportion of tumor cells, 2+ when labeling is complete, uneven and of low intensity in more than 10% of tumor cells or complete and intense membrane labeling of 30% or less of tumor cells; 3+ for more than 30% of complete uniform and intense membrane labeling in tumor cells.

2. TREATMENT

Surgery

The complete surgical removal of localized tumors without metastatic involvement is the therapeutic procedure with the highest probability of cure. Surgical excision of mammary tumors allows histopathological examination, increases survival time and the patient's quality of life, and can be curative, with the exception of inflammatory carcinoma or the existence of distant metastasis (30, 31).

The surgery type depends on the disease extent, lymphatic drainage, size and location of the lesion (69, 111). Small lesions of 0.5 cm can be treated by nodulectomy or lumpectomy, after evaluation of the aforementioned parameters of malignancy such as skin or muscle adhesion and the existence of ulcerations. Other tumors are removed by mastectomy, either simple (centralized injury, not adhered or ulcerated, with 2 to 4 cm), in block or radical, depending on the lymphatic drainage of the affected mammary gland (7, 69). It is important to ensure the surgical excision of the lesion and the whole tissue interposed between the mammary gland and lymphatic drainage (84).

Surgical excision may be curative in dogs with stage I of the disease and small tumors, non-invasive and well differentiated carcinomas. Dogs with large and high grade tumors, with a greater chance of metastatic development may benefit from additional therapy (111).

The advantages of local excision versus radical excision are widely debated. In a study of 144 dogs conducted by MacEwen *et al.* in 1985 (74), the results of single mastectomy and the removal of the whole chain were compared. There were no differences in recurrence rates and survival of these patients. However, the study published by Stratmann *et al.* (2008) (115) suggests that the entire mammary chain should be removed regardless of the number and size of lesions along the mammary chain. The authors report a

higher frequency of new neoplastic lesions appearing in the remaining mammary tissue of dogs that underwent regional mastectomy (58%), although the statistical significance of these values was not assessed. Recurrence is defined as a new tumor that develops in the same location from where the first tumor was removed; however, this was not observed in any of the 99 animals analyzed in the study. Radical mastectomy is indicated by the authors as the only treatment option for dogs with mammary neoplasms based on tumor excision and prevention of new lesions, without considering the evaluation of prognostic factors well established in the literature and described herein.

Lymphatic drainage

The lymphatic system is considered the main route for metastasis of malignant tumors of the mammary gland in dogs. Surgery for mammary tumors implies the removal of the tumor and associated glands with lymphatic drainage and the lymph node. It is important that the surgeon has knowledge concerning lymphatic drainage of canine mammary tumors so that the surgical excision can be performed adequately and an accurate prognosis be determined (91).

Patsikas *et al.* (2006) (91), studying the lymphatic drainage of neoplastic mammary glands,

reported that thoracic cranial and caudal breasts drain toward the ipsilateral axillary lymph nodes. The abdominal cranial breast drains mainly into the axillary lymph node, but simultaneously into the ipsilateral superficial inguinal lymph node. The caudal and inguinal abdominal glands drain into the ipsilateral superficial inguinal lymph node. Furthermore, they report that lymphatic connections between neoplastic and normal adjacent mammary glands are rare but can occur.

Chemotherapy

Chemotherapy has been used in dogs with malignant mammary gland tumors as an adjuvant therapy. However, there is limited information regarding the efficacy of adjuvant chemotherapy (111). The protocols proposed in the literature consist of the use of doxorubicin associated with cyclophosphamide or the use of cisplatin or carboplatin as single drugs, but further studies are required to determine an efficient protocol for canine mammary tumors (29, 69, 84, 88). The following protocols (Tables 5 to 11) are also described in the literature:

Table 5: Protocol Doxorubicin and Cyclophosphamide.

Day	Doxorubicin	Cyclophosphamide
1 st	X	
3 rd /4 th /5 th /6 th		X
22 nd	Repeat this cycle, every 21 days, 3 to 6 times total.	

Posology
Doxorubicin: 30mg/ m ² /IV or 1mg/ kg/ IV (for dogs weighing less than 10kg).
Cyclophosphamide: 50mg/ m ² / oral

Table 6: Protocol Gemcitabine and Carboplatin.

Day	Gemcitabine	Carboplatin
1 st	X	X
8 th	X	
22 nd	Repeat this cycle, every 21 days, 3 to 6 times total.	

Posology
Gemcitabine: 200mg/m ² /IV, for 20 minutes, 4 hours before carboplatin.
Carboplatin: 10mg/kg /IV, for 20 minutes.

Table 7: Protocol Carboplatin.

Day	Carboplatin
1 st	X
22 nd	Repeat this cycle, every 21 days, 3 to 6 times total.

Posology
Carboplatin: 250 to 300mg/ m ² / IV, every 21 days.

Table 8: Protocol Doxorubicin and Carboplatin (more appropriate in case of carcinosarcomas).

Day	Doxorubicin	Carboplatin
1 nd	X	
15 th		X
22 nd	Administrate the drugs interchangeably every 2 or 3 weeks, totalizing 3 administrations of each one.	

Posology
Doxorubicin: 30mg/ m ² / IV ou 1mg/ kg/ IV (for dogs weighing less than 10kg).
Carboplatin: 250 to 300mg/ m ² / IV, every 21 days.

With occurrence of metastasis in the lung parenchyma or other organs, the treatment of choice is antineoplastic

chemotherapy, and the use of paclitaxel has proved to increase survival in some cases (Table 9).

Table 9: Protocol Paclitaxel.

Day	Paclitaxel
1 st	X
22 nd	Administer the drug every 21 days, 3 to 6 times total.

POSOLGY
Paclitaxel: 170mg/ m ² / IV or 5mg/ kg/ IV
Pre-medicate patients with dexamethasone and diphenhydramine three days before and after chemotherapy infusion to minimize the occurrence of hypersensitivity reactions.

After histopathological evaluation, patients diagnosed with solid carcinomas, micropapillary carcinomas, anaplastic carcinomas and carcinosarcomas should undergo chemotherapy even when lymph node or lung metastasis is not evident. Chemotherapy is recommended for patients with metastasis regardless of the histological type of tumor.

Monitoring of patients should occur every three months in the first year after chemotherapy and

every semester during the second year until completion of a two year period.

Cox inhibitors

The increased Cox-2 expression in canine mammary tumors has been associated with more aggressive tumors and a worse prognosis. Heller *et al.* (2005) (60) observed 50% immunostaining for Cox-2 in the analyzed tumors and higher staining in anaplastic

carcinomas compared with adenocarcinomas. Lavalle *et al.* (2009) (71) observed that increased expression of COX-2 was associated with a worse prognosis and shorter survival time, and suggested that the use of COX-2 may be an alternative in the treatment and control of advanced neoplastic disease of the mammary gland in female dogs.

Souza *et al.* (2009) (113) demonstrated strong COX-2 expression in inflammatory carcinomas and submitted these patients to treatment with piroxicam. An improvement in clinical conditions and increased survival of the treated animals was observed.

The use of Cox-2 inhibitors (firocoxib, Table 10) is conditional upon completion of immunohistochemical analysis (score > 6) and confirmed Cox-2 positivity, reinforcing the use of Cox-2 as a predictive factor for mammary cancer in dogs (71).

Inflammatory carcinoma

Table 10: Protocol Firocoxib.

POSOLOGY
Firocoxib: 5mg/ Kg/ oral – every 24 hours
Administration for 6 consecutive months, with monthly evaluation of renal function and hemogram.

Table 11: Protocol Docetaxel and Piroxicam

Day	Docetaxel	Piroxicam
1 st	X	Every day of the cycle
22 nd	Repeat this cycle, every 21 days, 3 to 6 times total.	

POSOLOGY
Docetaxel: 30mg/ m ² / IV, every 21 days.
Pre-medicate patients with dexamethasone and diphenhydramine three days before and after chemotherapy infusion to minimize the occurrence of hypersensitivity reactions.
Piroxicam: 0,3mg/kg /oral/SID or 0,5mg/ kg/oral, every 48 hours.

Hormone therapy

According to Sorenmo (2003) (111), most mammary tumors in female dogs (both benign and malignant) expressed ER and the dogs that have carcinomas positive for this receptor present a higher survival rate and are candidates for hormone therapy (77).

Benign epithelial tumors and well differentiated carcinomas often demonstrate positivity for ER, while poorly differentiated and anaplastic

In inflammatory carcinomas, as surgical neoplasm resection is not recommended, therapies that promote the effective control of pain associated with antineoplastic chemotherapy are indicated. Piroxicam at a dose of 0.3 mg/kg/oral every 24 hours or 0.5 mg/kg orally every 48 hours, has provided increased survival of dogs with inflammatory carcinoma (113). The administration should last as long as possible, and if the patient can tolerate the treatment it should last between three to six months. Another option for chemotherapy for this neoplasm is the combination of docetaxel and piroxicam (Table 11). Recently, a new alternative treatment has been proposed using firocoxib 5mg/kg/oral every 24 hours (Table 10) in an attempt to provide clinical improvement (10).

tumors tend to be negative for this hormone receptor (48, 108).

The presence of hormone receptors in mammary tumors of female dogs suggests that hormone therapy may be an alternative treatment for this species, as is the case in human medicine (111, 118). It is necessary to evidence the antiestrogenic therapeutic benefit in veterinary medicine by carrying out studies using appropriate methodology and clinical follow up.

With respect to ovariectomy (OH), Fonseca and Daleck (2000) (50) performed an extensive

literature review and concluded that the development of mammary tumors in female dogs is an event programmed in the first years of life, and is not influenced by suppression of hormone stimuli at maturity; early OH appears to be the only method of preventing hormonal variability that occurs during the estrous cycle, which undoubtedly influences the development of these tumors. OH held at the time of surgical excision of the breast tumor in female dogs has no protective effect on the appearance of new tumors, metastases or on the extension of life span.

It is suggested that spayed dogs suffering from hormone receptor positive tumors can be treated with tamoxifen (0.8 mg / kg), but confirmatory studies are required (118).

3. FINAL COMMENTS

According to the available literature the use of TNM clinical staging criteria and evaluation of classic morphological prognostic factors (tumor size, mitotic count, histological grade and type, and lymphatic involvement), well established for humans, are useful in assessing the prognosis of female dogs with mammary carcinomas. Therefore, the diagnostic criteria should be improved and standardized, and continued investment in the study of prognostic and predictive markers is needed so that these factors are employed routinely by veterinary pathologists and provided to physicians and surgeons in an attempt to achieve appropriate treatment planning so that new treatment options and longer survival for these patients can be established. The aim is not to submit patients to unnecessary aggressive treatments or to fail to treat those who would benefit. The quality of life of the animal should always be prioritized.

References

1. ABREU E., KOIFMAN S. Fatores prognósticos no câncer da mama feminina. *Rev. Bras. Cancerol.*, 2002, 48, 113-131.
2. AJCC, American Joint Committee on Cancer. (<http://www.cancerstaging.org/index.html>).
3. ANTUOFERMO E., MILLER MA., PIRINO S., XIE J., BADVE S., MOHAMMED SI. Spontaneous mammary intraepithelial lesions in dogs - a model of breast cancer. *Cancer Epidemiol. Biomarkers Prev.*, 2007, 16, 2247-2256.
4. BENTUBO HDL., SOBRAL RA., UBUKATA R., HONDA ST., XAVIER JG. Carcinoma inflamatório de mama em cadela - relato de caso. *Clínica Veterinária*, 2006, 65, 40-44.
5. BERTAGNOLLI AC., CASSALI GD., GENELHU MCLS., COSTA FA., OLIVEIRA JFC., GONÇALVES PBD. Immunohistochemical Expression of p63 and Np63 in Mixed Tumors of Canine Mammary Glands and Its Relation with p53 Expression. *Vet. Pathol.*, 2009, 46, 407-415.
6. BOSTOCK DE. Canine and feline mammary neoplasms. *Br. Vet. J.*, 1986, 142, 506-515.
7. BRODEY RS., GOLDSCHMIDT MH., ROSZEL JR. Canine mammary gland neoplasms. *J. Am. Anim. Hosp. Assoc.*, 1983, 19, 61-90.
8. BRUNETTI B., SARLI G., PREZIOSI R., MONARI I., BENAZZI C. E-Cadherin and β -catenin reduction influence invasion but not proliferation and survival in canine malignant mammary tumors. *Vet. Pathol.*, 2005, 42, 781-787.
9. BRUNETTI B., SARLI G., MARCATO PS., BENAZZI C. Histochemical and immunohistochemical characterization of canine mammary mucinous carcinoma. *J. Comp. Pathol.*, 2003, 129, 131-136.
10. CAMPOS LC., LAVALLE GE., CARNEIRO RA., DUTRA AP., VIANA AAS., CASSALI GD. Carboplatina e inibidor de COX-2 no tratamento do carcinoma inflamatório de mama em cadela: relato de caso. *Rev. Clin. Vet.*, 2011, 92, 72-76.
11. CARDOSO MJL, BARBOSA MVF, SILVA SRV, ROCHA NS, FABRIS VE. Inflammatory mamma carcinoma in bitch. *Rev. Brasil. Med. Vet.*, 2002, 24(6), 262-264.
12. CARTER MR, HORNICK JL., LESTER S, FLETCHER CD. Spindle cell (sarcomatoid) carcinoma of the breast: a clinicopathologic and immunohistochemical analysis of 29 cases. *Am. J. Surg. Pathol.*, 2006, 30, 300-309.
13. CASSALI GD., BERTAGNOLLI AC., LAVALLE GE., TAVARES WLF., FERREIRA E., SILVA AE., CAMPOS CB. Perspectives for diagnosis, prognosis and treatment of mammary neoplasms in dogs. 34th World Small Animal Veterinary Congress - WSAVA 2009, 2009, São Paulo. Proceedings of the 34th World Small Animal Veterinary Congress - WSAVA 2009, 2009.
14. CASSALI GD., GOBBI H., MALM C., SCHMITT F. Evaluation of accuracy of fine needle aspiration cytology for diagnosis of canine mammary tumours: comparative features with human tumours. *Cytopathology (Oxford)*, 2007, 18, 191-196.
15. CASSALI GD. Patologias da glândula mamária. NASCIMENTO EF., LIMA RS. (Ed.). *Patologia da reprodução dos animais domésticos*. Rio de Janeiro: Guanabara Koogan, 2002a, 2, 131-133.
16. CASSALI GD., GÄRTNER F., SCHMITT FC. Pleomorphic lobular carcinoma of the canine mammary gland: histopathologic and immunohistochemical features. *Arq. Bras. Med. Vet. Zootec.*, 2002b, 54.
17. CASSALI GD., SERAKIDES R., GÄRTNER F., SCHMITT FC. Invasive micropapillary

- carcinoma of the dog mammary gland. A case report. *Arq. Bras. Med. Vet. Zootec.* 2002c, 24, 366-369.
18. CASSALI GD. Estudos morfológicos, imunohistoquímicos e citométrico de tumores mamários da cadela – aspectos comparativos com neoplasias da mama humana. (2000). 73 f. (Doutorado) - Ciência Animal, Universidade Federal de Minas Gerais, Belo Horizonte, 2000.
 19. CASSALI GD., GÄRTNER F., VIEIRA DA SILVA MJ., SCHMITT FC. Cytological diagnosis of a metastatic canine mammary tumor in pleural effusion. *Arq. Bras. Med. Vet. Zootec.*, 1999a, 51, 307-310.
 20. CASSALI GD., GOBBI H., GARTNER F., SCHMITT FC. Secretory carcinoma of the canine mammary gland. *Vet. Pathol.*, 1999b, 36, 601-603.
 21. CASSALI GD., GOBBI H, MALMA C., OLIVEIRA SR., GHELLER VA. Protocol for the examination of cytologic specimens obtained by fine needle aspiration biopsy (FNAB) of canine breast tumors. *Arq. Bras. Med. Vet. Zootec.*, 1998, 50, 475-478.
 22. CASTELLANO MC., IDIART JR. Carcinoma mamário inflamatório em la perra. *Rev. Méd. Vet.*, 1994, 76(4), 244- 248.
 23. CAVALCANTI MF., CASSALI GD. Fatores prognósticos no diagnóstico clínico e histopatológico dos tumores de mama em cadelas - revisão. *Clin. Vet.*, 2006, 11, 56-64.
 24. CAVALCANTI MF. Fatores prognósticos na abordagem clínica e histopatológica dos carcinomas mamários de cadelas: estadiamento TNM e sistema de Nottingham. (2006). 106 f. (Mestrado) - Patologia, Universidade Federal de Minas Gerais, Belo Horizonte, 2006.
 25. CHANG SC., LIAO JW., WONG ML., LAI YS., LIU CI. Mammary carcinoma with sebaceous differentiation in a dog. *Vet Pathol.*, 2007, 44(4), 525-527.
 26. COSTA C., SOARES R., REIS-FILHO JS., LEITÃO D., AMENDOEIRA I., SCHMITT FC. Cyclo-oxygenase 2 expression is associated with angiogenesis and lymph node metastasis in human breast cancer. *J. Clin. Pathol.*, 2002, 55, 429-434.
 27. DABBS DJ., CARTER G., FUDGE M., PENG Y., SWALSKY P., FINKELSTEIN S. Molecular alterations in columnar cell lesions of the breast. *Mod. Pathol.*, 2006, 19, 344-349.
 28. DAGLI MLZ. The search for suitable prognostic markers for canine mammary tumors: A promising outlook. *Vet. J*, 2008, 177, 3-5.
 29. DALECK CR., DE NARDI AB., RODASKI S. *Oncologia em Cães e Gatos*. 1. ed. São Paulo: Roca, 2009.
 30. DALECK CR., FRANCESCHINI PH., ALESSI AC., SANTANA AE., MARTINS MIM. Aspectos Clínicos e Cirúrgicos do Tumor Mamário Canino. *Ciência Rural*, 1998, 28, 95-100.
 31. DE NARDI AB., DALECK CR., LAUFER-AMORIM R., RODASKI S., PIEKARZ CH., MAGALHAES GM., CALAZANS SG., FERNANDES SC., CESAR JRF., CASTRO JHT., SILVA MCV., MOTTA FR. Correlação da ciclooxigenase-2 com o prognóstico dos carcinomas mamários de cadelas. *Acta Scient. Vet.*, 2007, 35, 619-627.
 32. DE NARDI AB., RODASKI S., SOUSA RS., COSTA TA., MACEDO TR., RODIGHIERI SM., RIOS A., PIEKARZ CH. Prevalência de neoplasias modalidade de tratamentos em cães, atendidos no Hospital Veterinário da Universidade Federal do Paraná. *Arch. Vet. Sci.*, 2002, 7, 15-26.
 33. DESTEXHE E., LESPAGNARD L., DEGEYTER M., HEYMAN R., COIGNOUL F. Immunohistochemical identification of myoepithelial, epithelial, and connective tissue cells in canine mammary tumors. *Vet. Pathol.*, 1993, 30, 146-154.
 34. DI COSTANZO D., ROSEN PP., GAREEN I., FRANKLIN S., LESSER M. Prognosis in infiltrating lobular carcinoma. An analysis of classical and variant tumors. *Am. J. Surg. Pathol.*, 1990, 14, 12-23.
 35. DORÉ M., LANTHIER I., SIROIS J. Cyclooxygenase-2 Expression in Canine Mammary Tumors. *Vet. Pathol.*, 2003, 40, 207-212.
 36. DUTRA AP., AZEVEDO JUNIOR GM., SCHMITT FC., CASSALI GD. Assessment of cell proliferation and prognostic factors in canine mammary gland tumors. *Arq. Bras. Med. Vet. Zootec.*, 2008, 60, 1403-1412.
 37. DUTRA AP., GRANJA NVM., SCHMITT FC., CASSALI GD. C-erbB-2 expression and nuclear pleomorphism in canine mammary tumors. *Braz. J. Med. Biol. Res.*, 2004, 37, 1673-1681.
 38. ELSTON CW., ELLIS IO. Assessment of histological grade. ELSTON CW., ELLIS IO. (Ed.). *Systemic Pathology. The breast*. London: Churchill Livingstone, 1998, 365-384.
 39. ELSTON CW., ELLIS IO. Pathological prognostic factors in breast cancer. I. The value of histological grade in breast cancer: experience from a large study with long-term follow-up. *Histopathol.*, 1991, 19, 403-410.
 40. ERDELYI I., VAN ASTEN AJ., VAN DIJK JE., NEDERBRAGT H. Expression of versican in relation to chondrogenesis-related extracellular matrix components in canine mammary tumors. *Histochem. Cell Biol.*, 2005, 124, 139-149.
 41. ESPINOSA DE LOS MONTEROS A., MILLÁN

- MY., RAMÍREZ GA., ORDÁS J., REYMUNDO C., MARTÍN DE LAS MULAS J. Expression of maspin in mammary gland tumors of the dog. *Vet. Pathol.*, 2005, 42, 250–257.
42. ESPINOSA DE LOS MONTEROS A., HELLMÉN E., RAMÍREZ GA., HERRÁEZ P., RODRÍGUEZ F., ORDÁS J., MILLÁN Y., LARA A., MARTÍN DE LAS MULAS J. Lipid-rich carcinomas of the mammary gland in seven dogs: clinicopathologic and immunohistochemical features. *Vet. Pathol.*, 2003, 40, 718-723.
43. ESPINOSA DE LOS MONTEROS A., MILLÁN MY., ORDÁS J., CARRASCO L., REYMUNDO C., MARTÍN DE LAS MULAS J. Immunolocalization of the smooth muscle-specific protein calponin in complex and mixed tumors of the mammary gland of the dog: assessment of the morphogenetic role of the myoepithelium. *Vet. Pathol.*, 2002, 39(2), 247-256.
44. ESTRELA-LIMA A., ARAUJO MSS., COSTA-NETO JM., TEIXEIRA-CARVALHO A., BARROUIN-MELO SM., CARDOSO SV., MARTINS-FILHO OA., SERAKIDES R., CASSALI GD. Immunophenotypic features of tumor infiltrating lymphocytes from mammary carcinomas in female dogs associated with prognostic factors and survival rates. *BMC Cancer*, 2010, 10, 1-14.
45. EVANS HL., AYALA AG., ROMSDAHL MM. Prognostic factors in chondrosarcoma of bone: a clinicopathologic analysis with emphasis on histologic grading. *Cancer*, 1977, 40(2), 818-831.
46. FERREIRA, E. Análise histomorfológica, imuno-histoquímica e de hibridização cromogênica in situ em lesões mamárias epiteliais ductais não neoplásicas de cadelas. (2010). (Doutorado) - Patologia, Universidade Federal de Minas Gerais, Belo Horizonte, 2010a.
47. FERREIRA E., GOBBI H., SARAIVA B., CASSALI G. Columnar cell lesions of the canine mammary gland: pathological features and immunophenotypic analysis. *BMC Cancer*, 2010b, 10, 1-7.
48. FERREIRA E., BERTAGNOLLI AC., CAVALCANTI MF., SCHMITT FC., CASSALI GD. The relationship between tumour size and expression of prognostic markers in benign and malignant canine mammary tumours. *Vet. Comp. Oncol.*, 2009, 193, 1-6.
49. FERREIRA E., BREGUNCI GC., SCHMITT FC., CASSALI GD. Protocol for the anatomopathological examination of canine mammary tumors. *Arq. Bras. Med. Vet. Zootec.*, 2003, 55, 105-109.
50. FONSECA CS., DALECK CR. Neoplasias mamárias em cadelas: influência hormonal e efeitos da ovariectomia como terapia adjuvante. *Ciência Rural*, 2000, 30, 731-735.
51. GAMA A., ALVES A., SCHMITT FC. Clinicopathologic features of mammary invasive micropapillary carcinoma (IMC) in dogs. *Vet. Pathol.*, 2008a, 45, 600-601.
52. GAMA A., PAREDES J., GÄRTNER F., ALVES A., SCHMITT F. Expression of E-cadherin, P-cadherin and β -catenin in canine malignant mammary tumours in relation to clinicopathological parameters, proliferation and survival. *Vet. J.*, 2008b, 177, 45-53.
53. GAMA A., ALVES A., GÄRTNER F., SCHMITT F. P63: a novel myoepithelial cell marker in canine mammary tissues. *Vet. Pathol.*, 2003, 40, 412–420.
54. GERALDES M., GÄRTNER F., SCHMITT F. An immunohistochemical study of hormonal receptors and cell proliferation in normal canine mammary glands and spontaneous mammary tumours. *Vet. Rec.*, 2000, 146, 403-406.
55. GILBERTSON SR., KURZMAN ID., ZACHRAU RE., HURVITZ AI., BLACK MM. Canine mammary epithelial neoplasms: biologic implications of morphologic characteristics assessed in 232 dogs. *Vet. Pathol.*, 1983, 20, 127-142.
56. GOMES C., VOLL J., FERREIRA KCRS., FERREIRA RR., OLIVEIRA LO., CONTESSINI EA., OLIVEIRA RT. Carcinoma inflamatório mamário canino. *Acta Scien. Vet.*, 2006, 34, 171-174.
57. GRANDI F., COLODEL MM., MONTEIRO LN., LEÃO JRVP., ROCHA NS. Extramedullary hematopoiesis in a case of benign mixed mammary tumor: cytological and histopathological assessment. *BMC Vet Res*. 2010, 6, 45.
58. HAMMOND MEH., HAYES DF., DOWSETT MD., ALLRED C., HAGERTY KL., *et al.* American Society of Clinical Oncology/College of American Pathologists Guideline Recommendations for Immunohistochemical Testing of Estrogen and Progesterone Receptors in Breast Cancer. *J. Clin. Oncol.*, 2010, 28(16), 2784-2795.
59. HANBY AM., HUGHES TA. In situ and invasive lobular neoplasia of the breast. *Histopathol.*, 2008, 52, 58–66.
60. HELLER DA., CLIFFORD CA., GOLDSCHMIDT MH., HOLT DE., SHOFRER FS., SMITH A., SORENMO KU. Cyclooxygenase-2 Expression is Associated with Histologic Tumor Type in Canine Mammary Carcinoma. *Vet. Pathol.*, 2005, 46, 776-780.
61. HELLMÉN E., BERGSTRÖM R., HOLMBERG L., SPÅNGBERG IB., HANSSON K., LINDGREN A. Prognostic factors in canine mammary tumors: a multivariate study of 202 consecutive cases. *Vet. Pathol.*, 1993, 30, 20-27.

62. JAIYESIMI IA., BUZDAR AU., HORTOBAGYI G. Inflammatory breast cancer: a review. *J. Clin. Oncol.*, 1992, 10(6), 1014-1024.
63. KARAYANNOPOULOU M., KALDRYMIDOU E., CONSTANTINIDIS TC., DESSIRIS A. Histological grading and prognosis in dogs with mammary carcinomas: application of a human grading method. *J. Comp. Pathol.*, 2005, 20, 1-7.
64. KARAYANNOPOULOU M., KALDRYMIDOU E., CONSTANTINIDIS TC., DESSIRIS A. Adjuvant post-operative chemotherapy in bitches with mammary cancer. *J. Vet. Med. Series A*, 2001, 48(2), 85-96.
65. KESHGEGIAN AA., CNAAN A. Proliferation markers in breast carcinoma: mitotic figure count, S-phase fraction, proliferating cell nuclear antigen, Ki-67 and MIB-1. *Am. J. Clin. Pathol.*, 1995, 104, 42-49.
66. KURZMAN ID., GILBERTSON SR. Prognostic factors in canine mammary tumors. *Seminars in Veterinary Medicine and Surgery (Small Animal)*, 1986, 1, 25-32.
67. KUSEWITT DF., HAHN FF., MUGGENBURG BA. Ultrastructure of a spindle cell carcinoma in the mammary gland of a dog. *Vet. Pathol.*, 1992, 29, 179-181.
68. LAGADIC M., ESTRADA M., CAMADRO JP., DURAND P., GOEBEL J. Tumeurs mammaires de la cne: critères d'u pronostic histologique et intérêt d'un grading. *Rec. Méd. Vét.*, 1990, 166, 1035-1042.
69. LANA SE., RUTTEMAN GR., WITHROW SJ. Tumors of the mamary gland. WITHROW SJ., VAIL DM. *Withrow & MacEwen's Small Animal Clinical Oncology*. 4° ed. Philadelphia: W. B. Saunders Company. 2007, 619-636.
70. LAUFER-AMORIM R., SOUZA CHM., BANDARRA EP., SANCHES OC., PIZA ET. Immunohistochemical study of estrogen and progesterone receptors and cell proliferative index in canine inflammatory mammary carcinoma: 9 cases. *Braz. J. Vet. Pathol.*, 2008, 1, 16-20.
71. LAVALLE GE., BERTAGNOLLI AC., TAVARES WLF., CASSALI GD. Cox-2 expression in canine mammary carcinomas: correlation with angiogenesis and overall survival. *Vet. Pathol.*, 2009, 46, 1275-1280.
72. LOSCO PE. Local and peripheral eosinophilia in a dog with anaplastic mammary carcinoma. *Vet. Pathol.*, 1986, 23, 536-538.
73. LUNA-MORÉ S., GONZALEZ B., ACEDO C., RODRIGO I., LUNA C. Invasive micropapillary carcinoma of the breast. A new special type of invasive mammary carcinoma. *Pathol. Res. Pract.*, 1994, 190, 668-664.
74. MACEWEN EG., HARVEY HJ., PATNAIK AK., JAY H., PATNAIK AK., MOONEY S., HAYES A., KURZMAN I., HARDY WDJ. Evaluation of effects of levamisole and surgery on canine mammary cancer. *J. Biol. Response Mod.*, 1985, 4, 418-426
75. MACEWEN EG., PATNAIK AK., HARVEY HJ., PANKO WB. Estrogen receptors in canine mammary tumors. *Cancer Res.*, 1982, 42, 2255-2259.
76. MARINHO VFZ., METZE K., SANCHES FSF., ROCHA GFS., GOBBI H. Marcadores moleculares em câncer de mama preditivos de metástases axilares. *Rev. Assoc. Med. Bras.*, 2008, 53, 203-207.
77. MARTIN PM., COTARD M., MIALOT JP, ANDRÉ F, RAYNAUD JP. Animal models for hormone-dependent human breast cancer. Relationship between steroid receptor profiles in canine and feline mammary tumors and survival rate. *Cancer Chemother. Pharmacol.* 1984, 12, 13-17.
78. MARTINS DC., PLIEGO CM, FERREIRA MLG., FERREIRA AMR. Utilização de marcadores prognósticos no estudo da proliferação celular em adenocarcinomas mamários. *Ciênc. Anim. Bras. (UFG)*, 2008, 9, 125-127.
79. MATOS AJF., FAUSTINO AMR., LOPES C., RUTTEMAN GR., GÄRTNER F. Detection of lymph node micrometastases in malignant mammary tumours in dogs by cytokeratin immunostaining. *Vet Rec.*, 2006, 158, 626-630.
80. MENDES TC., GUIM TN., DIAS MCF., BONEL-RAPOSO J., FERNANDES CG. Comparação entre os sistemas histomorfológico e de gradação histológica para classificação prognóstica de tumores mamários em cadelas. *Acta Scient. Vet.*, 2007, 35, 339-345.
81. MISDORP W. Tumors of the mammary gland. DJ M. (Ed.). *Tumors in Domestic Animals*. State: University of California, 2002, 575-606.
82. MISDORP W., ELSE RW., HELLMÉN E., LIPSCOMB E. Definitions and explanatory notes. *Who Histological Classification of Mammary Tumors of the Dog and Cat*. Washington: Armed Forces Institute of Pathology, 1999, 18-27.
83. MISDORP W., COTCHIN E., HAMPE JF., JABARA AG., VON SANDERSLEBEN J. Canine malignant mammary tumors III. Special types of carcinomas, malignant mixed tumors. *Vet. Pathol.*, 1973, 10, 241-256.
84. MORRISON WB. Canine and feline mammary tumors. MORRISON WB. (Ed.). *Cancer in dogs and cats; medical and surgical menegement*. Philadelphia: Linppincott Willians & Wilkins, 1998, 591-598.

85. MOUSER P., MILLER MA., ANTUOFERMO E., BADVE SS., MOHAMMED SI. Prevalence and classification of spontaneous mammary intraepithelial lesions in dogs without clinical mammary disease. *Vet. Pathol.*, 2010, 47, 265-274.
86. MURAKAMI A., KAWACHI K., SASAKI T., ISHIKAWA T., NAGASHIMA YOJI., NOZAWA A. Sebaceous carcinoma of the breast. *Pathol. Int.*, 2009, 59(3), 188–192.
87. NIETO A, PÉREZ-ALENZA MD, DEL CASTILLO N, TABANERA E, CASTAÑO M, PEÑA L. BRCA-1 expression in canine mammary dysplasias and tumours: relationship with prognostic variables. *J. Comp. Pathol.*, 2003, 128, 260-268.
88. OGILVE GK., MOORE AS. Mammary neoplasia. OGILVIE GK., MOORE AS. (Ed.). *Managing the veterinary cancer patient; a practice manual*. New Jersey: Veterinary learning systems co., 1996, 431-433.
89. OWEN LN. *The TNM Classification of tumors in domestic animals*. 1 ed. Geneva: World Health Organization, 1980.
90. PAL SK., LAU SK., KRUPER L., NWOYE U., GARBEROGLIO C., GUPTA RK., PAZ B., VORA L., GUZMAN E., ARTINYAN A., SOMLO G. Papillary carcinoma of the breast: an overview. *Breast Cancer Res. Treat.*, 2010, 122, 637-645.
91. PATSIKAS MN., DESSIRIS A. The lymph drainage of the neoplastic mammary glands in the bitch: a lymphographic study. *Anat. Hist. Embry.*, 2006, 35, 228-234.
92. PEÑA L., PÉREZ- ALENZA MD., RODRIGUES-BERTOS A., NIETO A. Canine inflammatory mammary carcinoma: histopathology, immunohistochemistry and clinical implications of 21 cases. *Breast Canc. Res. Treat.*, 2003, 78, 141-148.
93. PENG L., SUN Q., LIANG Z., ZHOU Y., MAO F., GUAN J. Pure Mucinous Carcinoma of the Breast: a Clinicopathologic Analysis with 56 Patients. *Chinese Med. Sci. J.*, 2010, 25(2), 115-118.
94. PEREZ-ALENZA MD., TABANERA E., PEÑA L. Inflammatory mammary carcinoma in dogs: 33 cases (1995–1999). *J. Am. Vet. Med. Assoc.*, 2001, 219(8), 1110–1114.
95. PÉREZ-MARTINEZ C., GARCIA-IGLESIAS MJ., DURÁN NAVARRETE AJ., ESPINOSA-ALVAREZ J., GARCÍA FERNÁNDEZ RA., LORENZANA-ROBLES N., FERNÁNDEZ-PÉREZ S., GARCÍA-MARÍN JF. Histopathological and immunohistochemical characteristics of two canine lipid-rich mammary carcinomas. *J. Vet. Med. A. Physiol. Pathol. Clin. Med.*, 2005, 52, 61–66.
96. PEROU CM., SORLIE T., EISEN MB., VAN DE RIJN M., JEFFREY SS., REES CA., POLLACK JR., ROSS DT., JOHNSEN H., AKSLEN LA., FLUGE O., PERGAMENSCHIKOV A., WILLIAMS C., ZHU SX., LONNING PE., BORRESEN-DALE AL., BROWN PO., BOTSTEIN D. Molecular portraits of human breast tumours. *Nature*, 2000, 406, 747-752.
97. PHILIBERT JC., SNYDER PW., GLICKMAN N., GLICKMAN LT., KNAPP DW., WATERS DJ. Influence of host factors on survival in dogs with malignant mammary gland tumors. *J. Vet. Intern. Med.*, 2003, 17, 102-106.
98. QUEIROGA F., LOPES C. Tumores mamários caninos, pesquisa de novos fatores prognósticos. *RPCV.*, 2002, 97, 119-127.
99. REIS-FILHO JS., LAKHANI SR. The diagnosis and management of pre-invasive breast disease: genetic alterations in pre-invasive lesions. *Breast Cancer Res.*, 2003, 5, 313-319.
100. RESSEL L., MILLANTA F., POLI A. Canine invasive lobular carcinoma of mammary gland: morphological and immunohistochemical characterization of three cases. *J Comp Pathol*. 2010, 1-5 (In press).
101. RIBEIRO GM. Carcinoma em tumor misto da mama da cadela: avaliação de aspectos morfológicos e perfil imunofenotípico. (2010). 73f. (Mestrado) – Patologia, Universidade Federal de Minas Gerais, Belo Horizonte, 2010.
102. RIBEIRO LGR., DAMASCENO KA., COSTA NETO JM., D’ASSIS MJM., SILVA NS., AGUIAR PHP., CASSALI GD., ESTRELA-LIMA A. Expressão da COX-2 nos carcinomas mamários de cadelas. *Vet. Foco*, 2009, 6, 134-139.
103. ROSEN PP. *Rosen's Breast Pathology*. 3ed. Lippincott Williams & Wilkins, 2009, 1116 p.
104. ROSEN PP. *Rosen's breast pathology*. 3 ed. NY: Lippincott, Williams & Wilkins Publishers, 2003.
105. ROSEN PP. *Rosen's Breast Pathology*. Philadelphia: Lippincott –Raven, 1997, 489-491.
106. ROSEN PP., OBERMAN HA. Tumors of the mammary gland. *Atlas of Tumor Pathology*, Third series, fascicle 7. Armed Forces Institute of Pathology, Washington DC. 1993.
107. SEIXAS F., PALMEIRA C., PIRES MA., LOPES C. Mammary invasive micropapillary carcinoma in cats: clinicopathologic features and nuclear DNA content. *Vet. Pathol.*, 2007, 44, 842–848.
108. SILVA AE., SERAKIDES R., CASSALI GD. Carcinogênese hormonal e neoplasias hormônio-dependentes. *Ciênc. Rural*, 2004, 34, 625-633.
109. SINGLETARY SE., PATEL-PAREKH L., BLAND KI. Treatment trends in early-stage invasive lobular carcinoma: a report from the National Cancer Data Base. *Ann Surg.*, 2005, 242(2), 281–289.
110. SOBIN L., WITTEKIND C. TNM classification of

- malignant tumours. 5. ed. New York: Wiley-Liss, 1997.
111. SORENMO K. Canine mammary gland tumors. *Vet. Clin. North Am. Small Anim. Pract.*, 2003, 33, 573-596.
 112. SORLIE T., TIBSHIRANI R., PARKER J., HASTIE T., MARRON JS., NOBEL A., DENG S., JOHNSEN H., PESICH R., GEISLER S., DEMETER J., PEROU CM., LONNING PE., BROWN PO., DALE ALB., BOTSTEIN D. Repeated observation of breast tumor subtypes in independent gene expression data sets. *Proc. Natl. Acad. Sci. Unit. States Am.*, 2003, 100, 8418-8423.
 113. SOUZA CHM., TOLEDO-PIZA E., AMORIN R., BARBOZA A., TOBIAS KM. Inflammatory mammary carcinoma in 12 dogs: Clinical features, cyclooxygenase-2 expression, and response to piroxicam treatment. *Can Vet J.*, 2009, 50, 506-510.
 114. STERNLICHT MD., KEDESHIAN P., SHAO ZM., SAFARIANS S., BARSKY SH. The human myoepithelial cell is a natural tumor suppressor. *Clin. Cancer Res.*, 1997, 3, 1949-1958.
 115. STRATMANN N., FAILING K., RICHTER A., WEHREND A. Mammary tumor recurrence in bitches after regional mastectomy. *Vet. Surg.*, 2008, 37(1), 82-86.
 116. SUSANECK SJ., ALLEN TA., HOOPEES J., WITHROW SJ., MACY DW. Inflammatory mammary carcinoma in the dog. *J. Am. An. Hosp. Assoc.*, 1983, 19, 971-976.
 117. SUZUKI F., SAITO A., ISHI K., OKAZAKI T., KINA K., KOYATSU J., SUGIYAMA K. Secretory carcinoma of the breast: an immunohistochemical and ultrastructural study. *Med. Electron. Microsc.*, 1999, 32, 50-56.
 118. TAVARES WLF., FIGUEIREDO MS., SOUZA AG., BERTAGNOLLI AC., LAVALLE GE., CAVALCANTI G., CASSALI GD. Evaluation of dose and side effects of tamoxifen in female dogs. *V ONCOVET*, 2009, São Paulo. *Vet. Comp. Oncol.*, 2009, 7, 93-94.
 119. TAVASSOLI FA., DEVILEE P. Tumours of the breast. *Pathology and Genetics of Tumours of the Breast and Female Genital Organs*. 1 ed. Lyon: IARC Press. 2003.
 120. TERZIAN ACB., ZUCCARI DAPC., PEREIRA RS., PAVAM MV, COELHO J. Avaliação da Caspase 3 e ki 67 como Marcadores Prognósticos nas Neoplasias Mamárias em Cadelas. *Braz. J. Vet. Res. Anim. Sci.*, 2007, 44, 96-102.
 121. TOKUDOME N., SAKAMOTO G., SAKAI T., SARUMARU S., OKUYAMA N., HORI F., HORII R., AKIYAMA F., TANABE M., SAITO K., TAKAHASHI K., KASUMI F. A Case of Carcinosarcoma of the Breast. *Breast Cancer*, 2005, 12, 149-153.
 122. UENG S., MEZZETTI T., TAVASSOLI FA. Papillary neoplasms of the breast: a review. *Arch. Pathol. Lab. Med.*, 2009, 133, 893-907.
 123. VELDHOEN N., WATTERSON J., BRASH M., MILNER J. Identification of tumour-associated and germ line p53 mutations in canine mammary cancer. *Brit. J. Cancer*, 1999, 81, 409-415.
 124. WAHED A., CONNELLY J., REESE T. E-cadherin expression in pleomorphic lobular carcinoma: an aid to differentiation from ductal carcinoma. *Ann. Diagn. Pathol.*, 2002, 6, 349-351.
 125. WERNER PR., WERNER J. Avaliação histopatológica. DALECK CR., *et al* (Ed.). *Oncologia em cães e gatos*. São Paulo: Roca, 2009, 121-34.
 126. WOLFF AC., HAMMOND MEH., SCHWARTZ JN., HAGERTY KL., ALLRED DC., COTE RJ., DOWSETT M., FITZGIBBONS PL., HANNA WM., LANGER A., MCSHANE LM., PAIK S., PEGRAM MD., PEREZ EA., PRESS MF., RHODES A., STURGEON CATHARINE., TAUBE SE., TUBBS R., VANCE GH., VIJVER MV., WHEELER TM., HAYES DF. American Society of Clinical Oncology/College of American Pathologists guideline recommendations for human epidermal growth factor receptor 2 testing in breast cancer. *J Clin Oncol.*, 2007, 25, 118-145.
 127. YAZIJI H., GOWN AM., SNEIGE N. Detection of stromal invasion in breast cancer: the myoepithelial markers. *Adv. Anat. Pathol.*, 2000, 7, 100-109.
 128. ZUCCARI DAPC., PAVAM MV., TERZIAN ACB., PEREIRA RS., RUIZ CM., ANDRADE JCA. Immunohistochemical Evaluation of e-cadherin, Ki-67 and PCNA in Canine Mammary Neoplasias: Correlation of Prognostic Factors and Clinical Outcome. *Pesq. Vet. Bras.*, 2008, 28, 207-215.
 129. ZUCCARI DAPC., SANTANA AE., CURY PM., CORDEIRO JA., ZANCHETTA NETTO D. Immunocytochemical study of Ki-67 as a prognostic marker in canine mammary neoplasia. *Vet. Clin. Pathol.*, 2004, 33, 23-28.
 130. ZUCCARI DAPC., SANTANA AE., ROCHA NS. Correlação entre a citologia aspirativa por agulha fina e a histologia no diagnóstico de tumores mamários de cadelas. *Braz. J. Vet. Res. Anim. Sci.*, 2001, 38, 38-41.