

Consensus Paper: Language and the Cerebellum: an Ongoing Enigma

Peter Mariën · Herman Ackermann · Michael Adamaszek · Caroline H. S. Barwood · Alan Beaton · John Desmond · Elke De Witte · Angela J. Fawcett · Ingo Hertrich · Michael Küper · Maria Leggio · Cherie Marvel · Marco Molinari · Bruce E. Murdoch · Roderick I. Nicolson · Jeremy D. Schmahmann · Catherine J. Stoodley · Markus Thürling · Dagmar Timmann · Ellen Wouters · Wolfram Ziegler

Published online: 7 December 2013

© Springer Science+Business Media New York 2013

Abstract In less than three decades, the concept “cerebellar neurocognition” has evolved from a mere afterthought to an entirely new and multifaceted area of neuroscientific research. A close interplay between three main strands of contemporary

neuroscience induced a substantial modification of the traditional view of the cerebellum as a mere coordinator of autonomic and somatic motor functions. Indeed, the wealth of current evidence derived from detailed neuroanatomical

P. Mariën · E. De Witte · E. Wouters
Department of Clinical and Experimental Neurolinguistics, CLIN,
Vrije Universiteit Brussel, Brussels, Belgium

M. Küper · M. Thürling · D. Timmann
Department of Neurology, University of Duisburg-Essen, Essen,
Germany

P. Mariën (✉) · E. Wouters
Department of Neurology, ZNA Middelheim General Hospital,
Lindendreef 1, 2020 Antwerp, Belgium
e-mail: peter.marien5@telenet.be

M. Leggio
Department of Psychology, Sapienza University of Rome, Rome,
Italy

P. Mariën
Vlaams Academisch Centrum (VLAC), Advanced Studies Institute
of the Royal Flemish Academy of Belgium for Sciences and the Arts,
Brussels, Belgium

M. Leggio · M. Molinari
I.R.C.C.S. Santa Lucia Foundation, Rome, Italy

H. Ackermann · I. Hertrich
Department of General Neurology, Center of Neurology,
Hertie-Institute for Clinical Brain Research, University of Tübingen,
Tübingen, Germany

R. I. Nicolson
Department of Psychology, The University of Sheffield, Sheffield,
UK

M. Adamaszek
Center of Neurologic Rehabilitation, Cognitive Neurophysiology,
University of Leipzig, Bennewitz, Germany

J. D. Schmahmann
Ataxia Unit, Cognitive and Behavioral Neurology Unit, Laboratory
for Neuroanatomy and Cerebellar Neurobiology, Department of
Neurology, Massachusetts General Hospital and Harvard Medical
School, Boston, USA

C. H. S. Barwood · B. E. Murdoch
Centre for Neurogenic Communication Disorders Research, School
of Health and Rehabilitation Sciences, The University of
Queensland, Brisbane, Australia

C. J. Stoodley
Department of Psychology, American University Washington,
Washington, USA

A. Beaton
Department of Psychology, Swansea University and Department of
Psychology, Aberystwyth, Wales, UK

W. Ziegler
Clinical Neuropsychology Research Group, Clinic for
Neuropsychology, City Hospital, Bogenhausen, Munich, Germany

J. Desmond · C. Marvel
Department of Neurology, Johns Hopkins University, Baltimore,
MD, USA

A. J. Fawcett
Centre for Child Research, University of Swansea,
Swansea, Wales, UK

W. Ziegler
Institute of Phonetics and Speech Processing, Ludwig-Maximilian
University, Munich, Germany

investigations, functional neuroimaging studies with healthy subjects and patients and in-depth neuropsychological assessment of patients with cerebellar disorders shows that the cerebellum has a cardinal role to play in affective regulation, cognitive processing, and linguistic function. Although considerable progress has been made in models of cerebellar function, controversy remains regarding the exact role of the “linguistic cerebellum” in a broad variety of nonmotor language processes. This consensus paper brings together a range of different viewpoints and opinions regarding the contribution of the cerebellum to language function. Recent developments and insights in the nonmotor modulatory role of the cerebellum in language and some related disorders will be discussed. The role of the cerebellum in speech and language perception, in motor speech planning including apraxia of speech, in verbal working memory, in phonological and semantic verbal fluency, in syntax processing, in the dynamics of language production, in reading and in writing will be addressed. In addition, the functional topography of the linguistic cerebellum and the contribution of the deep nuclei to linguistic function will be briefly discussed. As such, a framework for debate and discussion will be offered in this consensus paper.

Keywords Cerebellum · Language · Speech · Speech perception · Apraxia of speech · Working memory · Verbal fluency · Syntax · Phonology · Semantics · Aphasia · Imaging · Agraphia · Dyslexia · Functional topography · Imaging · fMRI · SPECT

Introduction

Two centuries of research on cerebellar function have been dominated by the role of the cerebellum in motor control (see Manto et al. [1] for a review). Although from time to time clinical case descriptions and experimental evidence from animal studies dating back to the early part of the nineteenth century suggested an association between cerebellar pathology and a variety of nonmotor cognitive as well as affective dysfunctions (see [2, 3]), a causal connection was dismissed for decades. In the mid-1900s, investigators started to examine a possible link between the cerebellum and cognition and emotion, exemplified by the work of Snider (e.g., [4–6]), Dow [7], Heath [8–10], Cooper [11], and others (see Schmahmann [2] for a review). This laid a foundation for the rediscovery of this concept by Leiner and colleagues (e.g., [12, 13]) who hypothesized that more recently evolved parts of the cerebellum contribute to learning, cognition, and language, and by Schmahmann ([2, 14, 15]) who introduced the dysmetria of thought hypothesis providing an historical, clinical, neuroanatomical and theoretical framework within which a cerebellar role in higher cognitive and affective

processes could be considered. That there may be a correlation between size of the cerebellum and aspects of general intelligence has been known for some time (e.g., [16–19]). From an evolutionary perspective, MacLeod et al. [20] demonstrated a reliable linear regression contrast between volumes of whole brain, cerebellum, vermis, and hemisphere of hominoids and monkeys and a striking increase in the lateral cerebellum in hominoids. Pangelinan et al. [21] showed with school-aged children that (after controlling statistically for age and sex), total cerebellar volume correlates significantly with cognitive ability (as measured by overall IQ) (but see Parker et al. [22] for negative findings). Posthuma et al. [23] reported that cerebellar volume in healthy adults (as well as total cerebral grey and white matter volumes) correlates with working memory performance. Such findings make it difficult to deny that the cerebellum is “an organ of cognition” [24].

Only a few years after the introduction of the dysmetria of thought theory, Schmahmann and Sherman [25] described in a seminal study of patients with focal cerebellar lesions a consistent pattern of cognitive and affective deficits and coined the term “cerebellar cognitive affective syndrome” (CCAS) to describe this condition. In addition to clusters of executive, visuospatial and affective symptoms, a variety of linguistic disturbances such as agrammatism, anomia, and dysprosodia were included in CCAS. Since then cerebellar involvement in linguistic processes has been studied by advanced neuroimaging methods in healthy subjects and a number of studies have been published focusing on a variety of linguistic dysfunctions following cerebellar lesions of different etiologies in children as well as adults. Reviews of the role of the cerebellum in nonmotor language functions are provided by Gordon [26], Mariën et al. [27], Paquier and Mariën [28], De Smet et al. [29, 30], Beaton and Mariën [31], Murdoch [32], and Highnam and Bleile [33].

The neuroanatomical substrate of the recently acknowledged nonmotor role of the cerebellum in cognitive and affective processing is a dense and reciprocal network of crossed cerebro-cerebellar pathways consisting of cortico-ponto-cerebellar and cerebello-thalamo-cortical loops that establish a close connection between the cerebellum and the supratentorial motor, paralimbic and association cortices subserving cognitive and affective processes. A plethora of contemporary lesion-behavior and neuroimaging studies have demonstrated that in addition to its somatotopic organization for motor control, the human cerebellum is topographically organized for higher-order cognitive and affective functions as well. A meta-analysis of neuroimaging studies investigating cerebellar involvement in motor, cognitive and affective processing paradigms has provided support for a dichotomy between the sensorimotor cerebellum—geographically organized in distinct regions in the anterior lobe—and the neurocognitive and affective cerebellum—represented in distinct parts in the posterior lobe (for a review, see Stoodley and

Schmahmann [34]). In addition, the majority of anatomoclinical studies of patients with linguistic impairments following focal cerebellar lesions and the majority of neuroimaging studies employing nonmotor language tasks typically show a lateralized involvement of lateral, posterior cerebellar regions (including lobules VI and Crus I/II) in nonmotor linguistic processes. Indeed, the patterns of lateralized (or even bilateral) cerebral representation of language in dextrals and sinistrals seem to be reflected at the cerebellar level by a “lateralized linguistic cerebellum”, subserved by crossed cerebello-cerebral connections between the cortical language network and the cerebellum.

The primary aim of this consensus paper is to collect and summarize the key concepts which have been proposed to explain the role of the cerebellar circuits in linguistic processing. To this aim, we have gathered contributions from experts in various areas of cerebellar language processing, providing a range of different, sometimes even controversial, viewpoints. Although final agreement has not yet been reached, we believe that a new consensus that draws on and integrates the ideas presented here will eventually emerge to unravel the enigmatic role of the cerebellum in nonmotor linguistic processing.

Role of the Cerebellum in Speech/Language Perception (I. Hertrich, H. Ackermann)

While a specific engagement of the cerebellum in motor speech control is well established for decades, a variety of more recent studies point, in addition, to a contribution of this hindbrain structure to central-auditory functions, speech perception and higher-order linguistic processes such as speech timing, phonological aspects of lexical access, and top-down mechanisms giving rise to expectations of upcoming verbal events. In line with these behavioral findings, the cortico-cerebellar loops not only target primary-motor and premotor regions, including the mesiofrontal supplementary motor area (SMA), but also the primary-sensory and supramodal association cortex. Although cerebellar functions do by far not represent a mandatory prerequisite for all aspects of speech perception and language tasks, increasing cognitive demands with respect to speed, acuity, memory load, and morphosyntactic processing—appear to entrain the cerebellum.

Among other things, temporal parameters of the acoustic speech signal contribute to the encoding of phonological information of verbal utterances. Considering the participation of the cerebellum in high-precision clock mechanisms [35, 36] and, furthermore, its functional linkage to extracerebellar structures via oscillatory mechanisms that could subservise the gating of sensorimotor and cognitive signals [37], a direct involvement of the cerebellum in the “handling” of phonetic

timing information must be expected [38]. Indeed, the processing of certain phonological distinctions was found to be impaired in subjects with cerebellar disorders if the relevant acoustic speech features were restricted to temporal/durational aspects such as the duration of stop occlusions, providing a secondary cue for stop consonant voicing [39, 40]. In line with these psychoacoustic data, functional magnetic resonance imaging revealed hemodynamic activation of distinct cerebellar structures in healthy subjects during application of the same test materials [41, 42]. Thus, the cerebellum seems to be directly engaged in the processing of—at least some—phonetic features. It must be noted, however, that other—aspects of speech timing such as the categorical perception of voice onset time and vowel duration appear more or less preserved in cerebellar patients, especially, when the respective portions of the acoustic speech signals encompass spectral energy and do not represent silent intervals [39, 43, 44]. Similarly, cerebellar disorders were found to compromise motor tasks only in case of discontinuous movements characterized by an explicitly specified temporal goal, rhythmic continuous activities being spared [45].

In addition to phonetic and phonological aspects of verbal communication, the cerebellum appears also to contribute to speech perception at the preceding stage of acoustic processing [46, 47] although textbook displays of the central-auditory pathways do not encompass the cerebellum (e.g., [48]). First, despite uncompromised auditory hearing thresholds, significantly impaired pitch discrimination capabilities could be documented in cerebellar patients—in parallel to the degree of cerebellar ataxia [49]. Second, the cerebellum has been found to subservise perceptual switching mechanisms and the segmentation of temporal sequences involved in auditory streaming [50]. As concerns speech perception, a clinical study addressing selective attention capabilities by means of a sentence identification test revealed impaired performance of cerebellar patients whenever a distractor signal was applied to the same ear as the target sentences, but not in case of contralateral stimulation [47]. Furthermore, impaired temporal resolution of central-auditory processing in cerebellar dysfunctions has been assumed to subsequently disrupt the emergence of phonological awareness and, thus, to contribute to the pathomechanisms of developmental dyslexia [51].

Presumably, some temporal aspects of cross- and supramodal processing depend upon the cerebellum as well. A recent functional-imaging study was able to document functional interactions between posterior aspects of the superior temporal sulcus and the anterior cerebellum concomitant with impaired cross-modal binding mechanisms during an audiovisual perceptual training experiment [52]. Furthermore, a recent model accounting for spectrotemporal predictive processes within the auditory domain postulates a division of labor between the cerebellum and the basal ganglia with respect to the tracking of acoustic events in time. While, more

specifically, the basal ganglia appear to engage in attentional processes, the cerebellum rather supports the representation of the temporal structure of a stimulus [53]. In summary, the cerebellum contributes to several domains of speech/language perception, including (1) distinct phonetic timing operations, (2) auditory signal segregation, and (3) cross-modal binding mechanisms. As a most plausible common denominator, temporal aspects of signal processing across these domains appear to depend upon the cerebellum.

Cerebellar Involvement in Speech Motor Planning and Apraxia of Speech (AOS) (W. Ziegler)

Generally, the term “motor planning” refers to processes specifying relevant movement parameters in advance of a motor action to be executed. *Inverse internal models* are considered to represent the planning information that is required to translate movement goals into appropriate motor commands [54]. During the feedforward execution of pre-planned movement trajectories, a parallel closed-loop feedback-control system relying on sensory information adapts the movement path to environmental conditions and corrects for aberrations of the actual from the predicted movement path [54]. The cerebellum is considered to be implicated in the acquisition and the implementation of inverse models, but also in the processing of sensory feedback during motor execution [1].

Contemporary models of *speech* production are based on a similar framework. The DIVA model, for instance, postulates a feedforward control subsystem in which *speech sound maps* supply the motor plans for speaking, i.e., the kinematic information that is required for the execution of speech movements. Parallel to the unfolding of this information, a feedback control subsystem corrects for perceived deviations of the pre-planned movements from their predicted goals [55, 56]. The WEAVER++ model makes specific claims concerning the content of speech motor plans, assuming that articulation patterns are planned on a syllabic level, at least for the frequently occurring syllables of a language [57, 58].

Speech motor plans are assumed to incorporate a speaker’s implicit “knowledge” of the language-specific regularities of speech motor patterns that is established during speech acquisition [59]. Accordingly, the stability of acquired speech motor plans depends on the frequency of occurrence of the respective motor patterns in a speaker’s language [60].

Functional imaging studies of speech motor control have identified a “minimal brain network” of overt speaking, which includes regions of the anterior mesial cortex, motor, sensory, and pre-motor cortex, basal ganglia, thalamus and cerebellum, BA 44 of the left inferior frontal gyrus, as well as the left anterior insula [61–63]. The paradigms used in these studies involved experimental variation of stimulus length and complexity, both of which are sensitive to planning and execution

aspects of speaking at the same time. Accordingly, the role of the cerebellum in speech motor planning vs. execution remained largely unresolved in these approaches. Other studies implying a variation of sublexical frequencies (syllable or biphone frequency) revealed a specific enhancement of activity in Broca’s area and the left anterior insula for low-frequency speech patterns, suggesting that activation of these structures is crucial for planning aspects sensitive to motor practice [64–66]. Cerebellar activation, to the contrary, was more related to fine motor complexity rather than frequency of occurrence. In a recent meta-analysis of the serial order of speech-related brain activations, cerebellar activation was found to occur more downstream than left anterior peri- and sub-sylvian activation [67], suggesting a hierarchically lower status of cerebellar relative to left premotor and anterior insular activity in speech production (Fig. 1).

The syndrome of *AOS* is considered as a clinical model of impaired speech motor planning [68]. Regarding the neuro-anatomical basis of *AOS* most researchers agree on lesion sites in the anterior peri- or sub-sylvian region of the left cerebral hemisphere, i.e., BA 44 of Broca’s area, left inferior premotor and motor cortex, and left anterior insular cortex [68–73]. Cerebellar lesions are not implicated in the origin of *AOS* but may rather cause *ataxic dysarthria*, i.e., a disorder conventionally ascribed to motor execution impairment [38, 74]. While *AOS* is predominantly characterized by impaired articulation and disfluency, with almost unremarkable respiratory and voice functions, dysarthria after cerebellar lesions is

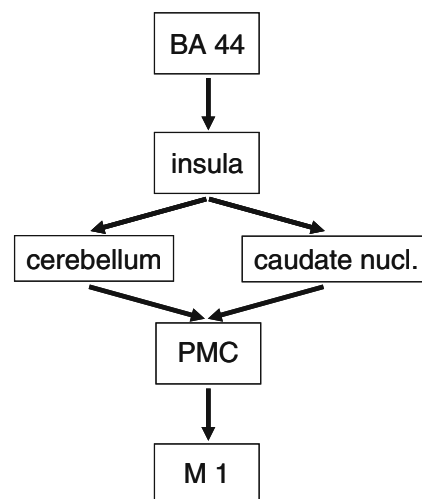


Fig. 1 Effective connectivity of overt speech production (modified after [56]). Dynamic causal modeling of data from a meta-analysis of 18 functional imaging studies of overt speaking (including 261 normal subjects) and from an fMRI study of word generation (including 20 participants). According to this model, the cerebellum is part of a sub-cortical pathway receiving input from Broca’s area (BA 44) via the left anterior insula and projecting onto left primary motor cortex (M1) via the (left) ventral premotor cortex (PMC). This model suggests that cerebellar involvement in speech is located hierarchically lower than the motor planning centers of left anterior cerebral cortex

Table 1 Clinical symptoms of ataxic dysarthria and apraxia of speech

	Ataxic dysarthria [263–265]	Apraxia of speech [68, 266]
Speech breathing	Reduced vital capacity, irregular breathing patterns, and use of expiratory reserve volume	No remarkable respiratory impairment relative to overall severity of speech disorder
Voice	Irregular alterations of voice quality (harsh and strained), irregular pitch/loudness, and voice tremor	No remarkable voice impairment relative to overall severity of speech disorder
Articulation	Hypotonia, irregular muscle activation, irregular over-/undershoot, and irregular hypo-/hypernasality	Inconsistent speech movement aberrations resulting in inconsistent sound distortions and phonemic errors
Rate and rhythm	Slowed speech, irregular duration contrasts between stressed and unstressed syllables, and eventually scanning rhythm	Slowed speech, breakdown of speech rhythm due to groping, false starts, inter-/intrasyllabic, pauses, etc. Eventually scanning rhythm
Self corrections	Rare indications of self-correcting behavior	frequent self correction

almost always associated with respiratory and phonatory impairment (Table 1). The errors made by apraxic speakers are modulated by factors associated with the degree of overlearnedness of speech motor patterns [60]. Some authors have claimed that the two syndromes share some similarities—especially the irregularity of symptoms, slowness, or a scanning rhythm [27, 75, 76], but these overlaps may also reflect universal aspects of motor impairment (e.g., slowing) or unspecific compensatory reactions (e.g., scanning) rather than a common pathomechanism.

Diadochokinetic tasks taxing vocal tract motor functions (i.e., rapid repetition of /pa/, /ta/, or /ka/) have proven particularly sensitive to cerebellar involvement. Unlike AOS patients, patients with cerebellar lesions are excessively slow on this task as compared with speaking (Fig. 2), suggesting that the cerebellum is particularly involved in adaptive sensorimotor functions of the vocal tract, whereas AOS interferes with the acquired capacity of planning the motor patterns for speaking [77, 78].

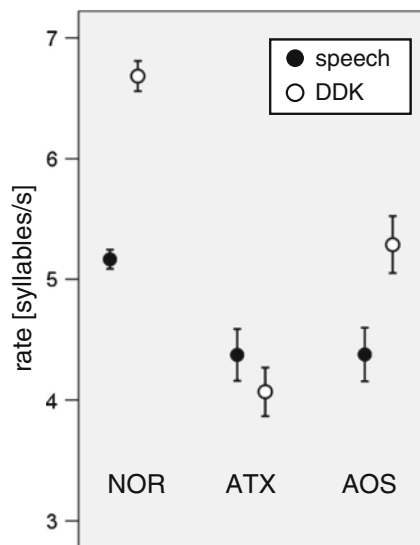


Fig. 2 Average syllabic cycle rates of /pa/, /ta/, and /ka/ (per second) in the context of a sentence production task (filled circles) and a syllable repetition (DDK) task (open circles; adapted from [67]). In sentence production, the target syllables were in the stressed position of an embedded pseudoword. In the DDK condition, subjects were instructed to produce the target syllables as fast as possible. Error bars represent one standard deviation. NOR normal participants ($N=32$), ATX patients with hereditary cerebellar ataxias ($N=15$), AOS patients with apraxia of speech after stroke ($N=15$). The ATX and AOS groups were matched for speaking rates. While normal subjects and AOS patients were able to increase their production rates in the DDK condition, cerebellar patients failed to accelerate their syllable productions. This was ascribed to a failure of cerebellar patients to adapt to the novel and highly specific requirements of the task of repeating a syllable at maximum rate

The Cerebellum and Verbal Working Memory (VWM) (C. Marvel and J. Desmond)

Cerebellar involvement in cognition has been studied perhaps most rigorously in VWM. VWM involves one's ability to temporarily store information that is verbalizable, such as letters, words, numbers, or nameable objects. An influential framework provided by Baddeley states that VWM includes a phonological loop in which speech-based information is stored and rehearsed [79] (Fig. 3a). Baddeley proposed that the phonological loop contains two subcomponents: (1) a passive storage process for acoustic or speech-based information that lasts 1–2 s, and (2) an active articulatory control process. The articulatory control process, according to Baddeley, is further divided into two stages, and this process will be the primary focus of this review. In the first stage, visually presented verbal content (e.g., printed words) must be translated into a phonological representation which is then maintained in phonological storage. Aurally presented information, by contrast, has direct access to storage, and no first-stage translation is required. In the second stage, subvocal repetition refreshes this information so that it can be maintained in phonological storage.

This review article addresses the notion that the cerebellum is an integral part of VWM. During VWM, motor versus nonmotor cerebellar contributions differentiate within the two-stage articulatory control process of Baddeley's working

memory model. Specifically, the superior cerebellar, Lobules VI, and Crus I may initiate an internal motor sequence of phonological content during information encoding. Inferior cerebellar, lobules VIIb/VIII below the horizontal fissure, may support phonological storage during the maintenance of verbal information. Evidence will be presented in support of this premise from clinical studies of patients with cerebellar damage and from neuroimaging studies of healthy volunteers. However, questions still remain concerning the precise role of the cerebellum in VWM, and some alternative views will be described.

Cerebellar damage or dysfunction can have a negative impact on VWM. Evidence from studies of patients with cerebellar infarctions [80–86], spino-cerebellar ataxia [83, 87], and cerebellar tumors [83, 84, 88–97] indicate mild to moderate VWM deficits relative to healthy, well-matched controls. In most studies, VWM has been assessed by measuring individual tests within a larger, broader neuropsychological assessment battery. Yet, several investigations have successfully studied the integrity of articulatory control and phonological storage processes within these patient populations.

In the first of these, a case study of an 18-year-old male with a right cerebellar hemisphere lesion [95] reported selective impairment in VWM but better digit span performance when he was allowed to point, rather than verbalize, his responses. After a battery of additional tests designed to assess the integrity of VWM subcomponents, the authors concluded that the patient's deficits originated in the articulatory control process rather than in the phonological storage component of VWM. Subsequent studies [80, 81, 83, 84, 90] have confirmed deficits in verbal, but not spatial, working memory after cerebellar damage, but have yielded a mixture of results concerning whether articulatory control and/or phonological storage are predominately affected.

Although interpretation of the results from these studies is complicated by the heterogeneity of cerebellar damage across patients within and between studies [98], the overall picture indicates that the cerebellum contributes to VWM even though the precise nature of its contribution is unclear. For this reason, investigators have postulated as an alternative to purely motor-related articulatory production, more specialized functions for the cerebellum, such as articulatory planning/trajectory formation [95, 99], articulatory monitoring [80], error correction [100, 101], timing [102], and sequencing [86]. The behavioral manifestations of cerebellar damage on VWM can be complex, and the exact pattern of behavioral symptoms may depend on the region of the cerebellum that is damaged and the cerebro-cerebellar connectivity that is disrupted [34, 102, 103]. Ravizza et al. [84] posited that the cerebellum may be involved in creating a memory trace during the first stage of articulatory control, when verbal content is translated into a phonological representation. This

hypothesis does not reconcile all patterns of VWM impairments described in the clinical studies above. It does, however, point to a role for the cerebellum in creating motor traces (i.e., the first stage of the articulatory control process) which can, in turn, be utilized during rehearsal by other brain regions that have direct involvement in subvocal repetition. In fact, neuroimaging studies in healthy volunteers tend to support this hypothesis, which is described in more detail below.

A number of neuroimaging studies have examined the neural correlates of VWM, and findings of cerebellar activations in these studies are ubiquitous [99, 101, 104–126]. For example, one early neuroimaging study by Paulesu et al. [122] differentiated the neural correlates of articulatory processes (i.e., translation and rehearsal) from phonological storage. Motor areas, such as Broca's area, the supplementary motor area (SMA), and the bilateral superior cerebellum, were co-activated in association with phonological recoding and subvocal rehearsal. By contrast, the left supramarginal gyrus (BA 40) was specifically associated with phonological storage. Although there was no cerebellar activity associated with phonological storage, this study, like most early neuroimaging studies, did not include the inferior cerebellum in its field of view, which has been implicated in storage processes more recently.

Studies have built upon these early findings by applying variations to the task used by Paulesu et al. (generally known as the Sternberg task [127]) to identify brain pathways associated with the different phases of VWM. In one study, Desmond and colleagues compared cerebellar activity during VWM for letters versus a motoric rehearsal condition that did not involve working memory demands [101]. They observed bilateral superior cerebellar activity during the working memory and motoric tasks, but found that right inferior cerebellar activity was unique to the working memory task. This study suggested for the first time that the inferior cerebellum played a role in nonmotor aspects of VWM, such as phonological storage. A follow-up study performed a conjunction analysis between brain activity during VWM and a motoric rehearsal task [104]. Results confirmed that bilateral superior cerebellar activity was common to both test conditions, whereas the right inferior cerebellum was unique to the working memory condition (Fig. 3b). Other brain regions associated with both conditions included Broca's area, the left premotor cortex, pre-SMA, and SMA (all motor regions). Activity in BA 40, however, was specific to working memory, replicating the early findings of Paulesu et al. The time course of these activations was explored further in two studies that measured activity on a second by second basis [99, 107] (Fig. 3b). Motor-related cortical regions co-activated with the bilateral superior cerebellum during the "encoding" phase of the Sternberg task, when information was perceived and recoded into a phonological representation. Right inferior cerebellar activity and left BA 40 reached peak levels of activity during the delay

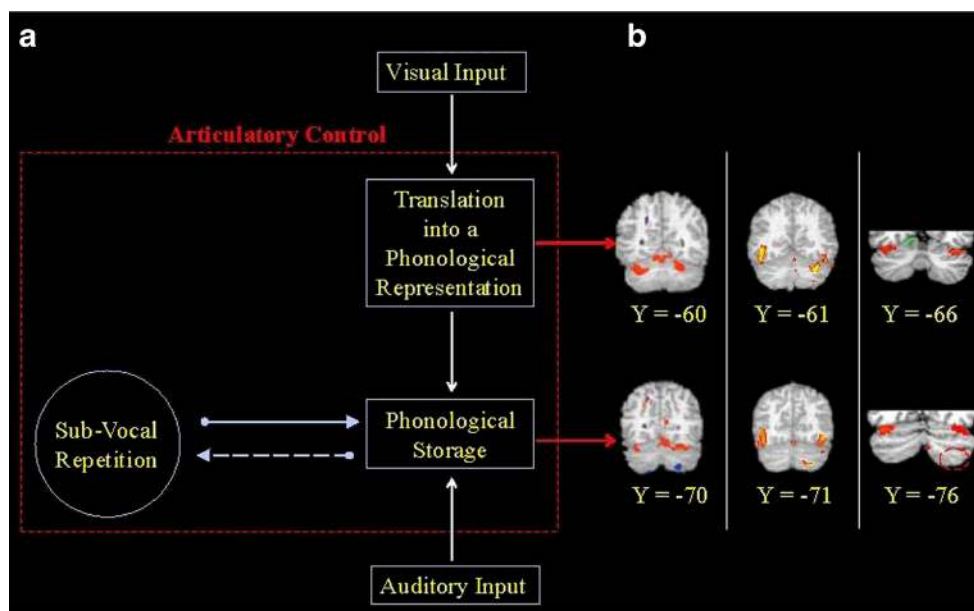


Fig. 3 The cerebellum is selectively involved in the articulatory control process within the phonological loop of verbal working memory. **a** Schematic of the phonological loop according to Baddeley [79]. Visual input is translated into a phonological representation prior to entering storage. Auditory input has direct access into storage, and no translation is required. Subvocal repetition refreshes the phonological storage information so that it can be maintained. **b** Evidence from neuroimaging data shows that the superior (Lobules VI/Crus I) and inferior (Lobules VIIb/VIII cerebellum make separate contributions to articulatory control. Column (1): a conjunction analysis identified regions of activation during working memory and motoric rehearsal (shown in red) vs. working memory but not motoric rehearsal (shown in blue) [104]. The superior cerebellum was involved in both tasks, supporting a motor-related translation function that supports

working memory. The inferior cerebellum (shown in blue) was specifically involved in the working memory task separate from motor demands. Column (2): a temporal analysis of verbal working memory revealed superior cerebellar activity specifically during translation, and inferior cerebellar activity specifically during storage [99]. Column (3): a visual vs. auditory working memory study revealed modality-specific cerebellar regions [105]. Red regions in the superior cerebellum represent greater activity for visual stimuli than auditory stimuli, consistent with the notion that visual information requires translation, whereas auditory information does not. There was an absence of visual vs. auditory activation differences in the inferior cerebellum (area shown in stippled red circle), indicating that both modalities relied equally on this region to maintain information once entered into phonological storage

phase when information was subvocally rehearsed and maintained in the phonological storage. Taken together, these studies suggested that lobes within the cerebellum differentially contributed to VWM. The superior cerebellum is part of a cerebro-cerebellar motor circuit that appears to be involved in creating motor-related articulatory trajectory paths (orthographic to phonological translation) but does not directly support subvocal repetition per se. This would predict greater superior cerebellar activity for visual than auditory stimuli because the latter has direct access to the phonological store. Indeed, this has been found in a direct comparison of visual and auditory modalities during VWM [105] (Fig. 3b). The inferior cerebellum, by contrast, is part of a circuit that supports the maintenance of information within the phonological store [103]. In the future, lobular analyses of cerebellar damage may provide further information regarding localization of working memory function within the cerebellum [87, 90].

This model is dynamic, however. A recent study by Marvel and Desmond [121] demonstrated that the superior cerebellum continues to be active when articulatory trajectories need to be created continuously, such as when manipulating information after it has been encoded. Moreover, superior cerebellar activity tends to increase under particularly high working memory

demands, even as performance declines. This may explain why cerebellar hyperactivity has been observed in patient populations with working memory impairments who need to work especially hard to keep up with task demands [128–130].

In summary, neuroimaging data and some patient studies are consistent with cerebellar involvement in articulatory control processes in VWM. Based on data from studies of patient and healthy populations, the superior cerebellum may contribute to phonological recoding of visually presented information, possibly creating a motor trace of that information. Cerebellar damage can produce abnormalities in phonological storage, and neuroimaging data suggest that the most likely locus of this function is in the inferior cerebellum.

Cerebellum and Verbal Fluency (Phonological and Semantic) (M. Molinari, M. Leggio)

Verbal fluency describes the rate at which one produces words; word generation tasks are standardized language tests that are typically used to assess lexical access. Semantic and phonemic fluency tasks are word generation tasks that measure the ability to generate as many words as possible with a

predetermined word retrieval cue under time constraints. The semantic fluency task requires the production of words in a specific semantic category (e.g., “birds”); the phonemic fluency task requires the production of words that begin with a specific letter (e.g., C “F”). Fluency tasks are particularly valuable, because they assess associative processes—phonological and semantic—and strategic abilities in word searching [131].

In retrieving words from a lexicon under forced conditions, peak performance requires the ability to organize words strategically into burst of words (clusters) that are semantically (successive words that belong to the same subcategory; e.g., birds of prey) or phonemically related (successive words that begin with the same letter in the first and the second positions; e.g., “fa”). When one associative cluster is exhausted, the solution requires one to make quick shifts (cluster switches) to search for and retrieve new clusters [132].

Impairments in verbal fluency tasks are common in patients who have been affected by focal and degenerative cerebellar lesions [25, 92, 133–140]. Despite conflicting results with regard to the laterality and specificity of cerebellar involvement in verbal fluency, clinical and neurophysiological studies have reported that the ability to generate lists of words per the phonemic rule is more affected than under the semantic rule [132, 133, 135, 136, 138, 139], with a specific damage on category switching [138] [132].

The evidence of selective impairment in clustering words phonologically confirms the presence of specific damage of phonemically related retrieval strategies in cerebellar patients [122]—supporting a model of modality-specific cerebellar influence.

Differences between semantic and phonological fluency tasks have been proposed to be attributed to their lexical representation and retrieval cue properties [141, 142]. When any category fluency task is performed, a semantic system that contains knowledge of the physical and functional properties of objects must be activated. Activation of an initial and usually highly prototypical exemplar affects the automatic activation of closely related semantic neighbors [141, 143].

By contrast, letter fluency must be performed at the phonological level of word representation, without reference to meaning, relying on less automatic, unusual means of word searching in the lexicon to form novel category neighbors [140, 143].

The acquisition of a novel word retrieval strategy requires sequencing abilities that allow one to compare previous and ongoing stimuli by maintaining data in a working memory buffer. Thus, to obtain a correct phonemic cluster, a subject must sequentially couple the last word with the new words to keep the prototypical sound active in the working memory system and recognize the last word sound/next word sound phonemic correspondence. When the retrieval and matching strategies are well learned (semantic cue retrieval), sequential

processing is achieved without significant cerebellar activation, whereas when the strategies are novel (phonemic cue retrieval), the activity of the disparate functional modules is not synchronized and significant cerebellar contribution is required to progressively smooth and accelerate the sequence [135].

Under this hypothesis, word output and the number of category switches during the early phase of a phonemic task (first 15 sec) decrease in patients with right unilateral cerebellar lesions [138] and healthy subjects after continuous theta burst stimulation (cTBS) that has been applied over the right posterior/lateral cerebellar cortex [132]. Typically, during the first 15 s of a verbal fluency task, search and retrieval strategies are the most flexible, and most words and cluster switches are generated during this time [144]. Subsequently, the number of correct selections begins to decline, strategic flexibility weakens, and words are produced less frequently [144]. According to Stuss and Alexander [145], words that are generated in the early phase reflect increased facilitation of the neuronal network to optimize the speed at which information is processed.

When the cerebellum is damaged, this facilitation is not obtained, and the network processing becomes slower and less smooth, affecting performance that requires nonautomatic sequence strategies. This phenomenon is consistent with a model of cerebellar function in sequencing incoming sensory patterns and outgoing responses [146–148] and supports the cerebellar “sequence detection” theory [86, 149].

Evidence from sensory [150–152], motor [153], and behavior [154] domains favors sequencing processing as a general operational mode of the cerebellum, according to the view of unitary basic cerebellar function, as the precise and geometric order of its neuronal circuitry suggests [155]. Thus, data on cerebellar function in verbal fluency support the hypothesis that sequencing processing is the basic function of the cerebellum in language [149].

Cerebellar Contributions to Grammar Processing (M. Adamaszek)

Clinical, neurophysiological and neuroimaging studies confirm that the cerebellum contributes to grammar processing, in both the expressive and receptive domain [29, 40, 86, 156–160]. In the 1990s a possible role of the cerebellum in morphological, syntactic and lexical aspects of grammar was for the first time explored. These early studies indicated involvement of the cerebellum in the detection of deviations from predicted grammar rules such as subject-verb agreement or canonical word order [158, 160–162][159, 163–165]. Subsequent investigations substantiated and extended this view to a wider spectrum of cerebellar contribution including motor-independent comprehensive grammar analysis of sentence

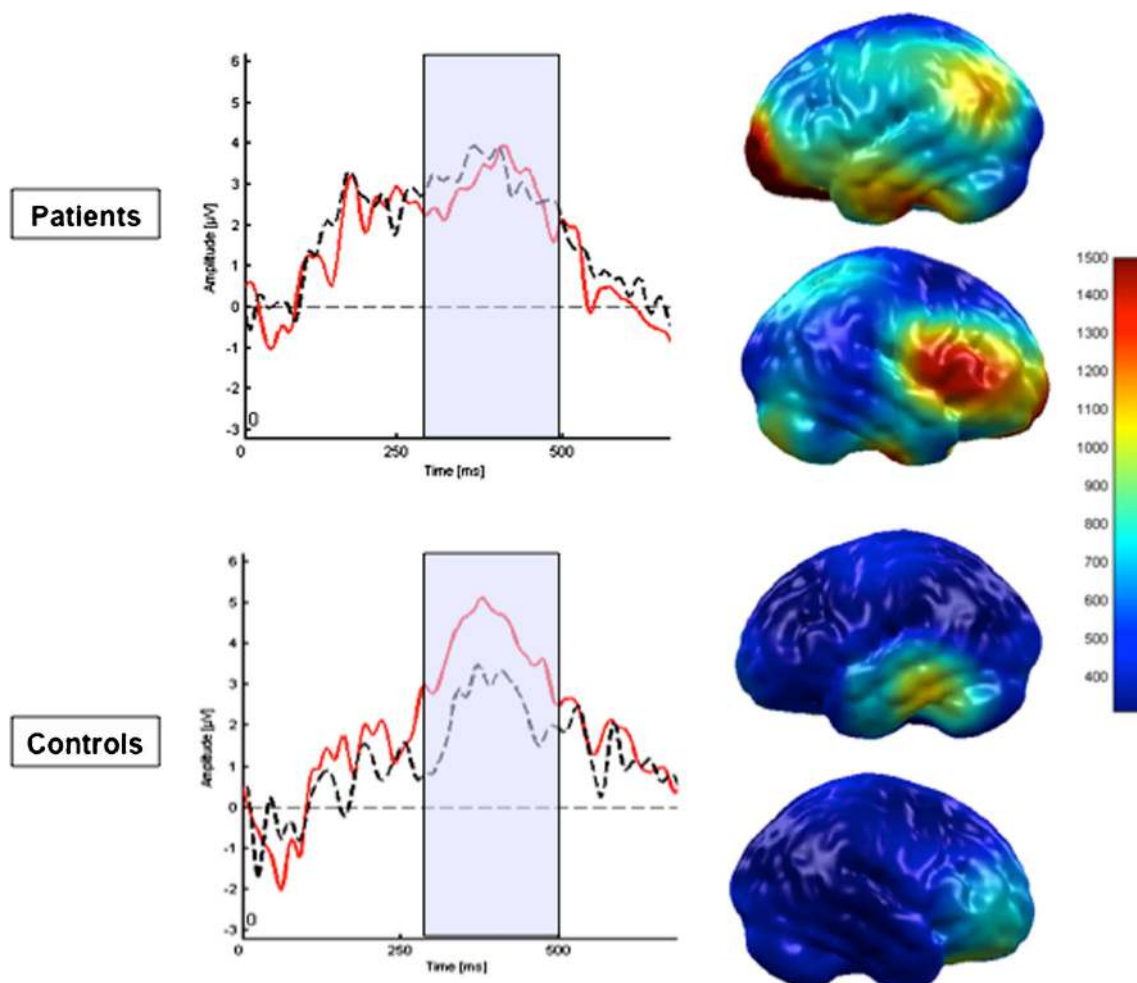


Fig. 4 Event-related potentials (ERP) demarking a sparse syntactic positivity shift (SPS) to morphological syntax violations in patients with ischemic cerebellar lesions in opposite to healthy controls. On the *left*, the grand average of ERP response (*black dotted line* correct syntax; *red line* syntax violation) of the patient as well as

the healthy control group is depicted. As displayed on the right, source analysis found increased activities of homologous Broca and left supramarginal area, suggesting aberrant syntax processing in terms of compensating lack of cerebellar feed forwarding contributions

structure [158]. Recent experimental and neuroimaging data indicates that the cerebellum interfaces with the cerebral areas involved in grammar processing by means of integrating specific cerebral processing signals in a feed-forward manner [34, 159, 162, 166]. Although most studies have shown that the right cerebellar hemisphere is part of the cerebral network subserving grammar processing [86, 157, 160, 162, 167], a few studies indicate that the left or even both cerebellar hemispheres may be involved in grammar processing as well [29, 158, 161]. Overall, recent findings indicate that the right cerebellum is embedded within a distinct grammar processing network, including the language dominant left prefrontal, temporal and parietal cortex and the basal ganglia [159, 163–165].

Based on the presumed involvement of the procedural memory system in grammar processing, the cerebello-cerebral pathways are considered to modify the performance of learnt sequences in grammar operations by searching and

retrieving implicitly learnt grammar rules that are inherent to the sentence structure [165]. In addition, portions of the dentate nucleus, the cerebellar hemispheres and the vermis have been demonstrated to be involved in declarative memory, which in turn interacts with procedural memory in a number of ways, some even in a competitive manner [34, 159, 160, 166]. VWM guides temporal speech information processing such as grammar and lexical analysis of language. There appears to be a critical point of intersection of features of grammar as delivered by the cerebellum [29, 40, 158, 165, 168].

It has been shown that the cerebellum supports the analysis and execution of rule-governed combinations of grammatical items into suitable representations of the operating neural networks [86, 165, 169, 170]. The cerebellar hemispheres in the first place register and assemble details of speech information such as interval lengths or regularity of phrase components governed by event-based temporal processing systems [163, 164, 171]. This information is forwarded via the

dentate nucleus and portions of the thalamus to the left prefrontal and temporal cortex and preSMA in both early and late speech processing stages [34, 162, 172, 173]. Thus, disruption of specific cerebello-cerebral pathways results in impaired temporal coordination and recall of implicit internal representations of the grammatical rules of sentence structure [86, 162, 166]. As demonstrated in Fig. 4, cerebellar involvement in an early and therefore predictive level of grammar analysis is confirmed in a group of patients with cerebellar disorders showing diminished amplitudes of event-related potentials (ERP) to syntax violations around 500 ms and compensatory activities of the left supramarginal gyrus and homologous Broca's area.

Current insights into the role of the cerebellum in grammar processing are still limited. Only a fraction of the grammatical operations in which the cerebellum is implicated have been analysed [40, 158, 164]. For example, details of cerebellar susceptibility to the competitive interaction between declarative and procedural memory in processing grammar sequences are lacking. The same holds for sequelae to the integrative steps of VWM [165]. It would be interesting to know whether the cerebellum only operates in a fairly non-specific way, detecting grammar violations, or whether there are specific features of cerebellar involvement in circumscribed grammar operations such as grammatical judgement or grammatical comprehension [158]. In addition, possible confounding factors such as attentional or executive dysfunction following cerebellar disorder have not been systematically looked for in clinical studies. Future research may consider the suggestions of Habas and of Krienen, based on structured protocols using high spatial resolution neuroimaging to clarify discrete topographic aspects of cerebellar areas, such as Crus II, as a possible region of subserving discrete contributions to the network of grammar processing [40, 161]. ERP studies may substantially add to current insights into the temporal aspects of cerebellar involvement in each processing stage of grammar operations [40, 161]. These studies may not only disentangle the neurophysiological processes subserving cerebellar contributions to grammar processing, they may also disclose cerebral, and perhaps intracerebellar, compensatory mechanisms that accompany cerebellar disorders. If future studies succeed to unravel the neural mechanisms underlying grammar operations, new avenues for the development of specific neurorehabilitative treatment options will be opened.

Cerebellar-Induced Aphasia (B.E. Murdoch, C.H.S. Barwood)

Controversy still surrounds the existence of aphasia in patients with cerebellar disease with some authors [174–177] advocating that cerebellar lesions may induce aphasia while others

report negative findings of language disruption subsequent to cerebellar pathology [137, 178–180]. The case for cerebellar involvement in language processing is based on evidence provided by clinical investigations of individuals with damage to the cerebellum supported by neuroanatomical and functional neuroimaging studies. Patients with vascular lesions within the cerebellum have been reported to present with anomia [25] and reduced phonemic fluency [135, 181]. Two of the most frequently reported language symptoms reported in association with cerebellar lesions are reduced verbal fluency and impaired semantic access [135, 160, 182–184]. Grammatical/syntactic impairment is another commonly reported feature of the language impairment associated with cerebellar pathology [156, 160, 185]. Agrammatic speech has been reported in several case studies of patients with right cerebellar hemisphere lesions. Impairments in reading, writing and mathematical operations have also been observed following a right cerebellar vascular lesion [186]. In addition, patients with cerebellar tumors have been reported to have impairments in syntactical processing [156] and phonemic verbal fluency [187], with phonemic fluency deficits also documented in spinocerebellar ataxia populations [188].

Reciprocal connections linking the cerebellum with centers in the cerebral cortex, including areas crucially involved in high-level linguistic function, provide a neural substrate whereby the cerebellum may be actively and directly involved in the organization, construction and execution of higher order behaviors, including language [13]. Importantly, within each of these circuits, each cerebellar hemisphere sends information to, and receives it primarily from the contralateral cerebral hemisphere. Crossed cerebello-cerebrocortical diaschisis reflecting a functional depression of supratentorial language areas due to reduced input to the cerebral cortex via crossed cerebello-cerebrocortical pathways may represent the neuropathological mechanism responsible for linguistic deficits associated with right cerebellar pathology [27]. In support of this suggestion, functional neuroimaging studies based on positron emission tomography (PET), functional magnetic resonance imaging (fMRI) or single photon emission computed tomography (SPECT) examinations of patients with aphasia-like symptoms have consistently revealed regions of contralateral cortical hypoperfusion in relation to the orientation of the cerebellar lesion [160]. For example, Mariën et al. [174] described a patient with cerebellar-induced aphasia and attributed the specific language symptoms to a focal left frontoparietal hypoperfusion as revealed by SPECT. Similar observations of reduced cerebral blood flow in the anatomoclinically suspected cortical region have been reported in several other studies and case reports [27, 185]. Mariën et al. [27] hypothesized the existence of a “lateralized linguistic cerebellum,” the hypothesis recognizing the increased probability of the posterolateral right cerebellar hemisphere being involved when

patients with aphasia-like symptoms present with cerebellar pathology.

Despite the evidence supporting a role for the cerebellum in language processing, several authors have questioned the existence of aphasia in people with cerebellar pathology [137, 160, 178–180]. The majority of these studies [137, 178–180] examined standard language and visuospatial tests in adults with focal lesions due to stroke and in children and adolescents with lesions due to surgery of benign cerebellar tumors. The results indicated no significant differences between the cerebellar and control groups leading the authors to conclude that aphasia is an uncommon outcome of cerebellar pathology. In that many of the above negative studies involved only adults with chronic cerebellar disease, it was suggested that aphasia may be more prominent in acute cerebellar disease. To investigate this possibility, Frank et al. [180] examined language abilities in 22 adults with acute cerebellar stroke. Their findings confirmed those of their previous research that patients with cerebellar lesions frequently perform within the normal range on tests of general language function. It is possible, however, that such tests lack the necessary sophistication to detect language impairments associated with cerebellar pathology. In support of this suggestion several recent studies have reported depressed language skills on tests of high-level language functions [176, 177]. Cook et al. [176] reported problems in definition tests and recreating sentences tasks, figurative language tests, word association tasks, antonym/synonym generation and interpreting semantic absurdities in five patients with left cerebellar lesions. The findings of Murdoch and Whelan [177] confirmed those of Cook et al. [176] that left cerebellar lesions may disrupt language processing, particularly in the area of complex or high-level language skills, including phonemic fluency, sentence formulation (e.g., key semantic elements required in sentence formation: actually/although/wrong, defined context: department store, patient response: “*Actually wrong sizes appear correct although they are wrong*” (reflects difficulty establishing a contextual plan and manipulating semantic elements at a multi word level of production)) and lexical-semantic manipulation tasks (e.g., target item: window, critical semantic elements: look out/see through/open/ close, patient response: “*Something that lets air in* (reflects an inability to identify or express critical semantic features of target words)).

According to some authors language deficits subsequent to cerebellar pathology do not represent aphasic disorders *per se* but rather are due to the impairment of some cognitive components (e.g., working memory) that are involved in language processing [176]. A contrasting hypothesis was proposed by Mariën et al. [174] who maintained that cerebellar lesions may induce an aphasia syndrome. Mariën et al. [174, 175] reported the case of a 73 year-old right-handed patient who presented with a predominantly expressive aphasic syndrome and agrammatism subsequent to an ischemic infarct in the right

cerebellar hemisphere. Specifically the aphasic disorder resembled a transcortical motor aphasia.

A further controversy surrounding the occurrence of language impairment in cases with cerebellar disease revolves around lateralization of language in the cerebellum. By far the majority of evidence published to date supports a role for the right cerebellar hemisphere in language operating over crossed connections to the language centers of the left cerebral hemisphere [27]. However, a small number of studies [156, 176, 177, 180] have documented language problems in association with lesions involving the left cerebellar hemisphere, implying that language representation in the cerebellum may be bilateral. Hubrich-Ungureanu et al. [189] suggested that lateralization of language in the cerebellum is dependent upon the lateralization of language within the cerebral cortex.

In summary, the existence of aphasia subsequent to damage to the cerebellum remains somewhat controversial and the precise role of the cerebellum in language is unknown. The reason for this controversy may lay, at least in part, with the inability of general language tests to identify the particular range of language deficits exhibited by patients with cerebellar pathology. Recent clinical neuroanatomical and neuroimaging studies have provided evidence to support a role for the cerebellum in modulation of a broad spectrum of linguistic functions such as verbal fluency, word retrieval, syntax, reading, writing and metalinguistic abilities. Further neurolinguistic investigations using high-level linguistic batteries in combination with neuroanatomical and neuroimaging procedures are needed to confirm, or otherwise, the existence of cerebellar induced aphasia. Although the precise mechanism underlying the occurrence of higher-level language deficits in individuals with cerebellar lesions is unknown however, the most plausible explanation posited to date is crossed cerebello-cerebral diaschisis.

Writing and Cerebellum (P. Mariën, E. De Witte)

Writing is a highly complex human skill, that requires the mastery and integration of a range of subskills involving cognitive operations, linguistic processing and sensorimotor functioning. Disruption of (hand)written output (agraphia) may be the result of acquired or developmental neurological damage to the language system itself affecting spelling skills (the central agraphias) or of motor or sensory impairments that primarily compromise the ability to correctly execute the manual production of letters (the peripheral agraphias) [190].

Very little is known about the possible causative role of the cerebellum in *central agraphia*. The pathophysiological mechanisms that subservise the observed neurolinguistic changes in written output related to cerebellar damage need to be elucidated. Indeed, only a handful of cases exist in which a central agraphia was found after focal [27, 156, 159, 174,




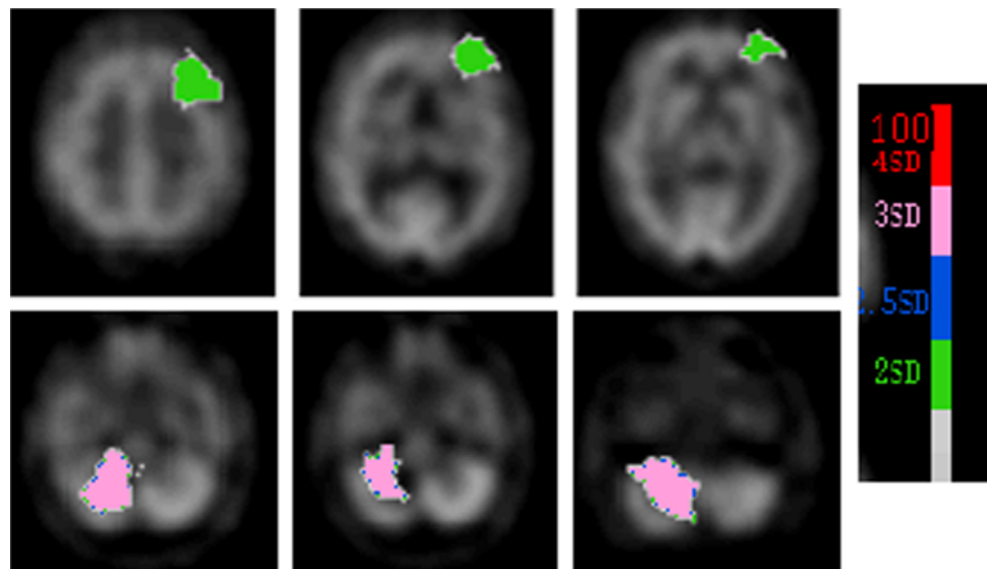
Fig. 5 Handwriting sample of the Dutch target sentence (Het is vandaag een mooie dag.) demonstrating some of the characteristic features of apraxic agraphia

[191] or diffuse cerebellar damage [192]. Whether or not the “cerebellar induced agraphias” are characterized by a uniform error typology needs to be clarified but in all these cases distorted written expression was hypothetically attributed to disruption of integration of cerebellar control in the frontal lobe system.

Classical tenets posit that the neural network subserving *handwriting skills* includes the language dominant superior parietal region, the dorsolateral and medial premotor cortex and the thalamus. Recent clinical and functional neuroimaging studies, however, indicate that the cerebellum may be crucially implicated in this network as well [190, 193–195]. By means of an fMRI study, Katanoda et al. [195] showed involvement of the cerebellum in the general neural network of writing. They concluded that activation of the anterior lobe of the right cerebellum represents the execution of complex finger movements required for writing. A growing number of anatomoclinical studies, however, show that the role of the cerebellum in handwriting extends beyond the pure motor control level. Silveri et al. [196, 197], for instance, described two adult patients with typical features of *spatial agraphia* following vascular ischemic damage of the left cerebellar hemisphere [196] and cerebellar atrophy [197]. This type of peripheral agraphia, which usually follows from impaired proprioceptive and visual control after posterior lesions of the nondominant hemisphere, was also reported by Fournier del Castillo et al. [198]. Frings et al. [199] recorded *megalographia* (abnormally large handwriting) in six children with chronic

surgical cerebellar lesions following posterior fossa tumour resection. *Apraxic agraphia* or *pure agraphia* is another type of peripheral agraphia that follows distortion of the skilled movement plans that direct the production of letters. This condition is characterized by a hesitant, awkward, irregular and imprecise graphomotor trajectory sometimes resulting in illegible scrawls (Fig. 5). Mechanisms held responsible for apraxic agraphia include destruction or disconnection of the stored graphic motor engrams or damage to systems associated with translating the information on graphic motor engrams into graphic innervatory patterns to specific muscles [200]. Recently, clinical evidence was found suggesting involvement of the cerebellum in the neural network of writing. In addition to lesions affecting the dominant parietal lobe (storage of graphic motor engrams), the dorsolateral premotor cortex and the SMA and the thalamus (involved in translating these programs into graphic innervatory patterns), distortion of the spatiotemporal features of handwriting has recently been found following functional disruption of the cerebello-cerebral network subserving the planning and execution of skilled motor actions. Indeed, Mariën et al. [190, 193] and De Smet et al. [194] described four patients with acquired apraxic agraphia following focal cerebellar damage and one patient with developmental apraxic agraphia. Quantified Tc-99m-ECD SPECT studies in these patients showed a consistent pattern of significant perfusion deficits in the structurally unaffected anatomical regions implicated in the distributed neural network subserving the planning and execution of skilled graphomotor actions. In addition to a significant perfusion deficit involving the medial prefrontal region of the left hemisphere, a hypoperfusion was found at the cerebellar level in both the developmental and acquired cases (Fig. 6). These findings are in line with recent anatomoclinical findings indicating that the cerebellum and prefrontal region are crucially involved in the distributed

Fig. 6 Quantified Tc-99m-ethyl cysteinate dimer SPECT showing a significant hypoperfusion in the right cerebellar hemisphere associated with decreased perfusion in the medial and lateral regions of the prefrontal language dominant hemisphere (crossed cerebello-cerebral diaschisis)



network of planning and organization of skilled motor actions. Haggard et al. [201] suggested that in patients with cerebellar lesions deficient motor programming may cause peripheral writing problems. Disruption of the feedforward-feedback mechanisms may cause decomposition of movement due to over-dependence on high-level cortical feedback loops in controlling the movements of the affected hand. Haggard et al. [201] hypothesized that if cerebellar function was intact, the act of writing would be performed more quickly, more smoothly and more accurately due to reliance on an integer predictive model of the limb. Fabbro et al. [156] suggested that cerebellar structures, including the right cerebellar hemisphere and portions of the vermis, may control written language processes by integrating their activity with the “frontal lobe system”. Our findings seem to corroborate these views [190, 193, 194]. A strong interplay between action and perception occurs during writing, and visual perception is firmly bound to attention and to activation of brain regions necessary for action preparation and control [192]. We hypothesize that apraxic writing deficits might result from damage to the cerebellar–encephalic projections, connecting the cerebellum to the prefrontal supratentorial areas which subserve attentional and planning processes.

Summing-up, the functional role of the cerebellum in the written language network has evolved from a mere motor coordinator of graphomotor execution to a central modulatory device crucially implicated in written language processing, including the planning and execution of written output. However, the exact mechanisms underlying the close cerebello-cerebral interplay involved in written language remain to be elucidated.

Reading and the Cerebellum (R.I. Nicolson, A.J. Fawcett)

In this paper we make three points: the cerebellum plays multiple roles in learning to read; impaired cerebellar function may lead to reading difficulties; and cerebellar experts have important roles in literacy research.

Skilled readers read silently, eyes flicking across the page two or three words at a time, averaging around 5 words/s. When reading aloud, they slow down, but maintain excellent prosody, as though talking, eyes two or three words ahead of their voice, the eye-voice span [202]. By contrast, 7-year-old intermediate readers laboriously fixate each word, say it, sometimes stumbling, taking maybe 2 s/word. Their working memory is highly stressed, occupied both in word decoding and meaning construction. Nonetheless, compared with a beginner, the intermediate reader is skilled at identifying the visual forms of letters (graphemes), remembering their names, and their sounds (phonemes), writing them down, fixating them steadily, learning their various combinations in words (orthography), and attacking novel words with a method.

Functional reading networks “migrate” during the acquisition of reading fluency [203–205]. For beginning readers there is an activity increase in the left temporal–parietal cortex (attributed to phonological processing) and then as fluency increases a gradual reduction in activity in the left temporal–parietal cortex and increasing activity in the left ventral occipital–temporal cortex (the “visual word form area” (VWFA)). Most studies have investigated single word reading at a fixed location. Recent studies of listening and of reading comprehension in children and adults [206, 207] identified the “comprehension cortex” around Wernicke’s area, together with areas of right cerebellum. None consider either eye movements or internalisation of speech.

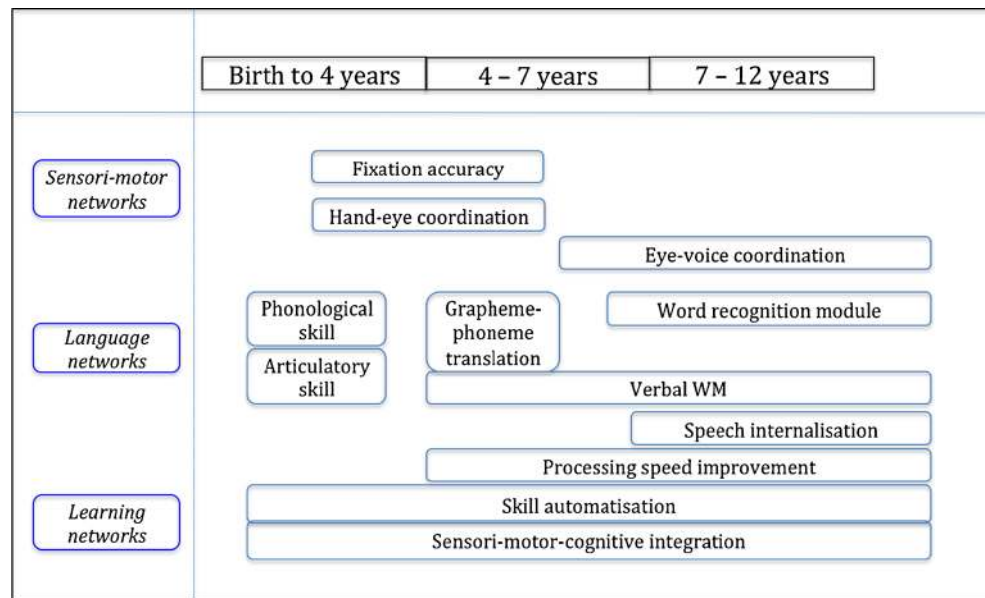
Converging evidence from theoretical, anatomical, neuroimaging and neuropsychological studies has repositioned the cerebellum as “orchestrator” of cognitive as well as motor skills. Underpinning this role are the distinctive two-way connections from the cerebellum to a range of regions of frontal and parietal cortex [166], facilitating three cerebellar roles: timing and coordination; sensorimotor imagery, such as imagined speech; and “as a learning machine that supports the adaptive plasticity needed for the emergence of skilled behavior” ([166], p. 426).

Focusing on neural systems involving the cerebellum and reading, there are two major bidirectional routes between the cerebral cortex and the cerebellum [208, 209]: a motor route between primary motor cortex and cerebellum and a cognitive route between pre-frontal cortex and cerebellum. The latter supports evidence that the cerebellum is centrally involved in cognitive processing related to language (e.g., [158, 210, 211]), VWM [114, 212] and during reading [213, 214]. Ito [210] claims that internal models of language provide the basis for inner speech and thus thought. The role of the basal ganglia and cerebellum in the various stages of motor and cognitive skill automatization is highlighted by several reviews [215, 216].

Figure 7 is our attempt to represent developmental changes in reading, with later skills “scaffolded” by earlier skills, and the roles of these two cerebellar-cortical networks. The cerebellum is depicted as having a significant but different role in each stage of reading development. Our inclusion of the emergence of silent speech and of eye movement control in the later stages highlights a relatively underexplored research topics.

Studies of reading development and dyslexia [202, 217] have established that children with dyslexia retain a relatively broad pattern of activation more typical of younger children rather than achieving migration to the VWFA. Major theories for reading disability (dyslexia) include phonological deficit [218, 219], magnocellular deficit [220] and automaticity/cerebellar deficit [221, 222]. Figure 7 also serves to highlight the diverse ways that impaired cerebellar function could impact on early, middle and later stages of reading development, leading to the possibility of a range of cerebellar “subtypes.”

Fig. 7 Cerebellar involvement in reading skill development. Figure 7 is our attempt to represent developmental changes in reading, with later skills “scaffolded” by earlier skills, and the roles of these two cerebellar-cortical networks



Discussion of these models is beyond our present scope—see [51] for a recent evaluation.

There is increasing diagnosis of developmental disorders, and significant overlap between different developmental disorders [223]. In our view [224], diagnostic confusion reflects an over-reliance on behavioural symptoms, and should be augmented by a neural system analysis, including subcortical and cortical networks.

Reading and its development are of major societal concern. The functional changes that occur in cerebral cortex as children learn to read have been extensively studied, but the processes involved are much less well understood. Skilled reading requires co-operative synergy between cortical and subcortical expertise. We argue that the cerebellum is the orchestrator not only for the coordinated eye-brain-voice concert of skilled reading but also for the learning processes that scaffold its development, from automatization of grapheme-phoneme conversion to the internalization of speech needed for silent reading. The insights of developmental cognitive neuroscience—especially the role of the cerebellum and cerebellar networks in reading—are crucial to the understanding and acceleration of reading development.

Functional Linguistic Topography of the Cerebellum (C.J. Stoodley, J.D. Schmahmann)

Anatomical and physiological studies in animals, neuroimaging experiments in humans, and clinical investigations in patients support the hypothesis [2] that there is topography of motor and cognitive function in the human cerebellum (for review [225]). The anterior lobe

(extending into medial lobule VI) and lobule VIII are involved in sensorimotor control; whereas lobules VI and VII, which are linked with association and paralimbic cortices, are important nodes in the neural circuitry underlying cognition and emotion. This topography is supported by functional connectivity analyses [226, 227] demonstrating the existence of separate cerebro-cerebellar loops for sensorimotor versus cognitive functions. This motor versus nonmotor dichotomy extends to language. Cerebellar motor control of the oral-pharyngeal-vocal apparatus of articulation determines the clarity of speech (or dysarthria, when it is impaired), whereas cerebellar cognitive influence on the semantic, phonemic and syntactic aspects of language manifest in tasks of verbal fluency, verb generation, grammatical construct and semantic judgment.

Spoken word production engages the representation of articulatory muscles in the sensorimotor cerebellum. Neuroimaging studies in humans indicate that articulation activates medial lobule VI bilaterally [228], corresponding to the sensorimotor representation of the face [229], tongue, and lips [230, 231]. These anteromedial cerebellar regions active during articulation are not modulated by the phonemic or syllabic content of utterances [232]. Functional localization of speech is present within the cerebellar nuclei as well, with motoric aspects of speech engaging the rostral and dorsal region of the dentate nucleus [228].

Patients with cerebellar stroke develop dysarthria when the lesion involves rostral paravermal regions including vermal lobule VI [231, 233, 234]. Voxel-based lesion-symptom mapping further demonstrates that slower speech is associated with damage in vermal and paravermal lobules V and VI [137] and midline lobules VIIAf, VIIB and VIIIA. Therefore,

the evidence from cerebellar patients suggests that overt speech is mediated by vermal and paravermal regions of lobules V–VI and VII–VIII, consistent with the cerebellar sensorimotor homunculi [229].

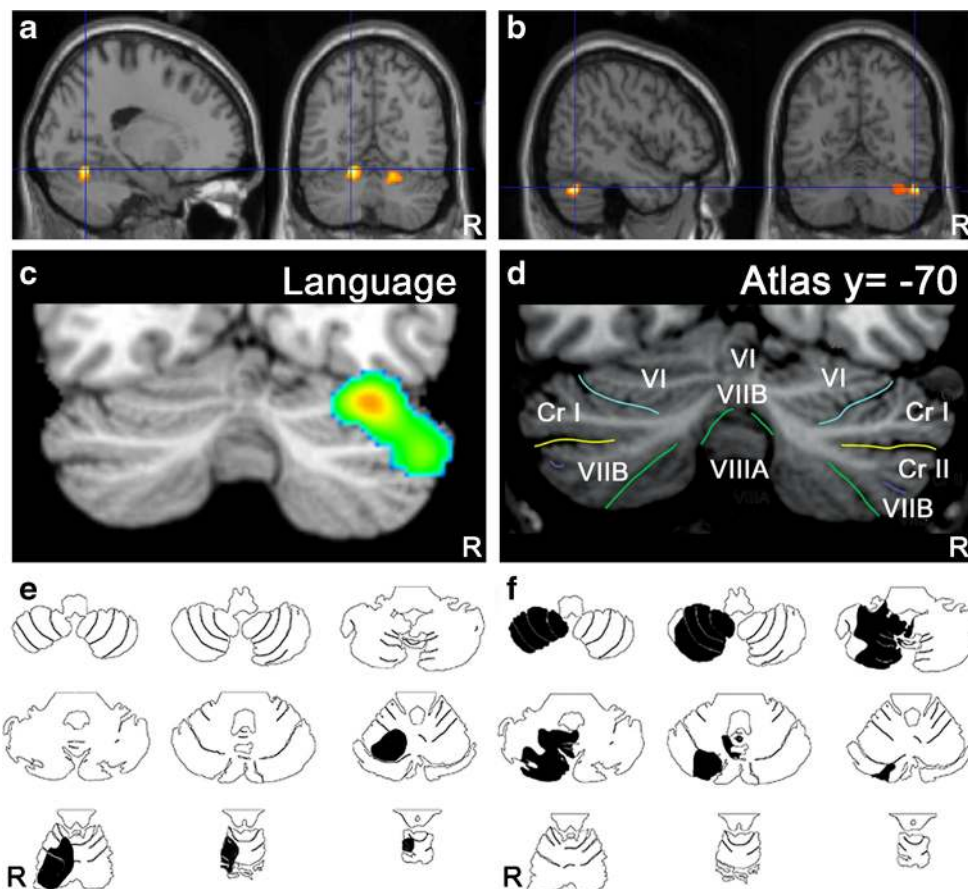
Functional neuroimaging studies show that the cerebellum is engaged by language tasks including verbal fluency, word stem completion, word or letter generation, and phonological and semantic processing (for reviews, [34, 235], Fig. 8). Reading tasks – whether overt or covert – also engage the cerebellum. Language-related activation tends to be in the right posterior-lateral cerebellum, involving lateral lobules VI and VII (Crus I and II; see [34]). This right-lateralization is consistent with the contralateral projections between the cerebellum and cerebral cortex [189, 236]. Dynamic causal modeling of fMRI data during rhyme judgment reveals reciprocal interactions between right cerebellar lobules VI and Crus I, and the left inferior frontal gyrus and left lateral temporal cortex [216], indicating that these cerebellar regions are part of the language network. Different regions of the cerebellar cortex and dentate nucleus are active in relation to overt speech compared with verb generation: variations on silent and overt reading and verb generation tasks show that the motor component of speech engages medial lobule VI and bilateral rostral regions of the dentate, whereas verb

generation activates right lateral regions of VI–Crus I and the right ventrocaudal dentate [228]. Similarly, reading aloud engages bilateral lobules V/VI, whereas lexical decision making activates right lateral lobule VI [237]. Neuroimaging studies also suggest that right lobule VIIIA may also be involved in language processing. Language interference in bilingual subjects is associated structurally (gray matter differences) and functionally (PET activation patterns) with right lobule VIIIA [238], and verb generation activates both right lobules VI–Crus I and a second cluster in right lobules VIIB–VIIIA [125].

Studies in patients with cerebellar lesions describe language deficits including impaired verbal fluency and agrammatism. These findings occur following damage to the cerebellar posterior lobe, often, but not always, from lesions of the right hemisphere ([25, 92, 140]; for review see [27]). Voxel-based lesion-symptom mapping shows that impaired verbal fluency results from damage to right Crus II, whereas paravermal lesions in lobules VI, VII, and VIIIA produce slower speech [137].

In summary, recent advances in our understanding of functional subregions of the cerebellum help to clarify the potential role of the cerebellum in language. While the cerebellum clearly contributes to motoric aspects of speech production,

Fig. 8 Topographic arrangement in cerebellum of speech versus language representation. Functional MRI localizes articulation (a) to medial parts of lobule VI bilaterally, whereas verb generation (b) activates lateral regions of lobule VI and Crus I on the right [259]. In a meta-analysis of functional imaging studies [34] higher level language tasks engage the right lateral posterior cerebellum, lobules VI and Crus I (c) according to the lobule identification in (d) [260]. Case studies of cerebellar stroke patients reveal topography for articulation vs. higher-level language tasks. A patient with stroke in the territory of the right superior cerebellar artery (e, *black shading*) involving lobules I–VI was dysarthric; whereas a patient with stroke in the territory of the right posterior inferior cerebellar artery (f, *black shading*) involving lobules VII–IX was not dysarthric but performed poorly on the Boston Naming Test [261]



the cerebellum is also engaged by higher order processes critical to linguistic processing. The cerebellar representation of the muscles of articulation is located in medial lobule VI, which is linked with sensorimotor areas of the cerebral cortex. By contrast, the conceptual elements of language engage mostly the right posterior-lateral regions of lobules VI and VII, which are reciprocally linked with language networks of the cerebral cortex. This motor versus cognitive dichotomy is evident also within the cerebellar deep nuclei. What are the mechanisms of this putative cerebellar contribution to language? It has been suggested that cerebellar activation during language tasks reflects inner speech or subvocal rehearsal (e.g., see [211]), but it now appears that this view of the cerebellar contribution to verbal (and nonverbal) expression is too limited. The fact that the cerebellum is engaged in articulation (motor speech) as well as in language (the abstract symbols of communication); the recognition that cerebellar regions involved in motor versus cognitive aspects of verbal expression have different anatomic signatures; and the dual anatomic realities of paracrystalline architecture of cerebellar histology on the one hand and the precisely arranged heterogeneity of cerebellar connectional anatomy and functional topography on the other, are all consistent with the dysmetria of thought theory [239–241]. In this view, the computation unique to the cerebellum, the universal cerebellar transform, integrates internal representations with external stimuli and self generated responses in an implicit (automatic/nonconscious) manner, serving as an oscillation dampener which optimizes performance according to context. How precisely this applies to linguistic processing is the subject of ongoing study.

Deep Cerebellar Nuclei and Language (D. Timmann, M. Thürling, M. Küper)

Cerebellar cortex and cerebellar nuclei are the key anatomical structures of the cerebellum [242]. Whereas cerebellar input is primarily directed to the cerebellar cortex, most of the output of the cerebellum is relayed via the cerebellar nuclei. Considering the methodological limitations, few functional neuroimaging and lesion studies have investigated functions of the cerebellar nuclei in humans [243, 244 for reviews]. The majority of human studies involve the cerebellar cortex. Regarding language, studies of the dentate nucleus are of particular interest given that the more ventral and caudal parts of the dentate nucleus are thought to contribute to nonmotor functions [166]. One problem in functional magnetic resonance imaging (fMRI) studies is the small size and variability of the dentate nucleus, making it difficult to precisely superimpose subdivisions of the nucleus for group comparisons. Here, a recently developed region of interest (ROI) driven normalization approach is of help and leads to near perfect overlap of the

dentate nuclei [245]. This method can equally be applied to normalize lesions of the cerebellar nuclei based on structural MRI in human cerebellar lesion studies [246]. The fact that the dentate nucleus, due to its high iron content, can be clearly seen on T2*-weighted (or susceptibility weighted imaging, SWI) scans as a hypointensity is used to ensure overlap of the deep cerebellar nuclei after normalization. High iron content on the other hand, leads to fMRI signal losses due to magnetic susceptibility artifacts. In addition, blood oxygenation dependent effects in the cerebellar nuclei are likely less compared with the cerebellar cortex. Ultra-high field MRI with its increased signal to noise ratio has been shown useful to overcome some of these limitations [126, 247].

A subdivision of the dentate nucleus in a more dorsal and rostral motor domain and a more ventral and caudal nonmotor domain has been proposed by Dum and Strick [248] based on their anatomical studies in monkey. In humans, fMRI studies provide first evidence that a similar topographic organization exists within the dentate nucleus [135, 247]. As mentioned by Stoodley and Schmahmann in section 9 of this article [225], initial findings suggest that different regions of the dentate nucleus support motor speech and language function [228]. One paradigm which has frequently been used to study the involvement of the cerebellum in language is verb generation [182, 249]. In this task, appropriate verbs are to be produced in response to written nouns. In two classic positron emission tomography studies, Petersen and co-workers [249, 250] reported activation of the right lateral cerebellum when generation of verbs was compared with reading of nouns. By contrast, cerebellar activation related to speech articulation (reading nouns aloud compared with silent reading) resulted in activation of the paravermal cerebellum. A recent 7 T fMRI study confirmed these findings for the cerebellar cortex (Fig. 9) and extended it to the level of the dentate nuclei (Fig. 10) [228]. Whereas motor speech related activation was found in the rostral parts of the dentate nucleus bilaterally, activation related to verb generation was found in the ventrocaudal parts of the dentate nucleus on the right. Lesions of the paravermal (“intermediate”) cerebellum are followed by dysarthria [231, 251]. Therefore, in addition to the dentate, the interposed nucleus (globose and emboliform in humans) likely contributes to motor speech control. Spatial resolution of the 7 T fMRI study did not allow for drawing conclusions on the level of the interposed nuclei. Activations of both the cerebellar cortex and the dentate nucleus related to verb generation were present unilaterally on the right side. Lateralization is in very good accordance with the assumption that the right cerebellum supports language function of the left cerebrum. A comparable functional compartmentalization at the level of the dentate nuclei has been found by Marvel and Desmond [120]. The authors report a relationship between dorsal dentate activation to the articulatory control system and ventral

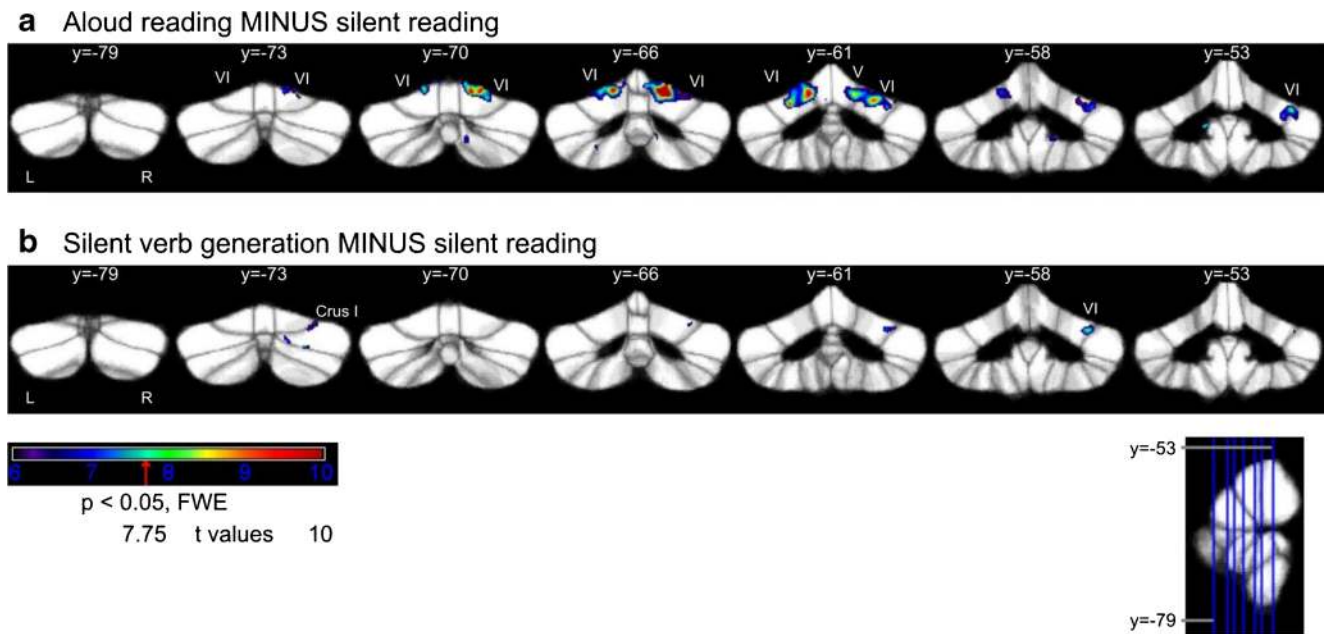


Fig. 9 Activation of the cerebellar cortex in a verb generation task [228]. **a** Cerebellar cortical activations of the contrasts *aloud reading* MINUS *silent reading*, and **b** (*silent*) *verb generation* MINUS *silent reading*. Activations of the cerebellar cortex are mapped onto coronal sections of

the SUIT maximum probability template [262]. A t value of 7.75 represents the threshold of $p < 0.05$ (FWE corrected). The positions of the coronal slices are shown in the sagittal view from $y = -79$ to -53 mm. *L* left, *R* right

dentate activation to cognitive aspects (retrieval) of a VWM task using event-related fMRI.

In conclusion, there is first evidence that the more ventral and caudal parts of the dentate nucleus contribute to language, and that language-related dentate areas are separated from

motor speech-related areas. The specific contributions of the deep cerebellar nuclei to language need to be elucidated in future studies using advanced structural and functional imaging methods in healthy subjects and patients with lesions including the cerebellar nuclei.




Fig. 10 Activation of the dentate nuclei in a verb generation task [220]. Dentate nucleus activations of the contrasts *aloud reading* MINUS *silent reading* on the right (*A*) and left (*B*), and (*silent*) *verb generation* MINUS *silent reading* on the right (*C*) and left

(*D*). Activations are mapped onto axial slices of the dentate template [262]. Color coding represents associated t values (threshold $p < 0.05$, Bootstrap corrected, $t = 3.72$)

Conclusions

In this consensus paper an attempt was made to capture the diversity of current opinions and viewpoints on the modulatory role of the cerebellum in a variety of nonmotor linguistic processes and some related impairments. Although a definite consensus statement cannot be reached with regard to the exact roles of the human cerebellum in linguistic function or the neurobiological mechanisms subserving cerebellar involvement in linguistic processes, the contributions by the panel of experts in the field of cerebellar neurocognition clearly highlight the variety of linguistic and cognitively related processes mediated by cerebellar input. It has to be noted, however, that disorders observed in patients with cerebellar disease are generally mild and test scores frequently fall into the lower end of the normal range. More sensitive neuropsychological tools are needed to identify the often discrete, but clinically relevant linguistic, cognitive and affective impairments following cerebellar damage. Furthermore, it is not always possible to rule out the influence of extracerebellar lesions and accompanying depression.

Several dimensions of speech and language production and perception seem to depend upon the modulatory role of the cerebellum: phonetic timing operations, auditory signal segregation and cross-modal binding mechanisms, adaptive sensorimotor function of speech motor planning, articulatory control processes in VWM, nonautomatic sequence strategies in verbal fluency, temporal coordination and recall of established explicit internal representations of sentence structures, high-level language functions (e.g., figurative language, word association, antonym/synonym generation), planning and execution of manual production of letters, and reading (development). Nonmotor linguistic function of the human cerebellum seems to be topographically organized in a “lateralized linguistic cerebellum” which reflects the patterns of cerebral language dominance in dextrals and sinistrals. In the majority of dextrals the “lateralized linguistic cerebellum” comprises the right ventrocaudal part of the dentate nucleus and the right posterior lateral cerebellum (involving lobules VI-VIII) that is reciprocally linked to the supratentorial language networks of the dominant hemisphere. However, anatomical studies providing direct evidence of reciprocal cerebellar connections to language areas are still lacking.

The theory that the cerebellum operates as an essential modulator of higher-level cerebral functions, including language and affect currently attracts much attention of the scientific community, but yet no consensus exists about the exact role and contributions of the cerebellum to the cognitive and affective domain [252]. Due to its uniform neuroanatomical structure and its dense connections with the supratentorial association areas via cerebrocerebellar pathways (corticopontine-pontocerebellar-cerebellothalamic-thalamocortical), the

cerebellum is considered a functional entity that contributes in a unique and general way to information processing (universal cerebellar transform, [240, 241, 253–255]). One of the computational models that supports this view on integrated cerebellar motor, cognitive and affective function is the dysmetria of thought theory which regards the cerebellum as an oscillation dampener (realising a maintenance of functioning around a homeostatic baseline, to smoothe out performance in all domains: cognitive, motor and emotional) [240, 241, 253, 254]. Several authors [101, 255, 256] regard the computational contribution of the cerebellum to motor, cognitive and affective function as a predictor of future states. This functional role implicates that the cerebellum generates internal neural “forward” models by means of optimization of motor programs and mediation of cognitive functioning. In a number of studies, Ito [210] suggested that the corticonuclear microcomplexes of the cerebellum function as learning machines, performing a comparator role consisting of the formation and updating of internal models through error learning (error predictions, processing and correction). According to others, the cerebellum may act as an “internal clock” crucially involved in the detection of deviations of an expected timing (control and regulation of motor and cognitive functions) [147, 257] or as a detector of change and deviations of sequential events [38, 86, 125, 149]. In other studies the role of the cerebellum is described as a control mechanism of shifts of attention, priming and boosting activity in the extracerebellar system to operate rapid and efficiently [256, 258].

More research is needed to elucidate the theoretical underpinnings of cerebellar neurocognition. An integrated vision of the theoretical conceptualisations of the general contribution of the cerebellum in cognitive functioning might be that of a high-level operational device that does not subserve a specific cognitive or affective function in itself but rather lends an active support to the central processes in a variety of ways including prediction of the consequences of a motor, affective or cognitive action or by error detection (in a sequence or in time).

Summing-up, cerebellar involvement in language extends far beyond the pure motor domain to a variety of high-level nonmotor linguistic processes at both the expressive and receptive language level. In general the role of the cerebellum in language adds evidence to the view that timing and sequencing processing, sensorimotor adaptation and cognitive skill automatization act as the overall operational modes of the cognitive cerebellum.

Acknowledgments This study is supported by NIH grants K01 DA0304425 (Dr. Marvel) and R01 AA018694 (Dr. Desmond) and by DFG TI 239/9-1. The editorial assistance of Mrs. Tine D’aes is greatly acknowledged.

Conflict of interest The authors declare that they have no conflict of interest.

References

1. Manto M, Bower JM, Conforto AB, Delgado-García JM, da Guarda SN, Gerwig M, et al. Consensus paper: roles of the cerebellum in motor control—the diversity of ideas on cerebellar involvement in movement. *Cerebellum*. 2012;11:457–87.
2. Schmahmann J. An emerging concept. The cerebellar contribution to higher function. *Arch Neurol*. 1991;48:1178–87.
3. Schmahmann JD. Rediscovery of an early concept. In: Schmahmann JD (Ed.) *The cerebellum and cognition*. Int Rev Neurobiol, vol. 41. San Diego: Academic; 1997. p. 3–27
4. Snider RS, Eldred E. Cerebral projections to the tactile, auditory and visual areas of the cerebellum. *Anat Rec*. 1948;100:714.
5. Snider RS. Recent contributions to the anatomy and physiology of the cerebellum. *Arch Neurol Psychiat*. 1950;64:196–219.
6. Snider RS, Maiti A. Cerebellar contributions to the Papez circuit. *J Neurosci Res*. 1976;2:133–46.
7. Dow RS. Some novel concepts of cerebellar physiology. *Mt Sinai J Med*. 1974;41:103–19.
8. Heath RG. Modulation of emotion with a brain pacemaker. Treatment for intractable psychiatric illness. *J Nerv Ment Dis*. 1977;165:300–17.
9. Heath RG. In: Schmahmann JD, editor. *The cerebellum and cognition*. Int Rev Neurobiol, vol. 41. San Diego: Academic; 1997. p
10. Heath RG, Franklin DE, Shraberg D. Gross pathology of the cerebellum in patients diagnosed and treated as functional psychiatric disorders. *J Nerv Ment Dis*. 1979;167:585–92.
11. Cooper IS, Riklan M, Amin I, Cullinan T. A long-term follow-up study of cerebellar stimulation for the control of epilepsy. In: Cooper IS, editor. *Cerebellar stimulation in man*. New York: Raven Press; 1978. p. 19–38.
12. Leiner HC, Leiner AL, Dow RS. Does the cerebellum contribute to mental skills? *Behav Neurosci*. 1986;100:443–54.
13. Leiner HC, Leiner AL, Dow RS. The human cerebro-cerebellar system: its computing, cognitive, and language skills. *Behav Brain Res*. 1991;44:113–28.
14. Schmahmann JD, Pandya DN. Posterior parietal projections to the basis pontis in rhesus monkey. Possible anatomical substrate for the cerebellar modulation of complex behavior. *Neurology*. 1987;37:297.
15. Schmahmann JD, Pandya DN. Anatomical investigation of projections to the basis pontis from posterior parietal association cortices in rhesus monkey. *J Comp Neurol*. 1989;289:53–73.
16. Allin M, Matsumoto H, Santhouse AM, Nosarti C, AlAsady MHS, Stewart AL, et al. Cognitive and motor functions and the size of the cerebellum in adolescents born very pre-term. *Brain*. 2001;124:60–6.
17. Ciesielski KT, Harris RJ, Hart BL, Pabst HF. Cerebellar hypoplasia and frontal lobe cognitive deficits in disorders of early childhood. *Neuropsychologia*. 1997;35:643–55.
18. Paradiso S, Andreasen N, O'Leary DS, Arndt S, Robinson RG. Cerebellar size and cognition: correlations with IQ, verbal memory and motor dexterity. *Neuropsychology*. 1997;10:1–8.
19. Mostofsky SH, Mazzocco MMN, Aakalu G, Warsofsky IS, Denckla MB, Reiss AL. Decreased cerebellar posterior vermis size in fragile X syndrome: correlation with neurocognitive performance. *Neurology*. 1998;50:121–30.
20. MacLeod CE, Zilles K, Schleicher A, Rilling JK, Gibson KR. Expansion of the neocerebellum in Hominoidea. *J Hum Evol*. 44(4):401–29. Erratum in: *J Hum Evol*. 2003;45(3):261
21. Pangelinan MM, Zhang G, VanMeter JW, Clark JE, Hatfield BD, Hauffler AJ. Beyond age and gender: relationships between cortical and subcortical brain volume and cognitive-motor abilities in school-age children. *NeuroImage*. 2011;54:3093–100.
22. Parker J, Mitchell A, Kalpakidou A, Walshe M, Jung HY, Nosarti C, et al. Cerebellar growth and behavioural and neuropsychological outcome in preterm adolescents. *Brain*. 2008;131:1344–51.
23. Posthuma D, Baaré WFC, Hulshoff Pol HE, Kahn RS, Boomsma DI, De Geus EJC. Genetic correlations between brain volumes and the WAIS-III dimensions of verbal comprehension, working memory, perceptual organization, and processing speed. *Twin Research*. 2003;6:131–9.
24. Justus TC, Ivry RB. The cognitive neuropsychology of the cerebellum. *Int Rev Psychiatr*. 2001;13:276–82.
25. Schmahmann JD, Sherman JC. The cerebellar cognitive affective syndrome. *Brain*. 1998;121:561–79.
26. Gordon N. Speech, language, and the cerebellum. *Eur J Disord of Commun*. 1996;31:359–67.
27. Mariën P, Engelborghs S, Fabbro F, De Deyn PP. The lateralized linguistic cerebellum: a review and a new hypothesis. *Brain Lang*. 2001;79:580–600.
28. Paquier PF, Mariën P. A synthesis of the role of the cerebellum in cognition. *Aphasiology*. 2005;19:3–19.
29. De Smet HJ, Baillieux H, De Deyn PP, Mariën P, Paquier P. The cerebellum and language: the story so far. *Folia Phoniatr Logop*. 2007;59:165–70.
30. De Smet HJ, Paquier P, Verhoeven J, Mariën P. The cerebellum: its role in language and related cognitive and affective functions. *Brain Lang*. 2013 [Epub ahead of print]
31. Beaton A, Mariën P. Language, cognition and the cerebellum: grappling with an enigma. *Cortex*. 2010;46:811–20.
32. Murdoch BE. The cerebellum and language: historical perspective and review. *Cortex*. 2010;46:858–68.
33. Highnam CL, Bleile KM. Language in the cerebellum. *Am J Speech Lang Pathol*. 2011;20:337–47.
34. Stoodley CJ, Schmahmann JD. Functional topography in the human cerebellum: a meta-analysis of neuroimaging studies. *NeuroImage*. 2009;44:489–501.
35. Ivry RB, Spencer RMC. The neural representation of time. *Curr Opin Neurobiol*. 2004;14:225–32.
36. Keele SW, Ivry R. Does the cerebellum provide a common computation for diverse tasks? A timing hypothesis. *Ann N Y Acad Sci*. 1990;608:179–211.
37. D'Angelo E, Koekkoek SKE, Lombardo P, Solinas S, Ros E, Garrido J, et al. Timing in the cerebellum: oscillations and resonance in the granular layer. *Neuroscience*. 2009;162:805–15.
38. Ackermann H. Cerebellar contributions to speech production and speech perception: psycholinguistic and neurobiological perspectives. *Trends Neurosci*. 2008;31:265–72.
39. Ackermann H, Gräber S, Hertrich I, Daum I. Categorical speech perception in cerebellar disorders. *Brain Lang*. 1997;60:323–31.
40. Ackermann H, Gräber S, Hertrich I, Daum I. Cerebellar contributions to the perception of temporal cues within the speech and nonspeech domain. *Brain Lang*. 1999;67:228–41.
41. Mathiak K, Hertrich I, Grodd W, Ackermann H. Cerebellum and speech perception: a functional magnetic resonance imaging study. *J Cogn Neurosci*. 2002;14:902–12.
42. Mathiak K, Hertrich I, Grodd W, Ackermann H. Discrimination of temporal information at the cerebellum: functional magnetic resonance imaging of nonverbal auditory memory. *NeuroImage*. 2004;21:154–62.
43. Ackermann H, Hertrich I. The contribution of the cerebellum to speech processing. *J Neurolinguist*. 2000;13:95–116.
44. Ivry RB, Gopal HS. Speech production and perception in patients with cerebellar lesions. Synergies in experimental psychology, artificial intelligence and cognitive neuroscience. In: Meyer DE, Kornblum S, editors. *Attention Perform*, vol. 14. Cambridge, MA: MIT Press; 1993. p. 771–802.

45. Spencer RMC, Zelaznik HN, Diedrichsen J, Ivry RB. Disrupted timing of discontinuous but not continuous movements by cerebellar lesions. *Science*. 2003;300:1437–9.
46. Petacchi A, Laird AR, Fox PT, Bower JM. Cerebellum and auditory function: an ALE meta-analysis of functional neuroimaging studies. *Hum Brain Mapp*. 2005;25:118–28.
47. Sens PM, Almeida CIR, Souza MMND, Gonçalves JBA, Carmo LCD. The role of the cerebellum in auditory processing using the SSI test. *Braz J Otorhi*. 2011;77:584–8.
48. Moore JK. The human auditory brain stem: a comparative view. *Hearing Res*. 1987;29(1):1–32.
49. Parsons LM, Petacchi A, Schmahmann JD, Bower JM. Pitch discrimination in cerebellar patients: evidence for a sensory deficit. *Brain Res*. 2009;1303:84–96.
50. Kashino M, Kondo HM. Functional brain networks underlying perceptual switching: auditory streaming and verbal transformations. *Philos T Roy Soc B*. 2012;367:977–87.
51. Stoodley CJ, Stein JF. The cerebellum and dyslexia. *Cortex*. 2011;47(1):101–16.
52. Powers AR, Hevey MA, Wallace MT. Neural correlates of multi-sensory perceptual learning. *J Neurosci*. 2012;32:6263–74.
53. Schwartz M, Tavano A, Schröger E, Kotz SA. Temporal aspects of prediction in audition: cortical and subcortical neural mechanisms. *Int J Psychophysiol*. 2012;83:200–7.
54. Wolpert DM, Ghahramani Z. Computational principles of movement neuroscience. *Nat Neurosci*. 2000;3:1212–7.
55. Bohland JW, Bullock D, Guenther FH. Neural representations and mechanisms for the performance of simple speech sequences. *J Cognitive Neurosci*. 2010;22:1504–29.
56. Perkell JS. Movement goals and feedback and feedforward control mechanisms in speech production. *J Neurolinguist*. 2012;25:382–407.
57. Roelofs A. WEAVER++ and other computational models of lemma retrieval and word-form encoding. In: Wheeldon L, editor. *Aspects of language production*. Sussex, UK: Psychology Press; 2000. p. 71–114.
58. Cholin J, Levelt WJ, Schiller NO. Effects of syllable frequency in speech production. *Cognition*. 2006;99:205–35.
59. Mooshammer C, Goldstein L, Nam H, McClure S, Saltzman E, Tiede M. Bridging planning and execution: temporal planning of syllables. *J Phonetics*. 2012;40:374–89.
60. Ziegler W, Aichert I, Staiger A. Apraxia of speech: concepts and controversies. *J Speech LangHear R*. 2012;55:S1485–501.
61. Ackermann H, Ziegler W. Brain mechanisms underlying speech. In: Hardcastle WJ, Laver J, Gibbon FE, editors. *The handbook of phonetic sciences*. New York: Wiley-Blackwell; 2010. p. 202–50.
62. Bohland JW, Guenther FH. An fMRI investigation of syllable sequence production. *Neuroimage*. 2006;32:821–41.
63. Shuster LI, Lemieux SK. An fMRI investigation of covertly and overtly produced mono- and multisyllabic words. *Brain Lang*. 2005;93:20–31.
64. Brendel B, Erb M, Riecker A, Grodd W, Ackermann H, Ziegler W. Do we have a “mental syllabary” in the brain? An fMRI study. *Mot Control*. 2011;15:34–51.
65. Riecker A, Brendel B, Ziegler W, Erb M, Ackermann H. The influence of syllable onset complexity and syllable frequency on speech motor control. *Brain Lang*. 2008;107:102–13.
66. Papoutsis M, de Zwart JA, Jansma JM, Pickering MJ, Bednar JA, Horwitz B. From phonemes to articulatory codes: an fMRI study of the role of Broca’s area in speech production. *Cereb Cortex*. 2009;19:2156–65.
67. Eickhoff SB, Heim S, Zilles K, Amunts K. A systems perspective on the effective connectivity of overt speech production. *Philos T Roy Soc A*. 2009;367:2399–421.
68. Ziegler W. Apraxia of speech. In: Goldenberg G, Miller B, editors. *Handbook of Clinical Neurology*. London: Elsevier; 2008. p. 269–85.
69. Dronkers NF. A new brain region for coordinating speech articulation. *Nature*. 1996;384:159–61.
70. Hillis AE, Work M, Barker PB, Jacobs MA, Breese EL, Maurer K. Re-examining the brain regions crucial for orchestrating speech articulation. *Brain*. 2004;127:1479–87.
71. Ottomeyer C, Reuter B, Jäger T, Rossmannith C, Hennerici MG, Szabo K. Aphemia: an isolated disorder of speech associated with an ischemic lesion of the left precentral gyrus. *J Neurol*. 2009;256:1166–8.
72. Schiff HB, Alexander MP, Naeser MA, Galaburda AM. Aphemia. Clinical-anatomic correlations. *Arch Neurol-Chicago*. 1983;40:720–7.
73. Terao Y, Ugawa Y, Yamamoto T, Sakurai Y, Masumoto T, Abe O, et al. Primary face motor area as the motor representation of articulation. *J Neurol*. 2007;254:442–7.
74. Duffy JR. *Motor speech disorders: substrates, differential diagnosis, and management*. Saint Louis: Elsevier; 2005.
75. Mariën P, Verhoeven J, Engelborghs S, Rooker S, Pickut BA, De Deyn PP. A role for the cerebellum in motor speech planning: evidence from foreign accent syndrome. *Clin Neurol Neurosurg*. 2006;108:518–22.
76. Mariën P, Verhoeven J. Cerebellar involvement in motor speech planning: some further evidence from foreign accent syndrome. *Folia Phoniatr Logo*. 2007;59:210–7.
77. Ziegler W, Wessel K. Speech timing in ataxic disorders: sentence production and rapid repetitive articulation. *Neurology*. 1996;47:208–14.
78. Ziegler W. Task-related factors in oral motor control: speech and oral diadochokinesis in dysarthria and apraxia of speech. *Brain Lang*. 2002;80:556–75.
79. Baddeley A. Working memory: looking back and looking forward. *Nat Rev Neurosci*. 2003;4(10):829–39.
80. Ben-Yehudah G, Fiez JA. Impact of cerebellar lesions on reading and phonological processing. *Ann NY Acad Sci*. 2008;1145:260–74.
81. Chiricozzi FR, Clausi S, Molinari M, Leggio MG. Phonological short-term store impairment after cerebellar lesion: a single case study. *Neuropsychologia*. 2008;46(7):1940–53.
82. Hokkanen LS, Kauranen V, Roine RO, Salonen O, Kotila M. Subtle cognitive deficits after cerebellar infarcts. *Eur J Neurol*. 2006;13(2):161–70.
83. Justus T, Ravizza SM, Fiez JA, Ivry RB. Reduced phonological similarity effects in patients with damage to the cerebellum. *Brain Lang*. 2005;95(2):304–18.
84. Ravizza SM, McCormick CA, Schlerf JE, Justus T, Ivry RB, Fiez JA. Cerebellar damage produces selective deficits in verbal working memory. *Brain*. 2006;129:306–20.
85. Ziemus B, Baumann O, Luerding R, Schlosser R, Schuierer G, Bogdahn U, et al. Impaired working-memory after cerebellar infarcts paralleled by changes in BOLD signal of a cortico-cerebellar circuit. *Neuropsychologia*. 2007;45(9):2016–24.
86. Leggio MG, Chiricozzi FR, Clausi S, Tedesco AM, Molinari M. The neuropsychological profile of cerebellar damage: the sequencing hypothesis. *Cortex*. 2011;47(1):137–44.
87. Cooper FE, Grube M, Von Kriegstein K, Kumar S, English P, Kelly TP, et al. Distinct critical cerebellar subregions for components of verbal working memory. *Neuropsychologia*. 2012;50(1):189–97.
88. de Ribaupierre S, Ryser C, Villemure JG, Clarke S. Cerebellar lesions: is there a lateralisation effect on memory deficits? *Acta Neurochir (Wien)*. 2008;150(6):545–50.
89. Gottwald B, Wilde B, Mihajlovic Z, Mehdorn HM. Evidence for distinct cognitive deficits after focal cerebellar lesions. *J Neurol Neurosurg Ps*. 2004;75(11):1524–31.
90. Kirschen MP, Davis-Ratner MS, Milner MW, Chen SH, Schraedley-Desmond P, Fisher PG, et al. Verbal memory

- impairments in children after cerebellar tumor resection. *Behav Neurol.* 2008;20:39–53.
91. Law N, Bouffet E, Laughlin S, Laperriere N, Briere ME, Strother D, et al. Cerebello-thalamo-cerebral connections in pediatric brain tumor patients: impact on working memory. *NeuroImage.* 2011;56(4):2238–48.
 92. Levisohn L, Cronin-Golomb A, Schmahmann JD. Neuropsychological consequences of cerebellar tumour resection in children: cerebellar cognitive affective syndrome in a paediatric population. *Brain.* 2000;123:1041–50.
 93. Riva D, Giorgi C. The cerebellum contributes to higher functions during development: evidence from a series of children surgically treated for posterior fossa tumours. *Brain.* 2000;123:1051–61.
 94. Scott RB, Stoodley CJ, Anslow P, Paul C, Stein JF, Sugden EM, et al. Lateralized cognitive deficits in children following cerebellar lesions. *Dev Med Child Neurol.* 2001;43(10):685–91.
 95. Silveri MC, Di Betta AM, Filippini V, Leggio MG, Molinari M. Verbal short-term store-rehearsal system and the cerebellum. Evidence from a patient with a right cerebellar lesion. *Brain.* 1998;121:2175–87.
 96. Steinlin M, Imfeld S, Zulauf P, Boltshauser E, Lövsblad KO, Ridolfi Luthy A, et al. Neuropsychological long-term sequelae after posterior fossa tumour resection during childhood. *Brain.* 2003;126:1998–2008.
 97. Vaquero E, Gomez CM, Quintero EA, Gonzalez-Rosa JJ, Marquez J. Differential prefrontal-like deficit in children after cerebellar astrocytoma and medulloblastoma tumor. *Behav Brain Funct.* 2008;4:18.
 98. Timmann D, Daum I. How consistent are cognitive impairments in patients with cerebellar disorders? *Behav Neurol.* 2010;23:81–100.
 99. Chen SH, Desmond JE. Temporal dynamics of cerebro-cerebellar network recruitment during a cognitive task. *Neuropsychologia.* 2005;43(9):1227–37.
 100. Ben-Yehudah G, Guediche S, Fiez JA. Cerebellar contributions to verbal working memory: beyond cognitive theory. *Cerebellum.* 2007;6(3):193–201.
 101. Desmond JE, Gabrieli JDE, Wagner AD, Ginier BL, Glover GH. Lobular patterns of cerebellar activation in verbal working-memory and finger-tapping tasks as revealed by functional MRI. *J Neurosci.* 1997;17(24):9675–85.
 102. Ackermann H, Mathiak K, Ivry RB. Temporal organization of “internal speech” as a basis for cerebellar modulation of cognitive functions. *Behav Cogn Neurosci Rev.* 2004;3(1):14–22.
 103. Marvel CL, Desmond JE. Functional topography of the cerebellum in verbal working memory. *Neuropsychol Rev.* 2010;20(3):271–9.
 104. Chen SH, Desmond JE. Cerebrocerebellar networks during articulatory rehearsal and verbal working memory tasks. *NeuroImage.* 2005;24(2):332–8.
 105. Kirschen MP, Chen SH, Desmond JE. Modality specific cerebro-cerebellar activations in verbal working memory: an fMRI study. *Behav Neurol.* 2010;23:51–63.
 106. Awh E, Jonides J, Smith EE, Schumacher EH, Koeppel RA, Katz S. Dissociation of storage and rehearsal in verbal working memory: evidence from positron emission tomography. *Psychol Sci.* 1996;7(1):25–31.
 107. Chein JM, Fiez JA. Dissociation of verbal working memory system components using a delayed serial recall task. *Cereb Cortex.* 2001;11(11):1003–14.
 108. Durisko C, Fiez JA. Functional activation in the cerebellum during working memory and simple speech tasks. *Cortex.* 2010;46(7):896–906.
 109. Fiez JA, Raife EA, Balota DA, Schwarz JP, Raichle ME, Petersen SE. A positron emission tomography study of the short-term maintenance of verbal information. *J Neurosci.* 1996;16(2):808–22.
 110. Grasby PM, Frith CD, Friston KJ, Bench C, Frackowiak RS, Dolan RJ. Functional mapping of brain areas implicated in auditory-verbal memory function. *Brain.* 1993;116:1–20.
 111. Grasby PM, Frith CD, Friston KJ, Simpson J, Fletcher PC, Frackowiak RS, et al. A graded task approach to the functional mapping of brain areas implicated in auditory-verbal memory. *Brain.* 1994;117:1271–82.
 112. Gruber O. Effects of domain-specific interference on brain activation associated with verbal working memory task performance. *Cereb Cortex.* 2001;11(11):1047–55.
 113. Hautzel H, Mottaghy FM, Specht K, Müller HW, Krause BJ. Evidence of a modality-dependent role of the cerebellum in working memory? An fMRI study comparing verbal and abstract n-back tasks. *NeuroImage.* 2009;47(4):2073–82.
 114. Hayter AL, Langdon DW, Ramnani N. Cerebellar contributions to working memory. *NeuroImage.* 2007;36(3):943–54.
 115. Henson RN, Burgess N, Frith CD. Recoding, storage, rehearsal and grouping in verbal short-term memory: an fMRI study. *Neuropsychologia.* 2000;38(4):426–40.
 116. Jonides J, Schumacher EH, Smith EE, Koeppel RA, Awh E, Reuter-Lorenz PA, et al. The role of parietal cortex in verbal working memory. *J Neurosci.* 1998;18(13):5026–34.
 117. Jonides J, Schumacher EH, Smith EE, Lauber EJ, Awh E, Minoshima S, et al. Verbal working memory load affects regional brain activation as measured by PET. *J Cognitive Neurosci.* 1997;9:462–75.
 118. Kirschen MP, Chen SH, Schraedley-Desmond P, Desmond JE. Load- and practice-dependent increases in cerebro-cerebellar activation in verbal working memory: an fMRI study. *NeuroImage.* 2005;24(2):462–72.
 119. LaBar KS, Gitelman DR, Parrish TB, Mesulam M. Neuroanatomic overlap of working memory and spatial attention networks: a functional MRI comparison within subjects. *NeuroImage.* 1999;10(6):695–704.
 120. Marvel CL, Desmond JE. The contributions of cerebro-cerebellar circuitry to executive verbal working memory. *Cortex.* 2010;46(7):880–95.
 121. Marvel CL, Desmond JE. From storage to manipulation: how the neural correlates of verbal working memory reflect varying demands on inner speech. *Brain Lang.* 2012;120(1):42–51.
 122. Paulesu E, Frith CD, Frackowiak RS. The neural correlates of the verbal component of working memory. *Nature.* 1993;362(6418):342–5.
 123. Schumacher EH, Lauber E, Awh E, Jonides J, Smith EE, Koeppel RA. PET evidence for an amodal verbal working memory system. *NeuroImage.* 1996;3(2):79–88.
 124. Smith EE, Jonides J, Koeppel RA. Dissociating verbal and spatial working memory using pet. *Cereb Cortex.* 1996;6(1):11–20.
 125. Stoodley CJ, Valera EM, Schmahmann JD. Functional topography of the cerebellum for motor and cognitive tasks: an fMRI study. *NeuroImage.* 2011;59(2):1560–70.
 126. Thurling M, Hautzel H, Kuper M, Stefanescu MR, Maderwald S, Ladd ME, et al. Involvement of the cerebellar cortex and nuclei in verbal and visuospatial working memory: a 7 T fMRI study. *NeuroImage.* 2012;62(3):1537–50.
 127. Sternberg S. High-speed scanning in human memory. *Science.* 1966;153(736):652–4.
 128. Desmond JE, Chen SH, DeRosa E, Pryor MR, Pfefferbaum A, Sullivan EV. Increased frontocerebellar activation in alcoholics during verbal working memory: an fMRI study. *NeuroImage.* 2003;19(4):1510–20.

129. Marvel CL, Faulkner ML, Strain EC, Mintzer MZ, Desmond JE. An fMRI investigation of cerebellar function during verbal working memory in methadone maintenance patients. *Cerebellum*. 2012;11(1):300–10.
130. Silverman DH, Dy CJ, Castellon SA, Lai J, Pio BS, Abraham L, et al. Altered frontocortical, cerebellar, and basal ganglia activity in adjuvant-treated breast cancer survivors 5–10 years after chemotherapy. *Breast Cancer Res Treat*. 2007;103(3):303–11.
131. Abwender DA, Swan JG, Bowerman JT, Connolly SW. Qualitative analysis of verbal fluency output: review and comparison of several scoring methods. *Assessment*. 2001;8:323–38.
132. Arasanz CP, Staines WR, Roy EA, Schweizer TA. The cerebellum and its role in word generation: a cTBS study. *Cortex*. 2012;48:718–24.
133. Brandt J, Leroi I, O’Hearn E, Rosenblatt A, Margolis RL. Cognitive impairments in cerebellar degeneration: a comparison with Huntington’s disease. *J Neuropsych Clin N*. 2004;16:176–84.
134. Gottwald B, Mihajlovic Z, Wilde B, Mehdorn HM. Does the cerebellum contribute to specific aspects of attention? *Neuropsychologia*. 2003;41:1452–60.
135. Leggio M, Silveri M, Petrosini L, Molinari M. Phonological grouping is specifically affected in cerebellar patients: a verbal fluency study. *J Neurol Neurosurg Ps*. 2000;69:102–6.
136. Peterburs J, Bellebaum C, Koch B, Schwarz M, Daum I. Working memory and verbal fluency deficits following cerebellar lesions: relation to interindividual differences in patient variables. *Cerebellum*. 2010;9:375–83.
137. Richter S, Gerwig M, Aslan B, Wilhelm H, Schoch B, Dimitrova A, et al. Cognitive functions in patients with MR-defined chronic focal cerebellar lesions. *J Neurol*. 2007;254:1193–203.
138. Schweizer TA, Alexander MP, Susan Gillingham BA, Cusimano M, Stuss DT. Lateralized cerebellar contributions to word generation: a phonemic and semantic fluency study. *Behav Neurol*. 2010;23:31–7.
139. Stoodley CJ, Schmahmann JD. The cerebellum and language: evidence from patients with cerebellar degeneration. *Brain Lang*. 2009;110:149–53.
140. Tedesco AM, Chiricozzi FR, Clausi S, Lupo M, Molinari M, Leggio MG. The cerebellar cognitive profile. *Brain*. 2011;134:3669–83.
141. Rosser A, Hodges JR. Initial letter and semantic category fluency in Alzheimer’s disease, Huntington’s disease, and progressive supranuclear palsy. *J Neurol Neurosurg Ps*. 1994;57:1389–94.
142. Troster AI, Warmflash V, Osorio I, Paolo AM, Alexander LJ, Barr WB. The roles of semantic networks and search efficiency in verbal fluency performance in intractable temporal lobe epilepsy. *Epilepsy Res*. 1995;21:19–21.
143. Martin A, Wiggs CL, Lalonde FM, Wiggs CL, Ungerleider LG. Word retrieval to letter and semantic cues: A double dissociation in normal subjects using interference tasks. *Neuropsychologia*. 1994;32:1487–94.
144. Troyer AK, Moscovitch M, Winocur G, Alexander MP, Stuss D. Clustering and switching on verbal fluency: the effects of focal frontal- and temporal-lobe lesions. *Neuropsychologia*. 1998;36:499–504.
145. Stuss DT, Alexander MP. Is there a dysexecutive syndrome? *Philos T Roy Soc B*. 2007;362:901–15.
146. Braitenberg V, Heck D, Sultan F. The detection and generation of sequences as a key to cerebellar function: experiments and theory. *Behav Brain Sci*. 1997;20:229–77.
147. Ivry R. Cerebellar timing systems. *Int Rev Neurobiol*. 1997;41:555–73.
148. Mauk MD, Medina JF, Nores WL, Ohyama T. Cerebellar function: coordination, learning or timing? *Curr Biol*. 2000;10:522–5.
149. Molinari M, Chiricozzi FR, Clausi S, Tedesco AM, De Lisa GM, Leggio MG. Cerebellum and detection of sequences, from perception to cognition. *Cerebellum*. 2008;7:611–5.
150. Bower JM. Control of sensory data acquisition. *Int Rev Neurobiol*. 1997;41:489–513.
151. Restuccia D, Della Marca G, Valeriani M, Leggio MG, Molinari M. Cerebellar damage impairs detection of somatosensory input changes. A somatosensory mismatch negativity study. *Brain*. 2007;130:276–87.
152. Tesche CD, Karhu JTT. Anticipatory cerebellar response during somatosensory omission in man. *Hum Brain Mapp*. 2000;9:119–42.
153. Thach WT, Goodkin HP, Keating JG. The cerebellum and the adaptive coordination of movement. *Annu Rev Neurosci*. 1992;15:403–42.
154. Leggio MG, Tedesco AM, Chiricozzi FR, Clausi S, Orsini A, Molinari M. Cognitive sequencing impairment in patients with focal or atrophic cerebellar damage. *Brain*. 2008;131:1332–43.
155. Ito M. Cerebellar circuitry as a neuronal machine. *Prog Neurobiol*. 2006;78:272–303.
156. Fabbro F, Moretti R, Bava A. Language impairments in patients with cerebellar lesions. *J Neuroling*. 2000;13:173–88.
157. Gasparini M, Di Piero V, Ciccirelli O, Cacioppo MM, Pantano P, Lenzi GL. Linguistic impairment after right cerebellar stroke: a case report. *Eur J Neurol*. 1999;6:353–6.
158. Justus T. The cerebellum and English grammatical morphology: evidence from production, comprehension, and grammaticality judgements. *J Cogn Neurosci*. 2004;16(7):1115–30.
159. Mariën P, Baillieux H, De Smet HJ, Engelborghs S, Wilsens I, Paquier P, et al. Cognitive, linguistic and affective disturbances following a right superior cerebellar artery infarction: a case study. *Cortex*. 2009;45:527–36.
160. Silveri MC, Leggio MG, Molinari M. The cerebellum contributes to linguistic production: a case of agrammatic speech following a right cerebellar lesion. *Neurology*. 1994;44:2047–50.
161. Adamaszek M, Strecker K, Kessler C. Impact of cerebellar lesion on syntactic processing evidenced by event-related potentials. *Neurosci Lett*. 2012;12(2):78–82.
162. Leiner HC, Leiner AL, Dow RS. Cognitive and language functions of the human cerebellum. *Trends Neurosci*. 1993;16:444–47.
163. Friederici AD. Neural basis of syntactic processes. In: Gazzaniga MS, editor. *The cognitive neurosciences*. Plaats van uitgave: MIT Press; 2004. p. 789–801.
164. Kotz SA, Schwartze M. Cortical speech processing unplugged: a timely subcortico-cortical framework. *Trends Cogn Sci*. 2010;14:392–99.
165. Ullman MT. A neurocognitive perspective on language: the declarative/procedural model. *Nat Rev Neurosci*. 2001;2(10):717–26.
166. Strick PL, Dum RP, Fiez JA. Cerebellum and nonmotor function. *Ann Rev Neurosci*. 2009;32:413–34.
167. Strelnikov K, Vorobyev VA, Chernigovskaya TV, Medvedev SV. Prosodic clues to syntactic processing – a PET and ERP study. *NeuroImage*. 2006;29:1127–34.
168. Aso K, Hanokawa T, Aso T, Fukuyama H. Cerebro-cerebellar interactions underlying temporal information processing. *J Cogn Neurosci*. 2010;22(12):2913–25.
169. Fridrikson J, Morrow L. Cortical activation and language task difficulty in aphasia. *Aphasiology*. 2005;19:239–50.
170. Witt K, Nühsman A, Deuschl G. Intact artificial grammar learning in patients with cerebellar degeneration and advanced Parkinson’s disease. *Neuropsychologia*. 2002;40(9):1534–40.
171. Hagoort P. How the brain solves the binding problem for language: a neurocomputational model of syntactic processing. *NeuroImage*. 2003;20:Suppl18–29.
172. Akkal D, Dum RP, Strick PL. Supplementary motor area and presupplementary motor area: targets of basal ganglia and cerebellar output. *J Neurosci*. 2007;27:10659–73.

173. Timmann D, Drepper J, Frings M, Maschke M, Richter S, Gerwig M, et al. The human cerebellum contributes to motor, emotional and cognitive associative learning. A review *Cortex*. 2009;46(7):845–57.
174. Mariën P, Saerens J, Nanhoe R, Moens E, Nagels G, Pickut BA, et al. Cerebellar induced aphasia: case report of cerebellar induced prefrontal aphasic language phenomena supported by SPECT findings. *J Neurol Sci*. 1996;144:34–43.
175. Mariën P, Engelborghs S, Pickut B, De Deyn PP. Aphasia following cerebellar damage: fact or fallacy? *J Neurolinguist*. 2000;13:145–71.
176. Cook M, Murdoch B, Cahill L, Whelan B. Higher-level language deficits resulting from left primary cerebellar lesions. *Aphasiology*. 2004;18:771–84.
177. Murdoch B, Whelan BM. Language disorders subsequent to left cerebellar lesions: a case for bilateral cerebellar involvement in language? *Folia Phoniatri Logop*. 2007;59:184–9.
178. Frank B, Schoch B, Hein-Kropp C, Hövel M, Gizewski E, Kamath HO, et al. Aphasia, neglect and extinction are no prominent clinical signs in children and adolescents with acute surgical cerebellar lesions. *Exp Brain Res*. 2008;184:511–9.
179. Richter S, Schoch B, Kaiser O, Groetschel H, Hein-Kropp C, Maschke M, et al. Children and adolescents with chronic cerebellar lesions show no clinically relevant signs of aphasia or neglect. *J Neurophysiol*. 2005;94:4108–20.
180. Frank B, Maschke M, Groetschel H, Berner M, Schoch B, Hein-Kropp C, et al. Aphasia and neglect are uncommon in cerebellar disease: negative findings in a prospective study in acute cerebellar stroke. *Cerebellum*. 2010;9:556–66.
181. Molinari M, Leggio M, Silveri M. Verbal fluency and agrammatism. In: Schmahmann JD, editor. *The cerebellum and cognition*. New York: Academic Press; 1997. p. 325–39.
182. Fiez JA, Petersen SE, Cheney MK, Raichle ME. Impaired nonmotor learning and error detection associated with cerebellar damage. *Brain*. 1992;115:155–78.
183. Leggio MG, Solida A, Silveri M, Gainotto G, Molinari M. Verbal fluency impairments in patients with cerebellar lesions. *Soc Neurosci Abst*. 1995;21:917.
184. Baillieux H, De Smet HJ, Lesage G, Paquier PF, Mariën P. Neurobehavioral alterations in an adolescent following posterior fossa tumor resection. *Cerebellum*. 2006;5:289–95.
185. Zettin M, Cappa SF, D'Amico A, Rago R, Perino C, Perani D, et al. Agrammatic speech production after a right cerebellar haemorrhage. *Neurocase*. 1997;3:375–80.
186. Hassid E. A case of language dysfunction associated with cerebellar infarction. *J Neurorehab Neural Repair*. 1995;9:157–62.
187. Molinari M, Leggio M, Solida A, Ciorra R, Misciagna S, Silveri M, et al. Cerebellum and procedural learning: evidence from focal cerebellar lesions. *Brain*. 1997;120:1753–62.
188. Burk K. Cognition in hereditary ataxia. *Cerebellum*. 2007;6:280–6.
189. Hubrich-Ungureanu P, Kaemmerer N, Henn FA, Braus DF. Lateralized organization of the cerebellum in a silent verbal fluency task: a functional magnetic resonance imaging study in healthy volunteers. *Neurosci Letters*. 2002;319:91–4.
190. Mariën P, de Smet E, de Smet HJ, Wackenier P, Dobbeleir A, Verhoeven J. “Apraxic dysgraphia” in a 15-year-old left-handed patient: disruption of the cerebello-cerebral network involved in the planning and execution of graphomotor movements. *Cerebellum*. 2013;12:131–9.
191. Fabbro F, Tavano A, Corti S, Bresolin N, De Fabritiis P, Borgatti R. Long-term neuropsychological deficits after cerebellar infarctions in two young adult twins. *Neuropsychologia*. 2004;42(4):536–45.
192. Moretti R, Torre P, Antonello RM, Carraro N, Zambito-Marsala S, Ukmar MJ, et al. Peculiar aspects of reading and writing performances in patients with olivopontocerebellar atrophy. *Percept Mot Skills*. 2002;94:677–94.
193. Mariën P, Verhoeven J, Brouns R, De Witte L, Dobbeleir A, De Deyn PP. Apraxic agraphia following a right cerebellar hemorrhage. *Neurology*. 2007;69(9):926–9.
194. De Smet HJ, Engelborghs S, Paquier PF, De Deyn PP, Mariën P. Cerebellar-induced apraxic agraphia: a review and three new cases. *Brain Cognition*. 2011;76(3):424–34.
195. Katanoda K, Yoshikawa K, Sugishita M. A functional MRI study on the neural substrates for writing. *Hum Brain Mapp*. 2001;13(1):34–42.
196. Silveri MC, Misciagna S, Leggio MG, Molinari M. Cerebellar spatial dysgraphia: further evidence. *J Neurol*. 1999;246(4):312–3.
197. Silveri MC, Misciagna S, Leggio MG, Molinari M. Spatial dysgraphia and cerebellar lesion: a case report. *Neurology*. 1997;48(6):1529–32.
198. Fournier del Castillo MC, Maldonado Belmonte MJ, Ruiz-Falcó Rojas ML, López Pino MA, Bernabeu Verdú J, Suárez Rodríguez JM. Cerebellum atrophy and development of a peripheral dysgraphia: a paediatric case. *Cerebellum*. 2010;9(4):530–6.
199. Frings M, Gaertner K, Buderath P, Christiansen H, Gerwig M, Hein-Kropp C, et al. Megalographia in children with cerebellar lesions and in children with attention-deficit/hyperactivity disorder. *Cerebellum*. 2010;9(3):429–32.
200. Rapcsak S, Beeson P. Agraphia. In: Crosson B, Rothi L, Nadeau S, editors. *Aphasia and language: theory and practice*. New York: Guilford; 2000. p. 184–220.
201. Haggard P, Jenner J, Wing A. Coordination of aimed movements in a case with unilateral cerebellar damage. *Neuropsychologia*. 1994;32:827–46.
202. Huey EB. *The psychology and pedagogy of reading*. New York: Macmillan; 1908.
203. Shaywitz BA, Skudlarski P, Holahan JM, Marchione KE, Constable RT, Fulbright RK, et al. Age-related changes in reading systems of dyslexic children. *Ann Neurol*. 2007;61(4):363–70.
204. Schlaggar BL, McCandliss BD. Development of neural systems for reading. *Annu Rev Neurosci*. 2007;30:475–503.
205. Pugh KR, Mencl WE, Jenner AR, Katz L, Frost SJ, Lee JR, et al. Neurobiological studies of reading and reading disability. *J Commun Disord*. 2001;34(6):479–92.
206. Berl MM, Duke ES, Mayo J, Rosenberger LR, Moore EN, VanMeter J, et al. Functional anatomy of listening and reading comprehension during development. *Brain Lang*. 2010;114(2):115–25.
207. Lindenberg R, Scheef L. Supramodal language comprehension: role of the left temporal lobe for listening and reading. *Neuropsychologia*. 2007;45(10):2407–15.
208. Ramnani N. The primate cortico-cerebellar system: anatomy and function. *Nat Rev Neurosci*. 2006;7(7):511–22.
209. Balsters JH, Cussans E, Diedrichsen J, Phillips KA, Preuss TM, Rilling JK, et al. Evolution of the cerebellar cortex: the selective expansion of prefrontal-projecting cerebellar lobules. *NeuroImage*. 2010;49(3):2045–52.
210. Ito M. Opinion - control of mental activities by internal models in the cerebellum. *Nat Rev Neurosci*. 2008;9(4):304–13.
211. Ackermann H, Mathiak K, Riecker A. The contribution of the cerebellum to speech production and speech perception: clinical and functional imaging data. *Cerebellum*. 2007;6(3):202–13.
212. Desmond JE, Fiez JA. Neuroimaging studies of the cerebellum: language, learning and memory. *Trends Cogn Sci*. 1998;2(9):355–62.
213. Vlachos F, Papathanasiou I, Andreou G. Cerebellum and reading. *Folia Phoniatri Logo*. 2007;59(4):177–83.
214. Fulbright RK, Jenner AR, Mencl WE, Pugh KR, Shaywitz BA, Shaywitz SE, et al. The cerebellum's role in reading: a functional MR imaging study. *Am J Neuroradiol*. 1999;20:1925–30.
215. Doyon J, Penhune V, Ungerleider LG. Distinct contribution of the cortico-striatal and cortico-cerebellar systems to motor skill learning. *Neuropsychologia*. 2003;41(3):252–62.

216. Booth JR, Wood L, Lu D, Houk JC, Bitan T. The role of the basal ganglia and cerebellum in language processing. *Brain Res.* 2007;1133(1):136–44.
217. Maisog JM, Einbinder ER, Flowers DL, Turkeltaub PE, Eden GF. A meta-analysis of functional neuroimaging studies of dyslexia. In: Eden GF, Flower DL, editors. *Learning, skill acquisition, reading, and dyslexia*. Oxford: Blackwell; 2008. p. 237–59.
218. Vellutino FR, Fletcher JM, Snowling M, Scanlon DM. Specific reading disability (dyslexia): what have we learned in the past four decades? *J Child Psychol Psych.* 2004;45(1):2–40.
219. Shaywitz SE, Morris R, Shaywitz BA. The education of dyslexic children from childhood to young adulthood. *Annu Rev of Psychol.* 2008;59:451–75.
220. Stein JF. The magnocellular theory of developmental dyslexia. *Dyslexia.* 2001;7:12–36.
221. Nicolson RI, Fawcett AJ. Automaticity: a new framework for dyslexia research? *Cognition.* 1990;35(2):159–82.
222. Nicolson RI, Fawcett AJ, Dean P. Developmental dyslexia: the cerebellar deficit hypothesis. *Trends Neurosci.* 2001;24(9):508–11.
223. Pennington BF, Bishop DVM. Relations among speech, language, and reading disorders. *Annu Rev Psychol.* 2009;60:283–306.
224. Nicolson RI, Fawcett AJ. Procedural learning difficulties: reuniting the developmental disorders? *Trends Neurosci.* 2007;30(4):135–41.
225. Stoodley CJ, Schmahmann JD. Evidence for topographic organization in the cerebellum of motor control versus cognitive and affective processing. *Cortex.* 2010;46(7):831–44.
226. Habas C, Kamdar N, Nguyen D, Prater K, Beckmann CF, Menon V, et al. Distinct cerebellar contributions to intrinsic connectivity networks. *J Neurosci.* 2009;29(26):8586–94.
227. Buckner RL, Krienen FM, Castellanos A, Diaz JC, Yeo BT. The organization of the human cerebellum estimated by intrinsic functional connectivity. *J Neurophysiol.* 2011;106(5):2322–45.
228. Thüring M, Kuper M, Stefanescu R, Maderwald S, Gizewski ER, Ladd ME, et al. Activation of the dentate nucleus in a verb generation task: a 7 T MRI study. *NeuroImage.* 2011;57(3):1184–91.
229. Snider R, Stowell A. Electro-anatomical studies on a tactile system in the cerebellum of monkey (*macaca mulatta*). *Anat Rec.* 1944;88:457.
230. Grodd W, Hulsmann E, Lotze M, Wildgruber D, Erb M. Sensorimotor mapping of the human cerebellum: fMRI evidence of somatotopic organization. *Hum Brain Mapp.* 2001;13(2):55–73.
231. Urban PP, Marx J, Hunsche S, Gawehn J, Vucurevic G, Wicht S, et al. Cerebellar speech representation: lesion topography in dysarthria as derived from cerebellar ischemia and functional magnetic resonance imaging. *Arch Neurol.* 2003;60(7):965–72.
232. Peeva MG, Guenther FH, Tourville JA, Nieto-Castanon A, Anton JL, Nazarian B, et al. Distinct representations of phonemes, syllables, and supra-syllabic sequences in the speech production network. *Neuroimage.* 2010;50(2):626–38.
233. Ackermann H, Vogel M, Petersen D, Poremba M. Speech deficits in ischaemic cerebellar lesions. *J Neurol.* 1992;239(4):223–7.
234. Schoch B, Dimitrova A, Gizewski ER, Timmann D. Functional localization in the human cerebellum based on voxelwise statistical analysis: a study of 90 patients. *NeuroImage.* 2006;30(1):36–51.
235. Stoodley CJ. The cerebellum and cognition: evidence from functional imaging studies. *Cerebellum.* 2012;11(2):352–65.
236. Jansen A, Floel A, Randenborgh JV, Konrad C, Rotte M, Forster AF, et al. Crossed cerebro-cerebellar language dominance. *Hum Brain Mapp.* 2005;24:165–72.
237. Carreiras M, Mechelli A, Estevez A, Price CJ. Brain activation for lexical decision and reading aloud: two sides of the same coin? *J Cogn Neurosci.* 2007;19(3):433–44.
238. Filippi R, Richardson FM, Dick F, Leech R, Green DW, Thomas MS, et al. The right posterior paravermis and the control of language interference. *J Neurosci.* 2011;31(29):10732–40.
239. Schmahmann JD. Dysmetria of thought. Clinical consequences of cerebellar dysfunction on cognition and affect. *Trends Cogn Sci.* 1998;2:362–70.
240. Schmahmann JD. The role of the cerebellum in affect and psychosis. *J Neurolinguist.* 2000;13:189–214.
241. Schmahmann JD. The role of the cerebellum in cognition and emotion: personal reflections since 1982 on the dysmetria of thought hypothesis, and its historical evolution from theory to therapy. *Neuropsychol Rev.* 2010;20:236–60.
242. Brodal P. *The central nervous system*. Oxford: Oxford University Press; 2010. p. 343–61.
243. Habas C. Functional imaging of the deep cerebellar nuclei: a review. *Cerebellum.* 2010;9:22–8.
244. Küper M, Thüring M, Maderwald S, Ladd ME, Timmann D. Structural and functional magnetic resonance imaging of the human cerebellar nuclei. *Cerebellum.* 2012;11:314–24.
245. Diedrichsen J, Maderwald S, Küper M, Thüring M, Rabe K, Gizewski ER, et al. Imaging the deep cerebellar nuclei in humans: a probabilistic atlas and normalization procedure. *NeuroImage.* 2011;54:1786–94.
246. Maderwald S, Thüring M, Küper M, Theysohn N, Müller O, Beck A, Aurich V, Ladd ME, Timmann D. Direct visualization of cerebellar nuclei in patients with focal cerebellar lesions and its application for lesion-symptom mapping. *NeuroImage;* 2012 [Epub ahead of print].
247. Küper M, Thüring M, Stefanescu R, Maderwald S, Roths J, Elles HG, Ladd ME, Diedrichsen J, Timmann D. Evidence for a motor somatotopy in the cerebellar dentate nucleus—an fMRI study in humans. *Hum Brain Mapp.* 2011. [Epub ahead of print].
248. Dum RP, Strick PL. An unfolded map of the cerebellar dentate nucleus and its projections to the cerebral cortex. *J Neurophysiol.* 2003;89:634–9.
249. Petersen SE, Fox PT, Posner MI, Mintun M, Raichle ME. Positron emission tomographic studies of the processing of single words. *J Cognit Neurosci.* 1989;1:153–70.
250. Raichle ME, Fiez JA, Videen TO, MacLeod AM, Pardo JV, Fox PT, et al. Practice-related changes in human brain functional anatomy during nonmotor learning. *Cereb Cortex.* 1994;4:8–26.
251. Lechtenberg R, Gilman S. Speech disorders in cerebellar disease. *Ann Neurol.* 1978;3:285–90.
252. Stoodley CJ, Desmond JE, & Schmahmann JD. Functional topography of the human cerebellum revealed by functional neuroimaging studies. *Tijdschrift. Jaartal;* in Press.
253. Schmahmann JD. The cerebellar cognitive affective syndrome: clinical correlations of the dysmetria of thought hypothesis. *Int Rev Psychiatr.* 2001;13:313–22.
254. Schmahmann JD. Disorders of the cerebellum: ataxia, dysmetria of thought, and the cerebellar cognitive affective syndrome. *J Neuropsych Clin N.* 2004;16:367–78.
255. Stoodley CJ, Stein JF. Cerebellar function in developmental dyslexia. *Cerebellum.* 2013;12(2):267–76.
256. Courchesne E, Allen G. Prediction and preparation, fundamental functions of the cerebellum. *Learn Memory.* 1997;4(1):1–35.
257. Ivry RB, Spencer RM, Zelaznik HN, Diedrichsen J. The cerebellum and event timing. *Ann NY Acad Sci.* 2002;978:302–17.
258. Salmi J, Pallesen KJ, Neuvonen T, Brattico E, Korvenoja A, Salonen O, et al. Cognitive and motor loops of the human cerebro-cerebellar system. *J Cognitive Neurosci.* 2009;22(11):2663–76.
259. Frings M, Dimitrova A, Schom CF, Elles HG, Hein-Kropp C, Gizewski ER, et al. Cerebellar involvement in verb generation: an fMRI study. *Neurosci Lett.* 2006;409:19–23.

260. Schmahmann JD, Doyon J, Toga A, Petrides M, Evans A. *MRI Atlas of the Human Cerebellum*. San Diego: Academic Press; 2000.
261. Schmahmann JD, Macmore J, Vangel M. Cerebellar stroke without motor deficit: clinical evidence for motor and non-motor domains within the human cerebellum. *Neuroscience*. 2009;162:852–61.
262. Diedrichsen J, Balsters JH, Flavell J, Cussans E, Ramnani N. A probabilistic MR atlas of the human cerebellum. *NeuroImage*. 2009;46:39–46.
263. Murdoch BE, Chenery HJ, Stokes PD, Hardcastle WJ. Respiratory kinematics in speakers with cerebellar disease. *J Speech Hear Res*. 1991;34:768–80.
264. Cannito MP, Marquardt TP. Ataxic dysarthria. In: McNeil MR, editor. *Clinical management of sensorimotor speech disorders*. New York: Thieme; 2009. p. 132–51.
265. Kent RD, Kent JF, Duffy JR, Thomas JE, Weismer G, Stuntebeck S. Ataxic dysarthria. *J Speech Lang Hear R*. 2000;43:1275–89.
266. Ogar J, Slama H, Dronkers N, Amici S, Gorno-Tempini ML. Apraxia of speech: an overview. *Neurocase*. 2005;11:427–32.