



Case Report

Contact lenses for visual rehabilitation in Bilateral Nanophthalmos with Retinal Dystrophy- A case report

Asik Pradhan¹, Sanjeeb Bhandari¹, Purushottam Dhungana¹, Raju Kaiti²

¹Tilganga Institute of Ophthalmology

²Department of Ophthalmology, Dhulikhel Hospital

Abstract

Background: Nanophthalmos is an uncommon developmental ocular disorder characterized by a small eye with short axial length, high hyperopia and high lens to eye volume ratio due to arrested development of the globe in all directions. Different types of fundus changes can rarely occur with nanophthalmos. **Observations:** This is a case report of a 17 years old female who presented with bilateral gradual progressive visual loss and photophobia at Tilganga Institute of Ophthalmology on 3rd July 2015. Her best corrected visual acuity was 20/300 with +12.00Ds/-1.00Dcyl@180 in the right eye and 20/200 with +12.00Ds/-1.50Dcyl@180 in the left eye. Axial lengths of two eyes were markedly shortened with pigmentary changes at the macula and dull foveal reflex along with retinal flecks in the mid-periphery. Full field ERG showed diminished rod and cone waves suggestive of rod and cone dysfunction. With the use of Rigid Gas Permeable (RGP) contact lenses, the acuity improved to 20/200 and 20/125 in the right and left eye respectively. **Conclusion:** This study proposes the use of contact lenses and light absorptive filters for better visual rehabilitation.

Keywords: Nanophthalmos, RGP contact lens

Introduction

Nanophthalmos is a rare bilateral genetic disease, included in the spectrum of developmental eye disorders, characterized by a small eye secondary to compromised growth (Sundin OH et al., 2008). Nanophthalmos is derived from the Greek word *nano*, meaning dwarf, and nanophthalmic eyes typically present very high to extreme axial hyperopia without other obvious structural defects (O'Grady RB, 1971; Cross & Yoder, 1976). Warburg (1981, 1993) defined nanophthalmos or pure microphthalmos

as a developmental arrest of ocular growth not associated with other ocular malformations. Later, it was underscored that nanophthalmos was a form of total microphthalmos, where both anterior and posterior segments are shortened. This occurs after the foetal fissure has closed and without other major malformations. It is characterized by short axial length, usually less than 20.00mm, and extreme hyperopia with refractive error usually in the range of +8.00 to +25.00 dioptres (DS). Characteristic features include normal cornea to microcornea, shallow anterior chamber and high lens/globe ratio. Different fundusoscopic appearances have been shown in nanophthalmic eyes, including pigmentary changes from retinal flecks to bone spicules, bull's eye maculopathy, macular

Received: 07/03/16

Accepted: 06/06/16

Address for Correspondence

Asik Pradhan, Consultant Optometrist

Cornea & Contact Lens Unit

Tilganga Institute of Ophthalmology

G.P.O Box 561, Gaushala, Bagmati Bridge, Kathmandu, Nepal

Tel: 977-1-4493775, 4493684; Fax no: 977-1-4474937

Email: asik.pradhan@tilganga.org

hypoplasia, retinal and macular cysts, and papillomacular folds (Khan & Zafar 2009). The best corrected visual acuity is rarely better than 20/40. Patients with nanophthalmos in the present study had cycloplegic refraction, best corrected visual acuity assessments using ETDRS, slit-lamp and fundus examinations, intraocular pressure measurement, fundus photography and ultrasonographic examination using A-mode and B-mode. Full field ERG was carried out.

Case Report

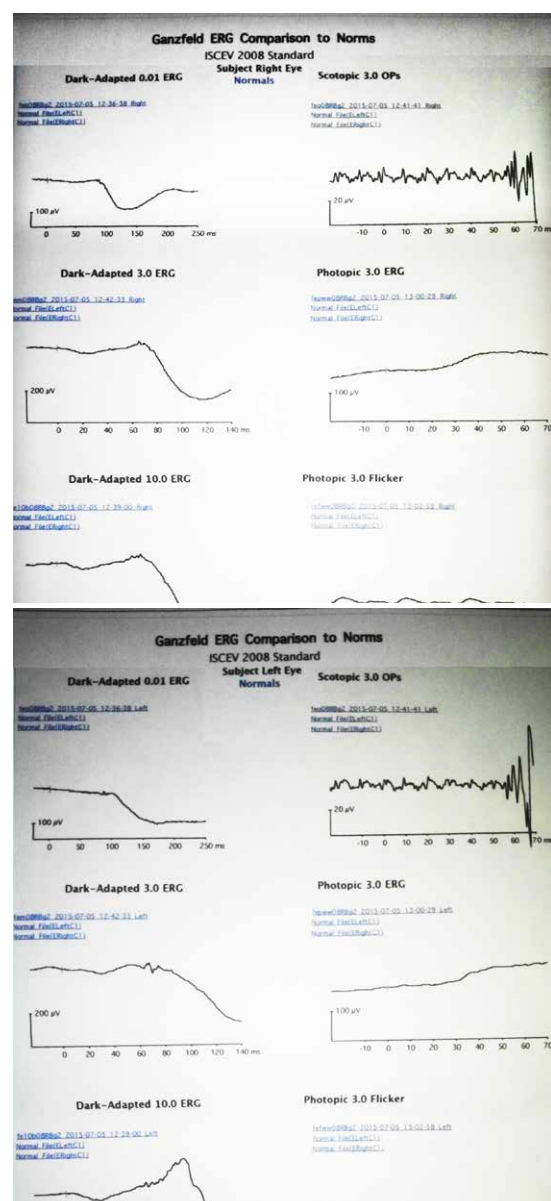
A 17 year old female complaining of bilateral decreased vision and photophobia presented with best corrected visual acuity was 20/300 with +12.00Ds/-1.00Dcyl@180 in the right eye and 20/200 with +12.00Ds/-1.50Dcyl@180 in the left eye. Her near acuities were N10 and N8@15 cms with average speed. Her axial lengths of two eyes were 17.84mms and 17.86mms in right and left eye respectively. On Ultrasonic Pachymetry, central corneal thicknesses of right and left eye were 527 microns and 534 microns, respectively. Her Keratometric findings were 7.70mm (43.75D)/7.85(43D) @180 in both eyes. Horizontal and vertical corneal diameters were 10mm and 10.2mms in right eye and 10.1mms and 10.30mms in left eye. And the vertical fissure heights were 12mms and 12.3mms in the two eyes respectively. The intraocular pressure so measured was 12mmHg OD, 14 mmHg OS. His anterior chambers were narrow (Grade II by Van Herick's method).

Fndoscopic examination showed small discs with sharp margins and pigmentary changes in the macular area with absent foveal reflex. Few retinal flecks were also present in the mid-periphery. The vasculature were unremarkable so as the retinal periphery.

Dark-adapted 0.001 ERG is responsible for rod initiated response recorded as b-wave. Similarly, Dark-adapted 3.0 ERG is responsible downhill a-wave and uphill b-wave representing photoreceptors and bipolar cells

activity respectively. Dark-adapted 10 ERG b-wave predominantly represent rod bipolar cell activity. Oscillatory potential simply represents the function of amacrine cells. Photopic 3.0 ERG and photopic 3.0 flicker represent cone function.

In above Full field ERG finding of right Eye, both rod and cone waves are diminished, representing dystrophy of both the rods and cones. In left eye, there is diminished rod response but there is minimal photopic response, suggesting rod-cone dystrophy.



OD

OS

Figure 1. Full-field ERG of Right & Left Eye



Management

Visual prognosis was explained to the patient. Small diameter Rigid Gas Permeable (F2 High Material) contact lenses were tried and best fit was achieved with a lens of Base curve(BC)-7.80mms, Total diameter(TD)-9.20mms, Optic Zone Diameter(OZD)-7.60mms, Back Vertex Power(BVP)- +13.50Ds. Her acuities so recorded after the contact lens intervention were 20/200 and 20/125 in the right and left eye respectively. Her near acuities were N10 and N8 @ 15cms with good speed. Along with it, a set of light absorptive filters were tried and among them she was very comfortable with the Dark Red filter (50%) for outdoors. She was advised to use contact lenses and dark red filter for outdoors. As for her hyperopic glasses correction she was advised to use High Index aspheric plastic lenses with a small round plastic frame with thick edges.

Discussion

Various macular lesions have rarely been associated with nanophthalmic eyes. Papillomacular folds and macular radial folds have been described (Serrano et al., 1998; Tay et al., 2007). Foveal avascular zone abnormalities in nanophthalmic eyes have been reported (Walsh & Goldberg 2007). Pigmentary retinal degeneration also rarely occurs with nanophthalmos (Proenca et al., 2006). This patient had photophobia especially outdoors under the sun. The macular lesions and white dots in the retina reported in this case also make an uncommon association. In similar case series study, A. Khan et.al; found that the patients with more than 18mm axial lengths did not have crowded discs, yellowish reflex or macular folds, which could be due to less crowding of the posterior segment. In contradiction, in our case there was no posterior segment crowding even when the axial lengths of the two eyes were less than 18mms. Early detection using ultrasonography of patients with high hyperopia may help in timely intervention

such as refractive correction, amblyopia therapy. The variety of retinal findings, in this case are rare features.

Contact lenses may offer a better mode of optical correction eliminating the aberrations and difficulties commonly encountered with high hyperopic correction such as thicker and magnifying lenses in cases of Nanophthalmos. The material used for this RGP was F2 high (Roflufocon E) with a Dk value of 100. These gas permeable materials would a better choice as with the increased thickness in hyperopic contact lenses also increases central thickness which may cause localized hypoxia of the corneal tissue as in soft hydrogel lenses.

Dark Red filter (50%) is an absorptive filter with 50% light transmittance only and lets in go only the longer wavelength i.e; it has transmission only above the wavelength of 570 nm and below this value other wavelengths are absorbed.

Small round plastic frames with High Index aspheric plastic lenses are ideal for improving the issues with weight, magnification and induced aberration in high hyperopic correction.

Conclusion

The above case highlights the fact that nanophthalmic patients may also present with retinal dystrophy. Vision may be affected in these patients due to high refractive amblyopia and any associated chorioretinal changes. Rigid Gas Permeable (RGP) contact lenses may provide a better functional visual outcome as compared to the usual spectacle correction. Light absorptive filter is a useful tool for helping people with photophobia.

References

- Cross HE, Yoder F (1976). Familial nanophthalmos. Am J Ophthalmol. 81(3): 300-306.
- Khan A, Zafar SN (2009). Variable retinal presentations in nanophthalmos. J Pak Med Assoc. 59(11): 791-793

O'Grady RB (1971). Nanophthalmos. *Am J Ophthalmol*. 71(6): 1251-1253.

Proenca H, Castanheira-Dinis A, Monteiro-Grillo M (2006). Bilateral nanophthalmos and pigmentary retinal dystrophy-an unusual syndrome. *Graefes Arch Clin Exp Ophthalmol*. 244(9): 1203-1205.

Serrano JC, Hodgkins PR, Taylor DS, Gole GA, Kriss A (1998). The nanophthalmic macula. *Br J Ophthalmol*. 82(3): 276-279.

Sundin OH, Dharmaraj S, Bhutto IA, et al. (2008). Developmental basis of nanophthalmos: MFRP is required for both postnatal ocular growth and postnatal emmetropization. *Ophthalmic Genet*. 29(1): 1-9.

Tay T, Smith JE, Berman Y, Ades L, Missotte I, Saglibene H, et al (2007). Nanophthalmos in a Melanesian population. *Clin Experiment Ophthalmol*. 35(4): 348-354.

Walsh MK, Goldberg MF (2007). Abnormal foveal avascular zone in nanophthalmos. *Am J Ophthalmol*. 143(6): 1067-1068.

Warburg M (1993). Classification of microphthalmos and coloboma. *J Med Genet*. 30(8): 664-669.

Warburg M (1981). Genetics of microphthalmos. *Int Ophthalmol*. 4(1-2): 45-65.

Source of support: nil. Conflict of interest: none