

Contrast Enhanced Ultrasound for the evaluation of Focal Liver Lesions in daily practice. A multicentre study

Ioan Sporea¹, Radu Badea², Alina Martie¹, Eugen Dumitru³, Simona Ioanițescu⁴, Roxana Șirli¹, Mihai Socaciu², Alina Popescu¹, Mirela Dănilă¹, Mihai Voiculescu⁴

¹ Department of Gastroenterology and Hepatology, University of Medicine and Pharmacy Timișoara, Romania

² Ultrasonography Department, 3rd Medical Clinic, University of Medicine and Pharmacy, Cluj-Napoca, Romania

³ Department of Gastroenterology, Faculty of Medicine Constanța, Romania

⁴ Department of Internal Medicine, Clinical Institute Fundeni, University of Medicine and Pharmacy Bucharest, Romania

Abstract

Background and aim: Development of contrast specific ultrasound techniques and introduction of the second-generation ultrasound contrast agents have improved the ability of this technique in detecting and characterizing focal liver lesions (FLLs). The purpose of this study was to present the experience of four Romanian centers in the evaluation of FLLs by contrast enhanced ultrasound (CEUS), in daily practice. **Materials and methods:** We performed a multicentre retrospective study, including 1,244 FLLs, evaluated by means of CEUS in four Romanian centers with extensive experience in ultrasound, during September 2009-December 2010. **Results:** This study included 1244 FLLs, both “de novo” (1,056 cases) and pre-existing (such as hepatocellular carcinomas evaluated after percutaneous treatment to assess the treatment results). In 1046/1244 of cases (84.1%), CEUS showed a typical pattern of enhancement (according to the EFSUMB Guidelines 2008), thus being sufficient for a correct and final diagnosis, while in 198/1244 of cases (15.9%), other methods of diagnosis were required, such as contrast CT/MRI or biopsy. In our study, CEUS established the benign or malignant nature of lesions in 1139/1244 of cases (91.5%). **Conclusion:** According to our results, CEUS could be the first imaging method of diagnosis for uncharacteristic FLLs detected by standard ultrasound, providing a correct classification in 84.1% of cases and a correct differentiation between benign/malignant lesions in 91.5% of cases. Thus, when faced with an uncharacteristic FLL on standard ultrasound, our local strategy is to perform CEUS as a first-line imaging investigation.

Keywords: Contrast Enhanced Ultrasound, focal liver lesions, multicentre study

Introduction

Contrast Enhanced Ultrasound (CEUS) is an imaging method currently used in daily practice, in many centers being the first technique used for the evaluation of Focal Liver Lesions (FLLs) discovered by standard ultrasound. After EFSUMB Guidelines regarding the use of CEUS [1] were published in 2004, then revised in 2008

[2], FLLs with typical contrast enhancement pattern can be easily classified. Thus, in the latter years, CEUS has become a reliable imaging method for the assessment of FLLs.

Two large prospective multicentre studies validated CEUS as a reliable method for the diagnosis of FLLs: the first one, performed under the auspices of the German Society of Ultrasound (DEGUM) [3] compares CEUS to liver biopsy, and the second one, performed by the French Society of Ultrasound, compares CEUS to contrast CT or MRI and/or liver biopsy [4]. Both studies showed good accuracy of CEUS for the characterization of FLLs, with accuracy ranging from 80 to 95% for different types of FLLs.

Recently, two multicentre German studies showed that for some FLLs, CEUS, multidetector - CT (MD-CT)

Received 20.03.2012 Accepted 10.04.2012

Med Ultrason

2012, Vol. 14, No 2, 95-100

Corresponding author: Ioan Sporea

Department of Gastroenterology and Hepatology,
University of Medicine and Pharmacy, Timișoara
13, Snagov str,
300482 Timișoara, Romania
Tel: +40-256-309455, Fax: +40-256-488003
E-mail: isporea@umft.ro

and contrast enhanced MRI (CE-MRI) have a similar diagnostic value [5,6]. Also, published studies demonstrated that by starting the evaluation of FLLs with CEUS, the cost of their investigation can be decreased [7,8].

Considering all these data, questions that can arise are: how useful is CEUS in daily practice for the evaluation of FLL and how often is this method able to make a final diagnosis and when is it necessary to perform another imaging technique?

The purpose of our study is to present a multicentre experience regarding the use of CEUS for the characterization of FLLs discovered on standard ultrasound examination and to find out when other expensive imaging methods, such as contrast enhanced CT or MRI, can be avoided.

Materials and methods

We performed a multicentre retrospective study, including 1244 FLLs, evaluated by CEUS in four Romanian centers with extensive experience in ultrasound, during September 2009-December 2010. There were both “de novo” (1,056 cases) and pre-existing lesions such as hepatocellular carcinomas evaluated after percutaneous treatment by means of percutaneous ethanol injection therapy (PEIT) and radiofrequency ablation (RFA), to assess the results of treatment.

The main purpose of our study was to evidence in which proportion of cases the final diagnosis can be obtained using only CEUS and how often CEUS can make a clear differential diagnosis between the benign and malignant enhancement pattern of lesions.

In all cases in which standard ultrasound was not sufficient for a correct diagnosis, we performed CEUS, interpreted according to the EFSUMB Guidelines [2]. A CEUS examination was considered conclusive for diagnosis if the FLL had a typical enhancement pattern after contrast injection during arterial, portal and late phases, according to the EFSUMB guidelines [2]. Following CEUS, we divided the patients in two groups: one in which CEUS evaluation was conclusive; and another in which CEUS was inconclusive and other diagnostic methods were performed (contrast CT or MRI, or biopsy of the lesion).

In addition, we divided our patients into two groups (a) a group of subjects without diffuse hepatic disease [excluded using clinical, biological, ultrasound and elastographic criteria (including transient elastography - TE and Acoustic Radiation Force Impulse elastography-ARFI)] and (b) a group of patients with chronic hepatopathies (liver cirrhosis or chronic hepatitis).

Exclusion criteria for performing CEUS were: subjects with acute cardiac infarction, class III/IV cardiac

insufficiency, cardiac rhythm disorders, and pregnant women. The study was approved by the Local Ethics Committee. After informed consent was obtained, CEUS was performed and all patients were monitored for adverse events, until two hours after the procedure.

A baseline US survey examination, including a color/power Doppler analysis, was performed. For CEUS examination, a very low mechanical index (< 0.08 MHz) was used for real-time imaging. Each examination lasted about 5 min after bolus injection of SonoVue® (Bracco, Italy) (a 2.4 ml bolus for each lesion to be characterized, via a 20-gauge intravenous catheter placed in the ante-cubital vein, and followed by 10 ml saline flush). To characterize the lesion, the hemodynamic behavior of SonoVue® enhancement (hypoenhancing, hyperenhancing, isoenhancing) during the arterial phase (15-30 seconds), portal venous (30-120 seconds) and late vascular phases (120-300 seconds), were evaluated. All sonographic examinations were digitally recorded.

The location and size of lesions were assessed on unenhanced and CEUS scans. Ultrasound diagnosis, in terms of the nature (malignant or benign) and type of the lesion (hemangiomas, focal nodular hyperplasia - FNH, liver adenoma, fatty liver alterations, hepatocellular carcinoma – HCC, or metastases) were based on SonoVue® enhanced US. Experienced physicians (level II or III in the EFSUMB classification: www.efsumb.org) evaluated all SonoVue® enhanced images, formulating a final diagnosis.

Data obtained from the patients were collected in a Microsoft Excel file, the statistical analysis being performed using the GraphPad Prism 5 program. Fisher’s exact test was used to compare proportions.

Results

In 1046/1244 of cases (84.1%), CEUS showed a typical enhancement pattern (according to EFSUMB Guidelines 2008), thus being sufficient for a correct and final diagnosis, while in 198/1244 of cases (15.9%), second line methods of diagnosis were required, such as contrast CT/MRI or biopsy of the lesion.

In our study, CEUS also established the benign and malignant nature of the lesion in 1139/1244 of cases (91.5%) (wash-out pattern in portal and/or late phases as a sign of malignancy according to the EFSUMB Guidelines 2008).

From the 1244 FLLs, 651 (52.3%) occurred in patients without known liver disease and 593 (47.7%) in patients with known chronic liver disease.

CEUS was conclusive for the diagnosis in 1046/1244 of cases (84.1%): in 493/593 (83.1%) of patients with

chronic liver disease and in 553/651 (84.9%) of patients without chronic liver disease.

For each center independently, the situation was as follows: conclusive for the diagnosis in center A: 542/693 (78.2%) vs. center B: 276/299 (92.3%) vs. center C: 134/147 (91.1%) vs. center D: 90/105 (85.7%), overall $p < 0.0001$ (A vs. B: $p < 0.0001$; A vs. C: $p = 0.0002$; A vs. D: $p = 0.09$; B vs. C: $p = 0.71$; B vs. C: $p = 0.5$; C vs. D: $p = 0.22$) (fig 1) and conclusive for the differentiation benign vs. malignant 613/693 (88.5%) in center A vs. 287/299 (96%) in center B vs. 139/147 (94.6%) in center C vs. 100/105 (95.2%) in center D, overall $p = 0.0002$ (A vs. B: $p = 0.001$, A vs. C: $p = 0.02$, A vs. D: $p = 0.04$; B vs. C: $p = 0.48$; B vs. C: $p = 0.78$; C vs. D: $p = 1$) (fig 2).

The main types of lesions found in patients without chronic liver disease (651 cases) were: metastasis (236 cases – 36.2 %), hemangiomas (147 cases – 22.6 %), FNH (44 cases – 6.8 %), focal fatty alterations (71 cases – 11 %), complex cysts (28 cases – 4.3%), adenomas (16 cases – 2.5%), abscesses (17 cases – 2.6%), cholangi-

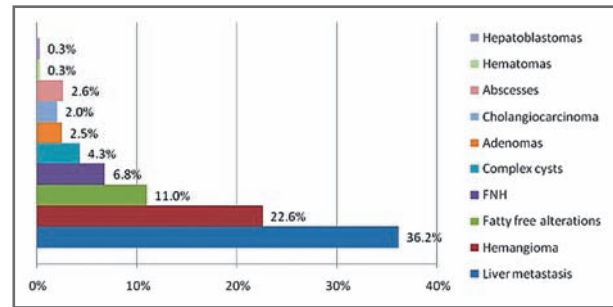


Fig 3. Types of lesions diagnosed by CEUS in patients without chronic liver disease

ocarcinomas (13 cases – 2%), hematomas (2 cases - 0.3 %), hepatoblastomas (2 cases – 0.3 %) and others (fig 3).

The most frequent inconclusive lesions at CEUS, in which the diagnosis was established by another method, were hepatocellular carcinomas (usually hypovascular), regenerative nodules and cholangiocarcinomas.

Discussions

EFSUMB formulated guidelines regarding the use of CEUS and the enhancement pattern of different FLLs [1,2]. Multicentric German [3] and French [4] studies have clearly demonstrated the value of CEUS for the diagnosis of incidental lesions discovered in the liver. The German study [3] included 1349 patients with FLLs discovered in standard US, and in which CEUS was compared with a diagnostic “gold standard”: biopsy in more than 75% of the lesions, spiral contrast CT or contrast MRI in the rest of the cases. In this study, the diagnostic accuracy of CEUS was 90.3%. CEUS correctly characterized 723/755 of the malignant lesions and 476/573 of the benign lesions, with 95.8% sensitivity and 83.1% specificity, with 95.4% PPV and 95.9% NPV for differentiating benign vs. malignant lesions.

The multicentre French study (STIC) [4] included 1034 FLL. CEUS was compared to contrast spiral CT, contrast MRI or liver biopsy, considered to be the “gold standard”. Standard US correctly diagnosed 62.4% of the cases, while CEUS increased the diagnostic performance to 86.1%. The diagnostic concordance between CEUS and the “gold standard” method was 73% (kappa=0.67), better for FLL on non-cirrhotic liver (73.5%, kappa=0.66), than in nodules on cirrhotic liver (71.8%, kappa=0.42).

In a study performed on a subgroup of patients from the DEGUM multicentre study, CEUS was compared to standardized spiral-CT (SCT) [5]. From the 267 patients, histological findings were available in 158 subjects. In

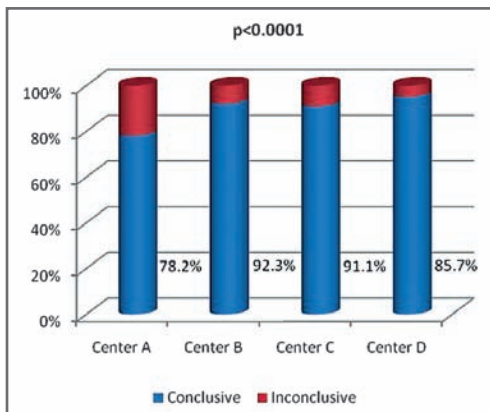


Fig 1. CEUS conclusive for the diagnosis

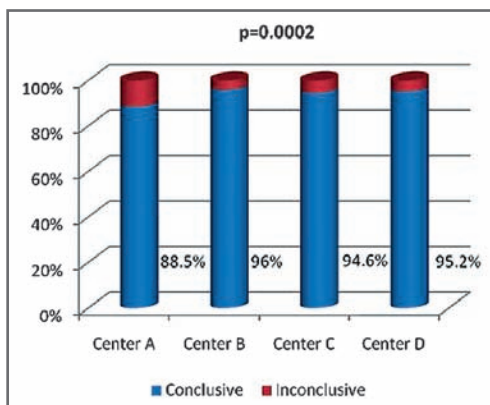


Fig 2. CEUS for the differentiation between benign and malignant FLL

this subgroup assessment of tumor differentiation with CEUS and SCT was concordant in 124 cases and discordant in 30 cases (CEUS/SCT: sensitivity 94.0/90.7%, specificity 83.0/81.5%, PPV 91.6/91.5%, NPV 87.5/80.0%, accuracy 90.3/87.8%). A statistically significant difference could not be established.

In a recently published study [6], also on a subgroup of patients from the DEGUM multicentre study, CEUS was compared to contrast MRI in 262 patients in which the definitive diagnosis in typical liver hemangioma and FNH was based on MRI as the “diagnostic gold standard”, on clinical evidence and additional follow-up (180 patients) or on histology (82 patients). Tumor differentiation was concordant in 56 (68.3%) cases and tumor entity in 44 cases (53.7%). There were no statistically proven differences between CEUS and MRI in this study.

Thus, all these studies demonstrated that CEUS is an accurate imaging method for FLLs characterization, comparable to contrast-CT and contrast-MRI. For this reason, in some centers [9,10] this method is the first line imaging method used for the evaluation of FLLs. In unclear lesions, a second line investigation is necessary. The advantages of this strategy are the lower price for the diagnosis of incidentally discovered FLLs [7,8] and the reduction of the time interval needed for a final diagnosis in clear CEUS cases.

We decided to perform this retrospective multicentre study in order to evaluate the relevance of this method in daily practice in Romania, in well trained centers in the field of ultrasound and CEUS. Ultrasound in Romania is well developed in some university centers, due to the long experience in using this method and, maybe, due to the fact that is performed mainly by clinicians (with indirect access to CT or MRI). On the other hand, our purpose was to discover if the accuracy of CEUS diagnosis is different or not among centers.

In our retrospective study, in patients with FLLs, in 1046/1244 of cases (84.1%), CEUS showed a typical enhancement pattern according to the EFSUMB Guidelines from 2008, already well known and accepted, thus being sufficient for a correct and final diagnosis, while in 198/1244 of cases (15.9%), other methods of diagnosis were required.

Another objective of our study was to find the value of CEUS for the differential diagnosis of benign vs. malignant FLLs. Some benign lesions such as hemangiomas, FNHs or fatty liver alterations are easily diagnosed, but sometimes it is quite difficult to formulate a correct diagnosis of hepatic adenoma [11]. On the other hand, published data showed that the sensitivities and specificities of CEUS for the diagnosis of hemangioma or FNH are very high: the accuracy of standard US for the diagnosis

of atypical hemangioma was 43%, while after SonoVue® it increased to 93% [11]. In another study, the sensitivities and specificities of CEUS for the diagnosis of focal nodular hyperplasia (FNH) and hemangioma were 100% and 87%, resulting in an accuracy of 94.5% [12].

In patients with liver cirrhosis or advanced fibrosis, we encountered difficulties for the correct CEUS diagnosis of some of the HCCs (usually small or well differentiated ones). The arterial enhancement is very often present, but the “wash out” in the portal or late phase can sometimes be not very evident, making the diagnosis of HCC difficult. The most difficult HCC to diagnose by means of CEUS is the hypovascular type, but it can be also misdiagnosed by MD-CT or CE MRI. A new MRI contrast agent (Gadoxetic acid- GD-EOB-DTPA) can overcome this problem [13]. Also, the diagnosis of cholangiocarcinoma is usually difficult with CEUS, published data showing that the accuracy was only 57% in a Chinese study [11] and 57.9% in the DEGUM study [3], so that other methods of diagnosis should be used for the final diagnosis.

A recently published multinational study [14] comprised 134 patients with one FLL detected in baseline ultrasound (US). Second line imaging methods included CEUS (n=134), contrast-enhanced CT (n=115) and/or dynamic contrast-enhanced MRI (n=70). Compared to CT and/or dynamic MRI, CEUS was 30.2% more sensitive in the recognition of malignancy and 16.1% more specific in the exclusion of malignancy and overall 22.9% more accurate. In our study also CEUS proved to be a very useful method that allowed the differentiation between benign or malignant FLLs, with only 10% unsuccessful examinations.

In a study performed in 11 centers in China [11], 148 patients with 164 lesions were evaluated. The final diagnosis in malignant lesions was based on liver biopsy as the gold standard in 129/164 cases. CEUS accuracy versus the gold standard was markedly higher (88%) than that of the fundamental ultrasound (41%) ($p < 0.01$). Probably this is the main indication of CEUS: after a basic US examination in which a FLL is discovered and where the diagnosis is not clear, SonoVue examination should be performed immediately. In conclusive examinations (hemangiomas, FNHs, liver metastases or some of the HCCs), no other investigations are required. In inconclusive cases, a second line imaging method should be performed.

In a large study, that included 452 patients with 452 undetermined lesions by baseline US, Quaiia et al [15] reported that the diagnostic accuracy for FLLs characterization increased from 49% at baseline US examination to 85% after CEUS. After contrast, the sensitivity

and specificity increased from 53% and 41% to 83% and 95%, respectively.

All these studies are clearly in favor of CEUS as compared to standard US for the characterization of FLLs, increasing the sensitivity and specificity of the ultrasound method. On the other hand, other studies, such as the one performed by Trillaud et al [14], showed that CEUS is sometimes the best imaging method for the characterization of FLLs.

But, in daily practice, CEUS has some limitations: the acoustic window for liver visualization must be very good; also, the hepatic lesion must be well seen in standard US, in order to be able to perform CEUS evaluation. On the other hand, if more than one lesion is present in the liver, a new injection of contrast agent is needed for their characterization in every vascular phase (especially on a cirrhotic liver). Thus, we must underline that in real life not all FLLs can be evaluated by CEUS, only those that are well seen by standard ultrasound.

In all imaging methods, using specific contrast, the vascular pattern is essential for diagnosis. In a study based on the DEGUM multicentre trial [16] that assessed the value of tumor-specific vascularization pattern (such as wheel-spoke pattern and arterial hyperenhancement followed by iso-enhancement in the late phase in FNH, or a nodular peripheral enhancement and partial or complete fill-in pattern in hemangiomas, or late phase hypo-enhancement in metastases), it could be assessed in the majority of cases, but not in all, so that the diagnostic accuracy of CEUS was 83.1% for all benign lesions, 95.8% for all malignant lesions and 91.4% for liver metastases and 84.9% for HCCs.

The aim of our study was to show the real value of CEUS in daily practice, regarding the final diagnosis of FLLs (when typical CEUS enhancement pattern is present, after a clear visualization of the FLL in basic ultrasound) and this was obtained in 84.1% of cases. We found that the results can differ significantly between centers: overall $p < 0.0001$ (A vs. B: $p < 0.0001$; A vs. C: $p = 0.0002$; A vs. D: $p = 0.09$; B vs. C: $p = 0.71$; B vs. D: $p = 0.5$; C vs. D: $p = 0.22$) and this can be maybe due to the different protocols used for diagnosis, to the quality of the ultrasound machine and possibly, to the experience of the center or of the examiner [14]. The same significant differences were found between the performances of these centers for the differentiation between benign and malignant FLL: overall $p = 0.0002$ (A vs. B: $p = 0.001$, A vs. C: $p = 0.02$, A vs. D: $p = 0.04$; B vs. C: $p = 0.48$; B vs. D: $p = 0.78$; C vs. D: $p = 1$).

Regarding the ability of CEUS to discriminate between malignant or benign lesions, in our study we were able to make this differentiation in 91.5% of cases, based

on the wash out pattern in portal and/or late phases. Difficult to diagnose were the adenomas and also the differential diagnosis between HCC and cholangiocarcinoma proved to be challenging.

Since CEUS was conclusive for the diagnosis “only” in 84.1% of the cases, the question that can rise is why not send patients with a FLL discovered in routine ultrasound directly to MD-CT or CE-MRI? The first reason against MD-CT is radiation. Secondly, both CE-CT and CE-MRI are expensive and using CEUS as a first line imaging method has proved to be cost efficient [7,8,17,18]. Also, the waiting time before these expensive methods is a stressful event for patients. As compared to contrast CT and MRI, CEUS has the advantage of being safe (extremely rare allergic side effects, no radiation), well tolerated by the patient, less expensive and, sometimes, available at the time of the initial ultrasound detection of FLLs.

Conclusion

In our multicenter study, in experienced ultrasound departments, CEUS was conclusive for the final diagnosis in 84.1% of the FLLs and the benign or malignant character of a lesion was demonstrated in 91.5% of cases. Thus, when faced to an uncharacteristic FLL on standard ultrasound examination, the strategy in experienced CEUS centers is to perform this method as a first-line investigation and only in unclear cases to perform contrast enhanced CT or MRI (or liver biopsy). Despite significant differences between the performance of CEUS among centers, overall the accuracy of this method is good enough to be proposed as a first line examination of FLLs discovered by ultrasound examination.

Conflict of interest: none

References

1. Albrecht T, Blomley M, Bolondi L, et al. for the EFSUMB Study Group. Guidelines for the use of contrast agents in ultrasound. *Ultraschall Med* 2004; 25: 249 – 256.
2. Claudon M, Cosgrove D, Albrecht T, et al. Guidelines and good clinical practice recommendations for contrast enhanced ultrasound (CEUS). Update 2008. *Ultraschall Med* 2008; 29: 28 – 44.
3. Strobel D, Seitz K, Blank W, et al. Contrast-enhanced Ultrasound for the Characterization of Focal Liver Lesions- Diagnostic Accuracy in Clinical Practice (DEGUM multicenter trial). *Ultraschall Med* 2008; 29: 499 - 505.
4. Tranquart F, Le Gouge A, Correas JM, et al. Role of contrast-enhanced ultrasound in the blinded assessment of fo-

- cal lesions in comparison with MDCT and CEMRI: Results from a multicentre clinical trial. *EJC* 2008; suppl.6: 9-15.
5. Seitz K, Strobel D, Bernatik T, et al. Contrast-Enhanced Ultrasound (CEUS) for the characterization of focal liver lesions - prospective comparison in clinical practice: CEUS vs. CT (DEGUM multicenter trial). *Ultraschall Med* 2009; 30: 383-389
 6. Seitz K, Bernatik T, Strobel D, et al. Contrast-Enhanced Ultrasound (CEUS) for the Characterization of Focal Liver Lesions in Clinical Practice (DEGUM Multicenter Trial): CEUS vs. MRI - a Prospective Comparison in 269 Patients. *Ultraschall Med* 2010; 31: 492-499.
 7. Şirli R, Sporea I, Martie A, Popescu A, Dănilă M. Contrast Enhanced Ultrasound in focal liver lesions – a cost efficiency study. *Med Ultrason* 2010; 12: 280-285.
 8. Romanini L, Passamonti M, Aiani L, et al. Economic assessment of contrast-enhanced ultrasonography for evaluation of focal liver lesions: a multicentre Italian experience. *Eur Radiol* 2007; 17 Suppl 6: F99-106.
 9. Sporea I, Şirli R, Martie A, Popescu A, Danila M. How useful is Contrast Enhanced Ultrasound for the characterization of Focal Liver Lesions? *J Gastrointestin Liver Dis* 2010; 19: 393-398 .
 10. Sporea I, Badea R, Martie A, et al. Contrast Enhanced Ultrasound for the characterization of focal liver lesions. *Med Ultrason* 2011; 13: 38-44.
 11. Wang WP, Wu Y, Luo Y, et al. Clinical value of contrast-enhanced ultrasonography in the characterization of focal liver lesions: a prospective multicenter trial. *Hepatobiliary Pancreat Dis Int* 2009; 4: 370 – 376.
 12. Trillaud H, Bruel JM, Valette PJ, et al. Characterization of focal liver lesions with SonoVue®- enhanced sonography: International multicenter-study in comparison to CT and MRI. *World J Gastroenterol* 2009; 15: 3748-3756.
 13. Granito A, Galassi M, Piscalia F, et al. Impact of Gadoteric Acid (GD-EOB-DTPA)-Enhanced Magnetic Resonance on the non-invasive diagnosis of small hepatocellular carcinoma. *J Hepatol* 2011; S386: A968.
 14. Trillaud H, Bruel JM, Valette PJ, et al. Characterization of focal liver lesions with SonoVue®- enhanced sonography: International multicenter-study in comparison to CT and MRI. *World J Gastroenterol* 2009; 15: 3748-3756.
 15. Quaia E, Calliada F, Bertolotto, et al. Characterization of focal liver lesions with contrast-specific US modes and a sulfur hexafluoride-filled microbubble contrast agent: diagnostic performance and confidence. *Radiology* 2004; 232: 420-430.
 16. Strobel D, Seitz K, Blank W, et al. Tumor-specific vascularization pattern of liver metastasis, hepatocellular carcinoma, hemangioma and focal nodular hyperplasia in the differential diagnosis of 1,349 liver lesions in contrast-enhanced ultrasound (CEUS). *Ultraschall Med* 2009; 30: 376-378.
 17. Tranquart F, Correas JM, Ladam Marcus V, et al. Echographie de contraste temps reel dans la prise en charge diagnostique des lesions nodulaires hepatiques: evaluation des performances diagnostiques et de l'impact economique sur une etude multicentrique francaise. *J Radiol* 2009; 90: 109-122.
 18. Giesel FL, Delorme S, Sibbel R, Kauczor HU, Krix M. Contrast-enhanced ultrasound for the characterization of incidental liver lesions - an economical evaluation in comparison with multi-phase computed tomography. *Ultraschall Med.* 2009; 30: 259-268.