

# Control of Hemorrhage in Critical Femoral or Inguinal Penetrating Wounds—An Ultrasound Evaluation

Michael Blaivas, MD, RDMS; Stephen Shiver, MD; Matthew Lyon, MD, RDMS; Srikar Adhikari, MD

Section of Emergency Ultrasound,  
Department of Emergency Medicine,  
Medical College of Georgia, Augusta,  
Georgia USA

## Correspondence:

Michael Blaivas, MD, RDMS  
Department of Emergency Medicine  
Medical College of Georgia  
1120 15th Street, AF-2056  
Augusta, GA 30912-4007 USA  
E-mail: blaivas@pyro.net

**Keywords:** emergency medicine; emergency ultrasound; exsanguination; femoral artery injury; prehospital medicine; tactical medicine

## Abbreviations:

AA = abdominal aorta  
BMI = body mass index  
CFA = common femoral artery  
CI = confidence interval  
CIA = common iliac artery  
EIA = external iliac artery  
IIA = internal iliac artery

**Received:** 29 December 2005

**Accepted:** 06 March 2006

**Revised:** 06 March 2006

**Web publication:** 08 December 2006

## Abstract

**Introduction:** Exsanguination from a femoral artery wound can occur in seconds and may be encountered more often due to increased use of body armor. Some military physicians teach compression of the distal abdominal aorta (AA) with a knee or a fist as a temporizing measure.

**Objective:** The objective of this study was to evaluate if complete collapse of the AA was feasible and with what weight it occurs.

**Methods:** This was a prospective, interventional study at a Level-I, academic, urban, emergency department with an annual census of 80,000 patients. Written, informed consent was obtained from nine male volunteers after Institutional Research Board approval. Any patient who presented with abdominal pain or had undergone previous abdominal surgery was excluded from the study. Subjects were placed supine on the floor to simulate an injured soldier. Various dumbbells of increasing weight were placed over the distal AA, and pulsed-wave Doppler measurements were taken at the right common femoral artery (CFA). Dumbbells were placed on top of a tightly bundled towel roughly the surface area of an adult knee. Flow measurements at the CFA were taken at increments of 20 pounds. This was repeated with weight over the proximal right artery iliac and distal right iliac artery to evaluate alternate sites. Descriptive statistics were utilized to evaluate the data.

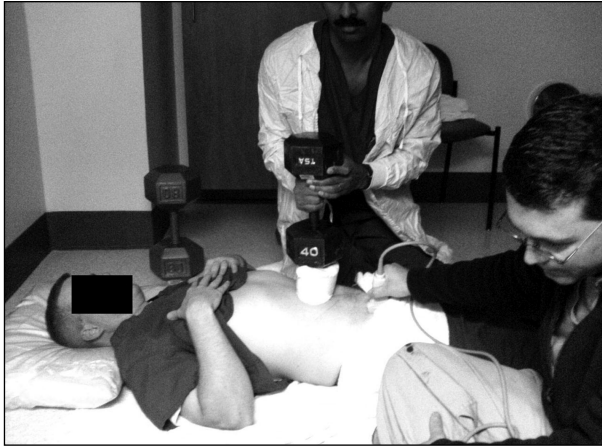
**Results:** The mean velocity through the CFA was 75.8 cm/sec at 0 pounds. Compression of the AA ranging 80 to 140 pounds resulted in no flow in the CFA. A steady decrease in mean flow velocity was seen starting with 20 pounds. Flow velocity decreased more rapidly with compression of the proximal right iliac artery, and stopped in all nine volunteers by 120 pounds of pressure. For all nine volunteers, up to 80 pounds of pressure over the distal iliac artery failed to decrease CFA flow velocity, and no subject was able to tolerate more weight at that location.

**Conclusion:** Flow to the CFA can be stopped completely with pressure over the distal AA or proximal iliac artery in catastrophic wounds. Compression over the proximal iliac artery worked best, but a first responder still may need to apply upward of 120 pounds of pressure to stop exsanguination.

Blaivas M; Shiver S; Lyon M; Adhikari S: Control of hemorrhage in critical femoral or inguinal penetrating wounds—An ultrasound evaluation. *Prehosp Disast Med* 2006;21(6):379–382.

## Introduction

Gunshot, shrapnel, and blast wounds are major causes of injury and death in law enforcement and military operations.<sup>1,2</sup> Sequential improvements in body armor have been made since the Vietnam War, and have helped to save many lives. However, wounds to the extremities can lead to rapid exsanguination.<sup>2</sup> This scenario was popularized through the media with the description of a soldier in the book and movie *Black Hawk Down*. In this case, an individual wearing body armor was protected adequately in his chest and abdomen, but suffered a gunshot wound high in his inguinal area.<sup>3</sup> Despite attempts to compress the bleeding site by other soldiers, the victim quickly exsanguinated.



Blaivas © 2006 Prehospital and Disaster Medicine

**Figure 1**—Volunteer with a 40-pound weight resting over the distal abdominal aorta. Blood flow is being measured in the right common femoral artery with a SonoSite Micromaxx.

Anecdotal reports from Special Forces medical instructors indicated that compression of the abdominal aorta (AA) to stop life-threatening bleeding in such wounds is taught as a final effort to save a soldier's life. This has implications in tactical medicine operations in which it may not be possible to remove patients from a scene quickly due to an austere location or because the scene has not been secured. Such a heroic effort may be the only way to keep a critically injured patient alive long enough to receive definitive care.

The success of such a maneuver in the battlefield has not been reported in the medical literature. However, case reports from obstetrical literature describe successful external compression of the AA in life-threatening hemorrhage after delivery.<sup>4-7</sup> One prospective study in the obstetrical literature also evaluated compression of the AA using the palms of healthy female volunteers. The loss of palpable pulses in the groin was achieved in a portion of the volunteers, but blood flow was not measured.

It is reasonable to postulate that compression of the AA may be difficult and requires accurate pressure placement of considerable force. This study sought to evaluate if complete compression of the AA was feasible, and the amount of pressure or weight that must be applied to stop distal blood flow. This study also evaluated if the use two alternate sites for compression may be more effective, i.e., the proximal common iliac artery and the distal external iliac artery near the inguinal ligament.

## Methods

This was a prospective, interventional study using human volunteers in a Level-I, urban hospital emergency department with an Emergency Medicine Residency Training Program. The emergency department has an annual census of 80,000 patients, and victims with gunshot wounds present frequently. Written informed consent was obtained from all subjects after Institutional Research Board approval. Nine healthy male volunteers served as subjects. Those subjects who were experiencing abdominal pain or who had previous abdominal surgery were excluded. Since most shrapnel or gunshot wound victims treated at the scene would not be treated on a hospital bed, sub-

jects were placed supine on the floor. For some comfort, the floor was covered with a thin blanket. Various dumbbells of increasing weight were placed over the distal AA, and pulsed wave Doppler measurements were taken at the right common femoral artery (CFA) (Figure 1). The dumbbells were placed on top of a tightly bundled towel that covered the surface area of an adult knee.

The CFA flow measurements were taken at 20-pound increments over the distal AA, starting at zero pounds. The dumbbell was lowered slowly onto the selected pressure area to avoid startling the volunteer into tightening his abdominal musculature. Subjects were allowed approximately one minute for recovery between increasing weights. Each subject was told they could ask for the weight to be removed immediately if it felt too uncomfortable. The same process was repeated with the weight placed over the proximal right iliac and distal right iliac artery to evaluate possible alternate sites of compression. Descriptive statistics were utilized to evaluate the data.

Blood flow evaluation was achieved using a SonoSite MicroMaxx with an L38e 10–5 MHz transducer. The common femoral artery was evaluated in real time in the long axis. Dual view capability allowed the artery to be visualized at the same time as the pulsed wave Doppler tracing was obtained. The operator maintained the common femoral artery in best view and obtained flow measurements in the center (Figure 2). Settings on the pulsed wave Doppler were optimized to allow high sensitivity for low flow states.

## Results

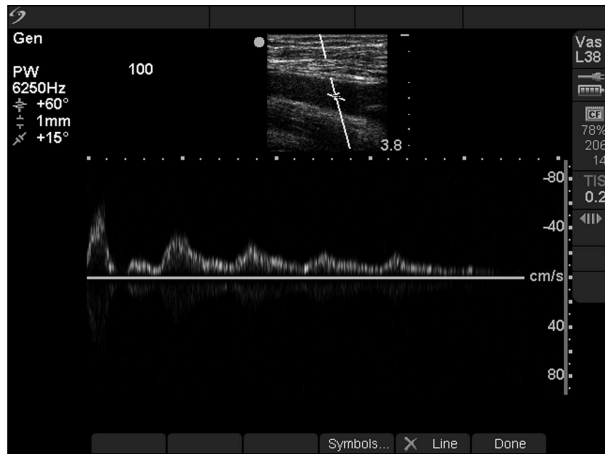
Nine subjects volunteered for this study. None of the volunteers asked to be excluded from the study. The mean height for the volunteers was 5.94 feet (1.84 meters) (95% CI 5.83–6.05 feet/1.78–1.84). The mean body weight was 194 pounds (88 kg) (95% CI 174.36–213.62 pounds (79.09–98.90 kg)). Body mass index calculation showed a mean BMI of 27.

The mean response to increasing weight over the distal AA is shown in Figure 3. Flow disappeared by 140 pounds (64 kg) in all volunteers. The range of weight at which flow disappeared was 80 to 140 pounds (36–64 kg). The mean value for the weights at which flow disappeared was 104.4 pounds (47 kg) (95% confidence interval (CI) = 78.1–130.8 pounds (35.4–59.3 kg)). When weight was placed over the proximal iliac artery, flow disappeared more rapidly; all volunteers lost all blood flow through the common femoral vein by 120 pounds (54 kg) (Figure 4). The mean value of the weights at which flow disappeared with pressure over the proximal iliac artery was 82 pounds (37 kg) (95% CI 62.7–101.7 pounds (28.4–46.1 kg)).

When weights were placed over the distal iliac artery flow, velocity increased. None of the subjects were able to tolerate pressure over the distal iliac artery until loss of blood flow. One subject tolerated up to 100 pounds. At that time, flow velocity was higher than at times with no compression.

## Discussion

Prior studies conducted by the military indicate that exsanguination can occur in as little as 45 seconds after gunshot wounds to the CFA, including partial transections of the vessel.<sup>8</sup> Media popularization aside, there is reason to believe that such wounds are becoming a more common source of mortal-



**Figure 2**—Tracing obtained at the common femoral artery with a 100-pound dumbbell being lowered slowly over the distal abdominal aorta. The Doppler tracing portion of the ultrasound image shows a sequentially decreasing size in the arterial velocity as more of the weight is allowed to rest on the abdomen. All traces of blood flow disappeared in this subject once the 100-pound weight was allowed to rest completely over the aorta.

ity than previously thought. One likely reason for this observation is the use of improved body armor by law enforcement and military personnel. Modern body armor is able to significantly minimize injury to the torso. Unfortunately, the extremities and inguinal areas remain exposed. In the past, victims would succumb quickly from severe shrapnel and projectile injuries to the chest and abdomen. With these sites better protected, injuries to other areas are more common. In addition, there is a possibility that when the lower abdomen is hit, some rounds from small arms may be deflected by body armor and impact the inguinal region.

Inguinal hemorrhage resulting from shrapnel and projectile injuries may be difficult to control in the field. Direct pressure techniques often are ineffective, as massive amounts of tissue destruction and torrential bleeding can make finding a particular point for effective compression nearly impossible. Given that exsanguination may occur quickly with such injuries, rapid hemorrhage control is of paramount importance. Applying pressure to arrest arterial inflow at a site remote from the injury focus remains an option.

The AA lies anterior to the vertebral column, and typically bifurcates at the level of the umbilicus. This site corresponds to the location of the fourth lumbar vertebra in the majority of adults. Following bifurcation, the common iliac artery (CIA) proceeds inferior and laterally into the pelvis. The CIA ends as it gives rise to the internal iliac artery (IIA) and the external iliac artery (EIA). The IIA supplies blood to the pelvic viscera as it courses deep within the pelvis. The EIA continues on an inferior and lateral course towards the lower extremity and becomes the CFA as it passes posterior to the inguinal ligament.

A study on healthy female volunteers simulating life-threatening obstetrical hemorrhages indicated that pulses palpated manually in a femoral artery were lost when a physician pressed the palm of their hand with all of their weight

just above the umbilicus.<sup>7</sup> However, pulses disappeared in only 55% of subjects, and it was impossible to determine exactly how much applied force was needed. Furthermore, while pulses may have been lost to manual palpation in some subjects, this cannot guarantee a lack of blood flow, as femoral pulses can be absent below a systolic pressure of 80 mmHg. It is possible that enough blood flow may remain to lead to a less rapid, but nonetheless progressive, exsanguination.

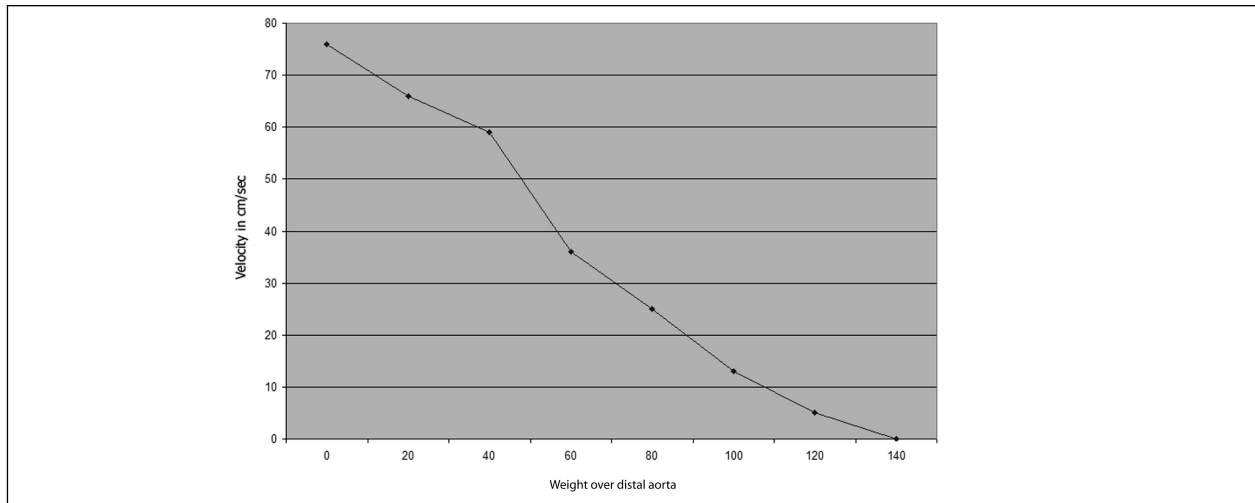
Compression points chosen for the current study included sites just proximal to the umbilicus in the midline, distal and slightly lateral to the umbilicus, and a site in the right lower quadrant. These topographical sites correspond to the distal aorta, proximal CIA, and EIA respectively. Results showed that complete cessation of blood flow occurred with compression overlying the distal aorta and proximal CIA. However, flow could not be halted by compressing the abdomen in the area overlying the EIA. These results may be explained by anatomic factors. Since the distal aorta and proximal CIA lie anterior to the vertebral column, compression at these sites is effective mechanically. Conversely, compression over the EIA is not as effective mechanically since its posterior border primarily is musculature.

The data indicate that mild pressure, created by leaning on the lower abdomen with the palm of the hand, probably is not sufficient to stop flow. In fact, a first responder likely must put more than half of his/her weight into the task. However, flow to the offending CFA can be stopped completely, with most alert patients able to tolerate the discomfort. No attempts to ascertain how long subjects could tolerate the compression were performed, but one could argue that with such catastrophic wounds, the procedure may save the life of the victim. Furthermore, some patients would be unconscious at the time, and would be unaware of any discomfort produced by the procedure.

Though it is clear that compression over the EIA is the least effective, it is not clear whether compression over the distal aorta or CIA is preferred. With regard to effort, compression over the CIA is preferred because less weight is required in order to cease femoral artery blood flow. A more difficult issue involves the status of blood flow to the contralateral extremity. Compression overlying the CIA preserves arterial inflow to the contralateral lower extremity, whereas compression overlying the aorta occludes it. A superficial analysis would conclude that preserving contralateral blood flow would be a benefit. However, many of these victims would be profoundly hypovolemic, and theoretically, the occlusion of contralateral lower extremity blood flow would increase central blood pressure and improve perfusion to key vital organs.

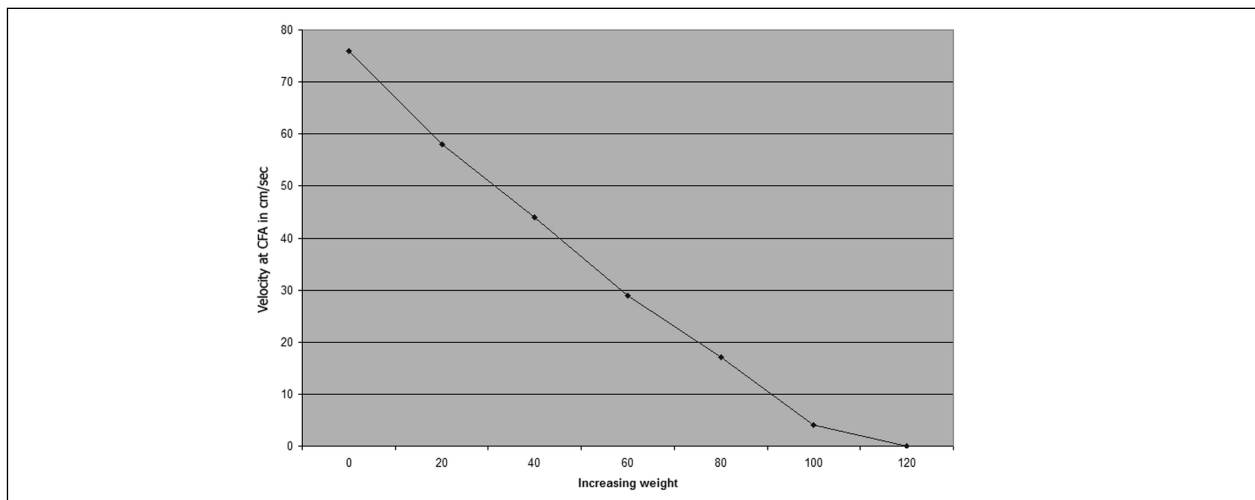
#### Limitations

There are a number of limitations to this study. It was performed on a few volunteers, none of whom were obese. Compression of the AA or iliac artery may be more difficult in obese subjects. However, first responders are less likely to encounter obese patients among military and law enforcement personnel than in the general population. As described, use of this technique may not immediately affect bleeding from a vein that may be injured along with an adjacent artery. Furthermore, it is unclear if venous pressure is elevated by the compression of the inferior vena cava, and



Blaivas © 2006 Prehospital and Disaster Medicine

**Figure 3**—Flow velocity at the common femoral artery in response to increasing weight placed on the distal abdominal aorta



Blaivas © 2006 Prehospital and Disaster Medicine

**Figure 4**—Flow velocity in the common femoral artery in response to increasing weight placed on the proximal common iliac artery

if such an elevation could lead to increased venous bleeding. The amount of time the volunteers could tolerate the compression was not measured. However, in a real-life situation, responders and victims would be motivated differently. Lastly, maintaining ongoing compression at a pressure equal to a 120-pound dumbbell may not only exhaust medical personnel, but also may commit them to continue to exert the pressure indefinitely. It may be helpful if a light-weight mechanical device able to be left alone once set in place, could achieve such compression.

#### References

1. Plani F, Bowley DM, Goosen J: Death and injury on duty—A study of South African police officers. *S Afr Med J* 2003;93:851–853.
2. Mabry RL, Holcomb JB, Baker AM, et al: United States Army Rangers in Somalia: An analysis of combat casualties on an urban battlefield. *J Trauma* 2000;49:515–528.
3. Mark Bowden: *Black Hawk Down*. Atlantic Monthly Press. New York, 1999.
4. Lucas WE: Postpartum hemorrhage. *Clin Obstet Gynecol* 1980;23:637–646.
5. Kelly JV: Postpartum hemorrhage. *Clin Obstet Gynecol* 1976;19:595–606.
6. Keogh J, Tsokos N: Aortic compression in massive postpartum haemorrhage—An old but lifesaving technique. *Aust N Z J Obstet Gynaecol* 1997;37:237–238.
7. Riley DP, Burgess RW: External abdominal aortic compression: A study of a resuscitation manoeuvre for postpartum haemorrhage. *Anaesth Intensive Care* 1994;22:571–575.
8. Acheson EM, Kheirabadi BS, Deguzman R, et al: Comparison of hemorrhage control agents applied to lethal extremity arterial hemorrhages in swine. *J Trauma* 2005;59(4):865–875.