

Conversion of Mild Cognitive Impairment to Alzheimer Disease Predicted by Hippocampal Atrophy Maps

Liana G. Apostolova, MD; Rebecca A. Dutton, BS; Ivo D. Dinov, PhD; Kiralee M. Hayashi, BS; Arthur W. Toga, PhD; Jeffrey L. Cummings, MD; Paul M. Thompson, PhD

Background: While most patients with mild cognitive impairment (MCI) transition to Alzheimer disease (AD), others develop non-AD dementia, remain in the MCI state, or improve.

Objective: To test the following hypotheses: smaller hippocampal volumes predict conversion of MCI to AD, whereas larger hippocampal volumes predict cognitive stability and/or improvement; and patients with MCI who convert to AD have greater atrophy in the CA1 hippocampal subfield and subiculum.

Design: Prospective longitudinal cohort study.

Setting: University of California–Los Angeles Alzheimer's Disease Research Center.

Patients: We followed up 20 MCI subjects clinically and neuropsychologically for 3 years.

Main Outcome Measure: Baseline regional hippocampal atrophy was analyzed with region-of-interest and 3-dimensional hippocampal mapping techniques.

Results: During the 3-year study, 6 patients developed

AD (MCI-c), 7 remained stable (MCI-nc), and 7 improved (MCI-i). Patients with MCI-c had 9% smaller left and 13% smaller right mean hippocampal volumes compared with MCI-nc patients. Radial atrophy maps showed greater atrophy of the CA1 subregion in MCI-c. Patients with MCI-c had significantly smaller hippocampi than MCI-i patients (left, 24%; right, 27%). Volumetric analyses showed a trend for greater hippocampal atrophy in MCI-nc relative to MCI-i patients (eg, 16% volume loss). After permutation tests corrected for multiple comparison, the atrophy maps showed a significant difference on the right. Subicular differences were seen between MCI-c and MCI-i patients, and MCI-nc and MCI-i patients. Multiple linear regression analysis confirmed the group effect to be highly significant and independent of age, hemisphere, and Mini-Mental State Examination scores at baseline.

Conclusions: Smaller hippocampi and specifically CA1 and subicular involvement are associated with increased risk for conversion from MCI to AD. Patients with MCI-i tend to have larger hippocampal volumes and relative preservation of both the subiculum and CA1.

Arch Neurol. 2006;63:693-699

Author Affiliations: Laboratory of Neuro Imaging (Drs Apostolova, Dinov, Toga, and Thompson and Mss Dutton and Hayashi), Department of Neurology (Drs Apostolova, Toga, Cummings, and Thompson), and Department of Psychiatry and Biobehavioral Sciences (Dr Cummings), The David Geffen School of Medicine at UCLA, and Department of Statistics (Dr Dinov), University of California–Los Angeles.

MILD COGNITIVE IMPAIRMENT (MCI) is an intermediate cognitive state between normal aging and dementia. Patients with amnesic MCI have memory decline while still enjoying functional lifestyles.^{1,2} Most patients with amnesic MCI transition to Alzheimer disease (AD), dementia with Lewy bodies, or vascular dementia, but some remain stable and others improve.³ Reversible MCI may be due to depression, adverse effects of medication, hormonal changes, or nonneurological conditions severe enough to affect cognition.⁴ Any improvement in our ability to predict the outcome of MCI would be invaluable for counseling patients, making therapeutic decisions, and planning clinical trials.⁵

Most amnesic MCI patients have AD pathology.^{6,7} In AD the pathology typically appears first in the entorhinal cortex, followed by the hippocampus and later the neocortex. Hippocampal atrophy correlates strongly with Braak and Braak pathological staging^{8,9} and cognitive decline,^{8,10,11} and predates conversion to MCI in the oldest old (≥ 85 years).¹²

The MCI outcomes correlate with annualized hippocampal atrophy rates. The annual atrophy rates for those who remain stable (MCI-nc) is 2.8% and for those who develop AD (MCI-c) is 3.7%. The latter is strikingly similar to the 3.5% to 4.0% observed in AD.^{13,14} Some researchers have found an association between smaller hippocampi and the observed annual conversion rate from MCI to AD,^{15,16} whereas oth-

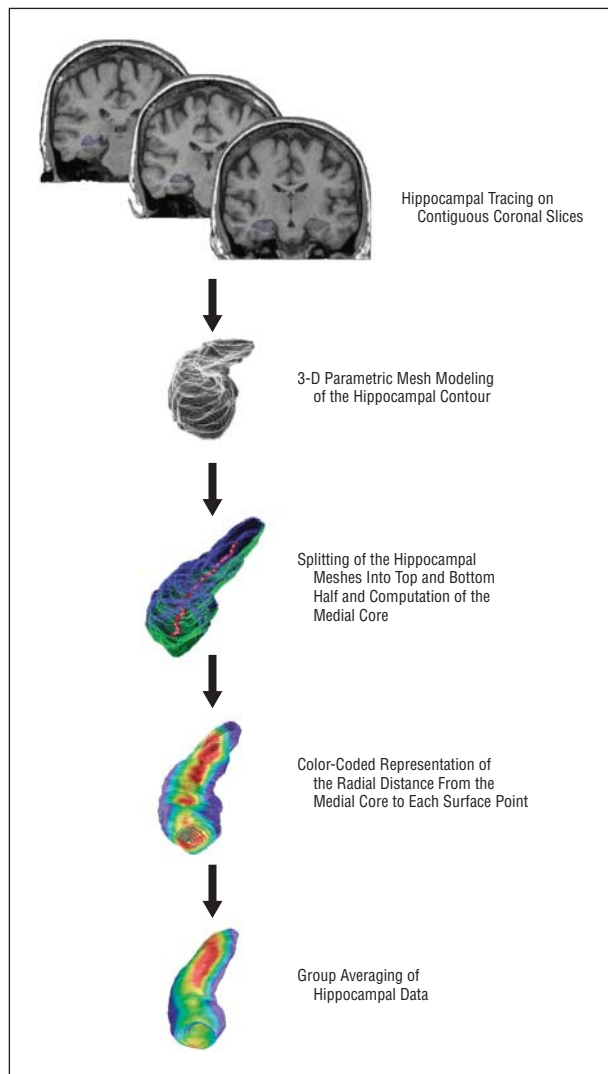


Figure 1. Schematic of the radial atrophy mapping method. 3-D indicates 3-dimensional.

ers have not.¹⁷⁻²⁰ Variable conversion rates, MCI sample heterogeneity, and variability in hippocampal volume may partly explain these conflicting results.

We analyzed hippocampal atrophy in MCI with a region-of-interest technique and a new hippocampal 3-dimensional (3-D) radial atrophy mapping approach²¹ assessing for subregional structural deformations. The technique has proved sensitive and reliable in several neurodegenerative,²¹⁻²³ developmental,^{24,25} and psychiatric^{26,27} disorders, as well as in normal brain development²⁸ and temporal lobe epilepsy.²⁹

METHODS

PATIENTS

All subjects were prospectively recruited at the University of California–Los Angeles Alzheimer’s Disease Research Center according to the restrictions and policies of the university’s institutional review board. We prospectively followed 20 amnesic MCI subjects prospectively for 3 years with detailed clinical and neu-

ropsychological examinations. We used the following inclusion criteria: age 55 to 90 years, cognitive complaint, memory decline of at least 1.5 SD below the age- and education-adjusted neuropsychological norms on at least 1 memory test (California Verbal Learning Test, second edition; Wechsler Memory Scale, third edition, logical memory and visual reproduction subtests; and Rey-Osterrieth Complex Figure delayed recall test), intact activities of daily living, no evidence of concurrent medical condition of sufficient severity to have an impact on cognition, no history of drug or alcohol abuse, and no concurrent psychiatric or other neurological illness. Patients underwent evaluation for depression with the Geriatric Depression Scale. Those who were clinically depressed (Geriatric Depression Scale score, >10), who had conditions precluding safe performance of magnetic resonance imaging, or who had baseline images acquired more than 6 months from the date of neuropsychological evaluation were excluded.

CLINICAL OUTCOME MEASURES

Three primary outcomes were defined: conversion to AD (MCI-c) according to the *Diagnostic and Statistical Manual of Mental Disorders*, fourth edition³⁰ and the National Institute of Neurological and Communicative Disorders and Stroke–Alzheimer’s Disease and Related Disorders Association criteria; cognitive improvement where patients no longer met criteria for MCI (MCI-i); and cognitive stability where they remained in the MCI category during the 3 years of follow-up (MCI-nc). Diagnosis was determined by consensus decision among neurologists, psychiatrists, and neuropsychologists who reviewed all available clinical and neuropsychological information.

IMAGING DATA ACQUISITION AND ANALYSIS

Imaging data were collected on a 1.5-T Signa magnetic resonance imaging scanner (GE Medical Systems, Milwaukee, Wis) with the following protocol: 3-D spoiled gradient coronal acquisition perpendicular to the long axis of the hippocampus, repetition time, 28 milliseconds; echo time, 6 milliseconds; field of view, 220 mm; 256 × 192 matrix; and slice thickness, 1.5 mm. Magnetic resonance images were scaled to match the ICBM53 (International Consortium for Brain Mapping) average brain imaging template using a 9-parameter linear transformation.³¹ Image nonuniformities due to magnetic field inhomogeneities were eliminated.³² Hippocampi were traced on contiguous coronal slices following a detailed, well-established protocol with high intrarater and interrater reliability.³³ When boundaries were ambiguous, a standard neuroanatomical atlas was consulted.³⁴ Tracings included the hippocampus proper, dentate gyrus, and subiculum. All traces were made in a blinded fashion with respect to the subjects’ age, sex, and cognitive outcome. Region-of-interest volumetric data were extracted and analyzed statistically.

The hippocampal contours were split into top and bottom components and transformed into 3-D parametric surface mesh models with normalized spatial frequency of the surface points within and across brain slices. This step ensures precise comparison of anatomy between subjects and groups at each hippocampal surface point. For each outcome group, we performed group averaging of hippocampal representations and recorded the variation between corresponding surface points. A medial core (central line threading down the long axis of the hippocampus) was computed for each hippocampus. Hippocampal radial distance measures (ie, the distance from the medial core to each point on the hippocampal surface model) were estimated. These values were used to generate individual distance maps that were combined across subjects to produce group average distance maps for comparing surface morphology between the groups.²¹ **Figure 1** summarizes these methods. The

Table 1. Demographic Data

Patient Groups	Age, Mean, y	Sex, No. M/F	Education, Mean, y	MMSE Score, Mean (SD)	
				Baseline	3-y Follow-up
MCI-c	68.3	4:2	15.6	27.8 (1.0)	24.8 (3.7)*
MCI-nc	72.7	4:3	15.8	28.9 (0.9)	27.6 (1.3)
MCI-i	75.1	2:5	15.7	28.3 (1.3)	28.7 (1.0)

Abbreviations: MCI, mild cognitive impairment; MCI-c, MCI that converted to Alzheimer disease; MCI-i, MCI that improved; MCI-nc, MCI that remained stable; MMSE, Mini-Mental State Examination.

* $P = .02$ for group comparison of MCI-c vs MCI-i patients and $P = .08$ for MCI-c vs MCI-nc (2-tailed t tests, pooled variances).

Table 2. Hippocampal ROI Volume Differences Between Groups

Patient Group Comparison	Difference, %	Volumetric Difference, Mean (SE), mm ³	95% Confidence Interval	t Test*		Tukey Test, P Value†
				t Statistic	P Value	
MCI-c vs MCI-nc						
Left	9	326.4 (130.1)	40 to 612	-2.51	.03	.52
Right	13	467.8 (219.2)	-15 to 950	-2.13	.06	.3
MCI-c vs MCI-i						
Left	24	1007.7 (356.9)	222 to 1793	-2.82	.02	.009
Right	27	1132.2 (334.4)	396 to 1868	-3.39	.006	.005
MCI-nc vs MCI-i						
Left	16	681.3 (325.5)	-28 to 1390	-2.09	.06	.07
Right	16	664.4 (327.7)	-49 to 1378	-2.03	.07	.09

Abbreviations: MCI, mild cognitive impairment; MCI-c, MCI that converted to Alzheimer disease; MCI-i, MCI that improved; MCI-nc, MCI that remained stable; ROI, region of interest.

*Indicates 2-sample t test with pooled variance. Statistically significant P values are indicated by boldface type.

†Indicates Tukey test adjusting for multiple comparisons. Statistically significant values are indicated by boldface type.

California Verbal Learning Test delayed recall scores were used as covariates to generate 3-D maps of cognitive correlations with atrophy.

STATISTICAL ANALYSES

The region-of-interest volumetric data were globally assessed for group effects using analysis of variance. Each group pair was first compared using the 2-sample t test with pooled variances, followed by a Tukey test correcting for multiple comparisons. Multiple linear regression analyses were performed controlling for group, age, and Mini-Mental State Examination score at baseline. The radial atrophy significance maps were subjected to permutation-based statistics using a threshold of $P < .01$ to ensure that the overall pattern of effects in the surface-based maps could not have been observed by chance alone.²¹

RESULTS

PRIMARY OUTCOME

Of the 20 MCI patients, 6 converted to AD (MCI-c), 7 remained stable (MCI-nc), and 7 improved (MCI-i). Demographic data are shown in **Table 1**. The follow-up Mini-Mental State Examination score after 3 years was significantly lower in MCI-c relative to MCI-i patients. The change in Mini-Mental State Examination score, over the 3-year follow-up interval, did not show a

significant correlation with hippocampal volumes assessed at baseline (left side, $r = -0.26$, $P = .26$; right side, $r = -0.33$, $P = .15$). These results did not change after stratification by MCI subgroup.

REGION-OF-INTEREST VOLUMETRIC ANALYSES

We found a significant group effect for the hippocampal volumes in our MCI cohort using analysis of variance (left side, $R^2 = 42\%$, $F = 6.06$, $P = .01$; right side, $R^2 = 45\%$, $F = 4.6$, $P = .006$). A multiple linear regression model with hippocampal volume as the dependent variable and age, group, and Mini-Mental State Examination score at baseline as the predictor variables was significant bilaterally (left side, $F = 6.05$, $P = .006$; right side, $F = 4.61$, $P = .02$). Of these predictors, only group membership was significantly associated with hippocampal volume (left side, $t = 4.06$, $P < .001$; right side, $t = 3.49$, $P = .003$).

Two-sample t -test statistics with pooled variance showed significant differences between MCI-c and MCI-nc patients in the left hippocampal volume and a trend for significance on the right. Significant bilateral differences were found between MCI-c and MCI-i patients. After correction for multiple comparisons, the MCI-c vs MCI-i volume differences remained significant, whereas the MCI-nc vs MCI-i differences showed a trend for significance (**Table 2**).

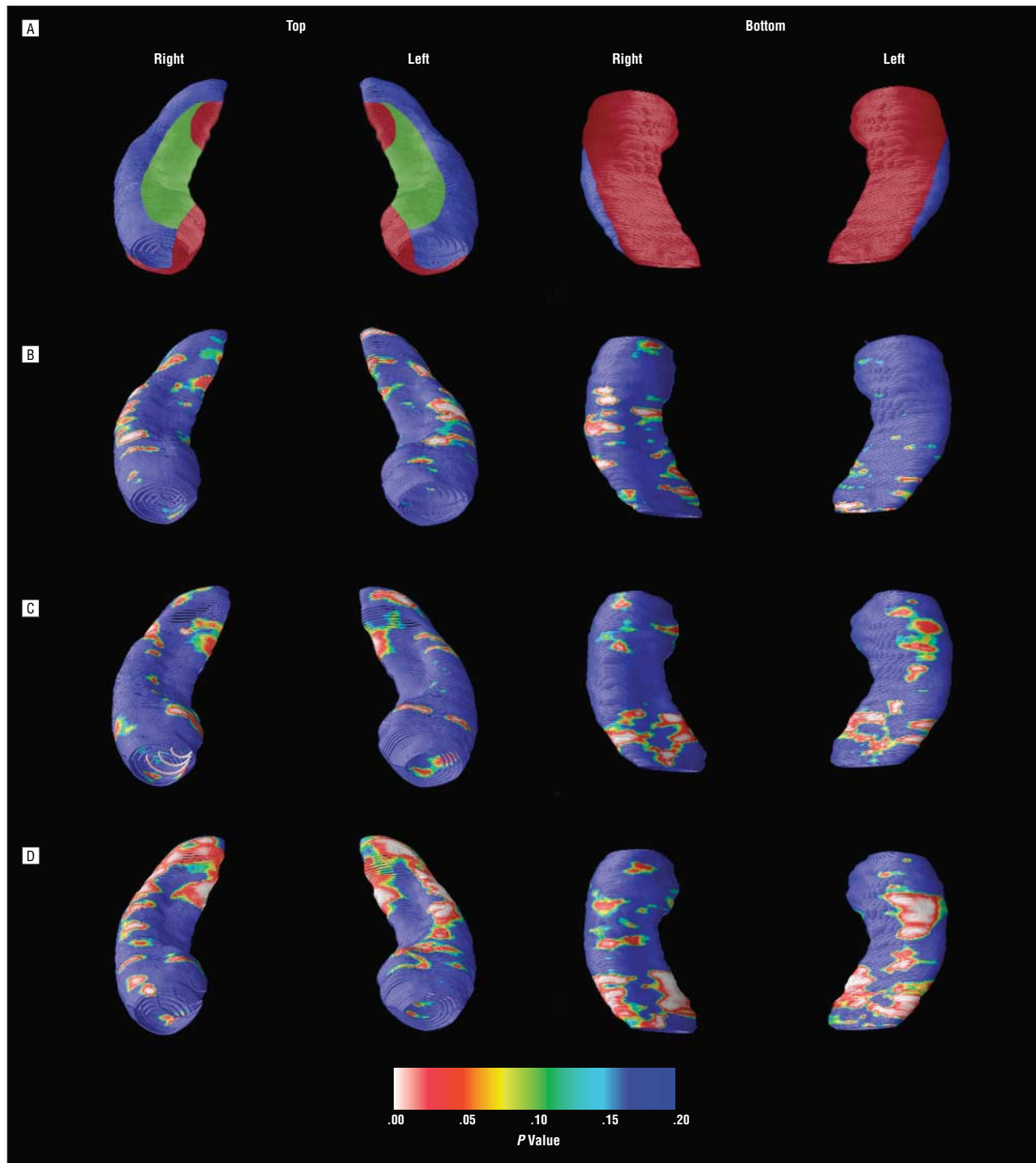


Figure 2. Hippocampal maps. A, Schematic representation of the hippocampal subfields is mapped onto the hippocampal surface (CA1 in blue, CA2 and CA3 in green, and subiculum in red). Definitions are based on Duvernoy³⁴ and West and Gundersen.³⁵ B-D, Statistical maps compare hippocampal radial atrophy between patients with mild cognitive impairment (MCI) that converted to Alzheimer disease (MCI-c) and those with stable MCI (MCI-nc) (B); between MCI-nc patients and patients with MCI that improved (MCI-i) (C); and between MCI-c and MCI-i patients (D).

RADIAL ATROPHY MAP

To better understand the anatomical distribution of radial atrophy, we consulted 2 well-established sources^{34,35} and demarcated the main hippocampal subfields on the hippocampal surface (**Figure 2A**). Statistical maps comparing the individual groups are shown in Figure 2B-D. We

subjected the maps to stringent multiple comparisons using permutation testing at a threshold of $P < .01$. The MCI-c and MCI-nc patients differed in the extent of involvement of the CA1 hippocampal subregion. The MCI-nc patients had significantly greater atrophy in the subicular region of the left and the CA1 region of the right hippocampus relative to MCI-i patients. The MCI-c patients showed signifi-

Table 3. Statistical Results From the 3-D Radial Atrophy Maps Corrected for Multiple Comparisons*

Patient Group Comparison	Left Hippocampus, <i>P</i> Values			Right Hippocampus, <i>P</i> Values		
	Dorsal Surface	Ventral Surface	Both Combined	Dorsal Surface	Ventral Surface	Both Combined
MCI-c vs MCI-nc	.12	.77	.45	.18	.42	.30
MCI-c vs MCI-i	.02	.007	.02	.009	.04	.02
MCI-nc vs MCI-i	.12	.01	.07	.04	.054	.049

Abbreviations: 3-D, 3-dimensional; MCI, mild cognitive impairment; MCI-c, MCI that converted to Alzheimer disease; MCI-i, MCI that improved; MCI-nc, MCI that remained stable; NS, not significant.

**P* values were determined by permutation testing with a threshold of $P < .01$. Statistically significant values are indicated by boldface type.

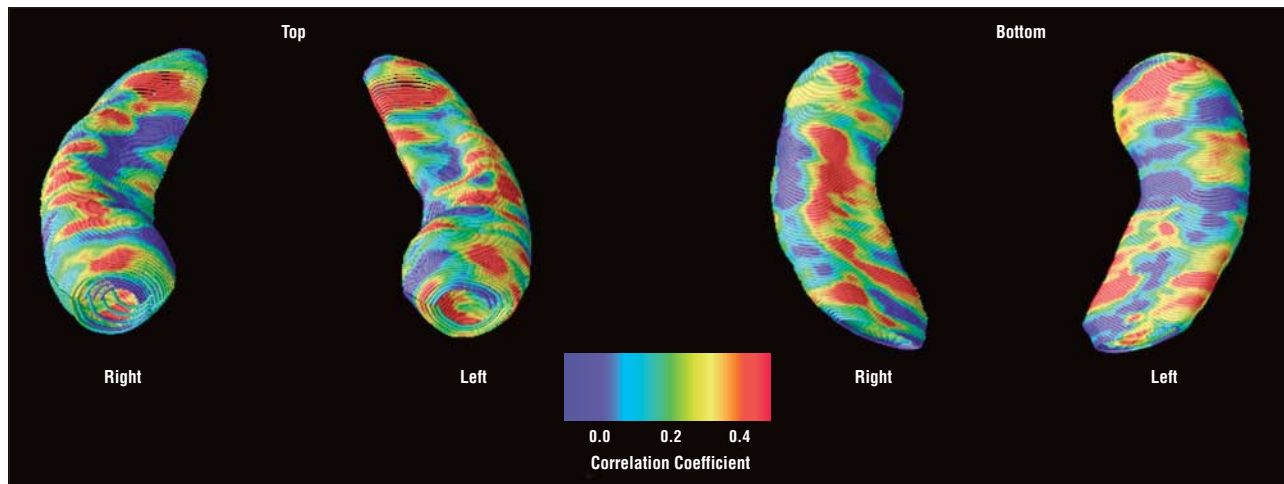


Figure 3. Statistical maps showing the correlation between the delayed recall score on the California Verbal Learning Test and regional hippocampal atrophy.

cantly greater CA1 and subicular involvement relative to MCI-i patients bilaterally. The CA2 and CA3 subfields showed no significant group differences (**Table 3**).

COGNITIVE CORRELATIONS

Figure 3 depicts 3-D statistical maps correlating the delayed recall score on the California Verbal Learning Test with hippocampal radial atrophy. The strongest correlations were seen (or observed) for the lateral and ventral hippocampal surfaces (CA1 and subiculum).

COMMENT

MCI-c showed a distinct pattern of hippocampal atrophy from MCI-nc and MCI-i. The magnetic resonance imaging preconversion difference at baseline is atrophy of the lateral edge of the hippocampal formation, possibly corresponding to the CA1 subfield. The baseline magnetic resonance imaging preconversion difference is atrophy of the lateral edge of the hippocampal formation, possibly corresponding to the CA1 subfield. As we expected, the CA2 and CA3 subfields did not show differences between the 3 groups, although a larger sample may be needed to detect subtle differences. The CA1 hippocampal subfield is particularly susceptible to neuronal loss in early AD.³⁶⁻³⁸ One recent study demonstrated preferential CA1 and subicular atrophy, and relative sparing

of CA2, CA3, and CA4 subfields in the earliest pathologic AD stages (Braak states I-III).³⁹

Using a computational anatomy approach similar to ours, Wang et al⁴⁰ and Csernansky et al⁴¹ compared hippocampal volume and shape between subjects with mild AD (Clinical Dementia Rating Scale score, 0.5) and age-matched control subjects. Their hippocampal deformation maps accurately distinguished subjects with AD from healthy controls. The AD group had lateral-edge atrophy in regions corresponding to the CA1 hippocampal subfield at baseline with spread to the hippocampal head at follow-up. Further extending their work, we found greater CA1 involvement in MCI patients who later developed AD. We found strong correlations between greater atrophy and verbal memory performance.

Some studies find that a proportion of MCI subjects revert back to normal cognition when followed up longitudinally.³ To our knowledge, ours is the first imaging study that includes the whole spectrum of clinical outcomes of cognitive worsening, improvement, and stability. Patients with reversible MCI seem to have CA1 and subicular sparing and larger hippocampal volumes at baseline. The precise etiology for the amnesic syndrome in our MCI-i patients remains obscure as we excluded patients with depression or any other illness that could contribute to cognitive decline. Future studies focusing on MCI-i will help clarify its etiology.

Our study has several limitations. Despite the small sample size, we were able to demonstrate significant morphological differences between the groups. A larger MCI patient sample will better define hippocampal regions that correlate best with cognitive outcomes and determine the specificity and sensitivity of our methods in predicting cognitive outcome in patients with newly diagnosed MCI. Without direct pathological validation, the interpretation of the subregional involvement remains arbitrary. The subregional boundaries we used are similar to those proposed by other research groups.^{42,43} Nevertheless, what we interpret as CA1 or subicular involvement may reflect changes in another hippocampal subregion. Our study focused on amnesic MCI. Our findings cannot be generalized to all MCI patients, especially to those with the nonamnesic subtype. A large prospective study that follows up patients with all MCI subtypes over time is needed to address the etiological, clinical, and prognostic questions that remain unanswered.

Accepted for Publication: January 1, 2006.

Correspondence: Liana G. Apostolova, MD, Reed Neurological Research Center, Suite 2-238, 710 Westwood Blvd, Box 951769, Los Angeles, CA 90095-1769 (lapostolova@mednet.ucla.edu).

Author Contributions: *Study concept and design:* Apostolova, Dutton, Dinov, and Cummings. *Acquisition of data:* Apostolova. *Analysis and interpretation of data:* Apostolova, Dutton, Dinov, Hayashi, Toga, Cummings, and Thompson. *Drafting of the manuscript:* Apostolova and Dinov. *Critical revision of the manuscript for important intellectual content:* Apostolova, Dutton, Dinov, Hayashi, Toga, Cummings, and Thompson. *Statistical analysis:* Apostolova and Dinov. *Obtained funding:* Apostolova, Dinov, Toga, and Thompson. *Administrative, technical, and material support:* Apostolova. *Study supervision:* Cummings and Thompson.

Funding/Support: This study was supported by grant NIA K23 AG026803, sponsored jointly by the National Institute on Aging (NIA), American Federation for Aging Research, The John A. Hartford Foundation, The Atlantic Philanthropies, The Starr Foundation, and an anonymous donor (Drs Apostolova and Dinov). The study was also supported by the Kassel Parkinson's Disease Foundation (Dr Apostolova); and grants AG16570 from the NIA (Drs Apostolova, Cummings, and Thompson), EB01651 from the National Institute of Biomedical Imaging and BioEngineering (Dr Thompson), LM05639 from the NLM (Dr Thompson), RR019771 from the National Center for Research Resources (NCRR) (Dr Thompson), R01 MH071940 from the National Institutes of Health (NIH) and National Institute of Mental Health (Drs Toga, Thompson, and Dinov), P41 RR013642 from the NIH and NCRR (Drs Toga, Thompson, and Dinov), U54 RR021813 from the NIH (Drs Toga, Dinov, and Thompson), and DUE 0442992 from the National Science Foundation (Dr Dinov).

REFERENCES

- Petersen RC, Smith GE, Waring SC, Ivnik RJ, Tangalos EG, Kokmen E. Mild cognitive impairment. *Arch Neurol.* 1999;56:303-308.
- Petersen RC, Doody R, Kurz A, et al. Current concepts in mild cognitive impairment. *Arch Neurol.* 2001;58:1985-1992.
- Wahlund LO, Pihlstrand E, Jonhagen ME. Mild cognitive impairment: experience from a memory clinic. *Acta Neurol Scand Suppl.* 2003;179:21-24.
- Gauthier S, Touchon J. Mild cognitive impairment is not a clinical entity and should not be treated. *Arch Neurol.* 2005;62:1164-1166, discussion, 1167.
- Petersen RC, Morris JC. Mild cognitive impairment as a clinical entity and treatment target. *Arch Neurol.* 2005;62:1160-1163.
- Price JL, Morris JC. Tangles and plaques in nondemented aging and "preclinical" Alzheimer's disease. *Ann Neurol.* 1999;45:358-368.
- Haroutunian V, Perl DP, Purohit DP, et al. Regional distribution of neuritic plaques in the nondemented elderly and subjects with very mild Alzheimer disease. *Arch Neurol.* 1998;55:1185-1191.
- Jack CR Jr, Dickson DW, Parisi JE, et al. Antemortem MRI findings correlate with hippocampal neuropathology in typical aging and dementia. *Neurology.* 2002;58:750-757.
- Silbert LC, Quinn JF, Moore MM, et al. Changes in premorbid brain volume predict Alzheimer's disease pathology. *Neurology.* 2003;61:487-492.
- Petersen RC, Jack CR Jr, Xu YC, et al. Memory and MRI-based hippocampal volumes in aging and AD. *Neurology.* 2000;54:581-587.
- Chetelat G, Desgranges B, de la Sayette V, et al. Dissociating atrophy and hypometabolism impact on episodic memory in mild cognitive impairment. *Brain.* 2003;126:1955-1967.
- Kaye JA, Swihart T, Howieson D, et al. Volume loss of the hippocampus and temporal lobe in healthy elderly persons destined to develop dementia. *Neurology.* 1997;48:1297-1304.
- Jack CR Jr, Petersen RC, Xu Y, et al. Rates of hippocampal atrophy correlate with change in clinical status in aging and AD. *Neurology.* 2000;55:484-489.
- Jack CR Jr, Petersen RC, Xu Y, et al. Rate of medial temporal lobe atrophy in typical aging and Alzheimer's disease. *Neurology.* 1998;51:993-999.
- Jack CR Jr, Petersen RC, Xu YC, et al. Prediction of AD with MRI-based hippocampal volume in mild cognitive impairment. *Neurology.* 1999;52:1397-1403.
- Jack CR Jr, Shiung MM, Gunter JL, et al. Comparison of different MRI brain atrophy rate measures with clinical disease progression in AD. *Neurology.* 2004;62:591-600.
- De Toledo-Morrell L, Goncharova I, Dickerson B, Wilson RS, Bennett DA. From healthy aging to early Alzheimer's disease: in vivo detection of entorhinal cortex atrophy. *Ann N Y Acad Sci.* 2000;911:240-253.
- Dickerson BC, Goncharova I, Sullivan MP, et al. MRI-derived entorhinal and hippocampal atrophy in incipient and very mild Alzheimer's disease. *Neurobiol Aging.* 2001;22:747-754.
- Killiany RJ, Hyman BT, Gomez-Isla T, et al. MRI measures of entorhinal cortex vs hippocampus in preclinical AD. *Neurology.* 2002;58:1188-1196.
- Convit A, de Asis J, de Leon MJ, Tarshish CY, de Santi S, Rusinek H. Atrophy of the medial occipitotemporal, inferior, and middle temporal gyri in nondemented elderly predict decline to Alzheimer's disease. *Neurobiol Aging.* 2000;21:19-26.
- Thompson PM, Hayashi KM, De Zubicaray GI, et al. Mapping hippocampal and ventricular change in Alzheimer disease. *Neuroimage.* 2004;22:1754-1766.
- Thompson PM, Hayashi KM, de Zubicaray G, et al. Dynamics of gray matter loss in Alzheimer's disease. *J Neurosci.* 2003;23:994-1005.
- Ballmaier M, O'Brien JT, Burton EJ, et al. Comparing gray matter loss profiles between dementia with Lewy bodies and Alzheimer's disease using cortical pattern matching. *Neuroimage.* 2004;23:325-335.
- Sowell ER, Thompson PM, Peterson BS, et al. Mapping cortical gray matter asymmetry patterns in adolescents with heavy prenatal alcohol exposure. *Neuroimage.* 2002;17:1807-1819.
- Sowell ER, Thompson PM, Welcome SE, Henkenius AL, Toga AW, Peterson BS. Cortical abnormalities in children and adolescents with attention-deficit hyperactivity disorder. *Lancet.* 2003;362:1699-1707.
- Ballmaier M, Sowell ER, Thompson PM, et al. Mapping brain size and cortical gray matter changes in elderly depression. *Biol Psychiatry.* 2004;55:382-389.
- Narr KL, Thompson PM, Szeszo P, et al. Regional specificity of hippocampal volume reductions in first-episode schizophrenia. *Neuroimage.* 2004;21:1563-1575.
- Sowell ER, Peterson BS, Thompson PM, Welcome SE, Henkenius AL, Toga AW. Mapping cortical change across the human life span. *Nat Neurosci.* 2003;6:309-315.
- Lin JJ, Salamon N, Dutton RA, et al. Three-dimensional preoperative maps of hippocampal atrophy predict surgical outcomes in temporal lobe epilepsy. *Neurology.* 2005;65:1094-1097.
- American Psychiatric Association. *Diagnostic and Statistical Manual of Mental Disorders.* 4th ed. Washington, DC: American Psychiatric Association; 1994.
- Collins DL, Neelin P, Peters TM, Evans AC. Automatic 3D intersubject registration of MR volumetric data in standardized Talairach space. *J Comput Assist Tomogr.* 1994;18:192-205.
- Shattuck DW, Sandor-Leahy SR, Schaper KA, Rottenberg DA, Leahy RM. Magnetic resonance image tissue classification using a partial volume model. *Neuroimage.* 2001;13:856-876.
- Narr KL, Thompson PM, Sharma T, et al. Three-dimensional mapping of temporolimbic regions and the lateral ventricles in schizophrenia: gender effects. *Biol Psychiatry.* 2001;50:84-97.
- Duvernoy H. *The Human Hippocampus: An Atlas of Applied Anatomy.* Munich, Germany: JF Bergmann Verlag; 1988.
- West MJ, Gundersen HJ. Unbiased stereological estimation of the number of neurons in the human hippocampus. *J Comp Neurol.* 1990;296:1-22.

36. Huesgen CT, Burger PC, Crain BJ, Johnson GA. In vitro MR microscopy of the hippocampus in Alzheimer's disease. *Neurology*. 1993;43:145-152.
37. Arnold SE, Hyman BT, Flory J, Damasio AR, Van Hoesen GW. The topographical and neuroanatomical distribution of neurofibrillary tangles and neuritic plaques in the cerebral cortex of patients with Alzheimer's disease. *Cereb Cortex*. 1991;1:103-116.
38. Bobinski M, Wegiel J, Wisniewski HM, et al. Atrophy of hippocampal formation subdivisions correlates with stage and duration of Alzheimer disease. *Dementia*. 1995;6:205-210.
39. Schonheit B, Zarski R, Ohm TG. Spatial and temporal relationships between plaques and tangles in Alzheimer-pathology. *Neurobiol Aging*. 2004;25:697-711.
40. Wang L, Swank JS, Glick IE, et al. Changes in hippocampal volume and shape across time distinguish dementia of the Alzheimer type from healthy aging. *Neuroimage*. 2003;20:667-682.
41. Csernansky JG, Wang L, Joshi S, et al. Early DAT is distinguished from aging by high-dimensional mapping of the hippocampus. *Neurology*. 2000;55:1636-1643.
42. Csernansky JG, Wang L, Miller JP, Galvin JE, Morris JC. Neuroanatomical predictors of response to donepezil therapy in patients with dementia. *Arch Neurol*. 2005;62:1718-1722.
43. Csernansky JG, Wang L, Swank J, et al. Preclinical detection of Alzheimer's disease. *Neuroimage*. 2005;25:783-792.

Announcement

Trial Registration Required. In concert with the International Committee of Medical Journal Editors (ICMJE), *Archives of Neurology* will require, as a condition of consideration for publication, registration of all trials in a public trials registry (such as <http://ClinicalTrials.gov>). Trials must be registered at or before the onset of patient enrollment. This policy applies to any clinical trial starting enrollment after July 1, 2005. For trials that began enrollment before this date, registration will be required by September 13, 2005, before considering the trial for publication. The trial registration number should be supplied at the time of submission.

For details about this new policy, and for information on how the ICMJE defines a clinical trial, see the editorial by DeAngelis et al in the January issue of *Archives of Dermatology* (2005;141:76-77). Also see the Instructions to Authors on our Web site: www.archneurol.com.