

## PDF hosted at the Radboud Repository of the Radboud University Nijmegen

The following full text is a publisher's version.

For additional information about this publication click this link.

<http://hdl.handle.net/2066/30188>

Please be advised that this information was generated on 2022-08-23 and may be subject to change.

# **Coronary Artery Fistulas in Adults Clinical and Coronary Angiographic Aspects**

**Salah A.M. Said**

Said, S.A.M.  
Coronary Artery Fistulas in Adults Clinical and Coronary Angiographic Aspects

ISBN: 978-90-9022016-1

Cover: Hearty, Ulrich Huckschlag, vakfotograaf, Hengelo  
Layout and cover design: Debbie Snijders  
Production: Drukkerij Hofmeijer, Hengelo, the Netherlands

Copyright © S.A.M. Said, Nijmegen, 2007. The copyright of the articles that have been published has already been transferred to the publisher of the journals.

# **Coronary Artery Fistulas in Adults Clinical and Coronary Angiographic Aspects**

Een wetenschappelijke proeve op het gebied van de Medische Wetenschappen

## **Proefschrift**

ter verkrijging van de graad van doctor  
aan de Radboud Universiteit Nijmegen  
op gezag van de Rector Magnificus Prof. mr. S.C.J.J. Kortman,  
volgens besluit van het College van Decanen  
in het openbaar te verdedigen op dinsdag 25 september 2007 des namiddags om 13.30 uur  
precies

door

**Salah Ali Mohamed Said**  
Geboren op 23 december 1953  
te Abu Za'bal, Kalyoubia, Egypte

**Promotor:**

Prof. Dr. T. van der Werf

**Manuscriptcommissie:**

Prof. Dr. J.G. Blickman

Prof. Dr. L. Eijssman

Prof. Dr. B.J.M. Mulder, UMC Amsterdam

The printing of this thesis was financially supported by

Actelion pharmaceuticals Ned, Altana, Astellas, AstraZeneca, Boehringer-Ingelheim, Boehringer-Mannheim, Bristol-Myers Squibb, Boston Scientific, Cordis, Ela medical, Guerbet, Guidant, Holland Medical, Knoll, Merck Sharp & Dohme, Medtronic, Menarini, Novartis, Pfizer, Riker, Roche, Sanofi Aventis, Schering-Plough, Servier, Foundation Heart centre Twente, Enschede, St. Jude Medical, Vitatron, Withering Foundation Nederland, Hospital Group Twente.

No part of this book may be reproduced in any form, by print or any other means without written permission from the author and the publishers of the published articles concerned.

The major part of this work has been performed in Hospital Group Twente (ZGT), location Regional Hospital Midden-Twente (SMT), Hengelo, the Netherlands.

To the soul of my father and my brother Ashraf  
To my mother and family in-law  
To Geer, Sherien and Ines  
To my brothers and sisters

Ter nagedachtenis aan mijn vader (19 september 1915 – 15 mei 1989) en aan mijn broer  
Ashraf (22 april 1967 - 07 juli 2005)  
Aan mijn moeder en schoonfamilie  
Aan Geer, Sherien en Ines  
Aan mijn broers en zusters



وَأَفْعَلُوا  
الْخَيْرَ  
تَعْلَمُ تَفْلِحُونَ

en doet het goede, Hopelijk zullen jullie weerslagen. Al-Hadj:77





# Table of contents

<b>Chapter 1</b>	Preface and scope of the thesis	<b>11</b>
<b>Chapter 2</b>	Literature review	<b>15</b>
	Coronary artery fistulas. Said SAM, Thiadens AAHJ, Fieren MJCH, Meijboom EJ, van der Werf T, Bennink GBWE. Neth Heart J 2002; 10:65-78	
<b>Chapter 3</b>	Own case series report	<b>39</b>
	<b>A-</b> Coronary arteriovenous fistulas: Collective review and management of six new cases. Changing etiology, presentation and treatment strategy. Said SAM, El Gamal MIH, van der Werf T. Clinical Cardiology 1997; 20:748-752	<b>41</b>
	<b>B-</b> Acquired coronary cameral fistulas: Are these collaterals losing their destination? Report of seven adult cases and literature review. Said SAM, van der Werf T. Clinical Cardiology 1999; 22:297-302	<b>51</b>
	<b>C-</b> Coronary angiographic morphology of congenital coronary arteriovenous fistulas in adults: report of four new cases and review of angiograms of fifteen reported cases. Said SAM, El Gamal MIH. Cathet Cardiovasc Diagn 1995; 35:29-35	<b>63</b>
	<b>D-</b> Congenital and atherosclerotic (acquired) coronary artery aneurysms: coronary angiographic and morphologic observations in 10 patients. Salah Said, Mamdouh El Gamal, Tjeerd van der Werf. Int J Angiology 1998; 7:206-210	<b>75</b>
<b>Chapter 4</b>	Cardiovascular Magnetic Resonance imaging and coronary artery fistulas Feasibility of Cardiovascular Magnetic Resonance for Detection of Angiographically Diagnosed Congenital Solitary Coronary Artery Fistulas. S.A.M. Said, M.B.M. Hofman, A.M. Beek, T. van der Werf, A.C. van Rossum. Journal of Cardiovascular Magnetic Resonance 2007; 9:1-9	<b>85</b>
<b>Chapter 5</b>	Dutch registry	<b>101</b>
	<b>A-</b> Argumentation for initiation of a Dutch Registry	<b>103</b>
	<b>B-</b> Appendix I: Dutch Registry Case Report Forms for acquisition of patient's data	<b>105</b>
	<b>C-</b> Angiographically diagnosed congenital coronary artery fistulas in an adult population. Said SAM, Relik-van Wely L, van der Werf T. Cardiologie 1998; 5:71-73	<b>109</b>
	<b>D-</b> Appendix II: Participating Dutch clinical centres	<b>113</b>
<b>Chapter 6</b>	Congenital solitary fistulas in adults Dutch survey of coronary artery fistulas in Adults: Congenital solitary fistulas. Multi-center observational survey in the Netherlands. S.A.M. Said, T.van der Werf. Int J Cardiol 2006; 106:323-332	<b>115</b>
<b>Chapter 7</b>	Congenital Coronary Artery-left ventricular Multiple Micro-Fistulas Dutch Survey of Congenital Coronary Artery Fistulas in Adults: Coronary Artery-Left Ventricular Multiple Micro-fistulas. Multi-center observational survey in the Netherlands. S.A.M. Said, T. van der Werf.	

Int J Cardiol 2006; 110:33-39	131
<b>Chapter 8</b> General discussion and future perspective	<b>143</b>
<b>Chapter 9</b> Summary and conclusions	<b>155</b>
<b>Chapter 10</b> Samenvatting	<b>161</b>
<b>Publications of the author</b>	<b>167</b>
<b>Dankwoord</b>	<b>173</b>
<b>Curriculum Vitae</b>	<b>175</b>

# Chapter 1

## Preface and scope of the thesis

### Introduction

Coronary artery fistulas (CAFs) are defined as abnormal communications, bypassing the capillary bed, between any otherwise normal coronary artery and cardiac chamber or a large intrathoracic vessel. Two major types are recognized: 1) solitary CAFs and 2) coronary artery-left ventricular multiple micro-fistulas (MMFs). The former is defined as a direct communication between otherwise normally originating coronary arteries and a cardiac chamber or intrathoracic vessels and the latter as a direct communication between otherwise normally originating coronary arteries and ventricular cavities characterized by multiple small channels opacifying the ventricles (blush appears in the **wall** of the LV and MMFs opacify the **lumen** of the LV).

CAFs are uncommon but potentially important congenital coronary artery disorders that can affect any age group. They may cause significant cardiac morbidity and mortality.<sup>1-5</sup> The incidence of congenital CAFs is 1:50.000 live births.<sup>6</sup> The incidence of congenital CAFs varies depending on whether the reported series is based on clinical, angiographic or autopsy series. It has been estimated that congenital CAFs are observed in 1:500 patients who undergo coronary arteriographic examination and the incidence at necropsy is 14%.<sup>7-10</sup>

Coronary artery fistulas may produce symptoms such as angina pectoris, congestive heart failure, rhythm disturbances and sudden death.<sup>1-5, 7, 9</sup> Due to the high prevalence of atherosclerotic heart disease, fistulas are often found in combination with atherosclerotic coronary artery disease. It is then not always obvious which of the two disease entities provokes the complaints. It may also be possible that both disease entities amplify each other. Finally there may be patients with no complaints or symptoms at all. It was an intriguing question for us if there are fistula patients without coronary artery disease but nonetheless with angina pectoris, in which the angina must be attributed to the presence of the fistula.

A variety of diagnostic imaging modalities can be used to determine the CAFs and outline characteristics of the fistula. Coronary arteriography remains the gold standard for delineating the anatomy of the involved coronary arteries with their collateral circulation, the course of the fistulous tract, and the receiving cardiac chamber or intrathoracic great vessels.<sup>11-16</sup> The anatomical characteristics are differently described in the case stories in the literature. Currently a systematic description of the fistula morphology derived from a large series of patients with this anomaly is lacking. Such morphologic appearance is important because it may influence the choice of the treatment options. Therefore we developed a simple but effective descriptive system for CAFs (origin, course and outflow, furthermore singularity, multiplicity and tortuosity) found on coronary arteriography. Furthermore we investigated the potential role of magnetic resonance for the diagnosis of CAFs.

Once a coronary artery fistula is discovered, the management should be established

including antibiotic prophylaxis and in case of dilatation of the involved fistula-related coronary artery and/or aneurysmal manifestation of the fistulous vessels antiplatelet regimen or oral anticoagulation is recommended. There are different therapeutic options: 1) Watchful waiting or conservative medical management, and permanent abolition of the fistula either by 2) Surgical closure or 3) Percutaneous transcatheter (therapeutic) embolization. There are yet no prospectively randomized studies concerning these therapeutic strategies.

Currently permanent occlusion of CAFs by surgical ligation is addressed when CAFs are presented with multiple connections, tortuous course, acute angulations, complex anatomy, distal localization, large fistula with high fistulous flow, side branch at risk, complicated with aneurysmal manifestation and associated with other cardiac anomalies requiring surgery.<sup>17</sup> Factors in favour of percutaneous therapeutic “transcatheter” embolization are: proximal location of the fistulous vessel, older patients, and absence of concomitant cardiac disorders necessitating surgical intervention.<sup>18</sup> There is general agreement that treatment is indicated for symptomatic patients having sizeable CAFs with a large left-to-right shunt. Asymptomatic subjects with small shunt may be managed by watchful waiting and/or conservative medical management strategy which have a benign long-term follow-up.<sup>8, 19</sup> Data are lacking regarding symptomatic or asymptomatic patients with medium-sized fistula.

Obviously there is a need for prospective and randomized studies. Once a fistula is seen during coronary arteriography and cardiac catheterization, the patient's case should be worked-up according to a standard protocol. Regarding the treatment, patients with medium-sized fistulas must be stratified based on the morphologic findings during coronary arteriography and thereafter randomized to a specific therapy with a good defined long-term follow-up.

### **Scope of the thesis**

The main aim of this thesis was to outline the clinical presentation and to elucidate the coronary angiographic morphology of these anomalies in a large Dutch Registry. Firstly we present the results of our own investigations on patients whose clinical and coronary angiographic features met the criteria for the diagnosis of CAFs comparing these findings to those reported in the literature.

In **Chapter 2** we summarize the current literature on CAFs. Nearly all the literature deals with single case reports or a compilation of a few cases, but there does not exist a systematic investigation.

Clinical and coronary angiographic morphologic manifestations of congenital and acquired CAFs are reported in **Chapter 3**. Due to the high volume of therapeutic endovascular procedures, acquired CAFs are increasingly reported. Can this currently lead to changing etiology, clinical presentation and management of CAFs? Six own cases together with 76 review subjects are evaluated and presented in **(3A)**. Is there a possible involvement of atherosclerosis in the pathogenesis of these acquired fistulas? Seven own patients and 34 review subjects are presented in **(3B)**.

A preliminary report of nineteen patients regarding the angiographic morphologic characteristics of congenital CAFs is given in **(3C)** and in ten patients particular attention is paid to the comparison between the aneurysmal manifestation associated with congenital CAFs and those related to atherosclerotic “acquired” coronary aneurysms **(3D)**.

As mentioned above, cardiovascular magnetic resonance (CMR) technique which is a new promising non-invasive diagnostic modality was used to evaluate its feasibility in imaging CAFs. The findings of CMR are discussed in **(Chapter 4)**.

The Dutch Registry, initiated by the author of this thesis, collected the angiographic and clinical data as well as data on the treatment and survival. The registry started in 1993. The details of the data registration and the first report from 1998 are given. The reasoning for a Dutch Registry is outlined in **(Chapter 5)**. Between 1996 and 2003, 30.829 coronary angiograms (from 28 Dutch adult coronary angiographic suits) have been independently re-evaluated. CAFs were found in 71 of them who formed the cornerstone of this thesis. It

appeared important to make a clear differentiation between solitary CAFs and coronary artery-left ventricular multiple micro-fistulas, considering symptomatology and therapy. Therefore we described both entities in two different chapters. Fifty-one cases had solitary CAFs (**Chapter 6**) and 20 patients had coronary artery-left ventricular multiple micro-fistulas (MMFs) (**Chapter 7**).

The study was primarily a clinico-angiographic morphological study on CAFs. We compared the clinical and angiographic morphological aspects recorded in our patients to those reported in the literature. The results of the Dutch Registry have been published in various articles (**Chapter 4, 6 and 7**).

The thesis is provided with general discussion in (**Chapter 8**) and a proposal for a prospective analysis is suggested. Ideally, to answer certain issues, large prospective and randomized studies are warranted. Summary and conclusions are given in (**Chapter 9**) with a Dutch summary in (**Chapter 10**).

Please note that a particular group of patients with unique angiographic morphologic manifestations was used for the data described in Chapters 3. A different group of patients was presented in Chapter 5. An additional group of patients (Dutch Registry) was used for data reported in Chapters 4, 6 and 7.

#### References:

1. Libერთson RR, Sagar K, Berkoben JP, Weintraub RM, Levine FH. Congenital coronary arteriovenous fistula. Report of 13 patients, review of the literature and delineation of management. *Circ* 1979; 59:849-854.
2. Wilde P, Watt I. Congenital coronary artery fistulae: six new cases with a collective review. *Clin Radiol* 1980; 31:301-311.
3. Lowe JE, Oldham HN, Sabiston DC. Surgical management of congenital coronary artery fistulae. *Ann Surg* 1981; 194:373-380.
4. Davis JT, Allen HD, Wheller JJ, et al. Coronary artery fistula in the pediatric age group: a 19-year institutional experience. *Ann Thorac Surg* 1994; 58:760-763.
5. Lau G. Sudden death arising from a congenital coronary artery fistula. *Forensic Sci Int* 1995; 73:125-130.
6. Schumacher G, Roithmair A, Lorenz HP, et al. Congenital coronary artery fistula in infancy and childhood: Diagnostic and therapeutic aspects. *Thorac Cardiovasc Surg* 1997; 45:287-294.
7. Vavuranakis M, Bush CA, Boudoulas H. Coronary artery fistulas in adults: Incidence, angiographic characteristics, natural history. *Cathet Cardiovasc Diagn* 1995; 35:116-120.
8. Yamanaka O, Hobbs RE. Coronary artery anomalies in 126,595 patients undergoing coronary arteriography. *Cathet Cardiovasc Diagn* 1990; 21:28-40.
9. Gillebert C, Van Hoof R, Van de Werf F, Piessens J, De Geest H. Coronary artery fistula in an adult population. *Eur Heart J* 1986; 7:437-43.
10. Ogden JA. Congenital anomalies of the coronary arteries. *Am J Cardiol* 1970; 25:474-479.
11. Duerinckx AJ, Shaaban A, Lewis A, Perloff J, Laks H. 3D MR imaging of coronary arteriovenous fistulas. *Eur Radiol* 2000; 10:1459-1463.
12. Ozeki S, Utsunomiya T, Kishi T, et al. Coronary arteriovenous fistula presenting as chronic pericardial effusion. *Circ J* 2002; 66:779-782.
13. Sato Y, Mitsui M, Takahashi H, et al. A giant left circumflex coronary artery-right atrium arteriovenous fistula detected by multi-slice spiral computed tomography. *Heart Vessels* 2004; 19:55-56.
14. Murata N, Yamamoto N. A case of ruptured coronary artery aneurysm associated with coronary artery fistulas. *Jpn J Cardiovasc Surg* 2001; 30:305-307.
15. Misumi T, Nishikawa K, Yasudo M, Suzuki T, Kumamaru H. Rupture of an aneurysm of a coronary arteriovenous fistula. *Ann Thorac Surg* 2001; 71:2026-2027.
16. Burns KEA, Ferguson KA, Spouge A, Brown JE. Massive congenital coronary arteriovenous malformation presenting with exertional dyspnea and desaturation in

- an adult: A case report and review of the literature. *Can J Cardiol* 2001; 17:85-89.
17. Gelsomino S, Rubattu G, Terrosu PF, Cossu L, Orrù F, Barbosa G. Successful repair of a coronary artery to pulmonary artery fistula with saccular artery aneurysm and critical stenosis of the left anterior descending coronary artery. *Ital Heart J* 2003; 4:350-353.
  18. Mavroudis Ann Thorac Surg 1997 Mavroudis C, Backer CL, Rocchini AP, Muster AJ, Gevitz M. Coronary artery fistulas in infants and children: A surgical review and discussion of coil embolization. *Ann Thorac Surg* 1997; 63:1235-1242.
  19. Reed WA, Kittle CF. Congenital coronary artery fistula. Indications for operative treatment. *Arch Surg* 1966; 93:772-5.

Because this thesis consists of several separate self-contained papers some repetition is inevitable.

Because of the limitations by the Dutch privacy law regulations, it was not possible to include all coronary artery fistulas (CAFs) cases in the Netherlands in the Dutch Registry.

# Chapter 2

## **CORONARY ARTERY FISTULAS**

S.A.M. Said  
A.A.H.J. Thiadens  
M.J.C.H. Fieren  
E.J. Meijboom  
T. van der Werf  
G.B.W.E. Bennink

Published in:

Netherlands Heart Journal 2002; 10:65-78



The aetiology of congenital coronary artery fistulas remains a challenging issue. Coronary arteries with an anatomically normal origin may, for obscure reasons, terminate abnormally and communicate with different single or multiple cardiac chambers or great vessels. When this occurs, the angiographic morphological appearance may vary greatly from discrete channels to plexiform network of vessels. Coronary arteriovenous fistulas (CAVFs) have neither specific signs nor pathognomonic symptoms; the spectrum of clinical features varies considerably. The clinical presentation of symptomatic cases can include angina pectoris, myocardial infarction, fatigue, dyspnea, congestive heart failure (CHF), subacute bacterial endocarditis (SBE), ventricular and supraventricular tachyarrhythmias or even sudden cardiac death. CAVFs may, however, be a coincidental finding during diagnostic coronary angiography (CAG). CAG is considered the gold standard for diagnosing and delineating the morphological anatomy and pathway of CAVFs. There are various tailored therapeutic modalities for the wide spectrum of clinical manifestations of CAVFs, including conservative pharmacological strategy, percutaneous transluminal embolization and surgical ligation.

**Key words:** aetiology, angiographic morphology, clinical picture, congenital and acquired, coronary artery fistula, treatment.

### **Introduction**

The aetiology of congenital coronary artery fistulas (CAFs) is very complex. A coronary artery with an anatomically normal origin may abnormally terminate and communicate with different single or multiple cardiac chambers or great vessels. In such cases, the angiographic morphological appearance varies greatly between discrete channels and plexiform network of vessels.

Arteriovenous malformations (AVM) may be present throughout the entire vascular system. They may be congenital or acquired, occurring after diagnostic or therapeutic endovascular interventions.<sup>1-5</sup> The head, extremities and visceral organs are the most common sites of congenital AVM, whereas the thoracic wall appears to be a rare site.<sup>3,6</sup> The symptoms of congenital AVM do not usually appear until adult life, mostly in the second or third decade.<sup>1</sup> The same holds true for congenital coronary arteriovenous fistulas. Cardiac symptoms such as precordial pain, cardiac dysrhythmia and dyspnea<sup>2</sup> may rarely occur, especially when the AVM are localized in the chest wall.

According to Levin, coronary artery fistulas are the most common hemodynamically significant congenital defect of the coronary arteries.<sup>7</sup> Even though many patients with this condition are asymptomatic, late complications occur especially in the presence of a large left-to-right shunt and include congestive heart failure,<sup>8,9</sup> myocardial ischemia,<sup>9,10</sup> endocarditis,<sup>9,11</sup> atrial fibrillation,<sup>11,12</sup> pulmonary hypertension,<sup>11,13</sup> rupture, thrombosis or venous obstruction.<sup>9</sup> Syncope and sudden death have also been reported in patients with CAVFs.<sup>14</sup> Consequently, surgical ligation of the arteriovenous or arteriocameral fistula has been recommended in most reported series in an effort to prevent these complications; perioperative mortality rates range from 2 to 4%.<sup>9,15</sup>

Although coronary arteriovenous fistulas (CAVFs) are infrequent, they are becoming increasingly important and their early recognition is imperative, as management and treatment could prevent serious complications. Many large or symptomatic CAVFs are amenable to cure by surgical or percutaneous transcatheter embolization techniques. Other abnormalities resulting from persistence of embryonal arrest such as ventriculo-venous communications<sup>16</sup> are excluded from this study.

### **Incidence of CAVFs**

CAVFs comprise 13% to 14% of the angiographically recognized coronary artery anomalies.<sup>7,9,14</sup> Congenital CAVFs are found in approximately 1 in every 50.000 patients with

congenital heart disease.<sup>17</sup> The angiographic incidence is presented in table 1.

Table 1. Incidence of congenital coronary artery fistulas, angiographic series.

First author	year	subjects no total/fistula	prevalence (%)
Querimit <sup>123</sup>	1971	2,500/6	0.2
Baltaxe <sup>89</sup>	1977	1,000/2	0.2
Gillebert <sup>26</sup>	1986	14,708/19	0.13
Yamanaka <sup>14</sup>	1990	126,595/225	0.18

The first reported post-mortem case of CAVF was by Krause in 1865.<sup>18</sup> In the second decade of the 19<sup>th</sup> century, Trevor described the post-mortem findings in a case with a right coronary-right ventricular fistula.<sup>19</sup> However, it was not until 1947 that Björck and Crafoord made the first ante-mortem diagnosis of the condition during operation for presumed patent ductus arteriosus (PDA).<sup>20</sup> In 1958, Munkner and colleagues described an ante-mortem congenital coronary artery aneurysm associated with a coronary arteriovenous fistula.<sup>21</sup> Historically, according to the site of termination, these fistulas may in some cases be present with characteristic continuous murmurs and occasionally may be confused with patent ductus arteriosus.<sup>22</sup>

The results of physical examination are variable; the continuous murmur may be absent. Furthermore, during catheterization intracardiac shunts are often undetectable.<sup>14</sup> Dating from the 1970s and from clinical point of view, a CAVF was most liable to be confused with a patent ductus arteriosus because of the similarity in physical findings and the formerly much higher incidence of the latter lesion. In 1970, PDA was the cause of a continuous murmur in 55% of adult patients.<sup>23</sup> Nowadays, in children PDA is the cause of continuous murmur in only 10%.<sup>24</sup> Even as recently as 1989 there were still patients operated for a presumptive diagnosis of PDA<sup>25</sup> which peroperatively was found to be a coronary artery fistula.

Coronary arteriovenous fistulas have an incidence of 0.1 to 0.2% (table 1), which has been reported in subjects undergoing selective coronary angiography.<sup>14,26</sup> This figure is surely too low since such lesions are uncommon but not rare, and many single cases are not reported or sometimes only reported in a hospital journal or local periodicals.<sup>27-30</sup> Therefore Eie and his colleagues suggested that if all patients with anginal complaints were examined using selective coronary angiography, the prevalence of this anomaly might prove to be higher than the currently accepted impression.<sup>31</sup>

### Definition of CAVFs

CAVFs (Figures 1 and 2) are defined as a congenital or acquired abnormal precapillary communication between one or several coronary arteries (characterized by normal origin of the coronary arteries) and any cardiac vein, chamber or great thoracic vessel bypassing the myocardial capillary bed. They may be presented as arteriovenous fistulas (CS, cardiac veins, SVC and pulmonary artery) or arteriocameral fistulas (RA, RV, LA and LV). The arterioarterial fistulas (LV, LA and pulmonary veins) are very rare. These CAVFs should be visualized without wedging of the catheter into coronary artery to prevent rapid circulation of contrast medium, which may give rise to erroneous identification of a pseudo-fistula.

To diagnose of true CAVFs, the following conditions should be avoided: (1) Forceful injection of a large amount of contrast material into the coronary artery or side branch; (2) wedging and deep catheter engagement into coronary artery or side branch.

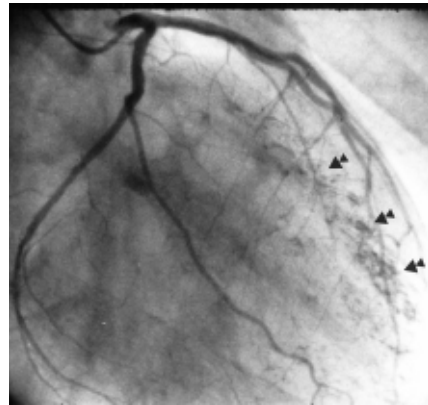
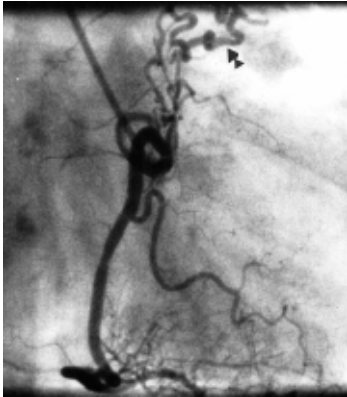


Fig. 1

Fig. 2

Fig.1 Frame of left anterior oblique projection of right coronary artery angiogram depicting a proximally located fistula (arrow) with multiple origin and single termination into the pulmonary artery.

Fig.2 Frame of right anterior oblique projection of left coronary artery angiogram demonstrating LAD-LV fistula (arrows) with multiple origin and multiple termination.

*Origin of fistulous communication*

Unilateral CAVFs more frequently originate from the right than from the left coronary arteries.<sup>7,9</sup> However, in 1986, Gillebert and associates<sup>26</sup> found that the left coronary artery was more frequently the origin of CAVFs. This finding was in contrast to the figures reported by McNamara et al<sup>11</sup> and in accordance with the findings of Goebel et al<sup>32</sup> who described the origin of the fistula by the left coronary artery in 75% of their cases.

*Pathway of fistulous communication*

The fistulous tract has been demonstrated to be a solitary single vessel or multiple convoluted plexuses of serpentine tortuous vessels.<sup>33</sup> Aneurysmal manifestation could be detected along the fistulous tract.<sup>21,34-37</sup> CAVFs terminate into the sites summarized in table 2. Over 90% of the CAVFs drain into the systemic low-pressure venous system.<sup>7</sup>

Table 2. Site of termination of CAVFs.

Percent (%)	site of termination
41	right ventricle (RV)
26	right atrium (RA)
17	pulmonary artery (PA)
7	coronary sinus (CS)
5	left atrium (LA)
3	left ventricle (LV)

### **Aetiology and development**

The aetiology of congenital CAVFs remains obscure. The primitive coronary circulation consists of wide, endothelial-lined spaces between the muscle columns of the embryonal heart and of some endothelial outgrowths towards the epicardial surfaces. The intertrabecular spaces or sinusoids freely communicate with these newly formed epicardial vessels and together form the original sinusoidal circulation.

Intracardiac coronary artery termination may be into the capillary plexus, into a myocardial sinusoid or directly into a lumen of ventricle. Generally speaking, blood entering the coronary arteries has a possible exit through any one or all of four routes.

1. By extracardiac anastomoses (mediastinum, lungs, parietal pericardium and diaphragm);
2. By way of the arterio-luminal vessels directly into the cardiac chambers (CC);
3. By way of the capillaries and veins; either into the coronary sinus (CS) or great cardiac veins (CV) and thence into the right atrium (RA) (conventional route), or through the Thebesian veins (TV) into the cardiac chambers;
4. By way of the arterio-sinusoidal vessels through the myocardial sinusoids into the cardiac chambers.

The last three systems also anastomose with one another.

#### *Speculations about the genesis of congenital CAVFs*

The pathogenesis of CAVFs is mainly congenital in the overwhelming majority of cases or has, as has recently been shown, an acquired pathogenesis due to increasing application of intravascular diagnostic instrumentations and therapeutic procedures.

Normally, the outermost intertrabecular spaces shrink and melt with the coronary vessels to form a capillary network. The intertrabecular vessels retain their ventricular communications to form the Thebesian veins of the adult heart. Thus it could be speculated that CAVFs develop due to an "embryologic arrest" of normal closure of the intertrabecular spaces connecting coronary arteries, veins and the cardiac chambers giving rise to persistence of such sinusoidal trabeculae.<sup>38</sup> In its most primitive form, multiple communications may be present between a coronary artery and cardiac chambers, since these are due to persistence of embryonal vascular sinusoids in the heart muscle communicating freely with coronary vessels. An accessory coronary artery originating from a cardiac chamber or sinus of Valsalva has also been proposed in the case of a fistula as a single vessel with a single origin and termination.<sup>39</sup>

The precise pathogenesis is unknown but some authors have speculated about such genesis considering the existence of right ventricular hypertension,<sup>40</sup> that the failure of expansion of the right ventricular myocardium might allow the persistence of embryonic sinusoids<sup>41</sup> and that some teratogenic factors may cause a delay in development and result in an arrest of coronary vascular transformation.<sup>42</sup>

Factors that might contribute to the development of CAVFs are:

- Chemotactic factors<sup>43</sup>
- Hemodynamic factors<sup>44</sup>
- Chemical factors<sup>45</sup>

### **Acquired CAVFs**

CAVFs are most commonly congenital in origin but they may also be acquired (table 3) secondary to various local and general pathological conditions.

Table 3. Acquired coronary arteriovenous fistulas.

Condition	1 <sup>st</sup> author / year / reference
Blunt and penetrating chest trauma	Morgan 1972, <sup>46</sup> Cheng 1973, <sup>47</sup> Toda 1991 <sup>29</sup>
Repeated endomyocardial biopsies	Sandhu 1989 <sup>50</sup>
Permanent pacing-lead erosion	Saeian 1991 <sup>56</sup>
Cardiac or coronary surgery	Rothschild 1985, <sup>58</sup> Lee 1988, <sup>59</sup> Pattee 1992 <sup>60</sup>
Secondary to severe coronary atherosclerosis and myocardial infarction	Searcy 1971, <sup>63</sup> King SB III 1971, <sup>64</sup> Ryan 1977, <sup>65</sup> Yu 1986, <sup>67</sup> Lee 1989, <sup>69</sup> Shimizu 1993, <sup>62</sup> Somsen 1994 <sup>30</sup>
Complicating PTCA procedures	Meng 1985, <sup>70</sup> Cherry 1987, <sup>71</sup> Iannone 1990, <sup>72</sup> Grill 1991, <sup>73</sup> Bata 1993, <sup>74</sup> El-Omar 1995 <sup>75</sup>

*Blunt and penetrating chest trauma*

CAVFs may develop after traumatic accidents and contusion of the anterior thoracic wall. An automobile<sup>46</sup> and motor cycle<sup>29</sup> blunt chest accidents were held responsible for the occurrence of fistulas between the left anterior descending and right coronary arteries and the right ventricle (RV), respectively. Also penetrating thoracic wounds may cause a CAVF.<sup>47-49</sup>

*Repeated endomyocardial biopsies*

Repeated endomyocardial biopsies are necessary in recipients of heart transplants to diagnose tissue rejection. CAVFs originating from either coronary arteries and terminating into the RV have been reported in such patients.<sup>50-54</sup> Fifty-two percent originated from the right, 43% from the left anterior descending artery (LAD) and 5% from the circumflex coronary arteries in the series published by Sandhu et al.<sup>50</sup> CAVFs occur in about 8% of cardiac transplant patients. Spontaneous resolution of the fistulas in asymptomatic patients has been reported in the series of Sandhu et al.<sup>50</sup> Direct ligation of the fistula and coronary artery bypass grafting has been reported in a symptomatic recipient of orthotopic heart transplant.<sup>54</sup> Obliteration of the fistula between the LAD and the RV by coil embolization improved the symptoms in a cardiac transplant patient.<sup>55</sup>

*Permanent pacing-lead erosion*

It is strongly suggested that endocardial-pacing electrodes may induce CAVFs. CAVFs arising from the LAD or septal artery and communicating with the RV have been reported by Saeian and associates<sup>56</sup> in two patients. The suggested mechanism is chronic erosion of the interventricular septum by the pacing lead.

*Cardiac or coronary surgery*

CAVFs can occur after coronary artery bypass surgery when sequential saphenous vein bypass grafts are inadvertently anastomosed between coronary arteries and cardiac veins. Furthermore, a fistula between the LAD-saphenous vein bypass graft and right ventricle was reported ten years following CABG<sup>57</sup> and a single right coronary artery-pulmonary artery arteriovenous fistula was reported 16 years after surgical correction of atrial septal defect.<sup>58</sup> Also after mitral valve replacement, due to right atrial artery injury, a postoperative fistula between a right atrial artery and the right atrium (site of access for cardiopulmonary bypass) has been described.<sup>59</sup> After closed commissurotomy, it has been demonstrated that selective

coronary angiography prior to surgical intervention in patients with previous cardiac surgery is useful since a fistula between the first diagonal artery and the left lower pulmonary vein was recognized occurring 21 years after closed mitral valvulotomy.<sup>60</sup> Such a CAVF may also develop after septal myectomy for hypertrophic obstructive cardiomyopathy.<sup>61</sup> Blunt or sharp surgical traumas of the heart are held responsible for the induction of such fistulas in the absence of bypass grafting.

#### *Secondary to severe coronary atherosclerosis and complicating MI*

CAVFs may be a consequence of coronary atherosclerosis especially in the presence of severe stenosis or total occlusion. Various mechanisms have been proposed to explain the fistula formation in the presence of severe narrowing and after myocardial infarction.

Postulated mechanisms of CAVF formation after MI are as follows:

- New growth or dilatation of arterioluminal vessels or capillaries or anastomosis between Thebesian veins;<sup>62</sup>
- Collateral channel formation stimulated by myocardial hypoxia and reopening with anastomosis of the Thebesian veins,<sup>63-66</sup>
- Rupture of the proximal portion of the coronary artery with extravasation and hematoma formation rupturing into a neighbouring cardiac vessel or chamber;<sup>64</sup>
- Growth of new vessels to a thrombus;<sup>62</sup>
- Erosion of a localized cardiac chamber calcification into a coronary vessel.<sup>64</sup>

It has been demonstrated angiographically and at autopsy that an acquired CAVF after MI had developed from the diagonal branch of the LAD and had communicated with the left ventricular cavity.<sup>62,67</sup> Phillips et al. described a CAVF from the LAD to the great cardiac vein detected on selective coronary angiography following myocardial infarction.<sup>68</sup>

Lee and colleagues described a patient who developed a circumflex coronary artery fistula that communicated with a left ventricular false aneurysm after MI.<sup>69</sup> Nevertheless it remains difficult to differentiate, on clinical, electrocardiographic and angiographic grounds, between congenital and acquired CAVFs, detected after MI.<sup>30,65</sup>

#### *Complicating PTCA procedures*

Iatrogenic CAVF formation is a very rare complication of percutaneous transluminal coronary angioplasty (PTCA). This complication develops due to perforation of the coronary artery during PTCA or rupture of a false aneurysm into a cardiac chamber after PTCA. This complication has been reported with angioplasty to native coronary arteries<sup>70-74</sup> and via a venous bypass graft to the left anterior descending coronary artery.<sup>75</sup>

### **Findings at necropsy**

The following findings have been recognized at post-mortem investigation: dilated epicardial coronary arteries participating in the fistula formation and enlargement of cardiac chamber at which the fistula terminates. Furthermore, vascular channels lined with endothelium communicating with the cardiac chamber have been shown and left ventricular hypertrophy associated with subendocardial fibrosis has also been reported.<sup>76</sup>

At necropsy of a patient with congenital multiple coronary artery-left ventricular fistulas Black and associates found, on microscopic examination, thin-walled vascular channels lined by endothelium and communicating with the left ventricular lumen. The size of these vessels ranged between 10 and 500  $\mu$ . Underlying fibrous tissue was also present.<sup>76</sup> Shimizu and colleagues found during post-mortem examination of a patient with an acquired CAVF post myocardial infarction that the walls of the communicating vessels were thick walled and the elastic membrane could be identified, confirming their arterial descent.<sup>62</sup> Histologically, it has been shown that the vessels participating in the formation of CAVFs have an arterial origin by demonstrating a thick muscular media layer and a well-defined internal and external

elastic membrane.<sup>77</sup>

## **Types of CAVFs**

### *Anatomical types*

The individual anatomy of the fistula varies considerably. Wearn et al. categorized the CAVFs into three anatomical types.<sup>78</sup>

- I- Arterioluminal type: Originates directly from the coronary arteries to the lumen of a heart chamber. They appeared to be more numerous in the ventricles than in the atria.
- II- Arteriosinusoidal type: From the coronary arteries via myocardial sinusoids into the lumen of a ventricle. The communication is through the myocardial sinusoidal network.
- III- Arterio-capillary type: The fistula drains into the capillaries and then through the Thebesian system into a cardiac chamber.

### *Angiographic Morphology*

Several Angiographic classifications of CAVFs have been reported. One of these divides CAVFs into two types:<sup>33</sup>

Type 1: The fistula consists of one large channel or one or more small but discrete channels terminating into the pulmonary trunk.

Type 2: The fistula is composed of a plexiform network of vessels.

Another method classifies the disorder into five types.<sup>26</sup>

## **Associated lesions**

About 20% of patients with CAVFs have an associated congenital cardiac anomaly. The commonest are aortic or pulmonary valvular atresia or patent ductus arteriosus.<sup>11</sup> In another series by Upshaw, associated congenital cardiovascular defects were present in 34% of the patients.<sup>79</sup>

In various series, it has been reported that CAVFs may incidentally coexist with almost any congenital or acquired disorder.<sup>80,81</sup>

## **Cardiac lesions frequently associated with CAVFs**

The association of patent ductus arteriosus (Botalli) with CAVFs has frequently been found.<sup>11,12,79,81,82</sup> Other associated cardiac lesions are pulmonary valvular atresia,<sup>11,79,81</sup> aortic valvular atresia<sup>79,82</sup> with reported mortality shortly after birth,<sup>55</sup> and ventricular or atrial septal defect.<sup>79,81</sup>

## **Cardiovascular lesions probably fistula-related associated with CAVFs**

CAVFs have been associated with premature coronary atherosclerosis.<sup>63,64,66,68,81</sup> Bilateral CAVFs are rare and multiple ones are even rarer.<sup>31,32,76,80,83-87</sup>

## **Disorders incidentally coexisting with CAVFs**

Association of CAVFs with congenital, rheumatic or degenerative valvular disease have been reported.<sup>33,64,88</sup> Mitral regurgitation secondary to papillary muscle dysfunction has been described,<sup>46</sup> tetralogy of Fallot;<sup>46,82,89</sup> asymmetric septal hypertrophy;<sup>26</sup> and tricuspid valvular atresia.<sup>81</sup> Furthermore, CAVFs have been reported incidentally in association with temporal arteritis,<sup>86</sup> persistent left superior vena cava<sup>90</sup> and in concurrence with chronic myeloproliferative disorder.<sup>91</sup>

## **The clinical picture of CAVFs**

### **Asymptomatic presentation**

Patients with CAVFs are to a great extent asymptomatic. It has been reported that more than

half of the patients with CAVFs may be asymptomatic.<sup>92</sup>

### **Symptoms of complications**

Unless the CAVF is large enough to cause a considerable left-to-right shunt (Qp: Qs ratio  $\geq$  2), this anomaly does not usually produce symptoms before the age of 30 years.

It has been shown that fistulous communication between a coronary artery and a cardiac chamber may cause anginal symptoms, although ECGs are normal.<sup>31</sup> In patients with CAVFs no signs of redistribution on thallium-201 perfusion scintigraphy were found.<sup>93</sup>

The majority of CAVFs are found incidentally during coronary angiographic studies. They produce no symptoms and show a benign long-term course.<sup>14</sup> Fifty-nine percent of patients were asymptomatic in the review of Rittenhouse in 1975.<sup>92</sup>

The reported symptoms of CAVFs are: angina pectoris, atypical chest pain, syncope, dizziness, fatigue, dyspnoea at rest and during exertion, palpitations, peripheral oedema and hemoptysis.<sup>92,94</sup> In the first two decades of life, CAVFs hardly ever produce any symptoms, but in adulthood they may be associated with an increased risk of complications giving rise to disorders such as congestive heart failure.<sup>9,90,95</sup>

Congestive heart failure (CHF) has been shown to be a common cause of death in untreated cases.<sup>96</sup> CHF was found in slightly more than fifty percent of cases in the series of Ogden.<sup>97</sup>

Cardiac failure in early infancy with a large size left-to-right shunt was reported by McNamara<sup>11</sup> but CHF generally occur after 30 years of age.<sup>95</sup> In the series of Liberthson and associates, it was noted that none of the symptomatic patients aged twenty years and older had symptoms or complications before the age of 30 years, although all were symptomatic after that age. Shunt size may still contribute to clinical sequelae with advancing age since a significant difference in mean Qp/Qs (1.7:1 versus 1.4:1,  $p < 0.05$ ) has been shown in a non-longitudinal study in older reported patients who had neither symptoms nor complications.<sup>95</sup>

Recurrent respiratory tract infections have been reported in patients with CAVFs.<sup>31</sup> Myocardial infarction has also been reported in adults and children.<sup>10,46,80,82,98</sup>

Several reports have included CAVF patients associated with atrial fibrillation.<sup>11,12,26,84,90,99,100</sup>

Rarely, sudden death due to rupture of an aneurysm<sup>95,101</sup> was reported. Furthermore, ventricular tachyarrhythmias<sup>102</sup> and atrioventricular valvular regurgitation<sup>46</sup> have been postulated to be subsequent to the CAVFs.

### **Physical examination**

The findings on physical examination are very variable in patients with a CAVF but it can be suspected clinically when any or all of the following signs are present during physical examination.

Arterial and venous pressures: The pulse pressure may be normal or widened. The jugular venous pressure is initially normal and in later stages elevated in cases of large shunts to the right heart.

Continuous murmur: On physical examination, a continuous murmur may be heard at an unusual location.<sup>82</sup> In some cases the continuous murmur is absent.<sup>14</sup> When the murmur is present, the location of the murmur is related to the drainage site of the fistula.

When the fistula drains into the right atrium, the continuous murmur is best heard in the second and third right intercostal parasternal areas. When entry is into the right ventricle, the maximum continuous murmur is located at the third, fourth and fifth left intercostal spaces.

When drainage into the pulmonary artery occurs, the maximum point of the murmur is heard at the second or third left intercostal space. Differentiation by auscultation between the murmur of patent ductus arteriosus and a CAVF draining into the pulmonary artery is difficult.

### **Diagnostic Approach**

In the past, the diagnosis of CAVFs was made on clinical grounds but because of the inaccuracy of clinical diagnosis it was of little value. Furthermore, the clinical diagnosis is non-specific because none of the signs or symptoms of CAVFs are unique to this condition and all may be caused by other cardiac conditions.

CAVFs may cause small (Qp/Qs ratio  $< 1.5$ ) or large (Qp/Qs ratio  $\geq 2.0$ ) left-to-right and



rarely left-to-left (arterio-systemic) shunts. Most fistulas drain into the low-pressure right heart chambers, the coronary sinus and the pulmonary artery, creating a left-to-right shunt. This may result in right or left ventricular overload depending on the site of termination of the CAVFs giving rise to exertional dyspnoea, or overt congestive heart failure. Drainage into the left atrium, the left ventricle and the bronchial circulation (arterio-arterial shunt) is infrequent. Small left-to-right shunts are relatively common.<sup>14</sup>

The significance of such a communication depends upon the magnitude and duration of shunting, whether or not myocardial blood flow is affected by the shunt, and the presence or absence of coexisting cardiac or coronary abnormalities. The left-to-right shunts are difficult or impossible to detect. Coronary blood flow represents only 4 to 6% of the cardiac output, corresponding to 280 to 420 ml/min.

The shunts, small as they are, may however be an important fraction of the total coronary blood flow. The volume of shunted blood may be considerable; actual measurements of 700 to 1,800 ml/min have been taken during operations.<sup>103</sup> In 1978, Kiso et al,<sup>104</sup> described a patient with right coronary-to-left ventricular fistula where intraoperative mean right coronary flow was recorded as 315 ml/min and dropped to 35 ml/min after repair of the fistula, suggesting that a large amount of blood, around 280 ml/min, was stolen by the fistula. The physiological effect of a coronary artery fistula depends on the size of the shunt, on the pressure gradient difference over the shunt and on whether it empties into the left or the right side of the heart. When the fistula empties into the left side or to the pulmonary trunk there is increase in volume load on the left ventricle. When the CAVFs terminate into the left ventricular cavity a hemodynamic pattern mimicking aortic regurgitation occurs.

Several non-invasive and invasive methods for the diagnosis of suspected CAVFs have been introduced in the past two decades.

#### **Electrocardiography and Roentgenography**

It is widely accepted that electrocardiography and chest roentgenography are not helpful in establishing the diagnosis.<sup>82,105</sup> When the CAVF is large enough, chest X-ray shows the secondary hemodynamic changes including cardiac enlargement or increased pulmonary vasculature, depending on the termination site. A large CAVF could be suggested on chest X-ray.<sup>106</sup>

CAVFs may rarely cause calcification on the chest X-ray. Intracardiac calcifications have been reported in patients with CAVFs.<sup>107</sup> A very rare radiographic finding is that of a localized excrescence on either heart border.<sup>38</sup>

#### **Phonocardiography**

In the seventies, phonocardiography was shown to be of great importance in distinguishing CAVF from other anomalies with a continuous murmur,<sup>108</sup> but this was challenged by others.<sup>31</sup>

#### **Radionuclide exercise perfusion scanning**

Myocardial perfusion scan could not demonstrate a reversible ischemia or "steal" phenomenon in patients with CAVFs associated with atypical angina.<sup>26,93</sup> Oshiro and associates demonstrated the occurrence of multiple perfusion defects in a patient with multiple coronary-left ventricular fistulas in the presence of typical angina.<sup>85</sup> The occurrence of "coronary steal" phenomenon in coronary artery-to-left ventricular fistula has been previously documented by Cheng.<sup>109</sup>

#### **Doppler-echocardiography**

Recent reports have suggested the supplementary role of several non-invasive techniques in the diagnosis and follow-up of these anomalies, such as Doppler echocardiography,<sup>110-115</sup> magnetic resonance imaging (MRI)<sup>36,116</sup> and transesophageal echocardiography (TEE).<sup>90,117-119</sup> Echocardiographic diagnostic features suggestive for CAVFs are:

- Demonstration of a dilated "proximal" coronary artery by 2-dimensional echocardiography;

- Assessment of the continuous flow turbulence in the involved drainage sites by pulsed Doppler echocardiography.

These diagnostic criteria, although widely accepted, are not well defined and therefore coronary artery dilatation from other causes should be differentiated and recognised. Previous medical history may be of importance in such interpretation, especially when patients have coronary artery disease secondary to Kawasaki's disease.<sup>111,120</sup> In such a disease coronary artery dilatation, aneurysms and/or obstructive lesions may occur.<sup>121,122</sup>

#### **Indicator dilution techniques**

Querimit and his colleagues were the first to use the indicator-dilution technique to localise left-to-right shunt in patients with CAVFs.<sup>123</sup> Using this technique, they applied indocyanine green (Cardio-Green) as an indicator. Indicator-dilution curves were applied using indocyanine green at a dose of 0.06 mg/kg per injection. The shunt was maximally visible after selective injection of the dye into the suspected coronary artery participating in the fistula formation.

Dye-dilution curves failed to differentiate patent arterial duct from CAVFs<sup>105</sup> and proved normal in the series of Iskandrian and associates.<sup>33</sup> Hydrogen studies also proved negative in the series of Iskandrian and associates. Right-heart catheterisation alone will not disclose a coronary artery fistula to the left heart. The magnitude of the shunt is often small and each shunt detection technique has its limitations. The left-to-right shunts of CAVFs may be impossible to detect. Liberthson and colleagues<sup>95</sup> and Urrutia-s et al.<sup>80</sup> found no statistically significant difference in the mean shunt size between symptomatic and asymptomatic patients.

#### **Selective coronary arteriography**

Selective coronary arteriography is considered to be the "gold standard" and cardiac catheterisation is the investigation of choice as these studies allow assessment of hemodynamics, quantitation of the intracardiac shunt, delineation of the fistulous pathway and the entire anatomy of the coronary vessels. Coronary angiography is essential for definite diagnosis of CAVFs (Fig 3 and 4). Coronary angiographic diagnostic features suggestive for CAVFs are:

- The coronary vessel involved in the congenital CAVF formation is usually tortuous and dilated;
- The contrast medium spurts through the fistula into the affected cardiac chamber. The involved cardiac chamber may also be enlarged;
- Identifiable origin, pathway and termination of the fistula.

It has been postulated that CAVFs are visualised only because of the pressure of injection during selective coronary angiography and may very well be functionally closed at other times.<sup>33,63</sup> There is an important limitation with respect to the applicability of the angiographic diagnostic criteria. This limitation is related to technique and quality of coronary arteriograms. Poor technique often results in incomplete filling of the coronary artery that may result in angiograms that do not provide sufficient information to achieve an accurate diagnosis.

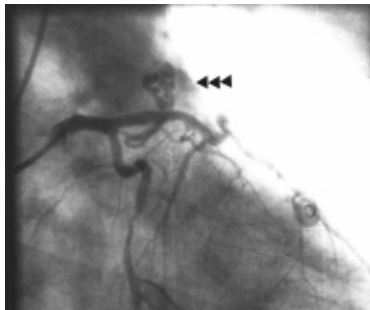

Fig. 3

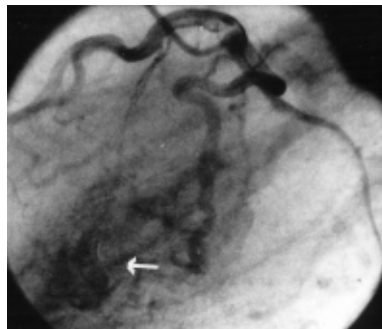

Fig. 4

Fig.3 Frame of right anterior oblique projection of left coronary artery showing proximally originating LAD-PA fistula (arrow).

Fig.4 Frame of left lateral projection of left coronary artery illustrating obtuse marginal-LV fistula (arrow).

### Differential Diagnosis

All lesions associated with continuous cardiac murmur should be considered. Generally, there are two mechanisms responsible for continuous murmurs:

1. Abnormal vascular flow: may occur in either arteries or veins.
2. Translesional shunt flow: may be intracardiac or extracardiac.

The definition of a continuous murmur is a murmur beginning in systole and extending through the second heart sound into diastole. The differential diagnoses of most common causes of a continuous murmur include:

*In normal physiologic conditions:* The venous hum: is the most frequent, innocuous and not associated with circulatory disorders or symptoms. This murmur is characteristically louder in diastole and is obliterated when the jugular vein is gently compressed. The mammary murmur is heard in about 15% of pregnant women during the second or third trimester of pregnancy.<sup>124</sup>

*In abnormal conditions:* The diagnosis of coronary arteriovenous fistula is important because it plays a role in the differential diagnosis of cardiac disorders associated with a continuous precordial murmur, such as:<sup>105</sup> Patent ductus arteriosus (Botalli); ruptured aneurysm of a sinus of Valsalva into the right heart; supralvalvular pulmonic stenosis; arteriovenous malformation of chest wall;<sup>6</sup> aorta-right ventricle fistula; aorto-pulmonary fenestration (window); ventricular septal defect with aortic regurgitation; arteriovenous fistula of the internal mammary vessels;<sup>125,126</sup> pulmonary arteriovenous fistula;<sup>127</sup> anomalous pulmonary arteries or veins;<sup>128</sup> and solid mediastinal mass.<sup>129</sup> Continuous murmurs are rarely heard in solid tumors of the chest.

CAVFs should enter the differential diagnosis of intracardiac calcifications, as calcified lesions have been reported in association with CAVFs.<sup>107</sup>

### Prognosis and natural History

Small coronary arteriovenous fistulas have a benign natural history.<sup>14</sup> The fate of CAVFs, with or without aneurysmal formation, is still unknown, but spontaneous regression of congenital and acquired fistulas has been reported.<sup>46,50</sup> CAVFs may expose thrombosis and spontaneous closure<sup>130-133</sup> or may rarely rupture causing hemopericardium and death.<sup>95,101</sup>

The natural history of most large CAVFs involves the development of a progressive dilatation and elongation of the affected coronary artery and the vessel or chambers receiving the

shunted blood, as a result of a progressive increase in blood flow.<sup>105</sup> It has been reported that neighbouring intrathoracic structures may be obstructed secondary to massive dilatation of the recipient coronary artery or cardiac chamber.<sup>35,37</sup> On the other end of the spectrum it has been shown that CAVFs are compatible with longevity.<sup>40</sup>

### **Complications of CAVFs**

The incidence of fistula-related complications appears to increase with older age groups.<sup>95</sup> Several complications (intracardiac and extracardiac) have been encountered in patients with CAVFs.

#### **Excessive load to cardiac chambers**

- Chronic volume overload as a consequence of intracardiac shunting can give rise to increased left ventricular end-diastolic pressure, left ventricular hypertrophy (LVH) and in older age groups to congestive heart failure.<sup>90,95</sup> Evidence of LVH or strain was most frequently noted regardless of which cardiac chamber the fistula drained into. Electrocardiographic changes of right or left ventricular overload were noted in 61% of patients with CAVFs.<sup>11</sup>
- Massive dilatation of recipient cardiac chamber could lead to mechanical interference with the cardiac function.<sup>35-37</sup> Floyd<sup>35</sup> described a case with giant atriomegaly subsequent to right coronary artery-left atrial fistula causing distortion of the heart and incomplete obstruction of the inferior vena cava. Rein and associates<sup>37</sup> described a four-year-old girl with congenital right coronary artery-right atrial fistula and infective endocarditis with concurrent unexplained facial swelling. Echocardiography was able to demonstrate the giant fistula causing obstruction of the distal superior vena cava. The fistula was successfully ligated.
- Cardiac rhythm disturbances: Atrial fibrillation and ventricular tachyarrhythmias have been associated with CAVFs.<sup>11,12,26,84,90,92,99,102</sup> Atrial fibrillation is frequently seen in older patients with CAVFs and may result in congestive heart failure when it occurs.<sup>107</sup>

#### **Coronary complications**

- Ipsilateral myocardial infarction in children and adults.<sup>10,46,80,82,92,98,134</sup> In 1972, Morgan and associates<sup>46</sup> were among the first to describe electrocardiographic evidence of infarction in children with CAVFs.
- "Coronary steal" producing myocardial ischemia due to diversion of blood from the high-resistance capillary bed to the low-resistance fistula seems to occur much less commonly than expected.
- Mechanical interference secondary to massive aneurysmal enlargement of recipient coronary artery.<sup>34-37</sup> Dilatation of the coronary artery participating in the CAVFs varies significantly. CAVFs can be complicated by enormous aneurysmal dilatation of the coronary artery (8-10 cm in diameter and 26 gram total weight), which may appear as a mediastinal mass.<sup>34</sup> In 1958, Edwards<sup>8</sup> suggested that aneurysmal dilatation results from structural weakening of the vessel wall due to excessive blood flow through the CAVFs.
- Premature coronary atherosclerosis.<sup>36,92</sup> It is thought that the shear-induced intimal damage, as a result of high flow through the fistula-related vessel, may form a substrate for the development of premature coronary atherosclerotic lesions.

#### **Valvular and endocardial complications**

- Valvular regurgitation secondary to papillary muscle dysfunction has been described in children and adults with CAVFs.<sup>46</sup>
- Infective endocarditis. In 1962 Lee and colleagues<sup>135</sup> demonstrated experimentally in dogs that the presence of an arteriovenous fistula not only renders the animal more susceptible to bacteremia but also tends to prolong the bacteremia and lengthen the

time needed for effective antibiotic therapy.<sup>135</sup> Infective endocarditis is a real complication of coronary arteriovenous fistulas, with an incidence varying from 0% to 12%.<sup>9,11,95,96</sup> Consequently, after the fistula is detected, endocarditis prophylaxis should be recommended in these patients.

### **Extracardiac Complications**

- Hemopericardium secondary to rupture of an associated aneurysm.<sup>95,101</sup> Fistula dissection and rupture are rare in CAVFs. Habermann and colleagues have reported a single case of sudden cardiac death secondary to rupture of CAVF in an adult in 1963.
- Moderate pulmonary hypertension. This has been reported in literature in only few patients especially when the left-to-right shunt magnitude is considerable.<sup>11,13,36,95</sup>

### **Treatment and management of CAVFs**

As soon as the diagnosis is established, antibiotics should be given as prophylaxis against subacute bacterial endocarditis (flow-chart, table 4).

### **Conservative approach**

Asymptomatic patients with small shunts should be treated conservatively,<sup>125</sup> since small fistulas appear to have a relatively benign natural history.<sup>14</sup> CAVFs may remain asymptomatic for decades and they may close spontaneously.<sup>131</sup> This spontaneous obliteration of the CAVFs establishes a rationale for clinical observation in such patients. But periodical non-invasive analysis remains recommended to establish any regression or progression of the CAVFs.

### **Surgical approach**

Biörck and Crafoord performed the first successful ligation in 1947.<sup>20</sup> It is generally agreed that CAVFs with large left-to-right shunt (Qp: Qs ratio  $\geq 2$ ) should be treated, depending on the type, size and localisation of shunt, either surgically or using a percutaneous transcatheter embolization technique. Patients should be selected for operation according to the magnitude of left-to-right shunt, symptoms and ECG changes.<sup>125</sup> It has been reported that surgical treatment has resulted in a low mortality from 0 to 4% and morbidity from 10 to 15%.<sup>9,15,80,92,95</sup> It has been suggested that the best age group for operative repair of these CAVFs is between 10 and 45 years. Operative correction in patients younger than 10 years or older than 45 years of age is probably coupled with an increased risk of morbidity and mortality.<sup>79,95</sup> In a review done by McNamara et al. through 1967, 57% of all reviewed cases (93/163) were treated surgically. In these 93 operated patients only three (3/93) operative deaths were reported.<sup>11</sup>

### **Non-surgical approach**

Pharmacological: Therapy with  $\beta$ -blockers has been successfully established in patients with coronary arterio-arterial and arterio-venous fistulas.<sup>85,109,136,137</sup> Also calcium channel blockers are reported to be effective.<sup>138</sup> Improving and counterbalancing the diminished coronary blood oxygen supply in relation to the myocardial blood demand probably produce these effects. These types of therapy, which reduce the myocardial oxygen demand, are recommended especially when surgical repair seems to be technically impossible. These therapeutic modalities, however, are never tested in a randomised trial.

Percutaneous transcatheter embolisation techniques (detachable balloon, microcoils, embolisation particles (or microspheres): Although several authors believe that CAVFs should be repaired when diagnosed,<sup>11,38,95,108</sup> the role of surgery in asymptomatic patients with CAVFs remains to be defined. The generally small size of the fistulas, and the tendency for spontaneous closure argue for nonsurgical management.<sup>50,130-133</sup> Not only successful closure of CAVFs using transcatheter embolisation techniques has been reported<sup>93,139-142</sup> but also unsuccessful procedures have been described occurring in an octogenarian.<sup>143</sup>

### **Surgical indications**

The indication for operation depends on:

1. Fistula-related indications: The site and type of the CAVFs; magnitude of the left-to-right shunt ( $Q_p: Q_s \geq 2.0$ );<sup>92</sup> and the degree of dilatation of the recipient coronary or cardiac chamber.
2. Symptomatic relief of chest pain or congestive heart failure in the absence of other causes in patients with large left-to-right shunt ( $Q_p: Q_s \geq 2.0$ ).<sup>11,77</sup>
3. Prevention of development of future complications: Congestive heart failure, pulmonary hypertension,<sup>11,79</sup> coronary insufficiency,<sup>97</sup> and rupture of an associated aneurysm.<sup>95,101</sup>
4. Prevention of bacterial endocarditis.
5. Prevention of eventual mechanical obstruction or mechanical interference with cardiac function.

### **Conclusion**

Congenital coronary artery fistulas are intriguing entities with unsolved aetiological issues. They possess different angiographic morphological spectra varying between discrete single channels and multiple serpiginous network of vessels. Antibiotic prophylaxis against endocarditis for patients with CAVFs is advised. For patients with symptomatic CAVFs, individualized surgical or interventional procedures, depending on the anatomy of the fistula and concomitant heart disease, are chosen. Pharmacological treatment is reserved for "symptomatic" small CAVFs shunts or inoperable cases.

## Abbreviations and acronyms

---

AVM	Arteriovenous malformation
CAF	Coronary artery fistula
CAG	Coronary angiography
CAVF	Coronary arteriovenous fistula
CC	Cardiac chamber
CHF	Congestive heart failure
CS	Coronary sinus
CV	Cardiac vein
IE	Infective endocarditis
IVC	Inferior vena cava
LA	Left atrium
LAD	Left anterior descending coronary artery
LV	Left ventricle
LVH	Left ventricular hypertrophy
MI	Myocardial infarction
MIBI	Technetium-99m methoxy isobutyl isonitrile
MRI	Magnetic resonance imaging
PA	Pulmonary artery
PDA	Patent ductus arteriosus
PTCA	Percutaneous transluminal coronary angioplasty
PTE	Percutaneous transcatheter embolization
RA	Right atrium
RV	Right ventricle
SBE	Subacute bacterial endocarditis
SIN	Cardiac sinusoids
SVC	Superior vena cava
TEE	Transoesophageal echocardiography
TV	Thebesian veins

---

## References

1. Salo JA, Ketonen PS. Congenital arteriovenous fistula in the chest wall. *Scand J Thor Cardiovasc Surg* 1988; 22:7-10.
2. Szilagyi DE, Elliott JP, DeRusso FJ, Smith RF. Peripheral congenital arteriovenous fistulas. *Surgery* 1965; 57:61-81.
3. Vollmar JF, Stalker CG. The surgical treatment of congenital arteriovenous fistulas in the extremities. *J Cardiovasc Surg* 1976; 17:340-7.
4. Baim DS, Grossman W. Percutaneous approach and transseptal catheterization. In: *Cardiac catheterization and angiography*, 3d edition. Philadelphia: Lea & Febiger. 1986:59-75.
5. Waksman R, King SB 3<sup>rd</sup>, Douglas JS, Shen Y, Ewing H, Mueller L, Ghazzal ZM, Weintraub WS. Predictors of groin complications after balloon and new-device coronary intervention. *Am J Cardiol* 1995; 75:886.
6. Said SAM, Bloemendaal K. Successful venous coronary artery bypass grafting in association with congenital arteriovenous malformation of the chest wall and left upper extremity. *Cardiologie* 1996; 3:151-3.
7. Levin DC, Fellows KE, Abrams HL. Hemodynamically significant primary anomalies of the coronary arteries. Angiographic aspects. *Circulation* 1978; 58:25-34.
8. Edwards JE. Anomalous coronary arteries with special reference to arteriovenous-like communications. *Circulation* 1958; 17:1001-6.
9. Wilde P, Watt I. Congenital coronary artery fistulae: six new cases with a collective review. *Clin Radiol* 1980; 31:301-11.
10. St John Sutton MG, Miller GAH, Kerr IH, Traill TA. Coronary artery steal via large coronary artery to bronchial artery anastomosis successfully treated by operation. *Br Heart J* 1980; 44:460-63.
11. McNamara JJ, Gross RE. Congenital coronary artery fistula. *Surgery* 1969; 65:59-69.
12. Sakakibara S, Yokoyama M, Takao A, Nogi M, Gomi H. Coronary arteriovenous fistula. *Am Heart J* 1966; 72:307-14.
13. Davison PH, McCracken BH, McIlveen DJ. Congenital coronary arteriovenous aneurysm. *Br Heart J* 1955; 17:569-62.
14. Yamanaka O, Hobbs RE. Coronary artery anomalies in 126,595 patients undergoing coronary arteriography. *Cathet cardiovasc Diagn* 1990; 21:28-40.
15. Kirklin JW, Barratt-Boyes BG. *Cardiac surgery* 2d edition. Churchill Livingstone, 1167-93.
16. Said SAM, Geeraedts LGM. Ventriculo-venous communications in adults: Ventriculographic observations in two female patients. *Int J Cardiol* 1997; 62:161-5.
17. Wenger NK. Rare causes of coronary artery disease. In Hurst JW (ed): *The Heart*. New York, McGraw-Hill, 1978, 1348-9.
18. Krause W. Über den Ursprung einer akzessorischen A. coronaria aus der A. pulmonalis. *Z Rationell Med* 1865; 24:225-27.
19. Trevor RS. Aneurysm of the descending branch of the right coronary artery situated in the wall of the right ventricle and opening into the cavity of the ventricle, associated with great dilatation of the right coronary artery and non-valvular infective endocarditis. *Proceedings of the Royal Society of Medicine* 1912; 5:20-26.
20. Biörck G, Crafoord C. Arteriovenous aneurysm of the pulmonary artery simulating patent ductus arteriosus botalli. *Thorax* 1947; 2:65-74.
21. Munkner T, Petersen O, Vesterdal J. Congenital aneurysm of the coronary artery with an arteriovenous fistula. *Acta Radiologica* 1958; 50:333-40.
22. Kimbiris D, Dasparian H, Knibbe P, Brest AN. Coronary artery-coronary sinus fistula. *Am J Cardiol* 1970; 26:532-39.
23. Huffman T, Leighton RF, Goodwin RS, Ryan JM, Wooly CF. Continuous murmurs associated with shunts in the acyanotic adult: an anatomic classification. *Am J Med* 1970; 49:160-9.
24. Rohmer J. In *aangeboren hartafwijkingen*. Arntzenius AC, Moolaert AJMG, eds.



- Bunge 1986.
25. Bogers AJJC. Congenital coronary artery anomalies: clinical and embryological aspects. Thesis, Leiden, 1989.
  26. Gillebert C, Van Hoof R, Van de Werf F, Piessens J, De Geest H. Coronary artery fistula in an adult population. *Eur Heart J* 1986; 7:437-43.
  27. Aelfers EWM, Huige MC. Coronairfistels: een opmerkelijke toevalsbevinding. *Medisch Journaal* 1992; 4:220-22.
  28. Tiraboschi R, Salomone G, Napoleone A, Bande A, Valsecchi O, Carminati M, Merlo M, Parenzan L. Congenital coronary fistulae. Comments on 9 surgical cases. *G Ital Cardiol* 1988; 18:104-08.
  29. Toda S, Nakamura A, Iwamoto T, Nakaji S: Successful surgical treatment of aortic regurgitation with coronary artery fistula due to blunt chest trauma. *Acase report. J Jpn Assoc Thorac Surg* 1991; 39:1087-1092.
  30. Somsen GA, Liem KS. Coronary artery-left ventricular fistulas probably due to transmural myocardial infarction: a case report. *Cardiologie* 1994; 1:65-7.
  31. Eie H, Hillestad L. Arterio-venous fistulae of the coronary arteries. A report of six cases. *Scand J Thor Cardiovasc Surg* 1971; 5:34-38.
  32. Goebel N von, Gander MP, Steinbrunn W. Small coronary artery fistulae. *Ann Radiol* 1979; 22:277-79.
  33. Iskandrian AS, Kimbiris D, Bemis CE, Segal BL. Coronary artery to pulmonary artery fistulas. *Am Heart J* 1978; 96:605-09.
  34. Meyer MH, Stephenson HE, Ketas TE, Martt JM. Coronary artery resection for giant aneurysmal enlargement of arteriovenous fistula. *Am Heart J* 1967; 74:603-13.
  35. Floyd WL, Young WG, Johnsrude IS. Coronary arterial-left atrial fistula: Case with obstruction of the inferior vena cava by a giant left atrium. *Am J Cardiol* 1970; 25:716-22.
  36. Wertheimer JH, Toto A, Goldman A, DeGroat T, Scanlon M, Nakhjavan FK, Kotler M. Magnetic resonance imaging and two-dimensional and Doppler echocardiography in the diagnosis of coronary cameral fistula. *Am Heart J* 1987; 114:159-62.
  37. Rein AJJ, Yatsiv I, Simcha A. An unusual presentation of right coronary artery fistula. *Br Heart J* 1988; 59:598-600.
  38. Gasul BM, Arcilla RA, Fell EH, Lynfield J, Bicoff JP, Luan LL. Congenital coronary arteriovenous fistula. Clinical, phonocardiographic, angiocardiographic and hemodynamic studies in five patients. *Pediatrics* 1960; 25:531-60.
  39. Lester RG. Congenital communication of a coronary artery with a cardiac chamber or the pulmonary trunk. *Circulation* 1961; 24:171-9.
  40. Williams RR, Kent GB, Edwards JE. Anomalous cardiac blood vessel communicating with the right ventricle: observations in a case of pulmonary atresia with an intact ventricular septum. *Arch Pathol* 1951; 52:480-7.
  41. Sissman NJ, Abrams HL. Bidirectional shunting in a coronary artery-right ventricular fistula associated with pulmonary atresia and an intact ventricular septum. *Circ* 1965; 32: 582-8.
  42. Dusek J, Ostadal B, Duskova M. Postnatal persistence of spongy myocardium with embryonic blood supply. *Arch Pathol* 1975; 99:312-7.
  43. Mikawa T, Fischman DA. Retroviral analysis of cardiac morphogenesis: Discontinuous formation of coronary vessels. *Proc Natl Acad Sci USA* 1992; 89:9504-8.
  44. Hutchins G, Abigail KH, Moore GW. Development of the coronary arteries in the embryonic human heart. *Circ* 1988; 77(6):1250-7.
  45. Vrancke Peeters MPFM, Gittenberg-de Groot AC, Mentink MMT, Hungerford JE, Little CD, Poelmann RE. Differences in development of coronary vessels and differentiation into arteries and veins in the embryonic quail heart. *Cardiovascular Research* 1997; 36:101-10.
  46. Morgan JR, Forker AD, O'Sullivan, Jr, MJ, Fosburg RG. Coronary arterial fistulas. Seven cases with unusual features. *Am J Cardiol* 1972; 30:432-36.

47. Cheng TO, Adkins PC. Traumatic aneurysm of left anterior descending coronary artery with fistulous opening into left ventricle and left ventricular aneurysm after stab wound of chest. Report of case with successful surgical repair. *Am J Cardiol* 1973; 31:384-90.
48. Jones RC, Jahnke EJ. Coronary artery atrioventricular fistula and ventricular septal defect due to penetrating wound of the heart. *Circ* 1965; 32:995-1000.
49. Tsagaris RJ, Bustamante RA. Coronary arteriovenous fistula and myocardial infarction due to trauma. *Am J Cardiol* 1966; 18:777-80.
50. Sandhu JS, Uretsky BF, Zerbe TR, Goldsmith AS, Reddy S, Kormos RL, Griffith BP, Haresty RL. Coronary artery fistula in the heart transplant patient. A potential complication of endomyocardial biopsy. *Circ* 1989; 79:350-56.
51. Henzlova MJ, Nath H, Bucy RP, Bourge RC, Kirklin JK, Rogers WJ. Coronary artery to right ventricle fistula in heart transplant recipients. *J Am Coll Cardiol* 1989; 14:258-61.
52. Sutsch G, Heywood T, Turina J, Buchi M, Schneider J, Gallino A, Turina M. Coronary artery-right ventricular fistula in a heart transplant patient. *J Heart Transplant* 1990; 9:32-5.
53. Yeoh JK, Anderson ST, Federman J, Esmore D. Coronary artery to middle cardiac vein fistula following endocardial biopsy in a heart transplant patient. *Cathet Cardiovasc Diagn* 1991; 24:108-110.
54. Uchida N, Baudet E, Roques X, laborde N, Billes MA. Surgical experience of coronary artery-right ventricular fistula in a heart transplant patient. *Eur J Cardio-thorac Surg* 1995; 9:106-8.
55. Furniss SS, Mitchell L, Kitipawong P. Coil embolization of a coronary fistula in a post-transplant patient. *Eur Heart J* 1995; 16:1147-8.
56. Saeian K, Vellinga T, Troup P, Wetherbee J. Coronary artery fistula formation secondary to permanent pacemaker placement. *Chest* 1991; 99:780-81.
57. Riahi M, Stone KS, Hanni CL, Fierens E, Dean RE. Right ventricular-saphenous vein graft fistula. *J Thorac Cardiovasc Surg* 1984; 87:628-8.
58. Rothschild AH, Adatepe MH, Magovern GJ, Rothschild MA, Joyner CR. Right coronary artery-pulmonary artery arteriovenous fistula secondary to open heart surgery. *J Am Coll Cardiol* 1985; 6:933-6.
59. Lee RT, Mudge GH, Colucci WS. Coronary artery fistula after mitral valve surgery. *Am Heart J* 1988; 5:1128-30.
60. Pattee PL, Chambers RJ. Acquired postoperative coronary arteriovenous fistula. *Cathet Cardiovasc Diagn* 1992; 26:140-42.
61. Chenzbraun A, Pinto FJ, Meyer B, Stinson EB, Popp RL. Frequency of acquired coronary-cameral fistula after ventricular septal myectomy in hypertrophic cardiomyopathy. *Am J Cardiol* 1993; 71:1244-46.
62. Shimizu M, Yoshio H, Ino H, Takeda R, Okada Y. Histopathologic findings of a left coronary artery fistula to the left ventricle after myocardial infarction. *Cardiology in the Elderly* 1993; 1:335-36.
63. Searcy RA, Stein PD, Ganesan G, Bruce TA. Arterio-atrial shunting in coronary atherosclerosis. *Chest* 1971; 59:398-01.
64. King SB III, Schoonmaker FW. Coronary artery to left atrial fistula in association with severe atherosclerosis and mitral stenosis: Report of surgical repair. *Chest* 1975; 67:361-63.
65. Ryan C, Gertz EW. Fistula from coronary arteries to the left ventricle after myocardial infarction. *Br Heart J* 1977; 39:1147-49.
66. Ray SG, Cowan MD, Kennedy JA. Spontaneously acquired fistula from the right coronary artery to the right ventricular cavity. *Br Heart J* 1992; 67:323-4.
67. Yu R, Sharma B, Franciosa JA. Acquired coronary artery fistula to the left ventricle after acute myocardial infarction. *Am J Cardiol* 1986; 58:557-8.
68. Phillips PA, Libanoff AJ. Arteriovenous communication associated with obstructive arteriosclerotic coronary artery disease and myocardial infarction. *Chest* 1974;

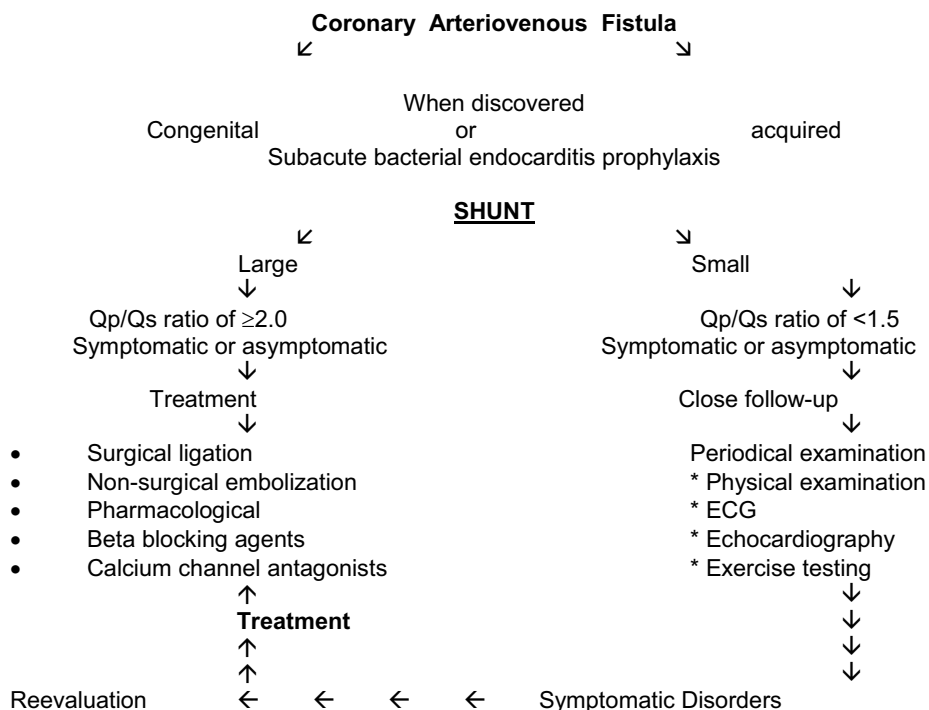
- 65:106-08.
69. Lee KMH, Pichard AD, Lindsay J, Jr. Acquired coronary artery-left ventricular pseudoaneurysm fistula after myocardial infarction. *Am J Cardiol* 1989; 64:824-25.
  70. Meng RL, Harlan JL. Left anterior descending coronary artery-right ventricle fistula complicating percutaneous transluminal angioplasty. *J Thorac Cardiovasc Surg* 1985; 90:387-90.
  71. Cherry S, Vandormael M. Rupture of a coronary artery and hemorrhage into the ventricular cavity during coronary angioplasty. *Am Heart J* 1987; 113:386-8.
  72. Iannone LA, Iannone DP. Iatrogenic left coronary artery fistula-to-left ventricle following PTCA: A previously unreported complication with nonsurgical management. *Am Heart J* 1990; 5:1215-17.
  73. Grill HP, Chew PH, Weiss JL, Merrillat JC, Hill G, Cadden J, Brinker JA. Contrast echocardiographic diagnosis of PTCA-induced coronary artery-left ventricle fistula. *Am J Cardiol* 1991; 121:194-98.
  74. Bata IR, MacDonald RG, O'Neill BJ. Coronary artery fistula as a complication of percutaneous transluminal coronary angioplasty. *Can J Cardiol* 1993; 9:331-5.
  75. El-Omar MM, Hargreaves MR, Venkataraman A, Been M. Coronary ventricular fistula as a complication of PTCA: A case report and literature review. *Int J Cardiol* 1995; 51:113-6.
  76. Black IW, Loo CKC, Allan RM. Multiple coronary artery-left ventricular fistulae: Clinical, angiographic, and pathological findings. *Cathet Cardiovasc Diagn* 1991; 23:133-35.
  77. Gobel FL, Anderson CF, Baltaxe HA, Amplatz K, Wang Y. Shunts between the coronary and pulmonary arteries with normal origin of the coronary arteries. *Am J Cardiol* 1970; 25:655-61.
  78. Wearn JT, Mettier SR, Klumpp TG, Zschiescho LJ. The nature of the vascular communication between the coronary arteries and the chambers of the heart. *Am Heart J* 1933; 9:143-49.
  79. Upshaw, Jr, CB. Congenital coronary arteriovenous fistula. Report of a case with an analysis of seventy-three reported cases. *Am Heart J* 1962; 63:399-404.
  80. Urrutia-s CO, Falaschi G, Ott DA, Cooly DA. Surgical management of 56 patients with congenital coronary artery fistulas. *Ann Thorac Surg* 1983; 35:300-7.
  81. Bogers AJJC, Quaegebeur JM, Huysmans HA. Early and late results of surgical treatment of congenital coronary artery fistula. *Thorax* 1987; 42:369-73.
  82. De Nef JJE, Varghese PJ, Losekoot G. Congenital coronary artery fistula. Analysis of 17 cases. *Br Heart J* 1971; 33:857-62.
  83. Martens J, Haseldoncks C, van de Werf F, De Geest H. Silent left and right coronary left ventricular fistulas. An unusual prominent Thebesian system. *Acta Cardiol* 1983; 38:139-42.
  84. Singham KT, Anuar M. Left coronary to pulmonary artery fistula. *Australas Radiol* 1988; 32:385-86.
  85. Oshiro H, Shimabukuro M, Nakada Y, Chibana T, Yoshida H, Nagamine F, Sunagawa R, Gushiken M, Murakami K, Mimura G. Multiple coronary LV fistulas: Demonstration of coronary steal phenomenon by stress thallium scintigraphy and exercise hemodynamics. *Am Heart J* 1990; 120:217-19.
  86. Cross SJ, Lee HS, Jennings KP. Two coronary artery fistulae in a patient with temporal arteritis and chest pain. *Scot Med J* 1991; 36:117-18.
  87. Podolsky L, Ledley GS, Goldstein J, Kotler MN, Yazdanfar S. Bilateral coronary artery to left ventricular fistulas. *Cathet Cardiovasc Diagn* 1991; 24:271-3.
  88. Baltaxe HA, Wixson D. The incidence of congenital anomalies of the coronary arteries in the adult population. *Radiology* 1977; 122:47-52.
  89. Saxena A, Sharma S, Shrivastava S. Coronary arteriovenous fistula in tetralogy of Fallot: an unusual association. *Int J Cardiol* 1990; 28:373-74.
  90. Kugelmass AD, Manning WJ, Piana RN, Weintraub RM, Baim S, Grossman W. Coronary arteriovenous fistula presenting as congestive heart failure. *Cathet Cardio-*

- vasc Diagn 1992; 26; 19-25.
91. Ho YL, Chen WJ, Wu CC, Lee YT. Acute myocardial infarction in a case of myelofibrosis with patent coronary arteries and arteriovenous fistulae draining into the main pulmonary artery. *Int J Cardiol* 1994; 46:49-51.
  92. Rittenhouse EA, Doty DB, Ehrenhaft JL. Congenital coronary artery-cardiac chamber fistula. Review of operative management. *Ann Thorac Surg* 1975; 20:468-85.
  93. Reidy JF, Anjos RT, Qureshi SA, Baker EJ, Tynan MJ. Transcatheter embolization in the treatment of coronary artery fistulas. *J Am Coll Cardiol* 1991; 18:187-92.
  94. Senac JP, Adda M, Molina L, Thevenet A, Puech P, Grolleau R. Communications anormales entre arteres coronaires et branches peripheriques des vaisseaux pulmonaires. A propos de deux cas. *Ann Radiol* 1979; 22:280-84.
  95. Libერთhson RR, Sagar K, Berkoben JP, Weintraub RM, Levine FH. Congenital coronary arteriovenous fistula. Report of 13 patients, review of the literature and delineation of management. *Circulation* 1979; 59:849-54.
  96. Ogden JA, Stansel HC. Coronary arterial fistulas terminating in the coronary venous system. *J Thorac Cardiovasc Surg* 1972; 63:172-82.
  97. Ogden JA. Congenital variations of the coronary arteries. Thesis, Yale University, School of Medicine, 1968.
  98. Shirai K, Ogawa M, Kawaguchi H, Kawano T, Nakashima Y, Arakawa K. Acute myocardial infarction due to thrombus formation in congenital coronary artery fistula. *Eur Heart J* 1994; 15:577-9.
  99. Brack MJ, Hubner PJB, Firmin RK. Successful operation on a coronary arteriovenous fistula in a 74 year old woman. *Br Heart J* 1991; 65:107-08.
  100. Glynn TP, Fleming RG, Haist JL, Huntzman RK. Coronary arteriovenous fistula as a cause for reversible thallium-201 perfusion defect. *J Nucl Med* 1994; 35:1808-10.
  101. Habermann JH, Howard ML, Johnson ES. Rupture of the coronary sinus with hemo-pericardium: a rare complication of coronary arteriovenous fistula. *Circulation* 1963; 28:1143-44.
  102. Moro-Serrano C, Martinez J, Madrid AH, Rufflanhas JJ, Novo L, Huerta EM, Vazquez A, Tamargo J. Ventricular tachycardia in a patient with congenital coronary arteriovenous fistula. *Am Heart J* 1992; 124:503-5.
  103. Hudspeth AS, Linder JH. Congenital coronary arteriovenous fistula. *Arch Surg* 1968; 96: 832-35.
  104. Kiso I, Itoh T, Morishita M, Kato K, Ishikura Y. Blood flow and pressure measurements of right coronary artery to left ventricular fistula. *Thorax* 1978; 33:253-56.
  105. Edis AJ, Schattenberg TT, Feldt RH, Danielson GK. Congenital coronary artery fistula. Surgical considerations and results of operation. *Mayo Clin Proc* 1972; 47:567-71.
  106. Takeda K, Okuda Y, Matsumura K, Sakuma H, Tagami T, Nakagawa T. Giant fistula between the right coronary artery and the left ventricle: diagnostic significance of right posterior oblique chest radiograph. *Am J Roentgenol* 1992; 159:1087-90.
  107. Colbeck JC, Shaw JM. Coronary aneurysm with arteriovenous fistula. *Am Heart J* 1954; 48:270.
  108. Roos JP, Hartman H, van der Schaar H, Brom AG. Diagnosis and surgical treatment of coronary artery fistula. *Thorax* 1970; 25:259-66.
  109. Cheng TO. Left coronary artery-to-left ventricular fistula: Demonstration of coronary steal phenomenon. *Am Heart J* 1982; 104:870-72.
  110. Rodgers DM, Wolf NM, Barrett MJ, Zuckerman GL, Meister G. Two-dimensional echocardiographic features of coronary arteriovenous fistula. *Am Heart J* 1982; 104:872-74.
  111. Yoshikawa J, Yanagihara K, Owaki T, Kato H, Takagi Y, Okumachi F, Fukaya T, Tomita Y, Baba K. Cross-sectional echocardiographic diagnosis of coronary artery aneurysms in patients with the mucocutaneous lymph node syndrome. *Circulation* 1979; 59:133-9.
  112. Chen CC, Hwang B, Hsiung MC, Chiang BN, Meng LC, Wang DJ, Wang SP. Re

- cognition of coronary arterial fistula by Doppler 2-dimensional echocardiography. *Am J Cardiol* 1984; 53:392-94.
113. Oliver JM, Lopes de Sa E, Dominguez F, Sobrino JA, Munoz JE, Iglesias A. Congenital right coronary artery-to-left atrium fistula detected by two-dimensional and Doppler echocardiography. *Am Heart J* 1987; 114:165-66.
  114. Bahl VK, Shrivastava S. Non-invasive diagnosis of congenital coronary arteriovenous fistula by cross-sectional and Doppler echocardiography. *Int J Cardiol* 1987; 17:89-91.
  115. Yoshikawa J, Kato H, Yanagihara K, Takagi Y, Okumachi F, Yoshida K, Tomita Y, Fukaya T, Baba K. Noninvasive visualization of the dilated main coronary arteries in coronary artery fistulas by cross-sectional echocardiography. *Circulation* 1982; 65:600-603.
  116. Kubota S, Suzuki T, Murata K. Cinemagnetic resonance imaging for diagnosis of right coronary arterial-ventricular fistula. *Chest* 1991; 100:735-37.
  117. Chen YT, Lee YS, Kan MN, Chen JS, Hu WS, Lin WW, Wang KY, Lin CJ, Chiang BN. Transesophageal echocardiography in adults with a continuous precordial murmur. *Int J Cardiol* 1992; 36:61-68.
  118. Fernandes F, Alam M, Smith S, Khaja F: The role of transesophageal echocardiography in identifying anomalous coronary arteries. *Circulation* 1993; 88:2532-2540.
  119. Giannacro PJ, Sochowski RA, Morton BC, Chan KL: Complementary role of transesophageal echocardiography to coronary angiography in the assessment of coronary artery anomalies. *Br Heart J* 1993; 70:70-74.
  120. Kawasaki T. Acute febrile mucocutaneous syndrome with specific desquamation of the fingers and toes. *Jpn J Allergy* 1967; 16:168-222.
  121. Nakanishi T, Takao A, Nakazawa M, Endo M, Niwa K, Takahashi Y. Mucocutaneous lymph node syndrome: Clinical, hemodynamic and angiographic features of coronary obstructive disease. *Am J Cardiol* 1985; 55:662-668.
  122. Said SAM, Veerbeek A, Werner HA, Herweyer TJ, Schuilenburg RM. Echocardiographic visualization of coronary aneurysms in the mucocutaneous lymph node syndrome 'Kawasaki disease'. *Netherl J Cardiol* 1991; 4:92-97.
  123. Querimit AS, Rowe GG. Localization of coronary arteriovenous fistula by indicator-dilution curves. *Am J Cardiol* 1971; 27:114-9.
  124. Tabatznik B, Randall TW, Hersch C. The mammary souffle of pregnancy and lactation. *Circ* 1960; 22:1069-73.
  125. Reed WA, Kittle CF. Congenital coronary artery fistula. Indications for operative treatment. *Arch Surg* 1966; 93:772-5.
  126. Boontje AH, Kruyswijk HH. Ateriovenous fistula of the internal mammary vessels. *J Thorac Cardiovasc Surg* 1971; 62:618-23.
  127. Moyer JH, Glantz G, Brest AN. Pulmonary arteriovenous fistulas: physiologic and clinical considerations. *Am J Med* 1962; 32:417-35.
  128. Craige E, Millward DE. Diastolic and continuous murmurs. *Prog Cardiovasc Dis* 1971; 14:38-56.
  129. Cooke M, Wolk PJ, Cheitlin MD. Mediastinal tumor causing continuous murmur. *Am Heart J* 1984; 107:1282-4.
  130. Jaffe RB, Glancy DL, Epstein SE, Brown BG, Morrow AF. Coronary artery right heart fistula: Long term observations in seven patients. *Circulation* 1973; 47:133-43.
  131. Griffiths SP, Ellis K, Hordof AJ, Martin E, Levine E, Gersony WM. Spontaneous complete closure of a congenital coronary artery fistula. *J Am Coll Cardiol* 1983; 3:1169-73.
  132. Hackett D, Hallidie-Smith KA. Spontaneous closure of coronary artery fistula. *Br Heart J* 1984; 52:477-9.
  133. Roughneen PT, Bhattacharjee M, Morris PT, Nasser M, Reul GJ. Spontaneous thrombosis in a coronary artery fistula with aneurysmal dilatation of the sinus of Valsalva. *Ann Thorac Surg* 1994; 57:232-34.
  134. Bishop JO, Mathur VS, Guinn GA. Congenital coronary artery fistula with myocardial

- infarction. *Chest* 1974; 65:233-34.
135. Lee SH, Fisher B, Fisher ER, Little A. Arteriovenous fistula and bacterial endocarditis. *Surgery* 1962; 52:463.
  136. Sheikhzadeh A, Stierle U, Langbehn AF, Thoran P, Diederich KW. Generalized coronary arterio-systemic (left ventricular) fistula: Case report and review of literature. *Jpn Heart J* 1986; 27:533-44.
  137. Duckworth F, Mukharji J, Vetrovec GW. Diffuse coronary artery to left ventricular communications: An unusual cause of demonstrable ischemia. *Cathet Cardiovasc Diagn* 1987; 13:133-37.
  138. McLellan BA, Pelikan PCD. Myocardial infarction due to multiple coronary ventricular fistulas. *Cathet Cardiovasc Diagn* 1989; 16:247-49.
  139. Reidy JF, Jones ODH, Tynan MJ, Baker EJ, Joseph MC. Embolisation procedures in congenital heart disease. *Br Heart J* 1985; 54:184-92.
  140. Bennett JM, Maree E. Successful embolization of a coronary arterial fistula. *Int J Cardiol* 1989; 23:405-06.
  141. van de Brand M, Pieterman H, Suryapranata H, Bogers AJJC. Closure of a coronary fistula with a transcatheter implantable coil. *Cathet Cardiovasc Diagn* 1992; 25:223-226.
  142. Lacombe P, Rocha P, Marchand X, Mulot R, Rigaud M, Jondeau G, Weber JM, Kahn JC. High flow coronary fistula closure by percutaneous coil packing. *Cathet Cardiovasc Diagn* 1993; 28:342-6.
  143. Millaire A, Goullard L, De Groote P, Ducloux G. Congenital high flow coronary cameral fistula in an 81-year-old woman: management problems. *Can J Cardiol* 1992; 8:917-20.

**Table 4.** Flow-chart of treatment of CAVFs (future perspective)





# Chapter 3

**A-** Coronary arteriovenous fistulas: Collective review and management of six new cases. Changing etiology, presentation and treatment strategy. Said SAM, El Gamal MIH, van der Werf T. *Clinical Cardiology* 1997; 20:748-752

**B-** Acquired coronary artery fistulas: Are these Collaterals losing their destination? Report of seven adult cases and literature review. Said SAM, van der Werf T. *Clinical Cardiology* 1999; 22:297-302

**C-** Coronary angiographic morphology of congenital coronary arteriovenous fistulas in adults: report of four new cases and review of angiograms of fifteen reported cases. Said SAM, El Gamal MIH. *Cathet Cardiovasc Diagn* 1995; 35:29-35

**D-** Congenital and atherosclerotic (acquired) coronary artery aneurysms: coronary angiographic and morphologic observations in 10 patients. Salah Said, Mamdouh El Gamal, Tjeerd van der Werf. *Int J Angiology* 1998; 7:206-210





# 3A

## **CORONARY ARTERIOVENOUS FISTULAS Collective Review and Management of Six New Cases- Changing Etiology, Presentation, and Treatment Strategy**

S.A.M. Said  
M.I.H. EL Gamal  
T. van der Werf

Published in:  
Clinical Cardiology 1997; 20:748-752

## Summary

We considered it worthwhile to review the literature of the last decade (1985-1995) to answer the question whether the etiology and the clinical picture of coronary arteriovenous fistulas (CAVFs) have changed. Furthermore, new therapeutic modalities such as percutaneous transcatheter embolization have been developed. We tried to define the place of these techniques in the therapeutic arena. Clinical presentation and management of six new patients with eight congenital CAVFs and 76 subjects with 96 congenital and acquired CAVFs taken from a review of the recent literature are presented. Sixty-three review subjects (78%) were treated medically, with one fatal case. Ligation of the fistula was achieved by surgical techniques in 10% of review subjects, while percutaneous transcatheter embolization (PTE) was performed in nine patients (12%). Percutaneous transcatheter embolization techniques are being increasingly used in the treatment of CAVFs. The etiology of CAVFs has a tendency to show alterations toward the acquired pathogenesis. In 64% of the review subjects the fistula was congenital in origin, and in 36% it had an acquired cause. Among the patients of the current review, the clinical presentations were 55% asymptomatic, 34% chest pain (anginal or atypical), and 13% congestive heart failure. The CAVFs of our six patients are all congenital in origin. In the current review, the clinical presentation showed a trend toward increasing chest pain complaints (34%) compared with the review (10%) published in the mid 1970s. This may be due to a higher mean age, and hence increased concurrent coronary artery disease due to aging compared with the review population of two decades ago.

## Introduction

Two decades ago, it was reported that nearly all coronary arteriovenous fistulas (CAVFs) are congenital and originate mostly from the right coronary artery and unload themselves most frequent in the right side of the heart.<sup>1</sup>

Coronary artery fistulas comprise 14% of congenital coronary artery anomalies.<sup>2</sup> They are seen in approximately 0.1 to 0.2% of all patients undergoing selective coronary angiography.<sup>3,4</sup> Acquired CAVFs have been reported as a complication of deceleration accidents,<sup>5</sup> percutaneous transluminal coronary angioplasty (PTCA),<sup>6</sup> repeated endomyocardial biopsies in heart transplant recipients,<sup>7</sup> permanent ventricular pacing leads,<sup>8</sup> or cardiac surgery.<sup>9,10</sup>

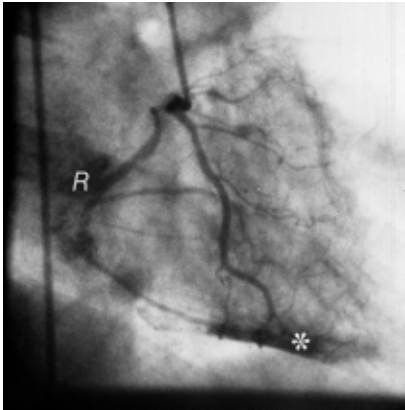
As acquired CAVFs are reported with increased frequency, we investigated their impact on the etiology, clinical presentation, and treatment strategy.

## Methods

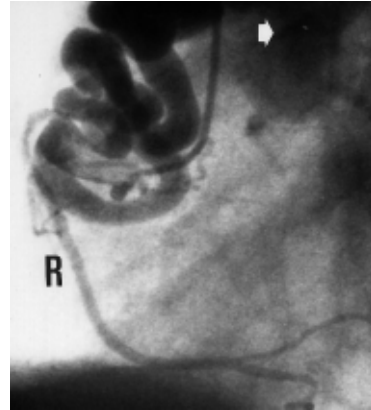
All clinical and therapeutic characteristics of the six adult patients (mean age 60 years, range 43-78 years) with eight congenital CAVFs, who recently came to our attention, are described. Clinical characteristics are summarized in Table I.

All CAVFs were demonstrated by using selective coronary arteriography (Fig.1); four patients manifested a single fistula and in the other two the CAVFs were bilateral.

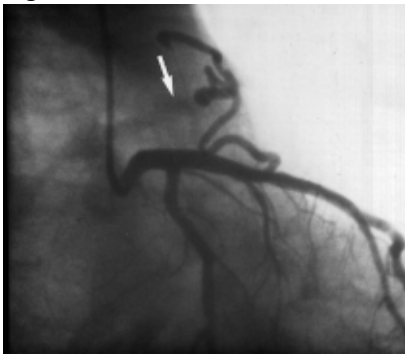The CAVFs originated from right (RCA) (n = 4), left anterior descending (LAD) (n = 3) and the circumflex (Cx) (n = 1) coronary arteries and terminated in the pulmonary trunk (n = 5), the left ventricle (n = 1), coronary sinus (n = 1) and right atrium (n = 1). The clinical presentation were atypical chest pain (n = 2), angina pectoris (n = 3), and tachyarrhythmias including paroxysmal atrial fibrillation with transient ischemic attack (n = 1).



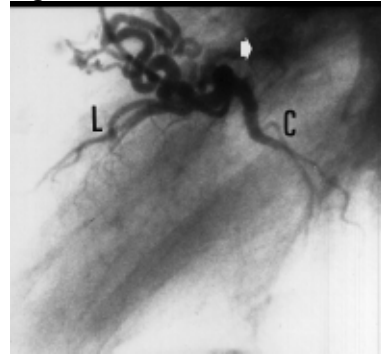
**Fig. 1A**



**Fig. 1B**



**Fig. 1C**



**Fig. 1D**

Fig.1 Representative coronary angiographic findings in three patients of the present series. (A) Right coronary angiogram in right anterior oblique position showing multiple small communications draining into the right atrium (⊗) and left ventricular cavity (\*). (B) Right coronary (⊗) angiogram in left anterior oblique projection showing dilated tortuous fistulous proximal right coronary artery terminating in the pulmonary trunk (arrow). (C) Left coronary angiogram in right anterior oblique projection demonstrating the fistulous vessel originating from the proximal left anterior descending coronary artery; a stream of dye is still visible while filling the pulmonary trunk (arrow). (D) The same patient as in (B). Left lateral view of left coronary artery angiogram illustrating dilated serpiginous fistulous vessel originating from the left anterior descending coronary artery and terminating in the pulmonary trunk (arrow). Shallow filling of the distal left anterior descending coronary artery (L) and circumflex coronary artery (C) is appreciated.

Table 1 Clinical data, angiographic findings, and management of six patients with coronary arteriovenous fistulas

Case	age (years)/sex	presentation	concurrent conditions	MI	IRA	fistula		management
						O	T	
1	63/F	arrhythmia	hyperten	none	none	RCA	LV	medical
2	64/F	chest pain	hyperten	none	none	Cx	CS	medical
3	64/M	chest Pain	hyperten	none	none	LAD	PT	medical
4	78/F	angina pectoris	none	anterior	LAD	LAD/RCA	PT	CABG/Ligation
5	60/M	angina pectoris	none	inferolateral	RCA	LAD/RCA	PT	PTE/PTCA
6	43/M	angina pectoris	none	inferolateral	Cx	RCA	RA	medical

*Abbreviations:* F = female, M = male, hyperten = hypertension, MI = myocardial infarction, O = origin, T = termination, RCA = right coronary artery, LV = left ventricle, Cx = circumflex coronary artery, CS = coronary sinus, LAD left anterior descending coronary artery, PT = pulmonary trunk, CABG = coronary artery bypass grafting, PTCA = percutaneous transluminal coronary angioplasty, FRA = fistula related artery, PTE = percutaneous transcatheter embolization.

Four patients were treated conservatively. In 1989, one subject underwent ligation of the fistula from the LAD to the pulmonary artery during concurrent coronary artery bypass grafting (CABG) for severe obstructive coronary artery disease. In 1992, percutaneous transcatheter embolization (PTE) of a dual fistula originating from the RCA and LAD, terminating in the pulmonary trunk, was performed in another patient. In 1994, an attempt to occlude a residual fistula of the RCA was complicated by an inferolateral myocardial infarction (MI). This was treated medically.

A previous history of moderate hypertension was present in three patients. Electrocardiographic (ECG) abnormalities were present in five patients. These included repolarization disturbances in the inferolateral leads (n = 1), prominent R wave in lead V1 and negative T wave in leads II, III, and aVF (n = 1), complete right bundle branch block and left axis deviation (n = 1) and Q wave in leads II, III, aVF, and negative T wave in leads II, III, aVF, and V4-V6 (n = 1).

A healed anterior MI was documented in one subject and inferolateral MI in two others. In one of the subjects MI was documented previous to the diagnosis of a fistula.

### **Review subjects**

Seventy-six patients (1985-1995) (our six patients in the present series are not included) with 96 CAVFs identified in the literature are reviewed.<sup>3-9, 11-26</sup> The mean age was 24.1 years (range 2-78 years; there were 51 males and 25 females (29%).

Forty-nine patients (64%) had congenital CAVFs and 27 (36%) patients manifested acquired CAVFs. These included postendomyocardial biopsy (17%), post-PTCA (4%), post-traumatic (4%), postendocardial ventricular pacing (3%), post-cardiac surgery (3%), post-MI (2%), atherosclerosis (1%), and 1% undefined. The origin of the fistula in 76 subjects with 96 CAVFs was the RCA in 30 (31%) and the left coronary artery (LCA) in 65 (68%).

A single coronary artery, originating from the left sinus of Valsalva, participated in the fistula formation in one subject. The termination of the fistula was in the right (87%) and left (11%) side of the heart and was undetermined in one subject. Dual fistulas were present in nine subjects (11%) and multiple fistulas were found in three patients.

Forty-two subjects (55%) were asymptomatic. Chest pain (anginal or atypical) was present in 34% of patients, and 13% had congestive heart failure. Endocarditis and cardiac arrhythmias were both present in a single patient (2%).

Conservative strategies were chosen for 59 subjects (78%). A single death occurred in this group. The patient died of complications (perforation of the LAD into the left ventricle) resulting from acquired CAVF following PTCA of the LAD.

Successful PTE was performed in nine patients (11 vessels). Residual fistulas remained in one subject after embolization due to damage to the valve of the detachable balloon. No deaths occurred. Different embolization techniques were used to occlude the fistula-related vessels. The embolization material included microcoils (n = 4), trefoil coil (n = 1), standard steel coil (n = 1), detachable balloon (n = 3), a combination of microcoil and detachable balloon (n = 1), and Ivalon particles (590-1000 µm) (Ingenor, France) (n = 1).

Surgical ligation was performed in eight subjects. A complication was reported in one patient: this comprised postoperative inferolateral MI. Asymptomatic sinoatrial conduction abnormalities were seen in another postoperative patient. No deaths occurred. Simultaneous cardiac and coronary surgery was performed in three patients, CABG in two, and aortic valve replacement in one patient.

## Statistical analysis

If appropriate, differences between the 1975 review<sup>1</sup> and this publication were analyzed with a simple chi-square test (Mantel Haenszel statistics, Epi/Info, Atlanta, Ga. USA).

## Definition of acquired coronary arteriovenous fistulas

A direct precapillary communication existed between coronary artery and cardiac chamber, bypassing the myocardial capillary network, which has the following characteristics: not congenital in origin; not present on a prior (when available) coronary angiographic study; occurs after a diagnostic or therapeutic (surgical or nonsurgical) endovascular coronary intervention; develops subsequent to thoracic trauma (blunt or sharp), permanent endocardial pacing, endomyocardial biopsy, and cardiac surgery.

## Observed changes between the surgical population of Rittenhouse and the current review (Table 2)

*Etiology:* In the present review, 64% of the subjects had congenital and 36% manifested with acquired CAVFs secondary to different etiologies. Rittenhouse *et al.* have indicated in their review that the etiology was mainly congenital.<sup>1</sup> The change in etiology is statistically significant [ $X^2$  testing revealed 43.68 ( $p < 0.0000$ )].

*Therapeutic strategy:* In the review of Rittenhouse *et al.*, all patients (100%) were treated with surgical (entry criteria) ligation: direct ligation in 76%, cardiopulmonary bypass in 23%, and hypothermia in 1%. The overall postoperative complication rate was 15%. In the current review, a conservative strategy was achieved in 78% of subjects. Twelve percent underwent PTE techniques and 10% were treated with surgical ligation.

Table 2: Results of comparison between the findings of the 1975 review and the current review

	Review 1975	current review	$X^2$	p value
Male gender (%)	38	71	21.85	<0.0000
Acquired CAVFs (%)	None	36	43.68	<0.0000
Origin from LCA (%)	41	69	13.27	<0.0000
Chest pain (%)	10	34	16.7	<0.0000

Abbreviations: LCA = left coronary artery, CAVFs = coronary arteriovenous fistulas.

## Discussion

Reviewing the literature from 1985 to 1995, we found that the etiology of the CAVFs has been changing significantly from mainly congenital<sup>1,3,4, 15-26</sup> to an increasing number of acquired pathogenesis.<sup>5-9, 11-14</sup>

In the present review, a substantial proportion of the fistulas (36%) have an acquired pathogenesis. It could be speculated that this increase may be due to an incremental use of intravascular procedures and interventional techniques, such as PTCA, endomyocardial biopsy, and permanent transvenous endocardial pacing.

In their review, Rittenhouse *et al.* found that the majority (59%) of patients remained asymptomatic. The most common clinical presentation was dyspnea at rest or during exertion (19%), angina pectoris or chest pain (10%), fatigue (10%), and congestive heart failure (9%).<sup>1</sup>

In the current review, 55% of patients were asymptomatic, 34% had chest pain, and 13% had congestive cardiac failure.

Although elective surgical ligation of CAVFs has been proposed by Liberthson and colleagues,<sup>27</sup> the management of the asymptomatic patients with small CAVFs remains controversial, particularly with regard to operative intervention. Currently, three management options are available (Table III). As a reflection on these therapeutic modalities, four of our current patients were managed medically. Percutaneous transluminal embolization was performed in a single case and ligation of the fistula combined with CABG was undertaken in another subject.

First, small asymptomatic CAVFs may be managed conservatively, as it has been reported that some CAVFs may close spontaneously<sup>16,28,29</sup> or may be associated with advanced age,<sup>30</sup> and it has been suggested that the small CAVFs generally have a benign long-term course.<sup>3</sup> In the present review, 78% of cases were managed medically. Medical regimens with either beta blockers or calcium-channel antagonists may be indicated.<sup>31,32</sup>

Second, surgery may be indicated if the patient is symptomatic or the vascular anatomy is unfavorable for PTE. It has been reported that postoperative morbidity accounted for 15% of the patients, the most frequent serious postoperative complication being MI (3.6%), and that early mortality was 2%.<sup>1</sup> In the current review, there were no deaths in the surgically treated group, but postoperative MI occurred in one patient. It should be mentioned that the surgical techniques have vastly improved since the mid 1970s and this may have an impact on the reported postoperative morbidity and mortality.

Finally, with PTE techniques, permanent occlusion of symptomatic CAVFs can be achieved, provided the vascular anatomy is favorable.<sup>17,18,20,33</sup> Nine reviewed patients underwent successful PTE. Because of low morbidity with no mortality, this method should be considered the future treatment of choice for CAVFs, provided that the lesion has an amenable anatomy.

### Limitation of the current study

The study has some limitations. Besides being small in size, it was retrospective and the patients were nonrandomized. Moreover, on reviewing the literature we found that there is a tendency to publish the iatrogenic complications of interventional procedures, and hence publication bias might be expected toward the etiology of acquired coronary arteriovenous fistulas.



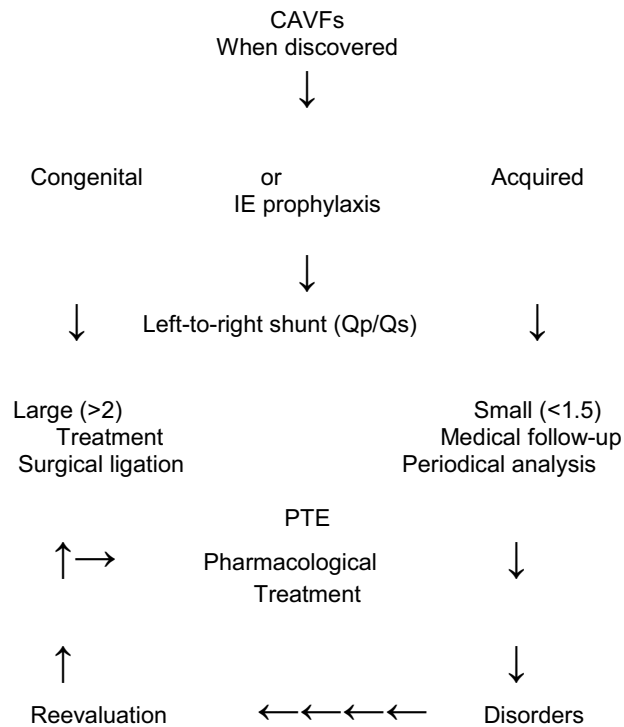
## Conclusions

Despite the limitations of the current review (small retrospective sample size, nonrandomized, individual selection bias, and publication bias), the following conclusions could be drawn: (1) The etiology of CAVFs has a tendency to show alterations in the direction of the acquired pathogenesis; (2) percutaneous transcatheter embolization techniques are being used increasingly in the treatment of coronary arteriovenous fistulas.

## Acknowledgements

The authors would like to thank K. Huisman, M.D., Medisch Spectrum Twente, Enschede, and W.G. de Voogt, M.D., St. Lucas Ziekenhuis, Amsterdam, The Netherlands, who contributed patients who served as the basis of this paper. Mrs. H.E. Blijdenstein, librarian of Hospital Streekziekenhuis Midden-Twente, Hengelo, is greatly acknowledged for her assistance during the preparation of this manuscript.

Table 3: Flow chart of treatment strategy of coronary arteriovenous fistulas



## References

1. Rittenhouse EA, Doty DB, Ehrenhaft JL: Congenital coronary artery-cardiac chamber fistula. Review of operative management. *Ann Thorac Surg* 1975; 20:468-485.
2. Yamanaka O, Hobbs RE: Coronary artery anomalies in 126,595 patients undergoing coronary arteriography. *Cathet Cardiovasc Diagn* 1990; 21:28-40.
3. Said SAM, Landman GHM: Coronary-pulmonary fistula: Long-term follow-up in operated and non-operated patients. *Int J Cardiol* 1990; 27:203-210.
4. Gillebert C, Van Hoof R, Van de Werf F, Piessens J, De Geest H: Coronary artery fistulas in an adult population. *Eur Heart J* 1986; 7:437-443.
5. Toda S, Nakamura A, Iwamoto T, Nakaji S: Successful surgical treatment of aortic regurgitation with coronary artery fistula due to blunt chest trauma. A case report. *J Jpn Assoc Thorac Surg* 1991; 39:1087-1092.
6. Iannone LA, Iannone DP: Iatrogenic left coronary artery fistula-to-left ventricle following PTCA: A previously unreported complication with nonsurgical treatment. *Am Heart J* 1990; 5:1215-1217.
7. Sandhu JS, Uretsky BF, Zerbe TR, Goldsmith AS, Reddy PS, Kormos RL, Griffith BP, Hardesty RL: Coronary artery fistula in the heart transplant patient. A potential complication of endomyocardial biopsy. *Circulation* 1989; 2:350-356.
8. Saeian K, Vellinga T, Troup P, Wetherbee J: Coronary artery fistula formation secondary to permanent pacemaker placement. *Chest* 1991; 3:780-781.
9. Lee RT, Mudge GH, Colucci WS: Coronary artery fistula after mitral valve surgery. *Am Heart J* 1988; 5:1218-1219.
10. Chenzbraun A, Pinto FJ, Meyer B, Stinson EB, Popp RL: Frequency of acquired coronary-cameral fistula after ventricular septal myectomy in hypertrophic cardiomyopathy. *Am J Cardiol* 1993; 71:1244-1246.
11. Yu R, Sharma B, Franciosa JA: Acquired coronary artery fistula to the left ventricle after acute myocardial infarction. *Am J Cardiol* 1986; 58:557-558.
12. Lee KMH, Pichard AD, Lindsay J Jr: Acquired coronary artery-left ventricular pseudoaneurysm fistula after myocardial infarction. *Am J Cardiol* 1989; 64:824-825.
13. Meng RL, Harlan JL: Left anterior descending coronary artery-right ventricle fistula complicating percutaneous transluminal angioplasty. *J Thorac Cardiovasc Surg* 1985; 90:387-390.
14. Grill HP, Chew PH, Weiss JL, Merillat JC, Hill G, Cadden J, Brinker JA: Contrast echocardiographic diagnosis of PTCA-induced coronary artery-left ventricle fistula. *Am J Cardiol* 1991; 121:194-198.
15. Rein AJJ, Yatsiv I, Simcha A: An unusual presentation of right coronary artery fistula. *Br Heart J* 1988; 59:598-600.
16. Roughneen PT, Bhattacharjee M, Morris PT, Nasser M, Reul GJ: Spontaneous thrombosis in a coronary artery fistula with aneurysmal dilatation of the sinus of Valsalva. *Ann Thorac Surg* 1994; 57:232-234.
17. Bennett JM, Maree E: Successful embolization of a coronary arterial fistula. *Int J Cardiol* 1989; 23:405-406.
18. Reidy JF, Anjos RT, Qureshi SA, Baker EJ, Tynan MJ: Transcatheter embolization in the treatment of coronary artery fistulas. *J Am Coll Cardiol* 1991; 18:187-192.
19. Brack MJ, Hubner PJB, Firmin RK: Successful operation on a coronary arteriovenous fistula in a 74-year-old woman. *Br Heart J* 1991; 65:107-108.
20. Van den Brand M, Pieterman H, Suryapranata H, Bogers AJJC: Closure of a

- coronary fistula with a transcatheter implantable coil. *Cathet Cardiovasc Diagn* 1992; 25:223-226.
21. Kugelmass AD, Manning WJ, Piana RN, Weintraub RM, Baim DS, Grossman W: Coronary arteriovenous fistula presenting as congestive heart failure. *Cathet Cardiovasc Diagn* 1992; 26:19-25.
  22. Bolognesi R, Tsialtas D, Barbaresi F, Manca C: Single coronary artery-right ventricular fistula with a partially thrombosed large aneurysm of its proximal tract in 66-year-old man. *Eur Heart J* 1994; 15:1720-1724.
  23. Said SAM, El Gamal MIH: Coronary angiographic morphology of congenital arteriovenous fistulas in adults: Report of four new cases and review of angiograms of fifteen reported cases. *Cathet Cardiovasc Diagn* 1995; 35:29-35.
  24. Singham KT, Anuar M: Left coronary to pulmonary artery fistula. *Australas Radiol* 1988; 32:385-386.
  25. Oliver JM, Lopes de Sa E, Dominguez F, Sobrino JA, Munoz JE, Iglesias A: Congenital right coronary artery-to-left atrium fistula detected by two-dimensional and Doppler echocardiography. *Am Heart J* 1987; 114:165-166.
  26. Gushiken M, Murkami K, Mimura G: Multiple coronary LV fistulas: Demonstration of coronary steal phenomenon by stress thalium scintigraphy and exercise hemodynamics. *Am Heart J* 1990; 120:217-219.
  27. Libersohn RR, Sagar K, Berkoben JP, Weintraub RM, Levine FH: Congenital coronary arteriovenous fistula. Report of 13 patients, review of the literature and delineation of management. *Circulation* 1979; 59:849-854.
  28. Jaffe RB, Glancy DL, Epstein SE, Brown BG, Morrow AF: Coronary artery right heart fistulae: Long term observations in seven patients. *Circulation* 1973; 47:133-143.
  29. Hackett D, Hallidie-Smith KA: Spontaneous closure of coronary artery fistula. *Br Heart J* 1984; 52:477-479.
  30. Gasul BM, Arcilla RA, Fell EH, Lynfield J, Bicoff JP, Luan LL: Congenital coronary arteriovenous fistula. Clinical, phonocardiographic, angiographic and hemodynamic studies in five patients. *Pediatrics* 1960; 25:531-560.
  31. Cheng TO: Left coronary artery-to-left ventricular fistula: Demonstration of coronary steal phenomenon. *Am Heart J* 1982; 104:870-872.
  32. McLellan BA, Pelikan PCD: Myocardial infarction due to multiple coronary-ventricular fistulas. *Cathet Cardiovasc Diagn* 1989; 16:247-249.
  33. Reidy JF, Jones ODH, Tynan MJ, Baker EJ, Joseph MC: Embolisation procedures in congenital heart disease. *Br Heart J* 1985; 54:184-192.

# 3B

## **ACQUIRED CORONARY CAMERAL FISTULAS Are These Collaterals Losing Their Destination?**

**Salah A.M. Said  
Tjeerd van der Werf**

**Published in:  
Clinical Cardiology 1999; 22:297-302**

## Summary

*Background:* The majority of coronary cameral fistulas (CCFs) are congenital in origin. On the other hand, acquired coronary cameral fistulas, having various etiopathogenic origins, are increasingly recognized.

*Hypothesis:* The aim of this study was to assess the possible involvement of coronary atherosclerosis in the pathogenesis of acquired coronary cameral fistulas.

*Methods:* Between 1993 and 1996 coronary cameral fistulas were detected in seven adult patients with coronary atherosclerosis (n = 4) and following myocardial infarction (n = 3) with a mean age of 59.3 years (range 40-77). They were analyzed at our hospital.

*Results:* Myocardial infarction (MI) was documented in six patients and was localized at the same territory of the fistula-related artery in three of them. All patients remained asymptomatic after the detection of the fistula. Five patients had associated cardiac disorders. Two patients were treated conservatively with medical therapy. Coronary artery bypass grafting (CABG) was performed in three patients. One patient died while awaiting CABG. Thirty-four adult cases with acquired CCFs were collected from the current literature. The right coronary artery was the origin of the fistula in 37% and they terminated into the right heart-side in 72% of cases. They remained asymptomatic in 62% of cases.

*Conclusions:* It could be concluded that acquired CCFs may complicate the course of severe atherosclerosis or myocardial infarction in certain adult patients. The symptomatology and treatment strategy is comparable in the congenital and acquired types. The distribution of involvement of the right or left coronary arteries is equally divided in both the acquired and congenital types. Further studies are needed to investigate the precipitating factors for the occurrence of and incidence of acquired CCFs in patients with severe atherosclerosis or post-MI subjects.

## Introduction

Coronary cameral fistulas (CCFs) are etiologically divided into congenital and acquired types. The vast majority of these lesions are congenital in origin.<sup>1-4</sup> Acquired CCFs may occur after heterogeneous causes of endogenous or exogenous trauma: exogenous trauma such as sharp<sup>5,6</sup> and blunt chest injury,<sup>7</sup> or endogenous surgical or nonsurgical trauma such as barotrauma after percutaneous transluminal coronary angioplasty (PTCA),<sup>8-11</sup> myocardial infarction (MI),<sup>12-16</sup> permanent ventricular pacing,<sup>17</sup> endomyocardial biopsy,<sup>18</sup> and cardiac surgery.<sup>19-21</sup> Coronary cameral fistulas may be spontaneously associated with severe coronary atherosclerosis.<sup>22,23</sup> In view of the increased use of endovascular procedures, acquired fistulas are reported increasingly.<sup>24</sup>

This report presents the clinical manifestations and angiographic findings of seven adult patients with incidentally detected CCFs associated with severe coronary artery disease or MI. The literature concerning the acquired CCFs is reviewed.

## Study Patients

Seven adult patients with acquired CCFs (Fig. 1 and 2) were analyzed at District General Hospital Streekeziekenhuis Midden-Twente, Hengelo, The Netherlands, between 1993 and 1996.

Acquired CCFs are defined as a direct communication of a coronary artery with a cardiac chamber, provided that cardiac or coronary intravascular "iatrogenic or spontaneous" procedure/event or extravascular thoracic trauma has taken place, especially when extravasation of contrast is visible from the coronary artery into or adjacent to the left

ventricle in an infarcted wall segment. Furthermore, the fistula arises proximal to severe coronary obstructive lesions.

None of our patients underwent therapeutic endovascular procedure prior to detection of the fistula, and none had penetrating or nonpenetrating thoracic trauma.

## Results

This study consisted of seven adult patients (six men, one woman), ranging in age from 40 to 70 years (mean age 59.3 years). Patient characteristics are summarized in Table 1.

When shunts were calculated, none were over 1.6. The patients had 7 CCFs. The origin of the CCFs was the right coronary artery (RCA) in 5 and the left coronary artery in two patients. Of these, the left anterior descending artery (LAD) participated in one while the circumflex artery (Cx) was the fistula-related artery in one patient. The sites of termination of the fistulous tract were the right atrium in four, the left ventricle in two and the pulmonary trunk in one patient. These CCFs were incidentally found during coronary angiographic studies performed for analysis of ischemic heart disease, congestive heart failure and cardiac arrhythmias.

Association of CCF with mitral valve prolaps (MVP) was seen in two patients (Nos. 1 and 7). Mitral regurgitation was present in two patients (Nos. 2 and 7).

Myocardial infarction occurred in five patients (Nos. 1, 2, 3, 4, and 6) and it was localized in the same territory of the fistula-related artery in three of these (Nos. 2, 3, and 6) (Fig.1-3). Mean left ventricular end-diastolic pressure (LVEDP) was marginally elevated at 13 mm Hg (range 5-20).

A systolic cardiac murmur was heard in two patients (Nos. 1 and 7). One patient (No. 6) had congestive heart failure and atrial fibrillation, with an elevated LVEDP of 16 mm Hg. The fistula terminated directly into the lumen of the left ventricle. Echocardiographic measurement of left ventricular end-diastolic dimension (LVEDD) was evaluable in four cases with a mean of 56.3 mm (range 50-66). It was found dilated (LVEDD > 64 mm) in two cases (Patients No. 1 and 6).

Severe coronary artery stenosis was defined as angiographic stenosis of > 80%. Severe narrowing of the fistula-related artery (FRA) was found in four patients (Nos. 1, 2, 3, and 5) and total occlusion of the FRA in three (Patients No. 4, 6, and 7). Well developed collateral circulation to the myocardial region of the severely stenotic or totally occluded FRA was demonstrated in four patients (Nos. 3, 4, 5, and 6). Bridge Collaterals to the periphery of the FRA were found in Patients No. 3 and 4. Collateral circulation was angiographically undetected in three cases (Patients No. 1, 2, and 7). Three patients (Nos. 4, 5, and 6) had dual coronary artery disease (CAD), and triple CAD was found in four cases (Patients No. 1, 2, 3, and 7). Coronary artery bypass grafting (CABG) was performed in three patients (Nos. 1, 2, and 3). Two patients (Nos. 4 and 6) underwent PTCA for concurrent coronary artery stenosis of non-fistula-related arteries.

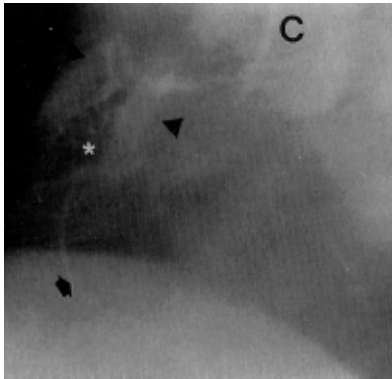


Fig. 1

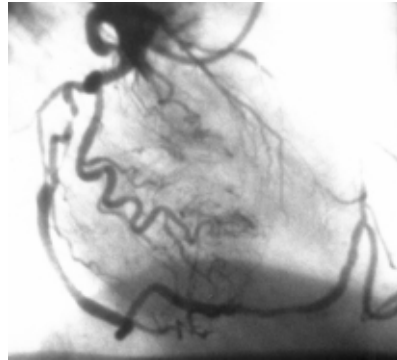


Fig.2

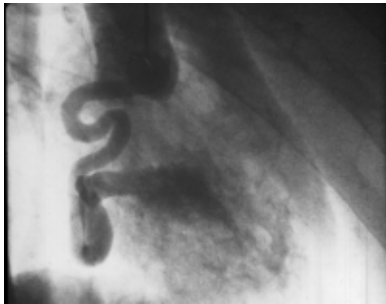


Fig. 3

Fig.1 Acquired single coronary cameral fistula (CCF). Right coronary artery (RCA) in right anterior oblique projection (RAO), showing proximal total occlusion with bridge collaterals (\*) filling the periphery (arrow) of the RCA and simultaneously blushing the right atrium (arrowheads). An example of acquired single CCFs originating from the RCA and terminating into the RA. The small calibre RCA, mainly seen in acquired CCF, is well appreciated.  
C: Right Judkins catheter

Fig.2 Acquired multiple coronary cameral fistula. Angiogram of the left coronary artery in right anterior oblique projection demonstrating multiple fistulas originating from the circumflex artery (Cx) to the lumen of the left ventricle (small arrows). Total occlusion of the left anterior descending (arrowhead) and significant stenosis of the Cx (o) arteries are well appreciated.  
C: Left Judkins catheter

Fig.3 Angiogram of a 30-years old male (not included in the present series) of the right coronary artery (RCA) (arrows) in the right anterior oblique (RAO) projection demonstrating severely dilated and tortuous congenital coronary cameral fistula originating from the distal RCA (arrowheads) and terminating directly into the lumen of the left ventricle.

## Review subjects

Thirty-four adult cases were collected from the current literature in the period between 1971 and 1996; they had 43 acquired CCFs. The aetiology varied from endovascular barotrauma and endomyocardial biopsy to chest injury.<sup>5-25</sup> The origin was the RCA in 16 of 43 (37%) and the LCA in 27 (63%) of the CAFs. They terminated into the right side of the heart in 31 of 43 (72%) and into the left side of the heart in 12 (28%) of the fistulas. Of 34 (62%) patients, 21 had no symptoms after detection of the CCF. Chest pain occurred in 23% and dyspnea in 15% of the subjects. Four patients (12%) were managed by surgical ligation, 82% medically, 3% by percutaneous transcatheter embolization; 3% died while awaiting CABG. On follow-up, 14 subjects remained asymptomatic. Spontaneous closure and near-closure was demonstrated in six subjects. Surgical ligation was performed in one patient. Three patients died. No details were available in the remaining 10 subjects.

## Discussion

Coronary cameral fistulas (CCFs) are commonly congenital in origin<sup>1-4</sup> but they may be acquired subsequent to a heterogeneous group of causes.<sup>5-23,25</sup> The various reported causes of acquired CCFs and speculative factors thought to be contributing to their development are listed in table 2. In our own series, all patients had an acquired CCF secondary to severe atherosclerotic changes and associated with MI. Coronary cameral fistulas were associated with MI in two and with severe atherosclerosis in five patients.

In the former two patients, it is possible that the fistula had formed as a result of the transmural MI facilitated by the occurrence of soft necrotic myocardial tissue in the infarction region. This complication has been described previously in literature.<sup>12-16</sup>

In the remaining five patients with associated severe atherosclerosis, the most likely mechanisms for the formation of the CCF are (1) aberrant development of collateral vessels, i.e. Collaterals that "lost their way" or direction and terminated elsewhere (inadvertently into a cardiac chamber) than the target myocardial region; (2) dilatation of arteriovenous channels may permit enough shunting of blood to be visualised during coronary angiography.<sup>14,22,23</sup> In one patient (No. 6), the development of post-MI pericarditis may also have played a role or facilitated the development of such a CCF. These CCFs are believed to be acquired secondary to atherosclerosis and MI because of the absence of dilatation (mostly seen in congenital cases) of the involved coronary artery and the presence of a consequent direct relation between the area of termination and the stenotic or occluded coronary artery responsible for the fistula formation.

Although most of the patients with CCF are asymptomatic, few may initially be presented with a catastrophic manifestation such as syncope and cardiac arrest.<sup>26</sup>

Termination of CCF in the left ventricle has been reported,<sup>27</sup> but is infrequent (3%).<sup>2</sup> In two of our patients, the CCF terminated into the lumen of the left ventricle. The LCA was the fistula bearing artery in both of these.

Coronary cameral fistulas may be single or multiple.<sup>28</sup> Bilateral or multiple CCFs, while rarely reported in congenital CCFs,<sup>28</sup> were even rarer both in our own series (1 of 7 cases) and in the current literature review of acquired CCFs (2 of 34 cases). Coronary cameral fistulas are either isolated<sup>29</sup> or associated with local aneurysmal formation<sup>27,30</sup> of the fistula-related artery. None of our patients showed aneurysmal formation of the fistulous tract or the fistula-related artery.

Spontaneous closure has been reported for congenital CCFs<sup>31,32</sup> and it has also been demonstrated in acquired CCFs.<sup>18,25</sup> It has been estimated that spontaneous closure occurs



in 1-2% of the patients.<sup>31</sup>

Patients with acquired or congenital CCFs with a large size shunt are treated either with percutaneous transcatheter embolization techniques<sup>20,33</sup> or, when the anatomy is not amenable, by surgical ligation method. In patients who cannot undergo surgery because of the risk of congestive heart failure and endocarditis, close long-term follow-up is recommended and antibacterial prophylactic measures should be considered. In the present series, the magnitude of the left-to-right shunt is small (mean Qp/Qs is 1.35). In the review subjects (34 cases), the shunt size was not reported. Of the 7 patients with acquired CCFs in our series and the 34 acquired CCFs from literature, none had symptoms attributable to the fistula. Based on the findings in our own series and literature review, the symptomatology in the acquired CCFs is not unique, but is usually related to the underlying cause: in our series, for instance, it was related to severe obstructive coronary atherosclerotic lesions and MI. In the literature review (34 cases), most patients with acquired CCFs were treated medically, but surgical ligation (4 times) or PTE (once) were performed in few subjects. At follow-up, spontaneous closure or near-closure of the CCF was documented in six of the review cases. Three patients with acquired CAFs (related to PTCA in two patients and secondary to MI in the third) died.

## Conclusions

As Collaterals “lose their way”, acquired CCFs can probably develop in patients with severe atherosclerosis and MI. No difference was found between congenital<sup>2</sup> and acquired CCFs in terms of vessel involvement. In our series (seven cases), the systemic to pulmonary shunt was small. In the current literature review and in our series, the acquired CCFs showed no specific or unique symptomatology, and the majority of patients with acquired CCFs were treated medically.

The question remains whether patients with acquired CCFs require endocarditis prophylaxis as recommended in congenital CCFs.

## Acknowledgement

The authors wish to thank Mrs. H.E. Blijdenstein for her expert secretarial assistance during the preparation of the manuscript.

## References

1. Yamanaka O, Hobbs RE. Coronary artery anomalies in 126.595 patients undergoing coronary arteriography. *Cathet Cardiovasc Diagn* 1990; 21:28-40.
2. Levin DC, Fellows KE, Abrams HL. Hemodynamically significant primary anomalies of the coronary arteries. Angiographic aspects. *Circ* 1978; 58:25-34.
3. Gillebert C, van Hoof R, van de Werf F, Piessens J, de Geest. Coronary artery fistulas in an adult population. *Eur Heart J* 1986; 7:437-443.
4. Said SAM, Landman GHM. Coronary-pulmonary fistula: Long-term follow-up in operated and non-operated patients. *Int J Cardiol* 1990; 27:203-210.
5. Cheng TO, Adkins PC. Traumatic aneurysm of left anterior descending coronary artery with fistulous opening into left ventricle and left ventricular aneurysm after stab wound of chest. *Am J Cardiol* 1973; 31:384-390.
6. Rangel A, Badui E, Verduzco C, Valdespino A, Enciso R. Traumatic coronary arteriovenous fistula communicating the left main coronary artery to pulmonary artery, associated with pulmonary valvular insufficiency and endocarditis: case

- report. *Angiology* 1990; 41:156-160.
7. Toda S, Nakamura A, Iwamoto T, Nakaji S. Successful surgical treatment of aortic regurgitation with coronary artery fistula due to blunt chest trauma-A case report. *J Jpn Assoc Thorac Surg* 1991; 39:1087-1092.
  8. Meng RL, Harlan JL. Left anterior descending coronary artery-right ventricle fistula complicating percutaneous transluminal angioplasty. *J Thorac Cardiovasc Surg* 1985; 90:387-390.
  9. Grill HP, Chew PH, Weiss JL, Merillat JC, Hill G, Cadden J, Brinker JA. Contrast echocardiographic diagnosis of PTCA-induced coronary artery-left ventricle fistula. *Am Heart J* 1991; 121; 194-198.
  10. Iannone LA, Iannone DP. Iatrogenic left coronary artery fistula-to-left ventricle following PTCA: A previously unreported complication with nonsurgical management. *Am Heart J* 1990; 120:1215-1217.
  11. El-Omar MM, Hargreaves MR, Venkataraman A, Been M. Coronary ventricular fistula as a complication of PTCA: A case report and literature review. *Int J Cardiol* 1995; 51:113-116.
  12. Yu R, Sharma B, Franciosa JA. Acquired coronary artery fistula to the left ventricle after acute myocardial infarction. *Am J Cardiol* 1986; 58:557-558.
  13. Lee KMH, Pichard AD, Lindsay J. Acquired coronary artery-left ventricular pseudoaneurysm fistula after myocardial infarction. *Am J Cardiol* 1989; 64:824-825.
  14. Ryan C, Gertz EW. Fistula from coronary arteries to left ventricle after myocardial infarction. *Br Heart J* 1977; 39:1147-1149.
  15. Shimizu M, Yoshio H, Ino H, Takeda R, Okada Y. Histopathologic findings of a left coronary artery fistula to the left ventricle after myocardial infarction. *Cardiology in the Elderly* 1993; 1:335-336.
  16. Somsen GA, Liem KS. Coronary artery-left ventricular fistulas probably due to transmural myocardial infarction: a case report. *Cardiologie* 1994; 1:65-67.
  17. Saeian K, Vellinga T, Troup P, Wetherbee J. Coronary artery fistula formation secondary to permanent pacemaker placement. *Chest* 1991; 99:780-781.
  18. Sandhu JS, Uretsky BF, Zerbe TR, Goldsmith AS, Reddy PS, Kormos RL, Griffith BP, Hardesty RL. Coronary artery fistula in the heart transplant patient. a potential complication of endomyocardial biopsy. *Circ* 1989; 79:350-356.
  19. Lee RT, Mudge GH, Colucci WS. Coronary artery fistula after mitral valve surgery. *Am Heart J* 1988; 115:1128-1130.
  20. Reidy JF, Anjos RT, Qureshi SA, Baker EJ, Tynan MJ. Transcatheter embolization in the treatment of coronary artery fistula. *J Am Coll Cardiol* 1991; 18:187-192.
  21. Pattee PL, Chambers RJ. Acquired postoperative coronary arteriovenous fistula. *Cathet cardiovasc Diagn* 1992; 26:140-142.
  22. Ray SG, Cowan MD, Kennedy JA. Spontaneous acquired fistula from the right coronary artery to the right ventricular cavity. *Br Heart J* 1992; 67:323-324.
  23. Searcy RA, Stein PD, Gunesan G, Bruce TA. Arterio-atrial shunting in coronary atherosclerosis. *Chest* 1971; 59:398-401.
  24. Karim MA. Coronary artery aneurysmal fistula: a late complication of stent deployment. *Int J Cardiol* 1996; 57:207-209.
  25. Bata IR, MacDonald RG, O'Neill BJ. Coronary artery fistula as a complication of percutaneous transluminal coronary angioplasty. *Can J Cardiol* 1993; 9:331-335.
  26. Bartorelli AL, Pepi M, Sganzerla P, Montorsi P, Loaldi A, Ravagnani P, Fabbiocchi F: Syncope with cardiac arrest as the first manifestation of two congenital left coronary artery-to-main pulmonary artery fistulae. *Am Heart J* 1994; 127:207-209.

27. Ogino K, Hisatome I, Kotake H, Furuse T, Mashiba H, Kuroda H, Mori T. A case of four coronary artery fistulae originating from three vessels associated with aneurysm. *Eur Heart J* 1987; 8:1260-1263.
28. Abhyankar AD, Mok NS, Helprin GA, L Pressley. Multiple coronary-pulmonary fistulae involving all three coronary arteries: a case report. *Int J Cardiol* 1996; 57:181-183.
29. Ashraf SS, Shaukat N, Fisher M, Clarke B, Keenan DJ. Bicoronary-pulmonary fistulae with coexistent mitral valve prolapse: a case report and literature review of coronary-pulmonary fistula. *Eur Heart J* 1994; 15:571-574.
30. Takahashi M, Sekiguchi H, Fujikawa H, Mito H, Eto M, Hojo Y, Chiba Y, Kitamura S, Shimada K. Multicystic aneurysmal dilatation of bilateral coronary artery fistula. *Cathet Cardiovasc Diagn* 1994; 31:290-292.
31. Farooki ZQ, Nowlen T, Hakimi M, Pinsky WW. Congenital coronary artery fistulae: A review of 18 cases with special emphasis on spontaneous closure. *Pediatr Cardiol* 1993; 14:208-213.
32. Shyam Sunder KR, Balakrishnan KG, Tharakan JA, Titus T, Pillai VRK, Francis B, Kumar A, Bhat A, Shankaran S. Coronary artery fistula in children and adults: a review of 25 cases with long-term observations. *Int J Cardiol* 1997; 58:47-53.
33. Perry SB, Rome J, Keane JF, Baim DS, Lock JE. Transcatheter closure of coronary artery fistulas. *J Am Coll Cardiol* 1992; 20:205-209.

Table1: Characteristics of seven adult patients with acquired coronary cameral fistula

Patient No.	Date of detection age/sex	Mode of detection Etiology	Collaterals and percent of stenosis CCF	MI	Associated disorders.	CABG
1	14-02-1994 59/M	CAG Atherosclerosis	LAD-80% → coll → Cx Cx-100%, RCA-80% CCF: RCA → RA	1994 ASMI	MVP/RR	LIMA → LAD VSM → RCA VSM → Cx
2	21-07-93 72/F	CAG Atherosclerosis	LAD-100%, pICx-90%, coll → RCA, RCA-100%. Graft D-LAD: patent Graft OM-PL: 100% CCF: Cx → LV	1987 ALMI	MR	VSM → D-LAD VSM → OM-PL
3	03-05-1995 46/M	CAG Myocardial infarction	LAD-80%, D-70%, Cx-70%, coll → RCA, RCA-90%, bridge coll. to periphery CCF: RCA → RA	IMI, silent	None	LIMA → LAD-D RIMA → OM2 VSM → PL-PD
4	15-11-1995 40/M	CAG Atherosclerosis	Cx-90%, RCA-100%, bridge coll. to periphery CCF: RCA → RA	1995 PMI, 1996 ILMI	None	Medical. 2x PTCA of Cx
5	06-12-1995 53/M	CAG Atherosclerosis	Cx-99%, bridge coll. to periphery and RCA, RCA-95% CCF: RCA → PT	None	None	Medical
6	12-06-1995 68/M	CAG Myocardial infarction	LAD-100%, AL-90%, pICx-80%, RCA- coll. to LAD CCF: LAD → LV	1990 ASMI, pericarditis 1995 reMI	CHF/AF	PTCA of AL and Cx
7	03-06-1996 77/M	CAG Atherosclerosis	LAD-90%, Cx-90%, RCA-100% CCF: RCA → RA	IPMI	MVP/MR	Died, cardiac death while awaiting CABG.

Abbreviations: M= male; F= female; CAG= coronary angiography; CABG= coronary artery bypass grafting; CCF= coronary cameral fistula; LAD=

left anterior descending coronary artery; Cx= circumflex coronary artery; RCA= right coronary artery; LIMA= left internal mammary artery; RIMA= right internal mammary artery; VSM= vena saphena magna; D= diagonal branch; OM= obtuse marginal branch; PL= posterolateral branch; AL= anterolateral branch; coll= collateral; PD= posterior descending artery; RA=right atrium; LV= left ventricle; PT= pulmonary trunk; MI= myocardial infarction; reMI= recurrent; ASMI= anteroseptal; ALMI= anterolateral; IMI= inferior; PMI= posterior; ILMI= inferolateral; MVP= mitral valve prolaps; MR= mitral regurgitation; RR= hypertension; AF= atrial fibrillation; CHF= congestive heart failure; →= to.

Table 2: Pathogenesis and speculative factors contributing to the formation of acquired coronary cameral fistula.

First author/year (Ref. No.)	Etiology	Factors contributing to fistula formation
Meng 1985 <sup>[8]</sup>	PTCA	Intracardiac perforation
Iannone 1990 <sup>[10]</sup>	PTCA	Oversized balloon, inappropriate wire tracking
Grill 1991 <sup>[9]</sup>	PTCA	Soft infarcted tissue surrounding ruptured artery
El-Omar 1995 <sup>[11]</sup>	PTCA	Oversized balloon, inappropriate wire tracking and intracardiac perforation
Lee 1989 <sup>[13]</sup>	MI	A limited bleeding and rupture of the coronary arteries into necrotic myocardial site creating the coronary-cameral fistula
Shimizu 1993 <sup>[15]</sup>		
Somsen 1994 <sup>[16]</sup>		
Searcy 1971 <sup>[23]</sup>	MI	Aberrant development of collateral vessels leading to coronary-cameral fistula formation <sup>[22, 23]</sup> or by reopening of the Thebesian veins <sup>[14]</sup>
Ryan 1977 <sup>[14]</sup>		
Ray 1992 <sup>[22]</sup>		
Lee 1988 <sup>[19]</sup>	Cardiac surgery	Direct injury of right atrial artery leading to the development of coronary-cameral fistula
Cheng 1973 <sup>[5]</sup>	Trauma	Traumatic laceration of coronary artery by stab wound
Saeian 1991 <sup>[17]</sup>	Cardiac pacing	Erosion of the permanent ventricular pacing lead into the interventricular septum creating coronary-cameral fistula
Sandhu 1989 <sup>[18]</sup>	Biopsy	Result of repeated right ventricular endomyocardial biopsy



# 3C

**Coronary Angiographic Morphology of  
Congenital Coronary Arteriovenous  
Fistulas in Adults  
Report of four new cases and review of  
angiograms of fifteen reported cases**

**Salah A.M. Said  
Mamdouh I.H. El Gamal**

**Published in:  
Cathet Cardiovasc Diagn 1995; 35:29-35**



The coronary angiographic features of four new cases of congenital coronary arteriovenous fistulas (CAVFs) are described, and the angiograms of 15 reported cases are reviewed. The morphologic appearance of CAVFs varied from a small discrete single channel to highly complex plexiform network with a maze of fine vessels. The majority of CAVFs in our series were composed of a single channel. Aneurysmal formation was present in 26% (6/23). Aneurysmal formation involved only the pathway and/or the termination, but never originated from the beginning of the CAVFs.

## Introduction

Coronary arteriovenous fistulas are no longer considered rare malformations of the coronary arteries and have become readily recognized.<sup>1</sup> Their incidence is estimated at 0.1% to 0.2% as demonstrated by selective coronary arteriography.<sup>1-3</sup> The patients are usually asymptomatic, and the diagnosis is often suspected when a continuous cardiac murmur is heard. However, the findings at physical examination are highly variable in patients with CAVFs. Coronary arteriovenous fistulas can be associated with congestive cardiac failure, myocardial ischemia or infarction and endocarditis. These fistulas are usually congenital, but may also have an acquired pathogenesis subsequent to surgical or nonsurgical thoracic trauma.

These fistulous communications generally occur as an isolated anomaly, but can be associated with other congenital or acquired cardiac disorders<sup>4-8</sup> or with severe coronary atherosclerosis.<sup>9</sup> CAVFs may also result from blunt or sharp chest injuries,<sup>10</sup> or they may be related to repeated endomyocardial biopsies in heart transplant patients.<sup>11</sup> CAVFs can also be associated with permanent endocardial pacing electrode erosion.<sup>12</sup> They can also occur as a consequence of cardiac<sup>13</sup> or coronary surgery,<sup>14</sup> or possibly following a myocardial infarction.<sup>15,16</sup> In this report, we describe the coronary angiographic characteristics of congenital coronary arteriovenous fistulas in nineteen patients.

## Materials and methods

To study the morphologic characteristics of coronary arteriovenous fistulas, we reviewed the coronary angiograms of 15 reported patients (cases 5-19) and reported the findings in four additional cases. The four new cases with CAVFs (patients 1-4) had a mean age of 47.7 years (range 33-63).

The clinical findings and long-term, follow-up data of the fifteen reported patients have been published elsewhere.<sup>2,7,19,20,23,35,36,38</sup> Coronary angiographic findings of all 19 patients (23 CAVFs) are presented in Table I. The morphologic appearance (Fig. 1 and 2) of the coronary arteriovenous fistulas is summarized in Table II. An arteriovenous fistula was defined as an abnormal communication between one or several coronary arteries and any cardiac chamber or great vessel. Two CAVFs consisted of simple channel and two were found to have complex structures. The origin of the CAVFs was the RCA (3x) and the LAD (1x). One CAVF terminated in the pulmonary trunk, two in the right atrium, and one in the right ventricle. Atrial fibrillation was documented in one subject with congestive cardiac failure. Evidence for acute myocardial infarction (AMI) was present in three patients (2 x anterior and 1 x inferior walls) with two of them occurring contralaterally and one occurring ipsilaterally to the shunt. Single vessel disease (VD) was present in one patient and triple VD in another patient. Triple coronary arterial bypass grafting was performed in the latter patient.

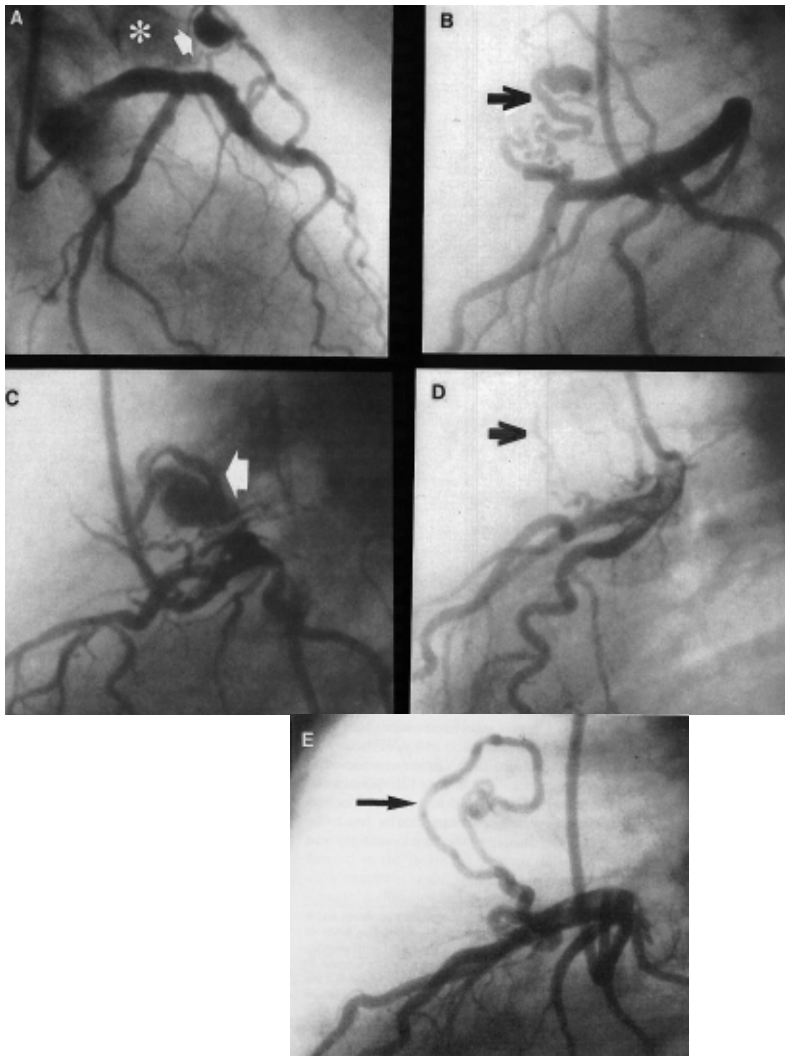


Fig. 1A: left coronary angiogram, right anterior oblique view, showing a CAVF with an aneurysm (arrow) along its pathway to the pulmonary trunk (\*). B: Left lateral view, demonstrating a convolute (arrow) of CAVF arising from the proximal LAD. C: Left lateral view depicting a CAVF consisting of serpiginous vessels and an aneurysm (arrow). D: Left lateral view showing CAVF containing several small tortuous vessels (arrow). E: Left lateral view showing the lasso-appearance of CAVF (arrow) with a small aneurysm along its pathway.

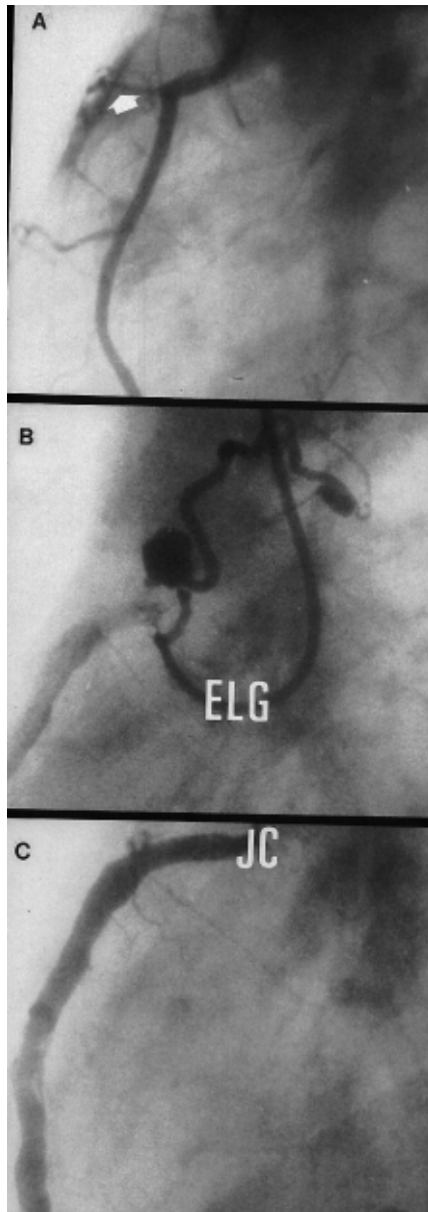


Fig. 2A: Right coronary angiogram, depicting contrast staining of the right atrial wall through a CAVF originating from its proximal portion. B: From Said and Landman [2] with permission and C: The El Gamal catheter has been used to demonstrate the CAVF which would have been overlooked if the Judkins catheter (JC) had been used. CAVF = coronary arteriovenous fistulas.

**Case 1**

A 47-year-old man, with known uncomplicated inferior myocardial infarction 1 yr earlier, underwent coronary angiography for risk stratification due to unstable angina. On physical examination, blood pressure was 140/90 mm Hg, pulse was regular 92/min. The remainder of the physical examination was not informative. Electrocardiogram demonstrated sinus rhythm and signs compatible with an old inferior myocardial infarction. Chest X-ray revealed a cardiothoracic ratio of less than 50% with clear lung fields. The radionuclide derived left ventricular ejection fraction was 52%.

During cardiac catheterization, intracardiac pressures and oximetric data were normal. Coronary angiography disclosed a normal left main coronary artery. There were tandem lesions with 70% stenoses in the left anterior descending coronary artery before the origin of the first diagonal branch and 60% stenosis in the posterolateral branch of the circumflex artery. The right coronary artery showed proximal total occlusion with bridge collaterals filling its distal portion and opacifying the right atrium via separate small channels. The left ventriculogram showed early relaxation of the anterolateral wall. Coronary revascularization was performed with a sequential saphenous vein graft anastomosed to the left posterolateral branch and right posterior descending arteries. The left internal mammary artery was anastomosed to the left anterior descending artery. The post-operative course was uncomplicated. The patient is doing well.

## **Case 2**

The patient was a 47-year-old man with a 1-yr-old anteroseptal myocardial infarction. He was normotensive and there were no abnormal physical signs on clinical examination. Laboratory findings were within normal limits. ECG was compatible with the diagnosis of an old anteroseptal myocardial infarction. The chest X-ray was normal. Doppler echocardiography demonstrated septal hypokinesia. Cardiac catheterization was performed because of recurrent anginal complaints. This procedure revealed normal intracardiac pressures and a normal coronary arterial tree. The left ventriculogram revealed anterolateral and apical hypokinesia. The right coronary artery demonstrated a fistula terminating into the right ventricle just below the tricuspid valve. Oximetric studies showed negligible left-to-right shunt. The radionuclide left-to-right shunt measurements showed a slight increment on exercise (qp:qs at rest was 1.1 and on exercise was 1.4). He was treated medically with aspirin, furosemide 40 mg once daily and nitrates 20 mg three times daily. The patient remains asymptomatic.

## **Case 3**

A 33-year-old woman was admitted with an acute anterolateral myocardial infarction. She was successfully treated with  $1.5 \times 10^6$  U of streptokinase administered intravenously. She was a smoker and was on oral contraceptives for many years. Physical examination revealed no abnormal findings. ECG revealed minimal R-wave loss in the right precordial leads and negative T-waves in the lateral leads. Chest X-ray was normal. During cardiac catheterization, careful orientation and manipulation of angiographic catheter was helpful in fully visualising a fistula originating from the right coronary artery terminating into the right atrium (Fig. 2). The branches of the left coronary artery were all normal except for a proximal stenosis of 50% in the diagonal branch. Contrast ventriculography showed a normal contraction pattern. Fluoroscopy in several projections demonstrated pooling of contrast in the right atrium following right coronary artery injection. She remains asymptomatic.

## **Case 4**

A 63-year-old man, with congestive heart failure and atrial fibrillation with rapid ventricular response, underwent successful radio frequency ablation of the bundle of His. ECG showed atrial fibrillation without ischemic changes. Doppler echocardiography revealed left

ventricular dilatation with diffuse hypokinesia and mild mitral incompetence. He responded well to diuretic therapy. Permanent transvenous ventricular pacing system was necessary because of total AV block. During cardiac catheterization, a left-to-right shunt was not detected. Intracardiac pressures were normal. Contrast ventriculography demonstrated diffuse hypokinesia with mitral incompetence grade I/IV. The coronary arterial tree was normal with a fistulous communication between the proximal portion of the left anterior descending coronary artery and the pulmonary trunk. He remains well.

## Discussion

Coronary arteriovenous fistulas (CAVFs) are the most common coronary anomaly. Proper early diagnosis is essential since they play a role in the differential diagnosis of cardiac disorders associated with a continuous murmur, such as patent ductus arteriosus. The majority of patients with CAVFs are usually asymptomatic, but occasionally they may develop acute or chronic symptoms of cardiac ischemia or infarction, heart failure, endocarditis, recurrent upper respiratory tract infection, or in some rare cases, pulmonary hypertension.<sup>17,18</sup> Myocardial infarction, ventricular and supraventricular rhythm disturbances have been reported in patients with CAVFs.<sup>19-22</sup> In the present series, intractable atrial fibrillation was present in one patient (Case 4), ipsilateral myocardial infarction in another and contralateral to the shunt in two of the patients. The clinical diagnosis is usually suspected from detection of a continuous murmur in an unusual location for a patent ductus arteriosus.<sup>17,18</sup> The conclusive diagnosis is made by means of coronary angiography. Several angiographic diagnostic features of CAVFs are proposed in the literature<sup>2,4,6</sup> and were all verified in our series: (1) The coronary artery involved in a congenital CAVF is usually tortuous and markedly dilated, (2) The contrast medium is seen clearly spurting into the affected cardiac chamber; this was present in all patients. In one patient (Case 3), the CAVF would have been overlooked if the catheter was not oriented toward the opening of the fistula.

Although coronary angiography is essential for definite diagnosis of CAVFs, recent reports have suggested the usefulness of several non-invasive techniques, such as Doppler echocardiography,<sup>23-28</sup> magnetic resonance imaging<sup>29,30</sup> and transesophageal echocardiography<sup>31-33</sup> in diagnosing these anomalies. The supplementary role of transesophageal echocardiography to coronary angiography for diagnosis of patients with coronary artery anomalies has been established.<sup>34</sup> In the selected series of Giannoccaro et al., transesophageal echocardiography confirmed the presence of coronary artery anomalies detected by angiography and helped to locate the course and drainage site of CAVFs.<sup>34</sup> CAVFs associated with intracardiac tumor are rare<sup>35</sup> and multiple fistulas are even rarer.<sup>36</sup> Although these abnormalities have been associated with longevity,<sup>37,38</sup> the spontaneous resolution of CAVF is rare. It has been postulated that small CAVFs are considered to have a relatively benign natural history.<sup>2</sup> When adult patients are evaluated, the possibility of acquired as well as congenital coronary arteriovenous fistulas has to be taken into account. Clinically, the two conditions can appear identical. The differentiation can be made, besides the history, by using selective coronary angiography and observing the size of the involved coronary artery. The involved coronary artery usually has a normal caliber in atherosclerotic disease, but is dilated and tortuous in congenital coronary arteriovenous fistulas. Moreover, true aneurysmal formation along the fistulous tract could be seen in the latter condition. In our series, the diagnosis was confirmed by the presence of these morphologic characteristics (Fig. 1 and 2).

Since the report of Krause in 1865, several reports have been published about the subject.<sup>21,22,39-41</sup> Correct identification of this anomaly is particularly important. Surgery can be successfully performed, even at older age, as was recently reported.<sup>42</sup> Recently, other nonsurgical procedures have been successfully performed in the treatment of patients with CAVFs. One such treatment is the application of transcatheter embolization techniques using Ivalon particles, implantable coils, and detachable balloon.<sup>43-46</sup> Congenital coronary arteriovenous fistulas show a wide clinical spectrum, occurring in the

young<sup>4</sup> as well as in elderly patients.<sup>47</sup> The reason for unpredictable clinical presentation of this anomaly depends on two features: the magnitude of left-to-right shunt; and the presence of associated cardiac disorders or concomitant important coronary atherosclerosis. In our series, 26% of the fistulas demonstrated aneurysmal formation. When the diagnosis is made, periodical noninvasive re-evaluation should take place. This includes ECG, stress testing, Doppler echocardiography, and Holter monitoring. When abnormalities are found, such as ischemic ECG changes, positive exercise testing, valvular dysfunction, or rhythm disturbances, invasive re-assessment prior to closure of the CAVF is recommended. Surgical or nonsurgical ligation of the CAVF depends on the type and size of the shunt and on the presence or absence of concomitant cardiac or coronary artery disease. We believe that endocarditis prophylaxis should be advised for this anomaly.

### Acknowledgments

We express our deep gratitude to Mrs. H.E. Blijdenstein and Mrs. M. Fraser for their secretarial assistance during the preparation of this manuscript. We are also very grateful to the staff of the Cardiology Department of Catharina Hospital, Eindhoven, for providing the angiograms.

### References

1. Gillebert C, Van Hoof R, Van de Werf F, Piessens J, de Geest H: Coronary artery fistulas in an adult population. *Eur Heart J* 1986; 7:437-443.
2. Said SAM, Landman GHM: Coronary-pulmonary fistula: Long-term follow-up in operated and non-operated patients. *Int J Cardiol* 1990; 27:203-210.
3. Baltaxe HA, Wixson D: The incidence of congenital anomalies of the coronary arteries in adult population. *Radiology* 1977; 122:47-52.
4. Upshaw, Jr, CB: Congenital coronary arteriovenous fistula. Report of a case with an analysis of seventy-three reported cases. *Am Heart J* 1962; 63:399-404.
5. Saxena A, Sharma S, Shrivastava S: Coronary arteriovenous fistula in tetralogy of Fallot: an unusual association. *Int J Cardiol* 1990; 28:373-374.
6. McNamara JJ, Gross RE: Congenital coronary artery fistula. *Surgery* 1969; 65:59-69.
7. Said SAM, Bucx JJJ, van de Weel FA: Coronary-cameral fistula in association with Klinefelter syndrome: exercise-induced ventricular tachycardia late after surgical ligation. *Int J Cardiol* 1992; 36:111-114.
8. King SB III, Schoonmaker FW: Coronary artery to left atrial fistula in association with severe atherosclerosis and mitral stenosis: Report of surgical repair. *Chest* 1975; 67:361-363.
9. Searcy RA, Stein PD, Gunesan G, Bruce TA. Arterio-atrial shunting in coronary atherosclerosis. *Chest* 1971; 59:398-401.
10. Morgan JR, Forker AD, O'Sullivan, Jr, MJ, Fosburg RG: Coronary arterial fistulas. Seven cases with unusual features. *Am J Cardiol* 1972; 30:432-436.
11. Sandhu JS, Uretsky BF, Zerbe TR, Goldsmith AS, Reddy PS, Kormos RL, Griffith BP, Hardesty RL: Coronary artery fistula in the heart transplant patient. A potential complication of endomyocardial biopsy. *Circulation* 1989; 2:350-356.
12. Saeian K, Vellinga T, Troup P, Wetherbee J: Coronary artery fistula formation secondary to permanent pacemaker placement. *Chest* 1991; 3:780-781.
13. Pattee PL, Chambers RJ. Acquired postoperative coronary arteriovenous fistula. *Cathet Cardiovasc Diagn* 1992; 26:140-142.
14. Riahi M, Stone KS, Hanni CL, Fierens E, Dean RE: Right ventricular-saphenous vein graft fistula. *J Thorac Cardiovasc Surg* 1984; 87:626-628.
15. Phillips PA, Libanoff AJ: Arteriovenous communication associated with obstructive arteriosclerotic coronary artery disease and myocardial infarction. *Chest* 1974; 65:106-108.

16. Ray SG, Cowan MD, Kennedy JA. Spontaneous acquired fistula from the right coronary artery to the right ventricular cavity. *Br Heart J* 1992; 67:323-324.
17. Pasternak RC: Case records of the Massachusetts General Hospital. *NEJM* 1986; 315:1533-1543.
18. Rittenhouse EA, Doty DB, Ehrenhaft JL: Congenital coronary artery-cardiac chamber fistula. Review of operative management. *Ann Thorac Surg* 1975; 20:468-485.
19. Said SAM, Relik Th: An unusual cause of non-sustained ventricular tachycardia in an athlete. *Netherl J Cardiol* 1990; 3:143-147.
20. Said SAM, Bucx JJJ: Coronary angiographic observations; coronary atherosclerosis and myocardial infarction in coronary-pulmonary fistula. *Netherl J Cardiol* 1991; 4:237-241.
21. Singham KT, Anuar M: Left coronary to pulmonary artery fistula. *Australas Radiol* 1988; 32:385-386.
22. Sakakibara S, Yokoyama M, Takao A, Nogi M, Gomi H. Coronary arteriovenous fistula. *Am Heart J* 1966; 72:307-314.
23. Said S: Doppler echocardiographic findings in coronary-pulmonary fistula. *Int J Cardiol* 1989; 25:343-646.
24. Rodgers DM, Wolf NM, Barrett MJ, Zuckerman GL, Meister G: Two-dimensional echocardiographic features of coronary arteriovenous fistula. *Am Heart J* 1982; 104:872-874.
25. Yoshikawa J, Katao H, Yanagihara K, Takagi Y, Okumachi F, Yoshida K, Tomita Y, Fukaya T, Baba K: Noninvasive visualization of the dilated main coronary arteries in coronary artery fistulas by cross-sectional echocardiography. *Circulation* 1982; 65:600-603.
26. Oliver JM, Lopes de Sa E, Dominguez F, Sobrino JA, Munoz JE, Iglesias A: Congenital right coronary artery-to-left atrium fistula detected by two-dimensional and Doppler echocardiography. *Am Heart J* 1987; 114:165-166.
27. Chen CC, Hwang B, Hsiung MC, Chiang BN, Meng LC, Wang DJ, Wang SP: Recognition of coronary arterial fistula by Doppler 2-dimensional echocardiography. *Am J Cardiol* 1984; 53:392-394.
28. Bahl VK, Shrivastava S: Non-invasive diagnosis of congenital coronary arteriovenous fistula by cross-sectional and Doppler echocardiography. *Int J Cardiol* 1987; 17:89-91.
29. Wertheimer JH, Toto A, Goldman A, DeGroat T, Scanlon M, Nakhjavan FK, Kotler M. Magnetic resonance imaging and two-dimensional and Doppler echocardiography in the diagnosis of coronary cameral fistula. *Am Heart J* 1987; 114:159-162.
30. Kubota S, Suzuki T, Murata K: Cinemagnetic resonance imaging for diagnosis of right coronary arterial-ventricular fistula. *Chest* 1991; 100:735-737.
31. Kugelmass AD, Manning WJ, Piana RN, Weintraub RM, Baim DS, Grossman W: Coronary arteriovenous fistula presenting as congestive heart failure. *Cathet Cardiovasc Diagn* 1992; 26:19-25.
32. Chen YT, Lee YS, Kan MN, Chen JS, Hu WS, Lin WW, Wang KY, Lin CJ, Chiang BN: Transesophageal echocardiography in adults with a continuous precordial murmur. *Int J Cardiol* 1992; 36:61-68.
33. Fernandes F, Alam M, Smith S, Khaja F: The role of transesophageal echocardiography in identifying anomalous coronary arteries. *Circulation* 1993; 88:2532-2540.
34. Giannoccaro PJ, Sochowski RA, Morton BC, Chan KL: Complementary role of transesophageal echocardiography to coronary angiography in the assessment of coronary artery anomalies. *Br Heart J* 1993; 70:70-74.
35. Said SAM, Werner HA, Veerbeek A: Coronary-cameral fistula in association with intracardiac tumour and aortic stenosis in an adult. *Int J Cardiol* 1991; 33:159-162.
36. Said SAM, Bucx JJJ, van de Weel FA: Stress MIBI scintigraphy in multiple coronary-pulmonary fistula: failure to demonstrate the 'steal' phenomenon. *Int J Cardiol* 1992; 35:270-272.

37. Gasul BM, Arcilla RA, Fell EH, Lynfield J, Bicoiff JP, Luan LL: Congenital coronary arteriovenous fistula. Clinical, phonocardiographic, angiographic and hemodynamic studies in five patients. *Pediatrics* 1960; 25:531-560.
38. Said SAM, Austermann-Kaper T, Bucx JJJ: Congenital coronary arteriovenous fistula associated with atrioventricular valvular regurgitation in an octogenarian. *Int J Cardiol* 1993; 38:96-97.
39. Wearn JT, Mettier SR, Klumpp TG, Zschiescho LJ: The nature of the vascular communication between the coronary arteries and the chambers of the heart. *Am Heart J* 1933; 9:143-149.
40. Krause W. Über den Ursprung einer akzessorischen A. coronaria aus der A. pulmonalis. *Z Rationell Med* 1865; 24:225-227.
41. Oshiro H, Shimabukuro M, Nakada Y, Chibana T, Yoshida H, Nagamine F, Sunagawa R, Gushiken M, Murkami K, Mimura G: Multiple coronary LV fistulas: Demonstration of coronary steal phenomenon by stress thallium scintigraphy and exercise hemodynamics. *Am Heart J* 1990; 120:217-219.
42. Brack MJ, Hubner PJB, Firmin RK: Successful operation on a coronary arteriovenous fistula in a 74-year-old woman. *Br Heart J* 1991; 65:107-108.
43. Bennett JM, Maree E: Successful embolization of a coronary arterial fistula. *Int J Cardiol* 1989; 23:405-406.
44. Van den Brand M, Pieterman H, Suryapranata H, Bogers AJJC: Closure of a coronary fistula with a transcatheter implantable coil. *Cathet Cardiovasc Diagn* 1992; 25:223-226.
45. Reidy JF, Anjos RT, Qureshi SA, Baker EJ, Tynan MJ: Transcatheter embolization in the treatment of coronary artery fistulas. *J Am Coll Cardiol* 1991; 18:187-192.
46. Peregrin JH, Zelizko M, Kovac J: Detachable balloon embolization of an iatrogenic aortocoronary arteriovenous fistula combined with aortocoronary bypass PTCA: A case report. *Cathet Cardiovasc Diagn* 1992; 27:137-140.
47. Iskandrian AS, Kimbiris D, Bemis CE, Segal BL: Coronary artery to pulmonary artery fistulas. *Am Heart J* 1978; 96:605-609.



Table 1: Coronary Angiographic Findings and Aneurysm Formation in CAVFs

Case <sup>a</sup>	Origin <sup>b</sup>	Termination <sup>c</sup>	Aneurysm <sup>d</sup>	Infarction <sup>e</sup>
1	RCA	RA	-	+, IMI
2	RCA	RV	-	+, ASMI
3	RCA	RA	-	+, ALMI
4	LAD	PT	-	-
5	LAD	PT	+	-
6	LAD	PT	+	-
7	LAD	PT	+	-
8	LAD	PT	-	-
9	LAD	PT	+	+, IMI
10	LAD	PT	-	-
11	LAD+RCA	PT	-	-
12	RCA	PT	+	-
13	LAD	PT	-	-
14	LAD+RCA	PT	-	+, IPMI
15	LAD	PT	+	+, IPMI
16	CX	CS	-	-
17	LAD+RCA+CX	PT	-	-
18	RCA	RA	-	-
19	CX	RA	-	+, PMI

<sup>a</sup> Clinical and follow-up data of cases 5-19 have been the subject of earlier reports.

<sup>2,7,19,20,23,35,36,38</sup> <sup>b</sup> RCA = right coronary artery; LAD = left anterior descending coronary artery; CX = circumflex coronary artery. <sup>c</sup> RA = right atrium; RV = right ventricle; PT = pulmonary trunk; CS = coronary sinus. <sup>d</sup> - = absent; + = present. <sup>e</sup> IMI = inferior myocardial infarction; ASMI = anteroseptal myocardial infarction; ALMI = anterolateral myocardial infarction; IPMI = inferoposterior myocardial infarction; PMI = posterior myocardial infarction.

Table 2: Morphological Appearance of 23 CAVFs in 19 Patients\*

Case	Origin	Termination	Pathway
1	Multiple	multiple	multiple+BC
2	Single	multiple	single
3	Single	single	single
4	Single	single	single
5	multiple + T	via aneurysm	T
6	Multiple	via aneurysm	T
7	single + T	via aneurysm	windings + T
8	Single	single	tortuous
9	Multiple	via aneurysm	T
10	Multiple	multiple	T
11	multiple + single	single + single	T
12	Single	single + E	aneurysm + T
13	Single	single	
14	single + single	single + single	T + T
15	Multiple	via aneurysm	aneurysm + T
16	single + E	single	T
17	3x single	3x single	T
18	Single	single	single
19	Single	single	T

\* Single = single fistulous channel; multiple = multiple fistulous channels; BC = bridge collaterals; T = tortuous; E = ectatic channel.



# 3D

## **Congenital and Atherosclerotic (Acquired) Coronary Artery Aneurysms: Coronary Angiographic and Morphologic Observations in 10 Patients**

**Salah A.M. Said  
Mamdouh El Gamal  
Tjeerd van der Werf**

**Published in:  
International Journal of Angiology 1998; 7:206-210**

## Abstract

Coronary angiographic observations in 10 patients with coronary artery aneurysms (CAAs) are reported. Four patients had atherosclerotic (acquired) and six had congenital CAAs. The mean age of patients with acquired CAAs was higher (64.7 years) compared with the congenital group (52.2 years). Ipsilateral myocardial infarction (MI) occurred in three of four patients with acquired CAAs but MI was not located on the same side as the aneurysm-bearing coronary artery (contralateral) in two patients with the congenital variety. In the patients with congenital CAAs, an aneurysm predilection site was observed in the proximal portion of the aneurysm-bearing vessel. Dual and multiple aneurysms were more common in the acquired CAAs. Although congenital CAAs were sizeable, the small-sized atherosclerotic CAAs developed complications more frequently. During an average follow-up of 7.9 years, only one patient died of a noncardiac cause and another developed recurrent uncomplicated non-Q-wave lateral MI. Both subjects had atherosclerotic CAAs. In our series, no rupture or sudden death occurred. Coronary artery bypass grafting (CABG) was performed in three patients with acquired and in one patient with congenital CAAs. In the latter patient, simultaneous ligation of the congenital aneurysm associated with a coronary arteriovenous fistula was performed. Regarding antiplatelet and anticoagulant policy for the whole group, three patients were on aspirin, four were on acenocoumarol, and in another three subjects with congenital CAAs, a medical regimen was followed. Larger series, however, are required in order to elucidate further angiographic characteristics of acquired vs congenital CAAs.

## Introduction

Coronary artery aneurysms were first reported post-mortem by Morgagni in 1761.<sup>1</sup> In 1958 Munkner and colleagues described a congenital coronary artery aneurysm associated with a coronary arteriovenous fistula ante-mortem.<sup>2</sup> There are several causes of CAAs. Atherosclerosis is responsible for 52%.<sup>3</sup> Other conditions include infections, trauma, vasculitis, neoplasm and connective tissue disorders (Ehlers-Danlos and Marfan's syndrome). CAAs may also complicate the course of the mucocutaneous lymph node syndrome (Kawasaki disease).<sup>4,5</sup>

The incidence of CAAs is 2.5%, based on arteriographic findings.<sup>6</sup> In association with CAAs, death has rarely been attributed to rupture of acquired aneurysms.<sup>6</sup> The coronary angiographic and morphological observations of atherosclerotic (acquired) and congenital CAAs are described.

## Patients and Methods

Ten patients (one female) with a mean age of 58.4 years (range 37-79) with acquired (4x, mean 64.7, range 53-79) and congenital (6x, mean age 53.2, range 37-62) CAAs are reviewed. This series was collected during the period 1981-93. The patient characteristics are summarized in Tables 1 and 2. According to Aintablian et al.,<sup>6</sup> an aneurysm is defined as a coronary dilatation that exceeds the diameter of the normal adjacent segments or the diameter of the patient's largest coronary vessel by a factor of 1.5. Since it has been reported that atherosclerosis is the most common cause of acquired CAAs, the following definition was used to discriminate between atherosclerotic and congenital CAAs. Coronary artery aneurysms were categorized as atherosclerotic (acquired) when aneurysms were detected in a diffusely atherosclerotic coronary arterial tree. The congenital CAAs were categorized as such when the aneurysms were detected in a nonobstructive coronary arterial tree without preceding chest trauma, endovascular intervention, or specific disease entities, and were coexistent with other congenital disorders.

The angiograms of four patients with acquired CAAs (Fig. 1) were compared with angiograms of six patients with congenital CAAs (Fig. 2) that were previously reported.<sup>7</sup> Significant atherosclerosis was present in all subjects with acquired CAAs. Regarding risk factors for coronary artery disease, two patients smoked, two had systemic hypertension

(moderate 1 x [180/100 mm Hg] and systolic 1 x [200/90 mm Hg]), and one had diabetes mellitus and elevated serum cholesterol level (8.2 mmol/L) (N 5.0 mmol/L). None of the patients had a history of Kawasaki disease, connective tissue disorders, or chest trauma. Two patients had two-vessel disease and two others three-vessel disease. MI was documented in three patients. Non-Q-wave MI occurred in two patients and one suffered a transmural MI.

The infarct area correlated well with the aneurysmatic vessel in two patients (2 x LAD) (left anterior descending) but the site of the infarct area in the third patient was undetermined (Table 3). Due to progression of angina despite adequate medical treatment, CABG was performed in three patients (patients 8, 9, 10) and percutaneous transluminal coronary angioplasty in a single patient (patient 7). In (patient 8) at operation, the coronary arteries inspected were of moderate quality. A jump venous graft was anastomosed to the diagonal, circumflex, and descending posterior coronary arteries and a single venous graft was anastomosed to the left anterior descending artery. On 2 April, 1993, patient 9 underwent coronary artery bypass grafting. A single venous graft was connected to the second obtuse marginal branch and another to the right coronary arteries; in the latter after endarterioectomy. Furthermore, the left internal mammary artery graft was anastomosed to the left anterior descending artery. When inspecting the coronary arteries during bypass surgery (patient 10), the obtuse marginal branch and descending posterior were of poor quality. A dual venous graft was anastomosed to the obtuse marginal and descending posterior coronary arteries. Coronary artery bypass surgery combined with ligation of an aneurysm associated with coronary arterial fistula was performed in patient 4. A left internal mammary artery graft to the left anterior descending artery and double venous grafting to the right and obtuse marginal arteries were performed.

The postoperative course was without complications. A regimen of oral anticoagulant therapy was followed in two patients (patients 9 and 10) and two patients (4 and 8) received therapy with aspirin. No perioperative MI occurred.

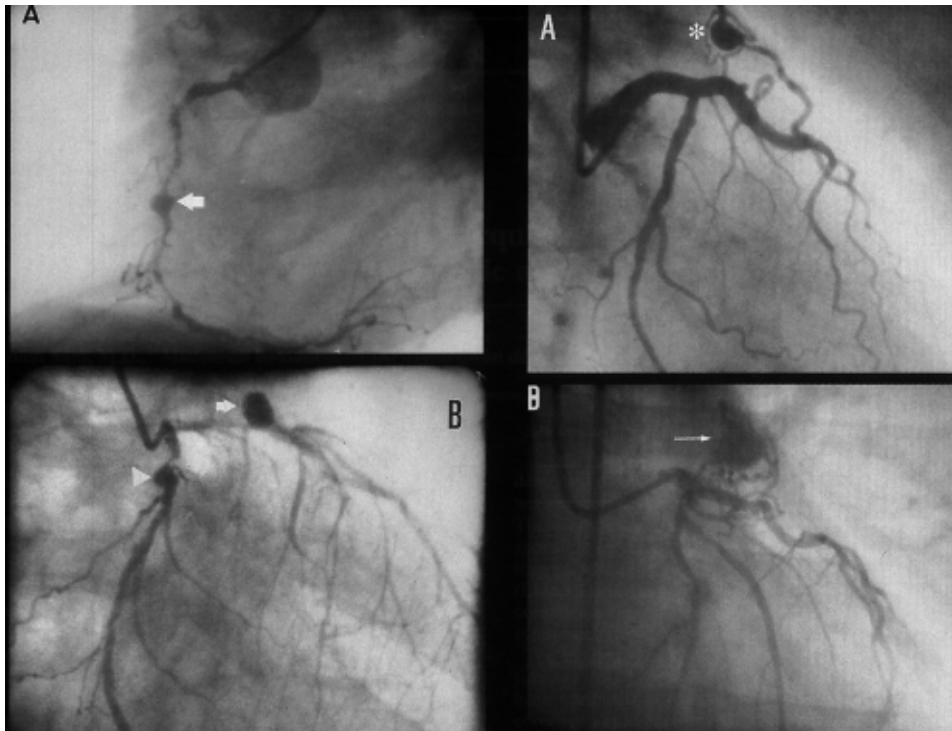


Fig. 1

Fig. 2

#### Legends

Fig. 1. Atherosclerotic (acquired) CAAs. **(A)** Right coronary angiogram in left anterior oblique (LAO) demonstrating diffuse sclerosis and stenoses with a large mid-traject saccular aneurysm (arrow). There is no side branch involvement. **(B)** Left coronary angiogram in right anterior oblique projection, showing dual high-grade stenosis in combination with saccular aneurysms located in the proximal part of both the left anterior descending (arrow and circumflex (arrowhead) coronary arteries. Note the poor side branch involvement compared with Figure 2.

Fig. 2. Congenital (associated with congenital coronary arteriovenous fistulas) CAAs. **(A)** Left coronary angiogram in RAO projection showing the well-developed side branches (asterisk) of an aneurysm associated with congenital coronary-pulmonary fistula originating from the proximal portion of the left anterior descending coronary artery and terminating in the pulmonary trunk (with permission of the International Journal of Cardiology).<sup>7</sup> **(B)** Left coronary angiogram in RAO projection, demonstrating a large aneurysm (arrow) originating from a fistula from the proximal part of the left anterior descending coronary artery. Multiple side branch involvement is clearly seen.

Table 1: Patient characteristics in CAAs

Case	Age/Gender	ECG	Qp/Qs	Multivessel disease	Presenting symptom	Exercise tolerance test
1	59/M	SR	<1.5	None	ACP	Neg
2	37/M	SR	<1.5	None	ACP	Neg
3	47/M	SR	<1.5	None	ACP	Neg
4	54/M	SR, IMI	<1.5	3	AP	ND
5	62/M	SR, repolarization disturbances lateral leads	<1.5	2	AP	Neg
6	60/F	SR, IPMI	<1.5	2	AP	Pos
7	58/M	SR, IMI, ASMI, negative T wave anterior leads	ND	2	AP	Neg
8	69/M	SR, negative T wave lateral leads	ND	3	UAP	ND
9	53/M	SR, RBBB	ND	3	AP	Inc
10	79/M	AF, LVH, ASMI	ND	2	AP	ND

CAAs = coronary artery aneurysms; SR = sinus rhythm; ACP = atypical chest pain; AP = angina pectoris; UAP = unstable angina pectoris; ND = not done; Neg, Pos, Inc = negative, positive or inconclusive test for myocardial ischemia, respectively; IMI = inferior myocardial infarction; IPMI = infero-posterior myocardial infarction; ASMI = antero-septal myocardial infarction; RBBB = right bundle branch block; AF = atrial fibrillation; LVH = left ventricular hypertrophy.



Table 2: Concomitant conditions and general management in patients with CAAs (follow-up until September 1996)

Case	Concomitant conditions	Management
1	Congenital CAVF	Medically
2	Car accident 1962, CAVF	Medically
3	Congenital CAVF	Medically
4	Congenital CAVF	CABG + ligation of congenital CAVF
5	Congenital CAVF	Medically
6	Congenital CAVF, pulmonary embolism	PTCA of the LAD
7	None	PTCA of the diagonal branch of the LCA
8	Psoriasis, peptic ulcer	CABG
9	Diabetes mellitus, peripheral vascular disease, hypertension, hypercholesterolemia, NSVT	CABG
10	Hypertension, atrial fibrillation, congestive heart failure, gastritis, epistaxis, metabolic encephalopathy, tubular colic adenoma	CABG; died on November 1994 of respiratory insufficiency

CABG = coronary artery bypass grafting; CAVF = coronary arteriovenous fistula; PTCA = percutaneous transluminal coronary angioplasty; LAD = left anterior descending coronary artery; LCA = left coronary artery; NSVT = nonsustained ventricular tachycardia.

Table 3: Coronary arteries involved in the aneurysm formation, electrocardiographic (MI) location, and anticoagulant regimen in patients with CAAs.

Case	Aneurysm-bearing vessel	ECG location of myocardial infarction	Anticoagulant/antiplatelet therapy
1	LAD	None	None
2	LAD	None	None
3	LAD	None	None
4	LAD	IMI	Aspirin
5	RCA	None	Aspirin
6	LAD	IPMI	Acenocoumarol
7	LAD, Cx	ASMI, IMI	Acenocoumarol
8	LAD, Cx	Undetermined	Aspirin
9	RCA	None	Acenocoumarol
10	LAD, Cx	ASMI	Acenocoumarol

IMI = inferior myocardial infarction; IPMI = infero-posterior myocardial infarction; ASMI antero-septal myocardial infarction; LAD = left anterior descending coronary artery; Cx = circumflex coronary artery; RCA = right coronary artery.

## Results

(Table 4): Acquired CAAs were secondary to atherosclerosis, and congenital aneurysms were associated with congenital coronary arteriovenous fistulas. Two of six patients (33%) with congenital CAAs had a MI not located on the same side (contralateral) as the aneurysm whereas three of four patients (75%) with acquired CAAs developed a MI located on the same side (ipsilateral) as the aneurysm. The surgical technique used was coronary bypass grafting alone in three patients (patients 8, 9, 10) and in combination with ligation of a congenital coronary arteriovenous fistula (CAVF)-associated aneurysm in one patient (patient 4). Oral anticoagulant therapy was given to three of these patients (patients 8, 9, 10) and aspirin was prescribed to one (patient 4). The acquired CAAs were either dual or multiple and were a smaller size (mean 2.6 cm) compared with the congenital aneurysms (mean 4.3 cm). Congenital CAAs were solitary. Intraoperative inspection revealed that the surface was irregular in acquired CAAs but had a smooth lining in the congenital variety. The latter demonstrated a multiple side branch involvement. The vessels in the vicinity of the coronary artery aneurysm were considered to be side branches when they had a visible connection to the lumen of the aneurysm. The side branches had a larger calibre in the congenital compared with the acquired CAAs. Saccular type coronary aneurysms were present in both groups. The atherosclerotic (acquired) aneurysms were observed along the entire length of the atherosclerotic vessels, whereas the aneurysms associated with congenital arteriovenous fistulas had a predilection site in the proximal portion of the affected vessels. After an average follow-up of 94.8 months, none of our patients with acquired or congenital CAAs had a rupture into the pericardium or died suddenly after the diagnosis was established. During the long-term follow-up, complications occurred in two patients with acquired CAAs, and recurrent non-Q-wave lateral myocardial infarction occurred in one patient (patient 7), which responded well to medical treatment. Another patient (patient 10) died of recurrent respiratory tract infections.

Table 4: Characteristics of CAAs in 10 patients with atherosclerotic (acquired) and congenital coronary aneurysms

Item	Acquired (atherosclerotic)	Congenital
Location	Proximal, mid and distal vessel	proximal part of vessel
Non-Q-wave MI	2/4	None
Transmural MI	¼	2/6
Associated coronary artery disease	4/4	3/6
Type of CAAs	5x saccular, 2x fusiform	6x saccular
CABG	3x	1x
PTCA of aneurysm-bearing vessel	1x	1x
Mean size (cm) of CAAs	2.6 (range 1.8-3.6)	4.3 (range 2.8-6.0)
Multiplicity of CAAs	Multiple/dual	Solitary/single

CAAs = coronary artery aneurysm; MI = myocardial infarction; CABG = coronary artery bypass grafting; PTCA = percutaneous transluminal coronary angioplasty.

## Discussion

Coronary artery aneurysm is a relatively rare affliction, which may be acquired or congenital. CAAs are known to have various etiologies, atherosclerosis being responsible for over half of

the aneurysms, while 17% are congenital, 11% mycotic, 4% syphilitic, and the cause is unknown in 6%.<sup>3</sup> These data are from the largest autopsy series published thirty years ago, the numbers may be different today. CAAs may be the cause of angina, myocardial infarction or sudden death due to thrombosis, peripheral embolization, or rupture. CAAs however, are usually asymptomatic and compatible with longevity. The angiographic incidence reported in the literature on these abnormalities varies from 0.04 to 4.5%, while based on the autopsy findings, the anatomical incidence is 1.4%.<sup>3,8-10</sup> Although some reports have suggested thrombosis and/or distal vessel embolization may occur, the true risk and incidence of these embolic complications remains unknown.<sup>8</sup> Only two of our patients with acquired CAAs developed non-Q-wave MI. The frequent occurrence of acquired CAAs has been documented in patients with Kawasaki disease.<sup>4,5</sup> CAAs may also occur in patients with Ehlers-Danlos syndrome, Marfan's syndrome, or after chest trauma.<sup>11</sup> It has been reported that CAAs may only rarely be associated with Osler-Weber-Rendu or with quaternary malaria.<sup>12,13</sup> Although it is generally accepted that CAAs are usually asymptomatic, acquired CAAs may be incriminated in the development of ipsilateral non-Q-wave and transmural MI. In the present series, since non-Q-wave MI was ipsilateral and limited to the acquired group, the possibility of embolization to the peripheral coronary bed seems likely. Daoud found a twelve percent incidence of rupture in his series.<sup>3</sup> It has been found that rupture of CAAs associated with acquired atherosclerosis resulting in cardiac tamponade and sudden death occurred more frequently than with congenital aneurysms accompanying congenital arteriovenous fistulas.<sup>6,14,15</sup> However, it is not at all clear if rupture and thrombotic occlusion occur more frequently in certain types of aneurysms.

Surgical treatment of CAAs depends on the severity of symptoms and the size and type of aneurysm.<sup>16</sup> Coronary bypass artery grafting either isolated<sup>17</sup> or in conjunction with aneurysm resection<sup>18</sup> or combined with surgical clipping of the aneurysm may be performed.<sup>19</sup> With the aid of coronary angioscope, surgical plication of an acquired coronary artery aneurysm with distal bypass was successfully carried out by Dralle.<sup>20</sup> Furthermore, it has been reported that transcatheter embolization of CAAs was successfully achieved, using helical fibered platinum coil. With this last therapeutic modality operative risk may be avoided and the hospital stay may be shortened.<sup>21</sup> In the current series, four patients (three with acquired and one with congenital CAAs) underwent CABG using venous and arterial conduits. Ligation of a congenital aneurysm associated with coronary arteriovenous fistula was performed in only one subject. All patients tolerated the surgical procedure well.

In our series, five of seven acquired CAAs were of a saccular type according to the morphological classification reported by Aparici et al.<sup>22</sup> Rittenhouse et al.<sup>23</sup> found that congenital aneurysms associated with coronary arteriovenous fistulas arise more commonly from the right coronary artery than from the left and that dual aneurysms were rare. In the present series, the LAD was the coronary artery frequently involved in the aneurysm formation. The acquired CAAs were associated with ipsilateral MI but the MI associated with the congenital CAAs was not located on the side of the coronary artery involved in the aneurysm formation, i.e., the aneurysm-bearing coronary artery did not participate in the infarction development. We found that dual CAAs were rare in the congenital group. The findings of Rittenhouse et al.<sup>23</sup> were similar. In accordance with the findings of other investigators,<sup>3</sup> We found that the acquired CAAs were frequently multiple. The number of cases in our series is too small to draw the conclusion that acquired CAAs are commonly associated with recurrent (ipsilateral) non-Q-wave MI located on the same side as the aneurysm. Future investigation of a larger number of patients with CAAs is required in order to differentiate between the clinical and angiographic characteristics of acquired and congenital CAAs.

### **Acknowledgements**

We are greatly indebted to L. Eijsman, M.D., Ph.D. for his critical review of the manuscript and Mrs. H.E. Blijdenstein for her secretarial assistance.

## References

1. Morgagni GB. De sedibus et causis morborum per anatomen indigatis libri quinque ventitus. Epistle 27, 1761; Article 28.
2. Munkner T, Peterson O, Vesterdal J. Congenital aneurysm of the coronary artery with an arteriovenous fistula. *Acta Radiol* 1958; 50:333-340.
3. Daoud AS, Pankin D, Tulgan H, Florentin RA. Aneurysms of the coronary artery. *Am J Cardiol* 1963; 11:228-237.
4. Kawasaki T. Mucocutaneous lymph node syndrome: A clinical observation in 50 cases. *Jpn J Allergy* 1967; 16:178.
5. Said SAM, Veerbeek A, Werner HA, Herweyer TJ, Schuilenburg RM. Echocardiographic visualization of coronary aneurysms in the mucocutaneous lymph node syndrome "Kawasaki disease". *Neth J Cardiol* 1991; 3:92-97.
6. Aintablian A, Hamby RI, Hoffman I, Kramer RJ. Coronary ectasia: Incidence and results of coronary bypass surgery. *Am Heart J* 1978; 96:309-315.
7. Said SAM, Landman GHM. Coronary-pulmonary fistula: Long-term follow-up in operated and no-operated patients. *Int J Cardiol* 1990; 27:203-210.
8. Brecker SJ, Gray HH, Oldershaw PJ. Coronary artery aneurysms and myocardial infarction: adult sequelae of Kawasaki disease? *Br Heart J* 1988; 59:509-512.
9. Carroll RJ, Falsetti HL. Coronary artery aneurysm: A re-view of the literature with a report of 11 new cases. *Chest* 1976; 69:630-636.
10. Swaye PS, Fisher LD, Litwin P, Vignola PA, Judkins MP, Kemp HG, Mudd JG, Gosselin AJ. Aneurysmal coronary artery disease. *Circulation* 1983; 67:134-138.
11. Eriksen UH, Aunsholt NA, Nielsen TT. Enormous right coronary arterial aneurysms in a patient with type IV Ehlers-Danlos syndrome. *Int J Cardiol* 1992; 35:259-261.
12. Tsuiki K, Tamada Y, Yasui S. Coronary artery aneurysms without stenosis in association with Osler-Weber-Rendu disease. *Angiology* 1991; 42:55-58.
13. Van der Wall EE, Padmos I, Cats VM. Coronary arterial aneurysm: possible relation with malaria? *Int J Cardiol* 1988; 21:351-353.
14. Habermann JH, Howard ML, Johnson ES. Rupture of the coronary sinus with hemopericardium. A rare complication of coronary arteriovenous fistula. *Circulation* 1963; 28:1143-1144.
15. Libersohn RR, Sagar K, Berkoben JP, Weintraub RM, Levine FH. Congenital coronary arteriovenous fistula. Report of 13 patients, review of the literature and delineation of management. *Circulation* 1979; 59:849-854.
16. Akiba T, Sato T, Yoshikawa M, Otaki S, Kobayashi Y, Nakasato M, Suzuki H, Hayashi T. Prognostic significance of the size of coronary artery aneurysms in Kawasaki disease. *Acta Paediatr Jpn Overseas Ed* 1989; 31:7-11.
17. Cohen AJ, Banks A, Cambier P, Edwards F. Post-atherectomy coronary artery aneurysm. *Ann Thorac Surg* 1992; 54:1216-1218.
18. Ebert PA, Peter RH, Gunnells JC, Sabiston DC. Resecting and grafting of coronary artery aneurysm. *Circulation* 1971; 43:593.
19. John LCH, Hornick P, Davies DW, Banim SO, Rees GM. The role of surgery in the management of solitary coronary artery aneurysm. *Eur J Cardiothorac Surg* 1991; 5:440-441.
20. Dralle JG, Turner C, Hsu J, Replogle RL. Coronary artery aneurysms after angioplasty and atherectomy. *Ann Thorac Surg* 1995; 59:1030-1035.
21. Chen MF, Chien KL, Tsang YM, Liao CS, Lee YT. Transcatheter embolization in treatment of congenital coronary artery aneurysm. *Am Heart J* 1996; 131:396-397.
22. Aparici M, Peteiro J, Fernandez de Almeida CA, Hidalgo R, Alzamora P, Barba J, Alegria E. Coronary ectasia: another form of atherosclerosis. *Med Clin* 1989; 93:368-371.
23. Rittenhouse EA, Doty DB, Ehrenhaft JL. Congenital coronary artery-cardiac chamber fistula. *Ann Thorac Surg* 1975; 20:468-485.



# Chapter 4

## **Feasibility of Cardiovascular Magnetic Resonance of Angiographically Diagnosed Congenital Solitary Coronary Artery Fistulas in Adults**

**S.A.M. Said  
M.B.M. Hofman  
A.M. Beek  
T. van der Werf  
A.C. van Rossum**

Presented in part at the Euro-CMR meeting, May 2005, Zurich

**Published in Journal of Cardiovascular Magnetic Resonance 2007; 9:1-9**

## Abstract

**Objective:** To evaluate the use of cardiovascular magnetic resonance (CMR) to visualize angiographically-detected congenital coronary artery fistulas in adults.

**Methods:** CMR techniques were used to study 13 patients, recruited from the Dutch Registry, with previously angiographically diagnosed fistulas.

**Results:** Coronary fistulas were detected in 10 of 13 (77%) patients by CMR, and retrospectively in two (92%) more. In 93% of these, it was possible to determine the origin and the outflow site of the fistulas. Cardiovascular magnetic resonance allowed demonstration of dilatation of the fistula-related coronary artery in all cases. Tortuosity of fistulas was detected in all visualized patients. Uni- or bilaterality of fistulas as seen on CAG was proven on CMR in all patients.

Flow measurement could be performed in 8 patients. A fairly good correlation ( $r=0.72$ ) was found between angiographic (mean 6.2 mm, range 1-16) and cardiovascular magnetic resonance (mean 6.3 mm, range 3-15) measured fistulous diameters.

**Conclusions:** Cardiovascular magnetic resonance of congenital fistulas with clinical significant shunting is feasible and can provide additional physiological data complementary to the findings of conventional coronary angiography.

**Key words:** cardiovascular magnetic resonance imaging, congenital coronary anomaly, coronary artery fistulas, coronary arteriography.

## Introduction

To date coronary arteriography (CAG) has been considered the “gold standard” for detection and delineation of the fistulous communications. There are several reports in the literature of noninvasive methods having been successfully used in the identification of such fistulas.<sup>1-6</sup> A noninvasive technique such as cardiovascular magnetic resonance (CMR) may therefore become important as it provides excellent 3D imaging and accurate flow quantification.<sup>7</sup> Flow quantification may give information on the amount of ventricular volume loading caused by a fistula which may be relevant to the timing and method of treatment. CMR may, therefore, provide a supplement or substitute for coronary angiography, and the purpose of this report is to assess its value in visualizing angiographically proven congenital coronary artery fistulas (CAFs) in a series of adult patients. Current experience with CMR for the diagnosis of CAFs is limited to case histories.<sup>8-11</sup> CAFs have varied consequences that range in importance from an incidental finding at CAG to important anomalies with hemodynamic significance and requiring intervention. CAFs can result in congestive heart failure due to sizeable left-to-right shunt, thromboembolic events, myocardial ischemia or infarction, infective endocarditis, ventricular and supraventricular arrhythmias or even sudden death secondary to rupture of an associated aneurysm of the fistula.<sup>1,3,5,10,12</sup> For symptomatic patients, surgical or percutaneous permanent occlusion of the fistulas is widely accepted. However, controversies exist in the management of asymptomatic subjects.<sup>5,13,14</sup> We report the findings on CMR of morphological anatomy and flow quantification of 13 adult patients with previously known congenital CAFs. These patients were recruited from a national Dutch Registry, where both angiography and CMR were available.<sup>15</sup>

## Materials and Methods

### Patients

A group of 13 consecutive patients with CAFs, who gave their informed consent and were recruited from the Dutch Registry (DR) where both coronary angiograms and CMR were available, were investigated for the value of CMR in detecting the fistulas.

### Data of the Dutch Registry

The DR of congenital CAFs comprised 71 adults out of 30,829 patients who underwent coronary angiography. The data of the DR on CAFs have been described earlier in detail.<sup>15</sup> In brief, between 1996 and 2003, a registry was started for collecting data of adult patients with CAFs. In the registry clinical data and coronary angiographic findings of 51 patients with congenital solitary CAFs and 20 subjects with coronary artery-left ventricle multiple micro-

fistulas were included.<sup>16</sup>

### **Coronary angiography**

Assessment of the size of the fistulous vessel was based on comparison with the angiography catheter diameter. For the definition of fistulous aneurysm, we adopted the definition of coronary aneurysm, which is angiographically defined as a coronary artery dilatation that exceeds the diameter of the normal adjacent segments or the diameter of the patient's largest coronary vessel by a factor of 1.5.<sup>17</sup> The pathway of the fistula was described by two terms: straight or tortuous and single or multiple. According to the outflow of the fistula, we defined the receiving vessel or cardiac chamber and singularity or multiplicity, respectively.

### **Cardiovascular magnetic resonance**

We performed CMR using a 1.5 Tesla whole-body magnetic resonance scanner (Magnetom Sonata, Siemens, Aerlangen, Germany) using a 4 element phased array radiofrequency receiver coil. First, black blood anatomical imaging was performed using a single shot turbo spin echo technique with half Fourier imaging, triggered to the heart rhythm in diastole (spatial resolution 1.7x1.4x5 mm<sup>3</sup>). During a breath-hold a series of 11 parallel axial or oblique slices were obtained. For more vessel detail, a recently developed coronary CMR technique was applied.<sup>18</sup> This bright blood technique used a fat suppressed 3D steady state free precession pulse sequence (true FISP) applied during a breath-hold (spatial resolution 1.4x1.3x4 mm<sup>3</sup>). A series of these thin slabs (2.4 cm) were placed to visualize the vessel anatomy in greater detail. In order to visualize entry jets of fistulas within other vascular structures cine imaging was applied. A standard true FISP cine sequence was acquired, as well as a breath-hold fast low-angle shot (FLASH) sequence with improved sensitivity to flow dephasing effects.<sup>19</sup> Areas where fistula entry points were detected on initial CMR images were re-imaged using appropriately located parallel cine views. Finally, the volume flow through the fistula was assessed through a plane perpendicular to the vessel. A phase sensitive flow quantification technique was applied within a breath-hold (spatial resolution 1.4x1.2x5.5 mm<sup>3</sup>, temporal resolution 60 ms). Analyses of volume flow data was performed with the FLOW® software package (Medis, Leiden, the Netherlands). Contours were manually drawn around the cross-section of the fistula on anatomic (magnitude) images, and the volume flow was calculated on the corresponding velocity map. By integrating all cardiac phases the net volume flow was determined.

The evaluation of CMR was single blinded. The investigators (ACvR, and AMB) knew that the patients had fistula, but had no access to further details regarding origin, outflow, pathway and fistula-related arteries.

### **Statistical analysis**

All continuous variables are presented as mean  $\pm$  standard deviation and discrete variables are expressed as frequencies and percentage. Linear correlations coefficients were assessed between the diameters calculated by CAG and measured by CMR. Nonparametric Bland-Altman analysis was performed for assessing agreement between two methods.

## **Results**

### **Patients**

Patient baseline characteristics are displayed in Table 1. The mean age of the 13 patients was 57 years (range 30-79 years), of whom 4 were women, and 9 were men.

### **Coronary angiographic examinations**

A total of 14 CAFs were apparent in the 13 patients on angiography: one bilateral and 12 unilateral. The mean diameter of the 14 CAFs was 6.2 mm (range 1-16 mm). The fistulous communications originated from the proximal segment of the left anterior descending artery in 7 cases, left main stem once, right coronary artery (RCA) 4 times and circumflex artery (Cx) twice. The outflow was into the pulmonary artery 6, right atrium 1, right ventricle (RV) 3, left atrium (LA) 1 and superior vena cava (SVC) 3 times.

### **Cardiovascular magnetic resonance**

The evaluation of CMR was single blinded. On the first review, 11 of the 14 fistulas (79%) in 10 of the 13 (77%) patients were detected. On a second review, guided by angiographic information, 2 of the 3 initially undetected fistulas were retrospectively identified. Example of



images obtained by CAG and CMR are shown in Figs. 1 and 2, demonstrating anatomical and physiological details (four consecutive images of Fig. 2, A-D demonstrate the details of the jet flow).

The mean diameter of the fistulous vessels was 6.3 mm (range 3-15 mm), providing good agreement ( $r = 0.72$ ) with the diameter assessed by CAG. As demonstrated on Bland-Altman plots, there was no systematic trend found.<sup>20</sup> Plot diagrams are shown in Fig. 3. Morphologic characteristics are listed in Table 2. Easy access of CAG relative to the limited availability of CMR resulted in delays of between 1 and 112 months between the two investigations, with a median delay of 3 months.

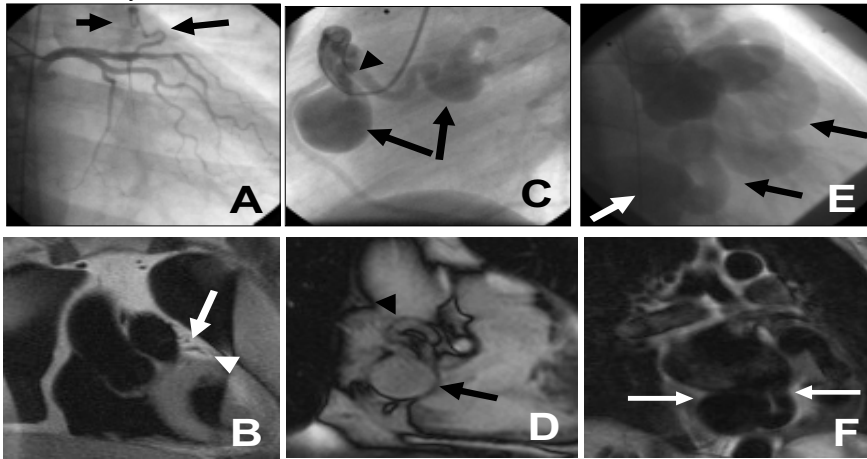


Fig. 1

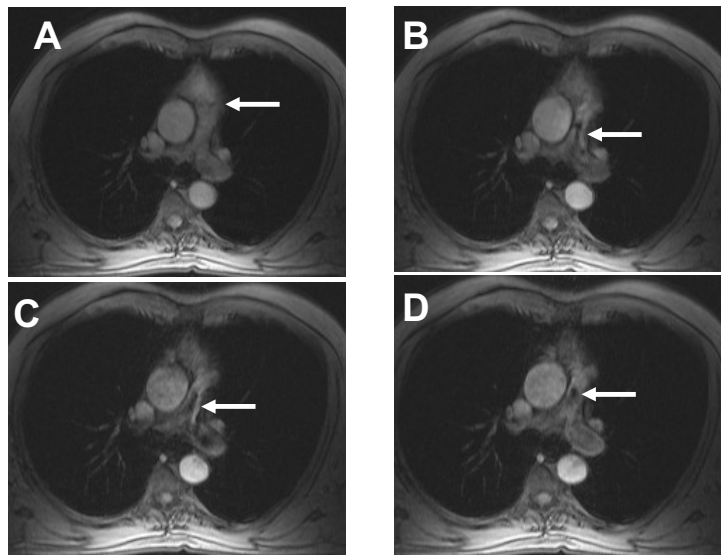


Fig. 2

Legends

Fig. 1 (A-F) Comparison of coronary angiographic and CMR images.

A, (patient 4): The left coronary arteriogram in right-anterior oblique (RAO) projection

demonstrating the fistula (long arrow) originating from the proximal LAD and outflow into the PA (short arrow). B, Trans-axial CMR cross section of the heart (spin echo technique) showing outflow of the LAD-fistula into the anterior side of the pulmonary artery (white arrow). A segment of the LAD is visible (white arrowhead). C, (patient 5): The right coronary arteriogram in left-anterior oblique (LAO) projection demonstrating the fistula (arrowhead) originating from the proximal RCA and its outflow into the SVC. Two aneurysms (arrows) are appreciated. D, CMR of the same patient showing the RCA in LAO equivalent view (coronal image) depicting the dilated fistulous vessel (white arrowhead) with one of the aneurysms (white arrow). The second aneurysm is outside the plane of the image. E, (patient 3): The aortogram in RAO projection demonstrating the fistula (black arrows) originating from the Cx and its outflow into the RA and coronary sinus (CS). Huge dilatation and ectatic fistulous vessel are noticeable. The CS shows aneurysmal dilatation (white arrowhead). F, CMR longitudinal view of the same patient demonstrating the dilated tortuous fistulous vessel (white arrows).

Fig. 2 (A-D): Four consecutive CMR transverse T1-weighted slice images, from patient number 9, taken at 50, 150, 250 and 350 ms during diastole. The images were obtained with TE of 8.2 ms. Slice thickness of 7 mm. The arrows identifying the waxing and waning of a signal free space in the pulmonary artery during this part of the cardiac cycle. This phenomenon, called “flow void”, is caused by the outflow jet from the fistula into the pulmonary artery.

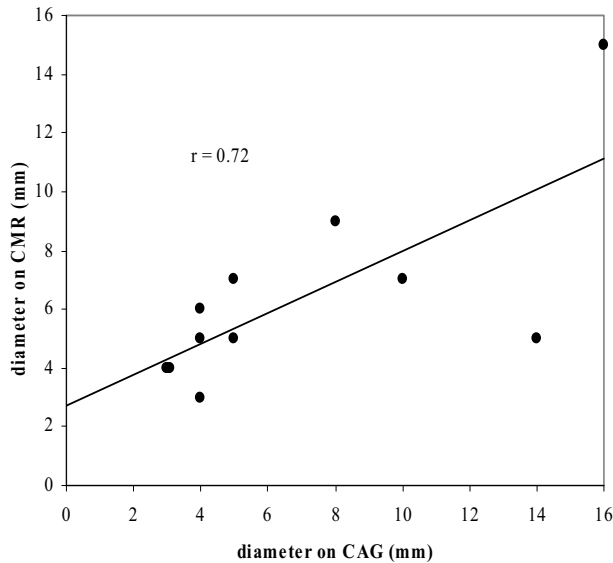


Fig. 3A

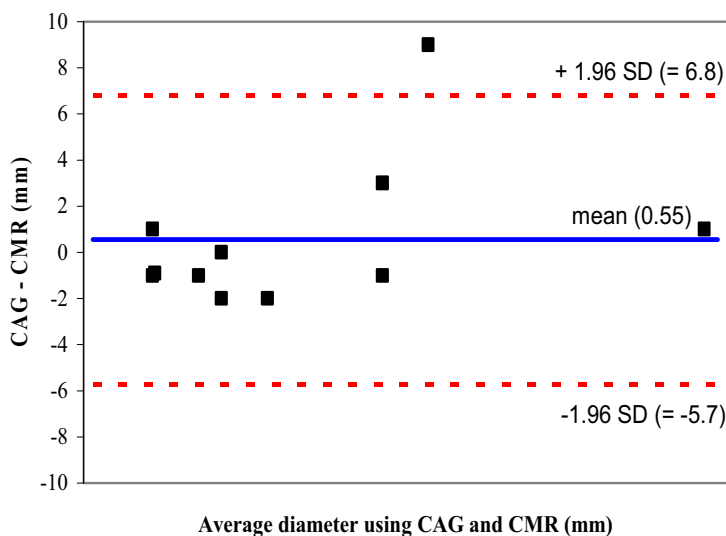


Fig. 3B

Fig. 3: A, Scatter plot of the relationship between the angiographically assessed and CMR measured diameter of the fistulous vessels and B, Bland-Altman scatter diagram of the differences plotted against the averages of the two methods within a mean of  $\pm 1.96$  SD. The differences are not clinically important.

#### Anatomical details (Table 2)

##### Origin

The origins of all 13 fistulas were identified in corresponding regions by CAG and CMR.

##### Outflow

In all fistulas, the outflow could be visualized by CMR and confirmed in cine images by signal loss at the site of the outflow jet. In one case (patient 11, of which outflow was to the SVC) the outflow was assessed by CMR as single, while the CAG showed multiple outlets. The 3 other fistulas draining to the SVC, were diagnosed correctly.

##### Pathway

In 3 fistulas, there were differences between the CAG and the CMR findings. In patient 5, the pathway was assessed on CMR to be multiple while on the CAG it proved to be single; this may be due to tortuosity of the fistulous vessel. In patient 10, the opposite was the case: on CMR, the pathway was diagnosed as single, while on the CAG it was seen to be multiple. In patient 12 (first fistula, RCA→RV), CMR could not provide a description of the pathway of one of the bilateral fistulas. It is striking that in all three of these disparities, the fistulas originating from the RCA.

##### Aneurysms

In 4 patients, 4 fistulas showed aneurysmal manifestation on CAG, (patients 3, 4, 5 and 7). Three out of four aneurysms (1 fusiform and 2 saccular) were detected by CMR (Table 1). The missed aneurysm by CMR was of small diameter (6x9 mm) (patient 4).

#### Failure of CMR in detecting CAFs (Table 3)

In the initial review, 3 fistulas were not detected. The angiographic diameters of these were 3, 1 and 10 mm, respectively. The fistulas originated from the proximal segment of the LAD in 2 patients (1 and 8) and from the RCA in one of the patients (patient 13). On the second CMR revision, 2 of the 3 fistulas were detected when guided by the angiographic road-map. The diameter of the undetected CAF was 1 mm, its course was straight, and no shunt was

detected by CMR.

Failure of CMR to detect CAFs can be attributed to the small diameter of the fistulous vessel or inadvertent misidentification of the fistulous vessel as a normal branch, because of localisation of the fistula adjacent to the pericardium.

### **Physiology**

Flow quantification could be performed in 8 out of 13 CAF patients. The average flow velocity measured in the fistulous vessel was 10 cm/s (range from 1.2 to 36). The mean flow quantification through the fistulas was 0.55 l/min (range 0.02-3.8). Individual results of all 13 patients are given in Table 4. In 5 other fistulas the flow measurements could not be analysed due to poor image quality caused by improper breath-holding.

Diastolic flow exceeded systolic flow in most cases. In mid-systole there was a dip followed by an increase towards the end of systole. In diastole flow generally increased gradually until end-diastole; in patients 3 and 10, there is a discrete mid-diastolic peak. In the 3 patients (patients 3, 11 and 12) with the largest fistulas associated with the highest flow through the fistula, surgical ligation in combination with coronary artery bypass grafting was performed.

Among the Dutch Registry patient's evaluated, there was no uniform oxymetrically calculated left-to-right shunt volumes available because it was based on retrospective registry data and a prospective protocol was lacking.

### **Discussion**

The present study is one of the first to investigate the feasibility of CMR for the detection of congenital coronary artery fistulas in adult patients. It demonstrated that CMR could initially identify fistulas in 79% of the cases. A second review under angiographic imaging guidance identified 92% of the angiographically established fistulas.

Until now CAG has been considered the standard for visualization of CAFs, but the relation of CAFs to other structures, their origin, and course may not always be apparent by this method. CMR may be of value for complementary imaging with diagnostic anatomical and physiological work-up, and eventually for follow-up.<sup>1</sup>

Previously published papers<sup>1-6</sup> concerning CMR and CAFs were mainly based on case reports,<sup>1-6</sup> which included individuals who were, on average, younger, more often symptomatic, and with considerably more comorbidity requiring surgical or non-surgical interventional procedures<sup>21</sup> than found in our current series. Several authors recommend the use of CMR as a diagnostic tool for pre-interventional work-up of CAFs.<sup>4,8,9,22</sup>

Our study shows that CMR is capable of detection of 92% of the fistulas. Smaller fistulas and small aneurysms were missed by CMR, but these are without clinical consequence. In some patients, measurement of the shunt flow may give pivotal information which may influence the clinical decision making. The findings of high flow through the shunt in patients 3, 11 and 12 did not alter but enforce the clinical management.

Failure to identify this fistula by CMR is likely due to the lack of spatial resolution, compared to angiography, though a learning curve effect cannot be excluded. Detailed characteristics of the missed fistulas are shown in Table 3.

CMR was capable of identifying tortuosity in 79%, multiplicity of pathways in 57% and multiplicity of the origin in 93% (Table 5). Furthermore, CMR determined the distance of origin of the CAFs with regard to the left main stem and outflow into the cardiac structures, diameter of the fistula-related artery, diameter of the fistulous vessel and assessment of dimension of the cardiac chambers (Table 2).

Current MR sequences have improved image quality with superior anatomical definition, pointing to CMR as an alternative diagnostic tool for evaluating anatomy, physiology and function.<sup>4,10-12</sup> Recent advances in fast CMR have facilitated its clinical use for imaging blood flow through the coronary arteries<sup>23</sup> and could enhance the detection rate of CAFs as breath holding was a major determining factor in the fistulous flow assessment by CMR. Another advantage of CMR is its noninvasiveness.

The ability of conventional CMR to detect CAFs may, however, be limited when the shunt is small and the donor artery is not dilated.<sup>9</sup> This is particularly true when fistulas drain into the

right side of the heart such as right ventricle (2x) or pulmonary artery (1x), as was the case in the three unidentified fistulas in this study.

Few discrepancies were found between the CAG and CMR assessed fistula morphological description (Tables 2 and 4). These discrepancies can be explained by the lack of accuracy in CAG assessed diameters of the fistulous vessels. Secondly, a discrepancy might be due to the differences in CMR sequence methods.

CMR visualization of coronary fistulas is not easy, and a final analysis of images is time consuming, making the technique unsuitable for initial screening. It may, however, be of great value for complementary imaging and diagnostic work-up as the shunt measurement is reliably performed by CMR.

### **Suggested criteria for fistula detection by CMR**

On the basis of previous findings<sup>8,10-12</sup> and our own experience, some criteria for identification of the fistula may be suggested when clinical suspicion is raised.

### **Anatomical assessment**

Assessment of unilateral as well as multilateral fistulous vessels originating from one or more coronary arteries, entering into the outflow site, identification of the fistulous jet within the entry site, and demonstration of the presence or absence of a dilated donor artery. Dilatation of the fistula-related artery is thought to be present when a disproportionate relation is found between the size of the coronary artery and the amount of myocardial territory it supplies.

### **Physiological assessment**

Signal loss (flow void) which is detected when an inflowing jet of turbulent flow in 2 perpendicular planes (e.g. transversal and sagittal) is seen waxing and waning into the recipient cardiac chambers or great thoracic vessels.

Patients suitable for CMR application are those with symptomatic congenital CAFs originating from the right, left or both coronary arteries and terminating into the right half of the heart.

### **Conclusion**

CMR is a noninvasive method that may provide additional anatomic information and shunt flow measurement as compared to conventional CAG in CAFs, provided that the diameter of the fistulous vessel is large enough. Further improvement of CMR techniques and future study of a larger number of cases are needed for more precise assessment.

CMR is useful not only for identification of CAFs but also for delineating their sites of origin and drainage. Furthermore, CMR may provide, in some CAFs patients, additional physiological data and definitive confirmation of CAFs. With its current performance, however, it is not the diagnostic modality of first choice when this anomaly is suspected and a prospective study with high resolution 3D CMR imaging is warranted.

### **Study limitations**

The present study included a small sample of patients. In spite of this limited number of patients, a good correlation was found between the CMR measured and CAG assessed diameter of the fistulous vessels.

In this single-blind retrospective study, we investigated the capability of CMR to detect the angiographically proven CAFs. The small sample size and the design of the study did not permit the calculation of the sensitivity and specificity of CMR for a given size CAFs. Only in patients where CAG and CMR were available, a comparison could be made. It comprised a small number of survey-based subjects. In view of the limited number of patients studied for flow measurement by CMR, the comparison was limited between the two methods.

Future prospective studies in large number of patients with continuous murmur are required to determine the clinical value of CMR in patients with CAFs.

### **Acknowledgements**

The authors appreciate the assistance of Dutch Cardiac Centres (appendix 1) and of Mrs.

M.A. Belderok and Mr. M. Mintjens during the preparation of the manuscript.

## References

1. Wertheimer JH, Toto A, Goldman A, DeGroat T, Scanlon M, Nakhjavan FK, Kotler MN, with the technical assistance of Parry, W.R.: Magnetic resonance imaging and two-dimensional and Doppler echocardiography in the diagnosis of coronary cameral fistula. *Am Heart J* 1987; 114:159-162.
2. Velvis H, Schmidt KG, Silverman NH, Turley K: Diagnosis of coronary artery fistula by two-dimensional echocardiography, pulsed Doppler ultrasound and color flow imaging. *J Am Coll Cardiol* 1989; 14:968-976.
3. Said S. Doppler echocardiographic findings in coronary-pulmonary fistula: *Int J Cardiol* 1989; 25:343-346.
4. Kubota S, Suzuki T, Murata K: Cine magnetic resonance imaging for diagnosis of right coronary-arterial ventricular fistula. *Chest* 1991; 100:735-737.
5. Said SAM, Vriesendorp WJS, van der Werf T: Een man met febris intermittens, algehele malaise en diastolisch hartgeruis (in Dutch). *Hartbulletin* 1998; 29:206-209.
6. Umaña E, Massey CV, Painter JA: Myocardial ischemia secondary to a large coronary-pulmonary fistula. A case report. *Angiology* 2002; 53:353-357.
7. Szolar DH, Sakuma H, Higgins CB. Cardiovascular application of magnetic resonance flow and velocity measurements. *J Magn Reson Imaging* 1996; 6:78-89.
8. Vandenbossche JL, Felice H, Grivegnee A, Englert M: Noninvasive imaging of left coronary arteriovenous fistula. *Chest* 1988; 93:885-887.
9. Sato Y, Ishikawa K, Sakurai I, Hashimoto M, Ebuchi T, Yoda S, Matsumoto N, Koyama S, Katsumata N, Sugino K, Sakamaki T, Kanmatsuse K: Magnetic resonance imaging in diagnosis of right coronary arteriovenous fistula: a case report. *Jpn Circ J* 1997; 61:1043-1046.
10. Duerinckx AJ, Shaaban A, Lewis A, Perloff J, Laks H: 3D MR imaging of coronary arteriovenous fistulas. *Eur Radiol* 2000; 10:1459-1463.
11. Heyne J, Leder U, Pohl P, Kaiser WA: Imaging of a coronary vessel anomaly with aneurysm and arteriovenous fistula by means of MR bolustracking technique. *Radiologe* 2001; 41:506-510.
12. Parga JR, Ikari NM, Bustamante LNP, Rochitte CE, De Ávila LFR, Oliveira SA. MRI evaluation of congenital coronary artery fistulae. *Brit J Radio* 2004; 77:508-511.
13. Levin DC, Fellows KE, Abrams HL. Hemodynamically significant primary anomalies of the coronary arteries: angiographic aspects. *Circ* 1978; 58:25-34.
14. Schumacher G, Roithmaier A, Lorenz HP, Meisner H, Sauer U, Müller KD, Sebening F, Bühlmeier K. Congenital coronary artery fistula in infancy and childhood: diagnostic and therapeutic aspects. *Thorac Cardiovasc Surg* 1997; 45:287-294.
15. Said SAM, van der Werf T. Dutch survey of coronary artery fistulas in adults: Congenital solitary fistulas. *Int J Cardiol* 2006; 106:323-332.
16. Said SAM, van der Werf T. Dutch survey of coronary artery fistulas in adults: Congenital coronary artery-left ventricular multiple micro-fistulas. *Int J Cardiol* 2006; 110:33-39.
17. Aintablian A, Hamby RI, Hoffman I, Kramer RJ. Coronary ectasia: Incidence and results of coronary bypass surgery. *Am Heart J* 1978; 96:309-315.
18. Deshpande VS, Shea SM, Chung YC, McCarthy RM, Finn JP, Li D: Breath-hold three-dimensional true-FISP imaging of coronary arteries using asymmetric sampling. *J Magn Reson Imaging* 2002; 15:473-478.
19. Keegan J, Gatehouse PD, John AS, Mohiaddin RH, Firmin DN: Breath-hold signal loss sequence for the qualitative assessment of blood flow disturbances in cardiovascular MR. *Proc Intl Soc Mag Reson Med* 2002; 10:1721.
20. Bland JM, Altman DG. Statistical methods for assessing agreement between two methods of clinical measurement. *Lancet* 1986; 1:307-310.

21. Hsieh KS, Huang TC, Lee CL: Coronary artery fistulas in neonates, infants, and children: clinical findings and outcome. *Pediatr Cardiol* 2002; 23:415-419.
22. Taoka Y, Nomura M, Harada M, Mitani T, Endo J, Kondo Y, Yukinaka M, Ito S, Nakaya Y, Nishitani H: Coronary-pulmonary artery depicted by multiplanar reconstruction using magnetic resonance imaging. *Jpn Circ J* 1998; 62:455-457.
23. Post JC, van Rossum AC, Hofman MB, Valk J, Visser CA: Protocol for two-dimensional magnetic resonance coronary angiography studied in three-dimensional magnetic resonance data sets. *Am Heart J* 1995; 130:167-173.

## **Appendix 1**

Participating Dutch centres, in alphabetical order:

W.G. de Voogt, MD, R.G.E.J. Groutars, MD, B. Ilmer, MD, A.R. Willems, MD, J. Visser, MD, St Lucas-Andreas Hospital Amsterdam; W.A.A.J. van Ekelén, MD, P.E. Polak, MD, St Anna Hospital Geldrop; J.A.J. de Boo, MD, A.H. Liem, MD, H.W.O. Roeters van Lennep, MD, Oosterschelde Hospital Goes; B. van Vlies, MD, A.J. Funke Küpper, MD, Kennemer Gasthuis Haarlem; A. Derks, MD, H.T. Droste, MD, J.H. Fast, MD, Hospital group Twente, Location Hengelo; D.G. de Waal, MD, Waterland Hospital Purmerend; D.E.P. de Waard, MD, Antonius Hospital Sneek; C.L.J.M. van Engelen, MD, Zaans Medical Centre De Heel Zaandam; W.J. Louridtz, MD, H.A. Oude Luttikhuis, MD, Isala clinics, location Sophia, Zwolle.

Table 1: Patient's characteristics and fistula detection

Case	Age and gender	Presenting symptoms	Management	Aneurysmal manifestation and detection		Fistula detection		
				Diameter (mm)		CAG	CMR Initial review	Second revision
1	52 M	ACP	CMM			pLAD→PA	No fistula detection	pLAD→PA
2	56 M	AP	CMM			pLAD→PA	pLAD→PA	
3	67 M	Arrhythmia	SL CABG MVP	57x57 saccular	45	Cx→CS-RA	Cx→CS-RA	
4	45 M	AP	CMM	6x9 fusiform	Missed	pLAD→PA	pLAD→PA	
5	60 F	AP, dyspnea and presyncope	CMM	28x33 saccular	25x24	RCA→SVC	RCA→SVC	
6	43 M	AP and palpitation	CMM			pLAD→PA	pLAD→PA	
7	56 F	ACP and palpitation	CMM	5x6 saccular	4x6	pLAD→PA	pLAD→PA	
8	30 F	Fatigue and dyspnea	CMM			pLAD→RV	No fistula detection	No fistula detection
9	71 M	ACP	CMM			pLAD→PA	pLAD→PA	
10	60 M	Arrhythmia	CMM			RCA→SVC	RCA→SVC	
11	79 M	AP	SL CABG			LMCA→SVC	LMCA→SVC	
12	66 M	AP	AVR CABG			RCA→RV	RCA→RV	
			CMM			CX→LA	CX→LA	
13	57 F	AP	CMM			RCA→RV	No fistula detection	RCA→RV

Abbreviations: CAG=coronary angiography, CMR=cardiovascular magnetic resonance, ACP=atypical chest pain, CMM=conservative medical management, pLAD=proximal left anterior descending coronary artery, PA=pulmonary artery, AP=angina pectoris, SL=surgical ligation, CABG=coronary artery bypass grafting, MVP=mitral valve plasty, Cx=circumflex coronary artery, CS=coronary sinus, RA=right atrium, RCA=right coronary artery, SVC=superior vena cava, RV=right ventricle, LMCA=left main coronary artery, AVR=aortic valve replacement, LA=left atrium.



Table 2: Anatomy of CAFs: Comparison between CAG and CMR findings

CAG and diameter of fistulous vessel in (mm)				CMR and diameter of fistulous vessel in (mm)				
Origin	Outflow	PW	Characteristics	Origin	Outflow	PW	Characteristics	
1	pLAD Multiple	PA Single	Tortuous Multiple	Unilateral (3)	pLAD Single	PA At left anterior side Single	Tortuous Single	Overlooked on 1 <sup>st</sup> occasion Revision: Technique of detection * 3-D FISP * Negative contrast sign with turbulent effect Unilateral (NA)
2	pLAD Single	PA Single	Tortuous Single	Unilateral (4)	pLAD Single	PA 1.5 cm above PV at left anterior side Single	Tortuous Single	Unilateral (5)
3	Cx Single	CS-RA Single	Tortuous Single	Unilateral (16) Aneurysm CAF Dilatation FRA	Cx Single	CS-RA Single	Tortuous Single	Unilateral (15) Dilatation of RA, LA, FRA and CS Aneurysm CAF
4	pLAD Single	PA Single	Tortuous Single	Unilateral (5) Aneurysm CAF	pLAD Single	PA 1.2 cm above PV at anterior side Single	Tortuous Single	Unilateral (5) No aneurysm detected
5	RCA Single	SVC Single	Tortuous Single	Unilateral (14) Aneurysm CAF Dilatation FRA	RCA Single	SVC Single	Tortuous Multiple	Unilateral (5) Aneurysm CAF Dilatation FRA
6	pLAD Single	PA Single	Tortuous Single	Unilateral (5)	pLAD Single	PA 1.7 cm above PV Single	Tortuous Single	Unilateral (7)

7	pLAD Single	PA Single	Tortuous Single	Unilateral (4) Aneurysm CAF	pLAD Single	PA Just above PV at left anterior lateral side Single	Tortuous Single	Unilateral (3) No aneurysm detected
8	pLAD Single	RV Single	Straight Single	Unilateral (1)	-	-	-	No fistula detection
9	pLAD Single	PA Single	Tortuous Single	Unilateral (3)	pLAD Single	PA 2.5 cm above PV Single	Tortuous Single	Unilateral (4)
10	RCA Single	SVC Multiple	Tortuous Multiple	Unilateral (4)	RCA Single	SVC Single	Tortuous Single	Unilateral (6)
11	LMCA Single	SVC Multiple	Tortuous Multiple	Unilateral (8)	LMCA Single	SVC 2 cm cranial to RAA Single	Tortuous Multiple	Unilateral (9)
12	RCA Single Cx Multiple	RV Single LA Multiple	Tortuous Single Tortuous Multiple	Bilateral (3)(7)	RCA Single Cx Multiple	RV Single LA Multiple	Not visible Not visible Tortuous Multiple	Bilateral (4) (NA) Dilatation of LA, LAA and LV
13	RCA Single	RV Single	Tortuous Single	Unilateral (10) Dilatation FRA	RCA Single	Junction area IVC and RA and distal CS Single	Unknown	Missed on 1 <sup>st</sup> occasion Revision: Technique of detection * Unknown Unilateral (7) Dilatation of CS and FRA

Abbreviations: CAG=coronary angiography, CMR=cardiovascular magnetic resonance, PW=pathway, pLAD=proximal left anterior descending coronary artery, PA=pulmonary artery, FISP=fast imaging with steady-state precession, PV=pulmonary valve, Cx=circumflex coronary artery, CS=coronary sinus, RA=right atrium, CAF= coronary artery fistula, FRA=fistula-related artery, LA=left atrium, RCA=right coronary artery, SVC=superior vena cava, RV=right ventricle, LMCA=left main coronary artery, RAA=right atrial appendage, LAA=left atrial appendage, LV=left ventricle, IVC=inferior vena cava, NA=not available.

Table 3: Morphologic characteristics of missed CAFs by CMR

Patient	Fistula diameter	Origin	Outflow	Fistula characteristics	Sequence of detection
1	3 mm	LAD	PA	Origin: multiple, Outflow: single, PW: multiple/tortuous	Detected on second review
8	1 mm	LAD	RV	Origin: single, Outflow: single, PW: single/straight	Missed on both occasions
13	10 mm	RCA	RV	Origin: single, Outflow: single, PW: single/tortuous	Detected on second review

Abbreviations: CMR=cardiovascular magnetic resonance, LAD=left anterior descending coronary artery, PA=pulmonary artery, RCA=right coronary artery, RV=right ventricle, PW=pathway.

Table 4: Characteristics, diameters and flow data of the fistulous vessels

Case	Diameter (mm)		Flow data	
	CAG	CMR	Velocity (cm/sec)	Volume (ml/min)
1	3	-	-	-
2	4	5	2.9	30
3	16	15	36	3835
4	5	5	9.4	85
5	14	5	-	-
6	5	7	2.4 – 3.6	-
7	4	3	-	-
8	1	-	-	-
9	3	4	2.4	20
10	4	6	1.2	15
11	8	9	14.4	550
12	3	4	18	130
	7	-	-	-
13	10	7	-	-

Table 5: CMR results of the different components of the fistula

	Number of fistulas (%)
Detection	
First review result	11/14 (79%)
Second review result	13/14 (93%)
Origin	
Donating vessel	13/14 (93%)
Single/multiple	13/14 (93%)
Pathway	
Straight/tortuous	11/14 (79%)
Single/multiple	8/14 (57%)
Outflow	
Site	12/14 (86%)
Single/multiple	11/14 (79%)
Aneurysms	¾ (75%)



# Chapter 5

**A-** Arguments for a registry

**B-** Case report forms for acquisition of patient's data

**C-** Angiographically diagnosed congenital coronary artery fistulas in an adult population.

S.A.M. Said, L. Relik-van Wely, T. van der Werf. *Cardiologie* 1998; 5:71-73

**D-** Participating clinical Dutch cardiology centres



# 5A

## Arguments for a registry

Because of the relative rarity of CAFs and the absence of a co-ordinated registry for patients with these disorders, only few prospective information is available on their true incidence, natural history or optimal management.<sup>1</sup> We have published a small number of case reports previously in national and international periodicals<sup>2-14</sup> illustrating the infrequent detection of CAFs and the diversity of their clinical presentation.

The above mentioned prior work of published case reports created the idea and encouraged us for collection of patient's data in a Dutch Registry within the limits and regulations of the Dutch Privacy Law. It is hypothesised that such a registry would increase the awareness and knowledge about this entity. The Dutch Registry could form the cornerstone for future studies and for the development of few Dutch Fistula Units to increase the experience of the surgical and interventional teams. In cardiology practice, the care and follow-up of adult individuals with congenital CAFs will be optimized by concentrating efforts.

We used the following definitions for collection of clinical and angiographic patients' data.

**Solitary CAFs:** Defined as an abnormal direct communication between a coronary artery and a cardiac cavity or any part of the pulmonary or systemic circulation where there is an increase in the diameter of the vessel or cardiac chamber receiving the fistulous communication associated with volume overload. The origin, termination and pathway may be identified. The fistulas may have congenital or acquired etiology.

**Coronary-ventricular multiple micro-fistulas:** Anomalies described as an abnormal communication between coronary arteries and a cardiac chamber characterized by multiple channels of small caliber opacifying the ventricular cavities, mostly left ventricle. The origin, termination and pathway may be visualized. The fistulas are mainly congenital in origin, and are also known as generalized myocardial micro-fistulas.

**Pseudo-fistulas:** Recognized by rapid passage of dye from an artery to the corresponding draining venous area, after inadvertent superselective injection into a side branch or the main coronary artery itself, subsequent to forceful injection of a large amount of contrast, causing pressure damping and/or arrhythmias, without the recognition of origin, termination and pathway of an abnormal fistulous communication. Patients with such anomalies were recognized and excluded from the study.

Data were collected according to previously developed case report forms (**Chapter 5B**). Patient demographic data, clinical presentation, non-invasive and invasive techniques and treatment options were retrospectively collected and analyzed.

Patients' characteristics recorded included name, date of birth, age, gender, unique hospital registration number and date of inclusion into the registry. Date and mode of detection (TTE or CAG) of the fistula and serial number of the used CAG medium (film, CD, super VHS) were registered. Other information recorded included physical examination, etiology (congenital or acquired secondary to penetrating or non-penetrating chest injury), previous history (myocardial infarction and specific attention to valve or coronary artery bypass surgery "CABG" and percutaneous transluminal coronary angioplasty "PTCA"), association of other congenital heart defects, co-morbidities and concurrent acquired conditions. Furthermore, non-invasive diagnostic methods (ECG, chest X-ray, ETT, TTE, MIBI scintigraphy) were reported. The angiograms were independently reviewed and re-analyzed for further details of the fistula description and morphologic aspects (singularity, multiplicity,



and tortuosity of origin/outflow/pathway, diameter of FRA and aneurysmal formation). Aneurysm was defined as a coronary artery dilatation that exceeds the diameter of the normal adjacent segments or the diameter of the patient's largest coronary vessel by a factor of one and half. The extent of coronary artery disease was assessed. A vessel with severe diameter reduction was considered significantly diseased. If a right heart catheterization with shunt assessment was performed. Treatment modalities (conservative medical management "CMM" and drugs used, percutaneous transluminal "therapeutic" embolization "PTE", surgical ligation "SL") were reported.

The urging need and emphasis for a Dutch Registry was supported and outlined in a recent editorial in the Netherlands Heart Journal.<sup>15</sup>

## References

1. Baim DS, Kline H, Silverman JF. Bilateral coronary artery-pulmonary artery fistulas. Report of five cases and review of the literature. *Circulation* 1982; 65:810-815.
2. Said S. Doppler echocardiographic findings in coronary-pulmonary fistula. *Int J Cardiol* 1989; 25:343-346.
3. Said SAM, Relik Th. An unusual cause of non-sustained ventricular tachycardia in an athlete. *Netherl J Cardiol* 1990; 3:143-7.
4. Said SAM, Landman GHM. Coronary-pulmonary fistula: Long-term follow-up in operated and non-operated patients. *Int J Cardiol* 1990; 27:203-10.
5. Said SAM, Werner HA, Veerbeek A. Coronary-cameral fistula in association with intracardiac tumour and aortic stenosis in an adult. *Int J Cardiol* 1991; 33:159-62.
6. Said SAM, Bucx JJJ. Coronary angiographic observations; coronary atherosclerosis and myocardial infarction in coronary-pulmonary fistula. *Netherl J Cardiol* 1991; 4:237-41.
7. Said SAM, Bucx JJJ, Brune DF, Austermann-Kaper T. Coronaire arterioveneuze fistel: een "hartedief" van jong en oud. *Nederlands Tijdschrift voor Cardiologie* (in Dutch) 1992; 6:3-9.
8. Said SAM, Bucx JJJ, van de Weel FA. Stress MIBI scintigraphy in multiple coronary-pulmonary fistula: failure to demonstrate the 'steal' phenomenon. *Int J Cardiol* 1992; 35:270-272.
9. Said SAM, Bucx JJJ, van de Weel FA. Coronary-cameral fistula in association with Klinefelter syndrome: exercise-induced ventricular tachycardia late after surgical ligation. *Int J Cardiol* 1992; 36:111-114.
10. Said SAM, Austermann-Kaper T, Bucx JJJ. Congenital coronary arteriovenous fistula associated with atrioventricular valvular regurgitation in an octogenarian. *Int J Cardiol* 1993; 38:96-97.
11. Said SAM, Vriesendorp WJS, van der Werf T. Een man met febris intermittens, algehele malaise en diastolisch hartgeruis (in Dutch). *Hart Bulletin* 1998; 29:206-209.
12. Said SAM, Crijns HJGM, van der Werf T. Prerequisite conditions for identification of true coronary artery fistula. *Cardiologie* 2000; 7:379-383.
13. Said SAM, Hensens AG. Coronary-Cameral Fistula Associated with Acquired Mitral Stenosis and Left Atrial Thrombus in a Female Adult Patient. *Neth Heart J* 2006; 14:39-392.
14. Said SAM, de Voogt WG, Soliman Hamad M, Schonberger J. Surgical treatment of bilateral aneurysmal coronary-pulmonary artery fistulas associated with severe atherosclerosis. *Ann Thorac Surg* 2007; 83:291-293
15. Mulder BJM. Congenital coronary artery fistulas in adults; need for a registry? *Neth Heart J* 2006; 14:3

# 5B

## Case report forms for acquisition of patient's data

The previously developed case report forms for acquisition of patient's data are extensively explained. The definitions for the different items are described. The five pages of case report forms are divided into 16 separate windows. From 1 to 16, each contains the following; patient registration, clinical presentation, physical examination, ECG, exercise tolerance test, myocard scintigraphy, etiology, chest X-ray, echocardiography, cardiac catheterization and fistula characteristics, extent of vessel disease, ventriculogram, findings of right heart catheterization and oxymetry, concurrent conditions, previous history and management.

**National registration form:  
Coronary Artery Fistula in adult population in the Netherlands**

**Patient registration**      Date \_\_\_\_\_  
Name \_\_\_\_\_ Hospital \_\_\_\_\_  
Gender \_\_\_\_\_ Hospital\_Unique \_\_\_\_\_  
Date of birth \_\_\_\_\_

**Symptoms / clinical presentation**  
Asymptomatic   
Symptomatic   
AP  CHF   
ACP  Extraductile   
Palpitation  Arrhythmia   
Fatigue  MI   
Syncope  Others \_\_\_\_\_  
Dyspnea

**Physical examination**  
Length \_\_\_\_\_ cm      Murmur  SM   
Weight \_\_\_\_\_ kg      CM   
RR \_\_\_\_\_ mm Hg      CM   
HR \_\_\_\_\_ bpm  
CVP Normal   
Elevated   
Other \_\_\_\_\_

**ECG**  
Normal  1c AVB  LBBB   
SB  2c AVB  RBBB   
AF  TAVB   
Reperfusion disturbances

**Exercise tolerance test**  
Not done   
Negative  Positive  Anterior   
Inferior   
Antero-lateral   
Posterior   
Others \_\_\_\_\_

**Myocard scintigraphy**  
Not done   
Negative  Positive  AL   
AJB   
Apical   
Inferior   
Postero-B   
Postero-L   
Septal   
Others \_\_\_\_\_

**Etiology**  
Congenital  Acquired  Trauma   
PTCA   
MI   
Surgical  Cardiac   
Coronary   
Atherosclerosis   
Endomyocardial biopsy   
Pacemaker   
Other \_\_\_\_\_

**Comments**  
\_\_\_\_\_  
\_\_\_\_\_  
\_\_\_\_\_

S.A.M. Geel      page 1 / 5      S.A.M. Geel      page 2 / 5

**Chest X ray**

Not done

Cardiomegaly  CTR  %

Pulmonary Vascular Congestion

Other

---

**Echocardiography**      Probe detection       Date of probe detection

TTE       Valvular abnormalities

TDE       AG

LVEDD       ME

LVEDV       AI

LVA       MR

EF  %      TI

FS  %      PI

---

**Coronary Catheterization/Fluoro**      Fluoroscope

**Pulvis trigone**      **Pulvis termination**

RCA       RA

LCA  LMCA       RV

LAD       LA

D       SA

S       LV

Cx       VCS

Others       Others

---

**Complications**

Arrhythmias       Rupture       Ectasia

---

**Fluoro characteristics**

Simple       Single

Compound       Dual / Bilateral

Tortuous / Sigmoid       Multiple

Straight       Sigmoid

S.A.M. Said      page 3 / 5

**Multivessel disease**

No VD

1 VD  RCA

Multi VD  LDA  LAD

Cx

---

**Vein/valves**

Nonobstructive       Site      AL

Hypokinetic       AB

Akinetic       Apical

Dyskinetic       Inferior

LVEDP  mm Hg      Postero-basal

EP  %      Postero-lateral

MR       Septal

---

**Right heart catheterization**

RV  mm Hg      RA  %

RA  mm Hg      RV  %

PA  mm Hg      PA  %

CO  L/min      VCI  %

Mean Wedge pressure  mm Hg      VCI  %

CI  L/min.m<sup>2</sup>      AO  %

SWR  Dyna.sec.cm<sup>5</sup>      Qp:Qa

PAW  Dyna.sec.cm<sup>5</sup>

---

**Concurrent conditions**

PDA       Aortic atresia

VSD       Pulmonary atresia

ASD       Others

AS

PS

S.A.M. Said      page 4 / 5

**Previous history**

MI in history

Year MI       Location      Anterior       Lateral

Year MI       Inferior       Septal

Year MI       Posterior

Others

Hypertension

Cancer       Date operation       Kind of surgery

Trauma       Date trauma       Kind of trauma

Intervention

PTCA       Date PTCA

CABG       Date CABG

Other intervention       Date

---

**Management**

Conservative medical       B-blockers       Antiplatelet drugs

Co-antagonists       Nitroes short acting

CAC       Nitroes long acting

PTE       Cx       Microcoil

Teflon

Stercoil

Balloon       Silicone

Latex

Ivabradine particles

Other intervention

Surgical ligation       alone

External ligation       in combination with  AVR

Arteriotomy and suture closure       MVR

Intra-aortic suture closure       CABG

Other

Complications

S.A.M. Said      page 5 / 5

# Coronary arteriography acquisition form

Fistula characteristics

Coronary arteriography acquisition form				
- Fistula characteristics				
Single (unilateral)	Dual (bilateral)		Multiple (multilateral)	
- Origin	Single		Multiple	
- Origin	Single		Multiple	
- Origin	Single		Multiple	
- Termination	Single		Multiple	
- Pathway	Straight	Tortuous	Single	Multiple
- Fistula aneurysm	yes		no	
- Dilatation of parent vessel	yes		no	
- Dilatation of recipient vessel/chamber	yes		no	
- Calcification	yes		no	
- CAD:	1VD	2VD	3VD	LV:
CAD=atherosclerotic coronary artery disease, VD=number of diseased vessels, LV=left ventricle				

CAD=atherosclerotic coronary artery disease, VD=number of diseased vessels, LV=left ventriculogram



# 5C

## **Angiographically diagnosed congenital coronary artery fistulas in an adult population**

**S.A.M. Said  
L. Relik-van Wely  
T. van der Werf**

**Published in:  
Cardiologie 1998; 5:71-73**

Coronary artery fistulas (CAFs) are an infrequent anomaly. Many diagnostic modalities are available but the considered gold standard is coronary angiography. Coronary artery fistulas are defined as a single or multiple abnormal communications between one or more coronary arteries ending in the right or left cardiac chambers, coronary sinus or great vessels. These communications are divided, according to the magnitude of the left-to-right shunt (Qp/Qs ratio), into small (<1.5), medium (1.5-2) and large (>2) fistulas.

With the widespread use of selective coronary arteriography, CAFs are being recognised with increasing frequency. Due to the low incidence, individual cardiologists may be uncertain about detecting patients with CAFs, what complications may be expected, the question whether or not to treat the anomaly, and treatment options. Therefore, national collection of data on CAF patients would seem to be advantageous.

To answer questions about incidence of CAFs in adults in the Netherlands, we have assessed the current angiographically diagnosed CAFs as a first step in a national data survey. In 1994, a one-page CAF questionnaire was added to the Committee of Coronary Angiography (CCA) annual coronary angiography survey and sent to all Dutch coronary angiographic centres (n=53). In the current CAF questionnaire, the cardiologist was asked to fill in the figures of annually performed CAGs in his/her hospital in the period from 1991 until 1993. They were also requested to fill in the number of detected CAFs during same period. The CAF questionnaire was answered personally, the names of cardiologist and the centre with its location had to be noted. This approach was used to obtain insight into the total number of CAGs performed per year and at the same time to establish the number of CAFs detected annually per coronary angiographic centre.

The activity of the CCA dates back to the late seventies. The initial response rate was very high (80-85%) due to obligatory reply to the request of the Dutch Ministry of Health.

We received a response from 70% of the centres. Of all these centres only (23/53) 43% sent full details about CAFs. Among these CAFs respondents (11/23), 48% reported to have documented coronary artery fistulas (CAFs). The figures of coronary artery fistulas and total numbers of CAG were provided from (18/23) 78% of the CAF respondents.

Up to the early 1970s, the diagnosis of CAFs was based mainly on phonocardiography.<sup>1</sup> In the 1980s, with the introduction of echocardiography, it became possible to diagnose CAFs, initially by means of transthoracic (TTE) and few years later by transoesophageal (TEE) Doppler echocardiographic examinations.<sup>2-4</sup> Magnetic resonance imaging (MRI) has also been sporadically used for detecting and for follow-up of CAFs.<sup>5</sup> The gold standard for recognising CAFs remains coronary angiography, which gives detailed information about the origin, pathway and termination of the fistula. Furthermore, the morphological anatomy of the fistula and coronary arterial tree is identified and it is conceivable that this influences the choice of the therapeutic modality.<sup>6-9</sup>

The response of the Dutch coronary angiographic centres culminated in a summarised description of the total number of CAGs performed and detected annually in the period from 1991 until 1993. This was also meant to build the cornerstone for a national orchestrated action towards obtaining a National Dutch Registry for patients with CAFs and to document all CAFs in the Netherlands.

When enough data is collected in the National Dutch Registry, the real need for a 'Dutch Fistula Unit' could be studied. In such a unit, a concentration of experience in fistula management should be present.

The estimated incidence of CAFs in the literature is about 1/1000-1/500 (0.1-0.2%) of all subjects undergoing coronary angiographic procedures.<sup>7,8</sup> In the current survey, this figure was 0.22%, which corresponds well with the figures found in the literature.

The total numbers of coronary angiographic examinations in the eleven respondent hospitals were 4491, 4905 and 5350 in the years 1991, 1992 and 1993, respectively. In the Netherlands, the annual total numbers of CAGs were 40,000, 42,000, and 45,000, respectively. Among the CAF respondents who completed the whole CAF questionnaire, seven, twelve and fourteen cases of CAFs were diagnosed in 1991, 1992 and 1993, respectively. Some of these patients were the subject of previous publications.<sup>10-13</sup> The CAF response rate of the coronary angiographic centres is very modest (43%).

For this latter reason, a second CAF questionnaire was undertaken in 1997 accompanying the CCA annual survey regarding the period 1994-1996. We believe that a National Dutch Registry of patients with CAFs is useful for optimal diagnosis, treatment and continuous quality control.

This aim of focusing on CAFs that may cause hazardous complications (congestive heart failure, myocardial infarction, infective endocarditis, syncope or sudden death) is meant to bring these disorders under the attention of the angiographers of the future.

Continued central collection of data and experience in subjects with CAFs can provide important information regarding prevalence and on the different therapeutic modalities.

This survey investigated the current angiographically diagnosed CAFs in the Netherlands. However, it indicates that there is still a need for further continuing effort to be invested to tackle the issue of possible under-registration of CAFs.

## References

1. Roos JP, Hartman H, Schaar H van der, Brom AG. Diagnosis and surgical treatment of coronary artery fistula. *Thorax* 1970; 25:259-66.
2. Reeder GS, Tajik AJ, Smith HC. Visualization of coronary artery fistula by two-dimensional echoacardiography. *Mayo Clin Proc* 1980; 55:185-9.
3. Said S. Doppler echocardiographic findings in coronary-pulmonary fistula. *Int J Cardiol* 1989; 25:343-6.
4. Giannoccaro PJ, Sochowski RA, Morton BC, Chan KL. Complementary role of transoesophageal echocardiography to coronary angiography in the assessment of coronary artery anomalies. *Br Heart J* 1993; 70:70-4.
5. Kubota S, Suzuki T, Murata K. Cinemagnetic resonance imaging for diagnosis of right coronary arterial-ventricular fistula. *Chest* 1991; 100:735-7.
6. Nef JJE, de, Varghese PJ, Losekoot G. Congenital coronary artery fistula. Analysis of 17 cases. *Br Heart J* 1971; 33:857-62.
7. Gillebert C, Hoof R van, Werf F van de, Piessens J, Geest H de. Coronary artery fistula in an adult population. *Eur Heart J* 1986; 7:437-43.
8. Said SAM, Landman GHM. Coronary-pulmonary fistula: Long-term follow-up in operated and non-operated patients. *Int J Cardiol* 1989; 27:203-10.
9. Levin DC, Fellows KE, Abrams HL. Hemodynamically significant primary anomalies of the coronary arteries. Angiographic aspects. *Circ* 1978; 58:25-34.
10. Said SAM, Austermann-Kaper T, Bucx JJJ. Congenital coronary arteriovenous fistula associated with atrioventricular valvular regurgitation in an octogenarian. *Int J Cardiol* 1993; 38:96-7.
11. Said SAM, El Gamal MIH. Coronary angiographic morphology of coronary arteriovenous fistulas in adults: Report of four new cases and review of angiograms of fifteen reported cases. *Cath Cardiovasc Diagn* 1995; 35:29-35.
12. Somsen GA, Liem KS. Coronary arter-left ventricular fistulas probably due to transmural myocardial infarction: a case report. *Cardiologie* 1994; 1:65-7.
13. Said SAM, El Gamal MIH, Werf T van der. Coronary arteriovenous fistula. Collective review and addition of six new cases. Changing etiology, presentation and treatment strategy. *Clinical Cardiol* 1997; 20:748-52.



Hospitals responding to CAF questionnaire

Hospital	City
Medisch Centrum Alkmaar Medical Centre	Alkmaar
Hospital Group Twente, location Almelo	Almelo
VU University Medical Centre	Amsterdam
Onze lieve Vrouwe Gasthuis	Amsterdam
Ziekenhuis Apeldoorn	Apeldoorn
Wilhelmina Ziekenhuis	Assen
Catharina Hospital	Eindhoven
Oosterschelde Hospital	Goes
Rivas Zorggroep	Gorinchem
Spaarne Hospital	Heemstede
Elkerliek Hospital	Helmond
Hospital Group Twente, location Hengelo	Hengelo
Zuiderzeeziekenhuis	Lelystad
St. Antonius Hospital	Nieuwegein
Laurentius Hospital	Roermond
Erasmus Medical Centre	Rotterdam
Ikazia Hospital	Rotterdam
Zuiderziekenhuis	Rotterdam
De Honte Hospital	Terneuzen
Diakonessenhuis	Utrecht
Hospital Bernhoven	Veghel
St. Jans-Gasthuis	Weert
Zaans Medical Centre, De Heel	Zaandam

# 5D

## Participating clinical Dutch cardiology centres

Many colleagues facilitated this work and offered the patient's data presented in this thesis. Participating institutions represent both academic (7%) and non-academic (93%) practices. I gratefully appreciate the cooperation of the departments of cardiology of the university medical centers and peripheral Dutch hospitals. The patient's data were collected from the following departments of cardiology as listed in the table below:

Hospital	Cardiologist	City
Alkmaar Medical Centre	J.O.J. Peels	Alkmaar
Hospital Group Twente, location Almelo	C.G.K.M. Fauser B.J.L. de Rode R.J. Lionarons <sup>1</sup>	Almelo
Meander Medical Centre	W.L. Mosterd	Amersfoort
VU University Medical Centre	C.C. de Cock	Amsterdam
St Lucas Andreas Hospital	W.G. de Voogt R.G.E.J. Groutars B. Ilmer A.R. Willems J. Visser	Amsterdam
Maas Hospital	J.R.M. Peters	Boxmeer
IJsselland Hospital	B.J. van den Berg	Capelle a/d IJssel
Deventer Hospitals	F.C.W. Tietge	Deventer
Máxima Medical Centre	L. Relik-van Wely C. de Nooyer	Eindhoven
Medical Spectrum Twente	E.M.C.J. Wajon	Enschede
St Anna Hospital	J.W. Louwerenburg W.A.A.J. van Ekelen P.E. Polak	Geldrop
Oosterschelde Ziekenhuis	J.A.J. de Boo A.H. Liem H.W.O. Roeters van Lennep	Goes
Kennemer Gasthuis	B. van Vlies A.J. Funke Küpper	Haarlem
St Jansdal Hospital	R. Dijkgraaf	Harderwijk
Elkerliek Hospital	R.R. Lalisang M.F. Scholten <sup>2</sup>	Helmond
Hospital Group Twente, location Hengelo	A. Derks H.T. Droste J.H. Fast	Hengelo
Bethesda Hospital	C.G.K.M. Fauser <sup>3</sup>	Hoogeveen
Atrium Medical Centre	A.G. Boehmer	Kerkrade
Leeuwarden Medical Centre	C.J. de Vries	Leeuwarden

Canisius-Wilhelmina Hospital	L.H.R. Bouwels	Nijmegen
Radboud UMC Nijmegen	T. van der Werf	Nijmegen
	J. Timmermans	
Waterland Hospital	D.G. de Waal	Purmerend
Maasland Hospital	G.J. de Weerd	Sittard
Antonius Hospital	D.E.P. de Waard	Sneek
Hospital Bernhoven	L. Relik-van Wely	Veghel
Zaans Medical Centre, De Heel	C.L.J.M. van Engelen	Zaandam
Gelre Hospitals, location Het Spitaal	A.C. Tans	Zutphen
Isala Clinics	W.J. Louridtz	Zwolle
	H.A. Oude Luttikhuis	

---

At present: <sup>1</sup> Bethesda Hospital, Hoogeveen, <sup>2</sup> Medical Spectrum Twente, Enschede and <sup>3</sup>Hospital Group Twente, location Almelo.

# Chapter 6

## **Dutch Survey of Coronary Artery Fistulas in Adults: Congenital Solitary Fistulas Multicentre observational survey in the Netherlands**

**S.A.M. Said  
T. van der Werf**

**Published in:  
International Journal of Cardiology 2006; 106:323-332  
Affiliated with the International Society for Adult Congenital Cardiac Disease**

Presented in part at the World Congress of Pediatric Cardiology, 2001, Toronto, Canada.  
Presented in part at the annual scientific meeting of the Dutch Society of Cardiology, April 2005, Amsterdam.

## **Abstract**

**Aims** Congenital coronary artery fistulas are frequently identified in adult and pediatric populations and they have been associated with various clinical and morphological features. The purpose of this study was to define the clinical and coronary angiographic morphological characteristics of adult patients with congenital solitary CAFs in the Dutch Registry.

**Methods and results** Fifty-one patients with angiographically documented CAFs were reviewed for clinical evaluation, used non-invasive and invasive diagnostic tools and treatment modalities. Unilateral CAFs were predominant (80%) and 84% of the patients were symptomatic. The most common presenting symptom was angina pectoris (57%). Angina pectoris was present in a quarter of the patients in the absence of coronary artery disease (CAD). Significant CAD was present in 39% of the patients. Twenty-nine percent of the CAFs showed aneurysmal formation, underlying their potential hazard of rupture. Myocardial infarction occurred in 18% of the patients. In 27% of CAFs multiplicity of the origin was found and nearly all fistulas were tortuous (97%). Treatment modalities were conservative medical in 70%, percutaneous transluminal embolisation in 5% and surgical ligation in 25% of the cases.

Multiple micro-fistulas from the coronary arteries to the left ventricle were excluded from the study.

**Conclusion** In this national survey series, congenital solitary CAFs can be presented with typical angina pectoris in the absence of obstructive CAD. Fistula-related coronary artery was infrequently involved in the development of ipsilateral myocardial infarction. Tortuosity and multiplicity of the CAFs may determine, for the individual patient, the choice of the currently available treatment modalities.

## **Introduction**

Congenital coronary artery fistulas have been recognized since 1865, and account for 0.08% to 0.4% of all congenital heart diseases.<sup>1-3</sup>

The incidence of coronary artery fistulas (CAF) in the general adult population is not known, but angiographic prevalence is estimated at 0.2%.<sup>4</sup> Recent survey estimated the cumulative prevalence of CAFs in the Netherlands at 0.22%.<sup>5</sup> In children, the incidence may be greater, however, echocardiographic incidence was estimated at 0.06-0.2%.<sup>6,7</sup>

The course can be benign in childhood, but with advancing age, symptoms of the disease increase and CAFs may lead to serious complications, or even sudden death.<sup>8,9</sup> Still little is known about the impact of congenital CAFs on coronary flow dynamics, angina pectoris and on the development of myocardial infarction during the extended course of the disease.

We conducted an inquiry to collect clinical and angiographic data in a Dutch Registry. Coronary artery-left ventricular micro-fistulas were excluded. In the present paper, we summarize clinically relevant issues of congenital solitary CAFs in an adult population with an emphasis on coronary morphological aspects.

## **Patients and methods**

### **Design of the inquiry**

In 1996, a questionnaire was sent out to catheterization laboratories of all Dutch cardiac institutions requesting information about the occurrence of CAFs among their adult population. Patients with CAFs from their databases were selected. Clinical and angiographic data were collected and analysed by the first author according to the method described below. Patients with angiographically documented CAFs were included in the survey of the Dutch Registry (DR). Patients from pediatric cardiac centres were not included into the study. Participating Dutch institutions are shown in appendix 1.

### **Patients**

In the DR, 86% of the patients were collected between 1996 and 2003 and 14% prior to 1996. The coronary angiographic findings and clinical data of 51 patients with CAFs were analyzed from a total catheterization population of 30829 from 28 centres. Data of these

patients (33 M (65%) and 18 F (35%)) with a mean age of 60.3 years (range from 29-85 yrs) were reviewed (Table 1). This volume is a reasonable representative sample of the catheterization population in the Netherlands. In 2004, a phone call was conducted to all participating centres inquiring and gathering information about mortality among the population under study. The response was 100%.

### Coronary arteriography (CAG)

CAG in multiple views and obliquities were performed according to the standard Judkins or Sones procedures. A vessel was considered to have significant stenosis if its diameter, by eyeball judgement, was narrowed by > 60% with respect to the adjacent pre-stenotic segment.

### Description and Fistula characteristics

The CAFs were described according to the origin, termination, their morphology and aneurysmal formation, if applicable.

In relation to the supplying "parent" coronary artery (CA) we used the following terminology. Unilateral: One CA is participating in the fistula formation. Bilateral "dual": Two separate CAs are involved in the fistulous formation. Multilateral "triple = multiple": All three major CAs are sharing the fistula formation. The uni-, bi-, and multilateral fistulas in the 51 patients formed a total of 63 coronary artery fistulas.

Origin, termination and pathway could be fully determined in all. We recognized for the origin and termination each, two morphological types: single or multiple channels and for the pathways three different types: tortuous/multiple, tortuous/single and straight/single channels with or without aneurysmal formation or dilatation of the fistula-related artery (Fig. 1).

**Statistical analysis:** Data are presented as mean ± SD, percentage or range.

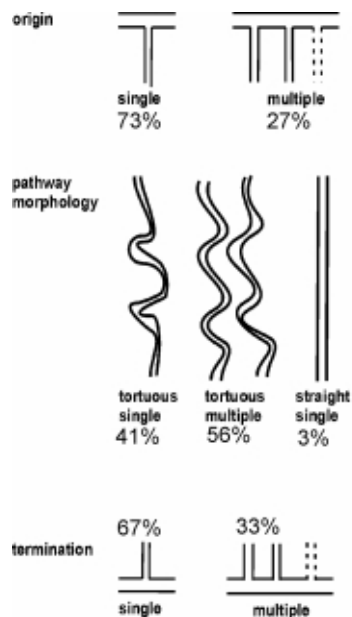


Fig. 1 An art drawing illustrating origin, pathways and ending of CAFs.

## Results

- Clinical presentations and indications for coronary arteriography

We collected 51 patients with a total of 63 CAFs. Sixty-nine percent of patients in the DR were in the age distribution group of >50 years and 31% were in the age group of <50 years. There were no patients with a sharp thoracic trauma in the history nor with previous intravascular procedures. Therefore all CAFs in the DR were considered to have a congenital origin. Only one female patient had a car accident several years prior to inclusion which is unlikely to be the cause of the formation of a fistula. The majority was not associated with other congenital cardiac anomalies. In only 5 patients (10%) associated congenital heart disorders were found. The congenital abnormalities were: atrial septal defect (primum and secundum ASD), ventricular septal defect (VSD), persistent ductus arteriosus (Botalli), and persistent left superior caval vein.

The clinical presentation was not always the same as the indication for cardiac catheterization. Indications for catheterization in the DR as given by the clinical cardiologists are shown in Table 2. At the time of diagnosis, the clinical presentations were as follows: Sixteen percent were asymptomatic (8 patients) and 84% were symptomatic (43 patients). Among the asymptomatic patients, cardiac catheter was performed during preoperative assessment for cardiac surgery (valve and congenital heart disease) in 2 patients, during work-up for lung transplantation (one patient), in two patients with abnormal rest ECG during cardiac evaluation for non-cardiac surgery and in three patients continuous heart murmur was audible. Of these 8 patients, concomitant ligation of the fistula was performed during reparative surgery for valve and congenital heart disease in two patients. The total number of complaints was 58. Angina pectoris (AP) 29x, atypical chest pain (ACP) 8x, fatigue 6x, palpitation 5x, dyspnea 8x, presyncope 1x and congestive heart failure (CHF) 1x. In summary, the most common symptoms were chest pain (anginal and atypical) followed by both dyspnea and fatigue. Risk factors for coronary artery disease occurred in 29% of patients. Hypercholesterolemia accounted for 15x, smoking for 9x, hypertension for 10x and diabetes mellitus for 1x.

- Results of coronary arteriography

Thirty-one patients (61%) had no coronary artery disease. Thirteen patients (25%) had one vessel disease (VD), while dual VD was present in 4% and triple VD in 10% of the patients. Dilatation of the fistula-related coronary artery (FRA) was seen in 10% and calcification within the cardiac silhouette in merely one of the patients. Contrast left ventriculogram was found normal in 30 patients (59%), abnormal in 13 (25%) and not performed in 8 (16%) of the subjects.

- Description of the CAFs: (Fig. 2, 3).

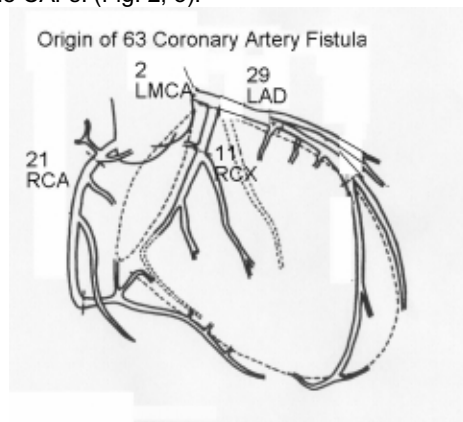
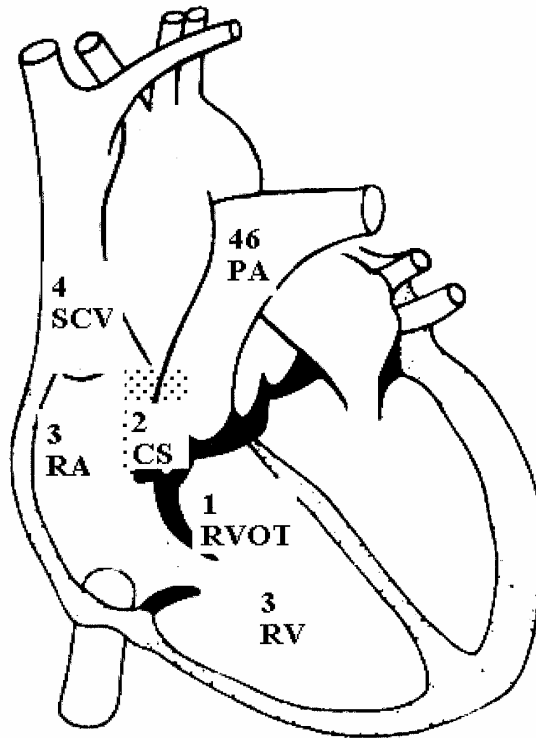


Fig. 2 Coronary arterial tree demonstrating the origin of 63 CAFs in the DR.

RCA = right coronary artery; LMCA = left main coronary artery; LAD = left anterior

descending coronary artery; RCX = circumflex coronary artery.

### Termination of 63 Coronary Artery Fistulas



#### Low systolic pressure areas

Fig.3 Number of CAFs draining to the different low systolic pressure areas of the heart are illustrated.

AP = pulmonary artery; CS = coronary sinus; RA = right atrium; RV = right ventricle; RVOT = right ventricular outflow tract; SCV = superior caval vein.

There were a total of 63 CAFs, of these 41 were unilateral (80%), 8 bilateral (16%) and 2 multilateral (4%) CAFs. Some examples are shown in (Fig. 4a-d).

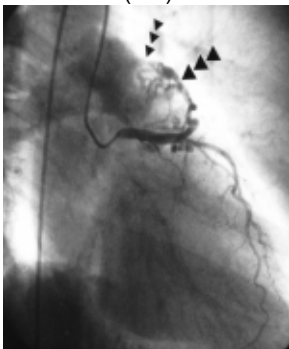


Fig. 4a

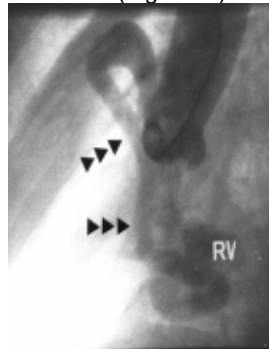


Fig. 4b



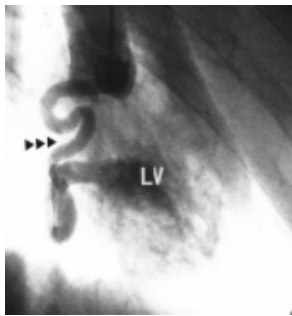


Fig. 4c

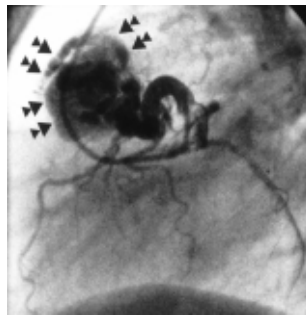


Fig. 4d

Fig. 4a

A female of 62 years old. Frame of right anterior oblique projection of left coronary angiogram demonstrating a proximally located fistula (arrows) having multiple origin but a single termination into the pulmonary trunk. Coronary hypoperfusion could be noticed distal to the fistula.

Fig. 4b

Aortogram of an adult unoperated female patient who became 73 years old, illustrating a huge tortuous fistulating right coronary artery (arrows) ending into the right ventricle (RV).

Fig. 4c

Aortogram of a patient of 35 years old man with endocarditis showing a dilated and tortuous right coronary artery (arrows) fistulating directly into the lumen of the left ventricle (LV).

Fig. 4d

Frame of left lateral projection of left coronary angiogram, of a female of 69 years old, depicting a huge serpiginous proximally located fistula (arrows) draining into the pulmonary trunk. The marked hypoperfusion of left anterior descending coronary and circumflex arteries is appreciated.

The CAFs originated 29x from the LAD, 21x from the RCA, 11x from the Cx and 2x from the LMCA. The pulmonary artery (PA) was the most common site of distal communication of the CAFs namely 46x. Furthermore 3x into the right atrium (RA), 4x into the superior caval vein (SCV), 3x into the right ventricle (RV), 3x into the left atrium (LA), 1x into the right ventricular outflow tract (RVOT), 2x into the coronary sinus (CS) and 1x into the left ventricle (LV). Aneurysmal formation of the fistulous communications occurred in 29% of the fistulas. It concerned 35% of the patients.

The origin, termination and pathways of the fistulous communications are shown in figure 1. Tortuous pathways were far most prevalent (97%). Because of the specific importance and therapeutic implications of these aspects the findings of Table 3 are highlighted. Multiplicity of origin and termination were found in 27% and 33% of CAFs, respectively. Furthermore, tortuosities of pathways were predominantly present in the CAFs with single (41%) and multiple (56%) channels.

- Results of Non-invasive diagnostic tests

A typical continuous murmur was audible in 11 (22%) patients, a diastolic murmur in 1, a systolic murmur in 13 (25%) and no murmur was heard in 26 (51%) of the cases. There were 22 patients with, mild or severe, concomitant valvular heart disease.

ECG was normal in 22 subjects and pathologic in 29 patients (ST-T segment abnormalities, pathologic Q waves, LVH and healed MI). Complete and incomplete RBBB was present in 7 cases and one patient showed ventricular pacing for chronic slow atrial fibrillation (AF). In 4 patients, AF was depicted; the remaining patients were in sinus rhythm (47; 92%).

Chest roentgenography was performed in 84% of the patients. It was normal in 30 patients (70%) and showed cardiac abnormalities in 13 patients (30%); of these nine demonstrated

cardiomegaly. Pulmonary disorders were found in 4% of the patients. Intracardiac calcification was detected in one patient (Fig. 5).

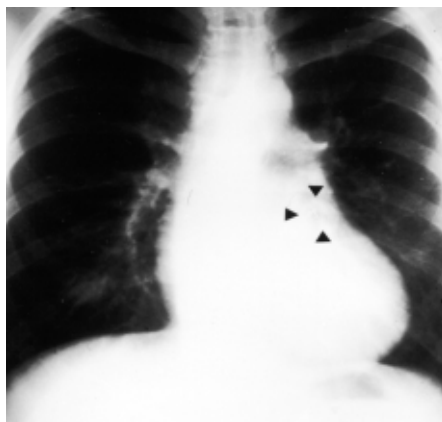

Fig 5  
Chest roentgenograph of a 36-year-old male demonstrating circular calcification (arrow heads) in the left paracardiac region in a patient with operated congenital coronary artery fistula.

Exercise tolerance test was performed in 32 subjects (63%) of which 23 cases proved to be normal (72%) and 9 patients demonstrated positive signs for coronary insufficiency (28%). Stress MIBI scintigraphy was performed in 20 patients (39%). Of these, 11 patients (55%) had a positive test demonstrating reversible myocardial defects.

Transthoracic echocardiography (TEE) was performed in 36 subjects (71%). It was judged normal in 8 cases (22%) and abnormal in 28 patients (78%). Of these, 25 had mild valvular disorders and 3 revealed wall motion abnormalities. In only 8% of the subjects the TTE was helpful, prior to coronary angiographic examination to detect or raise the suspicion of the presence of the CAF. Severe aortic and mitral valve disorders requiring replacement or valvuloplasty were found in 3 and 2 patients, respectively.

#### **Treatment and survival**

The treatment of the subjects in the DR was conservative medical management in 36 cases (70%). Of these 5 patients were followed-up with expectative (wait and see) strategy. Thirty-one patients were treated medically. The treatment of seven of these was primarily for CAFs and in 24 it was addressed for concomitant disorders (Hypertension 9 pts, hypercholesterolemia 8 pts, post-myocardial infarction 3 pts, congestive heart failure 2 pts, paroxysmal atrial fibrillation 1 pts and diabetes mellitus 1 pts).

Among the drugs used, were beta blockers in 28 pts, anticoagulant/antiplatelet in 16 pts, statins in 8 pts, diuretic therapy in 6 pts, calcium re-entry blockers in 6 pts, and long-acting nitrates in 11 pts. Furthermore, ACE inhibitors in 5 pts, All antagonists in 3 pts, antiarrhythmic drugs in 2 pts and oral antidiabetic drugs in 1 patient.

In only 2 cases percutaneous transluminal embolization techniques was utilized and in a third PTE was a failure. One patient had a small residual fistula and in the other, the procedure was complicated by a myocardial infarction due to migration of the coils distally into the parent coronary artery.

Retrospectively, surgical procedures were performed in 13 patients (25%). Primarily surgical ligation for CAFs was performed in 2 patients (4%). During surgical repair procedures (1x valve disease, 2x coronary artery and valve disease, coronary artery disease 6x and congenital heart disease 2x), concomitant closure of the fistula was undertaken in the remaining 11 patients (21%).

Among the indications for surgical intervention were endocarditis, associated congenital anomalies, acquired valve and coronary heart disease. However, surgical ligation of the fistula was impossible in another 3 patients who underwent coronary artery bypass surgery. It was technically difficult to reach the fistula because they had very proximal localisation.

### **Mortality**

One patient with cystic fibrosis died at the age of 29 years secondary to respiratory insufficiency awaiting lung transplantation.

Cardiac mortality was 4% during a mean follow-up period of 5 years. Up to 2004 and during mean follow-up period of  $62 \pm 41$  months (varying from 7-164), death occurred in 2 patients (1 female and 1 male). Both died at the age of  $> 72$  years. Both patients had chronic atrial fibrillation and demonstrated cardiomegaly on chest X-ray. One patient died secondary to terminal heart failure and 1 patient due to unwitnessed death at home; their fistula possessed no aneurysmal formation. In these 2 patients death could probably be related to the presence of the CAFs.

### **CAFs and myocardial infarction**

Myocardial infarction (MI) had occurred in 8 patients of the DR contingent. Localization of the MI was anterior 1x, inferior 3x, infero-lateral 2x, infero-posterior 1x and lateral 1x.

The CAFs (a total of 11 fistulas) were found to be unilateral 5x and bilateral 3x. Aneurysmal formation of the CAFs was detected in three patients. All the 8 patients had significant CAD as follows: single VD was present in 5 subjects and triple VD in three of these patients.

MI, contralateral to the shunt occurred in 7 subjects; whereas ipsilateral MI with a relation between the location of the infarct-related artery (IRA), MI and the fistula-related artery (FRA) was found in only 1 patient. A test for significance was not performed because of small numbers.

### **CAFs and angina pectoris**

Of the 51 DR patients, 29 had typical angina pectoris (Table 3) and 22 had no angina. Sixteen patients who presented themselves with AP had angiographically anatomic significant narrowing scattered in the coronary arterial tree. On the other hand, in thirteen patients with anginal symptoms no anatomically detectable coronary stenoses were found.

In the absence of AP, no significant coronary artery disease was found in eighteen and documented in only four patients. A comparison between the angiographic appearances of the subgroups with AP without concomitant CAD (subgroup 1) (13 subjects) and without AP or CAD (subgroup 2) (18 subjects) are summarized in Table 4. In subgroup 1 and 2, the right heart side was the site of termination in 100% and 90% of the fistulas, respectively and tortuous fistulous vessels were found in 93% and 95% of the fistulas. Moreover, aneurysmal formation accounted for 46% in subgroup 1 versus 39% in subgroup 2 patients.

Among all DR patients, significant coronary artery disease (CAD) was found in 20 patients (16 with AP and 4 without AP). CAD was not detected in 31 patients (13 with AP and 18 without AP).

We took a closer look at the 13 patients with angina pectoris but without CAD. Besides to AP, dyspnea occurred 3x, fatigue 2x, palpitation 1x and presyncope 1x. Co-morbidities were present as follows: COPD 1x, hypertension 3x, hypercholesterolemia (TC  $>5$  mmol/l) 5x, transient ischemic attack and carotid artery desobstruction 1x and temporal arteritis 1x. The ECG was abnormal in 6 patients depicting ST-T segment deviation and slow R-wave progression across the precordial leads. Atrial fibrillation was found in one patient. Chest X-ray demonstrated overt cardiomegaly in three, aorta elongation in one, not available in one and normal cardiac silhouette in eight of the patients.

Stress MIBI scintigraphic studies were available in six patients. These studies were positive for myocardial ischemia in four and negative in two. The results for reversible myocardial ischemia did not correspond all the time with the territory supplied by the fistula-related coronary artery. On the other hand, exercise tolerance test was performed in 9 subjects. It was found positive in three and negative for myocardial ischemia in six of the patients. In

total, 7 patients had an objective proof for coronary insufficiency. Bilateral CAFs occurred in 1 and unilateral in 12 of the patients. The origin of the CAFs was the LAD in 9 and the RCA in 5 of these fistulas. The exit of the CAFs was as follows: PA 11x, RA 1x, SCV 1x and RV 1x. They were mostly (13x) tortuous, multiple 6x and single 7x, compared to the straight/single type 1x. Aneurysmal formation of the fistulous communication was found in 6 patients and dilatation of the FRA in 2 patients. Contrast ventriculographic examinations revealed normokinetic left ventricle in 11 patients, dilated cardiomyopathy in one and was not available in only one.

## **Discussion**

### **Study population**

The number of studied cases (51/30829) corresponded well with the figures presented in the literature of 0,2%.<sup>4,5</sup> Thus we consider that the current study cohort is a representative sample of the adult catheterisation population in the Netherlands. None of our patients was under the age of twenty years.

### **Morphology of CAFs**

#### *Origin and termination*

The coronary artery to the left ventricle micro-fistulas were excluded from this report because of differences of etiology, symptomatology and pathophysiology.

In the DR, the origin and the termination of the fistulous communications consisted of multiple channels in slightly more than a quarter of the patients and in slightly more than one third of the fistulas, respectively. This figure is surely important hence PTE may not be facilitated or even abandoned.

In the DR, we found that the majority of the CAFs were unilateral but bilateral CAFs were 16% and the multilateral were rare. It has been reported that multiple (multilateral) CAFs occur in 10.7% to 16% of all fistulas, whereas bilateral fistulas are found in about 5%.<sup>10-13</sup> Triple (multilateral) fistulas are reported to be rare.<sup>14</sup> These differences might be related to the definition used in identification of the fistulas since bilateral CAFs might have been tabulated as multilateral fistulas. An earlier angiographic review of 23 subjects with CAFs described 26% to have evidence of aneurysmal dilatation.<sup>15</sup> In the DR, the aneurysmal formation of the fistulous communications was clearly visible in 35% of the patients.

#### *Morphology of the CAFs*

In the DR, the majority of the pathways of the fistulous communications were predominantly tortuous: with multiple small channels in over half of the fistulas and with single channels in 41% of the fistulas.

Regarding the morphological aspects of CAFs, Gillebert et al, described 5 different angiographic morphological types.<sup>4</sup> This was based on 23 patients and divided CAFs into 5 types and seemed that not all types would fit into this stratification. Iskandrian described only 2 angiographic morphological types.<sup>16</sup> This classification is incomprehensive and lacks completeness. In the DR, we demonstrated 2 types describing the origin, termination and 3 separate types describing the pathways. The DR classification included systematically all components of the CAFs with respect to the future choice of therapeutic intervention. These morphological differences between our findings and those described in literature make it difficult to compare the results due to lack of uniformity.

- **Clinical presentations**

In the DR only adult patients were included. In this adult population, none was under the age of twenty, 69% of the patients were above the age of 50 years and 72% had single or multiple risk factors for CAD. It has been reported that patients older than 25 years were symptomatic.<sup>17-19</sup>

In the current study, only 16% of the DR subjects were asymptomatic. The main presenting symptom was chest pain (72%) followed by dyspnea in (16%) of the patients. This high percentage of chest pain may be related to the advanced age and the presence of coronary

artery disease in the DR.

The clinical presentations of the CAFs are variable. Up till 1997, on reviewing the world literature, we found an increasing number of acquired CAFs and that the clinical presentations were asymptomatic in 55% of the subjects, 34% had chest pain and 13% had CHF.<sup>20</sup>

#### *CAFs and myocardial infarction*

In the DR, only 2% (1/51) of the patients developed an ipsilateral MI occurring in the same territory of the fistula-related and infarct-related coronary artery.

Acute myocardial infarction is considered a rare complication of CAFs.<sup>21-23</sup> It has been postulated that acute MI is presumably due to thrombotic embolism originating from the coronary artery fistula.<sup>21</sup> But regarding the involvement of the segment of the fistula-related arteries, proximal to the origin of the fistula, Bauer postulated that elevated shear stress due to increased flow velocity and turbulence may predispose a vessel to accelerated atherosclerosis and thrombosis, resulting in occlusion of distal flow, increased intraluminal pressure, and rupture of the weakened wall.<sup>24</sup> The presence of fresh thrombus, marked atherosclerosis, and mural thinning on pathologic analysis were documented.<sup>24</sup> None of our patients demonstrated, during CAG, intracoronary thrombus formation.

Our own observation, namely that from 51 patients with one or more fistulas, in only 1 case the infarct-related artery was the supplier of the fistula, makes it highly improbable that fistulas are a potential cause of infarction.

#### *CAFs and angina pectoris*

Intriguing were the 13 patients with angina pectoris but without the presence of CAD; seven of these had objective proof for coronary insufficiency.

With increased myocardial work during exercise, the microvasculature dilates to increase coronary blood flow up to four or five times basal flow: the so-called coronary flow reserve (CFR).

In CAFs, basal coronary blood flow is increased and hence the CFR is decreased. At rest, myocardial perfusion is adequate. But when exercising, myocardial perfusion may be inadequate due to inability of CFR to be augmented.

In the literature there are only 2 cases of actual measurement and full description of the flow pattern in the parent coronary artery or the fistula itself. Bitar et al, described a continuous flow pattern with a higher velocity in systole than diastole in a LAD to pulmonary artery fistula after measurement of the coronary flow velocity within the fistula and in the nutrient coronary artery. They demonstrated that the fistula was insensitive for adenosine administration and therefore concluded that there was no evidence for "steal" phenomenon. It was clearly shown by Bitar et al, that basic coronary velocity was elevated in the fistula-bearing vessel.<sup>25</sup>

In the fistula reported by Wexberg et al, intracoronary Doppler flow measurement revealed a high average peak flow velocity (APV) at baseline with loss of coronary flow reserve and after successful PTE of the RCA to coronary sinus fistula, CFR was restored to normal with concomitant reduction of baseline APV.<sup>26</sup> Although they used inappropriate terminology about "steal" in their report, there was no proof found for coronary steal in the patient mentioned. There were no measurements taken in the fistula itself.

Thus we conclude that chronically elevated basic coronary flow in absence of arterial narrowing has negative consequences with regard to CFR and may lead to angina pectoris with normal coronary arteries. Furthermore it is reasonably to suppose that in patients with CAFs and mild coronary stenosis it is likely that symptoms may prematurely evolve.

### **Treatment**

According to the ACC/AHA guidelines, CAFs have a class II indication for device occlusion treatment; CAFs are considered disorders for which coil occlusion may be indicated.<sup>27</sup> In the DR, quite a large number of CAFs demonstrated multiplicity and tortuosity. Only 5% of the patients were treated with PTE with moderate procedural success. In the series of Alekyan and co-workers, PTE was successful in 93% (14/15) of patients but with one early death (7%).<sup>28</sup> The acute and catastrophic presentation of spontaneous rupture supports the view that congenital CAFs should be electively repaired, preferably before age 20 years, when

operation risk is lowest.<sup>29</sup> Mavroudis et al concluded that coil embolization was feasible in only 37% of the patients, a figure similar to that reported by Perry et al.<sup>19,30</sup> In our series, surgical repair was performed in 25% of the patients. The mean age at operation was 53.4 yrs (varying from 7 to 79 yrs). In the DR, surgical ligation alone (4%) or associated (21%) with other coronary or cardiac interventions was performed. Bauer and co-workers reported their experience of surgical treatment of 14 patients with congenital CAFs with a mean age of 47 years, 7 patients exhibited additional coronary artery disease requiring surgery.<sup>31</sup> As was the case in the DR, surgical treatment, surgery and postoperative courses were uneventful in all patients of Bauer's series.

There is general agreement in the literature that surgical ligation or percutaneous transluminal embolization (PTE) of CAFs is indicated in symptomatic patients with a large shunt. The indications for PTE are among others proximal localization of the fistulous vessel, extra-anatomic termination of the fistulous vessel away from the normal coronary arteries and older subjects. On the other hand, indications for surgery include patients with large CAFs characterized with high fistulous flow, multiple communications, extreme tortuous pathways, multiple terminations or significant aneurysmal formation.<sup>19</sup>

An advice for antibiotic prophylaxis of infective endocarditis (IE) was recommended. Infective endocarditis occurred in only one patient (2%) of the DR. IE remains a real catastrophic event of CAFs with an incidence reported in the literature of 0-12%.<sup>2,29,32,33</sup>

### **Limitations of the study**

Registry is not as reliable as a trial. In a national registry a limited number of patients may be included. We collected angiographic and clinical data of 51 cases out of a total of 30829 subjects of catheterisation adult population. Based on the regulations of the Dutch privacy law it was expected that not all CAFs patients in the Netherlands could be included. Furthermore, the treatment modalities were not prospectively randomised.

The limitations of this study are its retrospective nature and its relatively small sample size. It describes the experience of a single European country and does not compare any therapeutic strategies.

This was mainly a clinical and angiographic registry. One of the important drawbacks of the current study is that there was no "prospective" rigorous protocol available prior to inclusion into the DR. It is of great value to investigate these CAFs patients prospectively according to a given protocol consisting of Doppler echocardiographic studies, exercise tolerance test, and/or MIBI scintigraphic examination, magnetic resonance imaging, cardiac catheterization for left-right shunt determination, Doppler wire studies with adenosine to evaluate the flow dynamics of the fistula and fistula parent vessel.

- **Clinical implications**

In a representative sample of the Dutch catheterisation population we found that the majority of the fistulas showed tortuosity and multiplicity. Therefore percutaneous transcatheter embolisation may be reserved for certain fistulas with suitable anatomy.

Fistulas can elicit angina, even in the absence of coronary artery narrowing, probably because of a reduced coronary flow reserve. On the other hand fistulas do seldomly or ever provoke myocardial infarction.

In 5 years cardiac mortality was 4%. We consider this favourable, taken into consideration the relatively high mean age of the sample (60 years).

### **Acknowledgements**

Great appreciation for many Dutch colleagues who facilitated this work and offered the patient's data presented in this study.

### **References**

1. Kirklin JW, Barratt-Boyes BG. Cardiac surgery. New York: Wiley, 1987:945-55.
2. McNamara JJ, Gross RE. Congenital coronary artery fistula. Surgery 1969; 65:59-69.

3. Baltaxe HA, Wixson D. The incidence of congenital anomalies of the coronary arteries in the adult population. *Radiology* 1977; 122:47-52.
4. Gillebert C, Van Hoof R, Van de Werf F, Piessens J, De Geest H. Coronary artery fistula in an adult population. *Eur Heart J* 1986; 7:437-43.
5. Said SAM, Relik-van Wely L, van der Werf T. Angiographically diagnosed congenital coronary artery fistulas in an adult population. *Cardiologie* 1998; 2:71-3.
6. Sherwood MC, Rockenmacher S, Colan SD, Geva T. Prognostic significance of clinically silent coronary artery fistulas. *Am J Cardiol* 1999; 83:407-11.
7. Hsieh KS, Huang TC, Lee CL. Coronary artery fistula in neonates, infants, and children: clinical findings and outcome. *Pediatr Cardiol* 2002; 23:415-9.
8. Tkebuchava T, von Segesser LK, Vogt PR, Jenni R, Arbenz U, Turina M. Congenital coronary fistulas in children and adults: diagnosis, surgical technique and results. *J Cardiovasc Surg* 1996; 37:29-34.
9. Carrel T, Tkebuchava T, Jenni R, Arbenz U, Turina M. Congenital coronary fistulas in children and adults: diagnosis, surgical technique and results. *Cardiology* 1996; 87:325-30.
10. Fernandes ED, Kadivar H, Hallman GL, et al. Congenital malformation of the coronary arteries: the Texas Heart Institute experience. *Ann. Thorac Surg* 1992; 54:732-40.
11. Kirklin JW, Barratt-Boyes BG. Congenital anomalies of the coronary arteries. In: Kirklin JW, Barratt-Boyes BG, eds. *Cardiac surgery*. New York: Churchill Livingstone, 1993; 1167-93.
12. Bauer EP, Piepho A, Klovekorn WP. Coronary arteriovenous fistula: surgical correction of a rare form. *Thorac Cardiovasc Surg* 1994; 42:237-9.
13. Olearchyk AS, Runk DM, Alavi M, Grosso MA. Congenital bilateral coronary-to-pulmonary artery fistula. *Ann Thorac Surg* 1997; 64:233-5.
14. Ashraf SS, Shaikat N, Fisher M, Clarke B, Keenan DJ. Bicornary-pulmonary fistulae with coexistent mitral valve prolapse: a case report and literature review of coronary-pulmonary fistula. *Eur Heart J* 1994; 15:571-4.
15. Said SAM, El Gamal MIH. Coronary angiographic morphology of congenital coronary arteriovenous fistulas in adults: Report of four new cases and review of angiograms of fifteen reported cases. *Cath Cardiovasc Diagn* 1995; 35:29-35.
16. Iskandrian AS, Kimbiris D, Bemis CE, Segal BL. Coronary artery to pulmonary artery fistulas. *Am Heart J* 1978; 96:605-9.
17. Kamiya H, Yasuda T, Nagamine H, Sakakibara N, Nishida S, Kawasuji M, Watanabe G. Surgical treatment of congenital coronary artery fistulas: 27 years' experience and a review of the literature. *J Card Surg* 2002; 17:173-7.
18. Urrutia-S CO, Falaschi G, Ott DA, et al.: Surgical management of 56 patients with congenital coronary artery fistulas. *Ann Thorac Surg* 1983; 35:300-7.
19. Mavroudis C, Backer CL, Rocchini AP, Muster AJ, Gevitz M. Coronary artery fistulas in infants and children: a surgical review and discussion of coil embolization. *Ann Thorac Surg* 1997; 63:1235-42.
20. Said SAM, El Gamal MIH, van der Werf T. Coronary arteriovenous fistulas. Collective Review and Management of Six New Cases- Changing Etiology, Presentation, and Treatment Strategy. *Clin Cardiol* 1997; 20:748-52.
21. Shirai K, Ogawa M, Kawaguchi H, Kawano T, Nakashima Y, Arakawa K. Acute myocardial infarction due to thrombus formation in congenital coronary artery fistula. *Eur Heart J* 1994; 15:577-9.
22. Sapin P, Frantz E, Jain A, Nichols TC, Dehmer GJ. Coronary artery fistula: an abnormality affecting all age groups. *Medicine* 1990; 69:101-13.
23. Levin DC, Fellows KE, Abrams HL. Hemodynamically significant primary anomalies of the coronary arteries. Angiographic aspects. *Circulation* 1978; 58:25-34.

24. Bauer HH, Allmendinger PD, Flaherty J, Owlia D, Rossi MA, Chen C. Congenital coronary arteriovenous fistula: Spontaneous rupture and cardiac tamponade. *Ann Thorac Surg* 1996; 62:1521-3.
25. Bitar SR, Aquirre FV, McBride L, Munroe C, Kern MJ. Characterization of intra-arterial flow velocity within left coronary to pulmonary artery fistula. *Cath Cardiovasc Diagn* 1997; 41:208-12.
26. Wexberg P, Gottsauner-Wolf M, Kiss K, Steurer G, Glogar D. An iatrogenic coronary arteriovenous fistula causing steal phenomenon: An intracoronary Doppler study. *Clin Cardiol* 2001; 24:630-2.
27. Allen HD, Beekman RH, Garson A.Jr, Hijazi ZM, Mullins C, O'Laughlin MP, Taubert KA. Pediatric therapeutic cardiac catheterization. A statement for healthcare professionals from the council on cardiovascular disease in the young, American Heart Association. *Circulation* 1998; 97:609-25.
28. Alekyan BG, Podzolkov VP, Cárdenas CE. Transcatheter coil embolization of coronary artery fistula. *Asian Cardiovasc Thorac Ann* 2002; 10:47-52.
29. Libersson RR, Sagar K, Berkoborn JP, Weintraub RM, Levine FH. Congenital coronary arteriovenous fistula. Report of 13 patients, review of the literature and delineation of management. *Circulation*. 1979; 59:849-54.
30. Perry SB, Rome J, Keane JF, Baim DS, Lock JE. Transcatheter closure of coronary artery fistulas. *J Am Coll Cardiol* 1992; 20:205-9.
31. Bauer M, Bauer U, Alexi-Meskishvili V, Pasic M, Weng Y, Lange PE, Hetzer R. Koronarfiistel : Angeborene koronarfiisteln-die häufigste angeborene koronaranomalie. *Zeitschrift für Kardiologie* 2001; 90:535-41.
32. Wilde P, Watt I. Congenital coronary artery fistulae: six new cases with a collective review. *Clin Radiol*. 1980; 31:301-11.
33. Ogden JA, Stansel HC. Coronary arterial fistulas terminating in the coronary venous system. *J Thorac Cardiovasc Surg* 1972; 63:172-82.

## Appendix 1

### Participating Dutch institutions, in alphabetical order:

J.O.J. Peels, MD, Hospital Medisch Centrum Alkmaar; C.G.K.M. Fauser, MD, R.J. Lionarons, MD, B.J.L. de Rode, MD, Hospital Ziekenhuisgroep Twente, location Almelo; W.L. Mosterd, MD, Eemland Hospital Amersfoort; C.C. de Cock, MD, University Hospital Vrije Universiteit Amsterdam; W.G. de Voogt, MD, R.G.E.J. Groutars, MD, B. Ilmer, MD, A.R. Willems, MD, J. Visser, MD, St. Lucas-Andreas Hospital Amsterdam; J.R.M. Peters, MD, Maas Hospital Boxmeer; B.J. van den Berg, MD, IJsselland Hospital Capelle a/d IJssel; F.C.W. Tietge, MD, Stichting Deventer Hospitals Deventer; L. Relik-van Wely, MD, C. de Nooyer, MD, Diaconessenhuis Hospital Eindhoven; E.M.C.J. Wajon, MD, J.C. Poortermans, MD, J.W. Louwerenburg, MD, Hospital Medisch Spectrum Twente Enschede; W.A.A.J. van Ekelén, MD, P.E. Polak, MD, St. Anna Hospital Geldrop; J.A.J. de Boo, MD, A.H. Liem, MD, H.W.O. Roeters van Lennep, MD, Oosterschelde Hospital Goes; B. van Vlies, MD, A.J. Funke Küpper, MD, Hospital Kennemer Gasthuis Haarlem; R. Dijkgraaf, MD, St. Jansdal Hospital Harderwijk; M.F. Scholten, MD, R.R. Lalisang, MD, Elkerliek Hospital Helmond; A. Derks, MD, H.T. Droste, MD, J.H. Fast, MD, Hospital Ziekenhuisgroep Twente, location Hengelo; A.G. Boehmer, MD, Hospital Atrium Medisch Centrum Kerkrade; C.J. de Vries, MD, Hospital Medisch Centrum Leeuwarden; L.H.R. Bouwels, MD, Canisius Wilhelmina Hospital Nijmegen; T. van der Werf, MD, J. Timmermans, MD, University Medical Center, St. Radboud, Nijmegen; D.G. de Waal, MD, Waterlandziekenhuis Purmerend; G.J. de Weerd, MD, Hospital Maasland Sittard; D.E.P. de Waard, MD, Antonius Hospital Sneek; C.L.J.M. van Engelen, MD, Hospital de Heel Zaans Medisch Centrum Zaandam; A.C. Tans, MD, Hospital het Spittaal Zutphen; W.J. Louridtz, MD, H.A. Oude Luttikhuis, MD, Isala Clinics, Zwolle.



Table 1: Age distribution and co-morbidity

Age (years) (mean)	60.3 (range 29-85)
Gender	33 M (65%) and 18 F (35%)
Age distribution	
- 20-50	16 (31%) (11 M and 5F)
- 51-70	21 (41%) (12 M and 9F)
- > 70	14 (28%) (10 M and 4 F)
Co-morbidity	
- COPD	6 (12%)
- Other non-cardiac vascular disease	5 (10%)
- Non-cardiac, nonvascular disorders	5 (10%)

COPD = chronic obstructive pulmonary disease; M = male; F = female.

Table 2: Indications for catheterization in the Dutch registry.

Indication	No. cases
Assessment of suspected coronary heart disease	24
Analysis of cardiac murmur and the presence of echocardiographic turbulent flow	9
Dyspnea and congestive heart failure	4
Risk stratification post-infarction	3
Evaluation of valvular heart disease	2
Ventricular and supraventricular arrhythmias	2
Preoperative assessment for non-cardiac surgery	2
Pathologic rest ECG	2
Prior to lung transplantation	1
Atypical chest pain	1
Congenital heart disease	1

Table 3: CAFs and angina pectoris.

No. of cases and (%)	Angina pectoris (AP)	Coronary artery disease (CAD)
16 (31.5%)	+	+
13 (25.5%)	+	-
18 (35%)	-	-
4 (8%)	-	+
Total 51 (100%)	AP+ 29 (57%)	CAD+ 20 (39%)
	AP- 22 (43%)	CAD- 31 (31%)

AP = angina pectoris; + = present; - = absent; CAF = coronary artery fistula; CAD = coronary artery disease.

Table 4: Comparison of angiographic morphology of CAFs in subgroups with or without AP in the absence of coronary artery disease.

Subgroups	AP+ CAD- (subgroup 1)			AP- CAD- (subgroup 2)							
Number of patients	13			18							
Aneurysmal formation	6			7							
Dilatation of FRA	2			3							
Number of FRA	Unilateral	Bilateral	Multilateral	Unilateral	Bilateral	Multilateral					
	12	1	-	16	1	1					
Fistulas	N=14			N=21							
Site of terminations	PA	RA	SVC	RV	P A	R A	SV C	R V	LA	LV	C S
	11	1	1	1	12	1	2	2	1	1	2
Fistula morphology											
Origin	Single		Multiple		Single		multiple				
	12		2		15		6				
Mode of termination	10			14							
Pathways	TM	TS	SS	TM	TS	SS					
	6	7	1	12	8	1					

AP = angina pectoris; + = present; - = absent; CAD = coronary artery disease; FRA = fistula-related artery; PA = pulmonary artery; RA = right atrium; SVC; superior vena cava; RV = right ventricle; LA = left atrium; LV = left ventricle; CS = coronary sinus; TM = tortuous multiple; TS = tortuous single; SS = straight single.



# Chapter 7

## **Dutch Survey of Congenital Coronary Artery Fistulas in Adults: Coronary Artery-Left Ventricular Multiple Micro-fistulas Multi-center observational survey in the Netherlands**

**S.A.M. Said  
T. van der Werf**

**Published in:  
International Journal of Cardiology 2006; 110:33-39  
Affiliated with the International Society for Adult Congenital Cardiac Disease**

Presented in part at the annual scientific meeting of the Dutch Society of Cardiology, April 2006, Amsterdam

## **Abstract**

Background: Congenital coronary artery-left ventricular multiple micro-fistulas (CA-LVMMFs) in adults are rare anomalies. They may cause angina pectoris and myocardial infarction in association with normal coronary arteries.

Methods and results: From the medical databases of a Dutch Survey of coronary artery fistulas in adult cardiology population (30.829 patients), we identified 20 patients with CA-LVMMFs out of 71 fistula-subjects between 1996 and 2003. Clinical files and individual coronary angiograms were reviewed and analysed. There were 13 females and 7 males with a mean age of 67.3 years (range 49-82). The main presenting symptoms were angina pectoris and dyspnea in 70% of the patients. The ECG showed pathologic changes in 75%. Exercise tolerance test and <sup>201</sup>thallium stress scintigraphy were positive for myocardial ischemia in 29% and 50%, respectively of the tested patients. In the absence of significant atherosclerotic coronary artery disease, ipsilateral to the fistulas, myocardial infarction was documented in 15% of the patients. Chest x-ray revealed cardiomegaly in 38% of the patients. Congestive heart failure was documented in 10% of the patients. Uni-, bi- and multilateral fistulas were present in 50%, 45% and 5%, respectively. The origin was the LCA in 71% and the RCA in 29% of the fistulas. The majority (97%) originated from the mid or distal segments of the coronary vessels. Among those patients, the coronary arterial tree had single, dual, and triple vessel disease in 25%, 15% and 5%, respectively. Angiographic anatomy precludes surgical intervention; they were all followed by conservative medical management.

Conclusions: Coronary artery-left ventricular multiple micro-fistulas are found more often in female patients. Furthermore, they originated from the distal segment of the coronary arteries. Coronary artery-left ventricular multiple micro-fistulas, in the presence of normal coronary arterial tree, may often lead to angina pectoris and coronary insufficiency.

## **Introduction**

Coronary artery fistulas (CAFs) are infrequent congenital malformations. In the majority of cases these solitary fistulas originate from one or more coronary arteries and terminate into the great veins, the right side of the heart, the coronary sinus or into the pulmonary artery.<sup>1-4</sup> In a previous publication of 51 patients with 63 solitary CAFs in only one patient a localized solitary fistula draining into the left ventricle was found.<sup>5</sup>

In contrast to these localized solitary CAFs, multiple micro-fistulas originating from one or more coronary artery fistulating into the left ventricular cavity are recognized. These arterio-arterial coronary-left ventricular multiple micro-fistulas may behave differently from the solitary fistulas.

This report deals with the clinical and angiographic characteristics of 20 patients with coronary artery-left ventricular micro-fistulas included in a Dutch Survey (DS) of coronary artery fistulas.

## **Patients and methods**

### **Design of the inquiry**

In 1996, a questionnaire was sent out to catheterization laboratories of all Dutch cardiac institutions requesting information about the occurrence of CAFs among their adult population (above 18 years of age). Patients with CA-LVMMFs from their databases were selected. Clinical, coronary angiograms and angiographic data were collected and analysed by the first author according to the method described below. Only adult patients with angiographically documented CA-LVMMFs were included in this study.

### **Patients**

Data of the patients were collected between 1996 and 2003. The coronary angiographic findings (restudied prospectively) and clinical files of 20 patients with CA-LVMMFs were reviewed from a total catheterization population of 30.829 from 28 centers (appendix 1). In

2004, a phone call was conducted to all participating centers inquiring and gathering information about mortality among the fistula population. A hundred percent response was attained for all 71 fistula patients.

### **Coronary arteriography (CAG)**

Coronary angiograms of all fistula patients, in multiple views and obliquities were performed according to the standard Judkins procedure, were re-evaluated for the arterial and venous phases. A vessel was considered to have significant stenosis if its diameter, by visual estimation, was narrowed by > 60%, with respect to the adjacent pre-stenotic segment.

#### **Description and Fistula characteristics**

The CA-LVMMFs were defined as multiple micro-communications between one or more coronary artery and the cavity of the left ventricle. These CA-LVMMFs were described according to the origin, termination and pathways. In relation to supplying “donor” coronary artery we used the following terminology regarding the number of coronary arteries which are involved in the fistula formation. Unilateral, one coronary artery is participating in the fistula formation; bilateral “dual”, two separate coronary arteries are involved in the fistulous formation; and multilateral “triple = multiple”, in which all three major coronary arteries are sharing the fistula formation.

Accumulation of the case reports and clinical series of the current world literature combined with the findings of the Dutch Survey are presented in brief (Table 3).

Statistical analysis: Data are presented as mean  $\pm$  SD, percentage or range.

## **Results**

### **Demographic characteristics**

From the database of the Dutch Registry of 30.829 patients, a total of 71 patients with coronary artery fistulas were studied, we identified 20 adult patients (13 females (65%) and 7 (35%) males with a mean age of 67.3 years, range 49-82) with CA-LVMMFs and 51 with solitary fistulas who underwent a coronary angiography between 1996 and 2003.

#### **History and physical examination**

Of these 20 patients, 12 complained of stable angina pectoris and 3 had atypical chest pain. Three patients had dyspnea of which two were presented with clinically overt congestive heart failure. Three patients were asymptomatic. In none of the patients the expected diastolic murmur was described while in seven patients a systolic murmur was heard.

#### **Non-invasive investigation**

The ECG demonstrated pathologic Q waves and signs of healed MI and ST-T segment changes in 15/20 (75%) patients. Two additional patients demonstrated left ventricular hypertrophy (LVH). One had permanent atrial fibrillation and all other patients demonstrated sinus rhythm. The chest X-ray showed cardiomegaly in 5 patients 5/13 (38%). Eleven patients underwent transthoracic Doppler echocardiography of whom one patient (1/11) depicted LVH, six had mild valvular (mitral, aortic and tricuspid) regurgitation (6/11) and one demonstrated wall motion disorders. Seven patients underwent exercise tolerance test of whom two (2/7) demonstrated myocardial ischemia. Thallium-201-exercise perfusion scintigraphy proved positive for myocardial ischemia in three (3/6) of the patients.

#### **Coronary arteriography**

Coronary angiography revealed CA-LVMMFs draining exclusively into the LV arising from one or more coronary arteries (Fig.1). After each coronary injection into the “donor” vessel, the left ventricular cavity was opacified with contrast material directly from the multiple small vessels at the endocardial surface of the left ventricle. The uni- (10x), bi- (9x), and multilateral (1x) fistulas in the 20 patients formed a total of 31 donor vessels of coronary artery fistulas. Origin, termination and pathway could be fully determined in all. All 20 patients' coronary venous drainages were visualized by the filling of the coronary sinus.

The origin of the fistula was the LAD in 16/31 (distal segment 11 and mid-distal 5), was the

Cx in 6/31 and was the RCA in 9/31 of the fistulas. All had distal origin except one Cx→LV fistula.

Eleven patients had no and 9 had atherosclerotic coronary artery disease. Of the latter, one, two and three vessel disease were recognized in 5, 3 and 1 of the patients, respectively. Left ventriculograms were obtained in two planes in 19 patients and illustrated wall motion disorders in three patients (3/19). All three have had an infarction, 2 with inferior and one with anterior localization. In 11 patients the left ventricular end diastolic pressure was assessed (11/18) and accounted as a mean of 13.6 mm Hg (range 8-23).

#### Figures and legends

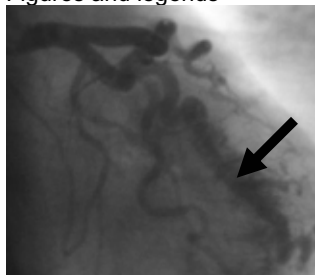

Fig. 1A

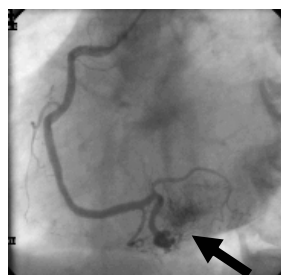


Fig. 1B

Fig. 1. (A) Frames of right anterior oblique projection of left coronary angiogram depicting the CA-LVMMFs opacifying the left ventricular cavity (arrow) originating from the mid and distal left anterior descending artery and (B) left anterior oblique projection of right coronary angiogram demonstrating the opacification of the left ventricular cavity (arrow) by multiple micro-fistulas from the distal right coronary artery.

#### Angina pectoris (AP)

Angina pectoris occurred in 12 patients (60%). Six patients who had AP had angiographically significant luminal narrowing of the coronary arterial tree; five of these had single vessel disease and one had dual vessel disease. On the contrary, in six patients with AP the coronary arterial tree was normal. Angina pectoris was defined as chest discomfort occurring spontaneously or on exertion.

#### Symptomatic patients without atherosclerotic coronary artery disease (Table 1):

Nine symptomatic patients without significant atherosclerotic coronary artery disease were further analysed in more details. The clinical presentations were angina pectoris 5x, unstable angina pectoris 1x, atypical chest pain 2x and dyspnea 1x. The ECG depicted pathologic changes in 7 and it was otherwise normal in two of the patients. They were all in sinus rhythm except one who had permanent atrial fibrillation. They were all treated medically (beta-blockers 6x, calcium antagonists 2x, anti-platelet therapy 4x and oral anticoagulation 1x).

#### Myocardial infarction (MI) (Table 2):

In our series, MI had occurred in 5 patients, 2 had anterior and 3 inferior localization. Two patients were known with an old MI (1x inferior and 1x anterior) and three patients were admitted because of an acute MI (2x inferior and 1x anterior). During follow-up period of  $62 \pm 41$  months, MI recurred in none of the patients. MI was contralateral to the shunt in 2 and was located at the same side of the fistula in 3 of the patients.

#### Treatment, follow-up and mortality:

Four patients underwent surgical (1x) or percutaneous (3x) interventions for concomitant severe obstructive coronary artery disease.

Up to 2004 after a mean follow-up period of  $62 \pm 41$  months (varying from 7-164), one death due to terminal congestive heart failure occurred in a female patient at the age of 78 years.

## Discussion

Coronary artery fistulas are considered a rare but potentially important congenital anomaly that can express itself in any age group (Table 4). In a review of 363 cases with solitary CAFs Levin and colleagues found that 3% terminated into the LV.<sup>1</sup> The true incidence of CA-LV multiple micro-fistulas is unknown. In our study, however, among a total of coronary angiographic population of 30.829 patients we found 20 out of 71 fistula patients who had these multiple micro-fistulas terminating into the LV which may be representative for the Dutch coronary angiographic population.

In agreement with previous reports, patients with CA-LVMMFs are more often female than male patients.<sup>6-10,14,15,17,19</sup> In the current study, females composed 65% of the cohort. Furthermore, it was noticed among the population of the Dutch Survey that whenever the LAD or other branches participated in the fistulous formation either as unilateral, bilateral or even multilateral mode, that the distal or mid-distal segments were nearly (97%) always the origin of CA-LVMMFs but rarely originated from the proximal segment of the vessel.

In contrast to these findings, it has been shown that solitary LAD fistulas to other intrathoracic or cardiac structures may originate from the proximal segment of the vessel.<sup>2,4,12</sup> These distal origins of CA-LVMMFs were also explicitly recognised in few reports.<sup>13-15</sup>

CA-LVMMFs may provoke angina and MI even in the absence of coronary artery disease. Most authors attributed this to "steal".<sup>6,8,13,16</sup> In the past, several attempts have been made to demonstrate the steal phenomenon.<sup>7-9,14,16</sup> This was indirectly studied by stress thallium or combined with hemodynamic studies or by assessment of cardiac metabolism utilizing coronary sinus lactate study.<sup>6-9,14,17</sup>

It is, however, unknown whether the pathophysiologic mechanisms are the same in CA-LVMMFs and the solitary fistulas. In this respect it is worthwhile to stress the observation of Shiota that these micro-fistulas had a thick muscular wall.<sup>11</sup>

In the case of CA-LVMMFs, to our knowledge, only few quantitative flow studies with exercise have been performed.<sup>9,18</sup> Oshiro and colleagues reported on an adult female patient with multilateral CA-LV micro-fistulas and normal coronary arteries.<sup>9</sup> Coronary sinus blood flow actually diminished during exercise indicating the presence of true coronary steal phenomenon by shunt of coronary arteries directly into LV lumen. Also Cottier et al performed a flow study in a symptomatic adult male with multiple left coronary artery to left ventricle micro-fistulas without obstructive coronary artery disease.<sup>18</sup> During exercise total coronary venous blood flow decreased despite an increase in cardiac output.

These findings reported by Oshiro and Cottier support the concept of a true coronary steal as the etiology for angina pectoris in patients with CA-LVMMFs associated with normal coronary arteries.<sup>9,18</sup> Thus it is conceivable that CA-LVMMFs may behave fundamentally different from the solitary coronary artery fistulas.

Clinical features of CA-LVMMFs are non-specific. According to the literature, most patients remain asymptomatic, but may develop angina and myocardial ischemia, congestive heart failure, rarely infective endocarditis, or syncope.<sup>6,13</sup> In the current series, 12/20 (60%) of the patients were presented with angina pectoris and only three patients were asymptomatic. In only 2 out of 20 patients, congestive heart failure was the presenting symptom. Ipsilateral MI was documented in three patients (2 anterior and 1 inferior). In two of these, the fistula-related artery (FRA) had significant lumen narrowing and in the third the FRA was free of atherosclerosis. Mean follow-up was more than 5 years. During this period, none of the patients developed a new or recurrent MI.

Due to the diffuse character of the anomaly conservative medical management modality and an advice for bacterial endocarditis were given. Although surgical strategy for CA-LVMMFs has sporadically been reported in the literature,<sup>19</sup> it is generally agreed that conservative medical management is the primary treatment of choice.<sup>8,20,21</sup>

### Adults with CA-LVMMFs (Dutch Survey and world literature) (Table 3):

A total of 96 fistulas (unilateral 13x (29%), bilateral 13x (29%) and multilateral 19x (42%)) were recognized in 45 adult patients collected from the world literature (n=25) and the Dutch



Survey (n=20). Female subjects formed seventy-one percent (32/45) of the whole cohort. The Multilateral fistulas were more frequently reported in case reports and small series of the world literatures (72%) than in the Dutch Survey 5%. Further details are delineated in Table 3.

Twenty-nine percent of patients were asymptomatic. In the 32 symptomatic patients, 39 complaints were reported. Among these angina pectoris was frequently recorded.

The expected diastolic murmur was heard in only one patient (2%), systolic murmur in 13 patients (29%), in more than half (56%) of the patients no audible murmur was present and the murmur was not reported in (13%).

Exercise tolerance tests were performed in 10 patients in whom 3 were positive for myocardial ischemia. Sixteen patients underwent stress thallium testing (16/45; 36%) in whom (9/16; 56%) demonstrated reversible defects.

MI was reported in 9 patients (20%). Three patients were reported to have had a non-Q-wave MI, all had normal coronary arterial tree. However, in 4 patients, no localization was reported. In 3 patients of the Dutch Survey, the MI was located at the ipsilateral and in 2 at the contralateral side of the shunt.

#### Conclusions

CA-LVMMFs although infrequent congenital anomalies, may cause angina pectoris and myocardial infarction in the absence of atherosclerotic changes. They are frequently reported in females of around fifty years of age. The fistulas originate from the mid and/or distal segments of the coronary arteries.

#### Limitations of the study:

This was a retrospective study of a limited number of patients. As expected in a survey, there is a lack of some of the data. Besides the relatively small number of patients we studied, the medication strategy was not always recorded. Prospective analysis according to a rigorous protocol including intracoronary flow measurement and assessment of venous flow drainage at rest and during provocation in a larger number of patients is needed.

#### References

1. Levin DC, Fellows KE, Abrams HC. Hemodynamically significant primary anomalies of the coronary arteries. *Circulation* 1978; 58:25-34.
2. Said SAM, El Gamal MIH. Coronary angiographic morphology of congenital coronary arteriovenous fistulas in adults: Report of four new cases and review of angiograms of fifteen reported cases. *Cath Cardiovasc Diagn* 1995; 35:29-35.
3. Yamanaka O, Hobbs RE. Coronary artery anomalies in 126,595 patients undergoing coronary arteriography. *Cathet Cardiovasc Diagn* 1990; 21:28-40.
4. Said SAM, El Gamal MIH, van der Werf T. Coronary arteriovenous fistulas. Collective Review and Management of Six New Cases- Changing Etiology, Presentation, and Treatment Strategy. *Clin Cardiol* 1997; 20:748-52.
5. Said SAM, van der Werf T. Dutch survey of coronary artery fistulas in adults: congenital solitary fistulas. *Int J Cardiol* 2006; 106:323-332.
6. Iadanza A, del Pasqua A, Fineschi M, Pierli C. Three-vessel left-ventricular microfistulization syndrome: a rare case of angina. *Int J Cardiol* 2004; 96:109-11.
7. Kawakami K, Shimada T, Yamada S, Murakami R, Morioka S, Moriyama K. The detection of myocardial ischemia by thallium-201 myocardial scintigraphy in patients with multiple coronary arterioventricular connections. *Clin Cardiol* 1991; 14:975-80.
8. Stierle U, Giannitsis E, Sheikhzadeh A, Potratz J. Myocardial ischemia in generalized coronary artery-left ventricular microfistulae. *Int J Cardiol* 1998; 63:47-52.
9. Oshiro K, Shimabukuro M, Nakada Y, Chibana T, Yoshida H, Nagamine F, et al. Multiple coronary LV fistulas: Demonstration of coronary steal phenomenon by stress thallium scintigraphy and exercise hemodynamics. *Am Heart J* 1990; 120:217-9.
10. Black IW, Loo CKC, Allan RM. Multiple coronary artery-left ventricular fistulae: Clinical, angiographic, and pathologic findings. *Cathet Cardiovasc Diagn* 1991;

- 23:133-5.
11. Shiota K, Kinoshita M, Kimura N, Kurosu H, Kuwahara K, Mori C. Multiple fistulae of coronary arteries to both ventricles. *Jpn Heart J* 1988; 29:741-6.
  12. Houghton JL, Saxena R, Frank MJ. Angina and ischemic electrocardiographic changes secondary to coronary arteriovenous fistula with abnormal basal and reserve coronary blood flow. *Am Heart J* 1993; 125:886-9.
  13. Papazoglou PD, Mitsibounas D, Nanas JN. Left anterior descending coronary artery-left ventricular fistula presenting as unstable angina and syncope. *Int J Cardiol* 2004; 96:121-2.
  14. Cheng TO. Left coronary artery-to-left ventricular fistula: Demonstration of coronary steal phenomenon. *Am Heart J* 1982; 104:870-2.
  15. Yokawa S, Watanabe H, Kurosaki M. Asymptomatic left and right coronary artery-left ventricular fistula in an elderly patient with a diastolic murmur only. *Int J Cardiol* 1989; 25:244-6.
  16. McLellan BA, Pelikan PCD. Myocardial infarction due to multiple coronary-ventricular fistulas. *Cathet Cardiovasc Diagn* 1989; 16:247-9.
  17. Ahmed SS, Haider B, Regan TJ. Silent left coronary artery-cameral fistula: Probable cause of myocardial ischemia. *Am Heart J* 1982; 104:869-70.
  18. Cottier C, Kiowski W, von Bertrab R, Pfisterer M, Burkart F. Multiple coronary arteriovenous fistulas as a cause of myocardial ischemia. *Am Heart J* 1988; 11:181-4.
  19. Berberich SN, Zager JRS, Herman PH, Eslava RL. Diffuse bilateral coronary artery fistulae entering the left ventricle: a case confirmed surgically. *Vasc Surg* 1978; 12:204-9.
  20. Chia BL, Chan ALK, Tan LKA, Ng RAL, Chiang SP. Coronary artery-left ventricular fistula. *Cardiology* 1981; 68:167-79
  21. Podolsky L, Ledley GS, Goldstein J, Kotler MN, Yazdanfar S. Bilateral coronary artery to left ventricular fistulas. *Cathet Cardiovasc Diagn* 1991; 24:271-3.
  22. Sercelik A, Mavi A, Ayalp R, Pestamerci T, Gumusburun E, Batiraliev T. Congenital coronary artery fistulas in Turkish patients undergoing diagnostic cardiac angiography. *Int J Clin Pract* 2003; 57:280-3.
  23. Ozeki S, Utsunomiya T, Kishi T, Tokushima T, Tsuji S, Matsuo S, et al. Coronary arteriovenous fistula presenting as chronic pericardial effusion. *Circ J* 2002; 66:779-82.
  24. Bauer HH, Allmendinger Ph D, Flaherty J, Owlia D, Rossi MA, Chen C. Congenital coronary arteriovenous fistula: Spontaneous rupture and cardiac tamponade. *Ann Thorac Surg* 1996; 62:1521-3.

## Appendix 1

### Participating Dutch institutions, in alphabetical order:

C.G.K.M. Fauser, MD, B.J.L. de Rode, MD, Ziekenhuisgroep Twente, location Almelo (TBA); W.G. de Voogt, MD, R.G.E.J. Groutars, MD, B. Ilmer, MD, A.R. Willems, MD, J. Visser, MD, St. Lucas-Andreas Hospital Amsterdam; L. Relik-van Wely, MD, C. de Nooyer, MD, Diaconessenhuis Hospital Eindhoven; W.A.A.J. van Ekelén, MD, P.E. Polak, MD, St. Anna Hospital Geldrop; A. Derks, MD, H.T. Droste, MD, J.H. Fast, MD, Ziekenhuisgroep Twente location Hengelo (SMT); A.G. Boehmer, MD, Hospital Atrium Medisch Centrum Kerkrade; A.C. Tans, MD, Hospital het Spitaal Zutphen.

Table 1: Symptomatic patients without coronary atherosclerosis in the Dutch Survey.

Number of patients	9		
Number of fistulas	15		
	Unilateral	Bilateral	Multilateral
	4	4	1
Fistula-related artery	LAD 8	Cx 2	RCA 5
Segment of Fistula-related artery	Mid+distal 14		proximal 1
Fistula description	Origin	Termination	Pathway
	M 14	M 14	MT 12
	S 1	S 1	SStr 2 MStr 1
Contrast ventriculogram	Normal 8		
	NA 1		

M=multiple, T=tortuous, S=single, Str=straight, NA=not available, LAD= left anterior descending coronary artery, Cx=circumflex coronary artery, RCA=right coronary artery.

Table 2: Patients with myocardial infarction reported in the Dutch Survey (n = 5) and in world literature (n = 4)

Cases	Year of myocardial infarction Normal value CK (20-88 u/l) MB (0-13 u/l)	Year of coronary angiography	Coronary artery fistula	Coronary atherosclerosis
TK,f	Recurrent 1999, Inferior (CK 105, MB 21)	February 1999	dLAD→LV	RCA
DH,f	Acute 1997, Inferior (CK 310, MB 38)	February 1997	Cx and RCA→LV	RCA
EM,f	Acute 2000, Anterior (CK 1610, MB 218)	June 2000	dLAD and RCA→LV	Cx
M,m	Acute 1992, Infero-posterior (CK 2850)	December 1996	M+dLAD and RCA→LV	LAD, Cx
D,m	Recurrent 1992, Anterior (CK 938)	January 1992	LAD→LV	LAD, Cx
[16],m	Recurrent 1989, unknown, (CK 622)	1989	LAD, Cx and RCA→LV and RV	None
[8],3f	3x Non-Q-wave myocardial infarction (CK not reported)	Not reported	LAD, Cx and RCA→LV	None

D= distal segment, m=mid-segment, LAD= left anterior descending coronary artery, Cx=circumflex coronary artery, RCA=right coronary artery, RV=right ventricle, LV=left ventricle, CK= creatine kinase, m=male, f=female.

Table 3: Congenital coronary artery-left ventricular multiple micro-fistulas in adults reported in literature and in the Dutch Survey.

Author/ reference/yr	No. of patients/ Gender/ age (yr)	Symptoms	ECG	ETT	Stress thallium	Murmur	CAD	Origin CAF	Myocardial infarction	Treatment and comments
Ahmed [17]1982	F 52 F 53	AP AP/dyspnea	N IRBBB +RVH	- -	Pos Neg	- S	- -	LAD, Cx LAD, Cx+RCA	-	Not mentioned Not mentioned
Cheng [14] 1982	F 45	AP/Palp	N	-	Pos	-	-	dLAD	-	Beta-blocker
Kawakami [7] 1991	3 F and 2 M 59±6	3x AP 2x asympt	3x path* 2x N 1x AF	-	2x Pos 3x neg	Unknow n	-	2x LAD, Cx, RCA LAD LAD, RCA LAD, Cx	-	Not mentioned
Chia [20] 1981	M 43	AP	Path	Pos	-	-	-	LAD, Cx, RCA	-	Beta-blocker
Podolsky [21] 1991	M 65	Chest pain	Path	-	-	S	1	LAD, RCA	-	Medically
Black[10] 1991	F 69	AP	Path	-	-	-	-	LAD, Cx, RCA	-	Calcium reentry blocker combined with nitrates Non-cardiac Death
McLellan [16] 1989	M 48	Chest pain Near syncope Short of breath	Path AF LVH	-	-	-	-	LAD, Cx, RCA	MI	Calcium re-entry blocker
Yokawa [15] 1989	F 62	General malaise Pretibial edema	Path	-	-	D	-	dLAD, Cx, RCA	-	Medical
Stierle [8] 1998	8 F mean	Asympt	3x	-	CSLS##	4x S	-	8x LAD, Cx,	3x MI	Medical

	51 (range 46-69)		path 5x N		Pos 6/7			RCA		
Papazoglou [13] 2004	M 59	UAP	Path	-		Unknow n	-	dLAD	-	Beta-blocker
Iadanza [6] 2004	F 55	AP	N	Neg	Pos	-	-	LAD, Cx, RCA	-	Beta-blocker
Berberich [19] 1978	F 65	AP	cLBBB	-		-	-	LAD, Cx, RCA	-	Surgery
Oshiro [9] 1990	F	AP Dyspnea	Path	Neg	Pos	-	-	LAD, Cx, RCA	-	Beta –blocker
Dutch Survey 2005	13 F and 7 M	12 AP, 1 UAP, 3 ACP 2 Dyspnea 3 asymptom atic	5 N 15 path	5 neg 2 pos 13 NA	3 neg 3 pos 14 NA	7x S 13x None	5x 1VD 3x 2VD 1x 3VD	dLAD 11, m+d LAD 5 RCA 9, Cx 6	5x MI	All medically associated with 3x PTCA and 1x CABG for concomitant atherosclerotic coronary artery disease

F=female, M=male, AP= angina pectoris, CAF=coronary artery fistula, UAP=unstable angina pectoris, ACP=atypical chest pain, ETT=exercise tolerance test, N=normal, Path=pathologic\*, Pos=positive, neg=negative, -= absent, AF=atrial fibrillation, CAD=number of atherosclerotic coronary arteries, 1VD= one vessel disease, 2VD= two vessel disease, 3VD=triple vessel disease, LCA=left coronary artery, RCA=right coronary artery, d=distal segment, m=mid segment, LAD=left anterior descending coronary artery, Cx=circumflex coronary artery, MI=myocardial infarction, LVH=left ventricular hypertrophy, RVH=right ventricular hypertrophy, S=systolic, D=diastolic, iRBBB=incomplete right bundle branch block, cLBBB=complete left bundle branch block, NA=not available.

Pathologic ECG= poor progression of “R” waves in the precordial leads, non-specific ST-T wave abnormalities and inverted T waves.

## CSLS= coronary sinus lactate study: positive for myocardial ischemia in 6/7 patient.

Table 4: Comparison between congenital coronary artery solitary and left ventricular multiple fistulas.

Item	Solitary	Multiple micro-fistula
Male: female ratio	No sex predilection	Female sex predilection exists
Manifestation	Pediatric and adulthood	Adulthood age
Incidence	0.02-2.1%	unknown
Cardiac murmur	Continuous, systolic or diastolic	Diastolic
Number of donor coronary arteries	Unilateral, bilateral, multilateral	Unilateral, bilateral, multilateral
	Arteriovenous or arteriosystemic	Arteriosystemic
Etiology	Congenital or acquired	Congenital
Pathologic anatomy	Of resected aneurysmal wall of the fistula contained both <i>arterial</i> and venous elements. No thrombus or atherosclerosis. Of resected fistula segment revealed an <i>artery</i> with mural thinning, fresh thrombus and atherosclerosis.	Multiple thin-walled <i>vesse/s</i> ranging in size from 10-500 um found 5 mm beneath the endocardium and communicated directly with the LV lumen. Multiple <i>vesse/s</i> of various diameters. The thick-walled vessels had an arterial character.
Associated cardiac anomalies	Frequent	Less frequent
Angiographic morphology of coronary arteries and fistulous pathway		
Tortuous	present	present
Aneurysm fistulous tract	present	never reported
Ectasia of coronary arteries	present	present
Origin	Proximal coronary arteries	Mid or distal coronary arteries
Termination	Any cardiac chambers and vessels	Frequently into left ventricle
Mode of termination	Single/multiple	Multiple
Type	Arterioluminal	Arterioluminal
	Arteriosinusoidal	Arteriosinusoidal
	Arteriocapillary	Arteriocapillary
Treatment	Conservative medical management	Conservative medical management
	Surgical ligation or PTE occlusion	

Abbreviations: PTE=percutaneous transluminal embolisation



# Chapter 8

**General discussion and future perspective**



Congenital coronary artery fistulas (CAFs) are increasingly recognised in the adult population.<sup>1-3</sup>

Selective coronary arteriography is mandatory for definitive diagnosis and planning of either permanent surgical repair or percutaneous occlusion by interventional procedures.<sup>4</sup>

Recently, new non-invasive diagnostic methods are reported to be used to identify congenital CAFs in adult patients. In 2004, magnetic resonance imaging (MRI) was reported to demonstrate CAFs by Parga and associates. In 2005, Datta and colleagues have reported the use of multi-detector row computed tomography (CT) angiography to delineate a congenital coronary artery fistula.<sup>5, 6</sup>

Congenital CAFs are considered the most common hemodynamically important coronary artery anomalies.<sup>7</sup> CAFs may itself cause cardiac symptoms, remain asymptomatic or may even be associated with longevity until the 8<sup>th</sup> decade of life.<sup>8, 9</sup> It is noteworthy to emphasize that the clinical course may also be secondary to fistula-related complications such as aneurysmal manifestations, rupture with hemopericardium and tamponade and distal thromboembolic events with myocardial infarction.<sup>10-14</sup>

Based on our findings of the clinical and angiographic data of the DR of congenital CAFs in adults we were able to distinguish two separate entities: 1) congenital solitary CAFs and 2) congenital coronary artery-ventricular multiple micro-fistulas (MMFs).<sup>Chapter 6 and 7</sup>

### Incidence

The true incidence of congenital CAFs will vary depending upon whether the reported series is based upon angiographic, echocardiographic studies or autopsy series.

In 2003, Serçelik and associates reviewed the world literature on the CAG incidence of CAFs and reported an incidence of 0.02-2.1% with the highest incidence observed in the Japanese population (Table 1).<sup>15, 16</sup> It is speculated that the incidence of CAFs may vary according to genetic or ethnic racial factors or either to different geographical regions or to fallacies caused by the rarity of the anomaly. In an adult population who had diagnostic CAG and cardiac catheterization, 0.1% had CAFs.<sup>17, 18</sup> In the Netherlands, we found an incidence of 0.22%.<sup>Chapter 5</sup>

Table 1: Angiographic incidence of congenital CAFs in adult population (adapted from Serçelik et al)<sup>15</sup>

Author/year	Patients	CAFs	Incidence (%)	Population
Gillebert 1986 <sup>19</sup>	14,708	20	0.13	Belgian
Yamanaka 1990 <sup>20</sup>	126,595	225	0.17	American
Bhandari 1993 <sup>21</sup>	4,886	8	0.11	Indian
Cieslinski 1993 <sup>22</sup>	4,016	1	0.02	German
Vavuranakis 1995 <sup>17</sup>	33,600	34	0.10	American
Nawa 1996 <sup>16</sup>	704	15	2.1	Japanese
Kardos 1997 <sup>23</sup>	7,694	5	0.06	Hungarian
Said 1990 <sup>24</sup>	11,000	13	0.12	Dutch
Garg 2000 <sup>25</sup>	4,100	4	0.09	Indian
Serçelik 2003 <sup>15</sup>	11,350	10	0.08	Turkish
Dutch Registry 2006 <sup>Chapter 6</sup>	33,829	71	0.21	Dutch

The reason, we believe, why Nawa et al found higher incidence of 2.1% is because their study group consisted of a mixture of fistulas where the major portion of CAFs were MMFs.<sup>16</sup> As seen in their report, the female sex was prevalent and multilaterality of fistula-related artery (FRA) terminating into the left ventricular cavity was predominant. Both are common findings in MMFs.<sup>Chapter 7</sup>

Echocardiographic studies estimated the incidence of congenital CAFs in children at 0.06 to 0.2%.<sup>26, 27</sup> In a necropsy series of pediatric and adult subjects with congenital defects of 224 coronary anomalies, 14% were found to be coronary artery fistulas.<sup>28</sup> Plausible explanation for the discrepancy in the results of various studies regarding the incidence of CAFs is the

usage of different imaging and diagnostic modalities.

The estimated mean incidence in the literature is 0.15% excluding Nawa et al. We found an incidence of 0.22% in the Netherlands,<sup>Chapter 5</sup> probably due to the low threshold for performance of CAG. Incidence is dependent on the the method used. It is speculated that the true incidence may be higher if CAG is performed in many asymptomatic patients.

### Clinical features

It has been reported that the age of the patient is significant in identifying the anomaly<sup>29</sup> and 27% of patients less than 30 years of age are asymptomatic,<sup>30</sup> furthermore, the severity of the symptoms is proportional to the size of the shunt.<sup>30</sup>

It has been stated that symptoms and complications of the fistulas may be associated with advanced age of the patients, not with the magnitude of the left-to-right shunt.<sup>31 29</sup>

In the Dutch Registry (DR)(solitary CAFs mean age 60 years, range 29-85 and MMFs mean age 67 years, range 49-82), we found that 84% and 85% of the solitary CAFs and MMFs subjects were symptomatic, respectively. Dyspnea and chest pain together represented a frequent clinical symptom in congenital solitary CAFs (77%) whilst in the MMFs group both dyspnea and chest pain accounted for 70% of the symptoms. Congestive heart failure (CHF) was more frequent (10%) in the MMFs subjects compared to 1% of solitary CAFs subjects.

### Murmur

Continuous heart murmur was the main reason for evaluation in the pediatric population. In the pediatric series of Wong and associate and of Schumacher and colleagues,<sup>32 33</sup> they found continuous murmur in 69% and 67% of the pediatric patients, respectively. In the literature, recognition of continuous heart murmur was reported in 3-70% of cases.<sup>30 34 35</sup> In the DR<sup>Chapter 6 and 7</sup> documentation of continuous heart murmur occurred in 22% of the solitary CAFs population and, as might be expected, in none of the MMFs subjects. On the other hand systolic heart murmur was documented in 25% and 35% of solitary CAFs and MMFs population, respectively. It is likely that subjects with CAFs and audible typical continuous heart murmur would have been diagnosed earlier during childhood and this would explain the low incidence of continuous murmur in adults with CAFs.

### Angina pectoris

In the solitary CAFs group of the Dutch Registry, 84% were symptomatic, angina pectoris (AP) occurred in 41 patients (58%) of the cohort. Of these, 22 (31%) had significant atherosclerotic CAD and 19 (27%) showed normal coronary arterial tree (Table 2). AP was present in 25% of the patients in the absence of coronary artery disease in the solitary CAFs group and in 30% of the MMFs subset.

In the retrospective study reported by Fernandes et al, 73% of the patients were symptomatic and 60% of the patients (age 4 days-78 years) reported AP.<sup>30</sup> It is noteworthy that also AP occurred and was a predominant symptom in the absence of atherosclerotic coronary artery disease (CAD).<sup>30</sup>

Table 2: Presence or absence of angina pectoris with or without significant coronary artery disease (CAD) in the DR cohort (n=71)

	Patients	CAD	No CAD
Angina pectoris	41	22	19
No angina pectoris	30	18	12
Total	71	40	31

For speculations regarding the cause of angina pectoris associated with CAFs please refer to the pathophysiology section of the general discussion.

### Diagnostic modalities

CAG remains the gold standard for delineating the anatomy of the involved coronary arteries and collateral circulation, the course of the fistulous tract, the receiving cardiac chamber, and

the exact communication site.

Complementary cardiovascular magnetic resonance imaging (CMR) and chest computed tomography scans have been reported to visualize congenital fistulas in some patients.<sup>2 36-40</sup>

In a subset of patients of the DR, the feasibility of CMR as a non-invasive technique to diagnose CAFs was investigated. CAFs were initially detected in ten of thirteen patients (77%) and retrospectively in two more (92%) by CMR.<sup>Chapter 4</sup> In the literature, several case reports have demonstrated the possibility of visualization of CAFs by CMR. Moreover, The CMR images improved the preoperative assessment of patients with CAFs.<sup>5 36 40</sup>

Transthoracic and transesophageal echocardiography demonstrated their ability to visualize non-invasively CAFs.<sup>41 42</sup>

Recently multi-slice computed tomography (MSCT) has been used for rapid and non-invasive visualisation of CAFs.<sup>6 43</sup>

## Angiographic morphology

### Historical overview

Historically, through the years (1966-2003) several attempts have been made to classify congenital CAFs.<sup>15 17-19 44</sup> Primary CAFs have been classified by several authors using angiographic morphology, in accordance with drainage site or mode of termination, into different types varying from 2 to 5 types. These attempts described the fistula itself neglecting the different individual components (origin, course and outflow). They were neither comprehensive nor considering the therapeutic options. Sakakibara et al 1966 (5 types)<sup>44</sup>, Iskandrian et al 1978 (2 types)<sup>45</sup>, Gillebert et al 1986 (5 types)<sup>19</sup>, Vavuranakis et al 1995 (2 types)<sup>17</sup>, Cijan et al 2000 (2 types)<sup>46</sup>, Yener et al 2001 (3 types)<sup>18</sup> and Serçelik et al 2003 (2 types)<sup>15</sup>.

In the DR, we assessed the unilaterality or multilaterality of the donor coronary arteries, described singularity or multiplicity of the origin and the outflow. Furthermore, the pathway “course” was described according to its tortuosity, singularity or multiplicity.

The distributions, characteristics and multilaterality of congenital CAFs in both solitary and MMFs subjects were not similar. In solitary CAFs, multiplicity of the origin was detected in 27% and of the outflow in 33% of the fistulas. Tortuosity of the course was found in 97% of the fistulas. Multilateral fistulas were present in 20% of the cases. Solitary CAFs are usually unilateral but can be bilateral or multilateral.<sup>17 19 Chapter 3A Chapter 6</sup> The Dutch Registry revealed 16% bilateral fistulas in the solitary subset and on the other hand 45% in the MMFs population. Bilateral fistulas of the solitary type (involving both coronary systems) are reported in 4% to 5% of patients.<sup>30 35</sup>

The impact of the morphological appearance of the different components (origin, pathway and outflow) of the fistulas on the choice of therapeutic modality was considered. The recognition of multilaterality, multiplicity and severe tortuosity of the fistula components is of practical importance, especially when a decision between percutaneous therapeutic embolisation (PTE) and surgical ligation (SL) has to be taken.

In the past decades, CAFs were classified according to drainage site (outflow)<sup>19 44 46</sup> or according to arteriographic size and morphological appearance of the fistula without extensive angiographic description of the fistula components.<sup>15 17 18 45</sup> The full description of the fistula components was given in the analysis of the DR (Table 3).

Classification of the DR.<sup>Chapter 6 and 7</sup> according to individual fistula components (origin, course and outflow) with special attention to singularity or multiplicity of the origin and the outflow and singularity, tortuosity, multiplicity of the course.

Table 3: Classification according to individual fistula components in the DR

CAFs	Origin		Course				Outflow	
Solitary <sup>Chapter 6</sup>	Single	Multiple	T/S	T/M	st/S	st/M	Single	Multiple
MMFs <sup>Chapter 7</sup>	Single	Multiple	T/S	T/M	st/S	st/M	Single	Multiple

Abbreviations: T/S=tortuous/single, T/M=tortuous/multiple, st/S=straight/single, st/M=straight/multiple.

In the DR, further description of the fistula according to: Multilaterality of the FRA, diameter of the fistulous vessel and FRA (arbitrarily small < 2, medium 2-8 and large > 8 mm) and dilatation of the FRA and aneurysmal manifestation of the fistula components.

### **Angiographic diameter of the fistula**

The actual size of the fistulous tract is rarely reported in the literature. In a report of 52 surgically treated CAFs patients, Shuiyun et al found that the angiographic mean diameter of the fistula in 43 patients with single ostium was 7.34 mm (range 1.5-18).<sup>47</sup> In two adult subjects, Duerinckx and associates performed CMR and measured the diameter of the FRA (range 10-20 mm); they recognized aneurysmal manifestation, dilatation and ectatic changes.<sup>36</sup> We found, as described in,<sup>Chapter 4</sup> a fairly good correlation between the angiographically assessed (mean 6.2 mm, range 1-16) and CMR measured (mean 6.3 mm, range 3-15) diameter of the fistulous vessels ( $r=0.72$ ). A Bland-Altman plot showed that the two methods may be used interchangeably.<sup>48 Chapter 4</sup>

### **Associated cardiac disorders**

#### **Congenital defects**

In the DR, we found that the incidence of associated congenital cardiac anomalies (primum ASD, secundum ASD, VSD, PDA 'Botalli' and persistent left superior caval vein) was 10% in the solitary CAFs group<sup>Chapter 6</sup> and less frequent in the MMFs population.<sup>Chapter 7</sup> Our findings are in agreement with the reported figures. Associated congenital cardiac anomalies have been reported in the literature in 5-40% of cases.<sup>19 30 31 34 49</sup>

#### **Pathophysiology: Coronary artery "Steal" phenomenon?**

Coronary flow reserve (CFR) signifies the quotient of coronary blood flow (CBF) under maximal dilatation, produced by physical exercise or pharmacological stimulations, and baseline CBF.<sup>50-53</sup> Basal CBF accounts to approximately 1 ml/gram of myocardial tissue/min (4-6% of total cardiac output).

The pathophysiological mechanism of coronary artery fistula is myocardial stealing or reduction in myocardial blood flow distal to the site of connection.

At rest, myocardial perfusion is adequate. Coronary artery fistulas may cause significant changes in the basal CBF. But the hypoperfusion of the distal segment of the FRA, results in dilatation (compensated steal) of the proximal segment of the FRA.

With increased myocardial work during exercise, the microvasculature dilates to increase CBF up to four or five folds basal flow.

This phenomenon has never been thoroughly investigated except by Bitar et al.<sup>53</sup> They found no evidence for "steal" phenomenon; the fistula was insensitive for intracoronary adenosine administration and the basal coronary velocity was elevated in the fistulous vessel which remained unchanged after pharmacologic stimulation.

On exertion, myocardial perfusion may be inadequate secondary to inability of the maximally dilated proximal segment of the FRA for further dilatation limiting the augmentation of CFR. Limitation of the proximal segment of the FRA of further dilatation in response to hyperemic stimulation (NO) renders the CFR unable to increment. This explanation seems the most likely to occur in CAFs.

Inadequate response of CFR to exercise-induced hyperemia and inability of CFR to increase is held responsible for the AP in CAFs.

It has also been proposed that a congenital CAFs proximal to a segment of acquired coronary atherosclerotic stenosis aggravates the distal perfusion deficit by acting as a low resistance alternative to the zone of coronary artery lesion. The occurrence of such a fistula may give rise to premature detection of concomitant moderate coronary atherosclerosis.

#### **Possible long-term complications of CAFs**

If left untreated, CAFs may result in several complications, and the incidence of complications increases with age.<sup>28 29</sup>

### **Aneurysmal manifestations**

Some aneurysms associated with CAFs may be large in the newborn period, but others gradually increase. Usually, the fistulous dilatation is uniform throughout the vessel, and it may become aneurysmal.

Earlier, aneurysms have been reported in adult subjects in 26% of fistulas (32% of the subjects).<sup>Chapter 3C</sup> Urrutia-S et al found aneurysmal manifestation in 19% of combined series of pediatric and adult patients.<sup>10</sup>

In the DR, aneurysmal manifestations were found in 35% of the solitary CAFs (mean age 60 years, range 29-85) and 5% of the MMFs (mean age 67 years, range 49-82) subjects that may reflect the influence of adult age of the cohort of the DR on these aneurysmal manifestations.<sup>Chapter 6 and Chapter 7</sup> The long-term fate of the aneurysms still has to be determined.

### **Coronary atherosclerosis**

Significant coronary atherosclerosis was defined by visual judgement as > 60% lumen narrowing with respect to the adjacent prestenotic segment. Suggestions have been made about association of fistulas with coronary atherosclerosis. About 30%-35% of congenital solitary CAFs are found in combination with coronary atherosclerosis.<sup>17 30</sup> In the DR, 39% of the solitary CAFs and 45% of the MMFs demonstrated atherosclerotic coronary artery disease (CAD).<sup>Chapter 6 and Chapter 7</sup> Since CAFs may cause significant changes in the coronary blood flow of the fistula-related coronary artery resulting in hypoperfusion, it is speculative whether the presence of congenital CAFs may induce premature or accelerate concomitant coronary atherosclerotic changes distal to the fistula. Still little is known about the pathogenetic mechanisms responsible for atherosclerosis associated with CAFs.

### **Therapeutic strategies**

#### **Historical aspects**

In 1947, Biörk and Crafoord described the 1<sup>st</sup> successful surgical repair of a coronary artery fistula.<sup>54</sup> Twelve years later, in 1959, Swan et al reported the closure of a fistula using cardiopulmonary bypass.<sup>55</sup> The first report of percutaneous therapeutic embolisation (PTE) was in 1983 when Reidy and colleagues reported the 1<sup>st</sup> successful transcatheter therapeutic fistula occlusion.<sup>56</sup>

Symptomatic fistulas can be treated by percutaneous transcatheter embolisation or suture obliteration. However, the treatment of asymptomatic lesions is controversial, with some authors advocating early surgical intervention<sup>29 34</sup> while others recommend a more conservative policy.<sup>26</sup>

The choice of treatment method depends on the anatomy and morphologic features of the fistula. In the DR (20% multilateral fistulas, multiple origins in 27% and multiple outflow in 33%, 97% tortuous course and 29% aneurysmal fistulas), 70% of the solitary CAFs subjects were treated by the conservative medical management. In 25% of the patients surgical closure was performed due to given fistula anatomy or the presence of associated cardiac disease. On the other hand, due to the high percentages of tortuous course and multiplicity of origin and outflow, percutaneous therapeutic embolisation (PTE) was considered possible in only 5% of the subjects.

However, currently surgical ligation (SL) is addressed for CAFs with multiple connections, tortuous pathways and acute angulations, complex anatomy associated with aneurysmal fistulas, distal location, large fistula with high flow, side branch at risk, and associated with other acquired cardiac diseases or congenital defects requiring surgery.<sup>57</sup>

The CAFs may be safely closed without cardiopulmonary bypass (CPB) especially when it represents the termination of a coronary artery branch. However, in the series of Urrutia-S and colleagues CPB was necessary in 57% of patients.<sup>10</sup> Surgical ligation is a widely accepted practice in symptomatic patients, but controversy exists in asymptomatic patients. The natural history of patients with CAFs is greatly variable. Many patients remain asymptomatic throughout life.

Patients remain at risk for developing endocarditis until the flow is totally abolished and

should receive antibiotic prophylaxis for any dental, gastrointestinal tract and urologic procedures.

### **Surgical ligation (SL)**

Surgical ligation of CAFs is not without risks; mortality rates are between 2 and 4% and the risk of peri-operative MI is 3.6%.<sup>58-61</sup> In the series of Liberthson et al, it has been reported that SL was performed in 69% of the subjects with an operative complication rate of 13% (MI 3%, ischemia 3%, recurrence 4%, and death 4%).<sup>29</sup> Recently, Watanabe et al demonstrated beating-heart endoscopic coronary artery surgery. These techniques have a potential for less invasive treatment of CAFs.

### **Percutaneous Therapeutic “Transcatheter” Embolisation (PTE)**

In the last decennia, PTE for closure of CAFs has become a therapeutic option for anatomically suitable vessels. Perry and Reidy in 1991 and Trehan in 2004, reported high successful closure rate of CAFs, 75%, 75% and 87% of patients, respectively.<sup>60 61 63</sup>

Factors in favour for PTE are: proximal location of the fistulous vessel, termination of the fistulous vessel away from the normal coronary arteries, older patients and absence of concomitant cardiac disorders requiring surgical intervention.<sup>64</sup>

The risks and complications associated with PTE of CAFs include coronary artery disruption with the guiding catheter or guide wire and pulmonary or systemic embolization of the occluder material, the potential complications of angiography and myocardial ischemia or infarction.<sup>65</sup>

PTE is still not widely applied, in only 5% of the solitary CAFs population.<sup>Chapter 6</sup> This might be due to the unsuitable fistula anatomy or for lack of interventional experience of catheterization laboratories.

### **Recommendations**

Once CAFs are visualised, unilaterality or multilaterality of the involved coronary arteries and the characteristics of angiographic morphology (singularity, multiplicity, tortuosity of origin, course and outflow) should be determined. When these items are stratified the treatment modality can be tailored.

As infective endocarditis may occur as an active initial manifestation, may develop in the course of the disease, or may complicate surgical intervention, antibiotic prophylaxis is advised.<sup>Chapter 6</sup>

Antiplatelet or anticoagulant therapy is recommended, as thrombo-embolic events may occur in dilated coronary arteries (10 mm)<sup>66 Chapter 6 and Chapter 7</sup> and inside aneurysmal manifestations of the fistulous vessels.

Awaiting the future data of randomized trials, the following therapeutic strategy may be currently adopted:

- Patients with CAFs and additional heart disease requiring surgery are referred for surgical repair.
- Patients with clinically significant CAFs (producing symptoms, complaints or complications) are referred for catheterization, where the fistula anatomy is further defined.
- Patients with suitable anatomy undergo PTE, while those unsuitable for PTE are offered surgical ligation or are followed up medically.

### **References**

1. Gamma R, Seiler J, Moschovitis G, Mohacsi P, Berdat P, Zürcher Zenklusen R, Tüller D, Walpoth N. Giant coronary artery fistula complicated by cardiac tamponade. *Int J Cardiol* 2006; 107:413-414.
2. Ozeki S, Utsunomiya T, Kishi T, Tokushima T, Tsuji S, Matsuo S, Natsuaki M, Ito T, Yano K. Coronary arteriovenous fistula presenting as chronic pericardial effusion.

- Circ J 2002; 66:779-782.
3. Ito M, Kodama M, Saeki M, Fukunaga H, Goto T, Inoue H, Kasuya S, Aizawa Y. Rupture of a giant saccular aneurysm of coronary arteriovenous fistulas. *Jpn Heart J* 2000; 41:659-646.
  4. Sadiq M, Wilkinson JL, Qureshi SA. Successful occlusion of a coronary arteriovenous fistula using an Amplatzer duct occluder. *Cardiol Young* 2001; 11:84-7.
  5. Parga JR, Ikari NM, Bustamante LNP, Rochitte CE, De Ávila LFR, Oliveira SA. MRI evaluation of congenital coronary artery fistulae. *Brit J Radiol* 2004; 77:508-511.
  6. Datta J, White CS, Gilkeson RC, Meyer CA, Kansal S, Jani ML, Arildsen RC, Read K. Anomalous coronary arteries in adults: Depiction at multi-detector row CT angiography. *Radiology* 2005; 235:812-818.
  7. Levin DC, Fellows KE, Abrams HL. Hemodynamically significant primary anomalies of the coronary arteries: angiographic aspects. *Circulation* 1978 58:25-34.
  8. Bauer HH, Allmendinger PD, Flaherty J, Owlia D, Rossi MA, Chen C. Congenital coronary arteriovenous fistula: Spontaneous rupture and cardiac tamponade. *Ann Thorac Surg* 1996; 62:1521-1523.
  9. Carr JF, Al-Sadir J, Jeevanandam V. Anomalous coronary to pulmonary artery fistula and aneurysm in an 86-year-old female. *J Card Surg* 2006; 21:188-190.
  10. Urrutia-S CO, Falaschi G, Ott DA, Cooley DA. Surgical management of 56 patients with congenital coronary artery fistulas. *Ann Thorac Surg* 1983; 35:300-307.
  11. Choh S, Orime Y, Tsukamoto S, Shiono M, Negishi N. Successful surgical treatment of rupture of coronary arteriovenous fistula with unconsciousness after chest and back pain. *Ann Thorac Cardiovasc Surg* 2005; 11:190-193.
  12. Habermann JH, Howard ML, Johnson ES. Rupture of the coronary sinus with hemopericardium. A rare complication of coronary arteriovenous fistula. *Circulation* 1963; 28:1143-1144.
  13. Shirai K, Ogawa M, Kawaguchi H, Kawano T, Nakashima Y, Arakawa K. Acute myocardial infarction due to thrombus formation in congenital coronary artery fistula. *Eur Heart J* 1994; 15:577-579.
  14. Dichtl W, Waldenberger P, Pachinger O, Müller S. An uncommon coronary artery fistula causing survived sudden cardiac death in a young woman. *Int J Cardiovasc I* 2005; 21:387-390.
  15. Serçelik A, Mavi A, Ayalp R, Pestamalci T, Gümüşburun E, Batiraliiev T. Congenital coronary artery fistulas in Turkish patients undergoing diagnostic cardiac angiography. *Int J Clin Pract* 2003; 57:280-283.
  16. Nawa S, Miyachi Y, Shiba T, Toshino N, Hayashi K, Tamesue K, Yamamoto H, Ota T, Shimizu N. Clinical and angiographic analysis of congenital coronary artery fistulae in adulthood. *Jpn Heart J* 1996; 37:95-104.
  17. Vavuranakis M, Bush CA, Boudoulas H. Coronary artery fistulas in adults: Incidence, angiographic characteristics, natural history. *Cathet Cardiovasc Diagn* 1995; 35:116-120.
  18. Yener N, Yener A. Another cause of chest pain: coronary artery-pulmonary artery fistulae. *Int J Angiol* 2001; 10:85-87.
  19. Gillebert C, Van Hoof R, Van de Werf F, Piessens J, De Geest H. Coronary artery fistulas in an adult population. *Eur Heart J* 1986; 7:437-443.
  20. Yamanaka O, Hobbs RE. Coronary artery anomalies in 126,595 patients undergoing coronary arteriography. *Cathet Cardiovasc Diagn* 1990; 21:28-40.
  21. Bhandari S, Kanojia A, Kasliwal RR, Kler TS, Seth A, Trehan N, Bhatia ML. Coronary artery fistulae without audible murmur in adults. *Cardiovasc Interven Radiol* 1993; 16:219-223.
  22. Cieslinski G, Rapprich B, Kober G. Coronary anomalies: incidence and importance. *Clin Cardiol* 1993; 16:711-715.
  23. Kardos A, Babai L, Rudas L, Gaál T, Horváth T, Tálósi L, Tóth K, Sárváry L, Szász K. Epidemiology of congenital coronary artery anomalies: a coronary arteriography study on a central European population. *Cathet Cardiovasc Diagn* 1997; 42:270-275.

24. Said SAM, Landman GHM. Coronary-pulmonary fistula: long-term follow-up in operated and non-operated patients. *Int J Cardiol* 1990; 27:203-210.
25. Garg N, Tewari S, Kapoor A, Gupta DK, Sinha N. Primary congenital anomalies of the coronary arteries: a coronary angiographic study. *Int J Cardiol* 2000; 74:39-46.
26. Sherwood MC, Rockenmacher S, Colan SD, Geva T. Prognostic significance of clinically silent coronary artery fistulas. *Am J Cardiol* 1999; 83:407-411.
27. Hsieh KS, Huang TC, Lee CL. Coronary artery fistulas in neonates, infants, and children: Clinical findings and outcome. *Pediatr Cardiol* 2002; 23:415-419.
28. Ogden JA. Congenital anomalies of the coronary arteries. *Am J Cardiol* 1970; 25:474-479.
29. Libერთson RR, Sagar K, Berkoben JP, Weintraub RM, Levine FH. Congenital coronary arteriovenous fistula. Report of 13 patients, review of the literature and delineation of management. *Circulation* 1979; 59:849-854.
30. Fernandes ED, Kadivar H, Hallman GL, Reul GJ, Ott DA, Cooley DA. Congenital malformations of the coronary arteries: The Texas Heart Institute experience. *Ann Thorac Surg* 1992; 54:732-740.
31. Shyam Sunder KR, Balakrishnan KG, Tharakan JA, Titus T, Pillai VRK, Francis B, Kumar A, Bhat A, Shankaran S. Coronary artery fistulas in children and adults: a review of 25 cases with long-term observations. *Int J Cardiol* 1997; 58:47-53.
32. Wong K, Menahem S. Coronary arterial fistulas in childhood. *Cardiol Young* 2000; 10:15-20.
33. Schumacher G, Roithmair A, Lorenz HP, Meisner H, Sauer U, Müller KD, Sebening F, Bühlmeyer K. Congenital coronary artery fistula in infancy and childhood: Diagnostic and therapeutic aspects. *Thorac Cardiovasc Surg* 1997; 45:287-294.
34. Hobbs RE, Milit HD, Raghavan PV, Moodie DS, Sheldon WC. Coronary artery fistulas: A 10 year review. *Clevel Clin J Med* 1982; Q49:191-197.
35. Liotta D, Hallman GL, Hall RJ, Cooley DA. Surgical treatment of congenital coronary artery fistula. *Surgery* 1971; 70:856-864.
36. Duerinckx AJ, Shaaban A, Lewis A, Perloff J, Laks H. 3D MR imaging of coronary arteriovenous fistulas. *Eur Radiol* 2000; 10:1459-1463.
37. Sato Y, Mitsui M, Takahashi H, Miyazawa T, Okabe H, Inoue F, Kusama J, Horie T, Matsumoto N, Hori Y, Furuhashi S, Takahashi M, Kanmatsuse K. A giant left circumflex coronary artery-right atrium arteriovenous fistula detected by multi-slice spiral computed tomography. *Heart Vessels* 2004; 19:55-56.
38. Murata N, Yamamoto N. A case of ruptured coronary artery aneurysm associated with coronary artery fistulas. *Jpn J Cardiovasc Surg* 2001; 30:305-307.
39. Misumi T, Nishikawa K, Yasudo M, Suzuki T, Kumamaru H. Rupture of an aneurysm of a coronary arteriovenous fistula. *Ann Thorac Surg* 2001; 71:2026-2027.
40. Burns KEA, Ferguson KA, Spouge A, Brown JE. Massive congenital coronary arteriovenous malformation presenting with exertional dyspnea and desaturation in an adult: A case report and review of the literature. *Can J Cardiol* 2001; 17:85-89.
41. Rangasetty UC, Ahmed M. Giant coronary artery fistula with aneurysm and multiple openings: a two-dimensional echocardiographic evaluation. *Echocardiography* 2006; 7:611-613.
42. Lida R, Yamamoto T, Kondo N, Suzuki T, Saeki S, Ogawa S. Identification of the site of drainage of left main coronary artery to right atrium fistula with intraoperative transesophageal echocardiography. *J Cardiothorac Vasc Anesth* 2005; 6:777-780.
43. Tan KT, Chamberlain-Webber R, McGann G. Characterisation of coronary artery fistula by multi-slice computed tomography. *Int J Cardiol* 2006; 111:311-312.
44. Sakakibara S, Yokoyama M, Takao A, Nogi M, Gomi H. Coronary arteriovenous fistula. *Am Heart J* 1966; 72:307-14.
45. Iskandrian AS, Kimbiris D, Bemis CE, Segal BL. Coronary artery to pulmonary artery fistulas. *Am Heart J* 1978; 96:605-09.
46. Cijan A, Zorc-Pleskovič R, Zorc M, Klokočovnik T. Local pulmonary malformation caused by bilateral coronary artery and bronchial artery fistulae to the left pulmonary



- artery in a patient with coronary artery disease. *Tex Heart Inst J* 2000; 27:390-394.
47. Shuiyun W, Qingyu W, Shengshou H, Jianping X, Lizhong S, Yunhu S, Feng L. Surgical treatment of 52 patients with congenital coronary artery fistulas. *Chin Med J* 2001; 114:752-755.
  48. Bland JM, Altman DG. Statistical methods for assessing agreement between two methods of clinical measurement. *Lancet* 1986; 1:307-310.
  49. Upshaw CB. Congenital coronary arteriovenous fistula. Report of a case with an analysis of 73 reported cases. *Am Heart J* 1962; 63:399-405.
  50. Reitz BA, Harrison LH Jr., Michaelis LL. Experimental coronary artery fistula. *Thorac Cardiovasc Surg* 1975; 69:278-282.
  51. Theman TE, Crosby DR. Coronary artery steal secondary to coronary arteriovenous fistula. *Can J Surg* 1981; 24:231-236.
  52. Houghton JL, Saxena R, Frank MJ. Angina and ischemic electrocardiographic changes secondary to coronary arteriovenous fistula with abnormal basal and reserve coronary blood flow. *Am Heart J* 1993; 125:886-889.
  53. Bitar SR, Aguirre FV, McBride L, Munroe C, Kern MJ. Characterization of intra-arterial flow velocity within left coronary to pulmonary artery fistula. *Cathet Cardiovasc Diagn* 1997; 41:208-212.
  54. Biörck G, Crafoord C. Arteriovenous aneurysm on the pulmonary artery simulating patent ductus arteriosus botalli. *Thorax* 1947; 2:65-74.
  55. Swan H, Wilson JN, Woodwark MB, Blount SG. Surgical obliteration of a coronary artery fistula to right ventricle. *AMA Arch Surg* 1959; 79:820.
  56. Reidy JF, Sowton E, Ross DN. Transcatheter occlusion of coronary to bronchial anastomosis by detachable balloon combined with coronary angioplasty at same procedure. *Br Heart J* 1983; 49:284-287.
  57. Gelsomino S, Rubattu G, Terrosu PF, Cossu L, Orrù F, Barbosa G. Successful repair of a coronary artery to pulmonary artery fistula with saccular artery aneurysm and critical stenosis of the left anterior descending coronary artery. *Ital Heart J* 2003; 4:350-353.
  58. Wilde P, Watt I. Congenital coronary artery fistulae: six new cases with a collective review. *Clin Radiol* 1980; 31:301-311.
  59. Kirklin JW, Barrat-Boyes BG. *Cardiac Surgery*. New York: John Wiley, 1986:945-955.
  60. Perry SB, Keane JF, Lock JE. Pediatric intervention. In: Grossman W, Baim DS, editors. *Cardiac catheterization, angiography, and intervention*. Philadelphia: Lea & Febiger, 1991:543-544.
  61. Reidy JF, Anjos RT, Qureshi SA, Baker EJ, Tynan MJ. Transcatheter embolization in the treatment of coronary artery fistulas. *J Am Coll Cardiol* 1991; 18:187-192.
  62. Watanabe G, Takahashi M, Misaki T, Kotoh K, Doi Y. Beating-heart endoscopic coronary artery surgery. *Lancet* 1999; 354:2131-2132.
  63. Trehan V, Yusuf J, Mukhopadhyay S, Rangasetty UC, Mehta V, Gupta MD, Gambhir DS, Arora R. Transcatheter closure of coronary artery fistulas. *Indian Heart J* 2004; 56:132-139.
  64. Mavroudis C, Backer CL, Rocchini AP, Muster AJ, Gevitz M. Coronary artery fistulas in infants and children: A surgical review and discussion of coil embolization. *Ann Thorac Surg* 1997; 63:1235-1242.
  65. Al-Ata J, Amin M, Galal MO, Kouatli A, Hussain A. Transcatheter occlusion of a large left coronary artery to right superior vena cava fistula using the Amplatzer duct occluder device. *Pediatr Cardiol* 2004; 25:70-72.
  66. McMahon CJ, Nihill MR, Kovalchin JP, Mullins CE, Grifka RG. Coronary artery fistula: Management and intermediate-term outcome after transcatheter coil occlusion. *Tex Heart Inst J* 2001; 28:21-25.

## Future perspectives

The current study was limited to the description of the clinical aspects and the angiographic morphological characteristics of the coronary artery fistulas (CAFs) in adult population. In this study, coronary atherosclerosis was found in combination with solitary CAFs (39%) and with MMFs (45%) in an important number of patients. Further investigation regarding this aspect, because of ethical issues, is difficult or even impossible to perform.

From our findings and other studies it seemed that a substantial part of the patients with CAFs have aneurysmal manifestation of the fistulous tract. A relevant investigation issue is to unravel the cause, long-term prognosis and the complications of such aneurysmal manifestations. This could be done non-invasively i.e. by means of CMR or echocardiographic examinations, if applicable.

A second possible investigation question is a prospective randomized (national, European or international) trial of the therapeutic options of CAFs. This could be addressed using the morphological appearances of the different fistula components (origin, course and outflow). To investigate the impact and outcome of morphological appearance on the choice of the therapeutic modality.

A third interesting issue is the genetic analysis of patients and their relatives in order to get more insight into CAFs and for improvement of possible earlier diagnosis and treatment.

A last question remains the influence of pre-intervention invasively (Doppler velocity wire) or non-invasively (CMR) determination of, in relation to symptoms and shunt magnitude, the hemodynamic consequences of the CAFs so that the choice of the therapeutic modalities could be established (surgical or PTE).



# Chapter 9

## Summary and conclusions

### Chapter 1

Chapter 1 gives the scope of this thesis which is obtaining a systematic description of coronary artery fistulas (CAFs) in an adult Dutch coronary angiographic population. Therefore a Dutch Registry for patients with angiographically documented CAFs was initiated and developed. By this registry we were able to describe among others the current clinical pictures and coronary angiographic morphological aspects of 71 adult Dutch patients.

### Chapter 2

In Chapter 2, a general introduction and a comprehensive review of the recent literature is presented focusing on the prevalence, pathogenesis, symptomatology and clinical picture, non-invasive and invasive diagnostic approach, angiographic morphology of CAFs and treatment strategies of patients with CAFs. A systematic analysis of CAFs or a randomized study regarding therapeutic modalities is still lacking.

### Chapter 3

Prior to the initiation of the Dutch Registry (DR) a total of 43 patients with specific clinical and coronary angiographic features of CAFs are presented. They were unrelated to the population of the DR. The clinical features, diagnostic tests and management of congenital and acquired CAFs (**3A and 3B**) and coronary angiographic morphological aspects of congenital and acquired fistulas associated with aneurysmal formation are presented (**3C and 3D**). The findings were compared to these of the literature.

Acquired CAFs are defined as a direct communication of a coronary artery with a cardiac chamber, provided that cardiac or coronary intravascular 'iatrogenic or spontaneous' procedure/event or thoracic trauma (penetrating or non-penetrating) has taken place, especially when extravasation of contrast is visible from the coronary artery into or in the vicinity of a cardiac chamber.

In **Chapter 3A**, the clinical picture, etiology and management of six own patients with congenital coronary artery fistulas (CAFs) and 76 review subjects with 96 congenital and acquired fistulas are described and compared to cases from the literature. In our own six patients, the CAFs were of a congenital etiology. Four patients were treated with conservative medical management (CMM). One patient underwent surgical ligation combined with coronary artery bypass grafting (CABG) for concurrent significant obstructive coronary artery disease (CAD) and in the other; percutaneous therapeutic "transcatheter" embolisation (PTE) was performed complicated with inferolateral myocardial infarction due to distal migration of the coil into the fistula-related coronary artery (FRA).

The pathogenesis, the clinical presentation and management of 76 subjects with 96 congenital and acquired CAFs taken from a review of the recent literature (1985-1995) were compared with a review by Rittenhouse published in the mid seventies. In the current review, the etiology of CAFs demonstrated an acquired pathogenesis; in 64% of the review subjects the CAFs were congenital in origin, and in 36% it had an acquired etiology; the clinical pictures of the review subjects were chest pain (anginal and atypical) 34%, congestive heart failure 13% and asymptomatic 55%. Seventy-eight percent (78%) of these subjects were treated medically, with one fatality. Surgical ligation of the CAFs was achieved in 10% and

PTE occlusion of the fistulous communication was performed in 12% of the review subjects. Based on the comparison with the review of Rittenhouse, it is concluded that the pathogenesis of CAFs has a tendency toward the acquired etiology and PTE techniques are being increasingly used as a treatment modality for CAFs.

The etiology of CAFs is changing adding acquired causes in 36% ( $p$  0.0000) of the review subjects (3A). Formerly, two decades ago the congenital etiology was 100%.

Chest pain (anginal or atypical) accounted for 34% ( $p$  0.0000); congestive heart failure (CHF) for 13% and asymptomatic presentation was found in 55% of the review subjects (3A). The trend toward increasing chest complaints compared with earlier finding (Rittenhouse, 1975) may be due to a higher mean age, and hence increased concomitant coronary artery disease due to aging among the current review subjects.

Coronary cameral fistulas (CCFs), congenital or acquired, are defined as fistulas terminating into one of the four cardiac chambers; the origin from the vessel segment may be single or multiple by uni-, bi- or multilateral coronary arteries. In contrast, congenital coronary artery-ventricular multiple micro-fistulas fistulate (MMFs) with multiple small channels terminate mainly into the left and to lesser extent into the right ventricular cavities; the origin is multiple from the mid-distal vessel segment by uni-, bi- or multilateral coronary arteries.

In **Chapter 3B**, we studied the clinical and angiographic findings of seven adult patients with acquired coronary cameral fistulas (CCFs) associated with significant coronary atherosclerosis (5 patients) and sustained myocardial infarction (2 patients). None of these patients underwent a therapeutic endovascular procedure prior to detection of the fistula. Significant narrowing of the FRA was found in 4 patients and total occlusion of the FRA in 3 patients. Well developed collaterals were demonstrated in 4 patients and were angiographically undetected in three patients. Myocardial infarction was localized in the same territory of the FRA in three patients. In the current series, two patients were treated medically, CABG was performed in three, and one patient underwent percutaneous transluminal coronary angioplasty (PTCA) for concurrent stenosis of non-fistula-related coronary artery and one patient died while awaiting CABG.

Thirty-four adult subjects with acquired CCFs were collected from the literature (1971-1996). The CCFs represented various pathogenetic etiologies. The management of these review subjects was comparable to our series. Eighteen percent (18%) of the review subjects demonstrated spontaneous closure of the CCFs.

It may be concluded that acquired CCFs may complicate the course of severe coronary atherosclerosis or myocardial infarction and considered as collaterals losing their final destination to the jeopardized myocardial segment. The mechanisms responsible for the development of these fistulous communications are discussed. The symptomatology, the distribution of the involved coronary arteries and therapeutic modalities are comparable in the congenital and acquired types. An unanswered question is whether patients with acquired CCFs require antibiotic prophylaxis as recommended in congenital fistulas.

In **Chapter 3C**, the angiographic morphological aspects of congenital CAFs in an adult population of 19 patients are presented. The morphologic appearance of the fistulas showed wide variability from a small discrete single channel to highly complex plexiform network with a maze of fine vessels. In this series, the origin composed of a single channel in 70% and of multiple fine vessels in 30% of the fistulas; the outflow was via a single channel in 65%, via an aneurysm in 22% and via multiple plexiform network in 13% of the fistulas. Ipsilateral myocardial infarction (MI) to the fistulous connection occurred in one patient. In this patient, the origin, outflow and pathways of the fistula were composed of multiple channels. Aneurysms were present in 26% of fistulas. Aneurysmal fistulas involved solely the pathway and/or the outflow, but never originated from the proximal part of the fistulous vessels. The angiographic diagnostic criteria are discussed.

Congenital solitary CAFs are often associated with aneurysms of the fistulous vessels.

In **Chapter 3D**, a description of coronary angiographic characteristics in 10 patients with acquired (4 patients) aneurysms and aneurysms (6 patients) associated with congenital CAFs is presented. The mean age of the acquired group (64.7 yrs) was higher compared

with the congenital group (52.5 yrs). Ipsilateral MI was predominant in the acquired group (75%). It was found that the aneurysm predilection site was the proximal part of the aneurysm-bearing vessel in the congenital group. While in the acquired group, it was found along the entire length of the aneurysm-bearing vessel. The congenital aneurysms were solitary and sizeable but the acquired aneurysms were multiple and frequently associated with recurrent vascular complications and coronary events. In the congenital group, all the aneurysms were of the saccular type and in the acquired group this accounted for 71%. In the acquired group, all patients had associated significant narrowing of the coronary arterial tree, but half of the patients of the congenital group demonstrated severe atherosclerotic CAD.

The number of patients is limited to draw conclusions, larger series of patients with coronary aneurysms are required to delineate further issues of angiographic characteristics of acquired and congenital aneurysms, differentiation between both types and appropriate treatment strategies.

#### **Chapter 4**

Cardiovascular magnetic resonance (CMR) is a new promising method for cardiovascular diagnosis. We anticipated that CMR not only might provide comprehensive anatomical data concerning the fistulas, but also a number of valuable physiological parameters. Therefore we evaluated the feasibility of CMR of angiographically (gold standard) detected congenital solitary CAFs in 13 adult patients (14 fistulas) of the Dutch Registry (DR). All patients gave written informed consent. The CMR diagnosis initially confirmed the presence of CAFs in 10 patients (77%). After revision of CMR images, 2 more additional patients were recognized. In almost all pts, origin, pathways and outflow of the fistula could be determined. Tortuosity of the pathways was specified in 12/13 pts. Singularity or multilaterality was proven in all pts, aneurysmal manifestation in 3 out of 4 and dilatation of the fistula-related artery in all. CMR demonstrated capability of detecting tortuosity (79%) and multiplicity (57%) of pathways and multiplicity (93%) of the origin of the fistulas.

Additional CMR data regarding flow measurements could be assessed in 8 pts. Average velocity was 10 cm/s (range 1.2-36); the mean flow through the fistula was 0.55 l/min (range 0.02-3.8). The mean CMR diameter of the fistulous vessels was 6.3 mm (range 3-15) compared to the angiographic assessed diameter of 6.2 mm (range 1-16). A fairly good correlation was found ( $r=0.72$ ). The duration between CAG and CMR ranged from 1-112 months with a mean of 25 and a median time lag of 3.

Failure to identify the fistula in one of the patients may be attributed to the small size of the fistulous vessel (1 mm) which may be clinically irrelevant.

CMR is becoming an important non-invasive method of detecting and diagnosing the morphological and physiological aspects of the CAFs but it remains a time consuming activity.

#### **Chapter 5**

A brief reasoning is given to advocate the need for a Dutch Registry of congenital CAFs in adults.

In the Netherlands, the current angiographically diagnosed congenital CAFs in an adult population are presented. The exact prevalence of CAFs is unknown. In 1994, a questionnaire was sent out to all Dutch coronary angiographic centres to answer questions about prevalence of CAFs. The response rate of these centres was 43%. Of the respondent centres, 48% reported to have CAFs. The figures of CAFs and total numbers of CAG were provided from 78% of the respondents. In this survey, the prevalence of CAFs was 0.22% which corresponded well with the figures in the literature.

Appendices of case report forms (I) and participating Dutch cardiac centers (II) are given.

#### **Chapter 6**

Congenital coronary artery fistulas may be divided into two main types; solitary (mainly arteriovenous) or multiple (mainly arteriosystemic). The angiographic morphology of origin,

outflow and pathways differ accordingly. Their clinical behaviour and gender predilection are not similar. The results of the Dutch Registry for these two types are outlined; congenital solitary CAFs in adults (chapter 6) and congenital CA-VMMFs in adults (chapter 7).

In Chapter 6, data of 51 patients (33 males (65%) and 18 females (35%)) with a mean age of 60.3 years (range from 29-85 yrs) included in the Dutch Registry with congenital solitary CAFs were collected from 28 cardiac centers of 30.829 diagnostic coronary angiographic patients. All CAFs were congenital in origin and the majority were not associated with other congenital cardiac anomalies. Associated congenital heart disease was found in 10% of the patients.

Sixty-nine percent of the patients were in the age distribution group of >50 years and 31% were in the age group from 20-50 years. At the time of diagnosis, 16% were asymptomatic and 84% of the patients were symptomatic. Angina pectoris, dyspnea, fatigue and palpitation were among the clinical presentation.

On auscultation of the heart, typical continuous cardiac murmur was heard in 22% of the patients. Myocardial infarction (MI) had occurred in 8 patients of the DR. Ipsilateral MI was found in 1 patient, in whom a relation was found between the FRA branch and the infarct-related artery.

The ECG demonstrated pathologic changes (ST-T segment abnormalities, pathologic Q waves, left ventricular hypertrophy and healed MI) in 57% of the patients. Chest roentgenogram showed cardiac abnormalities in 13 patients; of these nine demonstrated cardiomegaly.

In this database, all 51 patients had 63 CAFs; of these 41 were unilateral (80%), 8 bilateral (16%) and 2 multilateral (4%). In the current angiographic series, the aneurysms of the fistulous communications were clearly visible in 29% of the fistulas i.e. 35% of the patients.

We described two different morphological types of the origin and outflow of the CAFs. Furthermore, three different morphological types were identified specifically for the fistulous pathways. In the series of the DR, we found that 73% of the origin composed of single channel and 27% of multiple channels, regarding the outflow this was 67% and 33%, respectively. Considering the pathways, 56% delineated tortuous/multiple fine channels, 41% tortuous/single channel and straight with single solitary channel in 3% of the fistulas.

The treatment of the subjects in the DR was conservative medical management in 36 cases (70%). Only 5 patients were followed-up with watchful waiting strategy and 31 patients were treated medically (beta blockers, calcium reentry blockers and nitrates). Surgical procedures were performed in 13 patients (25%) and percutaneous therapeutic embolization was utilized in 2 patients. Among the DR population, cardiac mortality was 4% during a mean follow-up of 5 years.

## **Chapter 7**

Congenital Coronary Artery-Ventricular Multiple Micro-Fistulas (MMFs) in adults are infrequent anomalies defined as multiple micro-fistulation from one or more coronary arteries draining into the ventricular cavities. The true incidence is unknown. This report deals with the clinical and angiographic findings of patients with such anomaly. We identified 20 adult patients with (n=31) congenital Coronary Artery-Ventricular Multiple Micro-Fistulas (MMFs) from the database of the Dutch registry out of 71 fistula subjects between 1996 and 2003 from a total coronary angiographic population of 30.829 (from 28 Dutch catheterization units). Patient's clinical data (patient's characteristics, clinical presentation, physical examination, reason for angiography, non-invasive and invasive examinations, treatment and follow-up) were reviewed and the individual coronary angiographic studies were independently re-analysed for fistula description (number of donor coronary arteries, origin, pathway, outflow of the fistula, dilatation of the fistula-related artery and of ventricular cavity) and extent of atherosclerotic CAD. A vessel was considered to have significant stenosis if its diameter, by visual estimation was severely narrowed, with respect to the adjacent pre-stenotic segment. Contrary to solitary types, the origin of MMFs was found at the mid and/or distal segment of the FRA.

The mean age was 67.3 years (range 49-82). Females accounted for 65% (13/20) of the

multiple micro-fistula population. Three patients had no symptoms and 17 were symptomatic. Stable angina pectoris was the presenting symptom in 12, atypical chest pain in three and congestive heart failure in 2 of the patients. Angina pectoris and dyspnea together occurred in 70% of the patients. Angina pectoris and myocardial infarction occurred in association with congenital MMFs and normal epicardial coronary arteries. The theoretically expected diastolic murmur was reported to be absent while systolic murmur was found to be audible in 7 patients.

The ECG depicted pathologic Q-waves and signs of healed myocardial infarction (MI) and ST-T segments abnormalities in 15/20 patients. Chest X-ray demonstrated cardiomegaly in 5/13 patients. Distal origin of the fistula from the coronary artery was found in all except one. Atherosclerotic CAD was found in 9/20 patients. Five patients developed MI, anterior localization in two and inferior in three. Two were known with an old MI and three presented with new MI. The MI was ipsilateral in three and contralateral to the shunt in two. All fistula patients were treated medically. At follow-up of  $62\pm 41$  months, one patient died secondary to CHF at the age of 78 years and none developed recurrent or new MI.

MMFs may cause angina pectoris and to a lesser extent myocardial infarction in the absence of atherosclerotic changes. The fistulas originate from the mid and/or distal segments of the coronary arteries. The typical patient is a female subject of approximately fifty years of age presenting with angina pectoris, without audible cardiac murmur and inconclusive non-invasive diagnostic tests that is analysed for suspected obstructive CAD. The pathophysiology still has to be elucidated.

The diffuse character of the fistulous communications renders it neither amenable for percutaneous therapeutic "transcatheter" embolisation (PTE) nor surgical ligation (SL) but for conservative medical treatment (CMM).

## **Conclusions**

### **Chapter 3A**

Changing etiology, clinical picture and treatment strategy of congenital CAFs: Since the increased use of diagnostic and therapeutic endovascular procedures and the improvement of non-invasive and invasive diagnostic modalities, acquired CAFs are being more detected and reported.

Asymptomatic presentation of acquired CAFs was reported in 55% of the patients. Prior to 1983 all patients were treated either surgically or medically. Percutaneous transcatheter "therapeutic" PTE techniques are being increasingly used in the management of CAFs; this was found in 12% of the review subjects.

### **Chapter 3B**

The distribution of involvement of the right and left coronary arteries is equally divided in both the congenital and acquired CAFs.

Acquired CAFs manifested as coronary cameral fistulas (CCF) may complicate the course of severe atherosclerosis or MI in adults and that they may be considered as collaterals losing their destination to the jeopardized myocardial area. The clinical features and treatment strategy is comparable in the congenital and acquired CAFs.

### **Chapter 3C**

With regard to the morphological aspects of CAFs and its relation to the choice of the treatment option: Multiplicity of the origin of CAFs was found in 30% and multiplicity with aneurysms of the outflow in 35% of cases. Furthermore, these aneurysms involved the pathway and/or the outflow but never the origin of the fistulous tracts.

The angiographic diagnostic criteria of congenital CAFs are: (1) The FRA is usually tortuous and markedly dilated; (2) The contrast medium is seen clearly spurting into the affected cardiac chamber or great intrathoracic vessel.

### **Chapter 3D**

A comparison was made between the angiographic morphologic characteristics and clinical pictures of four patients with acquired coronary artery fistulas (acquired group) versus six patients with congenital aneurysmal fistulas (congenital group): Ipsilateral MI occurred in  $\frac{3}{4}$  of the acquired and in none of the congenital group. The aneurysm predilection site was



proximally located in the congenital group compared to the diffuse multiple aneurysmal manifestation along the whole length of the involved coronary artery in the acquired group.

#### **Chapter 4**

In a feasibility study, cardiovascular magnetic resonance (CMR) was able to detect congenital CAFs in adults in 85% of the patients with angiographically proven CAFs. CMR was able to detect congenital CAFs in adults in 85% of the patients with angiographically proven CAFs. On the basis of our own experience, some criteria for identification of the fistula by CMR may be suggested when clinical suspicion is raised.

##### **Anatomical assessment:**

Assessment of unilateral as well as multilateral fistulous vessels entering into the outflow site. Identification of the fistulous jet within the entry site. Demonstration of the presence or absence of a dilated donor coronary artery.

##### **Physiological assessment:**

Signal loss (flow void) which is detected when an influxing jet of turbulent flow in 2 perpendicular planes (e.g. transversal and sagittal) is seen waxing and waning into the recipient cardiac chambers or great thoracic vessels.

#### **Chapter 5**

In the Netherlands, the incidence of CAFs was 0.22% which corresponded well with the figures in the literature.

#### **Chapter 6**

**Solitary CAFs:** There is no gender predilection for the solitary CAFs. They may be manifested in any age group. CAFs may be arteriovenous or arteriosystemic.

Angina pectoris occurred in 25% of cases in the absence of CAD. Significant coronary artery disease (CAD) was present in 39% of cases. Myocardial infarction associated with CAFs is rare.

Aneurysmal fistulas occurred in 35% of cases (29% of CAFs). The proximal segment of the coronary artery was responsible for the development of the fistula in the overwhelming majority of the patients.

Unilateral CAFs were predominant (80%). The origin of CAFs showed multiple fistulous tracts in 27% of cases. The outflow was multiple in 33% of cases. Tortuosity of the pathway was found in 97% of the subjects. As treatment modality conservative medical treatment (CMM) was applied in 70%, and permanent occlusion was achieved by surgical ligation in 25% and by percutaneous transcatheter embolisation (PTE) in 5%.

Congenital coronary artery fistulas (CAF) and atherosclerotic coronary artery disease (CAD) often coexist in adult subjects.

#### **Chapter 7**

**Coronary artery-ventricular multiple micro-fistula (MMFs):** In MMFs female sex predilection exists (65%). They are manifested in adulthood. MMFs (arteriosystemic fistulas) behave differently from the solitary CAFs. In contrast to the solitary CAFs, the mid or distal segments of the donor coronary arteries were responsible for the fistulation in 97% of the MMFs patients. Angina pectoris and dyspnea accounted for 70% of the clinical features. MMFs were responsible for angina pectoris which occurred in the absence of CAD in 30% of the patients. Conservative medical treatment (CMM) is the only available therapeutic strategy.

# Chapter 10

## Samenvatting

Hoofdstuk 1, geeft het doel van dit proefschrift aan, welke de systematische beschrijving van congenitale coronaire fistels bij volwassen patiënten behelst. Hiervoor werd een landelijke registratie (Dutch Registry) voor patiënten met gedocumenteerde congenitale coronaire fistels (CAFs) opgezet. In deze registratie werden onder andere de huidige klinische presentaties en coronaire angiografisch morfologische aspecten van de geïnccludeerde patiënten beschreven.

Hoofdstuk 2, omvat vervolgens een algemene introductie en een uitgebreid overzicht van recent gepresenteerde literatuur. Deze is gefocust op de incidentie, etiologie, symptomatologie en klinische presentaties, op bevindingen bij het lichamelijke onderzoek, diagnostische mogelijkheden, coronaire angiografische morfologie en behandeling strategieën van patiënten met coronaire fistels. Het merendeel van de gegevens uit de literatuur beschrijft case reports of een compilatie van enkele gevallen. Tot op heden ontbreken systematische studies of gerandomiseerde trials voor wat betreft de behandeling van congenitale CAFs.

In hoofdstuk 3A, worden de klinische gegevens, de diagnostiek en de behandeling van zes patiënten beschreven en vergeleken met de bevindingen in de literatuur. Dit vond plaats vóórdat er sprake was van de Dutch Registry. De coronaire fistels bij deze zes patiënten, hadden allen een congenitale etiologie. Vier van deze patiënten werden volgens conservatief medicamenteus beleid behandeld. Eén patiënt onderging chirurgische ligatie van de fistel gecombineerd met coronair bypass operatie (CABG) wegens de aanwezige significante coronaire sclerose en bij de zesde patiënt werd een percutane transluminale embolisatie (PTE) van de coronaire fistel verricht. Deze laatste behandeling werd gecompliceerd door het optreden van een myocard infarct (MI) als gevolg van distale migratie van de coil en de afsluiting van de "fistula-gerelateerde" kransslagader.

Een literatuur-vergelijking werd verricht van de etiologie, de klinische presentatie en behandeling van 76 patiënten met 96 congenitale en verworven coronaire fistels. Dit werd gedaan op basis van nieuwe inzichten uit de literatuur beschreven, tussen 1985-1995, versus de opinie van Rittenhouse gepubliceerd halverwege de zeventiger jaren. In de huidige opvatting, toont de etiologie van coronaire fistels een tendens naar de verworven pathogenese; in 64% van de onderzochte patiënten waren de aanwezige coronaire fistels congenitaal van oorsprong en van 36% was de etiologie verworven. De klinische presentaties van de geïnccludeerde patiënten behelsde pijn op de borst (angina en atypisch) 34%, hartfalen 13% en asymptomatisch 55%. Zevenentachtig procent van de gevallen werd medicamenteus behandeld, waarvan één met fatale afloop. Chirurgische ligatie van de coronaire fistels werd bereikt in 10% van de patiënten en PTE sluiting van de fistuleuze communicatie werd verricht in 12% van de gevallen. Gebaseerd op de vergelijking met de bevindingen van Rittenhouse, werd geconcludeerd dat de pathogenese van fistels een tendens toonde in de richting van de verworven etiologie en dat de PTE sluiting techniek bezig is terrein te winnen als behandelingsmethode bij patiënten met coronaire fistels.

In hoofdstuk 3B, worden de klinische en angiografische bevindingen van zeven volwassen patiënten met coronaire-camerale fistels (CCFs) bestudeerd. Er is sprake van een coronaire-camerale fistel (CCF), congenitaal of verworven, wanneer een fistel uitmondt in een van de vier hartcompartimenten; de oorsprong van het vaat segment kan enkel of multipel zijn met bijdrage van één, twee of drie (uni-, bi- of multilaterale) kransslagaders. De congenitale coronaire arterie-ventriculaire multipele micro-fistels monden echter uit met multipele kleine vaatjes, hoofdzakelijk in de linker en in mindere mate in de rechter ventrikel; de oorsprong is

multipel uit het mid-distaal kransslagader segment met bijdrage van één, twee of drie (uni-, bi- of multilaterale) kransslagaders.

De zeven CCFs waren geassocieerd met significante coronaire atherosclerose (5 patiënten) of secundair aan een myocard infarct (post-infarct, 2 patiënten). Geen van de patiënten onderging therapeutische endovasculaire procedures vóór de ontdekking van de fistel. Bij vier patiënten werden significante vernauwingen van de "fistula-gerelateerde" kransslagader gevonden en totale occlusie van de "fistula-gerelateerde" kransslagader werd geconstateerd bij 3 patiënten. Goed ontwikkelde collateralen werden aangetoond bij 4 patiënten en waren angiografisch ongedetecteerd bij 3 patiënten. Bij 3 patiënten was het infarct gelokaliseerd in hetzelfde territorium van de "fistula-gerelateerde" kransslagader. In onze huidige serie (7 patiënten), werden 2 patiënten medicamenteus behandeld, een coronaire bypass operatie werd verricht bij 3 patiënten; één patiënt onderging de PTCA procedure van een aanwezige vernauwing van een niet "fistula-gerelateerde" kransslagader en één patiënt overleed tijdens het wachten op CABG.

Vierendertig volwassen patiënten met verworven coronaire fistels werden verzameld uit de huidige literatuur (1971-1996). De coronaire fistels vertegenwoordigden verschillende pathogenetische etiologieën. De behandeling van deze onderzochte patiënten was vergelijkbaar met die van onze serie. Achttien procent van deze patiënten vertoonde spontane sluiting van de coronaire fistel.

Er kan worden geconcludeerd dat verworven coronaire fistels complicerend kunnen zijn in het verloop van ernstig coronaire atherosclerose of na het doormaken van een hartinfarct. Deze verworven coronaire fistels kunnen worden beschouwd als collateralen die hun richting hebben verloren naar het bestemde hartspier segment dat in gevaar is. Ook de mechanismen, verantwoordelijk voor het ontstaan van deze fistuleuze communicaties, worden in hoofdstuk 3B uiteengezet. De symptomatologie, de distributie van de betrokken kransslagaders en de therapeutische modaliteiten zijn vergelijkbaar in de congenitale en verworven entiteiten. Een onbeantwoorde vraag is of ook bij patiënten met verworven fistels endocarditis profylaxe is geïndiceerd, zoals reeds aanbevolen bij patiënten met congenitale fistels.

In hoofdstuk 3C, worden de angiografisch morfologische aspecten van de congenitale coronaire fistels bij 19 volwassen patiënten gepresenteerd. De morfologische verschijning van de fistels toonde grote spreiding variërend van een klein discreet vaatje tot een hoog gecompliceerde plexus met een netwerk van multi-pele fijne vaatjes. In deze serie, bestond de fistel uit een enkel vaatje in 70% en uit multi-pele fijne vaatjes in 30% van de fistels. De fistel mondde uit via een enkel vaatje in 65%, via een aneurysmatische verwijding in 22% en via een multi-pele plexus van netwerk in 13% van de fistels. Één patiënt ontwikkelde een ipsilateraal hartinfarct. Bij deze patiënt, waren de oorsprong, de uitmonding en het "fistelpad" samengesteld uit multi-pele vaatjes. Aneurysma vorming was aanwezig bij 26% van de fistels, hierbij waren het "fistelpad" en/of de uitmonding betrokken. Aneurysma vorming werd niet gezien bij de oorsprong van de fistels. Naast de morfologische aspecten worden ook de angiografische diagnostische criteria in hoofdstuk 3C besproken.

Coronaire fistels kunnen vaak worden geassocieerd met aneurysma vorming van de fistuleuze vaatjes. In hoofdstuk 3D, zijn de coronair angiografische karakteristieken beschreven van 10 patiënten met verworven (4 patiënten) en congenitale (6 patiënten) kransslagader aneurysmata geassocieerd met CAFs. In vergelijking tot de "congenitale" groep (52.2 jr) lag de gemiddelde leeftijd bij de "verworven" groep hoger (64.7 jr).

In de "verworven" groep waren ipsilaterale hartinfarcten overheersend aanwezig (75%). Er werd gevonden dat een aneurysmata voorkeursplek bestaat in het proximale gedeelte van het aneurysma-gerelateerde bloedvat in de "congenitale" groep, maar in de "verworven" groep langs de gehele lengte van het aneurysma-gerelateerde bloedvat. Hoewel de congenitale aneurysmata solitair waren en behoorlijk groot van omvang, waren de verworven aneurysmata multipel en frequent geassocieerd met vasculaire complicaties. Bij de "congenitale" groep, waren alle aneurysmata van het sacculaire type. In de "verworven" groep werd dit type slechts in 71% van de gevallen gevonden. In de "verworven" groep was significante coronair hartziekte aanwezig bij alle patiënten, maar bij slechts de helft van de

“congenitale” groep.

Het aantal patiënten is te gelimiteerd om een conclusie te kunnen trekken omtrent de verschillen tussen de aneurysmata geassocieerd met congenitale fistels en verworven aneurysmata. Grotere aantallen patiënten met coronaire aneurysmata zijn noodzakelijk om verdere zaken als angiografische karakteristieken van congenitale en verworven aneurysmata te kunnen schetsen, of om differentiatie tussen beide types en optimale behandelstrategieën te kunnen vaststellen.

Vervolgens worden in hoofdstuk 4 de bevindingen van de cardiovasculaire magnetische resonantie (CMR) techniek uiteengezet. CMR is een nieuwe veelbelovende methode welke wordt gebruikt voor cardiovasculaire diagnostiek. De hypothese is dat CMR niet alleen uitgebreide anatomische beelden van de fistels kan tonen maar ook een aantal hoogwaardige fysiologische parameters kan verschaffen. Deze hypothese werd getest door de resultaten van CMR imaging met de door angiografische studie (gouden standaard) gedetecteerde congenitale solitaire coronaire fistels bij 13 volwassen patiënten (14 fistels) uit de Dutch Registry met elkaar te vergelijken. Deze patiënten gaven geschreven toestemming tot deelname aan het onderzoek. De initiële CMR beeldvorming confirmeerde de aanwezigheid van de fistel bij 10 (77%) patiënten. Bij revisie van CMR beelden, werden 2 additionele patiënten herkend, hiermee kwam het totale aantal op 12. Bij het overgrote deel van de patiënten kon met CMR de oorsprong, het fistelpad en de uitmonding van de fistel worden aangegeven. Ook tortuositeit van de fistelpaden werd m.b.v. CMR gespecificeerd bij 12 van de 13 patiënten. Enkel- of meervoudigheid werden met CMR bij alle patiënten gevonden, ook aneurysma vorming bij 3 van de 4 en verwijding van “fistel-gerelateerde” kransslagaders bij alle patiënten.

CMR demonstreerde potentiële mogelijkheid om tortuositeit (79%) te herkennen en meervoudigheid van de fistelpaden (57%) en van de oorsprong van de fistels (93%) te detecteren.

Additionele CMR data betreffende flow meting werden verkregen bij 8 patiënten. Gemiddelde snelheden werden gemeten van 10 m/sec (bereik 1.2 – 36); de gemiddelde flow door een fistel was 0.55 l/min (bereik 0.02 – 3.8).

De gemiddeld gemeten CMR diameter van de fistuleuze vaatjes was 6.3 mm (bereik 3 -15) vergeleken met de angiografisch bepaalde diameter van 6.2 mm (bereik 1 -16). De periode tussen het verrichten van CAG en CMR was variërend van 1-112 maanden met een mediaan van 3 maanden.

Het falen om de fistel te identificeren van 1 van de patiënten kan worden toegeschreven aan de kleine diameter van het fistelvaatje (1 mm) welke klinisch irrelevant bleek te zijn.

CMR wordt een steeds belangrijker non-invasieve diagnostiek en detectie techniek om de morfologie en fysiologie van coronaire fistels te bepalen, maar het uitvoeren ervan blijft een tijdrovende activiteit.

In hoofdstuk 5, wordt de behoefte aan een Dutch Registry uiteengezet. 5A- geeft de argumenten voor de noodzaak van het initiëren en opzetten van een DR aan. 5B- Beschrijft de huidige situatie omtrent CAFs in Nederland. De angiografisch gediagnosticeerde congenitale coronaire fistels bij een volwassen populatie gepresenteerd. De incidentie van coronaire fistels is niet exact bekend. Er werd een vragenlijst gezonden naar alle coronair angiografie centra in Nederland om antwoord te geven betreffende de incidentie van coronaire fistels. De respons van deze centra bedroeg 43%. Van de responderende centra, waren bij 48% coronaire fistels gerapporteerd. Gegevens over het jaarlijkse aantal coronaire fistels en het aantal coronaire angiogrammen werden verkregen van 78% van de respondenten. In deze survey, was de incidentie van coronaire fistels 0.22%. Dit correspondeerde goed met de gegeven cijfers in de literatuur. 5C en 5D- In appendices I en II worden de gebruikte formulieren “case report forms” en de participerende Nederlandse hartcentra getoond.

Congenitale coronaire fistels kunnen worden ingedeeld in twee hoofdtypes; solitaire en multipiele micro-fistels. De angiografische morfologie van oorsprong, uitmonding en fistelpad verschillen naar gelang het type. De klinische manifestatie en geslachtspredilectie zijn niet hetzelfde. De resultaten van de Dutch Registry voor deze twee types zijn uiteengezet;

congenitale solitaire coronaire fistels bij volwassenen (hoofdstuk 6) en congenitale coronaire arterie-ventriculaire multipiele micro-fistels bij volwassenen (hoofdstuk 7).

In hoofdstuk 6, worden gegevens van 51 patiënten met congenitale solitaire coronaire fistels beschreven. Deze patiënten zijn opgenomen in de Dutch Registry (DR) en werden verzameld uit 28 catheterisatie laboratoria uit een totaal van 30.829 catheterisatiepatiënten. Van deze 51 patiënten waren er 33 mannen (65%) en 18 vrouwen (35%) met een gemiddelde leeftijd van 60.3 jr (bereik van 29-85 jr). Alle fistels waren congenitaal van oorsprong en de meerderheid was niet geassocieerd met andere congenitale hart aandoeningen.

Van deze patiënten viel 69% in de leeftijd distributie groep van ouder dan 50 jr en 31% had een leeftijd van tussen de 20 en 50 jr. Bij presentatie was 16% van de patiënten asymptomatisch en 84% symptomatisch. Als klinische presentatie waren angina pectoris, kortademigheid, vermoeidheid en hartfalen vertegenwoordigd. Bij auscultatie van het hart was typisch continu hartgeruis hoorbaar bij 22% van de patiënten. Acht patiënten van de DR maakten een myocard infarct door. Een myocard infarct aan dezelfde kant van de coronaire fistel werd gevonden bij 1 patiënt. Hierbij was een relatie aanwezig tussen de fistula-gerelateerde en infarct-gerelateerde arterie.

Het ECG toonde pathologische veranderingen aan bij 57% van de patiënten. Hartafwijkingen waren te zien op de thorax-foto bij 13 patiënten; 9 van deze vertoonde cardiomegalie.

In de huidige databank werden bij 51 patiënten 63 coronaire fistels vastgesteld. Van deze fistels, waren er 41 unilateraal (80%), 8 bilateraal (16%) en 2 multilateraal (4%). Bij deze angiografische groep, was aneuysmata vorming van de fistuleuze communicaties duidelijk zichtbaar bij 29% van de fistels dat wel zeggen bij 35% van de patiënten.

We beschreven twee verschillende morfologische types van de oorsprong en uitmonding van de fistels. Verder werden 3 verschillende types "fistelpaden" geïdentificeerd. In de groep van de DR werd gevonden dat 73% van de oorsprong der fistels samengesteld was uit een enkel vaatje en 27% had multipiele vaatjes, wat de uitmonding betreft waren deze percentages respectievelijk 67 % en 33%. Met betrekking tot de "fistelpaden", vertoonde 56% tortuoos/multipiele fijne vaatjes, 41% tortuoos/enkel vaatje en bij 3% van de fistels was de uitmonding straight met een enkel solitair vaatje.

De behandeling van deze patiënten uit de Dutch Registry was bij 36 (70%) van de gevallen volgens conservatieve medische maatregelen. Vijf patiënten werden gevolgd met de "behoedzaam afwachten" strategie en 31 patiënten werden medicamenteus behandeld. Sluiting van de fistels door middel van chirurgische procedures werd verricht bij 13 patiënten (25%) en sluiting door middel van percutane therapeutische embolizatie werd uitgevoerd bij 2 patiënten. De cardiale sterfte in de DR bedroeg 4% in een periode van 5 jaar follow-up.

Afsluitend worden in hoofdstuk 7 de congenitale coronary artery-ventricular multipiele micro-fistulas (CA-VMMFs) bij volwassenen behandeld. Congenitale CA-VMMFs bij volwassenen, zijn infrequente anomalieën, die worden gedefinieerd als multipiele micro-fistula tussen een of meer kransslagaders en de hartkamer (s). De echte incidentie hiervan is niet bekend. Dit huidige rapport beschrijft de klinische en angiografische bevindingen van patiënten met zulke anomalieën. We identificeerden 20 volwassen patiënten met 31 CA-VMMFs van de databank van de Dutch Registry (totaal 71 fistel patiënten) in de periode van 1996 tot en met 2003. Dit betrof een coronaire angiografische populatie van 30.829 patiënten uit 28 Nederlandse cardiologische klinieken. Klinische gegevens (patiënten gegevens, klinische presentatie, lichamelijk onderzoek, reden voor angiografie, niet invasief en invasief onderzoek, behandeling en follow-up) werden retrospectief verzameld en de individuele coronaire angiografie films werden onafhankelijk opnieuw geanalyseerd ten behoeve van de beschrijving van fistel morfologie (aantal betrokken kransslagaders, oorsprong, uitmonding, "fistelpad", dilatatie van de coronaire fistel-gerelateerde arterie en van kamer(s)) en de uitgebreidheid van de atherosclerotische veranderingen van de kransslagaders. Een significante vernauwing in een vat werd geconstateerd als een belangrijke vernauwing aanwezig was ten opzichte van het naburige segment. In tegenstelling tot de solitaire types, werd de oorsprong van CA-VMMFs mid-distaal of distaal gevonden in het verloop van het fistel-gerelateerde vat.

De gemiddelde leeftijd was 67.3 jr (bereik van 49 tot 82). Vrouwen zorgden voor 65% (13/20) van de microfistels populatie. Drie patiënten waren asymptomatisch, 17 patiënten hadden wel symptomen. Twaalf presenteerden zich met stabiele angina pectoris, atypische thoracale pijn werd gevonden bij 3 en hartfalen was aanwezig bij 2 patiënten. Angina pectoris en kortademigheid samen waren aanwezig bij 70% van de patiënten. In aanwezigheid van CA-VMMFs, angina pectoris en myocard infarct ontwikkelde zich bij normaal coronair arterieel systeem. Het te verwachten diastolisch hartgeruis was afwezig terwijl systolisch hartgeruis was te horen bij slechts 7 patiënten.

Het ECG liet een pathologische Q-golf, een litteken van een oud myocard infarct en STT-segment afwijkingen zien bij 15/20 patiënten. Op de thorax-foto werd cardiomegalie gezien bij vijf van de dertien patiënten. Bij alle patiënten lag de oorsprong van de fistel distaal, behalve bij één patiënt, deze had een proximale oorsprong. Atherosclerotische vernauwing van de kransslagaders was te zien bij 9/20 patiënten. Vijf patiënten hadden een myocard infarct (MI), voorwand (anterior) lokalisatie bij 2 en onderwand (inferior) bij 3. Twee van hen hadden een oud MI en 3 patiënten werden opgenomen met een acuut MI. Het MI was gelokaliseerd aan dezelfde kant van de fistel bij 3 en aan de tegenovergestelde kant bij 2 patiënten. Alle patiënten werden medicamenteus behandeld. Tijdens follow-up van 62±41 maanden, overleed één patiënt aan de gevolgen van chronisch hartfalen op 78 jarige leeftijd. Geen van de patiënten ontwikkelden recidief of nieuw MI.

CA-VMMFs kunnen angina pectoris, en in mindere mate MI veroorzaken bij afwezigheid van atherosclerotische veranderingen. De oorsprong van de fistels ligt in het midden dan wel aan het distale segment van de kransslagader.

Een typische patiënt is een vrouw van omstreeks vijftig jaar die wordt opgenomen met angina pectoris zonder hoorbaar hartgeruis en met een inconclusief niet-invasief onderzoeksresultaat. Dit geeft aanleiding tot invasief onderzoek voor vermeende atherosclerotische kransslagaderlijke aandoeningen. De pathofysiologie moet nog worden opgehelderd.

Het diffuse karakter van de aandoening maakt het niet toegankelijk voor permanente sluiting door middel van percutane therapeutische embolizatie technieken maar wel voor conservatief medisch beleid. Hoofdstuk 7 vergelijkt dus de eerder gepubliceerde literatuurgegevens en onderzoekt de gezichtspunten die verdere analyse nodig hebben met betrekking tot de CA-VMMFs.

#### Hoofdstuk 8

De Dutch Registry, ofschoon gelimiteerd door het beperkte aantal patiënten, toonde bij volwassenen de aanwezigheid van twee op zichzelf staande entiteiten van congenitale kransslagader fistels. Er werden twee hoofd types onderscheiden; solitaire en multipole micro-fistulas.

De klinische en angiografische data van beide types werden systematisch uiteengezet en geanalyseerd. De wetenschappelijke waarde van dit proefschrift beoogt om de aandacht van de huidige en toekomstige angiografisten te trekken voor vroege herkenning en ontdekking van coronaire fistels en ze op weg te helpen om vast te stellen wat de juiste therapeutische mogelijkheden zijn.

Gebaseerd op de data van de Dutch Registry, kunnen er nog geen conclusies worden getrokken met betrekking tot de optimale behandelmethode van de kransslagader fistels met middelmatige shuntgrootte.

De verkregen gegevens zijn van patiënten die gediagnosticeerd en behandeld werden op een niet gerandomiseerde wijze en waarbij sommige gegevens gedeeltelijk incompleet waren. Zoals men mag verwachten bij een registry, waren sommige belangrijke patiënten gebonden karakteristieken blijkbaar niet geschikt voor analyse. Deze omvatten de volgende onderdelen: fietstest, echocardiografie en stress MIBI scintigrafisch onderzoek.

# Toekomstperspectieven

## Vragen voor verder onderzoek

In deze studie hebben we ons beperkt tot het beschrijven van de klinische aspecten en de angiografisch morfologische kenmerken van de coronaire fistels (CAFs). In een niet onaanzienlijk percentage van de solitaire CAFs (39%) en MMFs (45%) patiënten werd coronaire atherosclerose geconstateerd. Nader onderzoek naar de relatie tussen CAFs en atherosclerose is buitengewoon moeilijk.

Uit onze en andere studies is gebleken dat een niet onaanzienlijk deel van de patiënten aneurysmatische manifestatie vertoont. Een relevante onderzoeksvraag is om de oorzaken, prognose op langetermijn en de complicaties van aneurysmatische manifestatie vast te stellen. Dit kan geschieden door middel van non-invasief onderzoek bijvoorbeeld CMR of echocardiografische methode.

Een tweede mogelijke onderzoeksvraag is een prospectief gerandomiseerd (nationaal, Europees of internationaal) onderzoek naar de therapeutische opties van CAFs met in acht nemen van de morfologische aspecten van de verschillende componenten van de fistel.

Een derde interessante onderzoeksvraag is of genetische analyse van patiënten en de familieleden van patiënten met congenitale CAFs meer informatie zal opleveren om de aandoening eerder te kunnen diagnosticeren en te behandelen.

Een laatste onderzoeksvraag betreft de invloed van pre-interventie determineren van flow eigenschappen, gerelateerd aan de klachten en L-R shunt, om de grootte van de fistel en de hemodynamische significantie te bepalen, op de keuze van de therapeutische mogelijkheden (chirurgische of percutane behandeling). Hiervoor kan men gebruikmaken van Doppler velocity wire and CMR.

## Publications of the author

### 1987

- Bonnier JJRM, Said SAM, Bartholomeus I. Follow-up in patients with acute myocardial infarction after fibrinolytic therapy with intravenous APSAC or intracoronary streptokinase. *European Heart Journal* 1987; 8 (suppl II):396
- Ciampricotti R, El Gamal M, Said S, van Gelder B, Bonnier J. Myocardial infarction and sudden death after sport: Acute angiographic findings. *Circulation* 1987; 76 (Abstr):361

### 1989

- Said S. Doppler echocardiographic findings in coronary-pulmonary fistula. *Int J Cardiol* 1989; 25:343-6
- Said SAM, El Gamal M. Prolonged fifteen year survival with acquired rupture of interventricular septum post myocardial infarction. *Neth J Cardiol* 1989; 2:107-8

### 1990

- Said SAM, Relik Th, Tan-Go I. Doppler echocardiographic features in biopsy-proved cardiac amyloidosis. *Neth J Cardiol* 1990; 3:105-9
- Said SAM, Landman GHM. Coronary-pulmonary fistula: Long-term follow-up in operated and non-operated patients. *Int J Cardiol* 1990; 27:203-10
- Said SAM, Relik Th. An unusual cause of non-sustained ventricular tachycardia in an athlete. *Neth J Cardiol* 1990; 3:143-7
- Ciampricotti R, El Gamal M, Bizouati G, Relik T, El Deeb F, Bonnier J, Said S, de Swart J, van Gelder B. Acute and late outcome of coronary angioplasty at bifurcation lesions. *European Heart J* 1990; (suppl II):363

### 1991

- Said SAM, Troquay RPT, Tan-Go I. Cardiac complications of Wegener's granulomatosis: Acute and late manifestations. *Neth J Cardiol* 1991; 2:60-3
- Said SAM, Werner HA, Veerbeek A, Herweyer TJ, Schuilenburg RM. Echocardiographic visualization of coronary aneurysms in the mucocutaneous lymph node syndrome (Kawasaki disease). *Neth J Cardiol* 1991; 3:92-7
- Said SAM, Veerbeek A, van der Wieken LR. Dextrocardia, situs inversus and severe mitral stenosis in a pregnant woman: successful closed commissurotomy. *European Heart J* 1991; 12:825-8
- Said SAM, Werner HA, Veerbeek A. Coronary-cameral fistula in association with intracardiac tumour and aortic stenosis in an adult. *Int J Cardiol* 1991; 33:159-62
- Said SAM, Bucx JJJ. Coronary angiographic observations; coronary atherosclerosis and myocardial infarction in coronary-pulmonary fistula. *Neth J Cardiol* 1991; 4:237-41

### 1992

- Said SAM, Bucx JJJ, Brune DF, Austermann-Kaper T. Coronaire arterioveneuze fistel: een "hartedief" van jong en oud. *Nederlands Tijdschrift voor Cardiologie* (in Dutch) 1992; 6:3-9
- Said SAM, Bucx JJJ. Exercise-induced ventricular tachycardia during oral flecainide therapy. *Neth J Cardiol* 1992; 1:32-6
- Said SAM, Bucx JJJ, van de Weel FA. Stress MIBI scintigraphy in multiple coronary-pulmonary fistula: failure to demonstrate the 'steal' phenomenon. *Int J Cardiol* 1992; 35:270-272
- Said SAM, Bucx JJJ, Stassen CM. Failure of subclavian venipuncture: the internal jugular vein as a useful alternative. *Int J Cardiol* 1992; 35:275-278



- Said SAM, Bucx JJJ, van de Weel FA. Coronary-cameral fistula in association with Klinefelter syndrome: exercise-induced ventricular tachycardia late after surgical ligation. *Int J Cardiol* 1992; 36:111-114
- Said S, Bucx J, Brune D, Austermann-Kaper T. Outcome of conservative strategy in asymptomatic patients with coronary-pulmonary fistulas. *European Heart Journal* 1992; 13 (suppl):332

### **1993**

- Said SAM, Bucx JJJ, Austermann-Kaper T, Hamburg RF. Delayed pericardial effusion with tamponade following left internal mammary artery graft: successful bedside pericardiocentesis. *Neth J Cardiol* 1993; 1:46-48
- Said SAM, Bucx JJJ, Wesseling FJH, Stassen CM, Greefhorst APM, ten Berge EJFM, Wester A and van de Weel FA. Intrapulmonary arterial thrombolysis in massive pulmonary embolism associated with pseudo-myocardial infarction in three patients. *Neth J Cardiol* 1993; 2:85-89
- Said SAM, Raymakers JTFJ, Heijmans GJ, Verhoog BD, Wesseling FJH. Post-pneumonectomy acute cardiac herniation presented with precordial low-voltage ECG and shock. *Neth J Cardiol* 1993; 3:181-183
- Said SAM, Austermann-Kaper T, Bucx JJJ. Congenital coronary arteriovenous fistula associated with atrioventricular valvular regurgitation in an octogenarian. *Int J Cardiol* 1993; 38:96-97
- Said SAM, Bucx JJJ, Dankbaar H, Huizing G, van Gilst WH. Ibopamine-induced reversible leukopenia during treatment for congestive heart failure. *European Heart J* 1993, 14:999-1001
- Said SAM, Oude Luttikhuis HA, Somer ST. Acute pancreatitis presenting as an acute anterolateral myocardial infarction. *Neth J Cardiol* 1993; 6:382-384
- Said SAM. Coronary angiographic characteristics of congenital and acquired coronary arteriovenous fistulas in 17 adults. Abstract and oral presentation at the Egyptian Society of Cardiology 1993; 22:22-23

### **1994**

- Said SAM, Somer ST, Oude Luttikhuis HA. Flecainide-induced JT prolongation, T wave inversion and ventricular tachycardia during treatment for symptomatic atrial fibrillation. *Int J Cardiol* 1994; 44:285-287
- Said SAM, Somer ST, Bloemendaal K. Dissecting aneurysm of the ascending aorta: An uncommon complication of CABG. *Cardiologie* 1994; 1:103-105

### **1995**

- Said SAM, Somer ST, Creemers J, Sutorius FFJM, van der Bij W. Cardiac complications of multisystem histiocytosis X. *Cardiologie* 1995; 2:248-252
- Said SAM, El Gamal MIH. Coronary angiographic morphology of coronaryarteriovenous fistulas in adults: Report of four new cases and review of angiograms offifteen reported cases. *Cathet Cardiovasc Diagn* 1995; 35:29-35

### **1996**

- Said SAM, Bloemendaal K. Successful CABG in association with congenital arteriovenous malformation (AVM) of the anterior chest wall. *Cardiologie* 1996; 3:151-3
- Said SAM, van Rooijen H, Brunekreeft W. Adaptive mode switching using a new DDD pacemaker with Tachy Fall-back Rate. *Vitatext* 1996; 1:12-13
- Said SAM, van Driel BA, Onrust A. Pacemaker twiddler's syndrome: Delayed transection of permanent ventricular lead. Letters to the Editor. *European Heart Journal* 1996; 17:1911-1915

### **1997**

- Said SAM, Crijns HJGM. Late proarrhythmic effects of sotalol during treatment for atrial fibrillation. *Cardiologie* 1997; 4:7-10
- Said SAM, Geeraedts LGM. Ventriculo-venous communications in adults: Ventriculographic observations in two female patients. *Int J Cardiol* 1997; 62:161-5
- Said SAM, Koetsveld-Baart JC. Nonfatal MI associated with patent coronary arteries in a migraine patient using sumatriptan and dihydroergotamine. *Cardiologie* 1997; 4:530-3
- Said SAM, Koetsveld-Baart JC, den Hollander JC. Takayasu's arteritis: a rare cause of cardiac death in a Caucasian teenage female patient. *Neth J Med* 1997; 51:182-186
- Said SAM, El Gamal MIH, van der Werf T. Coronary arteriovenous fistula. Collective review and addition of six new cases. Changing etiology, presentation and treatment strategy. *Clinical Cardiol* 1997; 20:748-52
- Said SAM. Coronary artery fistulas in adult population. Preliminary results of a National Dutch Registry. Book of abstracts Werkgroep Cardiologische Centra Nederland 1997; (B1): 59

### **1998**

- Said SAM, Keeris LM, van Ingen G. A soccer victim: Late rupture of the ascending aorta after violent physical trauma. *Int J Cardiol* 1998; 63:306-312
- Said SAM, Vriesendorp WJS, van der Werf T. Een man met febris intermittens, algehele malaise en diastolisch hartgeruis (in Dutch). *Hart Bulletin* 1998; 29:206-209.
- Said SAM, ten Have K. Coronary artery bypass graft surgery in an adult female patient with dextrocardia and situs inversus totalis. *Cardiologie* 1998; 5:640-642
- Said SAM, Severin WPJ. Acute nonrheumatic myopericarditis associated with group A streptococcal tonsillitis in a male ICU-nurse. *Neth J Medicine* 1998; 53:266-270
- Said S, El Gamal M, van der Werf T. Congenital and atherosclerotic (acquired) coronary artery aneurysms: coronary angiographic and morphologic observations in 10 patients. *Int J Angiology* 1998; 7:206-210
- Said SAM, Relik-van Wely L, van der werf T. Angiographically diagnosed congenital coronary artery fistulas in an adult population. *Cardiologie* 1998; 5:71-73
- Said SAM. Electrocardiografische afwijkingen bij accidentele hypothermie. *Cardiologie* 1998; 5:336
- Said SAM. Asymptomatic left main coronary artery aneurysm in Marfan's syndrome. *Cardiologie* 1998; 5:594

### **1999**

- Said SAM, Severin WPJ. Acute nonrheumatic streptococcal tonsillitis-myopericarditis: *Neth J Medicine* 1999; 54:243-244
- Said SAM, Gerrits CJH, Sutorius FFJM. Transesophageal echocardiographic diagnosis of perforation of anterior mitral valve leaflet secondary to infective endocarditis: anatomical-pathologic confirmation. *Cardiologie* 1999; 6:421-424
- Said SAM. Spontaneous rupture of chordae tendineae in an octogenarian. *Cardiologie* 1999; 6:143
- Said SAM, van der Werf T. Acquired coronary cameral fistulas: Are these collaterals losing their destination? Report of seven adult cases and literature review. *Clinical Cardiol* 1999; 22:297-302
- Said SAM. Electrocardiographic alterations of spontaneous left-sided tension pneumothorax. *Cardiologie* 1999; 6:265-266
- Said SAM. Subtle changes of the ECG in right-sided pneumothorax. *Cardiologie* 1999; 6:519
- Said SAM. ECG alteration of hyperkalemia associated with renal function impairment.

- Cardiologie 1999; 6:615
- Said SAM, Alberink A, Onrust A, Zwieneberg F. Double lead fracture due to the subclavian crush syndrome. Book of abstracts Werkgroep Cardiologische Centra Nederland 1999; (11): 55

### 2000

- Said SAM, Ticheler CHJM. Early pulmonary embolism following transvenous permanent dual chamber pacemaker implantation. Electrocardiographic and scintigraphic evaluation. Cardiologie 2000; 7:21-24
- Said SAM, Crijns HJGM, van der Werf T. Prerequisite conditions for identification of true coronary artery fistula. Cardiologie 2000; 7:23-27

### 2001

- Said SAM, Fast JH, Severin WPJ. Een tevoren gezonde jonge vrouw met koorts, hemoptoe en acuut hartfalen. Hart Bulletin (in Dutch) 2001; 4:106-109
- Said SAM, Suijker WJL. Mechanical complication of inferior myocardial infarction: A large inferior wall pseudoaneurysm. Cardiologie 2001; 8:78-9
- Said SAM. Left ventricular diverticulum. Neth Heart J 2001; 9:244
- Said SAM, Onrust A, Droste HT, Hazelaar H. Pacing in atrial arrhythmia, a case report. Annual meeting of Dutch Working Group on Cardiac Stimulation, 2001, Hengelo.
- Said SAM, Thiadens AAHJ, Fieren MJCH, van der Werf T, Bennink GBWE, Meijboom EJ. Coronary artery fistula: Management and follow-up. World congress of pediatric Cardiology, 2001, Toronto, Canada

### 2002

- Van Gelder IC, Hagens VE, Bosker HA, Kingma JH, Kamp O, Kingma T, Said SA, Darmanata JJ, Timmermans AJM, Tijssen JGP, Crijns HJGM. A comparison of rate control and rhythm control in patients with persistent atrial fibrillation. NEJM 2002; 347:1834-1840
- Said SAM, Thiadens AAHJ, Fieren MJCH, van der Werf T, Bennink GBWE, Meijboom EJ. Isolated Coronary Artery Fistulas: Oral presentation at: The 29<sup>th</sup> annual international conference of the Egyptian Society of Cardiology, February 2002, Alexandria, Egypt
- Said SAM, Thiadens AAHJ, Fieren MJCH, van der Werf T, Bennink GBWE, Meijboom EJ. Coronary artery fistulas: management and follow-up. Scientific meeting of the Netherlands Society of Cardiology, April 2002, Scheveningen
- Said SAM, Thiadens AAHJ, Fieren MJCH, Meijboom EJ, van der Werf T, Bennink GBWE. Coronary artery fistulas. Neth Heart J 2002; 10:65-78
- Said SAM, Fast JH, Droste HT, Onrust A. Does pacemaker output setting influence the chronic value of high impedance lead? Europace Supplements 2002; 3:A259
- Said SAM, Sie HT. Surgical revascularization for 'atherosclerotic' coronary artery aneurysms associated with multiple obstructive coronary artery disease. Neth Heart J 2002; 10:245-249

### 2003

- Said SAM, Sie HT. Revascularisation chirurgicale pour anévrismes coronariens 'athéromateux' associés à des lésions pluitronculaires (in French). J Cardiol 2003; 2:50-54
- Said SAM, Sie HT. Heelkundige revascularisatie voor 'atherosclerotische' aneurysmata van de coronaire arteriën in associatie met meertaks coronair lijden (in Dutch). Tijdschrift Cardiol 2003; 2:50-54

## **2004**

- Said SAM, Fast JH, Stassen CM, Schepers-Bok R, Zijlstra JJ, Dankbaar H, van Driel B, Heijmans HJ. Percutaneous transvenous retrieval of intracardiac port-a-cath catheter fragment: a case report. *Neth Heart J* 2004; 12:117-120
- Said SAM, Droste HT, Baart JC, Klaver MM, Sie HT. Neurological symptoms and cerebro-vascular accidents: manifestations of left-sided cardiac tumours in adults. *Neth Heart J* 2004; 12:504-507
- Eraldo O, Francalacci G, Said S, Droste H, Hofmann R, Bortink M, Vassanelli C, Smit J, Corbucci G. Correlation between right ventricular evoked QT interval and left ventricular systolic interval: a pilot study. *Progress in Clinical Pacing*, December 2004, Rome, Italy

## **2005**

- Said SAM, Ticheler CHJM, Stassen CM, Derks A, Droste HT. Possible Complications of Subclavian Crush Syndrome. *Neth Heart J* 2005; 13:91-96
- Said SAM, Wester A, Brouwer RML, Monnick SHJ, Koning-Mulder WAH, de Vos RAI, van Baarlen J. "Spontaneous" Cholesterol Embolization Syndrome (CES) after Successful Thrombolysis for Acute Myocardial Infarction. *Neth Heart J* 2005; 6:242-243
- Said S, van der Werf T. Dutch survey of coronary artery fistulas in adults: Congenital solitary fistulas. Multi-center observational survey in the Netherlands. Poster presentation at the scientific meeting of the Netherlands Society of Cardiology, April 2005, Amsterdam.
- Said S, Hofman M, van Rossum A, van der Werf T. Feasibility of CMR for detection of angiographically diagnosed congenital solitary coronary artery fistulas. Oral presentation at the Euro CMR meeting, May 2005, Zurich

## **2006**

- Said SAM, Baart JC, de Voogt WG. Pacing for conduction disturbances Steinert's disease: a new indication for biventricular ICD? *Neth Heart J* 2006; 14: 258-262
- Said SAM, Lam J, van der Werf T. Solitary Coronary Artery Fistulas: A Congenital Anomaly in children and adults. *Contemporary Review. Congenit Heart Dis.* 2006; 1:63-76
- Said SAM, van der Werf T. Dutch Survey of Congenital Coronary Artery Fistulas in Adults. *Neth Heart J* 2006; 14: 5-13
- Said SAM, van der Werf T. Dutch survey of coronary artery fistulas in adults: Congenital solitary fistulas. *Int J Cardiol* 2006; 106:323-332
- Said SAM, van der Werf T. Dutch survey of coronary artery fistulas in adults: Congenital coronary artery-left ventricular multiple micro-fistulas. *Int J Cardiol* 2006; 110:33-39
- Said S, van der Werf T. Dutch survey of coronary artery fistulas in adults: Congenital coronary artery-left ventricular multiple micro-fistulas. Oral presentation at the scientific meeting of the Netherlands Society of Cardiology, Amsterdam, April 2006
- Said SAM, Hensens AG. Coronary-Cameral Fistula Associated with Acquired Mitral Stenosis and Left Atrial Thrombus in a Female Adult Patient. *Neth Heart J* 2006; 14:391-392

## **2007**

- Said SAM, H.T. Droste, A. Derks, C.J.H. Gerrits J.H. Fast. Down syndrome associated with severe hypothyroidism and Chronic Pericardial Effusion: Echocardiographic Follow-up in an adult patient. *Neth Heart J* 2007;15:67-70
- Said SAM, Hofman MBM, Beek AM, van der Werf T, van Rossum AC. Feasibility of cardiovascular magnetic resonance for detection of angiographically diagnosed

- congenital solitary coronary artery fistulas. *Journal of Cardiovascular Magnetic Resonance* 2007; 9:1-9
- Basalus M, Said SAM, Stassen CM, Fast JH. Clinical and diagnostic features of partially anomalous pulmonary venous connection in an adult female patient. Case report and review of the literature. *Neth Heart J. In press*
  - Said SAM, de Voogt WG, Soliman Hamad M, Schonberger J. Surgical Treatment of Bilateral Aneurysmal Coronary-Pulmonary Artery Fistulas Associated with Severe Atherosclerosis. *Ann Thorac Surg* 2007; 83:291-293
  - Said SAM, Schroeder-Tanka JM, Mulder BJM. Female Gender and the Risk of Rupture of Congenital Aneurysmal Fistula in Adults. Case report and collective review. *Congenit Heart Disease*. Accepted for publication.
  - Richtlijn "Voorzorgmaatregelen bij jodiumhoudende contrastmiddelen". CBO, kwaliteitsinstituut voor de gezondheidszorg. *In press*

# Dankwoord

Allereerst wil ik mijn promotor professor dr. Tjeerd van der Werf hartelijk bedanken voor het feit dat hij mij de gelegenheid bood om bij hem te promoveren. Tjeerd, bedankt voor je steun, geduld, coaching, vertrouwen en altijd opbouwende kritiek. CAFE, AC wegrestaurant Beekbergen werd omgetoverd tot Academisch Center Beekbergen. Hier vond de meeste discussie plaats waardoor ik heb ervaren hoe het kaf (CAF) van het koren gescheiden wordt.

Het tot stand komen van dit proefschrift kon verder alleen geschieden met de assistentie van vele personen. Het vertrouwen heeft me enthousiast gemaakt en gemotiveerd om de Registry af te sluiten met dit boekje. Gaarne wil ik iedereen bedanken, die op een of andere wijze betrokken was bij de bewerkstelling van dit proefschrift.

Dank aan de cardiologen maatschap van het Sophia Ziekenhuis, Zwolle, bestaande uit Rob Enthoven, Hans Holtkamp, Henk Oude Luttikhuis en Willem Jan Louridtz, die mij daar de mogelijkheid boden om mijn opleiding tot cardioloog te mogen starten.

Met het eerste "case report" samen met mijn opleider Mamdouh El Gamal in het Catharina Ziekenhuis, Eindhoven, was het **START**sein gegeven in Hengelo voor een reeks publicaties in nationale en internationale tijdschriften met uiteindelijk dit proefschrift tot gevolg. Mijn oprechte dank en appreciatie aan de staf en medewerkers van de afdeling cardiologie van het Catharina Ziekenhuis, Eindhoven.

Ria Hamming (†) (met haar onderwater zwemmen bij het programma wordperfect) en Liesbeth Blijdenstein voormalige bibliothecaresse van de medische bibliotheek van het Streeksziekenhuis Midden-Twente, twee belangrijke steunpilaren, waren altijd bereid om te assisteren bij tekstverwerking en literatuurverwerking. Na de fusie met Almelo, waren de steunpilaren Mw. A. Geerdink en de heer G. Maas. Tevens wil ik Richard Rieksen van het streeklaboratorium Oost-Nederland, Enschede hartelijk bedanken voor zijn hulp en assistentie tijdens het voorbereiden van dit proefschrift.

Het secretariaat cardiologie, functieafdeling, verpleegkundigen, laboranten en de leden van de maatschap cardiologie van de Ziekenhuisgroep Twente, locatie Hengelo, Anita Derks, Herman Droste en Jules Fast wil ik van harte bedanken. Ook bedank ik de maatschap cardiologie van het Medisch Spectrum Twente, in het bijzonder Hans Louwerenburg, Elly Wajon en Peter Molhoek en de maatschap cardiologie, ziekenhuisgroep Twente, locatie Almelo voor hun bijdrage. Jullie hulp bij het zoeken naar geschikte patiënten was buitengewoon collegiaal.

De medeauteurs, ben ik zeer erkentelijk voor hun bijdrage aan de verschillende artikelen welke een hoeksteen vormen voor dit proefschrift. De collega's worden in alfabetisch volgorde genoemd: T. Austermann-Kaper (†), Prof.dr. GBWE Bennink, DF Brune, dr. JJJ Bucx, Prof. dr. HJGM Crijns, MIH El Gamal, MJCH Fieren, GHM Landman, EJ Meijboom, L Relik-van Wely, Th. Relik, AAHJ Thiadens, A Veerbeek, WJS Vriesendorp en HA Werner.

Prof. dr. León Eijnsman wil ik bedanken voor het kritisch nakijken van het manuscript (3D) en dr. Willem de Voogt voor het aansporen om fistel patiënten te blijven verzamelen, zelfs in Cairo, Egypte. Dit laatste mondde uit in een case report gepubliceerd in *The Annals of Thoracic Surgery*\*. Dr. Mark Hofman, A.M. Beek en Prof. dr. Bert van Rossum, VUMC wil ik bedanken voor hun bijdrage aan de CMR gegevens.

Gaarne wil ik de leden van de beoordelingscommissie, Prof. dr. J.G. Blickman, Prof. dr. L. Eijnsman en Prof. dr. B.J.M. Mulder, bedanken voor de wetenschappelijke beoordeling van

het manuscript.

Tevens wil ik mijn dank uitspreken aan de paranimfen Jaap Ruiten en Willem de Voogt voor hun steun op deze belangrijke dag.

Rest nog het thuisfront, plezierige rust thuis is onontbeerlijk voor een dergelijke onderneming als deze. Dankzij de rust en kalmte is het uiteindelijk gelukt om dit proefschrift te produceren. Als alles achter de rug is, hoop ik met mijn gezin veel leuke dingen te ondernemen. Een ieder, die ik mocht zijn vergeten, ook bedankt.

\*Surgical Treatment of Bilateral Aneurysmal Coronary-Pulmonary Artery Fistulas Associated with Severe Atherosclerosis. Salah A.M. Said, Willem G. de Voogt, Mohamed Soliman Hamad, Jacques Schonberger. Ann Thorac Surg 2007; 83:291-293.

# Curriculum Vitae

Salah Ali Mohamed Said was born on 23 of December 1953 in Abu Za'bal, Kalyoubia, Egypt. He restarted his medical studies at the Free University of Amsterdam in 1976 and obtained his medical diploma in 1982.

He is married to Mrs. G. Said-Lust and they have two daughters, Sherien (1981) and Ines (1983).

- 1971-1975: Faculty of Medicine, Al-Azhar University, Cairo, Egypt
- 1976-1982: Faculty of Medicine, Free University, Amsterdam, the Netherlands
- 1983-1985: Residency in Internal Medicine, Sophia Hospital, Zwolle (T. Tjabbes, MD, PhD)
- 1985-1986: Residency in Cardiology, Sophia Hospital, Zwolle (R. Enthoven, MD, PhD)
- 1986-1988: Residency in Cardiology, Catharina Hospital, Eindhoven (M. El Gamal, MD)
- 1988-1989: Chef de clinique, Department of Cardiology, Catharina Hospital, Eindhoven
- 1989-1990: Deputy Cardiologist, Onze Lieve Vrouwe Gasthuis, Amsterdam and deputy cardiologist, Elisabeth Gasthuis, Haarlem
- 1990-present: Practicing cardiologist, Hospital Group Twente, location Streekeziekenhuis Midden-Twente, Hengelo
- 1993-present: Active member of Rotary Club Hengelo
- 2001-present: President of the Egyptian Community in the Netherlands
- April 2007: International reviewer of Journal of Clinical Rehabilitative Tissue Engineering Research (CRTER)



