



Since January 2020 Elsevier has created a COVID-19 resource centre with free information in English and Mandarin on the novel coronavirus COVID-19. The COVID-19 resource centre is hosted on Elsevier Connect, the company's public news and information website.

Elsevier hereby grants permission to make all its COVID-19-related research that is available on the COVID-19 resource centre - including this research content - immediately available in PubMed Central and other publicly funded repositories, such as the WHO COVID database with rights for unrestricted research re-use and analyses in any form or by any means with acknowledgement of the original source. These permissions are granted for free by Elsevier for as long as the COVID-19 resource centre remains active.

[†]Servicio de Hemato-Oncología Pediátrica, Hospital Universitario La Paz, Madrid, Spain

* Corresponding author:

E-mail address: ccalvorey@gmail.com (C. Calvo).

Available online 27 April 2020

REFERENCES

1. Wu Z, McGoogan JM. Characteristics of and important lessons from the coronavirus disease 2019 (COVID-19) outbreak in China: summary of a report of 72 314 cases from the Chinese Center for Disease Control and Prevention. *JAMA*. 2020. <http://dx.doi.org/10.1001/jama.2020.2648>.
2. Dong Y, Mo X, Hu Y, et al. Epidemiological Characteristics of 2143 Pediatric Patients With 2019 Coronavirus Disease in China. *Pediatrics*. 2020. <https://doi.org/10.1542/peds.2020-0702>

3. Chen Z, Xiong H, Li JX, et al. COVID-19 With Post-Chemotherapy Agranulocytosis in Childhood Acute Leukemia: A Case Report. *Zhonghua Xue Ye Xue Za Zhi*. 2020;41:E004 <https://doi.org/10.3760/cma.j.issn.0253-2727.2020.0004>
4. Shi S, Qin MM, Shen BB, et al. Association of Cardiac Injury With Mortality in Hospitalized Patients With COVID-19 in Wuhan. *China JAMA Cardiol*. 2020;e200950.
5. Wiseman DH, Mercer J, Tylee K, et al. Management of mucopolysaccharidosis type IH (Hurler's syndrome) presenting in infancy with severe dilated cardiomyopathy: a single institution's experience. *J Inherit Metab Dis*. 2013;36:263–270.
6. Siddiqi HK, Mehra MR. COVID-19 Illness in Native and Immunosuppressed States: A Clinical-Therapeutic Staging Proposal. *J Heart Lung Transplant*. 2020. <http://dx.doi.org/10.1016/j.healun.2020.03.012>.

<https://doi.org/10.1016/j.rec.2020.04.011>
1885-5857/

© 2020 Sociedad Española de Cardiología. Published by Elsevier España, S.L.U. All rights reserved.

COVID-19 and cardiogenic shock. Different cardiovascular presentations with high mortality



COVID-19 y shock cardiogénico: diferentes formas de presentación cardiovascular con alta mortalidad

To the Editor,

Coronavirus disease 2019 (COVID-19) is the clinical manifestation of infection by severe acute respiratory syndrome-related coronavirus 2 (SARS-CoV-2). Patients with this condition usually present with respiratory symptoms that can progress to pneumonia, and severe cases may develop acute respiratory distress syndrome and cardiogenic shock. Information on the etiology and mortality of cardiogenic shock in COVID-19 is currently limited and is the objective of the present study.

Between 1 March and 15 April, 2020, urgent cardiac catheterization was carried out in 23 patients with a suspected ST-elevation acute coronary syndrome or cardiorespiratory arrest. Seven of them (30%) tested positive for COVID-19 by polymerase chain reaction (PCR) in nasopharyngeal exudate. All patients testing negative for COVID-19 were ultimately discharged without complications. Of the 7 testing positive for COVID-19, 2 were discharged, 1 died due to respiratory failure secondary to severe pneumonia, and 4 developed cardiogenic shock immediately after arrival at the hospital. Three of these 4 patients died, yielding a mortality rate of 75% in the context of cardiogenic shock. The clinical, analytical, and imaging features of these patients, the treatment they received, and their clinical courses are summarized in [table 1](#).

The first case was a 42-year-old woman, with no cardiovascular risk factors or comorbidities, who attended the emergency room with symptoms of dyspnea and cough. Minutes later she developed cardiorespiratory arrest in a defibrillation-amenable rhythm, which led to an arrhythmic storm refractory to antiarrhythmic therapy. Echocardiography showed severe biventricular dysfunction. During cardiopulmonary resuscitation in the cardiac catheterization laboratory, a venoarterial extracorporeal membrane oxygenation (VA-ECMO) support system was implanted by peripheral cannulation. Aortography depicted a normal aorta and coronary arteries, and pulmonary angiography ruled out pulmonary thromboembolism ([figure 1A,B](#)). At completion of the procedure, an intra-aortic counterpulsation balloon was implanted to attempt left ventricular unloading, as well as a temporary pacemaker, but the patient died within hours in refractory shock. As the patient tested PCR-positive for COVID-19, the most likely diagnosis was acute fulminant myocarditis.

The second case was a 50-year-old man with no cardiovascular risk factors or comorbid conditions, who was hospitalized for severe bilateral pneumonia due to COVID-19 with a need for mechanical ventilation. A few hours after he was admitted, he suddenly developed severe hypotension (systolic blood pressure, 60 mmHg) with lateral wall ST-segment elevation. Urgent cardiac catheterization showed lesion-free coronary arteries and severe left ventricular dysfunction with contractility changes consistent with stress cardiomyopathy (inverted tako-tsubo), with akinesis of the basal and mid segments, and apical hypercontractility ([figure 1C,D](#)). Left ventricular end-diastolic pressure was 22 mmHg. The patient progressed gradually to distributive shock, requiring ventilation. After 11 days of hospitalization under treatment with hydroxychloroquine, antiretroviral agents, antibiotics, and corticosteroids, he was discharged with normal cardiac contractility.

The third case was a 75 year-old man, with no cardiovascular risk factors or notable comorbidities, who attended the emergency room for symptoms of dyspnea and chest pain. Electrocardiography showed inferior wall ST-segment elevation and complete atrioventricular block. He experienced several episodes of primary ventricular fibrillation requiring electrical cardioversion, as well as orotracheal intubation and mechanical ventilation. Norepinephrine perfusion was started, and primary angioplasty was performed with implantation of a stent in the right coronary artery ([figure 1E,F](#)). The echocardiogram showed biventricular dysfunction with right-sided predominance, and the chest radiograph, bilateral pneumonia. Within a few hours the patient died in electromechanical dissociation, with a diagnosis of right coronary artery thrombosis and bilateral SARS-CoV-2 pneumonia.

Finally, the fourth case was a 37 year-old woman, obese and with a history of deep venous thrombosis, who attended the emergency room for symptoms of dyspnea and chest pain. Troponin I was found to be elevated, and because of her medical history, urgent CT angiography of the pulmonary arteries was performed, which showed bilateral pulmonary thromboembolism with right ventricular dilation, in addition to patchy peripheral opacities compatible with SARS-CoV-2 pneumonia, which was confirmed by PCR ([figure 1G,H](#)). Suddenly, she experienced severe, persistent hypotension and severe oxygen desaturation (peripheral saturation < 80%). Despite administration of systemic thrombolysis, the patient died due to cardiogenic shock without reaching the cardiac catheterization laboratory for possible percutaneous treatment.

As illustrated by these 4 cases, cardiogenic shock can develop suddenly in COVID-19 patients and can have different causes. It is essential to perform a differential diagnosis with a view toward

Table 1
Clinical, analytical, and imaging features, treatment, and outcome of 4 patients with cardiogenic shock complications

	Case 1	Case 2	Case 3	Case 4
Sex	Woman	Man	Man	Woman
Age, y	42	50	75	37
Weight, kg/BMI	50/19.5	66/21.7	65/22.9	120/43
CVRF	Dyslipidemia	None	None	Morbid obesity
Chronic treatment	Drospirenone-ethinyl estradiol 3/0.02 mg (oral contraceptive)	None	None	None
Comorbidities	None	Copper metabolism disorder of unknown origin Benign right mediastinal tumor	None	History of DVT 8 years previously due to immobilization after a fracture
Symptom onset to emergency room admission, d	12	8	2	10
Symptoms	Dyspnea, diarrhea, vomiting, anosmia, and dysgeusia	Fever, dyspnea, and cough	Dyspnea	Fever, dyspnea and chest pain
ECG	Sinus rhythm with recent-onset LBBB	Sinus tachycardia with lateral ST segment elevation, 2 mm	Complete atrioventricular block with inferior ST segment elevation	Sinus tachycardia SI QIII TIII pattern Inconclusive anterior ST segment elevation
Chest radiography	Cardiomegaly. Diffuse bilateral infiltrates	Extensive bilateral lung involvement: faint patchy opacities in the right lung and faint, diffusely increased density of the left lung, predominantly in the middle fields No cardiomegaly	Bilateral parenchymal opacities No cardiomegaly	Increased peripheral density in the right lung base obliterating the costophrenic angle, consistent with peripheral lung consolidation
Echocardiography	LV dilation with severely reduced LVEF and global hypokinesis No pericardial effusion	No LV dilation, akinesis of all basal segments and hypercontractility of mid-apical segments Normal right chambers No pericardial effusion	No LV dilation, inferior basal akinesis with moderate dysfunction Severe RV dilation with severe dysfunction No pericardial effusion	Not done
Catheterization	Coronary arteries normal Pulmonary arteries normal	Coronary arteries normal Ventriculography shows an inverted takotsubo pattern	Thrombotic occlusion of middle segment of the right coronary artery	No time to perform catheterization
Troponin I, ng/mL	70.4 (NV < 0.1)	64.1	500	0.4
BNP, pg/mL	Not available	790.7	2212.4	382
IL-6, pg/mL	Not available	260.2	Not available	50.93
D dimer, ng/mL	4342 (NV < 500)	2442	7530	3128
CRP, mg/L	1	379.5	113.8	82.9
Lymphocytes, 10 ³ /L	8.04	0.80	0.90	1.91
Hemoglobin, g/dL	8	15.6	21.2	13.7
Ferritin, ng/mL	Not available	986.67 (NV 20-300)	Not available	232
Presumptive cardiologic diagnosis	Fulminant myocarditis	Stress cardiomyopathy Inverted takotsubo	Inferior infarction, Killip III	High-risk bilateral PTE
Treatment for COVID-19	No time to establish treatment	Hydroxychloroquine 200 mg/12 h Lopinavir-ritonavir 200/50 mg, 2 tablets/12 h Tocilizumab 400 mg/day Azithromycin 500 mg/day Methylprednisolone 30 mg/day (tapering dose)	Since positive test results for COVID-19, no time to establish treatment	Since positive test results for COVID-19, no time to establish treatment
Anticoagulant / antiplatelet therapy	NFH	No	Aspirin 300 mg and ticagrelor 180 mg* Tirofiban i.v.	Enoxaparin 120 mg/12 h Fibrinolysis with i.v. tPA
Clinical course	Cardiorespiratory arrest CPR maneuvers Arrhythmic storm Refractory VF Cardiogenic shock VA-ECMO and IABC Mechanical ventilation Death	Mixed shock (initially cardiogenic and later septic) Mechanical ventilation Vasoactive support (3 days) Discharged home at 11 days Normalization of contractility changes	Cardiorespiratory arrest Primary VF Primary PCI Cardiogenic shock refractory to vasoactive amines Mechanical ventilation Multiorgan failure Death	Cardiogenic shock Cardiorespiratory arrest and electromechanical disassociation Died following CPR maneuvers

BNP, brain natriuretic peptide; CPR, cardiopulmonary resuscitation; CRP, C-reactive protein; CVRF, cardiovascular risk factors; DVT, deep vein thrombosis; IABC, intra-aortic balloon counterpulsation; i.v., intravenous; LBBB, left bundle branch block; LV, left ventricle; LVEF, left ventricular ejection fraction; NFH, non-fractionated heparin; NV, normal values; PCI, percutaneous coronary intervention; PTE, pulmonary thromboembolism; RV, right ventricle; tPA, tissue plasminogen activator; VA-ECMO, venoarterial extracorporeal membrane oxygenation; VF, ventricular fibrillation;

* Ticagrelor was administered despite knowledge of potential interactions with lopinavir-ritonavir. COVID-19 was diagnosed after the primary PCI.

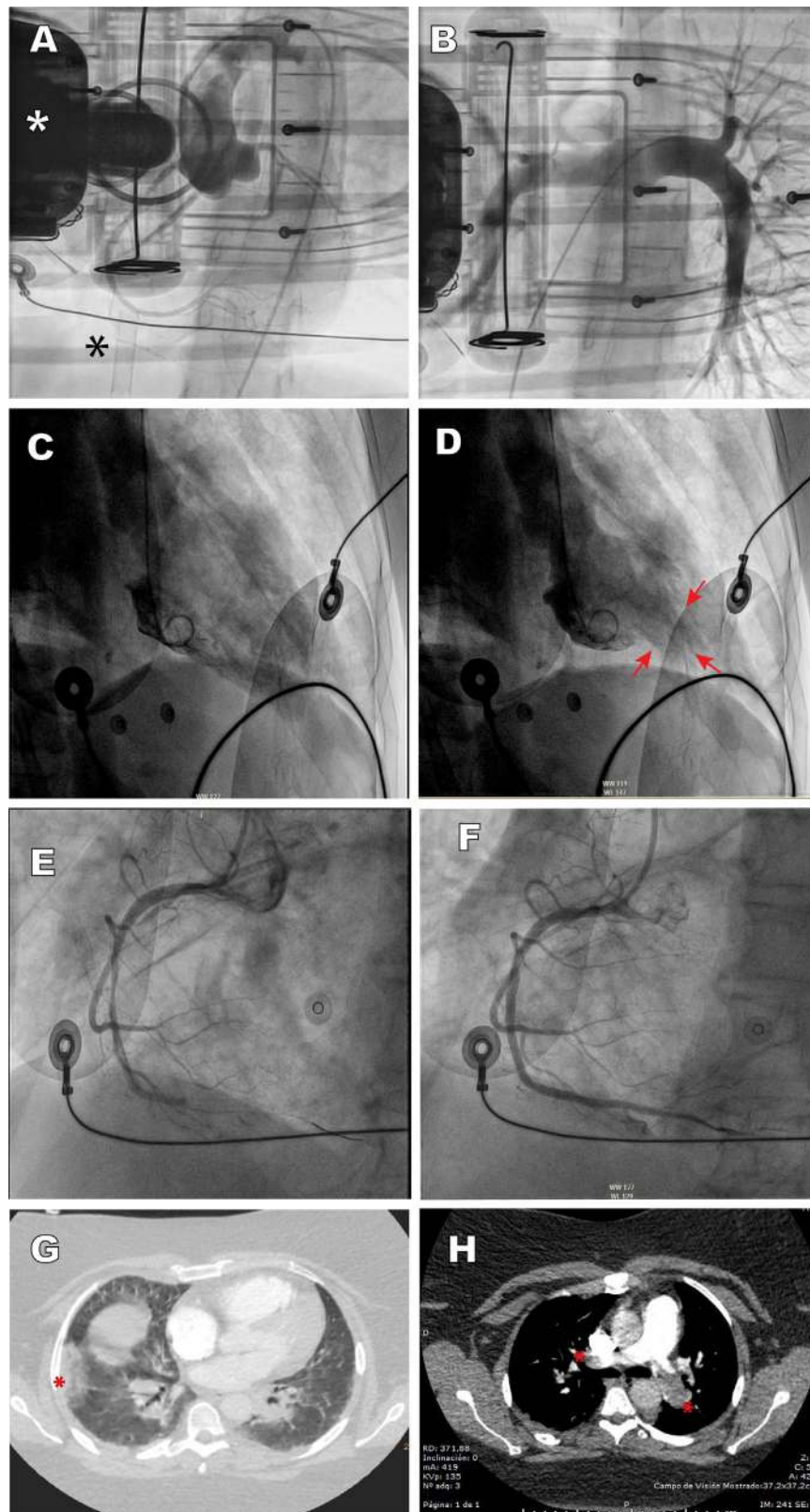


Figure 1. A: case 1, aortography depicts a normal aorta and coronary arteries; the white asterisk indicates the chest compression device, and the black asterisk the venous cannula of the extracorporeal membrane oxygenator. B: case 1, pulmonary angiography shows normal findings. C and D: case 2, ventriculography depicts a pattern consistent with inverted tako-tsubo, diastole and systole; the arrows indicate apical hypercontractility. E and F: case 3, thrombotic occlusion of the mid segment of the right coronary artery and revascularization with stent implantation. G: case 4, CT angiography depicts pulmonary infarction (asterisk) and patchy peripheral opacities consistent with SARS-CoV-2 pneumonia. H: case 4, CT angiography shows thrombotic occlusion of both pulmonary arteries (asterisks). This figure is shown in full color only in the electronic version of the article.

etiological treatment. The general approach includes routine measures, such as infusion of amines or implantation of VA-ECMO as a bridge to recovery.¹ Myocardial inflammation underlies the acute myocarditis, and SARS-CoV-2 particles have recently been demonstrated in the myocardium of these patients.² In addition to respiratory and circulatory support measures, treatment includes the use of corticosteroids and immunoglobulins. Stress cardiomyopathy in COVID-19 may be triggered by catecholamine discharge secondary to hypoxemia or sepsis, by myocardial injury related to the systemic inflammatory process, by direct myocardial infection with the virus, or by a mixture of factors.³ Treatment consists of administration of amines and mechanical support in addition to the other therapeutic measures used in COVID-19 (table 1).

Pulmonary thromboembolism is common in the hypercoagulability state provoked by COVID-19 and can lead to cardiogenic shock with high mortality. All available measures should be applied, such as VA-ECMO, thrombolysis, and percutaneous treatment, particularly if there is a contraindication for thrombolysis or if this measure fails. Another thrombotic complication that can cause cardiogenic shock is the development of acute coronary thrombosis in segments proximal to the main coronary arteries. This case was treated with percutaneous stent placement, as is recommended in the related clinical practice guidelines.

One consideration to mention is the absence of pathological studies in these patients, as they were not allowed in our setting at the beginning of the pandemic.

This limited series illustrates the variety and severity of cardiovascular manifestations in COVID-19 patients, including acute myocarditis, stress cardiomyopathy, acute coronary syndrome, and pulmonary thromboembolism.

CONFLICTS OF INTEREST

Á. Sánchez-Recalde is an associate editor of *Revista Española de Cardiología*. The editorial procedure established in the journal was followed to guarantee impartial management of the manuscript.

Acknowledgements

We thank Dr. Luisa Salido Tahoces, Dr. José Luis Mestre-Barcia, Dr. Rosa Ana Hernández-Antolín, and Dr. Ana Pardo Sanz for their critical assessment and in-depth revision of the manuscript.

Ángel Sánchez-Recalde,^{a,*} Jorge Solano-López,^a Javier Miguelena-Hycka,^b Jesús Javier Martín-Pinacho,^c Marcelo Sanmartín,^a and José L. Zamorano^a

^aServicio de Cardiología, Hospital Universitario Ramón y Cajal, Madrid, Spain

^bServicio de Cirugía Cardiovascular, Hospital Universitario Ramón y Cajal, Madrid, Spain

^cServicio de Radiología, Hospital Universitario Ramón y Cajal, Madrid, Spain

* Corresponding author:

E-mail address: recalde@secardiologia.es (Á. Sánchez-Recalde).

Available online 27 April 2020

REFERENCES

- García-Carreño J, Sousa-Casasnovas I, Devesa-Cordero C, Gutiérrez-Ibañes E, Fernández-Aviles F, Martínez-Sellés M. Reanimación cardiopulmonar con ECMO percutáneo en parada cardiaca refractaria hospitalaria: experiencia de un centro. *Rev Esp Cardiol*. 2019;72:880–882.
- Tavazzi G, Pellegrini C, Maurelli M, et al. Myocardial localization of coronavirus in COVID-19 cardiogenic shock. *Eur J Heart Fail*. 2020. <http://dx.doi.org/10.1002/ehf.1828>.
- Meyer P, Degrauwe S, Van Delden C, Ghadri J-R, Templin C. Typical takotsubo syndrome triggered by SARS-CoV-2 infection. *Eur Heart J*. 2020. <http://dx.doi.org/10.1093/eurheartj/ehaa306>.

<https://doi.org/10.1016/j.rec.2020.04.012>
1885-5857/

© 2020 Sociedad Española de Cardiología. Published by Elsevier España, S.L.U. All rights reserved.

Pulmonary infarction secondary to pulmonary thromboembolism in COVID-19 diagnosed with dual-energy CT pulmonary angiography



Infarto pulmonar secundario a tromboembolia pulmonar en COVID-19 diagnosticada con angiotomografía computarizada pulmonar con energía dual

To the Editor,

We report the cases of 2 patients from Barcelona, Spain, admitted to the emergency department of our hospital secondary to COVID-19 (formerly known as SARS-CoV-2) pneumonia, confirmed with a real-time reverse-transcription polymerase chain-reaction test^{1,2}; both patients showed respiratory deterioration and elevated serum D-dimer levels. Figure 1 illustrates the case of a 32-year-old man, with no comorbidities or risk factors, admitted to our emergency department on day 14 after symptom onset with dry cough, asthenia, arthromyalgia, fever, and right pleuritic pain. A baseline electrocardiogram showed sinus rhythm, 97 bpm, normal PR interval (120 ms) and normal QRS complex (80 ms), aQRS 0°. QTc (Friderica) 415 msec. Echocardiography was not performed but initial physical examination showed systemic blood pressure values of 136/79 mmHg, regular rhythm with no murmurs, present and symmetrical distal pulses, and no signs of

deep vein thrombosis. Laboratory data showed elevated ferritin levels (615 ng/mL), C-reactive protein (CRP) = 3.6 mg/dL, and increased interleukin-6 (IL-6) (144.7 pg/mL). Coagulation studies: prothrombin time (PT) 12 seconds, international normalized ratio 1.1, partial thromboplastin time (aPTT) 28.2 seconds. Lupus anticoagulant testing was positive. Immunoglobulin G and immunoglobulin M anticardiolipin antibodies were also tested with a negative result. D-dimer levels were elevated up to 2460 ug/L and therefore, due to high suspicion of pulmonary thromboembolism, dual-energy pulmonary computed tomography (CT) angiography (CTPA) was performed. CTPA confirmed bilateral thromboembolism associated with multiple opacities compatible with viral pneumonia (figure 1A,B). Iodine map images showed a triangular peripheral pulmonary infarction (figure 1C).

The patient received therapy with hydroxychloroquine at a loading dose of 400 mg on the first day followed by a maintenance dose of 200 mg/d for the next 4 days. Azithromycin 500 mg/d for 3 days and enoxaparin 80 mg/12 h for 10 days were also prescribed. Throughout the admission, the patient showed clinical improvement with no respiratory support requirements, maintaining oxygen saturation levels around 97% to 99% on room air. On the 10th day after admission, 24 days after symptom onset, the patient was discharged with good health status and was asymptomatic. Given the positivity to lupus anticoagulant auto-antibodies, thrombophilia testing will be performed in 3 months. A