



Clinical research

CRAVT: a prospective, randomized study comparing transvenous cryothermal and radiofrequency ablation in atrioventricular nodal re-entrant tachycardia

G.P. Kimman, D.A.M.J. Theuns, T. Szili-Torok, M.F. Scholten, J.C. Res, L.J. Jordaens*

Department of Clinical Electrophysiology, Thorax Centre, Erasmus MC, Room D307, dr Molewaterplein 40, 300 CA Rotterdam, The Netherlands

Received 13 April 2004; revised 14 June 2004; accepted 1 July 2004
Available online 24 August 2004

KEYWORDS

Catheter ablation;
Cryothermal;
Arrhythmia;
Tachycardia;
Supraventricular

Background Transvenous catheter ablation of atrioventricular nodal re-entrant tachycardia (AVNRT) with radiofrequency (RF) is effective and safe, but carries a 1–3% incidence of early and potentially late heart block. Cryotherapy can create transient effects, and identify potentially successful ablation sites and decrease the risk for permanent heart block.

Methods In this prospective, randomized trial 102 patients with recurrent narrow QRS-complex tachycardia suggestive of AVNRT were randomized to either RF or cryoablation before a diagnostic study.

Results In 63 patients with AVNRT, 33 were randomized to RF and 30 to cryoablation. Procedural success was achieved, respectively, in 30 (91%) patients in the RF and 28 (93%) in the cryoablation group. The median number of cryothermal applications was significantly lower than the number of RF applications (2 versus 7, $p < 0.005$). No accelerated junctional rhythm was seen with cryotherapy, while it was present in 31/33 RF patients. Both fluoroscopy and procedural times were comparable. The radiological position of the successful site in relation to anatomical landmarks was slightly different ($p < 0.05$). No cryotherapy related complications were observed, and no permanent AV conduction disturbances occurred. During a mean follow up of 13 ± 7 months long-term clinical success was seen in one additional patient in each group. In the same period, 3 patients in both groups experienced recurrent AVNRT.

Conclusion Cryoablation is as effective and safe as RF for AVNRT. Significantly fewer applications are necessary, with comparable procedure times. This makes cryotherapy useful for the treatment of tachyarrhythmias near the compact AV node.

© 2004 Published by Elsevier Ltd on behalf of The European Society of Cardiology.

Introduction

Catheter-based radiofrequency (RF) energy has become the preferred modality for tachyarrhythmia ablation

* Corresponding author. Tel: +31 104632699; fax: +31 104632701.
E-mail address: l.jordaens@erasmusmc.nl (L.J. Jordaens).

and has proven to be highly effective in the treatment of atrioventricular nodal re-entrant tachycardias (AVNRT), accessory pathway tachycardias, atrial flutter, focal atrial fibrillation, and ventricular tachycardias. However, lesions created by RF energy inevitably involve some degree of tissue disruption, are irreversible and thrombogenic.^{1–3} During ablation of the slow pathway in AVNRT, and of (para)septally located accessory pathways, there is an increased risk of right bundle branch block or inadvertent complete AV-block, as these pathways run in close proximity to the atrioventricular node.^{4–10} Applications should be delivered during sinus rhythm and not during tachycardia, because of the risk of catheter dislodgement at termination of the tachycardia.

Because freezing (cryotherapy) has the ability to reversibly demonstrate loss of function of tissue with cooling at less negative temperatures (ice mapping), and because progressive ice formation at the catheter tip causes adherence to the adjacent tissue, this ablation method potentially has advantages over RF ablation for safe ablation, even during tachycardia.¹¹ Therefore, cryotherapy could be especially useful in AVNRT and (para)septally located accessory pathways, to reduce the risk of inadvertent right bundle branch block, or complete AV-block.^{12–14} The purpose of this prospective, randomized, single centre study was to compare cryothermal and RF ablation in AVNRT. We hypothesized that cryoablation is as effective as RF, that it is a safe method, and in comparison with RF ablation less applications will be necessary, with no occurrence of complete AV-block or thrombo-embolic complications.

Methods

Consecutive patients with recurrent narrow QRS-complex tachycardia, suggestive for AVNRT were enrolled. All patients signed informed consent and were randomized by an independent institution (Cardialysis) to either cryothermal or RF ablation before the baseline electrophysiological study. All antiarrhythmic drugs were discontinued for a duration of 5 half-lives. A standard electrophysiological study was performed. One bipolar catheter and two quadripolar catheters were inserted into the right femoral vein and advanced to the high right atrium, His bundle position, and right ventricular apex, respectively. A decapolar catheter was positioned in the coronary sinus via the left subclavian vein. A detailed measurement of the AV junction in relation to radiological hallmarks was made on the CAAS II system (delineation of the His bundle, and its relation and distance to the os of the coronary sinus). Images of this position were stored in three radiological views: anteroposterior (AP), right anterior oblique (RAO 30), left anterior oblique (LAO 30). Incremental atrial and ventricular pacing and extra stimulus testing were performed, with determination of the anterograde and retrograde effective refractory periods (ERP) of the AV node, as well as the Wenckebach point, and the stable 2:1 AV-block interval. Diagnosis of dual AV nodal pathways (AH-jump) and AVNRT was made on the basis of standard diagnostic criteria. If sustained tachycardia could not be induced, isoproterenol and eventually atropine were infused to facilitate tachycardia.

Ablation

The target in both ablation techniques was slow pathway ablation guided by a combination of intracardiac electrogram criteria and anatomical landmarks.¹⁵ Catheter positioning and handling was performed during continuous fluoroscopy. The target position was labelled in the 3 mentioned radiological planes, with the His bundle and coronary sinus catheter as references. The endpoint was non-inducibility of AVNRT.

For RF ablation, a 7Fr 40–60 mm curve, 4 mm tip catheter (Conductr, Medtronic, Minneapolis, USA) was used with a conventional electrosurgical generator (Atakr II, Medtronic, Minneapolis, USA) as a source of radiofrequency energy. Each application was started with power set at 10 W; if AV conduction was preserved, the power was increased up to 40 W until a maximum of 65 °C was reached. Fluoroscopy was used throughout each application. For cryoablation, a 7 Fr 53 mm curve, 4 mm tip catheter (Freezor 3, Cryocath Technologies, Montréal, Canada) was used, and a CCT2 CryoConsole (Cryocath Technologies, Montréal, Canada). Initially, ice mapping was performed by cooling to –30 °C for a maximum of 60 s. Fluoroscopy was applied until a stable temperature of –30 °C was reached. During these 60 s, atrial extra stimulus testing was performed. Disappearance of an AH-jump, termination or non-inducibility of AVNRT was considered to be an identification of a potentially successful ablation site, and ablation was subsequently performed by cooling to –75 °C for a 4 min period to create a permanent lesion. If there was no clear AH-jump, and AVNRT was difficult to induce at baseline, prolongation of the anterograde AV refractory period during atrial extra stimulus testing during ice mapping was used to identify a target site.

In both the cryotherapy and RF group, inducibility of AVNRT was tested after each application, and if non-inducible, repeated after a 30 min waiting period. Conduction and ERP-intervals were measured again. Procedure time was measured from the moment of arrival of the patient at the EP lab until the end of the treatment, including the 30 min waiting period.

Follow-up

After ablation, all patients received an event recorder for 3 months to transmit an ECG during symptoms and were seen at the out patient clinic. One year after the procedure all patients were approached by telephone and asked about recurrent palpitations.

Statistical analysis

Continuous variables were expressed as mean \pm standard deviation. Non-parametric data were compared using the Mann-Whitney *U* test. The level of significance was set at $p < 0.05$.

Results

A total of 102 patients were enrolled in this study. After baseline study, AVNRT was diagnosed in 63 patients (Fig. 1). Of the remaining 39 patients, 12 had a (para)septally located accessory pathway, and 13 patients suffered

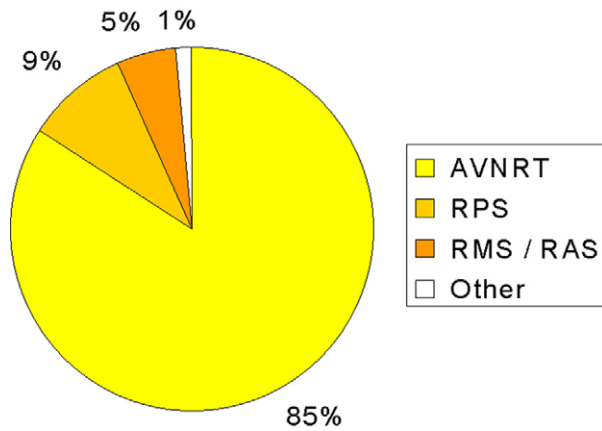


Fig. 1 Diagnosis after baseline electrophysiological study in patients included in the trial and in whom the arrhythmia was located in Koch's triangle. Atrioventricular nodal re-entrant tachycardia (AVNRT), right posteroseptal pathways (RPS); right midseptal and anteroseptal pathways (RMS/RAS). Other, focal tachycardia.

from other circus movement tachycardias. Atrial flutter was the target arrhythmia in 3 patients; in another 3 patients it was a focal atrial tachycardia, and in 8 patients arrhythmias were non-inducible. Of the 63 patients with AVNRT, 33 were randomized to RF and 30 to cryoablation before baseline EP study (Table 1). There were 10 men and 23 women in the RF group with a mean age of 44 years. The cryotherapy group consisted of 14 men and 16 women with a mean age of 52 years. Successful ablation was achieved in 30 (91%) patients in the RF and 28 (93%) in the cryotherapy group, respectively (Table 1). The median number of ice maps (applications until -30°C) was 5. The median number of applications in the cryotherapy group was significantly lower than in the RF group, namely 2 versus 7 ($p < 0.005$). The median fluoroscopy time was 35.2 min in RF and 29.2 min in the cryotherapy group and was not significantly different. The procedure times were also comparable with both techniques, namely 144 min in the RF and 142.5 min in the cryotherapy group. Furthermore, there were no differences in electrophysiological characteristics before and after the procedure in both groups (Table 2). One patient in the RF group had a pericardial effusion (due to the right ventricular lead positioning), which resolved after

Table 1 Results of radiofrequency (RF) and cryoablation in AVNRT

	RF ablation	Cryoablation
Number of patients (N)	33	30
Male/female (N/N)	10/23	14/16
Procedural success (N; %)	30 (91%)	28 (93%)
Ice maps (median, N)	—	5(2–42)
Fluoroscopy time (median, min)	35.2	29.2
Procedural time (median, min)	144	142.5
Applications (median, N)	7 (1–31)	2 (1–13) [*]
Complications	0	0

^{*} $p < 0.05$.

Table 2 Conduction intervals and refractory periods before and after ablation

	Radiofrequency		Cryotherapy	
	Before	After	Before	After
PR interval (ms)	160 ± 33	157 ± 24	158 ± 21	157 ± 24
AH interval (ms)	91 ± 25	91 ± 19	83 ± 21	88 ± 21
HV interval (ms)	42 ± 12	41 ± 7	42 ± 8	41 ± 7
ERP _{AVN} (ms)	279 ± 67	270 ± 69	248 ± 52	263 ± 44
Wenckebach (ms)	356 ± 71	359 ± 64	340 ± 73	332 ± 66
2:1 AV block (ms)	306 ± 45	312 ± 47	301 ± 45	295 ± 51
ERP _{VA} (ms)	274 ± 80	256 ± 70	262 ± 49	251 ± 57
VA block (ms)	331 ± 84	318 ± 63	318 ± 70	306 ± 54

ERP, effective refractory period; AVN, atrioventricular node (antegrade); VA, atrioventricular node (retrograde).

drainage. No other procedural complications were seen. In one patient in the RF group a temporary PR prolongation was registered for the duration of a few beats. In the cryotherapy group, 2 patients had temporary complete AV-block, lasting 10 and 13.4 s, while this was not observed during cryomapping (Fig. 2). Transient AV-block was observed during icemapping in 2 patients, and 2:1 block in one during mapping while in AVNRT. No permanent AV conduction disturbances were seen. During RF applications, a fast junctional rhythm was observed in all but 2 patients in the successful application; it was

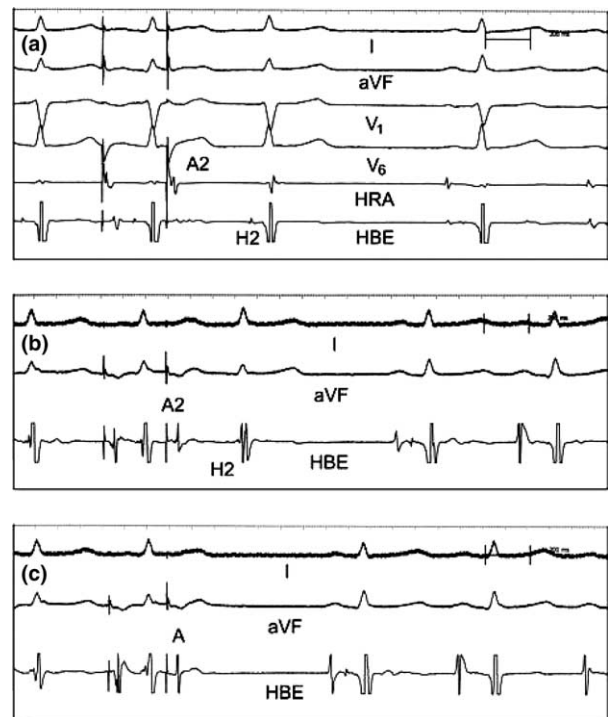


Fig. 2 Programmed electrical stimulation in the high right atrium (HRA) at baseline (a) and after ice mapping was started (b and c). In A, conduction of the extra stimulus A2 is conducted over the slow pathway (A2H2 interval 360 ms). When ice mapping is started A2H2 is conducting over a faster path, 240 ms in B, and AV conduction is blocked in panel C. This sign that the fast pathway is preserved can be used to start ablation.

Table 3 Follow-up of patients treated with radiofrequency (RF) or cryoablation in AVNRT

	RF ablation	Cryoablation
Number of patients (N)	33	30
Duration of follow up (months)	12.9 (1–22)	11.7 (1–22)
Long-term success after failed 1st procedure (N)	1	1
Acute success (N; %)	31 (94%)	29 (97%)
Recurrence of AVNRT (N)	3	3

never seen during cryotherapy. The radiological position of the ablation tip at the successful site was different between both approaches in the RAO 30° angle. The median distance in systole between ablation tip and the vertical perpendicular line from the His bundle distal tip electrode was 12.7 mm for RF and 4.5 mm for cryotherapy ($p < 0.05$). The distance with the coronary sinus os in horizontal axis also showed a similar difference ($p < 0.05$). During a mean follow-up of 12.9 ± 6.3 months in the RF and 11.7 ± 7.0 in the cryotherapy group, long-term clinical success was seen in 2 patients (one in each group) after a failed procedure (Table 3). In the same period 3 patients in each group experienced recurrent AVNRT. One patient of the RF group had recurrent palpitations due to atrial fibrillation.

Discussion

AVNRT is the most common regular narrow QRS complex tachycardia in humans. Nowadays, RF catheter ablation is the treatment of choice in patients with recurrent episodes of AVNRT. Although RF ablation is highly successful, the success rate is not 100% and a risk of an inadvertent RBBB or complete AV-block still exists.^{4–10} Because cryothermal energy has the ability to create temporary lesions (ice mapping), prospective ablation sites can be investigated, before a definitive, and irreversible lesion is created.^{11–14} Theoretically, this should lead to less applications and abolish the risk for permanent conduction disturbances. On the other hand, it still remains to be proven that cryotherapy is as effective as RF both during the procedure and in long-term follow-up. In this study, the acute success rate of both cryoablation and RF ablation was comparable. There was no difference in the median number of ice maps in the cryotherapy group in comparison with the number of applications in the RF group. However, the number of real applications in the cryotherapy group was significantly lower than the number of applications in the RF group. This can be explained by the characteristics of cryoenergy. Ice mapping provides a tool to investigate prospective ablation sites. In both techniques these sites are initially chosen by the same kind of intracardiac electrograms and anatomical landmarks. However, if during ice mapping, AVNRT is still inducible and/or an AH jump is still present, ice mapping is terminated and no ablation will be carried out. So, no irreversible lesions

are created. On the contrary, with RF, ablation is immediately performed on the grounds of the same markers, almost immediately causing irreversible tissue damage. This more precise delivery of therapy with cryotherapy results in less tissue damage (less applications), together with the formation of homogenous fibrosis with a well demarcated border.¹⁶ This makes cryotherapy, in contrast to RF, potentially less proarrhythmic. Earlier studies with RF in AVNRT suggested at least a relationship with the late occurrence of atrial flutter.^{15,17–19} No persisting conduction disturbances were observed in either group, and no thrombo-embolic complications occurred. During long-term follow up a comparable number of patients in both groups had recurrent AVNRT (see Fig. 3).

Observations with cryotherapy

At this time the cryocatheter is not as manoeuvrable as a conventional RF catheter, and this could limit the proper positioning of the cryoablation catheter. A question that still remains is whether cooling to -30°C always implies that the observed effect is maximal. In other words, is it possible that this is not cold enough to cause an effect, while theoretically it could be the right spot? Indirect evidence is the observation that while complete AV-block was observed in one case a few seconds after cryoablation was started, this conduction delay was not present during ice mapping. Full recovery of AV conduction occurred within a few seconds of termination of cryoablation. This is in-line with an observation that most conduction damage recovers very quickly after freezing.²⁰ Furthermore, during an earlier study with cryoablation, we observed that, especially in left posteroseptally located accessory pathways, ice mapping did not always interrupt or modify pre-excitation, while cryoablation at the same spot could still be successful.¹⁴ An explanation for this observation could be a deeper or even epicardially located accessory pathway. On the other hand, as tissue temperature rises away from the centre, tissue effects that occur late during a cryo-application are expected to be reversible. This could mean that more precise mapping is necessary, or that delivery of more energy, e.g., with larger tips, is necessary. At this moment no definitive conclusion can be made, and more experimental studies are needed to provide an answer to these observations. The fact that we did find a slight radiological difference underscores the importance of cryomapping.

Fluoroscopy

Finally, because of cryo-adherence of the cryocatheter, an important asset could be a diminished fluoroscopy time. In this study there was only a tendency in favour of cryotherapy. The relatively long fluoroscopy time can be explained by the fact that ablation was carried out in the ‘old fashioned’ way by continuous fluoroscopy, and not directed by a navigation system, such as Loca-

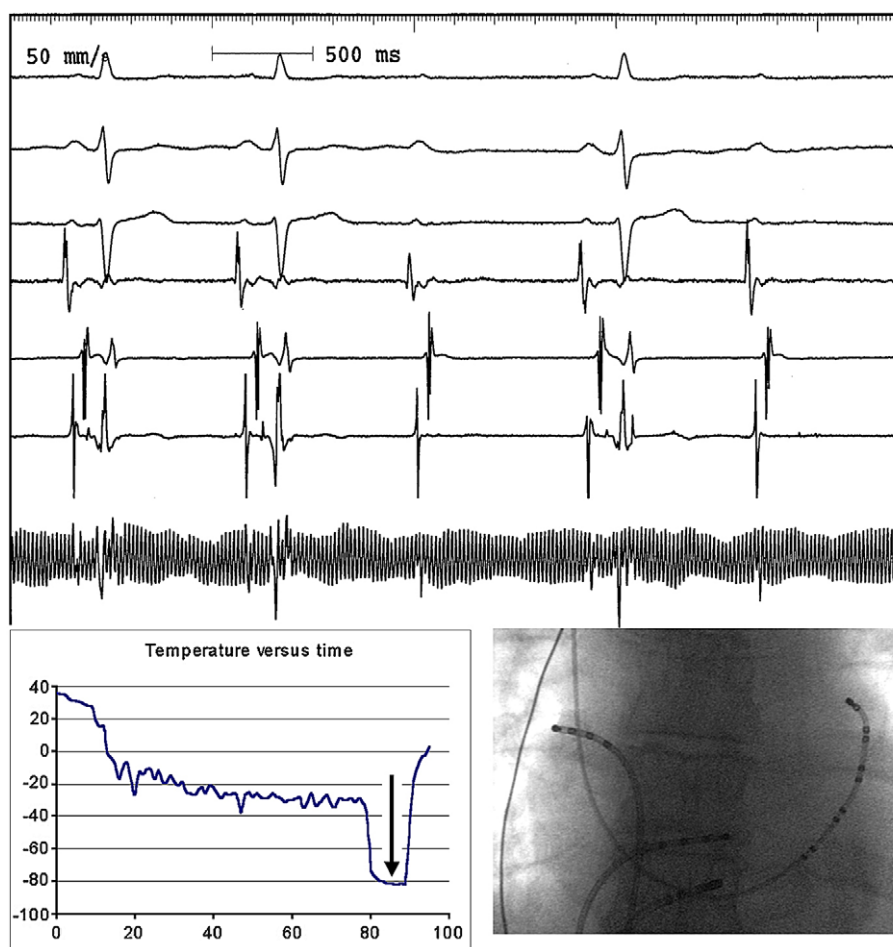


Fig. 3 Onset of temporary complete AV block with cryoablation (leads I, aVF, V1, HRA, proximal CS, His and ablation signal). During ice mapping (-30°C) AVNRT could no longer be induced and normal AV conduction was present. However, after 7 s of cryoablation (-80°C) heart block was seen. Freezing was discontinued. This temporary AV block lasted for 17 s. Inserted is the temperature–time curve of the cryoconsole, and the position of the ablation and his catheter in anteroposterior view. The arrow points to the moment that the block starts.

Lisa.²¹ Furthermore, catheter handling during ablation was mostly done by less experienced physicians, with the senior electrophysiologist operating the EP lab. Indeed, a learning curve was seen, as fluoroscopy time was decreasing during the course of the study.

Conclusion

This study showed that, in AVNRT, cryotherapy is as effective and safe as RF – both acutely and chronically. Procedures are comparable in length, and results remain similar during long-term follow-up. No persisting conduction disturbances or thrombo-embolic complications occurred. The lower number of applications also makes it attractive for other sites in the heart, as less collateral damage will occur. It is the only method potentially targeting the slow pathway on an electrophysiological basis, offering a way to avoid the fast pathway. The fact that no accelerated junctional rhythm is seen with cryotherapy is another argument to believe that this energy

form is safer.²² There is a potential for cryotherapy to replace RF, or to be used as an alternative for ablation of (para)septal circus movement tachycardia and also for pulmonary vein isolation, to create lesions that are deeper and transmural, without the danger of creating pulmonary vein stenosis.²³ With the reversibility, it is an excellent teaching tool.

Acknowledgements

We thank G.A. van Es, Cardialysis, Rotterdam, for the randomization and support. Cryocath provided an educational grant for this study.

References

- Madrid AH, del Rey JM, Rubi J et al. Biochemical markers and cardiac troponin I release after radiofrequency catheter ablation: approach to size of necrosis. *Am Heart J* 1998;136:948–55.

2. Anfinson OG, Gjesdal K, Brosstad F et al. The activation of platelet function, coagulation, and fibrinolysis during radiofrequency catheter ablation in heparinized patients. *J Cardiovasc Electrophysiol* 1999;**10**:503–12.
3. Anfinson OG, Gjesdal K, Aass H et al. When should heparin preferably be administered during radiofrequency catheter ablation. *Pacing Clin Electrophysiol* 2001;**24**:5–12.
4. Hindricks G. On behalf of the Multicenter European Radiofrequency Survey (MERFS) investigators of the Working Group on Arrhythmias of the European Society of Cardiology. Incidence of complete atrioventricular block following attempted radiofrequency catheter modification of the atrioventricular node in 880 patients. *Eur Heart J* 1996;**17**:82–8.
5. Lipscomb KJ, Zaidi AM, Fitzpatrick AP. Slow pathway modification for atrioventricular node re-entrant tachycardia: fast junctional tachycardia predicts adverse prognosis. *Heart* 2001;**85**:44–7.
6. Fenelon G, Malacky T, Manios E et al. Radiofrequency ablation of atrioventricular node reentrant tachycardia: fast or slow pathway ablation. In: Farr J, Moro C, editors. *Ten years of radiofrequency catheter ablation*. Armonk: Futura Pub Cy; 1998. p. 103–14.
7. Willems S, Weiss C, Shenasa M et al. Optimized mapping of slow pathway ablation guided by subthreshold stimulation: a randomized prospective study in patients with recurrent atrioventricular nodal reentrant tachycardia. *J Am Coll Cardiol* 2001;**37**:1645–50.
8. Pelargonio G, Fogel RI, Knilans TK et al. Late occurrence of heart block after radiofrequency catheter ablation of the septal region: clinical follow-up and outcome. *J Cardiovasc Electrophysiol* 2001;**12**:56–60.
9. Fenelon G, d'Avila A, Malacky T et al. Prognostic significance of transient complete atrioventricular block during radiofrequency ablation of atrioventricular node reentrant tachycardia. *Am J Cardiol* 1995;**75**:698–702.
10. Elhag O, Miller HC. Atrioventricular block occurring several months after radiofrequency ablation for the treatment of atrioventricular nodal reentrant tachycardia. *Heart* 1998;**79**:616–8.
11. Dubuc M, Talajic M, Roy D et al. Feasibility of cardiac cryoablation using a transvenous steerable catheter. *J Interv Cardiovasc Electrophysiol* 1992;**2**:285–92.
12. Skanes AC, Dubuc M, Klein GJ et al. Cryothermal ablation of the slow pathway for the elimination of atrioventricular nodal reentrant tachycardia. *Circulation* 2000;**102**:2856–60.
13. Skanes AC, Yee R, Krahn AD et al. Cryoablation of atrial arrhythmias. *Cardiovasc Electrophysiol Rev* 2002;**6**:383–8.
14. Kimman GP, Szili-Torok T, Theuns DAMJ et al. Comparison of radiofrequency versus cryotherapy catheter ablation of septal accessory pathways. *Heart* 2003;**89**:1091–2.
15. Haissaguerre M, Gaita F, Fischer B et al. Elimination of atrioventricular nodal reentrant tachycardia using discrete slow potentials to guide application of radiofrequency energy. *Circulation* 1992;**85**:2162–75.
16. Khairy P, Chauvet P, Lehmann J et al. Lower incidence of thrombus formation with cryoenergy versus radiofrequency catheter ablation. *Circulation* 2003;**107**:2045–50.
17. Kalbfleish SJ, El-Atassi R, Calkins H et al. Association between atrioventricular node reentrant tachycardia and inducible atrial flutter. *J Am Coll Cardiol* 1993;**22**:80–4.
18. Interian A, Cox MM, Jimenez RA et al. A shared pathway in atrioventricular nodal reentrant tachycardia and atrial flutter: implications for pathophysiology and therapy. *Am J Cardiol* 1993;**71**:297–303.
19. Kimman GP, Hemel van NM, Jessurun ER et al. Comparison of late results of surgical or radiofrequency catheter modification of the atrioventricular nodal reentrant tachycardia. *Eur Heart J* 1999;**20**:527–34.
20. Friedman PL, Dubuc M, Green M et al. Cryomapping and cryoablation of A-V Nodal reentrant supraventricular tachycardia: results of the Frosty trial (abstract). *Pacing Clin Electrophysiol* 2003;**26**:979.
21. Wittkamp FH, Wever EF, Derksen R et al. LocaLisa: new technique for real-time 3-dimensional localization of regular intracardiac electrodes. *Circulation* 1999;**99**:1312–7.
22. Yu JC, Lauer MR, Young C et al. Localization of the origin of the atrioventricular junctional rhythm induced during selective ablation of slow-pathway conduction in patients with atrioventricular node reentrant tachycardia. *Am Heart J* 1996;**131**:937–46.
23. Tse HF, Reek S, Timmermans C et al. Pulmonary vein isolation using transvenous catheter cryoablation for treatment of atrial fibrillation without risk of pulmonary vein stenosis. *J Am Coll Cardiol* 2003;**42**:752–8.